



Recommendations for Noninvasive Evaluation of Native Valvular Regurgitation

A Report from the American Society of Echocardiography Developed in Collaboration with the Society for Cardiovascular Magnetic Resonance

William A. Zoghbi, MD, FASE (Chair), David Adams, RCS, RDCS, FASE, Robert O. Bonow, MD, Maurice Enriquez-Sarano, MD, Elyse Foster, MD, FASE, Paul A. Grayburn, MD, FASE, Rebecca T. Hahn, MD, FASE, Yuchi Han, MD, MMSc,* Judy Hung, MD, FASE, Roberto M. Lang, MD, FASE, Stephen H. Little, MD, FASE, Dipan J. Shah, MD, MMSc,* Stanton Shernan, MD, FASE, Paaladinesh Thavendiranathan, MD, MSc, FASE,* James D. Thomas, MD, FASE, and Neil J. Weissman, MD, FASE, *Houston and Dallas, Texas; Durham, North Carolina; Chicago, Illinois; Rochester, Minnesota; San Francisco, California; New York, New York; Philadelphia, Pennsylvania; Boston, Massachusetts; Toronto, Ontario, Canada; and Washington, DC*

TABLE OF CONTENTS

| | | | |
|--|-----|--|--|
| I. Introduction | 305 | | |
| II. Evaluation of Valvular Regurgitation: General Considerations | 305 | | |
| A. Identifying the Mechanism of Regurgitation | 305 | | |
| B. Evaluating Valvular Regurgitation with Echocardiography | 305 | | |
| 1. General Principles | 305 | | |
| a. Comprehensive imaging | 306 | | |
| b. Integrative interpretation | 306 | | |
| c. Individualization | 306 | | |
| d. Precise language | 306 | | |
| 2. Echocardiographic Imaging | 306 | | |
| a. Valve structure and severity of regurgitation | 306 | | |
| b. Impact of regurgitation on cardiac remodeling | 307 | | |
| 3. Color Doppler Imaging | 307 | | |
| a. Jet characteristics and jet area | 308 | | |
| b. Vena contracta | 309 | | |
| c. Flow convergence | 309 | | |
| 4. Pulsed Doppler | 310 | | |
| a. Forward flow | 310 | | |
| b. Flow reversal | 310 | | |
| 5. Continuous Wave Doppler | 310 | | |
| a. Spectral density | 310 | | |
| b. Timing of regurgitation | 310 | | |
| c. Time course of the regurgitant velocity | 310 | | |
| 6. Quantitative Approaches to Valvular Regurgitation | 311 | | |
| a. Quantitative pulsed Doppler method | 311 | | |
| b. Quantitative volumetric method | 312 | | |
| c. Flow convergence method (proximal isovelocity surface area [PISA] method) | 312 | | |

From Houston Methodist Hospital, Houston, Texas (W.A.Z., S.H.L., D.J.S.); Duke University Medical Center, Durham, North Carolina (D.A.); Northwestern University, Chicago, Illinois (R.O.B., J.D.T.); Mayo Clinic, Rochester, Minnesota (M.E.-S.); University of California, San Francisco, California (E.F.); Baylor University Medical Center, Dallas, Texas (P.A.G.); Columbia University Medical Center, New York, New York, (R.T.H.); Hospital of the University of Pennsylvania, Philadelphia, Pennsylvania (Y.H.); Massachusetts General Hospital, Boston, Massachusetts (J.H.); University of Chicago, Chicago, Illinois (R.M.L.); Brigham and Women's Hospital, Boston, Massachusetts (S.S.); Toronto General Hospital, University Health Network, University of Toronto, Toronto, Ontario, Canada (P.T.); and MedStar Health Research Institute, Washington, DC (N.J.W.).

The following authors reported no actual or potential conflicts of interest in relation to this document: David Adams, RCS, RDCS, FASE; Robert O. Bonow, MD; Judy Hung, MD, FASE; Stephen H. Little, MD, FASE; Paaladinesh Thavendiranathan, MD, MSc; and Neil J. Weissman, MD, FASE. The following authors reported relationships with one or more commercial interests: Maurice Enriquez-Sarano, MD, received research support from Edwards LLC; Elyse Foster, MD, FASE, received grant support from Abbott Vascular Structural Heart and consulted for Gilead; Paul A. Grayburn, MD, FASE, consulted for Abbott Vascular, Neochord, and Tendyne and received research support from Abbott Vascular, Tendyne, Valtech, Edwards, Medtronic, Neochord, and Boston Scientific; Rebecca T. Hahn, MD, FASE, is a speaker for Philips Healthcare, St. Jude's Medical, and Boston Scientific; Yuchi Han, MD, MMSc, received research support from Gilead and GE; Roberto M.

Lang, MD, FASE, is on the advisory board of and received grant support from Philips Medical Systems; Dipan Shah, MD, MMSc, received research grant support from Abbott Vascular and Guerbet; Stanton Shernan, MD, FASE, is an educator for Philips Healthcare, Inc.; James D. Thomas, MD, FASE, received honoraria from Edwards and GE, and honoraria, research grant, and consultation fee from Abbott; and William A. Zoghbi, MD, FASE, has a licensing agreement with GE Healthcare and is on the advisory board for Abbott Vascular.

Reprint requests: American Society of Echocardiography, 2100 Gateway Centre Boulevard, Suite 310, Morrisville, NC 27560 (E-mail: ase@asecho.org).

Attention ASE Members:

The ASE has gone green! Visit www.aseuniversity.org to earn free continuing medical education credit through an online activity related to this article. Certificates are available for immediate access upon successful completion of the activity. Nonmembers will need to join the ASE to access this great member benefit!

* Society for Cardiovascular Magnetic Resonance Representative.

0894-7317/\$36.00

Copyright 2017 by the American Society of Echocardiography.

<http://dx.doi.org/10.1016/j.echo.2017.01.007>

Abbreviations

| |
|--|
| 2D = Two-dimensional |
| 3D = Three-dimensional |
| ACC/AHA = American College of Cardiology/American Heart Association |
| ARO = Anatomic regurgitant orifice |
| AR = Aortic regurgitation |
| ASE = American Society of Echocardiography |
| CMR = Cardiovascular magnetic resonance |
| CSA = Cross-sectional area |
| CWD = Continuous wave Doppler |
| EROA = Effective regurgitant orifice area |
| LA = Left atrium, atrial |
| LV = Left ventricle, ventricular |
| LVEF = Left ventricular ejection fraction |
| LVOT = Left ventricular outflow tract |
| MR = Mitral regurgitation |
| MV = Mitral valve |
| MVP = Mitral valve prolapse |
| PA = Pulmonary artery |
| PISA = Proximal isovelocity surface area |
| PR = Pulmonary regurgitation |
| PRF = Pulse repetition frequency |
| PV = Pulmonary valve |
| RF = Regurgitant fraction |
| RV = Right ventricle, ventricular |
| RVol = Regurgitant volume |
| RVOT = Right ventricular outflow tract |
| SSFP = Steady-state free precession |
| SV = Stroke volume |
| TEE = Transesophageal echocardiography |
| TR = Tricuspid regurgitation |
| TTE = Transthoracic echocardiography |
| TV = Tricuspid valve |
| Va = Aliasing velocity |
| VC = Vena contracta |
| VCA = Vena contracta area |
| VCW = Vena contracta width |
| VTI = Velocity time integral |

- C. Evaluating Valvular Regurgitation with Cardiac Magnetic Resonance 314
 - 1. Cardiac Morphology, Function, and Valvular Anatomy 314
 - a. Ventricular volumes 314

- b. Correct placement of the basal ventricular short-axis slice is critical 314
 - c. Planimetry of LV epicardial contour 315
 - d. Left atrial volume 315
 - 2. Assessing Severity of Regurgitation with CMR 315
 - a. Phase-contrast CMR 315
 - b. Quantitative methods 315
 - c. Technical considerations 317
 - d. Thresholds for regurgitation severity 317
 - 3. Strengths and Limitations of CMR 317
 - 4. When Is CMR Indicated? 317
 - D. Grading the Severity of Valvular Regurgitation 318
- III. Mitral Regurgitation 318
 - A. Anatomy of the Mitral Valve and General Imaging Considerations 318
 - B. Identifying the Mechanism of MR: Primary and Secondary MR 319
 - 1. Primary MR 319
 - 2. Secondary MR 320
 - 3. Mixed Etiology 321
 - C. Hemodynamic Considerations in Assessing MR Severity 323
 - 1. Acute MR 323
 - 2. Dynamic Nature of MR 323
 - a. Temporal variation of MR during systole 323
 - b. Effect of loading conditions 323
 - c. Systolic anterior MV motion 324
 - 3. Pacing and Dysrhythmias 324
 - D. Doppler Methods of Evaluating MR Severity 324
 - 1. Color Flow Doppler 324
 - a. Regurgitant jet area 324
 - b. Vena contracta (width and area) 328
 - c. Flow convergence (PISA) 328
 - 2. Continuous Wave Doppler 330
 - 3. Pulsed Doppler 330
 - 4. Pulmonary Vein Flow 330
 - E. Assessment of LV and LA Volumes 330
 - F. Role of Exercise Testing 330
 - G. Role of TEE in Assessing Mechanism and Severity of MR 330
 - H. Role of CMR in the Assessment of MR 331
 - 1. Mechanism of MR 331
 - 2. Methods of MR Quantitation 331
 - 3. LV and LA Volumes and Function 331
 - 4. When Is CMR Indicated? 331
 - I. Concordance between Echocardiography and CMR 331
 - J. Integrative Approach to Assessment of MR 332
 - 1. Considerations in Primary MR 334
 - 2. Considerations in Secondary MR 334
- IV. Aortic Regurgitation 334
 - A. Anatomy of the Aortic Valve and Etiology of Aortic Regurgitation 334
 - B. Classification and Mechanisms of AR 335
 - C. Assessment of AR Severity 336
 - 1. Echocardiographic Imaging 336
 - 2. Doppler Methods 336
 - a. Color flow Doppler 336
 - b. Pulsed wave Doppler 336
 - c. Continuous wave Doppler 336
 - D. Role of TEE 340
 - E. Role of CMR in the Assessment of AR 340
 - 1. Mechanism 340
 - 2. Quantifying AR with CMR 340
 - 3. LV Remodeling 342
 - 4. Aortopathy 342
 - 5. When Is CMR Indicated? 342
 - F. Integrative Approach to Assessment of AR 343
- V. Tricuspid Regurgitation 345
 - A. Anatomy of the Tricuspid Valve 345

| | |
|---|-----|
| B. Etiology and Pathology of Tricuspid Regurgitation | 345 |
| C. Role of Imaging in Tricuspid Regurgitation | 345 |
| 1. Evaluation of the Tricuspid Valve | 345 |
| a. Echocardiographic imaging | 345 |
| b. CMR imaging | 345 |
| 2. Evaluating Right Heart Chambers | 345 |
| D. Echocardiographic Evaluation of TR Severity | 350 |
| 1. Color Flow Imaging | 350 |
| a. Jet area | 350 |
| b. Vena contracta | 350 |
| c. Flow convergence | 350 |
| 2. Regurgitant Volume | 352 |
| 3. Pulsed and Continuous Wave Doppler | 352 |
| E. CMR Evaluation of TR Severity | 353 |
| F. Integrative Approach in the Evaluation of TR | 353 |
| VI. Pulmonary Regurgitation | 353 |
| A. Anatomy and General Imaging Considerations | 353 |
| B. Etiology and Pathology | 355 |
| C. Right Ventricular Remodeling | 355 |
| D. Echocardiographic Evaluation of PR Severity | 355 |
| 1. Color Flow Doppler | 355 |
| 2. Pulsed and Continuous Wave Doppler | 356 |
| 3. Quantitative Doppler | 356 |
| E. CMR Methods in Evaluating PR | 358 |
| F. Integrative Approach to Assessment of PR | 358 |
| VII. Considerations in Multivalvular Disease | 360 |
| A. Impact of Multivalvular Disease on Echocardiographic Parameters of Regurgitation | 360 |
| 1. Color Jet Area | 360 |
| 2. Regurgitant Orifice Area | 360 |
| 3. Proximal Convergence and Vena Contracta | 360 |
| 4. Volumetric Methods | 360 |
| B. CMR Approach to Quantitation of Regurgitation in Multivalvular Disease | 360 |
| VIII. Integrating Imaging Data with Clinical Information | 362 |
| IX. Future Directions | 363 |
| Reviewers | 363 |
| Notice and Disclaimer | 363 |

I. INTRODUCTION

Valvular regurgitation continues to be an important cause of morbidity and mortality.¹ While a careful history and physical examination remain essential in the overall evaluation and management of patients with suspected valvular disease, diagnostic methods are often needed and are crucial to assess the etiology and severity of valvular regurgitation, the associated remodeling of cardiac chambers in response to the volume overload, and the characterization of longitudinal changes for optimal timing of intervention. In 2003, the American Society of Echocardiography along with other endorsing organizations provided, for the first time, recommendations for evaluation of the severity of native valvular regurgitation with two-dimensional (2D) and Doppler echocardiography.² Advances in three-dimensional (3D) echocardiography and cardiovascular magnetic resonance (CMR) have occurred in the interim that provide additional tools to further delineate the pathophysiology and mechanisms of regurgitation and supplement current methods for assessing regurgitation severity.³⁻⁶ Furthermore, within this time frame, critical information linking Doppler echocardiographic measures of regurgitation severity to clinical outcome has been published.⁷⁻⁹ This update on the evaluation of valvular regurgitation is a

comprehensive review of the noninvasive assessment of valvular regurgitation with echocardiography and CMR in the adult. It provides recommendations for the assessment of the etiology and severity of valvular regurgitation based on the literature and a consensus of a panel of experts. This guideline is accompanied by a number of tutorials and illustrative case studies on evaluation of valvular regurgitation, posted on the following website (www.asecho.org/vrcases), which will build gradually over time. Issues regarding medical management and timing of surgical interventions are beyond the scope of this document and have been recently updated.¹

II. EVALUATION OF VALVULAR REGURGITATION: GENERAL CONSIDERATIONS

A. Identifying the Mechanism of Regurgitation

Valvular regurgitation or insufficiency results from a variety of etiologies that prevent complete apposition of the valve leaflets or cusps. These are grossly divided into organic valve regurgitation (primary regurgitation) with structural alteration of the valvular apparatus and functional regurgitation (secondary regurgitation), whereby cardiac chamber remodeling affects a structurally normal valve, leading to insufficient coaptation. Etiologies of primary valve regurgitation are numerous and include degeneration, inflammation, infection, trauma, tissue disruption, iatrogenic, or congenital. Doppler techniques are very sensitive, and thus trivial or physiologic valve regurgitation, even in a structurally normal valve, can be detected and occurs frequently in right-sided valves.

It is not sufficient to only note the presence of regurgitation. One is obligated to describe the mechanism and possible etiologies, particularly in clinically significant regurgitation, as these affect the severity of regurgitation, cardiac remodeling, and management.^{7,10,11} The mechanism of regurgitation is not necessarily synonymous with the cause. For example, endocarditis can cause either perforation or valvular prolapse. The resolution (spatial and temporal) of imaging modalities have markedly improved, resulting in identification of the underlying mechanism of regurgitation in the majority of cases. Transthoracic echocardiography (TTE) is usually the first-line imaging modality to investigate valvular regurgitation (etiology, severity, and impact). However, if the TTE is suboptimal, reliance on transesophageal echocardiography (TEE) or CMR would be the next step in evaluating the etiology or severity of regurgitation. Three-dimensional echocardiography has significantly enhanced our understanding of the mechanism of regurgitation and provides a real-time display of the valve in the 3D space. This is particularly evident when imaging the mitral, aortic, and tricuspid valves (TVs) with TEE.

B. Evaluating Valvular Regurgitation with Echocardiography

1. General Principles. TTE with Doppler provides the core of the evaluation of valvular regurgitation severity. Additional methods, echocardiographic (TEE) and nonechocardiographic (computed tomography, CMR, angiography), can be useful at the discretion of examining physicians based on the combination of the potential for these methods to be informative versus their potential risk. This could be particularly important for patients with suboptimal image quality

Table 1 Echocardiographic parameters in the comprehensive evaluation of valvular regurgitation

| | Parameters |
|---|---|
| Clinical information | Symptoms and related clinical findings |
| | Height/weight/body surface area |
| | Blood pressure and heart rate |
| Imaging of the valve | Motion of leaflets: prolapse, flail, restriction, tenting of atrioventricular valves, valve coaptation |
| | Structure: thickening, calcifications, vegetations |
| | Annular size/dilatation |
| Doppler echocardiography of the valve | Site of origin of regurgitation and its direction in the receiving chamber by color Doppler |
| | The three color Doppler components of the jet: flow convergence, VC, and jet area |
| | Density of the jet velocity signal, CW |
| | Contour of the jet in MR and TR, CW |
| | Deceleration rate or pressure half-time in AR and PR, CW |
| | Flow reversal in pulmonary/hepatic veins (MR, TR); in aorta/PA branches (AR, PR) |
| Quantitative parameters for regurgitation | LV and RV filling dynamics (MR, TR) |
| | PISA optimization for calculation of RVol and EROA |
| | Valve annular diameters and corresponding pulsed Doppler for respective SV calculations and derivation of RVol and RF |
| | Optimization of LV chamber quantitation (contrast when needed) |
| 3D echocardiography* | Localization of valve pathology, particularly with TEE |
| | LV/RV volumes calculation |
| | Measured EROA |
| Other echocardiographic data | Automated quantitation of flow and RVol by 3D color flow Doppler [†] |
| | LV and RV size, function, and hypertrophy |
| | Left and right atrial size |
| | Concomitant valvular disease |
| | Estimation of PA pressure |

*If available in a laboratory.

[†]Needs further clinical validation.

and/or whenever there is a discrepancy between the clinical presentation/symptoms and the evaluation by echocardiography. When TTE provides a complete array of good quality data on the regurgitation, little or no additional information may be needed for the clinical care of patients. However, when the quality of the data is in question, or more precise/accurate measurements are required for clinical decision making, advanced imaging has an important role.

There are a number of principles to apply in the evaluation of valvular regurgitation with echocardiography:

a. Comprehensive imaging. All modalities included in the standard TTE evaluation inclusive of M-mode, 2D, and 3D where applicable, pulsed, color, continuous wave Doppler (CWD), and combined qualitative and quantitative assessment contribute to valve regurgitation assessment.

b. Integrative interpretation. While the predictive power for outcome of all the measurements is not equal and is dominated by a few powerful quantitative measures, interpretation should not rely on a single parameter. Single measures are subject to variability (anatomic, physiologic, and operator); a combination of measures and signs should be comprehensively used to describe and report the final assessment of valve regurgitation.

c. Individualization. Recent data show that valve regurgitation measures and signs that appear similar may have different implications in

different etiologies, so that measures and signs require individualized interpretation, taking into account body size, cause of regurgitation, cardiac compliance and function, acuteness or chronicity of the regurgitation, regurgitation dynamics, and hemodynamic conditions at measurement, among others.

d. Precise language. Avoiding imprecision and including detailed and comprehensive observations of the cause, mechanism, severity, location, associated lesions, and cardiac response are required. This language should be standardized and concise. [Table 1](#) summarizes the essential parameters needed in the evaluation of valvular regurgitation with echocardiography.

2. Echocardiographic Imaging. The main goal of echocardiographic imaging is to define the etiology, mechanism, severity, and impact of the regurgitant lesion on remodeling of the cardiac chambers.

a. Valve structure and severity of regurgitation. Competent leaflets are characterized by a sufficient coaptation surface, which approximates 8-10 mm for the mitral valve (MV), 4-9 mm for the TV, and a few millimeters for semilunar valves. Measurement of leaflet coaptation surface is not accurate with TTE. Three-dimensional TEE or other imaging modalities may allow a prediction of regurgitation severity based on leaflet coaptation. Severe regurgitant lesions when noted represent direct signs of large regurgitant orifices. Such

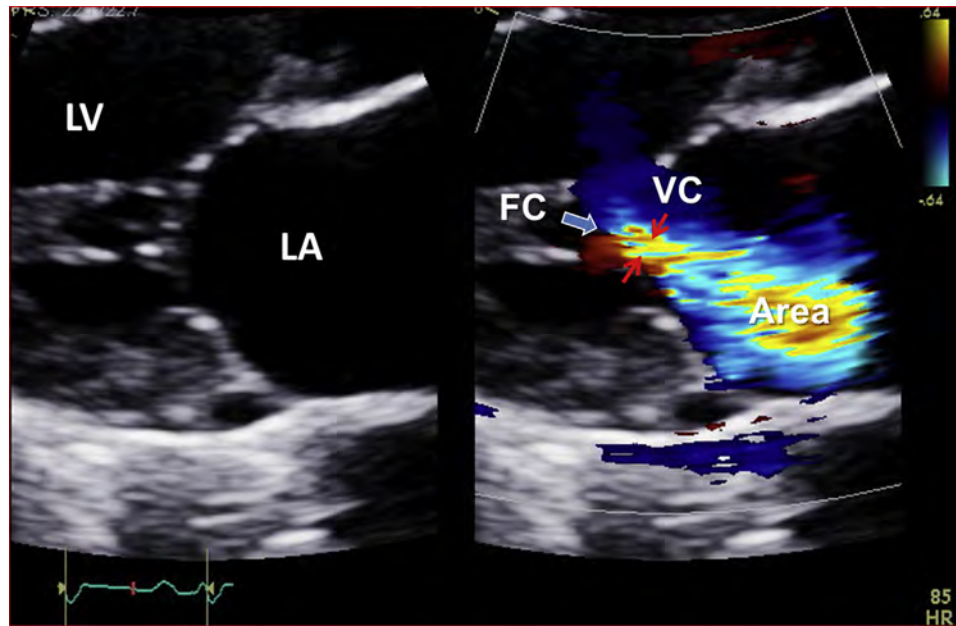


Figure 1 Depiction of the three components of a color flow regurgitant jet of MR: flow convergence (FC), VC, and jet area.

lesions occur in various etiologies: large perforations, large flail segments, profound retraction of leaflets leaving a coaptation gap, or marked tenting of leaflets with tethering and loss of coaptation. All of these findings predict severe valve regurgitation with a high positive predictive value but low sensitivity. Hence, these specific signs are useful when present, but their absence does not exclude severe regurgitation. TTE is the main modality to assess valvular structure usually with the 2D approach, with TEE reserved for inconclusive studies, and to assess eligibility and suitability for transcatheter or surgical procedures. Three-dimensional applications in evaluating valve morphology have had a significant impact on the accuracy of localization of valvular lesions mostly from the transesophageal approach, particularly for the atrioventricular valves. The current lower spatial and temporal resolution of 3D TTE limits its evaluation of valvular structure, however, this is improving.¹²

b. Impact of regurgitation on cardiac remodeling. As blood is incompressible, the regurgitant volume (RVol) must be contained in the cardiac cavities affected, implying that some degree of cavity dilation is proportional to the severity and chronicity of regurgitation. Despite this obligatory remodeling, the dilatation of cardiac cavities is considered in general a supportive sign of valvular regurgitation severity and not a specific sign (unless some conditions are met) because of multiple factors affecting cardiac remodeling. Acute severe regurgitation is characterized by a large regurgitant orifice, but cavity dilatation is minimized. The kinetic energy transmitted through the regurgitant orifice is affected by low cavity compliance, whereby the regurgitant energy is transformed into potential energy (elevated pressure in the receiving chamber) so that rapid equalization of pressure occurs with a low driving force for regurgitation. Consequently, acute severe regurgitation may be brief, with low RVol (low kinetic energy) and little cavity dilatation. In chronic regurgitation, however, cavity dilatation should reflect the regurgitation severity and duration. Cavity dilatation may be specific for significant regurgitation when ventricular function is preserved but loses specificity in conditions such as cardiomyopathy or ischemic ventricular dysfunction. A component of intrinsic dilatation (e.g., cardiomyopathy, atrial dilata-

tion due to atrial fibrillation) may exaggerate the apparent “consequences” of regurgitation. Conversely, in patients with small cavities prior to the onset of regurgitation, an increase in cavity size may be underestimated if preregurgitation cavity size is unknown. Anatomic variability and technical issues may limit the ability to detect cavity dilatation. Measuring cavity diameters rather than volumes has inherent limitations as the diameter-volume relationship is nonlinear. Furthermore, the proposed range of normal values currently available is based on a limited number of subjects, so that for patients with small or very large body size, normalcy is difficult to define. The small body size limitation is of particular concern in evaluating valve regurgitation in females, where normalizing ventricular and regurgitant measurements to body size may provide a more accurate assessment of outcomes.¹³ Nevertheless, in a patient with regurgitation, an enlarged ventricle is consistent with significant regurgitation in the chronic setting and in the absence of other modulating factors, particularly when ventricular function is normal. Once a diagnosis of significant regurgitation is established, serial echocardiography with TTE is currently the method of choice to assess the progression of the impact of regurgitation on cardiac chamber structure and function. Careful attention to consistency of measurements and individualized interpretation of results are critical to the assessment of cardiac remodeling as a sign of regurgitation severity. Contrast echocardiography should be used in technically difficult studies for better endocardial visualization, as it enhances overall accuracy of ventricular volume measurements.¹⁴ Three-dimensional TTE can also be used for an overall more accurate assessment of volumes and ejection fraction, as it avoids foreshortening of the left ventricle (LV).¹⁵

Echocardiography in general tends to underestimate measurements of LV volumes compared to other techniques when the traced endocardium includes ventricular trabeculations; the use of contrast to better visualize the endocardial borders excludes trabeculations and provides larger measurements of cavity size, closer to those by computed tomography and CMR.^{14,15}

3. Color Doppler Imaging. Color flow Doppler is widely used for the detection of regurgitant valve lesions and is the primary method

Table 2 Factors that increase or reduce the color Doppler jet area

| Increases jet area | Reduces jet area |
|---|---|
| Higher momentum Larger regurgitant orifice area Higher velocity (greater pressure gradient) Higher entrainment of flow | Lower momentum Smaller regurgitant orifice area Lower velocity (lower pressure gradient) Chamber constraint/wall-impinging jet |
| Lower Nyquist limit | Higher Nyquist limit |
| Higher Doppler gain | Lower Doppler gain |
| Far-field beam widening | Far-field attenuation/attenuation by an interposed ultrasound-reflecting structure |
| Slit-like regurgitant orifice, imaged along the thin, long shape of the orifice | |
| Multiple orifices | |

for assessment of regurgitation severity. This technique provides visualization of the origin of the regurgitant jet and its size (VC),¹⁶ the spatial orientation of the regurgitant jet area in the receiving chamber, and, in cases of significant regurgitation, flow convergence into the regurgitant orifice (Figure 1). Experience has shown that attention to these three components of the regurgitation lesion by color Doppler—as opposed to the traditional regurgitant jet area alone with its inherent limitations—significantly improves the overall accuracy of assessment of regurgitation severity. The following are important considerations for color Doppler imaging of regurgitant jets:

a. Jet characteristics and jet area. Since color Doppler visualization of regurgitant jets plays such a significant role in the assessment of valvular regurgitation, it is useful to discuss the underlying basis of color jet formation and display and factors that affect it. A more detailed exposition on color jet formation has been described elsewhere.¹⁷ First, it is important to understand that simply knowing the orifice flow rate is not enough to predict jet size, since the jet will entrain additional flow as it propagates into the receiving chamber and this entrainment strongly depends on the orifice velocity (which in turn is affected by the orifice driving pressure). Rather, jet flow is governed mainly by conservation of momentum. Cardiologists are likely less familiar with momentum as opposed to the other two conserved quantities in fluid flow: mass (manifest in the continuity equation) and energy (found in the Bernoulli equation); but momentum is a critical concept for understanding regurgitant jets. For a jet originating through a regurgitant orifice with effective orifice area A and velocity v , the flow Q is equal to Av , and the momentum M is given by Qv or Av^2 . (By extension, energy is given by Qv^2 or Av^3). The amount of momentum that is within a jet at its orifice remains constant throughout the jet.¹⁸ Thus, a 5 m/sec mitral regurgitation (MR) jet with a flow rate of 100 mL/sec should appear the same by color Doppler as a 2.5 m/sec tricuspid regurgitation (TR) jet with a flow rate of 200 mL/sec. For a free turbulent jet, the centerline velocity in the jet drops off inversely with distance from the regurgitant orifice.

To understand how large a jet will appear in color Doppler, one needs to know the minimum velocity that can be detected by the instrument. This is not specifically defined on the echocardiogram but typically is a fraction (around 10%) of the full Nyquist velocity. The jet will appear anywhere the jet velocity is greater than this minimally detectible velocity. The situation is somewhat more complicated in that no jets inside the heart are completely free but are constrained by the chamber walls, causing the velocity to fall off earlier than it would otherwise. The effect of the interplay among momentum, chamber constraint, and minimal displayed velocity on jet area is

complex,¹⁷ but for clinical purposes, it suffices to know the following determinants of jet size (Table 2):

- Jet momentum (Av^2): a major overall determinant of jet size.
- Jet constraint/wall impingement: eccentric wall-hugging jets lose momentum rapidly, thus appearing smaller than unconstrained jets of the same RVol.
- Nyquist limit (velocity scale): reducing the velocity scale emphasizes lower velocities and makes the jet appear larger. In addition, blood cells within the receiving chamber that move in response to or are entrained by the regurgitant jet may reach the minimal velocity and thus appear part of the regurgitant jet.
- Orifice geometry: slit-like orifices (particularly imaged along the long axis of the orifice) and multiple separate orifices lead to larger jets than single, relatively round orifices.
- Pulse repetition frequency (PRF): affects jet area inversely
- Doppler gain: jet size is quite sensitive and proportional to gain.
- Ultrasound attenuation: attenuation in the far field, from body habitus, or from an interposing highly reflectant structure such as calcium or metal (interferes with both imaging and Doppler) will decrease jet size.
- Transducer frequency: this has a dual effect. The higher frequency experiences a significant Doppler shift at lower velocities, making jets larger, such as in TEE. On the other hand, these higher frequency beams suffer excessive attenuation and jets may appear smaller in the far field, during TTE.
- Angle of interrogation: since color Doppler is sensitive only to the component of flow in the direction of the transducer, jets interrogated orthogonally may appear smaller than the same jet imaged axially. This effect actually is lessened as the turbulence within jets leads to high-velocity flow in all directions, thus making the jet visible even when imaged from the side.
- Color versus tissue threshold: if the tissue priority is set too high, structures may encroach on the color Doppler signal.

Thus, a larger area of a jet that is central in the cavity may imply more regurgitation, but as discussed, sole reliance on this parameter can be misleading.^{19,20} Figure 2 illustrates examples of modifiers of jet size. Standard technique is to use a Nyquist limit (aliasing velocity $|V_a|$) of 50-70 cm/sec and a high color gain that just eliminates random color speckle from nonmoving regions (Figure 2). Eccentric wall-impinging jets appear significantly smaller than centrally directed jets of similar hemodynamic severity.^{19,20} Their presence however, should also alert to the possibility of structural valve abnormalities (e.g., prolapse, flail, or perforation), frequently situated in the leaflet or cusp opposite to the direction of the jet.²¹ A jet may appear larger by increasing the driving pressure across the valve (higher momentum); hence the importance of measuring blood pressure for left heart lesions at the time of the study, particularly in the intraoperative setting or in a sedated patient. Lastly, it is important to note that in cases of very large regurgitant

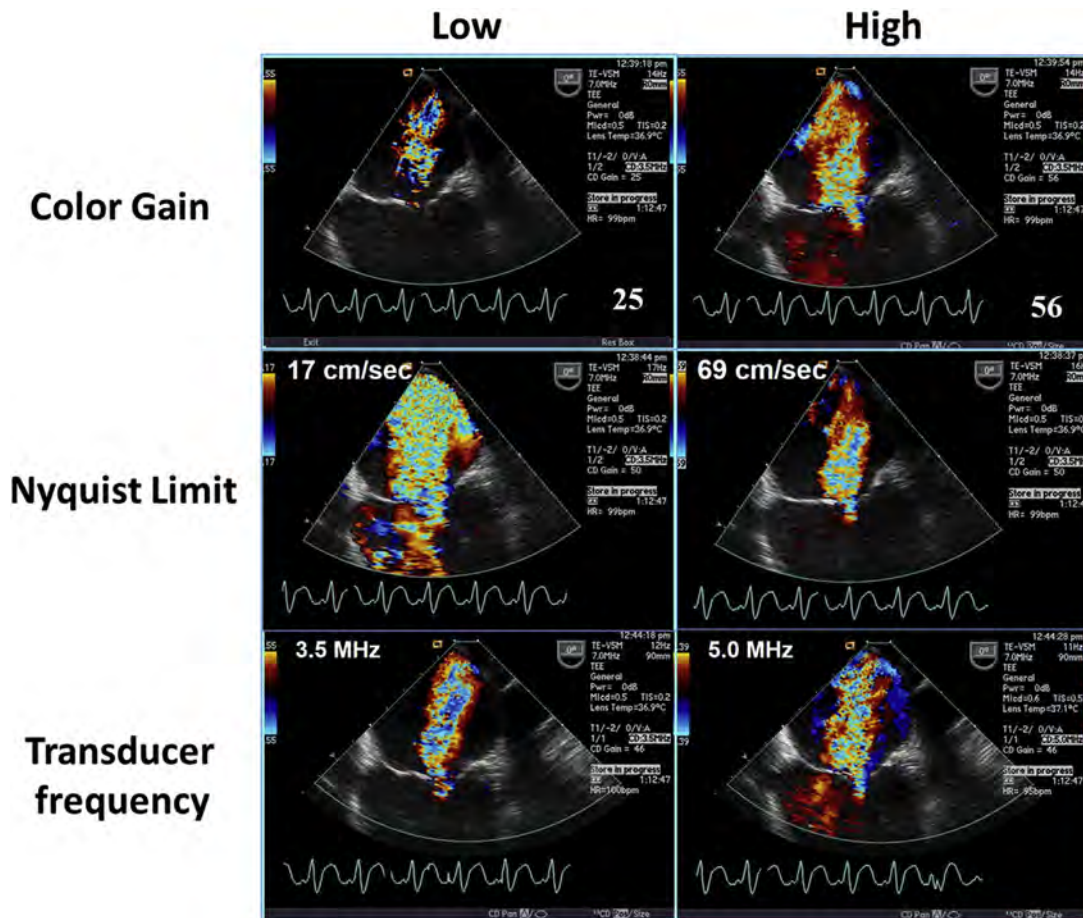


Figure 2 Effect of color gain, Nyquist limit, and transducer frequency on color jet area. Color gain should be optimized high, just below clutter noise level, otherwise the jet will be much smaller. A low Nyquist limit will emphasize lower velocities, and thus the jet will be larger; Nyquist should be between 50 and 70 cm/sec. A higher transducer frequency, as used in TEE, will also depict a slightly larger jet.

orifice areas, such as in cases of massive TR with a wide, noncoapting valve, a distinct jet may not be seen with color Doppler because of laminar flow and very low blood velocity.

b. Vena contracta. The vena contracta (VC) is the narrowest portion of the regurgitant flow that occurs at or immediately downstream of the regurgitant orifice (Figure 1). It is characterized by high-velocity laminar flow and is slightly smaller than the anatomic regurgitant orifice (ARO).²² Thus, the cross-sectional area (CSA) of the VC represents a measure of the effective regurgitant orifice area (EROA),^{23,24} a true parameter of lesion severity.²⁵ The size of the hydraulic VC is independent of flow rate and driving pressure for a fixed orifice.²⁶ However, if the regurgitant orifice is dynamic, the VC may change during the cardiac cycle.²⁷ In general, the VC by color Doppler significantly overestimates the hydraulic VC and is dependent on flow rate, likely because of entrainment.²² Despite these limitations, it remains a helpful semiquantitative measure of valve regurgitation severity.²² The VC by color Doppler is considerably less dependent on technical factors (e.g., PRF) compared with the jet extent. Imaging of the VC can be achieved using 2D or 3D color-flow Doppler, each presenting different challenges. For 2D VC measurement, it is indispensable to have a linear view of the three components of regurgitant flow (flow convergence, VC, jet area)

and to orient the ultrasonic beam as perpendicular to the flow as possible to take advantage of axial measurement accuracy. Hence, it is often necessary to angulate the transducer out of the conventional echocardiographic imaging planes. Proper beam-flow orientation is best achieved for aortic²⁸ or pulmonary regurgitation (PR), less for MR,¹⁶ and even less for TR.²⁹ A zoomed view is also indispensable to minimize the measurement inaccuracies for a width of a few millimeters. VCA tracing requires 3D imaging and is achieved offline by reorienting images and using cropping planes to locate the VC.³⁰ The color flow sector should also be as narrow as possible, to maximize lateral and temporal resolution. Achieving reasonable certainty that the smallest flow area is traced is a tedious process and may be difficult and lengthy; automated processes are being developed to this end.³¹⁻³³ Because of the small values of the width of the VC (usually <1 cm), small errors in its measurement may lead to a large percent error and misclassification of the severity of regurgitation, hence the importance of accurate acquisition of the primary data and measurements.

c. Flow convergence. Locating the flow convergence proximal to the regurgitant orifice provides qualitative information on both the location of the lesion causing the regurgitation and the magnitude of the regurgitant flow.³⁴ A well-defined small flow convergence combined with a

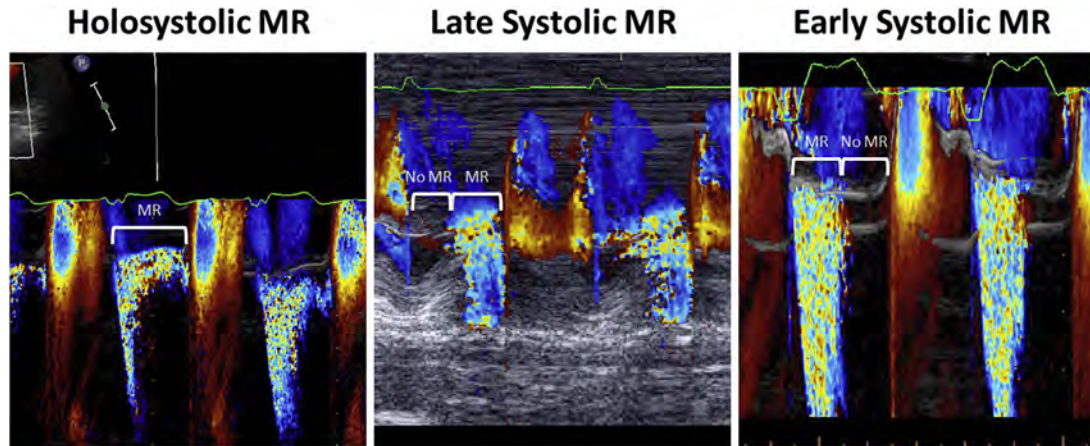


Figure 3 M-mode color images depict timing of MR: classic holosystolic MR, late systolic MR due to MVP, and early systolic MR in a patient with cardiomyopathy and left bundle branch block. Single-frame measurements of EROA or VC (width or area) will overestimate MR severity when it is not holosystolic.

small jet is specific for mild regurgitation, while a large flow convergence recorded at the minimum 50-70 cm/sec range, persisting throughout the duration of flow is specific for severe regurgitation. Flow convergence is amenable to quantitation of regurgitant flow (see below).

4. Pulsed Doppler. Pulsed Doppler is used combined with multiple measures of flow velocity as part of the quantitative assessment of valve regurgitation (see below). However, alterations in forward flow and reversed flow detected with pulsed Doppler associated with regurgitation can also be used as qualitative measures of valve regurgitation severity.

a. Forward flow. Valve regurgitation implies that the forward stroke volume (SV) across the affected valve during the cardiac cycle is increased.³⁵ For atrioventricular valves, increased forward flow is characterized by increased early E velocity and E/A ratio, generally associated with a short E deceleration time in the absence of stenosis. This supportive sign is mired by the multiple factors affecting ventricular filling including diastolic function, ventricular inflow obstruction (e.g., annular calcification), or alterations in cardiac output. For semilunar valves, ejection velocity is slightly increased with severe regurgitation, but the velocity time integral (VTI) of forward flow at the annulus is generally increased along with a prolongation in ejection time. This supportive sign is nonspecific but is a useful part of the constellation of findings in severe regurgitation.

b. Flow reversal. The RVol, when significant, may cause flow reversal in the receiving or proximal chamber, depending on the valve. In atrioventricular valves, valve regurgitation may result in pulmonary systolic venous flow reversal with MR or hepatic venous systolic flow reversal in cases of TR.³⁶⁻³⁹ Such systolic reversals are considered specific (>85% probability of severe regurgitation when present) but insensitive. Care should be taken to exclude other causes of flow reversal such as atrioventricular dissociation or pacemakers with ventriculoatrial conduction. For aortic regurgitation (AR), reversal of flow is diastolic, noted in the aortic arch and abdominal aorta, and is influenced by multiple factors, particularly peripheral vascular resistance and aortic compliance. Hence, prominent holodiastolic aortic flow reversal is a specific sign of severe AR but insensitive. Other causes of diastolic flow reversal should be sought in the absence of AR such as

arteriovenous fistulas, ruptured sinus of Valsalva, or patent ductus arteriosus.

5. Continuous Wave Doppler. Recording of jet velocity with continuous wave Doppler (CWD) provides valuable information as to the velocity and gradient between the two cardiac chambers involved in the regurgitation, its time course, and timing of the regurgitation. The density of the signal is also helpful, provided the Doppler waveform is not overgained.

a. Spectral density. The intensity (amplitude) of the returned Doppler signal is proportional to the number of red blood cells reflecting the signal. Hence, the signal density of the CWD of the regurgitant jet should reflect the regurgitant flow.⁴⁰ Thus a faint, incomplete, or soft signal is indicative of trace or mild regurgitation. A dense signal may not be able to differentiate moderate from severe regurgitation. Signal density also depends on spectral recording of the jet throughout the relevant portion of the cardiac cycle. Therefore, a central jet well aligned with the ultrasound beam may appear denser than an eccentric jet of much higher severity, if not well aligned.

b. Timing of regurgitation. The duration and timing of regurgitation can be valuable in the overall assessment of the physiology and hemodynamics of regurgitation. While the majority of regurgitant lesions are holosystolic or holodiastolic, some may occur during a brief period (Figure 3). In patients with MV prolapse (MVP), the regurgitation may be limited to late systole and is rarely severe when not holosystolic, with infrequent cardiac remodeling. MR and TR may be limited to isovolumic contraction and relaxation phases or both, particularly in functional regurgitation, which correspond to mild or trivial regurgitation.⁴¹

c. Time course of the regurgitant velocity. The spectral velocity profile of a regurgitant jet is determined by the pressure difference between the upstream and downstream chambers,^{42,43} with a general parabolic shape during systole for atrioventricular valves and a trapezoid shape during diastole for semilunar valves. For atrioventricular valves, an early peaking or cutoff sign denotes a large regurgitant wave in the respective atrium and significant regurgitation. A rapid decay of the diastolic slope in semilunar valve

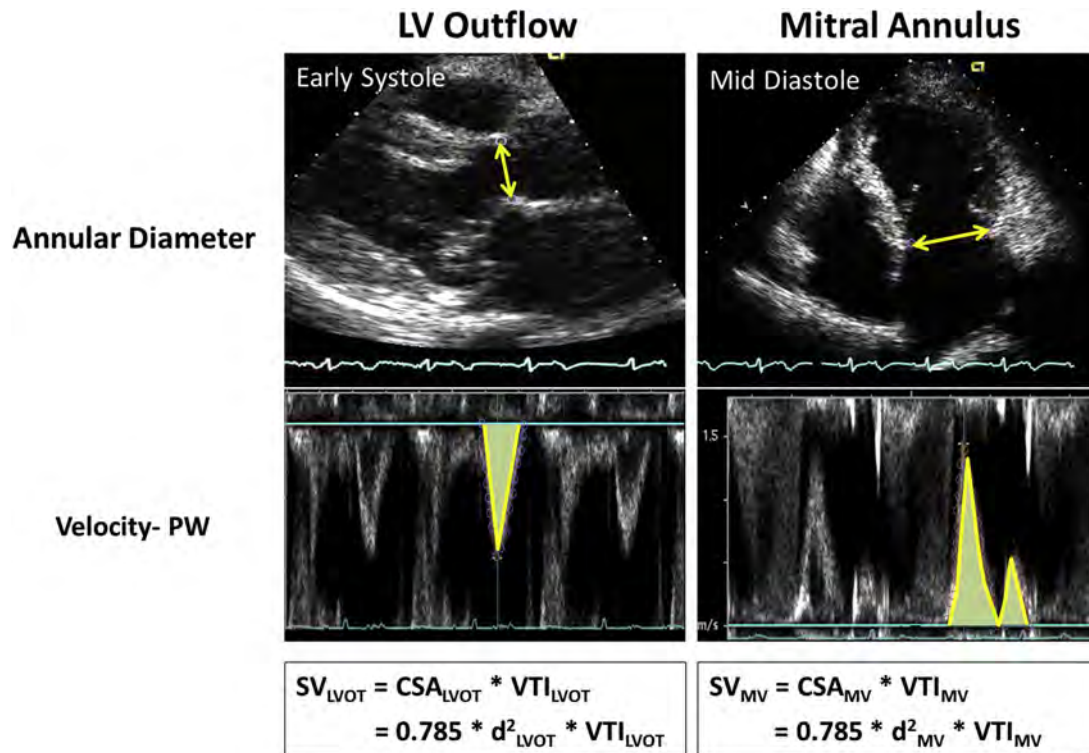


Figure 4 Echo-Doppler calculations of SV at the LVOT and MV annulus sites. In this example of severe MR, SV_{MV} was 183 mL ($d = 3.5$ cm, $VTI = 19$ cm) and SV_{LVOT} was 58 mL ($d = 2.3$ cm, $VTI = 14$ cm). This yielded an RVol of 125 mL and an RF of 125/183 or 68%. d , Diameter of the annulus; PW , pulsed wave Doppler.

regurgitation also can denote significant regurgitation but is exaggerated in cases of poor ventricular compliance and thus may not be specific.⁴⁴ Pulmonic regurgitation (PR) may end prior to end diastole and may be related to poor ventricular compliance and/or severe regurgitation. Premature termination of diastolic flow is rarely seen in AR and usually denotes acute severe regurgitation.

6. Quantitative Approaches to Valvular Regurgitation. There are few methods using echo Doppler techniques to quantitate valvular regurgitation. All these methods derive three measures of regurgitation severity:

- The EROA, the fundamental measure of lesion severity.
- The RVol per beat, which provides a measure of the severity of the volume overload.
- The regurgitant fraction (RF) provides a ratio of the RVol to the forward SV specific to the patient.

Prior studies suggest that the absolute measurements of EROA and RVol provide the strongest predictors of outcome. It is uncertain whether normalization of these measures to body size (body surface area or body mass index) is superior to absolute values, particularly in women. Careful attention should be paid to assess whether the regurgitation covers its entire period (systole for atrioventricular, diastole for semilunar valves); for regurgitations limited to part of their flow period, the EROA should be normalized to the entire period of potential regurgitation or ignored, as it would overestimate the severity of regurgitation.⁴⁵ Overall, in such partial regurgitations, the RVol is a better measure of regurgitation severity.

There are three methods for quantitative assessment of valvular regurgitation:

a. Quantitative pulsed Doppler method. Doppler recording of VTI can be combined with 2D or 3D measurement of flow area to derive SVs at different sites. The difference between inflow and outflow SVs of the same ventricle is caused by the RVol in single valvular regurgitation.^{20,46} This method is simple in principle, however, accurate results require individual training (e.g., practice in normal patients where SVs at different sites are equal). Briefly, forward SV at any valve annulus—the least variable anatomic area of a valve apparatus—is derived as the product of CSA and the VTI, measured by pulsed Doppler at the annulus.^{46,47} Overall, assumption of a circular geometry has worked well clinically. In this case,

$$SV = CSA * VTI = (\pi d^2 / 4) * VTI = 0.785 * d^2 * VTI,$$

where d is the diameter of the annulus in centimeters, VTI in centimeters, and SV in milliliters.

Calculations of SV can be made at two or more different sites: left ventricular outflow tract (LVOT), mitral annulus and right ventricular outflow tract (RVOT). In the absence of regurgitation, SV determinations at these sites are equal. In the presence of regurgitation of one valve, without the presence of any intracardiac shunt, the SV through the affected valve is larger than through the other competent valves. The difference between the two represents the RVol (Figure 4). RF is then derived as the RVol divided by the SV through the regurgitant valve. Thus,

$$RVol = SV_{RegValv} - SV_{CompValv},$$

$$RF = RVol / SV_{RegValv},$$

where $SV_{RegValv}$ is the SV derived at the annulus of the regurgitant valve and $SV_{CompValv}$ is the SV at the competent valve.

EROA can be calculated using the VTI of the regurgitant jet (VTI_{RegJet}) recorded by CWD as

$$EROA = RVol / VTI_{RegJet}$$

All measurements are expressed in centimeters or millimeters, leading to the calculation of EROA in square centimeters.

The most common errors encountered in determining these parameters are (1) failure to measure the valve annulus accurately (error is squared in the formula), (2) failure to trace the modal velocity (brightest signal representing the velocity of the majority of blood cells) of the pulsed Doppler tracing, and (3) failure to position the sample volume correctly, and with minimal angulation, at the level of the annulus.^{46,47} Furthermore, in the case of significant calcifications of the mitral annulus and valve, quantitation of flow at the mitral site is less accurate and more prone to errors.

A major challenge with all volumetric methods is that each of the component SVs has intrinsic error, in part due to the multiple parameters that must be combined into each one. These errors increase (as the root sum square) when the SVs are subtracted, with the relative error increasing even more as one subtracts one large number from another to get a small RVol. For example, a recent study of 3D color flow quantitation⁴⁸ demonstrated 95% confidence limits of mitral flow (relative to CMR) of ± 18.9 mL and ± 17.8 mL for the aortic valve. When these SVs are subtracted, the confidence intervals rise to ± 26 mL, emphasizing the critical need for meticulous attention to technique with these methods.

b. Quantitative volumetric method. Because blood is incompressible, the total SV ejected by the ventricle in single-valve regurgitation is equal to the SV at the regurgitant valve ($SV_{RegValv}$). If the forward SV ($SV_{Forward}$) is measurable simultaneously by Doppler or by any other method, the RVol can be calculated. Most use of this method has been for single left-sided regurgitant valves and the LV SV has been calculated using 2D echocardiography measurement of LV volumes.^{25,49} In such cases $SV_{Forward}$ is measured on the nonregurgitant valve (aortic valve for MR or MV for AR). Hence calculations are the following:

$$SV_{LV} = (\text{end-diastolic LV volume}) - (\text{end-systolic LV volume}),$$

$$RVol = SV_{LV} - SV_{Forward}$$

$$EROA = RVol / VTI_{RegJet}$$

Methods for calculation of LV volumes by echocardiography have been previously detailed.⁵⁰ The limitation of the method is the potential pitfall of underestimating true LV volume as noted above and therefore underestimating regurgitation severity. This can be improved with avoidance of foreshortening and use of contrast echocardiography.^{14,51} Assessment of ventricular volumes based on M-mode measurements has important limitations and is not recommended. The use of 3D echocardiography may improve the accuracy of LV volume determinations.^{3,50}

c. Flow convergence method (proximal isovelocity surface area [PISA] method). In valvular regurgitation, blood flow converges towards the regurgitant orifice forming concentric, roughly hemispherical shells of increasing velocity and decreasing surface area.³⁴ Color flow mapping offers the ability to image one of these hemispheres⁵² that corresponds to the first aliasing threshold (where the displayed color changes from red to yellow) as one moves out from the regurgitant orifice. This is generally done by shifting the baseline of the color scale in the direction of the regurgitant jet (i.e., down for MR into the LA on TTE and up for MR on TEE) to highlight an aliasing contour where flow convergence has a roughly hemispheric shape; it may appear more teardrop-shaped because lateral flows, perpendicular to the ultrasound beam, cannot be detected by Doppler. Alternatively, one could reduce the PRF to decrease the Nyquist (and aliasing) velocity, although most echocardiographers prefer shifting the baseline. The radius of the PISA is measured from the point of color Doppler aliasing (abrupt change in color from blue to yellow if jet direction is away from transducer) to the VC. Regardless, the aliasing contour is better detected if variance color mapping is turned off. For a hemispheric proximal convergence zone with radius r , the regurgitant flow rate (RFlow, in mL/sec) is calculated as the product of the surface area of the hemisphere ($2\pi r^2$) and the Va ⁵²⁻⁵⁶ as

$$RFlow = 2\pi r^2 * Va,$$

Assuming that the selected PISA radius occurs at the time of peak regurgitant velocity, the EROA at that specific time is derived as

$$EROA = (6.28 * r^2 * Va) / PeakV_{RegJet}$$

where $PeakV_{RegJet}$ is the peak velocity of the regurgitant jet by CWD. The radius is expressed in centimeters and velocities in centimeters per second, allowing the EROA to be expressed in square centimeters. The RVol can be calculated as

$$RVol = EROA * VTI_{RegJet}$$

where VTI_{RegJet} is the VTI of the regurgitant jet expressed in centimeters.

The PISA method is simple conceptually and in its practical calculation (Figure 5). It allows a qualitative and a quantitative assessment of the severity of the regurgitation and has become the main method of quantification of regurgitation, particularly on the mitral and TVs. However, there are several core principles to pay attention to in order to maintain quality control:

- Timing of measurements: since the PISA calculation provides an instantaneous peak flow rate, the EROA calculated by this approach may not be equivalent to the average regurgitant orifice throughout the regurgitant phase.⁴¹ Previous studies using timed measurement in MR have shown that the regurgitation is often dynamic; two important precautions were highlighted^{41,53}: first, measurement of flow and velocity should be performed at simultaneous moments of the regurgitant phase (Figure 5; e.g., not combining a late-systolic flow convergence with a midsystolic velocity). Second, the PISA measurement most representative of the mean EROA is that performed simultaneously with the peak velocity of the regurgitation (Figure 5). Hence it is essential to follow these rules without aiming for the largest flow convergence, while also remembering that the dynamic nature of the jets may lead to underestimation in the case of typically bimodal secondary MR^{57,58} or overestimation in the case of late systolic primary MR.⁵⁹

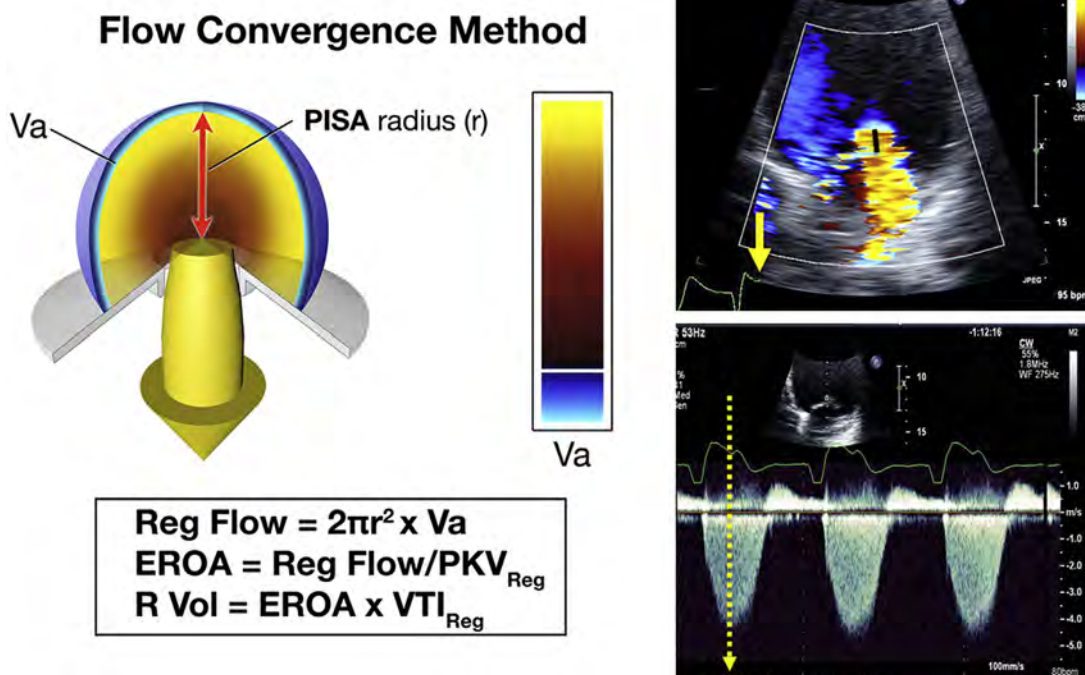


Figure 5 Schematic representation of the flow convergence method (PISA). The example on the right shows the measurement of the PISA radius and the timing of the selection of the color frame for measurement (solid yellow arrow), corresponding to the maximal jet velocity by CWD (dashed arrow). *Reg*, Regurgitation; *PKV*, peak velocity of regurgitant flow by CWD; *VTI*, velocity time integral of the regurgitant jet by CWD.

- Duration of regurgitation: the issue of instantaneous versus average measurement comes particularly into play for “partial” regurgitation (e.g., myxomatous MR confined to mid-late systole or functional MR in early systole and isovolumic relaxation).⁴⁵ For such partial regurgitation, the RVol can be approximated by multiplying the maximal EROA by the VTI from the densest part of the CWD tracing. When reporting the EROA, however, it is best to use the “mean” EROA, where the maximal EROA is normalized by the proportion of systole during which significant regurgitation occurs; preferably, the RVol should be retained as the most appropriate index. Where feasible, volumetric methods can yield these regurgitant parameters without needing to make assumptions about variation in the EROA.
- Shape of PISA: the standard method assumes that the valvular plane from which the regurgitant orifice arises is planar and that the flow convergence is homogeneous, but this is not always the case.⁶⁰ First, the plane of the regurgitant orifice may be conical rather than flat or planar (180°), as seen in TR and MV leaflet tenting. This conical angle should be accounted for, as the flow convergence covers more than a hemisphere.⁵⁵ Second, the shape of the flow convergence may be inconsistent with a hemisphere, which may require adjustment of the *Va* such that a well-defined hemisphere is shown. If the flow convergence does not fulfill the criteria of a hemisphere due to constraint, the initial approach is to attempt avoiding the constraint by increasing the *Va*, making the flow convergence smaller and less prone to constraint. However, if the constraint persists, the echocardiographer should decide whether a simple angle correction for the truncation of the flow convergence is possible,⁶⁰ and if not, the method should not be reported.
- Shape of the regurgitant orifice: a factor that complicates PISA calculations is the shape of the regurgitant orifice itself. While organic disease (e.g., leaflet flail) usually causes a roughly circular orifice, the regurgitant orifice area in functional disease is often elongated throughout the coaptation line.⁶¹ Application of the standard PISA formula to such an elliptical orifice will lead predictably to flow underestimation.⁶² Recent computational fluid dynamics simulations have shown that this underestimation may not be as severe as might be feared, depending on the shape of the ellipse, since the flow

contours rapidly become hemispheric as one moves away from the orifice.⁶³ For a 3:1 ellipse, use of the standard PISA formula (with 40 cm/sec *Va* and 5 m/sec orifice velocity) only results in 8% underestimation relative to a circular orifice. However, a 5:1 ratio leads to a 17% underestimation, and a 10:1 ratio to a 35% underestimation.⁶³

A few additional limitations of PISA should be noted.^{64,65} Central jets allow an easy alignment of the ultrasound beam and the centerline of the flow convergence. In contrast, eccentric jets may present a challenge, for both flow convergence and CWD recording (angulation or inability to record jet despite multiple windows). It is generally easy to identify the aliasing line of the hemispheric contour, but deciding on the position of the regurgitant orifice is more challenging. The presence of dark zones indicating horizontal flow perpendicular to the beam of ultrasound represents the best marker of the position of the regurgitant orifice (Figure 5). In cases where this is not obvious, a display of simultaneous color and noncolor 2D images or turning off the color-flow imaging may be helpful. In cases where the regurgitant orifice is noncircular, as frequently is seen in functional MR (crescent shape), the PISA shape is also modified and no longer hemispheric.⁶⁵⁻⁶⁷ Three-dimensional color flow would provide a better assessment of the PISA surface (likely underestimated with 2D PISA), although with additional limitations of lower spatial and temporal resolution.^{66,67} Lastly, in patients with multiple jets, the PISA method can be applied to each orifice, with flows and EROA added together; if one lesion is very mild, it can be neglected. Overall, the PISA method by the combination of both qualitative visual assessment and full calculation is the most used method for quantitation of valvular regurgitation in routine clinical practice.

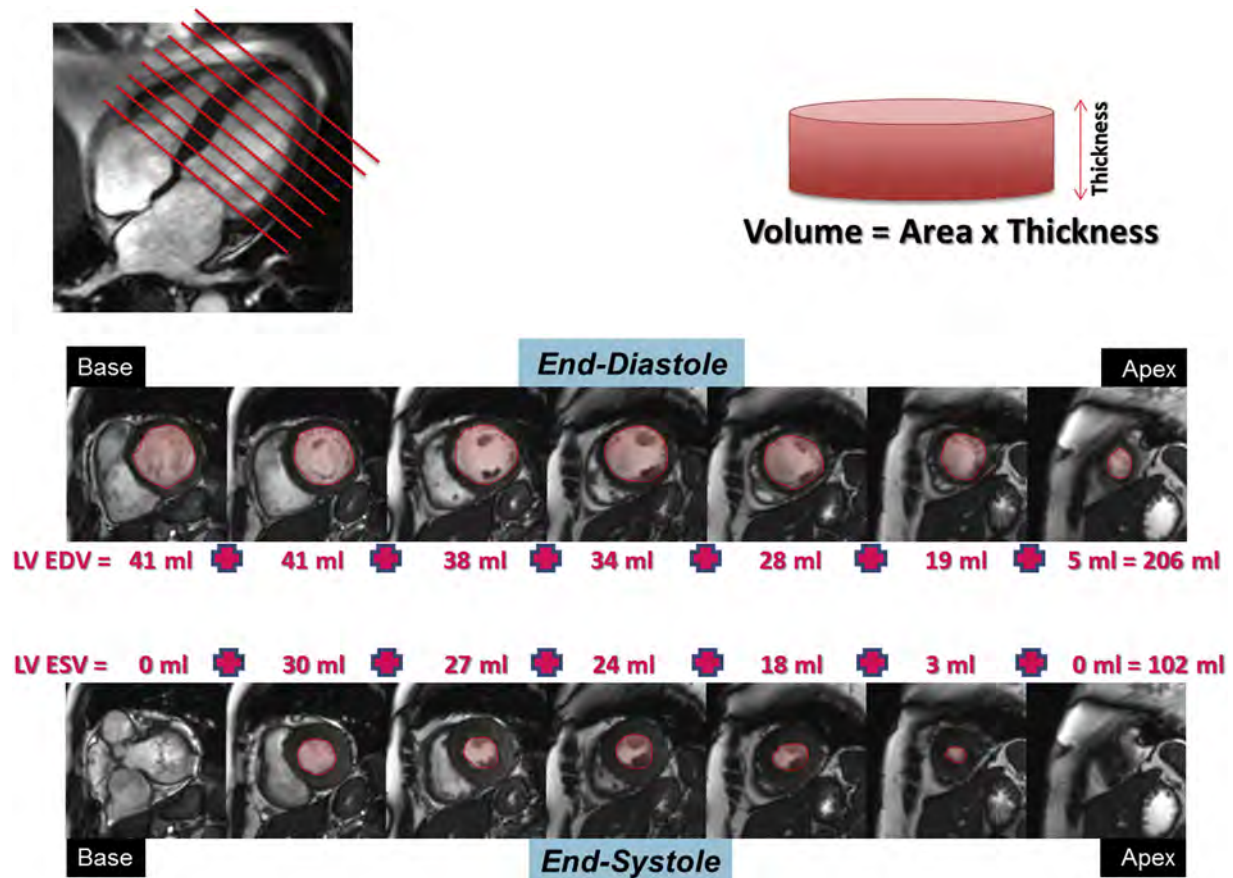


Figure 6 Example CMR study for assessment of LV function. Sequential short-axis slices are acquired from the mitral annular plane (base) to the apex of the LV. LV end-diastolic volume (LVEDV) is calculated by summation of the volume (area \times thickness) of each short-axis slice during diastole. LV end-systolic volume (LVESV) is calculated by summation of the volume of each short-axis slice during systole. Note, this methodology requires no geometric assumptions.

C. Evaluating Valvular Regurgitation with Cardiac Magnetic Resonance

While echocardiography remains the first line modality for assessment of valvular regurgitation, in some situations, it may be suboptimal. In these instances, CMR can play a useful role because of a number of unique advantages: it provides a view of the entire heart without limitations of imaging windows or body habitus, allows free choice of imaging planes as prescribed by the scan operator, is free of ionizing radiation, and does not require contrast administration. In addition to assessing the *severity* of the regurgitant lesion, a comprehensive CMR study is able to quantitate cardiac remodeling and provide insight into the mechanism of regurgitation.

1. Cardiac Morphology, Function, and Valvular Anatomy.

The typical CMR study for evaluating valvular regurgitation involves the performance of a complete set of short-axis and long-axis (two-, three-, and four-chamber views) cine images using a steady-state free precession (SSFP) pulse sequence, which provides excellent signal-to-noise ratio and high blood-to-myocardium contrast.⁶⁸ The typical spatial resolution is 1.5-2.0 mm per pixel with 6- to 8-mm slice thickness and 2- to 4-mm interslice gap to produce a short-axis image every 10 mm from base to apex.⁶⁹ Some CMR laboratories have adopted a strategy of utilizing no interslice gap to theoretically improve the accuracy of SV quantification, especially for the RV with its unique geometry. Using this fast pulse

sequence, temporal resolution of ≤ 45 msec (frame rates of 20-25/sec) can be achieved within a 5- to 8-second breath hold that is generally tolerable for most patients. In individuals who have significant difficulty with breath holding, a nonbreath-held "real-time" pulse sequence has been shown to provide comparable assessment of LV and RV volumes and ejection fraction with only a modest compromise in spatial and temporal resolution.⁷⁰

An example of a typical series of cine images is shown in [Figure 6](#). In addition to providing a comprehensive assessment of regional LV and RV function, this data set can be used to perform planimetry of LV and RV volumes at end diastole and end systole, thus determining ventricular SV and ejection fraction with the method of discs. While full details on performing planimetry of ventricular volumes can be found at the Society for Cardiovascular Magnetic Resonance position statement on standardized image interpretation and post processing,⁶ there are a few key points worth mentioning:

a. Ventricular volumes. When performing planimetry, it is important to draw the LV and RV end-diastolic and end-systolic contours on the phases with the largest and smallest blood volume, respectively.⁶

b. Correct placement of the basal ventricular short-axis slice is critical. It is recommended that the most basal slice be located immediately on the myocardial side of the atrioventricular junction at end

Table 3 CMR methods for valvular regurgitation

| Approach | MR | AR | TR | PR |
|--|--|--|--|--|
| Preferred method for quantitation* | (LV SV)–(AO total forward SV) | Direct diastolic reverse volume at AO root | (RV SV)–(PA total forward SV) | Direct diastolic reverse volume at PA |
| Secondary methods for quantitation† | <ul style="list-style-type: none"> • (LV SV)–(PA forward SV) • (LV SV)–(RV SV) • (Mitral inflow SV)–(AO total forward SV) | <ul style="list-style-type: none"> • (AO total forward SV)–(PA total forward SV) • (LV SV)–(RV SV) | <ul style="list-style-type: none"> • (RV SV)–(AO total forward SV) • (RV SV)–(LV SV) | <ul style="list-style-type: none"> • (RV SV)–(LV SV) • (RV SV)–(AO total forward SV) |
| Corroborating signs of significant regurgitation | LV dilation, LA dilation | LV dilation | RV dilation, right atrium dilation | RV dilation |

AO, Aortic.

*Preferred method for quantitation is generally not affected by the presence of concomitant valvular regurgitant lesions.

†Secondary methods are most reliable in the absence of concomitant valvular regurgitation, or as long as the severity of other valvular regurgitant lesions can be accounted for.

diastole.⁶⁹ As a result of systolic motion of the MV toward the apex, a slice containing LV blood volume at end diastole may include only left atrium (LA) without LV blood volume at end systole. The LA can be identified when less than 50% of the blood volume is surrounded by myocardium and the blood volume cavity is seen to be expanding during systole. It can be helpful to use analysis software that allows adjustment for systolic atrioventricular ring descent using cross-referencing from long-axis locations.⁶ The RV contouring is performed in an analogous manner, with the RVOT volume included in the RV end-diastolic volume. Because of the tomographic nature of the technique, CMR can provide these volumetric measures in a 3D fashion without the need for geometric assumptions—in fact, it is considered the gold standard, with demonstrated accuracy and high reproducibility.⁵

c. Planimetry of LV epicardial contour. This can be performed to derive LV mass.

d. Left atrial volume. LA volume can be derived by performance of multiple short-axis slices through the LA or by utilizing the biplane area-length method as in echocardiography.^{71,72}

It is important to note that normal reference ranges for left and right cardiac chamber volumes by CMR are higher than for echocardiography^{71,72} and that correlation between the two modalities is improved with use of 3D echocardiography and/or administration of echocardiographic contrast.^{14,15,73,74} The ability to image in any plane makes CMR robust for assessment of valvular anatomy⁷⁵ and aids in assessment of mechanism of regurgitation. This can be especially useful for assessment of right-sided valves, which may be difficult to visualize by echocardiography. Assessment of valve anatomy is accomplished by performing a series of contiguous (no gap) parallel thin slice (4–5 mm) SSFP cine acquisitions in the plane of interest. The exact planes to be chosen for each valve will be described in detail in subsequent sections.

2. Assessing Severity of Regurgitation with CMR. Assessing the severity of valvular regurgitation can be performed via a variety of methods: (1) visual assessment of the extent of signal loss due to spin dephasing on cine CMR acquisitions,^{76,77} (2) planimetry of the ARO area from the cine CMR acquisitions of the valve,^{78,79} or (3) quantitation of the RVol. While the first

two methods can be used to obtain a qualitative assessment of regurgitant severity, the last method is the most robust and the crux of CMR assessment of valvular regurgitation. The following are approaches and considerations for quantitation of valvular regurgitation (Table 3):

a. Phase-contrast CMR. This is the imaging sequence of choice in quantifying flow and calculating velocities. Protons moving along a magnetic field gradient acquire a phase shift relative to stationary spins. The phase shift is directly proportional to the velocity of the moving protons in a linear gradient. Phase-contrast CMR produces two sets of images: magnitude images and phase velocity maps (Figure 7). The magnitude image is used for anatomic orientation of the imaging slice and to identify the boundaries of the vessel imaged. The phase map encodes the velocities within each pixel. Using both images, a region of interest can be traced at each time frame of the data set. The region of interest must be drawn carefully for each frame of the cardiac cycle because of movement and deformation of the vessel. Flow is derived by integrating the velocity of each pixel and its area over the cardiac cycle, allowing for calculation of anterograde and retrograde flows through a region of interest (Figure 7). CMR flow measurements have extensive validation in both in vitro and in vivo studies.^{80–83}

b. Quantitative methods. Methods for quantification of valvular regurgitation can be broadly divided into direct and indirect methods. The direct method employs use of through-plane phase-contrast CMR to quantify blood flow at any given location. This method has been shown to be very accurate for assessing anterograde and retrograde flow across semilunar valves and therefore is the preferred technique used for assessing aortic or pulmonic insufficiency. Phase contrast for direct assessment of flow in the mitral or TVs is more difficult because of significant motion of the annulus during systole. For this reason, quantification of mitral or tricuspid RVol is performed using an alternative, indirect approach by comparing ventricular SV (derived by planimetry of short-axis cines) to forward flow (derived by phase-contrast CMR) across the aortic or pulmonary valves (PVs; Figure 8). In addition to the preferred methods for each valve lesion described above, multiple additional indirect methods such as comparison of LV and RV SVs or use of mitral

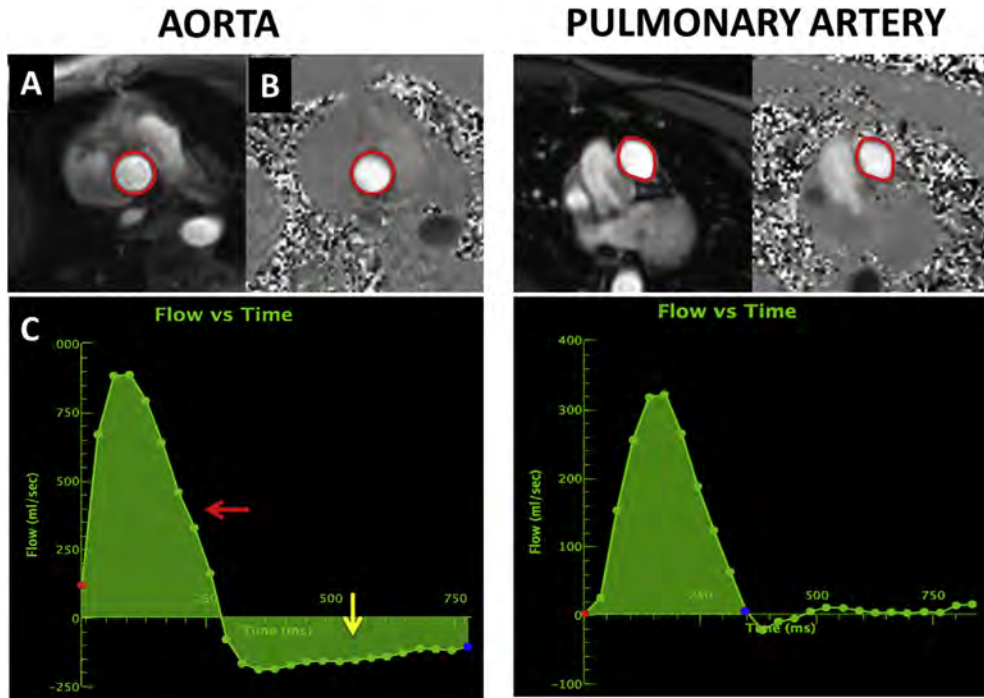


Figure 7 CMR technique for assessment of great vessel forward and retrograde flow. Left side of the figure demonstrates a phase-contrast acquisition performed in the aortic root. This produces a set of two cine images at matched anatomic locations that provide differing information: a magnitude image that provides anatomic reference (A) and velocity or phase map with pixel values linearly related to velocity and direction of flow (B). On postprocessing, via drawing a region of interest around the aortic root (red circles), a flow versus time graph is generated (C), which can be used to compute forward (red arrow) and reverse flow (yellow arrow). In this example of AR, the reverse flow represents the directly measured volume of AR. The right side of the figure demonstrates the same, performed at the PA trunk to derive PA flow.

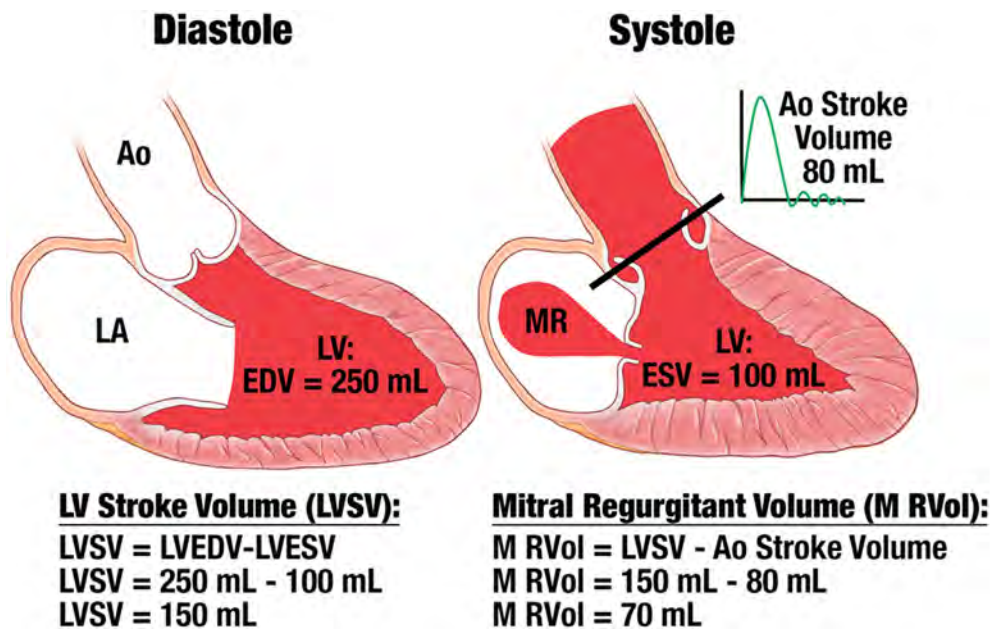


Figure 8 Example CMR method for quantification of MR. The volume of the LV is calculated during end-diastole (LVEDV) and during end-systole (LVESV) via the methodology demonstrated in Figure 6. The total volume of blood ejected from the LV, LV SV, is computed as the difference between LV end-diastolic volume and LV end-systolic volume. In this example LV SV is 150 mL. The volume of blood crossing the aortic (AO) valve is measured by performance of a phase-contrast acquisition in the aorta (as detailed in Figure 6); in this example, 80 mL. The mitral RVol (M RVol) is computed as the difference between the LV SV and aortic forward SV; in this example, 70 mL.

Table 4 Strengths and limitations of CMR in evaluation of valvular regurgitation

| Strengths | Limitations |
|--|---|
| No limitations from acoustic windows or body habitus (except inability to fit in scanner). Free choice of imaging planes. | Not widely available. Claustrophobia in some patients. Cannot be performed at bedside. Unable to perform in patients with certain implanted devices (e.g., pacemakers, defibrillators) except in specialized centers. |
| High signal-to-noise ratio and high blood pool to myocardium contrast Accurate and reproducible measures of cardiac remodeling (i.e., ventricular volumes, function, and mass) without geometric assumptions. | Requires good breath holding to achieve optimal image quality. Need to acquire images over several cardiac cycles can lead to compromised quality in setting of arrhythmias (i.e., atrial fibrillation or premature ventricular contractions), and current widely available phase-contrast sequences can fail in frequent arrhythmias. |
| Ability to provide information about myocardial viability and scarring if gadolinium contrast is administered. | Difficulty to image small or chaotically mobile objects (e.g., vegetations) due to averaging over multiple cardiac cycles and inadequate spatial and temporal resolution. |
| Phase-contrast imaging derives flow using velocities from entire orifice (without needing to assume flat transorifice flow profile or certain geometric shape). | For through-plane phase-contrast imaging, the imaging plane needs to be perpendicular to the blood flow, and difficulty can exist especially in dilated PAs. Adjacent sternal wires and stented valve prosthesis can create susceptibility artifact compromising image quality. |
| Allows quantitation of flow through each ventricle (LV/RV) and great vessel (aorta/PA). | Phase-contrast acquisitions have lower temporal resolution than echo Doppler-based methods, which may lead to underestimation of peak velocity. Inadequate spatial resolution may lead to underestimation due to partial volume averaging. |
| Severity assessment based on quantitation of RVol or fraction (no hemodynamic or shape assumptions; not affected by jet direction or presence of multiple jets). | In case of turbulence when there is mixed stenosis and regurgitation, phase contrast can underestimate volume due to intravoxel dephasing and loss of signal For mitral and TVs there is no established direct method to quantify regurgitation severity Limited data on RVol and fraction cutoffs for severity grading, and limited outcome data available based on the grading. |

or tricuspid diastolic inflow can be employed to serve as an internal check.

c. Technical considerations. When performing flow measurements a few technical aspects need to be kept in mind. The velocity encoding should be set to the lowest velocity feasible without aliasing. It is important that the imaging plane be (1) centered in the vessel of interest, (2) aligned orthogonally to the expected main blood flow direction in two spatial directions, and (3) centered in the isocenter of the magnetic field.⁶⁹ Despite these steps, phase offset errors due to eddy currents in the magnetic field can still occur, and it is important to consider the use of phantom or background correction in every case if possible.⁸⁴

d. Thresholds for regurgitation severity. There is a paucity of data on specific CMR thresholds of RVol or fraction that define severe regurgitation based on outcomes. An earlier study suggested using a RF threshold of 48% by CMR to define severe regurgitation of the aortic or MVs, based on achieving the best correlation with limited echocardiographic assessment.⁸⁵ One study in MR and another in AR have focused on RVol/fraction thresholds for prognosis.^{86,87} Progression to symptoms and need for valve surgery were seen with a RF of >40% for MR and >33% for AR (or >55 mL). Due to the paucity of data and absence of other recommendations, the general cutoffs for RVols and RFs recommended by echocardiography² and the recent American College of Cardiology/American Heart Association (ACC/AHA) guidelines¹ are used.

3. Strengths and Limitations of CMR. CMR has a number of unique strengths, which make it ideal for assessment of valvular disease (Table 4). Specifically, the free choice of imaging planes allows for a comprehensive assessment of all four cardiac valves without limitations of acoustic windows. In addition, volumetric assessment by CMR has been shown to have high interstudy reproducibility and therefore may be ideal for serial assessment.

The limitations of CMR are listed in Table 4 and include its inability to be performed in patients with certain implanted devices.⁸⁸ A comprehensive review of all contraindicated devices is beyond the scope of this document, but it is essential that all CMR laboratories perform careful screening on all patients referred for imaging. Since most CMR acquisitions are performed in a segmented fashion (obtained over multiple cardiac cycles), arrhythmias such as atrial fibrillation or premature ventricular contractions may pose a challenge for standard breath-held phase-contrast CMR sequences. CMR is also not as readily available as echocardiography, cannot be performed at the bedside or in some patients with claustrophobia, and is generally a more expensive modality. There are no uniform thresholds for grading severity of regurgitation, and there is a paucity of outcome data available regarding specific thresholds. Lastly, CMR is unable to assess pressures inside a vessel or cardiac chamber.

4. When Is CMR Indicated? While echocardiography remains the first-line modality for assessment of valvular regurgitation, CMR is generally indicated when (1) echocardiographic images are

Key Points

- A comprehensive evaluation of valvular regurgitation should include identifying the mechanism and the severity of valvular regurgitation, along with adaptation of the heart to the volume overload.
- Height, weight, body surface area, heart rate, rhythm, and blood pressure are required clinical parameters in the assessment of regurgitation.
- Echocardiography with Doppler is the primary modality for evaluation of native valvular regurgitation.
- Color Doppler is the primary method for detection of regurgitation. In evaluating severity of regurgitation with color Doppler, the three components of the regurgitant jet need to be assessed: flow convergence, VC, and the regurgitant jet direction and area into the receiving chamber.
- While color Doppler is important, pulsed and CWD are also essential in providing flow characteristics and dynamics. An integrative interpretation of valvular structure, cardiac size and function, and all Doppler parameters is crucial for assessing regurgitation severity, since each of these parameters has advantages and limitations.
- CMR is an excellent modality for evaluating native valvular regurgitation. While echocardiography remains the first-line modality, CMR is indicated when:
 - Echo images are suboptimal
 - Discordance exists between 2D echocardiographic features and Doppler findings
 - Discordance exists between clinical assessment and severity of regurgitation by echocardiography
- In addition to quantifying the severity of regurgitation, a comprehensive CMR study will also quantitate cardiac remodeling (both atrial and ventricular) and provides insights into the mechanism of regurgitation.
- Regurgitation severity may be difficult to assess, as it lacks a true gold standard and is influenced by hemodynamic conditions. Quantitative parameters include RVol, RF, and regurgitant orifice area. Recommendations for grading severity of regurgitation are those of mild, moderate, and severe.

suboptimal, (2) when there is discordance between 2D echocardiographic features and Doppler findings (e.g., ventricular enlargement greater than expected on the basis of Doppler measures of valvular regurgitation), or (3) when there is discordance between clinical assessment and severity of valvular regurgitation by echocardiography.¹ Specific scenarios when CMR may be indicated will be described in further detail in subsequent sections for individual valvular lesions.

The direct method described above for quantification of aortic or PR and the indirect method described for mitral and TR are independent of other coexisting valvular lesions, and therefore CMR may be especially useful in the setting of multiple valvular lesions when echocardiographic assessment is challenged. This will be presented in more detail in the section on multivalvular disease.

D. Grading the Severity of Valvular Regurgitation

Characterization of the severity of regurgitant lesions is among the most difficult problems in valvular heart disease. Such a determination is important since mild regurgitation does not lead to remodeling of cardiac chambers and has a benign clinical course, whereas severe regurgitation is associated with significant remodeling, morbidity and mortality.¹ Contributing to the difficulty of assessment of regurgitation is the lack of a true gold standard and the dependence of regurgitation severity on the hemodynamic conditions at the time of evaluation. Although angiography has been used historically to define the degree of regurgitation based on opacification of the receiving chamber, it is also dependent on several technical factors and hemodynamics.^{11,89,90} For example, an increase in blood pressure will increase all parameters of aortic or MR, be it assessed as RF or angiographic grade. Furthermore, the angiographic severity grades, which have ranged between three and five grades, have only modest correlations with quantitative indices of regurgitation.^{11,46,90}

Doppler and CMR methods for valvular regurgitation have been validated in animal models against independent flow parameters, and clinically, against the angiographic standard and each other. The majority of these studies have involved left-sided cardiac valves. For Doppler echocardiography, and as discussed above, there are several qualitative and quantitative parameters that can provide assessment of valvular regurgitation. Although this adds to the complexity of evaluation, the availability of these different parameters provides an internal check and corroboration of the severity of the lesion, particularly when technical or physiologic conditions preclude the use of one or the other of these indexes. For CMR, the

evaluation involves fewer parameters, is mostly quantitative, but is still influenced by technical and physiologic factors. In order to mitigate the effect of these factors within each individual exam, quantitative internal checks within the CMR exam should be employed. For example, in patients with isolated MR, the difference between the LV SV and aortic total forward flow should be the same as the difference between the LV SV and the pulmonary artery (PA) total forward flow or RV SV. Thus, an integrative, comprehensive approach is essential. In echocardiography, if there are signs suggesting that the regurgitation is significant and the quality of the data lends itself to quantitation, it is desirable for echocardiographers with experience in quantitative methods to determine quantitatively the degree of regurgitation, particularly for left-sided lesions. Ultimately, the interpreter of either echocardiography or CMR must integrate the information and disregard “outlying” data (because of poor quality or a physiologic condition that alters accuracy of a certain parameter), making a best estimate of regurgitation severity. The consensus of the writing group is to classify grading of severity of regurgitation into mild, moderate, and severe. “Trace” regurgitation is used in the event that regurgitation is barely detected. Usually this is physiologic, particularly in right heart valves and MV, and may not produce an audible murmur. Since the severity of regurgitation may be influenced by hemodynamic conditions, it is essential to record the patient’s blood pressure, heart rate, and rhythm at the time of the study and note the patient’s medications whenever possible. When following a patient with serial examinations, these factors need to be considered in comparing the severity of regurgitation and its hemodynamic consequences and actual studies reviewed and compared because of inherent variability of techniques and measurements.

III. MITRAL REGURGITATION

A. Anatomy of the Mitral Valve and General Imaging Considerations

The MV apparatus includes the anterior and posterior mitral leaflets, the mitral annulus, chordae tendinae, papillary muscles, and the underlying LV myocardium. Echocardiographic views and their relation to mitral anatomy and the three scallops of each leaflet have been reviewed in detail.^{91,92} Typically, a 2D long-axis view runs through the middle portion of the anterior leaflet (A2) and the middle scallop of the posterior leaflet (P2). A short-axis view is

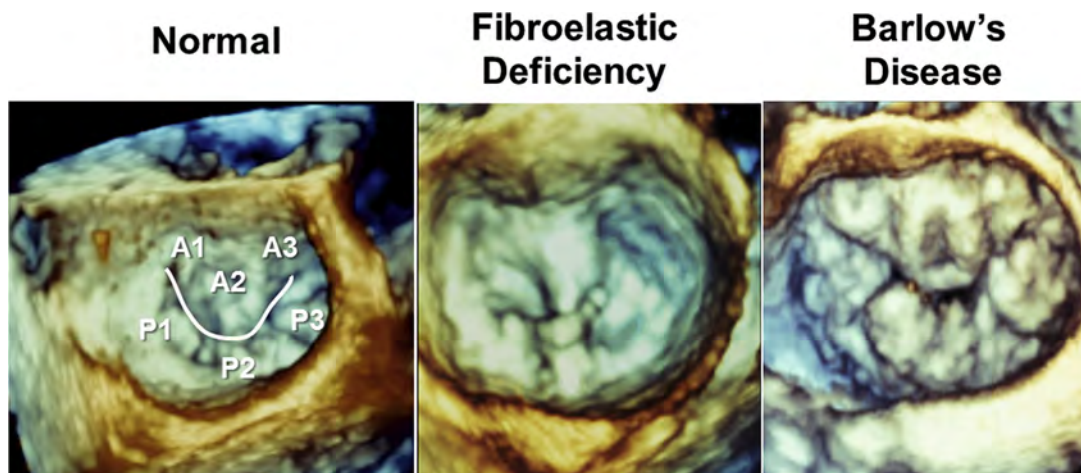


Figure 9 Three-dimensional echocardiographic frames of MVs from the LA view depicting a normal valve with delineation of the anterior and posterior scallops, a patient with fibroelastic deficiency and a flail P2 segment, as well as a patient with Barlow's disease.

useful in defining the exact location of pathology because it allows imaging of both leaflets and the commissures. The four-chamber view can cut through the leaflets at different locations. A cross-commissural view (typically by TEE but approximated by the transthoracic apical two-chamber view) is good at identifying the lateral (P1) and medial (P3) scallops of the posterior leaflet and the middle (A2) anterior leaflet. The optimal view of the coaptation line is a 3D en face view by either TTE or TEE. Three-dimensional echocardiography can provide detailed views of the complex structure of the MV apparatus, either from the LA or the LV.³ This facilitates both anatomic and functional interpretation, allowing precise localization of abnormal MV anatomy, particularly with TEE (Figure 9).^{3,4,12,93}

B. Identifying the Mechanism of MR: Primary and Secondary MR

The mechanism of MR can be divided broadly into two categories, based on whether the mitral leaflets exhibit significant pathological abnormality or not (Table 5). In primary MR, an intrinsic abnormality of the leaflets causes the MR, whereas secondary MR results from distortion of the MV apparatus due to LV and/or LA remodeling. Hence, most secondary MR is a disease of the LV. It is important to distinguish primary from secondary MR as therapeutic approaches and outcomes differ. It is also useful to consider whether leaflet motion is intrinsically normal or abnormal according to the Carpentier classification⁹⁴ (Figure 10). Type I leaflet motion is normal but can be associated with MR if there is annular dilation (secondary MR) or a leaflet perforation. Type II leaflet motion is excessive and is most commonly due to MVP or flail leaflet. Type III leaflet motion is restrictive, commonly seen in the presence of LV dilation (secondary MR) or rheumatic MV disease or other postinflammatory conditions such as collagen vascular disease, radiation injury, carcinoid syndrome, or drug-induced inflammatory changes. Table 6 compares the MV apparatus, cardiac remodeling, and jet characteristics in primary and secondary MR.

1. Primary MR. The most common cause of primary MR is myxomatous degeneration, most frequently MVP.⁹⁴ MVP is a spectrum of disease ranging from a focal abnormality of a mitral leaflet to

Table 5 Etiology of primary and secondary MR

| Primary MR (leaflet abnormality) | |
|--|--|
| MVP myxomatous changes | Prolapse, flail, ruptured or elongated chordae |
| Degenerative changes | Calcification, thickening |
| Infectious | Endocarditis vegetations, perforations, aneurysm |
| Inflammatory | Rheumatic, collagen vascular disease, radiation, drugs |
| Congenital | Cleft leaflet, parachute MV |
| Secondary MR (ventricular remodeling) | |
| Ischemic etiology secondary to coronary artery disease | |
| Nonischemic cardiomyopathy | |
| Annular dilation | Atrial fibrillation, restrictive cardiomyopathy |

diffuse involvement of both leaflets. Fibroelastic deficiency refers to focal segmental pathology with thin leaflets, while Barlow's disease refers to diffuse thickening and redundancy, typically affecting multiple segments of both leaflets and chordae (Figure 9). Characteristically, the MR occurs during mid-late systole when the laxity resulting in leaflet malcoaptation is greatest. In such cases, failure to recognize that MR is not holosystolic can lead to overestimation of MR severity by methods that rely on single-frame color Doppler measurements acquired when MR is at its maximum (Figure 11).⁴⁵

Using echocardiography, MVP is diagnosed ideally in the parasternal long-axis window as systolic displacement of the mitral leaflet into the LA of at least 2 mm from the mitral annular plane.⁹⁵ If parasternal windows are of poor quality, the apical long-axis view can also be used, although the latter is less standardized and thus more variable. Diagnosis of MVP should be avoided in the apical four- or two-chamber windows as these windows image the MV annulus along the low

Mitral Regurgitation

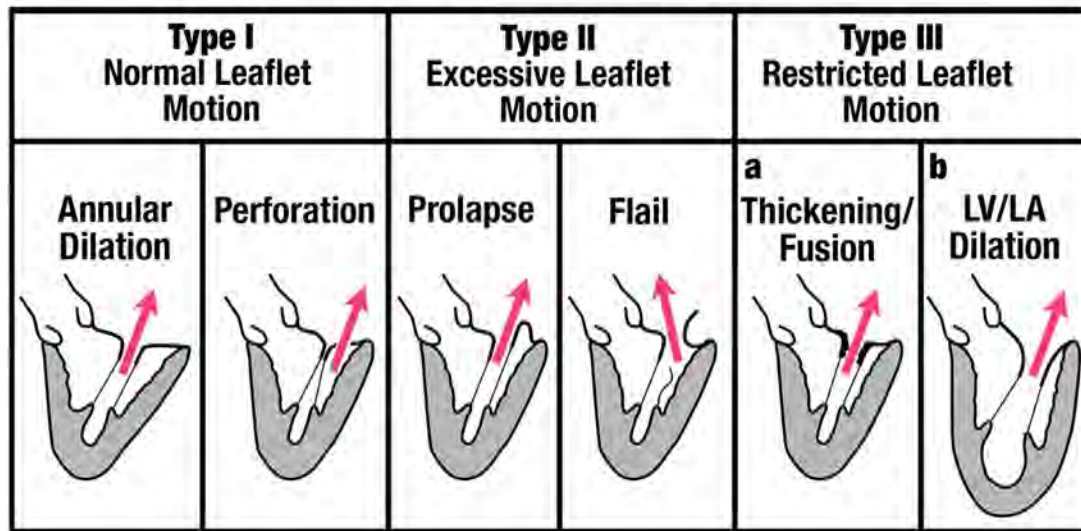


Figure 10 Depiction of mechanisms of MR as per the Carpentier classification.

Table 6 MV apparatus, cardiac remodeling, and jet characteristics in primary and secondary MR

| | Primary MR* | Secondary MR* | |
|---------------------------|---|--|---|
| | | Regional LV dysfunction | Global LV dysfunction |
| Etiology | Myxomatous or calcific leaflet degeneration | Inferior myocardial infarction | Nonischemic cardiomyopathy, large anterior or multiple myocardial infarctions |
| LV remodeling | Global, if severe chronic MR | Primarily inferior wall | Global dilation with increased sphericity |
| LA remodeling | Moderate to severe if chronic MR | Variable | Usually severe |
| Annulus | Dilated, preserved dynamic function | Mild to no dilation, less dynamic | Dilated, flattened, nondynamic |
| Leaflet morphology: | | | |
| • Thickening | Yes/moderate, severe | No/mild | No/mild |
| • Prolapse or flail | Usually present | No | No |
| • Calcification | Variable | No/mild | No/mild |
| Tethering pattern | None | Asymmetric | Symmetric |
| Systolic tenting | None | Increased | Markedly increased |
| Papillary muscle distance | Normal | Increased posterior papillary-intervalvular fibrosa distance | Increased interpapillary muscle distance |
| MR jet direction | Eccentric or central | Posterior | Usually central |
| CWD | May be late systolic (if MVP) or uniform if flail or with calcific degeneration | Density usually uniform throughout systole | Biphasic pattern, with increased density in early- and late-systolic flow and midsystolic dropout |
| PISA | Often hemispheric | Often not hemispheric | Often not hemispheric; may be biphasic |

*Primary and secondary MR may coexist.

points of the saddle-shaped MV annulus, falsely making the leaflets appear to be displaced into the LA from the annular plane.⁹⁶

A flail leaflet is part of the MVP spectrum and occurs when the leaflet edge, not just the leaflet body, is located in the LA with free motion. It occurs most commonly from rupture of the marginal chords. A flail leaflet almost always denotes severe MR and is clearly associated with adverse outcomes.⁹⁷⁻¹⁰⁰ An extreme of flail MV is

papillary muscle rupture. Other etiologies of primary MR are listed in [Table 5](#).

2. Secondary MR. The leaflets are intrinsically normal in secondary MR, although minor leaflet thickening and annular calcification can be present. With adverse LV remodeling, one or both of the mitral leaflets are pulled apically into the LV as a result of the outward

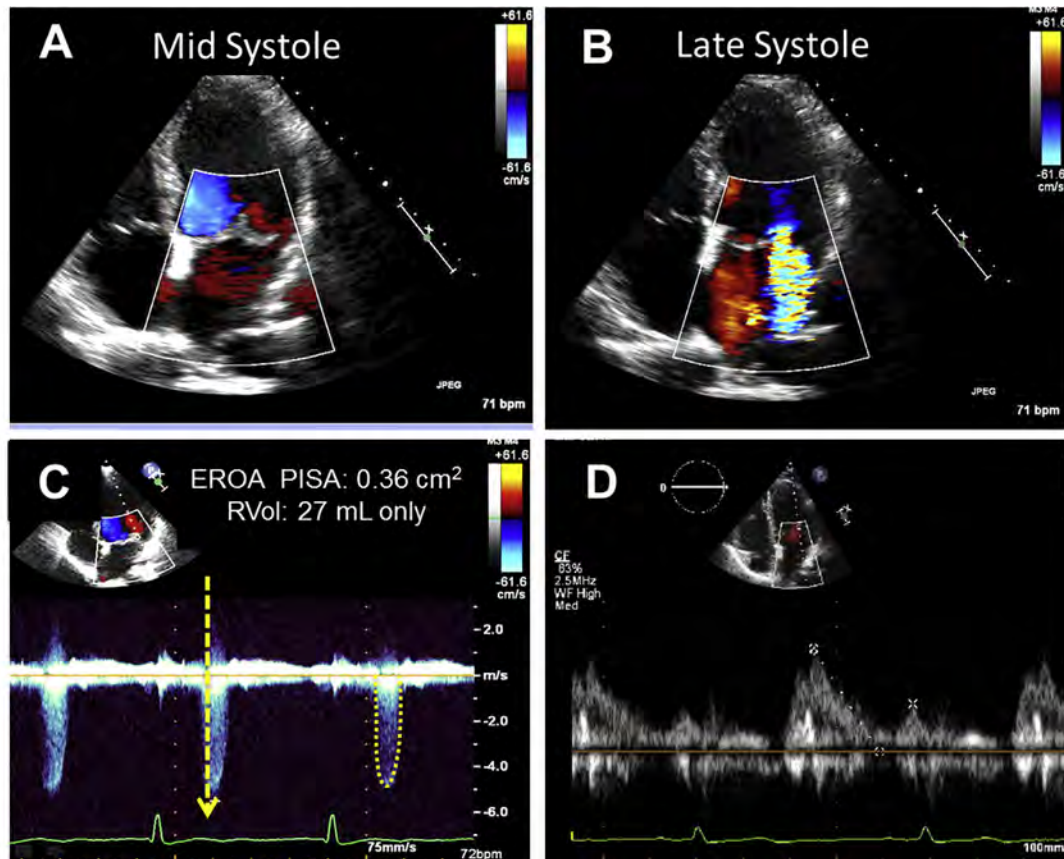


Figure 11 Late systolic MR in MVP. (A) Midsystolic frame shows no MR by color Doppler. LA volume index was normal (26 mL/m²). (B) Late-systolic frame shows an eccentric MR jet with a large flow convergence. (C) CWD profile of MR jet demonstrates that MR is confined to late systole (onset at *yellow arrow*, small VTI of jet, *dotted contour*). (D) Pulsed wave Doppler of mitral inflow shows an E wave velocity of 75 cm/sec with normal E/e' ratio consistent with normal LA pressure. Calculation of EROA will overestimate regurgitation severity: $EROA = 2\pi r^2 \cdot Va/PkV_{reg} = 2 \times 3.14 \times 1^2 \times 29.9/527 = 0.36 \text{ cm}^2$. Quantitation of regurgitation should rely on RVol by either PISA or volumetric measures. RVol by PISA = $EROA \cdot VTI_{reg} = 0.36 \times 76 = 27 \text{ mL}$.

displacement of the papillary muscles. This results in incomplete mitral leaflet closure.¹⁰¹⁻¹⁰⁷ The leaflets are apically displaced, tethered, and may have restricted mobility, especially the posterior leaflet. Leaflet tethering is often asymmetric, particularly in ischemic as opposed to dilated cardiomyopathies, where the P3 scallop is tethered more apically than is P1.¹⁰⁶ In such cases, the regurgitant orifice tends to be largest at the posteromedial scallop (P3), it may be irregularly shaped, and there may be two separate MR jets, which sometimes cross each other in the LA (Figures 12 and 13). Additional echocardiographic features of tethering include a bend in the body of the anterior leaflet from tethering of the basal or strut chordae (“seagull” or “hockey stick” sign), with a posteriorly directed jet. This should not be confused with MVP.

Several methods have been proposed to quantify the degree of tethering. The most common is a simple area measurement from the leaflet tips to the annular plane (tenting area) performed at mid-systole where the area is at a minimum. Another measure is coaptation height or depth, which measures the maximal distance from the leaflet tips to the annular plane and appears to correlate with the presence and severity of ischemic MR. More recently, 3D echocardiography has been applied to quantify leaflet tethering by measuring the tethering distance from papillary muscle tip to the mitral annulus and measuring the tenting volume (volume from leaflets to annular plane). While there is a general correlation between

tenting area or height and severity of secondary MR, these measurements are not precise in discriminating mild, moderate, or severe MR,¹⁰⁸ particularly since the leaflets may vary in size and thus accommodate the outward tethering. Mitral annular dilation also plays a role in the development of functional MR by increasing the area needed for the mitral leaflets to cover.¹⁰⁸⁻¹¹⁰ However, annular dilation alone without leaflet tethering is an uncommon cause of significant secondary MR, such as in patients with severe LA dilatation from long-standing atrial fibrillation.^{111,112}

3. Mixed Etiology. Occasionally, patients may present with mixed etiologies of MR that include both primary and secondary MR. For example, a patient with long-standing ischemic or nonischemic cardiomyopathy and secondary MR may rupture a chord and develop a flail leaflet. Conversely, a patient with mild or moderate MR from primary leaflet pathology may have a myocardial infarction and develop worse MR from tethering of the already abnormal leaflets. Although most cases of MR fall into the primary or secondary classification scheme, it should be recognized that mixed etiology can and does occur. It is important to emphasize that a severely restricted posterior leaflet due to ischemic wall motion abnormality may result in anterior leaflet override. In such cases, the anterior leaflet is not prolapsed and this does not represent a mixed etiology.

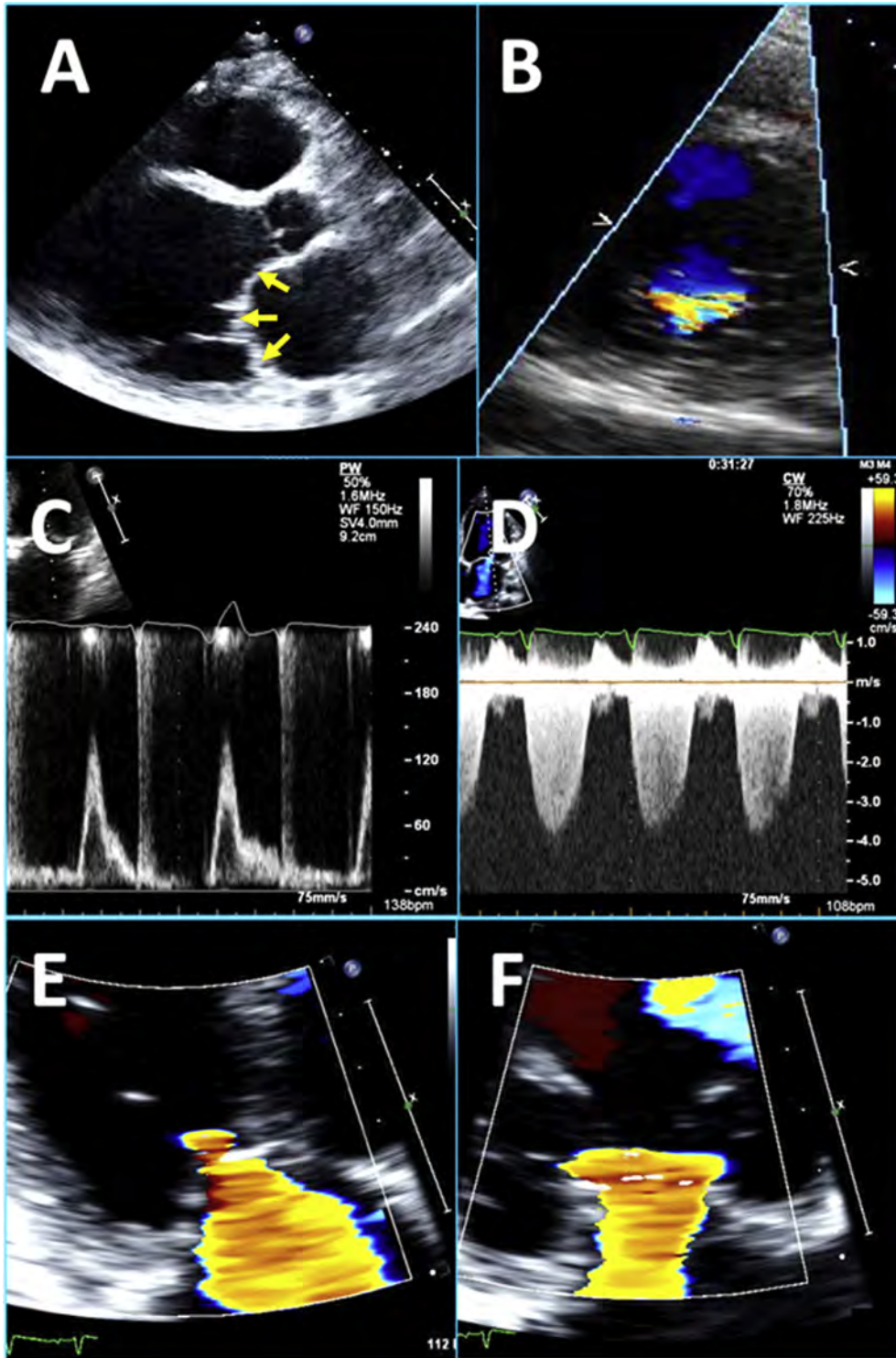


Figure 12 (A) An example of significant secondary MR in a dilated cardiomyopathy with marked tenting (*arrows*) of the MV. (B) Parasternal short-axis color Doppler showing regurgitation along the entire length of the valve coaptation. (C) PW Doppler at tips of the MV leaflets with high E velocity. (D) Triangular shape to the CW spectral in the setting of significant MR. (E and F) PISA from apical three- and two- (commissural) chamber views showing the different shapes of the flow convergence (nonhemispheric) and VC (noncircular). Assumption of a hemispheric flow convergence or circular VC would underestimate MR.

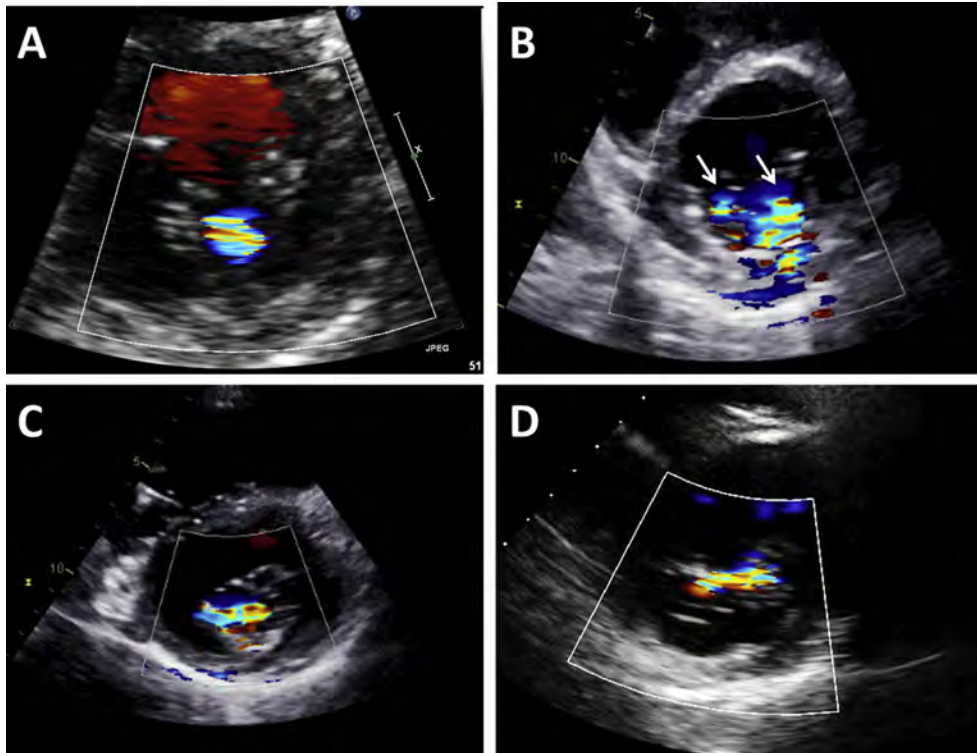


Figure 13 Short-axis views of MR in four different patients. (A) Relatively round orifice in myxomatous MV with flail P2 scallop. (B) Patient with secondary MR and two separate MR jets (arrows). (C) Noncircular MR located at P3 and P2 scallops in a patient with ischemic cardiomyopathy and a large inferoposterior wall motion abnormality. (D) Elliptical MR jet extending from commissure to commissure in a patient with ischemic cardiomyopathy.

C. Hemodynamic Considerations in Assessing MR Severity

1. Acute MR. Acute MR is far less common than chronic MR and usually results in hemodynamic compromise. It occurs most commonly due to ruptured papillary muscle after acute myocardial infarction, ruptured chordae tendinae resulting in a flail leaflet, or leaflet destruction due to endocarditis and less frequently due to rapid onset of cardiomyopathy (e.g., Takotsubo, myocarditis, or postpartum cardiomyopathy). Patients often present with pulmonary edema from elevated LA pressure, tachycardia, and severe hypotension from loss of forward SV. The combination of hypotension and high LA pressure results in a low driving pressure and therefore lower MR jet velocity across the MV. Accordingly, color Doppler imaging often will not show a large turbulent flow disturbance, and thus MR may be underestimated or not appreciated at all. The color Doppler jet is usually markedly eccentric, which again can underestimate MR severity. Anatomic imaging of flail leaflet or ruptured papillary muscle and the finding of a hyperdynamic LV with low Doppler systemic output along with clinical findings should be enough to substantiate the diagnosis, even if color Doppler does not show a large MR jet.¹¹³ Systolic flow reversal in the pulmonary veins is usually present and is helpful. TEE may be better at identifying acute severe MR. The Doppler methods for assessing MR severity in the remainder of this section apply to chronic and not to acute severe MR.

2. Dynamic Nature of MR. *a. Temporal variation of MR during systole.* The regurgitant orifice area in MR is often a variable quantity during the cardiac cycle, whether holosystolic or not. The measured

EROA as described earlier differs from the dynamic regurgitant orifice area in that it is usually derived from static, maximal values from single systolic frames. Although MR is classically holosystolic, patients with MVP often have no MR in early systole, with a relatively large EROA limited to mid- or late systole.⁴⁵ Compared with patients with holosystolic MR, those with late systolic MR yield lower RVols, despite similar EROA and jet areas.⁴⁵ In such patients, RVol has been shown to be superior to EROA in predicting cardiac death, admission for congestive heart failure, or new-onset atrial fibrillation.⁴⁵ On the other hand, patients with secondary MR often exhibit a biphasic pattern of MR, with an initial EROA peak in early systole, a decline in midsystole, and a second peak in late systole and isovolumic relaxation.^{41,57,58} Occasionally, transient MR limited to early systole is seen, particularly with bundle branch block. Thus, duration and timing of MR should be carefully evaluated. EROA to grade MR severity (Figure 3) should be used only if adjusted for the duration of MR, where feasible. Volumetric methods for assessing MR would forgo the above limitations and are preferred in nonholosystolic MR.

b. Effect of loading conditions. Grading of MR severity can be significantly impacted by hemodynamic changes, particularly blood pressure.¹¹⁴ Figure 14 shows an example of the dynamic nature of MR. Hemodynamic variation could be seen with conscious sedation (during TEE) but is particularly challenging in the operating room, brought about by anesthesia and vasoactive agents. In general, the commonly encountered intraoperative decrease in loading conditions or contractility is more likely to result in an underestimation of the MR grade compared with ambulatory conditions.¹¹⁵

Effect of Pressure Difference on Regurgitation Severity

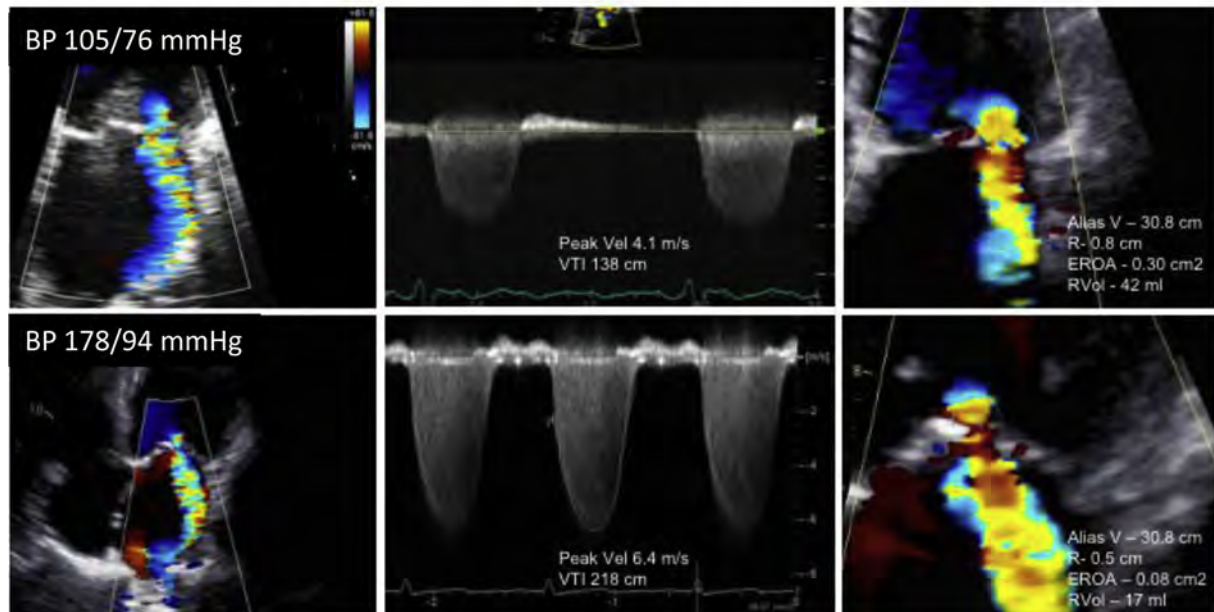


Figure 14 Importance of MR jet velocity in MR. The images are from two patients with functional ischemic MR due to posterior leaflet restriction, LVEF 30%, and similar appearance of eccentric MR jets directed laterally. The patient in the top panels has a low MR velocity (4.1 m/sec) consistent with low blood pressure and/or elevated LA pressure. His blood pressure (BP) was 105/76 mmHg. EROA by PISA is 0.3 cm² with an RVol of 42 mL. The patient in the lower panels has a similar MR jet appearance but has a peak MR velocity of 6.4 m/sec due to hypertension (178/94 mmHg). EROA is 0.08 cm² with an RVol of 17 mL. Despite similar MR jet appearance on color Doppler, the patient in the top panel has moderate MR; the patient in the bottom panel has mild MR.

Consequently, the preoperative MR grade may be preferred to guide therapeutic decisions. Intraoperative optimization of loading conditions may be used to guide surgical decision making.^{116,117} Patients with secondary MR may demonstrate significant variation in severity from one occasion to the next, depending on volume status and other hemodynamic variables.

c. Systolic anterior MV motion. Dynamic changes in MR severity can also occur with systolic anterior motion of the MV and LVOT obstruction, most commonly associated with either hypertrophic obstructive cardiomyopathy or following valve repair with a ring annuloplasty. This phenomenon has also been described in some patients with LV dysfunction and a hyperdynamic base following acute myocardial infarction or Takotsubo cardiomyopathy. Anterior MV leaflet motion exceeds that of the posterior leaflet, thereby creating malcoaptation with a posteriorly directed jet.¹¹⁸⁻¹²⁰

3. Pacing and Dysrhythmias. The severity of MR can also be influenced by cardiac dysrhythmias and pacing.¹²¹ RV pacing has been associated with development of functional MR,¹²² and cardiac resynchronization therapy has been shown to improve functional MR; the response, however, is not uniform.¹²³⁻¹²⁶ Atrial fibrillation is commonly experienced by patients with MR and may confound its grading due to rapid ventricular response or variable cycle lengths. In patients with a prolonged PR interval due to atrioventricular conduction abnormalities, atrial systole can induce premature ineffective valve closure, accompanied by varying degrees of diastolic MR.¹²⁷ Careful attention to heart rhythm and pacing is therefore important in evaluating MR.

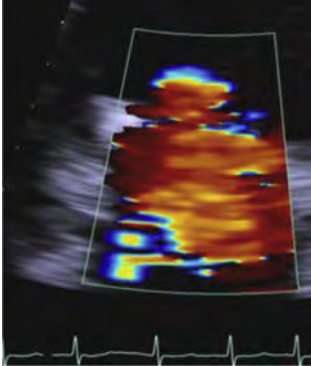
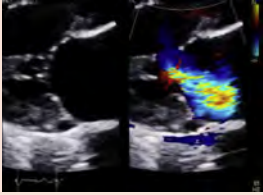
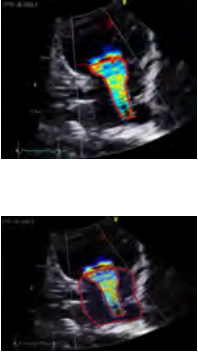
D. Doppler Methods of Evaluating MR Severity

There are several methods for evaluating the severity of MR with Doppler echocardiography. The various methods, their optimization, advantages, and limitations are hereby discussed and highlighted in [Table 7](#).

1. Color Flow Doppler. Color Doppler flow mapping is the primary modality to screen for MR ([Figure 15](#)). There are three methods of evaluating MR severity by color flow Doppler: regurgitant jet area, VC, and flow convergence. Although jet area was the first method used for assessing MR severity, its sole use is less accurate than the latter two methods.

a. Regurgitant jet area. Although jet area is excellent for excluding MR, it is not reliable for grading MR severity, even when indexed for LA area.^{2,128} Patients with acute severe MR, in whom blood pressure is low and LA pressure is elevated, may have a small color flow jet area, whereas hypertensive patients with mild MR may have a large jet area. Jet area is also dependent on the mechanism of MR. With flail leaflet, the MR jet is often very eccentric; jet area is small, underestimating MR severity as the jet spreads out along the wall and loses energy.¹⁹ In secondary MR, central jets with a slit-like orifice can appear large, particularly in the two-chamber view, along the line of MV coaptation, even when the EROA is small. Therefore, MR grade should not be determined by “eyeballing” the color flow area of the MR jet alone, without considering the origin of the jet (VC) and its flow convergence. However, a small noneccentric jet with a narrow VC (<0.3 cm) and no visible flow convergence region usually indicates mild MR ([Table 7](#)). Conversely, a large jet with a wide VC

Table 7 Doppler echocardiography in evaluating severity of MR

| Modality | Optimization | Example | Advantages | Pitfalls |
|------------------------------------|---|---|--|--|
| Color flow Doppler 2D: | | | | |
| Proximal flow convergence | <ul style="list-style-type: none"> Align direction of flow with insonation beam to avoid distortion of hemisphere from noncoaxial imaging Zoomed view Variance off Change baseline of Nyquist limit in the direction of the jet Adjust lower Nyquist limit to obtain the most hemispheric flow convergence (typically 30-40 cm/sec) Measure the radius from the point of color aliasing to the VC |  | <ul style="list-style-type: none"> Rapid qualitative assessment Absence of proximal flow convergence usually a sign of mild MR | <ul style="list-style-type: none"> Multiple jets Eccentric jets Constrained jet (LV wall) Nonhemispheric shape, particularly functional MR Overestimation when MR not holosystolic |
| VCW | <ul style="list-style-type: none"> Parasternal long-axis view Zoomed view Imaging plane for optimal VC Best measured when proximal flow convergence, VC, and MR jet aligned in same plane |  | <ul style="list-style-type: none"> Surrogate for regurgitant orifice size Independent of flow rate and driving pressure for a fixed orifice Can be applied in eccentric jets Less dependent on technical factors Good at separating mild (<0.3 cm) from severe MR (≥ 0.7 cm) | <ul style="list-style-type: none"> Problematic in the presence of multiple jets Convergence zone needs to be visualized for adequate measurement Overestimation when MR not holosystolic |
| Jet area or jet area/LA area ratio | <ul style="list-style-type: none"> Apical view Zoom view Measure largest jet alone or as ratio to LA area in same view |  | <ul style="list-style-type: none"> Easy to measure | <ul style="list-style-type: none"> Shown to be imprecise in multiple studies, particularly in eccentric, wall-impinging jets Dependent on hemodynamic (especially LV systolic pressure) and technical variables Overestimation when MR not holosystolic |

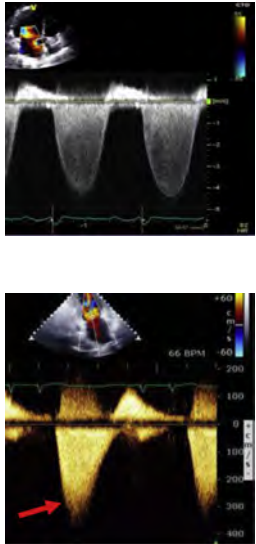
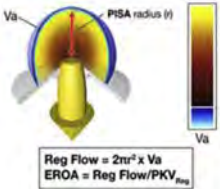
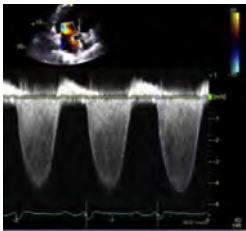
(Continued)

Table 7 (Continued)

| Modality | Optimization | Example | Advantages | Pitfalls |
|--|---|---------|--|--|
| Color flow Doppler 3D: 3D VCA | <ul style="list-style-type: none"> Color flow sector should be as narrow as possible to improve volume rates and line density Align orthogonal cropping planes along the axis of the jet Planimeter the high velocity aliased signal of VC, avoiding low velocity (dark color) signals | | <ul style="list-style-type: none"> Multiple jets of differing directions may be measured Can identify severe functional MR in some cases where PISA underestimates EROA | <ul style="list-style-type: none"> Subject to color Doppler blooming Limited temporal and spatial resolution Overestimation when MR not holosystolic Multiple jets may be in different planes, must be analyzed separately and then added Cumbersome, often requires offline analysis |
| Pulsed wave Doppler: Mitral inflow velocity | Align insonation beam with the flow across the MV at leaflet tips in apical four-chamber view | | <ul style="list-style-type: none"> E velocity ≥ 1.2 m/sec a simple supportive sign of severe MR (volume load) Dominant A-wave inflow pattern virtually excludes severe MR Can be obtained with both TTE and TEE | <ul style="list-style-type: none"> Depends on LV relaxation and filling pressures High E velocity not specific for severe MR in secondary MR, atrial fibrillation and mitral inflow stenosis |
| Pulmonary vein flow pattern | Use small sample volume (3-5 mm) placed 1 cm into pulmonary vein | | <ul style="list-style-type: none"> Systolic flow reversal in more than one pulmonary vein is specific for severe MR Normal pulmonary vein pattern suggests low LA pressure and hence nonsevere MR | <ul style="list-style-type: none"> Eccentric MR of mild or moderate severity directed into a pulmonary vein alters flow pattern Systolic blunting is not specific for significant MR (common in secondary MR and present in elevated LA pressure, atrial fibrillation) |

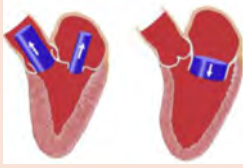
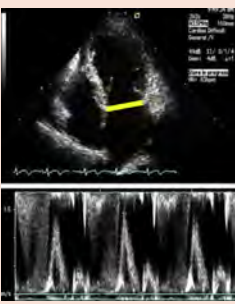
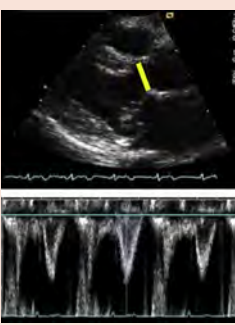
(Continued)

Table 7 (Continued)

| Modality | Optimization | Example | Advantages | Pitfalls |
|---|---|---|---|---|
| CWD | | | | |
| Density and contour of regurgitant jet | Align insonation beam with the flow |  | <ul style="list-style-type: none"> • Simple • Density is proportional to the number of red blood cells reflecting the signal • Faint or incomplete jet is compatible with mild MR • A triangular contour (early MR peak velocity; see arrow) denotes a large regurgitant pressure wave and hemodynamic significance | <ul style="list-style-type: none"> • Qualitative • Perfectly central jets may appear denser than eccentric jets of higher severity • Density is gain dependent • A contour with an early peak velocity is not sensitive for severe MR |
| Quantitative Doppler: EROA, RVol, and fraction | | | | |
| Flow convergence method (PISA): | <ul style="list-style-type: none"> • Align insonation beam with the flow, usually in apical views; zoomed view • Lower the color Doppler baseline in the direction of the jet • Look for the hemispheric shape to guide the best low Nyquist limit • Look for need for angle correction if flow convergence zone is nonplanar • Measure PISA radius at roughly the same time as CW jet peak velocity |  | <ul style="list-style-type: none"> • Rapid quantitative assessment of lesion severity (EROA) and volume overload (RVol) • Shown to predict outcomes in degenerative and functional MR | <ul style="list-style-type: none"> • May not be accurate in multiple jets • Less accurate in eccentric jets or markedly crescent-shaped orifices • Small errors in radius measurement can lead to substantial errors in EROA due to squaring of error. This is less likely to misclassify patients at very large (≥ 1.0 cm) or very small radii (≤ 0.4 cm) |
| | |  | | |

(Continued)

Table 7 (Continued)

| Modality | Optimization | Example | Advantages | Pitfalls |
|--|--|--|---|--|
| <p>SV method</p>  <p>$RVol = SV_{MV} - SV_{LVO}$</p> | <ul style="list-style-type: none"> • LVOT diameter measured at the annulus in systole and pulsed Doppler from apical views at same site • Mitral annulus measured at mid-diastole; pulsed Doppler at the annulus level in diastole • Total LV SV can be measured by pulsed Doppler technique at mitral annulus or by the difference between LV end-diastolic volume and end-systolic volume. • LV volumes are best measured by 3D. Contrast may be needed to better trace endocardial borders. If 3D not feasible, use 2D method of disks. | <p>Mitral annulus</p>  <p>LVOT</p>  | <ul style="list-style-type: none"> • Quantitative, valid with multiple jets and eccentric jets. • Provides both lesion severity (EROA, RF) and volume overload (RVol) • Validated against CMR in isolated MR | <ul style="list-style-type: none"> • Not valid for combined MR and AR, unless pulmonic site is used • Cumbersome, needs training; small errors in each different measurement can combine to magnify error in final results • Pulsed Doppler method (mitral SV) and LV volume method may give different results. |

(≥ 0.7 cm) and where the jet wraps around the LA and penetrates into the pulmonary veins is almost always severe MR. Anything else should alert the observer to use the methods below.

b. Vena contracta (width and area). The VC is a measure of the effective regurgitant orifice.²⁶ For MR, the VC width (VCW) should be imaged preferably in a parasternal long-axis view (axial resolution) and measured using zoom mode at the narrowest portion of the jet as it emerges from the orifice (Figure 1). A VC < 0.3 cm usually denotes mild MR; ≥ 0.7 cm is specific for severe MR.^{2,128} Intermediate values overlap substantially between MR grades, so additional methods should be used for confirmation. VCW works equally well for central and eccentric jets,²⁴ however, it is dependent on orifice geometry, underestimating MR severity if there are multiple jets or if there is a markedly elliptical (noncircular) orifice shape, as often seen in secondary MR.

The development of 3D echocardiography has allowed direct measurement of VC area (VCA). Multiplanar reconstruction tools are used to orient orthogonal imaging planes (x and y) through the long axis of the MR jet, and the z plane is adjusted perpendicularly through the narrowest CSA of the VC (Figure 16). VCA can then be measured by manual planimetry of the color Doppler signal. If there are multiple jets, the imaging plane should be oriented through each jet separately for tracing. Care should be taken to only measure the highest velocity, aliased signal so as not to include low-velocity (dark color) eddies that are not part of the jet core. Limitations include technically difficult images, dynamic variation in the regurgitant orifice over the cardiac cycle, and the color Doppler blooming effect, in which the color Doppler signal is larger than the jet core itself.¹²⁹

Three-dimensional echocardiography has shown that the regurgitant orifice is often crescent shaped in secondary MR (Figure 16).^{30-33,61,62,130-133} In such cases, the assumption of circular orifice geometry inherent to VCW may result in underestimation of secondary MR. In a recent study, 3D VCA > 0.4 cm² denoted severe MR.³⁰ However, studies relating 3D VCA to outcomes have not been performed yet.

c. Flow convergence (PISA). In MR, PISA is more accurate for central regurgitant jets than eccentric jets and for circular orifices than noncircular orifices. It is usually easy to identify the aliasing line of the hemisphere; however, it can be difficult to judge the exact location of the orifice. Optimization of acquisition and measurement of PISA are essential and have been discussed earlier, as any error in radius is subsequently squared in the derivation of EROA. Errors of 10%-25% are common even among expert readers¹³⁴ and are the smallest for central jets; therefore, PISA should always be considered in the context of the other echo/Doppler findings. The dynamic nature of the orifice in MR can also lead to errors with the PISA formula. The regurgitant orifice is often crescent shaped in secondary MR. In such cases, the assumption of circular orifice geometry inherent to 2D PISA may result in underestimation of secondary MR. This may partly explain the finding that lower values of EROA by 2D PISA are associated with worsened prognosis in secondary MR.¹³⁵⁻¹³⁷ Also, it should be remembered that PISA EROA, like VCW or VCA, is calculated from a single-frame image. These parameters therefore will overestimate MR severity when MR is not holosystolic (Figure 11). Finally, poor alignment of the CWD beam

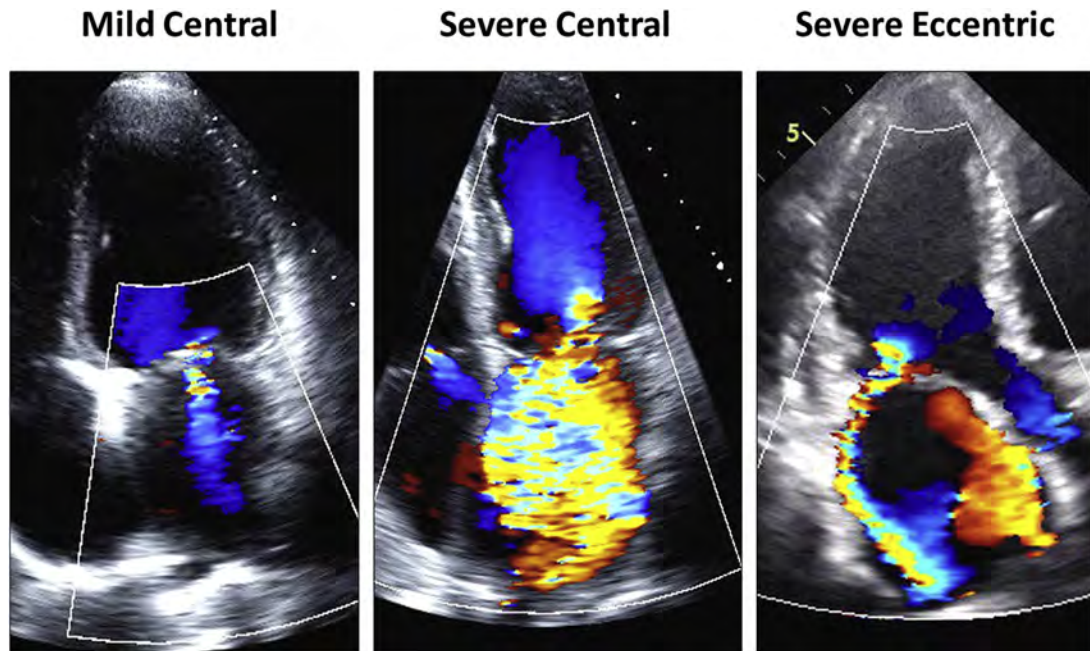


Figure 15 Color Doppler panel of mild and severe MR (central and eccentric). In the eccentric, wall-impinging jet case, the jet area is small, but the flow convergence and VC are large and alert to the severity of regurgitation.

3D Quantitation in Primary and Secondary MR

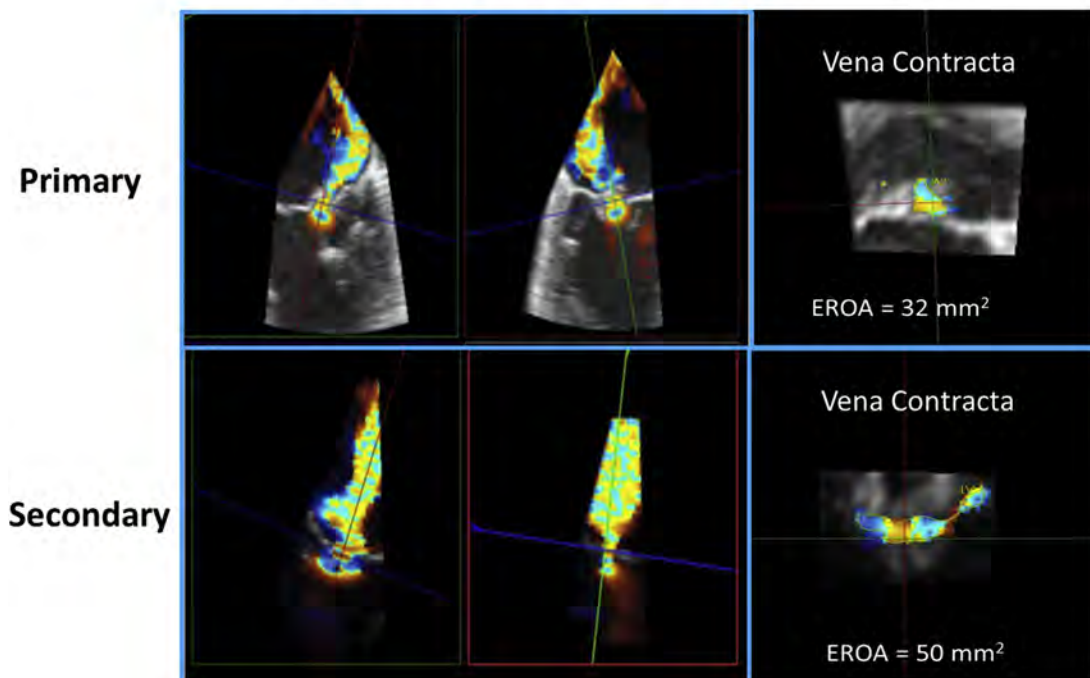


Figure 16 Two cases showing evaluation and quantitation of VCA with 3D echocardiography and multiplanar reconstruction. A case of primary MR (*upper panels*) with a circular VCA and hemispheric PISA and another with secondary MR (*lower panels*) with elliptical VCA and nonhemispheric PISA.

with an eccentric jet will lead to an underestimation of velocity and an overestimation of the EROA.

A simplified approach to PISA quantitation has been validated.¹³⁸ Assuming a 5 m/sec MR jet (100 mmHg pressure difference between LV and LA in systole), baseline shifting the color Doppler display to a V_a of around 40 cm/sec and measuring the aliasing radius r yields a

simplified estimate of $EROA = r^2/2$. This simplification does not hold at extremes of blood pressure, but the vast majority of patients have jets between 4 and 6 m/sec for which this approximation is reasonable. Generally, in primary MR, an $EROA \geq 0.4 \text{ cm}^2$ is consistent with severe MR, $0.20\text{-}0.39 \text{ cm}^2$ with moderate, and $< 0.20 \text{ cm}^2$ with mild MR.

2. Continuous Wave Doppler. In most patients, maximum MR velocity is 4-6 m/sec due to the high systolic pressure gradient between the LV and LA. The velocity itself does not provide useful information about the volumetric severity of MR, but it does provide clues to the hemodynamic consequences of MR. A low MR peak velocity (e.g., 4 m/sec) suggests hemodynamic compromise (low blood pressure/elevated LA pressure). In addition to peak velocity, the contour of the velocity profile and its density are useful. A truncated, triangular jet contour with early peaking of the maximal velocity indicates elevated LA pressure or a prominent regurgitant pressure wave (Figure 12). The density of the CWD signal is a qualitative index of MR severity; a dense signal suggests significant MR, whereas a faint signal is likely to be mild or trace MR. CWD should also be used to interrogate the TR jet to estimate PA systolic pressure, another indirect clue as to MR severity and compensation for the volume overload.

3. Pulsed Doppler. Pulsed Doppler methods can be used to calculate SVs at the LVOT and MV level and determine RVol and RF (Figure 4; Table 7).^{20,46,139,140} RVol can also be calculated by comparing Doppler LVOT SV to total LV SV derived from LV volumes. Because 2D echocardiography tends to underestimate LV volumes, 3D LV volumes are preferable, and ultrasound contrast should be used if needed to identify endocardial borders.^{3,50}

Pulsed Doppler tracings at the mitral leaflet tips are commonly used to evaluate LV diastolic function but can be helpful in MR. Patients with severe MR have a dominant early filling (increased E velocity) due to increased diastolic flow across the MV (E velocity is usually ≥ 1.2 m/sec). An impaired relaxation pattern with a low E velocity and A wave dominance virtually excludes severe MR. Because of the effect of relaxation on mitral inflow indices, these observations are more applicable in individuals older than 50 years of age or in conditions of impaired myocardial relaxation.¹²⁸ The mitral inflow pattern is also more reliable for assessing primary MR because, in secondary MR, it is difficult to determine whether E dominance is due to significant MR or elevated LV filling pressures. The peak E velocity is also affected by even mild degrees of mitral stenosis in the presence of rheumatic disease, mitral annular calcification, or a mitral annular ring.

4. Pulmonary Vein Flow. Pulsed Doppler of pulmonary venous flow is a useful adjunct to evaluating the hemodynamic consequences of MR. With increasing severity of MR, there is a diminution of the systolic velocity, culminating with systolic flow reversal in severe MR. Since the MR jet may selectively enter a vein, sampling more than one vein is recommended, especially during TEE. One limitation of the pulmonary venous pattern is that elevation in LA pressure of any etiology as well as atrial fibrillation may also result in a blunted systolic forward flow.¹⁴¹ Thus, systolic blunting is less valuable in secondary MR than in primary MR. As a result, the pulmonary venous flow pattern should be used adjunctively with other parameters. Nevertheless, the finding of systolic flow reversal in more than one pulmonary vein is specific for severe MR. If the MR is confined to late systole, flow reversal may be present only during late systole. It is also important to distinguish true systolic flow reversal from contamination by the MR jet itself, a more difficult task during TTE compared with during TEE.

E. Assessment of LV and LA Volumes

Primary significant MR imposes a pure volume overload on the LV. If chronic, such a condition would result in chamber dilation and ultimate LV dysfunction if untreated.¹ It is important to consider body size in evaluating LV size, particularly in patients with small body surface area such as women.¹³ On the other hand, in secondary MR, the relation between LV dilation and MR severity is complicated because MR results from LV dysfunction but also may contribute to it. In either case, it is important to measure both LV chamber size and function for determining the need for surgical or percutaneous intervention and for measuring any reverse LV remodeling after therapy.¹⁴² Three-dimensional echocardiography is now recommended for evaluation of LV volumes because it offers improved accuracy and precision compared to 2D echocardiography.^{3,50} Echocardiographic measurements of global longitudinal strain may become useful in evaluating earlier myocardial dysfunction in MR^{143,144} that could be masked by volume-based measurements, such as LV ejection fraction (LVEF).

LA dilation is also an expected consequence of severe MR. A normal LA size generally excludes severe chronic MR. LA volumes are superior to LA diameters in evaluating LA dilation and in predicting outcomes and atrial fibrillation.¹⁴⁵ However, LA dilatation can occur in many disease states including hypertension and atrial fibrillation. Therefore, a dilated LA does not necessarily imply severe MR.

F. Role of Exercise Testing

Exercise echocardiography can be useful in evaluating patients with both primary MR and ischemic functional MR.¹²⁸ Exercise may unmask the presence of symptoms and establish functional capacity in patients who are sedentary or have equivocal symptoms. Failure of LVEF to increase normally with exercise predicts worse postoperative LV function in primary MR.¹⁴⁶ Color Doppler inclusive of changes in EROA derived with PISA during exercise can be technically difficult to capture due to tachypnea and tachycardia and may be best performed during supine bicycle exercise. Increases in EROA (≥ 13 mm²) during exercise have been shown to be associated with symptoms and adverse outcome in secondary MR.¹³⁶ Lastly, increased PA pressure during exercise (≥ 60 mmHg) may be important in asymptomatic severe primary MR.^{1,136,146,147} There is currently no role for pharmacologic stress echocardiography to evaluate severity of MR or direct its management.

G. Role of TEE in Assessing Mechanism and Severity of MR

TEE is indicated to evaluate MR severity in patients in whom TTE is inconclusive or technically difficult. In addition, TEE is particularly well suited to identify the underlying mechanism of MR and for planning MV surgery or percutaneous valve procedures and provides overall a better accuracy in localizing MV pathology.¹² The majority of the above methods of quantifying MR can be used during TEE. In particular, the higher resolution of TEE, multiplane and 3D capabilities, and proximity to the MV makes VC imaging and PISA easier and probably more accurate. Furthermore, interrogation of all pulmonary veins is generally feasible and better than with TTE. A few cautionary points are worth mentioning regarding TEE. Since jet size is affected by transducer frequency, PRF, and signal strength, the same jet may appear larger on TEE compared with on TTE. Because sedatives are used, careful attention to blood pressure is important; secondary MR may appear less severe if the blood pressure is significantly lowered. Quantitative pulsed Doppler is more

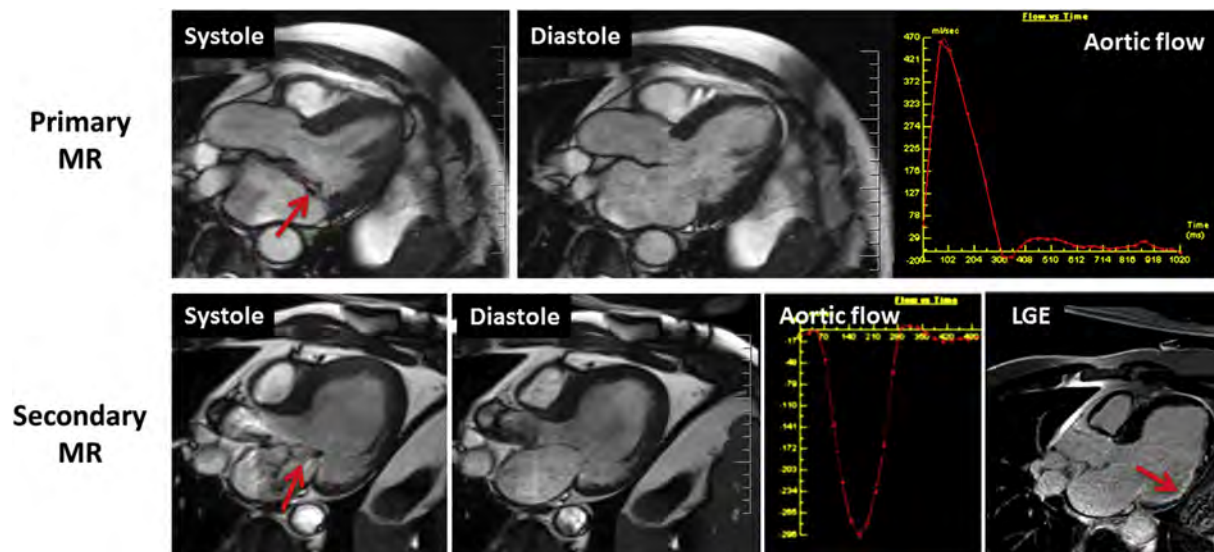


Figure 17 Examples of primary and secondary MR evaluated with CMR. There is flail of the posterior MV leaflet (red arrow) with highly eccentric anteriorly directed jet of MR. Volumetric calculations showed an LV end-diastolic volume of 235 mL, end-systolic volume of 75 mL, and thus a total LV SV of 160 mL. The systemic aortic SV was 94 mL. Thus, the mitral RVol was 66 mL and the RF was 66/160 or 41%. In the case of secondary MR, the mitral leaflets are seen tethered apically with the jet of MR (red arrow). The total LV SV was 77 mL with an RVol of 32 mL and an RF of 42%. Late gadolinium enhancement (LGE) showed localization of a previous infarction in the posterior wall. This is consistent with moderate MR.

challenging and is the most affected quantitative MR parameter with TEE: acquisition of pulsed Doppler in the LVOT is usually hampered by angulation issues, leading to underestimation of systemic output.

H. Role of CMR in the Assessment of MR

CMR offers several important advantages in the assessment of MR. This includes identifying the mechanism of MR, quantifying MR severity, and determining its consequences on cardiac remodeling.

1. Mechanism of MR. Like echocardiography, CMR can provide information about the mechanism of MR by identifying morphologic abnormalities of the MV apparatus.¹⁴⁸ The presence of billowing, prolapse, or flail segments can be identified by dedicated cine imaging performed through the different scallops of the MV leaflets (Figure 17).^{149,150} In secondary MR, CMR offers accurate assessment of LV dilation and function in addition to identification of myocardial and papillary muscle scar (Figure 17).^{151,152}

2. Methods of MR Quantitation. MR can be assessed using several techniques by CMR. This includes qualitative or semiquantitative visual assessment of MR jet based on spin dephasing in the LA,¹⁵³ measurement of the VCA or anatomical regurgitant orifice area on short-axis cine of phase-contrast images,^{77,154} and quantification of RVol and RF.¹⁵⁵⁻¹⁵⁷ Among these techniques, quantification of RVol and fraction is recommended (Figures 8 and 17). The suggested preference order for calculation of RVols is the use of

- The difference between LV SV using planimetry of short-axis cine images and aortic SV obtained by phase-contrast images
- The difference in LV and RV SV by endocardial contouring of LV and RV cine images
- The difference between the mitral inflow SV and aortic SV by phase-contrast imaging

The RF can be calculated by dividing the RVol by the LV SV for the first two methods and by the mitral inflow SV for the third method.

3. LV and LA Volumes and Function. CMR provides the most accurate and reproducible assessment of LV volume and ejection fraction and LA volume. All measurements should be indexed to BSA, and remodeling can be assessed based on existing reference values.^{158,159}

4. When Is CMR Indicated? The primary indication of CMR is the evaluation of MR severity when assessment by echocardiography is felt to be unsatisfactory or when there is a discrepancy between MR severity and clinical findings. CMR may provide additional information about the mechanism of MR and myocardial viability, both of which may have implications for surgical intervention, and CMR importantly provides quantitative evaluation of chamber size, RVol, and fraction.

I. Concordance between Echocardiography and CMR

As CMR is increasingly used in evaluating MR and is usually performed after an initial echocardiogram, it is important to review the concordance of evaluating MR severity between these two modalities and what to expect clinically, even with technical adequacy of both studies. There is a paucity of comparative studies, and the majority have shown a modest concordance in the qualitative or quantitative evaluation of MR.^{85,139,160-162} This is expected in view of the various factors that affect evaluation of regurgitation by each modality. Reproducibility of quantitation has been consistently higher with CMR. In a recent study, echocardiographic grading of MR severity was higher, and 2D PISA-derived RVols were larger than by CMR.¹⁶¹ More recently, however, using volumetric pulsed Doppler flow quantitation, a modest correlation was seen between RVol/fraction by echo and CMR, without a consistent over estimation by either

Table 8 Grading the severity of chronic MR by echocardiography

| | MR severity* | | | |
|-------------------------------------|---|--|---------------------|---|
| | Mild | Moderate | | Severe |
| Structural | | | | |
| MV morphology | None or mild leaflet abnormality (e.g., mild thickening, calcifications or prolapse, mild tenting) | Moderate leaflet abnormality or moderate tenting | | Severe valve lesions (primary: flail leaflet, ruptured papillary muscle, severe retraction, large perforation; secondary: severe tenting, poor leaflet coaptation) |
| LV and LA size [†] | Usually normal | Normal or mild dilated | | Dilated [‡] |
| Qualitative Doppler | | | | |
| Color flow jet area [§] | Small, central, narrow, often brief | Variable | | Large central jet (>50% of LA) or eccentric wall-impinging jet of variable size |
| Flow convergence | Not visible, transient or small | Intermediate in size and duration | | Large throughout systole |
| CWD jet | Faint/partial/parabolic | Dense but partial or parabolic | | Holosystolic/dense/ triangular |
| Semiquantitative | | | | |
| VCW (cm) | <0.3 | Intermediate | | ≥0.7 (>0.8 for biplane) [¶] |
| Pulmonary vein flow [#] | Systolic dominance (may be blunted in LV dysfunction or AF) | Normal or systolic blunting [#] | | Minimal to no systolic flow/ systolic flow reversal |
| Mitral inflow ^{**} | A-wave dominant | Variable | | E-wave dominant (>1.2 m/sec) |
| Quantitative^{††,‡‡} | | | | |
| EROA, 2D PISA (cm ²) | <0.20 | 0.20-0.29 | 0.30-0.39 | ≥0.40 (may be lower in secondary MR with elliptical ROA) |
| RVol (mL) | <30 | 30-44 | 45-59 ^{††} | ≥ 60 (may be lower in low flow conditions) |
| RF (%) | < 30 | 30-39 | 40-49 | ≥50 |

ROA, Regurgitant orifice area.

Bolded qualitative and semiquantitative signs are considered specific for their MR grade.

*All parameters have limitations, and an integrated approach must be used that weighs the strength of each echocardiographic measurement. All signs and measures should be interpreted in an individualized manner that accounts for body size, sex, and all other patient characteristics.

[†]This pertains mostly to patients with primary MR.

[‡]LV and LA can be within the "normal" range for patients with acute severe MR or with chronic severe MR who have small body size, particularly women, or with small LV size preceding the occurrence of MR.

[§]With Nyquist limit 50-70 cm/sec.

^{||}Small flow convergence is usually <0.3 cm, and large is ≥ 1 cm at a Nyquist limit of 30-40 cm/sec.

[¶]For average between apical two- and four-chamber views.

[#]Influenced by many other factors (LV diastolic function, atrial fibrillation, LA pressure).

^{**}Most valid in patients >50 years old and is influenced by other causes of elevated LA pressure.

^{††}Discrepancies among EROA, RF, and RVol may arise in the setting of low or high flow states.

^{‡‡}Quantitative parameters can help subclassify the moderate regurgitation group.

modality, similar to previous studies.¹⁶² Exact concordance of semi-quantitative grading of MR (four-grade scale) was seen in 50% of patients, increasing to 90% when allowing for a one grade difference in MR severity.¹⁶² The majority of the discrepancies in assessing MR occurred in secondary MR, where RVols are small and more subject to errors. It is important to note that while CMR is more reproducible, each modality has its potential errors and limitations and is technically demanding. In the 10%-20% where a significant discrepancy in assessment of MR between these modalities occurs¹⁶² and may be important clinically, further assessment would be required with either TEE or invasive means if reconciliation of findings (e.g., problem with

one technique or the other, interim physiologic changes, rhythm disturbance, etc.) cannot be achieved.

J. Integrative Approach to Assessment of MR

Evaluation of MR severity ideally integrates multiple parameters because all methods have intrinsic limitations and lack precision. It is also important to distinguish between the amount of MR and its hemodynamic consequences. For example, a modest RVol that develops acutely into a small, noncompliant LA may cause severe pulmonary congestion and systemic hypotension.

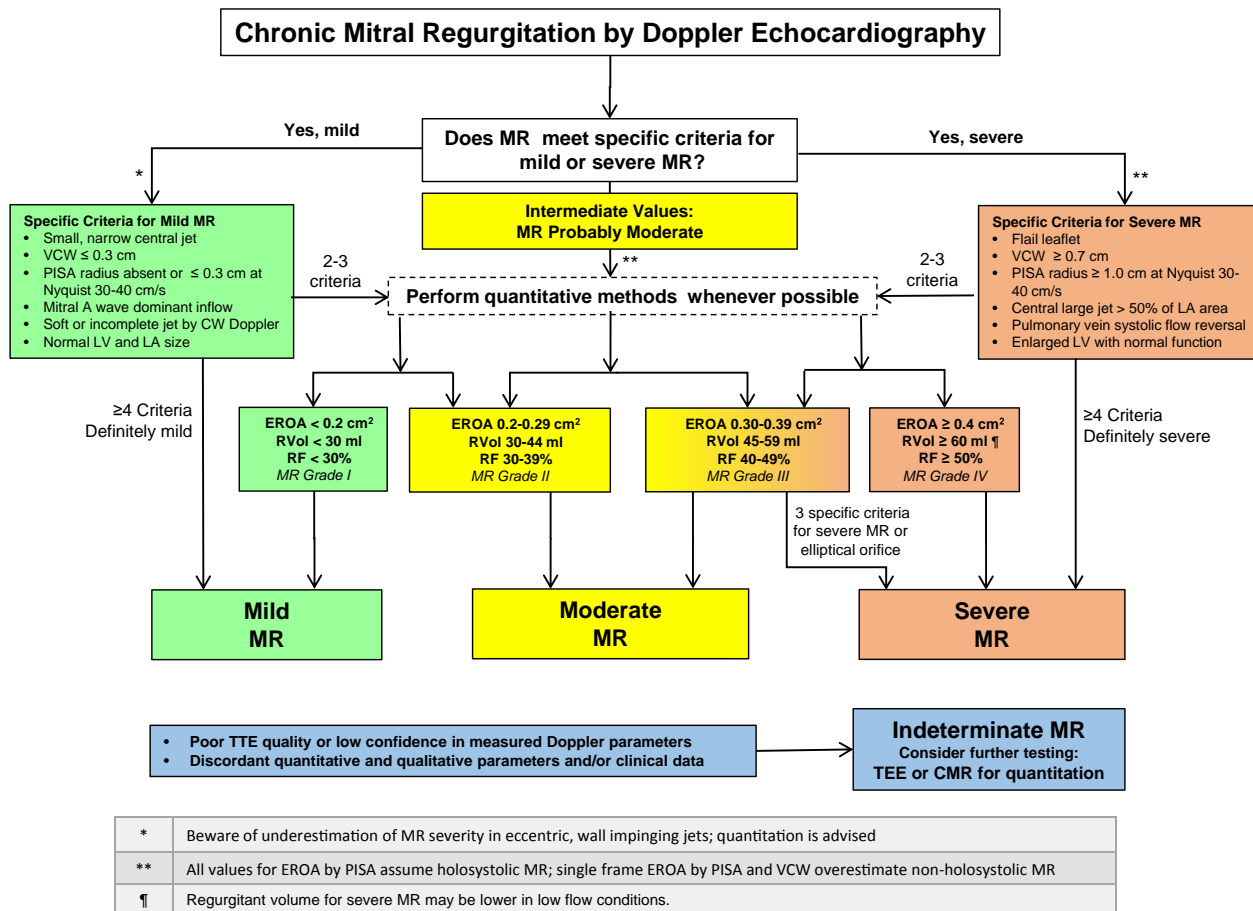


Figure 18 Algorithm for the integration of multiple parameters of MR severity. Good-quality echocardiographic imaging and complete data acquisition are assumed. If imaging is technically difficult, consider TEE or CMR. MR severity may be indeterminate due to poor image quality, technical issues with data, internal inconsistency among echo findings, or discordance with clinical findings.

Conversely, some patients with chronic severe MR remain asymptomatic owing to compensatory mechanisms and a dilated, compliant LA. It is important to consider primary and secondary MR separately, as the etiology, mechanism, underlying cardiac structures, and hemodynamics differ significantly and may modulate echo/Doppler parameters assessing MR. However, regardless of etiology, if there is a small central jet, normal leaflet morphology, a VCW < 0.3 cm, no proximal flow convergence, and an A-wave dominant mitral inflow pattern, then MR is mild and further quantitation is not necessary. Conversely, if there is a large jet, with a prominent flow convergence, large VCW > 0.7 cm, flow reversal in the pulmonary veins, then MR is severe; quantitation would substantiate the severity of the regurgitation.

The qualitative, semiquantitative, and quantitative parameters used in grading primary MR are summarized in Table 8, along with a suggested algorithm for the assessment of MR severity (Figure 18) that incorporates these various parameters. In applying this scheme, the writing committee wishes to emphasize that specific signs have inherently a high positive predictive value for the severity of regurgitation and are thus highlighted in bold in Table 8. The supportive signs or clues may be helpful in consolidating the impression of the degree of MR, although their predictive value is more modest. It is the consensus of the committee mem-

bers that the process of grading MR should be comprehensive, using a combination of clues, signs, and measurements obtained by Doppler echocardiography. If the MR is definitely determined as mild or less using these signs, no further measurement is required. If there are signs suggesting that the MR is more than mild and the quality of the data lends itself to quantitation, it is desirable for echocardiographers with experience in quantitative methods to determine quantitatively the degree of MR, including the RVol and fraction as descriptors of volume overload and the EROA as a descriptor of the lesion severity. Quantitation of regurgitation can further subclassify regurgitation into four grades, with grade III having some overlap with characteristics of severe MR (Figure 18 and Table 8), hence the need for an integrative approach. Finally, it is important to stress that when there is congruent evidence from different parameters, it is easy to grade MR severity with confidence. When different parameters are contradictory, one must look carefully for technical and physiologic reasons to explain the discrepancies and rely on components with the highest quality of the primary data that are the most accurate, considering the underlying physiologic condition. There will be times when MR severity and/or mechanism is uncertain by TTE and further testing is needed with TEE or CMR. The following are some considerations in the assessment of severity of primary and secondary MR:

1. Considerations in Primary MR. Severe valve lesions on 2D or 3D imaging, such as flail leaflet, ruptured papillary muscle, severe leaflet retraction, or a large perforation, are specific for severe MR. Similarly, a properly measured VCW ≥ 0.7 cm is specific for severe MR, as is systolic flow reversal in more than one pulmonary vein. In contrast, failure to identify a proximal flow convergence region or the presence of an A-wave dominant mitral filling pattern are specific for nonsevere MR. Proper integration of the many echocardiographic findings include appropriate discounting of measurements that may not be considered accurate for technical reasons. As noted earlier, it is critical to pay attention to the duration of MR as late systolic MR is rarely severe. The hemodynamic consequences of MR are reflected in several parameters including LA and LV volumes, the contour of the CWD profile, and pulmonary venous flow pattern. Finally, clinical presentation and hemodynamic state should also be considered in making a final judgment of MR severity.

2. Considerations in Secondary MR. Secondary MR can be much more challenging to grade than primary MR. The challenge arises from several situations as alluded to earlier in Section II, General Considerations: the total LV forward SV may be reduced and thus RVol is usually lower than in primary MR (below 60 mL for severe MR if total SV is reduced). Although RF would account for comparative lower flows, its derivation has higher errors because of the small numbers involved.^{46,162} The regurgitant orifice is frequently semilunar or elliptical, affecting measurements of VCW and possibly leading to underestimating EROA by the 2D PISA method. EROA may also vary with LV size and LVEF.¹⁶³ Thus while EROA ≥ 0.4 cm² still denotes severe MR, a lower cutoff of EROA ≥ 0.3 cm² may still be likely severe MR by 2D PISA due to the above considerations. Adding to the challenges of secondary MR, adjunctive findings are less helpful because they are often rendered abnormal by the underlying cardiomyopathy. For example, most patients with cardiomyopathy have systolic blunting of the pulmonary venous flow pattern due to elevated LA pressure. Because of a combination of elevated LA pressure, a dilated and compliant LA, and depressed LV systolic function, systolic flow reversal is not commonly seen, even though it remains specific for severe secondary MR when present. Another confounding problem is that secondary MR is notoriously dynamic (Figure 15). It is important to consider volume status, blood pressure, and other clinical variables, as in primary MR.

Several studies have shown that EROA ≥ 0.2 cm² portends a worse prognosis in secondary MR.^{136,137,164} Considerable controversy has arisen regarding whether EROA ≥ 0.2 cm² by 2D PISA should redefine severe secondary MR based on prognosis alone.^{163,165,166} In fact, this criterion has been incorporated in the last ACC/AHA guidelines.¹ This issue and how to address secondary MR was deliberated on and discussed extensively among the writing committee members. The rationale for the current recommendations regarding EROA is as follows. If association with adverse prognosis warrants labeling a lesion as severe, then any degree of secondary MR should be considered clinically significant, since there is evidence that even mild MR is associated with adverse prognosis.^{167,168} It is not clear whether the prognostic value of EROA ≥ 0.2 cm² is primarily due to the MR itself or to the underlying LV dysfunction or degree of myocardial scarring and irreversible damage. Importantly, there is no evidence that surgical correction of secondary MR improves

Key Points

- When MR is detected, the evaluation starts with an assessment of the anatomy of the MV to determine the mechanism of the regurgitation, classified as primary or secondary (functional), especially when MR is more than mild (Table 5 and Figures 9 and 10). The mechanism should be specified and reported.
- No single Doppler and echocardiographic parameter is precise enough to quantify MR in individual patients. Integration of multiple parameters is required for a more accurate assessment of MR severity (Tables 7 and 8, and Figure 18). When multiple parameters are concordant, MR severity can be determined with high probability, especially for mild or severe MR.
- Assessing LV/LA volumes, indexed to body surface area, is important. Chronic severe MR almost always leads to dilated LV and LA, and thus normal chamber volumes are unusual with chronic severe MR. (Tables 6 and 8). In individuals with small body surface areas (inclusive of women), normalization of cardiac chambers to body surface area is important in accurately identifying enlarged chambers.
- In evaluating severity of MR by color Doppler, always evaluate the three components of the jet (flow convergence, VC, and jet area) and the direction of the MR jet. Beware of very eccentric jets hugging the atrial wall, as jet area will underestimate severity and cannot be used.
- Duration of MR is important. MR limited to late systole (MVP) or early systole (ventricular dyssynchrony) is usually not severe but may be misinterpreted as severe when based only on single-color frame measurements such as VC or PISA (Figures 3 and 11).
- Perform quantitative measurements of MR severity when qualitative and semiquantitative parameters do not establish clearly the severity of the MR, provided that the quality of the data is good.
- Pay attention to systemic blood pressure and MR jet velocity. Color flow jets are proportional to A_v^2 . A high velocity (e.g., > 6 m/sec) MR jet can look large by color Doppler although EROA or RVol are small (Figure 14). This is often seen with hypertension, severe aortic stenosis, or significant LVOT obstruction.
- Acute severe MR due to flail MV or ruptured papillary muscle is more challenging to diagnose than chronic severe MR, particularly with color Doppler (very eccentric MR, short duration, tachycardia, low MR velocity). A high index of suspicion should be maintained if conventional echo/Doppler parameters point to significant MR, with a low threshold for performance of TEE.
- Additional testing with TEE or CMR is indicated when the TTE examination is suboptimal in patients with suspected MR, the mechanism for significant MR is not elucidated, the echo/Doppler parameters are discordant or inconclusive regarding the severity of MR, or in the presence of a discrepancy between TTE findings and the clinical setting.

outcomes,¹ and there is concern that calling lesser degrees of MR as severe might lead to unnecessary intervention. In fact, recent data have shown that MV repair of moderate ischemic MR (using an integrative approach, inclusive of EROA 0.2-0.39 cm²) did not improve outcome and was associated with an increased hazard of neurologic events and supraventricular arrhythmias.¹⁶⁹ Finally, in patients with severe MR treated with the MitraClip, reduction of MR severity was associated with favorable LV and LA remodeling and improved functional class, even when residual MR was moderate.¹⁴² Redefining such MR as severe based on EROA is problematic, unless improvement in remodeling and outcome can be shown for catheter-based interventions on traditional moderate MR. Further research is needed to refine severity criteria in secondary MR using 2D and 3D echocardiography, address the role of CMR, and assess whether LV and LA reverse remodeling occurs, along with improved clinical outcome when intervening on patients with various cutoff values of regurgitation severity. This will likely be facilitated by the advent of catheter-based techniques of MV repair and replacement.

IV. AORTIC REGURGITATION

A. Anatomy of the Aortic Valve and Etiology of Aortic Regurgitation

The aortic valve is composed of three semilunar cusps attached to the aortic wall and forming in part, the sinuses of Valsalva. The highest point of attachment at the leaflet commissures defines the sinotubular

Table 9 Etiology and mechanisms of AR

| Mechanism | Specific etiology |
|--|--|
| Congenital/leaflet abnormalities | Bicuspid, unicuspid, or quadricuspid aortic valve Ventricular septal defect |
| Acquired leaflet abnormalities | Senile calcification Infective endocarditis Rheumatic disease Radiation-induced valvulopathy Toxin-induced valvulopathy: anorectic drugs, 5-hydroxytryptamine (carcinoid) |
| Congenital/genetic aortic root abnormalities | Annuloaortic ectasia Connective tissue disease: Loeys Deitz, Ehlers-Danlos, Marfan syndrome, osteogenesis imperfecta |
| Acquired aortic root abnormalities | Idiopathic aortic root dilatation Systemic hypertension Autoimmune disease: systemic lupus erythematosus, ankylosing spondylitis, Reiter's syndrome Aortitis: syphilitic, Takayasu's arteritis Aortic dissection Trauma |

Aortic Regurgitation

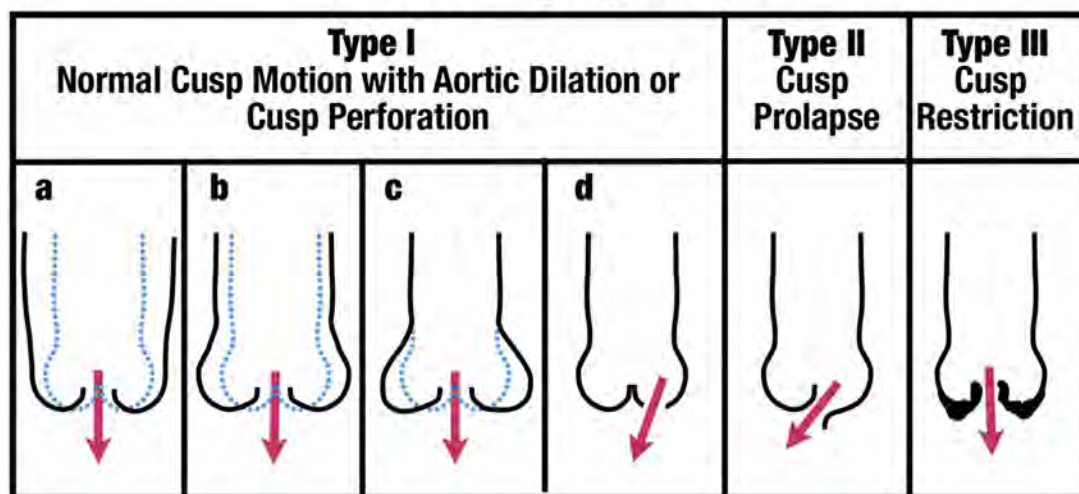


Figure 19 Suggested classification of AR morphology,¹⁸¹ depicting the various mechanisms of AR. Type Ia depicts sinotubular junction enlargement and dilatation of the ascending aorta. Type Ib depicts dilatation of the sinuses of Valsalva and sinotubular junction. Type Ic depicts dilatation of the ventriculoarterial junction (annulus). Type Id denotes aortic cusp perforation.

junction, and the most ventricular point (i.e., the nadir of the cusps) defines the annular plane.¹⁷⁰ The coaptation zone of the leaflets (lunulae) are more uniform in thickness except for a slightly more fibrous region at the anatomic midpoint of each cusp or nodules of Arantius.^{171,172} Given the anatomy of the aortic valve, AR results from disease of either the aortic leaflets and/or the aortic root (Table 9) that results in valve malcoaptation.¹⁷³

In congenital bicuspid aortic valve, all combinations of conjoined cusps can be identified by TTE; visualization of the raphe is key to classification of bicuspid valve types.^{174,175} Because of the increased stress on the typically larger conjoined cusp, these valves may become stenotic, regurgitant, or both. In addition, AR may be seen secondary to the associated dilatation of the aorta.¹⁷⁶⁻¹⁷⁸ TTE has up to a 92% sensitivity and 96% specificity for detecting bicuspid valve anatomy.¹⁷⁹

B. Classification and Mechanisms of AR

Identifying the mechanism responsible for AR is essential in determining the reparability of the aortic valve. Several functional classifications can be used. Adaptation of the Carpentier classification originally designed for the MV⁹⁴ have been described for AR¹⁸⁰ and can be helpful to understand the mechanism of AR, guide valve repair technique, and predict recurrence of AR (Figure 19).¹⁸¹ This scheme classifies dysfunction based on the aortic root and leaflet morphology. Type I is associated with normal leaflet motion and can be subcategorized based on the exact pathology of either the aortic root or valve. Type Ia occurs in the setting of sinotubular junction enlargement and dilatation of the ascending aorta, type Ib is a result of dilatation of the sinuses of Valsalva and the sinotubular junction, type Ic is the result of dilatation of the ventriculoarterial junction (i.e., the annulus), and type Id results from cusp perforation or

fenestration without a primary functional aortic annular lesion. Type II is associated with excessive leaflet motion from leaflet prolapse as a result of either excessive leaflet tissue or commissural disruption. Type III is associated with restricted leaflet motion seen with congenitally abnormal valves, degenerative calcification, or any other cause of thickening/fibrosis or calcification of the valve leaflets.

C. Assessment of AR Severity

1. Echocardiographic Imaging. Echocardiography plays an important role in the overall assessment of AR and in the timing of surgical intervention.¹ While “physiologic” or mild degrees of tricuspid and PR are commonly noted in normal exams, AR is not. When AR is detected, the evaluation starts with an assessment of the anatomy of the aortic valve and root to determine the etiology of the regurgitation followed by an assessment of LV size, geometry, and function. Similar to MR, the hemodynamics and cardiac adaptation to acute versus chronic AR are quite different. In severe acute AR, the LV is not dilated and the sudden rise in LV end-diastolic pressure may cause the MV to close prematurely, best documented with an M-mode. In chronic AR, echocardiography is essential in tracking the changes in LV geometry (progressive increase in LV volume) and function (progressive worsening) due to the protracted LV volume overload. LV dilatation, particularly with preserved LV function, is a supportive sign of significant AR and becomes more specific with exclusion of other causes of LV volume overload (e.g., athlete, anemia). Stress echocardiography can be utilized in both asymptomatic and symptomatic patients to assess functional capacity, the presence of coronary disease, and response of LV size and function to exercise.

2. Doppler Methods. Doppler echocardiography is essential in the evaluation of AR severity. The underlying principles for color flow Doppler, pulsed, and CWD in the assessment of valve regurgitation have been discussed earlier under Section II, General Considerations. The various methods in assessing AR, their advantages and limitations are detailed in Table 10. Table 11 summarizes the parameters involved in grading the severity of AR.

a. Color flow Doppler. AR in most patients is easily seen with color flow Doppler as a mosaic blend of colors originating from the aortic valve during diastole. Although the apical approach is the most sensitive for detection, the parasternal long and short axis are essential in evaluating the origin of the jet and its semiquantitative characteristics. It is important to visualize the three components of the color jet (flow convergence, VC, and jet area) for a better assessment of the origin and direction of the jet and its overall severity (Figure 20). Because the length of the AR jet into the LV chamber is so dependent on the driving pressure (diastolic blood pressure), it is not a reliable parameter of AR severity. Lastly, AR usually lasts throughout diastole except in acute AR, where it may be brief and of lower velocity, making detection and assessment with color Doppler more difficult.

Jet width in LVOT: the width of the AR jet compared with the LVOT diameter in centrally directed jets can be used to assess the severity of regurgitation semiquantitatively. This ratio is obtained in the parasternal long-axis view, just apical to the aortic valve. A ratio <25% generally indicates mild, 25%-64% indicates moderate, and ≥65% indicates severe AR. Similarly, a ratio of the area of the jet in cross section (short-axis view) to LVOT area is a measure of AR severity (Tables 10 and 11). However, both the width and area

ratios are not valid in eccentric jets, directed towards the septum or anterior MV, or in multiple jets.

Vena contracta: the VC is best visualized and measured in a zoomed, parasternal long-axis view. Since it is the narrowest area of the jet, it is smaller than the jet width in the LVOT. It can be measured in most patients with good echocardiographic images. A VC < 0.3 cm indicates mild, 0.3-0.6 cm indicates moderate, and > 0.6 cm indicates severe AR. If optimized, VC can still be measured in most eccentric jets. The VCW is small, so errors in measurement of 2 mm or more can influence AR grading.



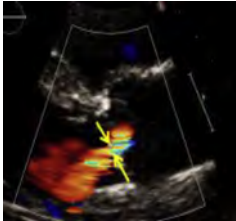
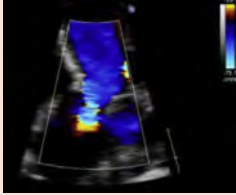
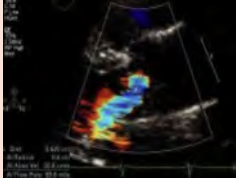
Flow convergence (PISA): flow convergence can be used qualitatively and quantitatively for evaluation of AR severity (Figure 21), similar to MR. Zooming on the LVOT in either the parasternal or apical long-axis views is the best approach to record the proximal flow convergence area, with a baseline shift of the Nyquist limit to measure the flow convergence radius. Measurement of the AR peak velocity and VTI by CWD allows calculation of the EROA and RVol (see earlier and Table 10). The threshold for severe AR is an EROA ≥ 0.30 cm² and an RVol greater than 60 mL (Table 11). Clinically, PISA quantitation of AR is used less often than in MR, as the flow convergence is in the far field and may be shadowed by aortic valve thickening and calcifications. Imaging from the right parasternal window may be helpful.¹⁸²

b. Pulsed wave Doppler. Aortic diastolic flow reversal: pulsed wave Doppler from the suprasternal window in the descending aorta often shows a brief early diastolic flow reversal in normals. Holodiastolic flow reversal is an abnormal finding (Figure 22) and indicates at least moderate AR; when present in the abdominal aorta, it is consistent with severe AR. However, in the absence of AR, holodiastolic retrograde aortic flow can also be seen in other conditions such as a left-to-right shunt across a patent ductus arteriosus, reduced compliance of the aorta in the elderly, an upper extremity arteriovenous fistula, a ruptured sinus of Valsalva, or when there is an aortic dissection with diastolic flow into the false lumen. Note that in acute severe AR or bradycardia, there may be equilibration of pressure between the aorta and ventricle before the end of diastole leading to flow reversal that is not holodiastolic. The ratio of the VTI of the reverse flow to the forward flow provides a rough assessment of RF. Variation in aortic size during the cardiac cycle limits this from being a truly quantitative measure.

Flow calculations: quantitation of flow with pulsed Doppler for the assessment of AR is based on comparison of measurements of aortic SV at the LVOT with mitral or pulmonic SV, provided there is no significant MR or PR. Grading of AR severity with RVol and RF is shown in Table 11. EROA can also be calculated by dividing the RVol by the VTI from AR CWD jet recording. Total LV SV (equal to SV at LVOT in isolated AR) can also be obtained from the difference between LV diastolic and systolic volumes. The use of 3D echocardiography and contrast enhances the accuracy of this measurement and decreases the underestimation of total LV SV by echocardiography. As noted in the general section, meticulous attention to accuracy is needed throughout this process, and even then, the confidence intervals may remain wide.

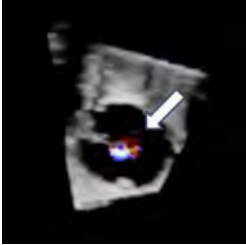
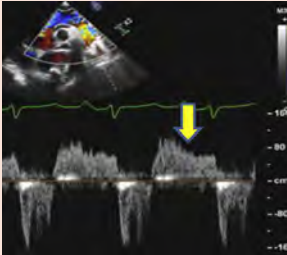
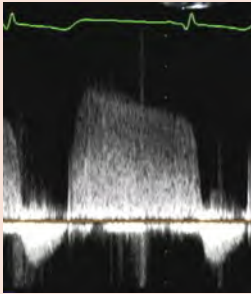
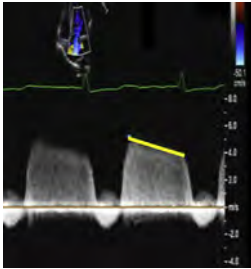
c. Continuous wave Doppler. The best window for the evaluation of AR with CWD is the apical window. However, in very eccentric jets, identified by color Doppler, a parasternal window may give a better ultrasound alignment and recording of the jet.

Table 10 Doppler echocardiography in evaluating severity of AR

| Modality | Optimization | Example | Advantages | Pitfalls |
|------------------------------|---|--|--|--|
| Color flow Doppler 2D | | | | |
| Jet width/ LVOT diameter | <ul style="list-style-type: none"> • Long-axis view • Zoomed view • Imaging plane for optimal VC measurement may be different from PISA • Measure in LVOT within 1 cm of the VC |  | <ul style="list-style-type: none"> • Simple sensitive screen for AR • Rapid qualitative assessment | <ul style="list-style-type: none"> • Underestimates AR in eccentric jets • May overestimate AR in central jets as AR jet may expand unpredictably below the orifice • Is affected by the size of the LVOT |
| Jet area/LVOT area | <ul style="list-style-type: none"> • Short-axis view • Zoom view • Measure within 1 cm of the VC |  | <ul style="list-style-type: none"> • Estimate of regurgitant orifice area | <ul style="list-style-type: none"> • Direction and shape of jet may overestimate or underestimate jet area |
| VC | <ul style="list-style-type: none"> • Parasternal long-axis view • Zoomed view • Imaging plane for optimal VC measurement may be different from that for PISA • Narrowest area of jet at or just apical to the valve |  | <ul style="list-style-type: none"> • Surrogate for regurgitant orifice size • May be used in eccentric jets • Independent of flow rate and driving pressure • Less dependent on technical factors • Good at identifying mild or severe AR | <ul style="list-style-type: none"> • Problematic in the presence of multiple jets or bicuspid valves • Convergence zone needs to be visualized • The direction of the jet (in relation to the insonation beam) will influence the appearance of the jet |
| Proximal flow convergence | <ul style="list-style-type: none"> • Align direction of flow with insonation beam to avoid distortion of hemisphere from noncoaxial imaging • Zoomed view • Change baseline of Nyquist limit in the direction of the jet • Adjust lower Nyquist limit to obtain the most hemispheric flow convergence | <p>Apical view</p>  <p>Parasternal view</p>  | <ul style="list-style-type: none"> • Rapid qualitative assessment | <ul style="list-style-type: none"> • Multiple jets • Constrained jet (aortic wall) • Nonhemispheric shape • Timing in early diastole |

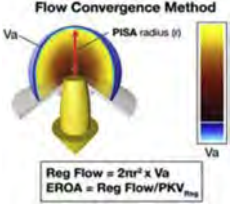
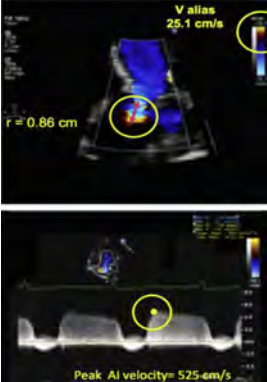



(Continued)

Table 10 (Continued)

| Modality | Optimization | Example | Advantages | Pitfalls |
|--|--|---|---|--|
| Color flow Doppler 3D: 3D VC | <ul style="list-style-type: none"> Color flow sector should be narrow Align orthogonal cropping planes along the axis of the jet Choose a middiastolic cycle Noncoaxial jets or aliased flow may appear “laminar” but still represent regurgitant flow |  | <ul style="list-style-type: none"> Multiple jets of differing directions may be measured | <ul style="list-style-type: none"> Dynamic jets may be over- or underestimated |
| Pulsed wave Doppler: Flow reversal in proximal descending aorta | <ul style="list-style-type: none"> Align insonation beam with the flow in the proximal descending or abdominal aorta |  | <ul style="list-style-type: none"> Simple supportive sign of severe AR More specific sign if seen in abdominal aorta Can be obtained with both TTE and TEE | <ul style="list-style-type: none"> Depends on compliance of the aorta; less reliable in older patients Brief velocity reversal is normal Can be present in arteriovenous fistula in upper extremity, ruptured sinus of Valsalva May not be holodiastolic in acute AR |
| CWD | | | | |
| Density of regurgitant jet | <ul style="list-style-type: none"> Align insonation beam with the flow Adjust overall gain |  | <ul style="list-style-type: none"> Simple Density is proportional to the number of red blood cells reflecting the signal Faint or incomplete jet is compatible with mild or trace AR | <ul style="list-style-type: none"> Qualitative Perfectly central jets may appear denser than eccentric jets of higher severity Overlap between moderate and severe AR |
| Jet deceleration rate (pressure half-time) | <ul style="list-style-type: none"> Align insonation beam with the flow Usually best from apical windows In eccentric jets, may be best from parasternal window, helped by color Doppler |  | <ul style="list-style-type: none"> Simple Specific sign of pressure relation between aorta and LV If long, excludes severe AR | <ul style="list-style-type: none"> Qualitative Poor alignment of Doppler beam may result in lower pressure half-time Affected by changes that modify LV-aorta pressure gradient (if short, implies significant AR or high LV filling pressure) |

(Continued)

Table 10 (Continued)

| Modality | Optimization | Example | Advantages | Pitfalls |
|---|--|---|---|--|
| Quantitative Doppler: EROA, regurgitation volume and fraction | | | | |
| <p>Flow Convergence Method</p>  <p>Reg Flow = $2\pi r^2 \times Va$ EROA = Reg Flow / PKV_{max}</p> | <ul style="list-style-type: none"> Align insonation beam with the flow Lower the color Doppler baseline in the direction of the jet Look for the hemispheric shape to guide the best lower Nyquist limit CWD of regurgitant jet for peak velocity and VTI |  | <ul style="list-style-type: none"> Rapid quantitative assessment of lesion severity (EROA) and volume overload (RVol) | <ul style="list-style-type: none"> Feasibility is limited by aortic valve calcifications Not valid for multiple jets, less accurate in eccentric jets Limited experience Small errors in radius measurement can lead to substantial errors in EROA due to squaring of error. |
| <p>SV method</p>  <p>RVol = SV_{LVOT} – SV_{MV}</p> | <ul style="list-style-type: none"> LVOT diameter measured at the annulus in systole and pulsed Doppler from apical views at same site Mitral annulus measured at mid-diastole; pulsed Doppler at the annulus level in diastole Total LV SV can also be measured by the difference between LV end-diastolic volume and end-systolic volume. LV volumes are best measured by 3D. Contrast may be needed to better trace endocardial borders. If 3D not feasible, use 2D method of disks. |   | <ul style="list-style-type: none"> Quantitative, valid with multiple jets and eccentric jets. Provides both lesion severity (EROA, RF) and volume overload (RVol) Verify results using LV end-diastolic volume and LV end-systolic volume | <ul style="list-style-type: none"> Difficulties measuring mitral annulus diameter, particularly with annular calcification Not valid for combined MR and AR, unless pulmonic site is used |

Signal density: the density of the CWD signal reflects the volume of regurgitation, particularly when compared to the density of the forward flow. A faint or incomplete jet indicates mild or trace regurgitation, while a dense jet may be compatible with more significant regurgitation but cannot differentiate between moderate and severe AR.

Pressure half-time: the pressure half-time of the AR spectral Doppler slope can be a parameter of severity. The CW signal has to be adequate with a clear visualization of the decrease in diastolic AR velocity for this measurement to be performed. A steep slope indicates a more rapid equalization of pressures between the aorta and

LV during diastole (Figure 22). A pressure half-time >500 msec suggests mild AR, and <200 msec suggests severe AR. However, since this parameter is affected by compliance of the LV, patients with severe chronic regurgitation with well compensated ventricular function may have a pressure half-time in the “moderate” range. In contrast, mild AR in patients with severe diastolic dysfunction may have short pressure half-time. The pressure half-time reflects reduction in the transvalvular gradient, which can also be accomplished by vasodilator therapy (reduces diastolic blood pressure independent of the AR). Thus, this method is less useful for monitoring AR in patients being treated medically.^{183,184}

Table 11 Grading the severity of chronic AR with echocardiography

| | AR severity | | |
|--|--|------------------------|--|
| | Mild | Moderate | Severe |
| Structural parameters | | | |
| Aortic leaflets | Normal or abnormal | Normal or abnormal | Abnormal/flail, or wide coaptation defect |
| LV size | Normal* | Normal or dilated | Usually dilated [†] |
| Qualitative Doppler | | | |
| Jet width in LVOT, color flow | Small in central jets | Intermediate | Large in central jets; variable in eccentric jets |
| Flow convergence, color flow | None or very small | Intermediate | Large |
| Jet density, CW | Incomplete or faint | Dense | Dense |
| Jet deceleration rate, CW (PHT, msec) [‡] | Incomplete or faint Slow, >500 | Medium, 500-200 | Steep, <200 |
| Diastolic flow reversal in descending aorta, PW | Brief, early diastolic reversal | Intermediate | Prominent holodiastolic reversal |
| Semiquantitative parameters[§] | | | |
| VCW (cm) | <0.3 | 0.3-0.6 | >0.6 |
| Jet width/LVOT width, central jets (%) | <25 | 25-45 46-64 | ≥65 |
| Jet CSA/LVOT CSA, central jets (%) | <5 | 5-20 21-59 | ≥60 |
| Quantitative parameters[§] | | | |
| RVol (mL/beat) | <30 | 30-44 45-59 | ≥60 |
| RF (%) | <30 | 30-39 40-49 | ≥50 |
| EROA (cm ²) | <0.10 | 0.10-0.19 0.20-0.29 | ≥0.30 |

PHT, Pressure half-time; PW, pulsed wave Doppler.

Bolded qualitative and semiquantitative signs are considered specific for their AR grade. Color Doppler usually performed at a Nyquist limit of 50-70 cm/sec.

*Unless there are other reasons for LV dilation.

[†]Specific in normal LV function, in absence of causes of volume overload. Exception: acute AR, in which chambers have not had time to dilate.

[‡]PHT is shortened with increasing LV diastolic pressure and may be lengthened in chronic adaptation to severe AR.

[§]Quantitative parameters can subclassify the moderate regurgitation group.

D. Role of TEE

TTE is an essential first diagnostic test⁸⁴ and is frequently sufficient to evaluate the presence and severity of AR. TEE is usually reserved for more detailed assessment, if needed, of the morphology of the valve and aorta, mechanism of AR, and measurements of color flow parameters. Both 2D and 3D TEE have proven utility, improving diagnostic accuracy of TTE in a number of disease processes causing AR: infectious or inflammatory endocarditis,^{185,186} isolated aortic root dilatation,¹⁸⁷ or acute aortic dissection.^{188,189} The diagnostic value of 2D and 3D TEE in defining the mechanisms of AR is particularly important for presurgical evaluation of patients undergoing aortic root surgery,¹⁹⁰ valve-sparing aortic surgery,¹⁹¹ or valve repair.¹⁹²⁻¹⁹⁴ Understanding leaflet as well as aortic root morphology will likely be more important in the planning of transcatheter repair or replacement devices.^{195,196}

E. Role of CMR in the Assessment of AR

There are four main roles for CMR in the assessment of AR: identification of the mechanism of AR, quantification of its severity, evaluation of LV remodeling, and potential associated aortopathy:

1. Mechanism. Anatomic assessment of the aortic valve and aortic root is typically performed with the use of cine SSFP sequences

(Figure 23). An imaging plane is prescribed to produce a standard three-chamber long-axis view and additionally an LVOT coronal view.⁶⁹ These views are then used to prescribe a parallel series of at least 3 thin (4-5 mm) slices in short axis and provide a comprehensive assessment of aortic valve and aortic root anatomy and can aid in identifying congenital leaflet anomalies (i.e., bicuspid), acquired leaflet abnormalities (i.e., vegetations), or aortic root or ascending aortic abnormalities (Figure 23).

There are limitations of cine CMR that need to be mentioned. Specifically, while the in-plane resolution is high (typically 1.5 mm), the slice thickness is 4-5 mm, which can lead to some partial volume effects. Additionally, since cine CMR images are acquired over multiple cardiac cycles, there may be difficulty in visualizing highly mobile objects such as small mobile vegetations. Nonetheless, CMR can still provide useful insights into the mechanism of AR in most cases.

2. Quantifying AR with CMR. There are several methods for quantifying AR by CMR, broadly categorized as direct and indirect methods (see Section II, General Considerations). The direct method involves performing phase-contrast velocity mapping in a plane perpendicular to the aorta; most operators recommend positioning in the aortic root (just above the aortic valve)¹⁹⁷⁻¹⁹⁹ (Figures 7 and 24). Forward and reverse flow is derived by integrating the velocity of each pixel and its

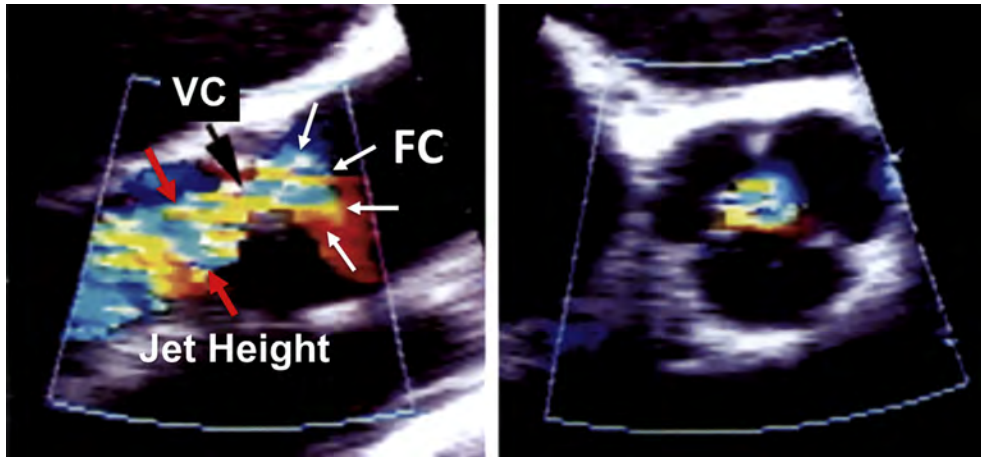
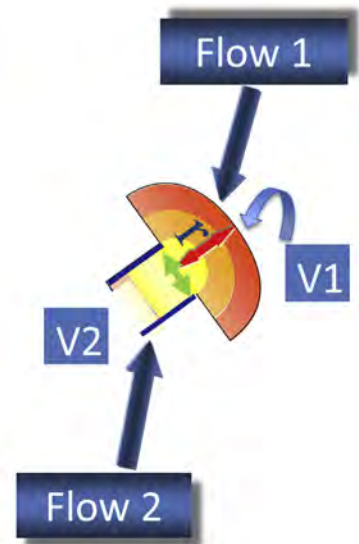
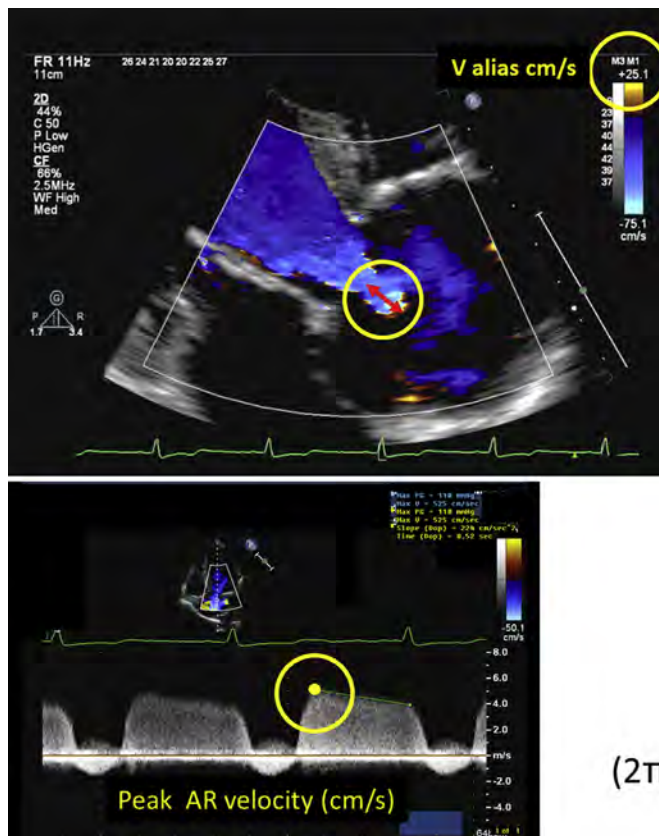


Figure 20 Color flow Doppler of AR in the parasternal long- and short-axis views. The three components of the jet are shown with arrows: flow convergence (FC), VC, and jet height (or width) in the LV outflow.



$$Q_{prox} = Q_{distal}$$

$$A_1 V_1 = A_2 V_2$$

$$(2\pi r^2) \times V_a = EROA \times PkV_{AR}$$

Figure 21 Flow convergence or PISA can be performed for obtaining the EROA in patients with AR. Zooming in on the LVOT in either the parasternal or apical long-axis views is the best way to record the proximal flow convergence area. Adjust the Nyquist limit using the baseline shift control to obtain and measure the flow convergence radius (red arrow). Regurgitant flow rate is calculated as $2\pi \times r^2 \times V_{Alias}$ (r = the radius of the flow convergence in early diastole [red arrow], and V_{Alias} is the V_a in cm/sec). EROA and RVol can then be calculated as EROA = regurgitant flow rate/peak AR velocity in early diastole in cm/sec. RVol = EROA \times VTI of the AR. For the aortic valve, severe regurgitation is an EROA greater than 0.30 cm² and an RVol greater than 60 mL.

area over the cardiac cycle.^{6,200} This information can then be used to calculate RF (reverse volume/forward volume * 100%). In most instances this direct method is the preferred technique for assessment of AR as it is the most validated and is not affected by coexisting valvular regurgitant lesions.^{80,160,201-203}

Occasionally in the setting of arrhythmias or atrial fibrillation, the data obtained from the direct method may be compromised (specifically the diastolic reverse flow assessment). In these instances, multiple indirect methods can be employed to determine AR severity. In the absence of significant PR, aortic RVol can be

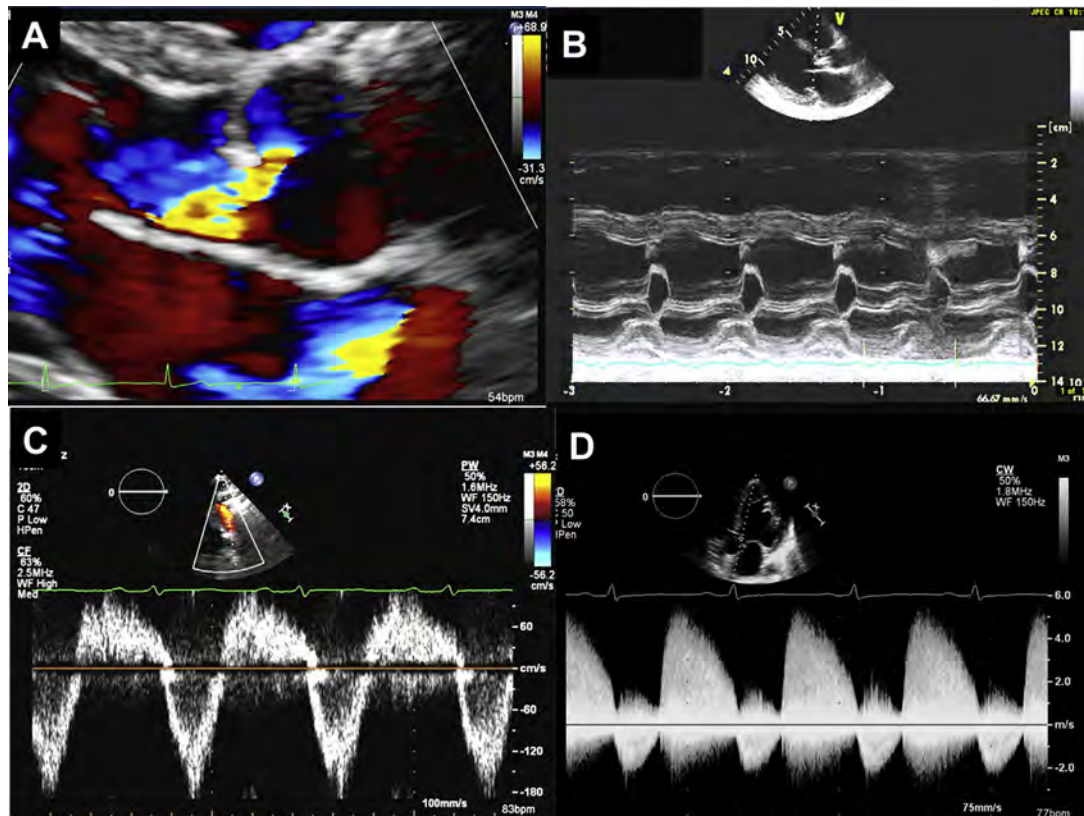


Figure 22 (A) Still frame of a patient with moderate eccentric AR due to aortic valve prolapse. Note the area of flow convergence and VC. (B) Early closure of the MV (before the R wave of the electrocardiogram) in a patient with acute AR due to bacterial endocarditis. (C) Pulsed Doppler in the descending aorta in a patient with severe AR depicting holodiastolic aortic flow reversal. (D) CW Doppler of a patient with severe and acute AR. Note the steep deceleration slope and similar density of the antegrade and retrograde flows.

derived by subtracting the pulmonic forward flow from the aortic forward flow.²⁰⁴ Another indirect method involves comparing the RV and LV SVs obtained by planimetry²⁰⁵⁻²⁰⁷; however, it will not be reliable if there is significant coexisting mitral or right-sided regurgitant lesions.

In addition to volumetric quantification, a number of features have been evaluated as corroborating signs of severe AR. The ARO can be determined by obtaining an “en face” view of the aortic valve using sequential SSFPs cines. The smallest diastolic regurgitant orifice in middiastole is traced. An ARO ≥ 0.48 cm² was found to have a sensitivity and specificity of 83% and 97%, respectively, in detecting severe AR.⁷⁶ In a separate study, the presence of holodiastolic flow reversal in the mid descending aorta predicted severe AR with high sensitivity (100%) and specificity (93%).²⁰⁸

3. LV Remodeling. LV remodeling could be a consequence of chronic severe AR and may be a specific marker of regurgitation severity. CMR provides the most accurate measurement of LV volumes. This is accomplished using the acquisition of short-axis SSFP cine images from the base to the apex of the ventricle followed by endocardial contouring with commercially available software. Recently a study focused on prognosis demonstrated that an LV volume of >246 mL (unindexed) predicted progression to symptoms or the need for aortic valve replacement over a mean follow-up of 2.6 years.⁸⁶

4. Aortopathy. The presence of aortopathy can be a cause of AR or associated with AR. It is reliably assessed using contrast and non-contrast magnetic resonance angiography techniques.

5. When Is CMR Indicated? While echocardiography remains the first line modality for assessment of AR, CMR is indicated in the following situations: (1) suboptimal echocardiographic images; (2) discordance between echocardiographic and Doppler findings (i.e., discordance between LV enlargement and Doppler measures of AR severity); or (3) discordance between clinical assessment and severity of AR by echocardiography²⁰⁹; (4) patients with moderate or severe AR and suboptimal echocardiography for assessment of LV volumes and systolic function and measurement of AR severity²⁰⁹; (5) patients with bicuspid aortic valves, when the morphology of aortic sinuses, sinotubular junction, or ascending aorta (to at least 4 cm above the valve plane) cannot be assessed accurately or fully by echocardiography.^{209,210} Lastly, the direct method for AR quantification described in this section is independent of other coexisting valvular lesions, and therefore CMR may be used in the setting of multiple valvular lesions when echocardiographic assessment may be challenged. This will be presented in more detail in the section on multivalvular disease.

CMR measurement of regurgitant severity of AR and accompanying LV remodeling is less variable than with echocardiography and may therefore be ideally suited for longitudinal follow up in individual patients.¹⁶⁰ Furthermore, patients with bicuspid aortic valves,

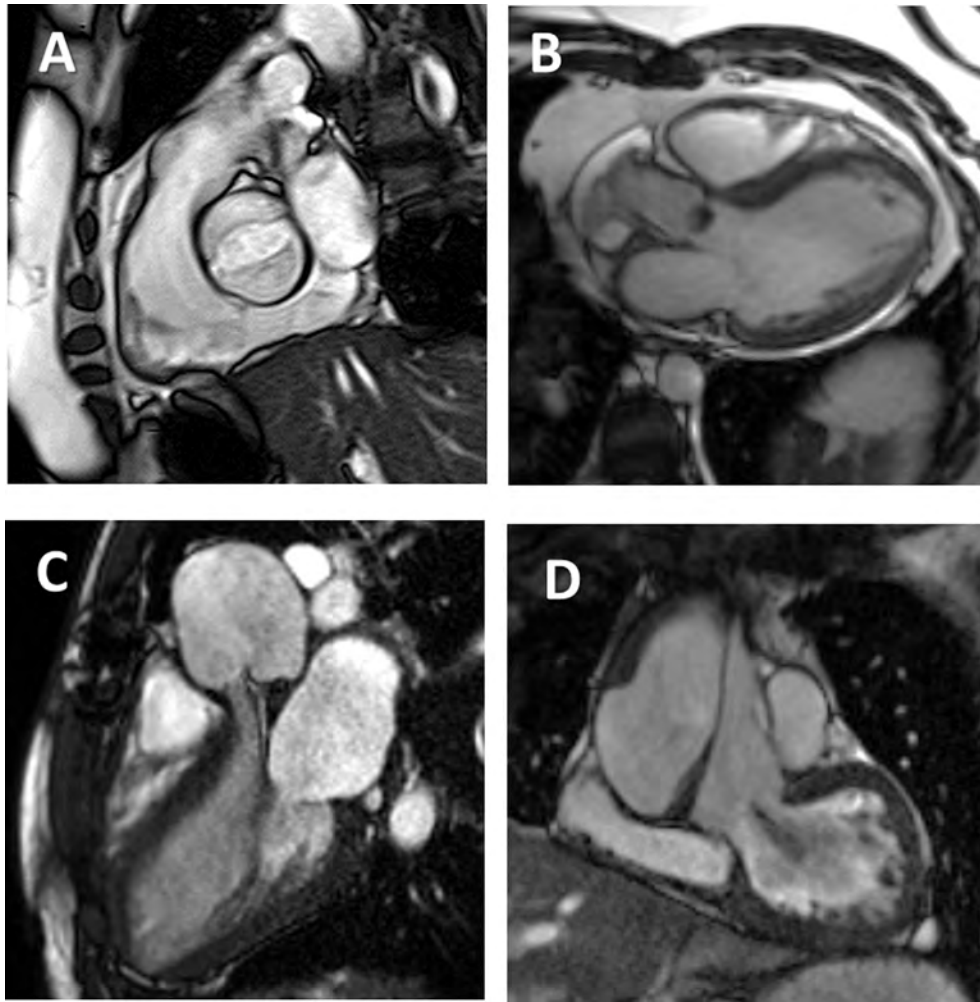


Figure 23 Examples of various etiologies of AR identified with CMR: bicuspid aortic valve (A), vegetation on the aortic valve (B), aortic root dilation (C), and type A aortic dissection (D).

concomitant AR, and ascending aortic dilatation may be best followed with CMR, depending on the severity of AR and size of the aorta.

F. Integrative Approach to Assessment of AR

The evaluation of AR by Doppler echocardiography should be a comprehensive and an integrative process based on all the information collected during the examination, since each of the parameters used in this evaluation has advantages and limitations (Tables 10 and 11). In all cases one should routinely perform an evaluation of the aortic valve and LV size and function and an assessment of the jet characteristics by color flow imaging. The LV outflow velocity and the velocity in the proximal descending aorta and/or abdominal aorta should be recorded by pulsed Doppler. CWD of the AR jet should also be routinely recorded but only utilized if a complete signal is obtained.

Based on data in the literature and a consensus of the committee members, the writing committee proposes a scheme for evaluation of patients with AR (Figure 25). In applying this scheme, it is the consensus of the committee members that the process of grading AR should be comprehensive using a combination of these signs,

clues, and measurements obtained by Doppler echocardiography. If the AR is definitely determined as mild or severe using these specific signs, no further measurement is required, particularly for mild lesions. If there are only few parameters consistent with mild or severe AR, and the quality of the primary data lends itself to quantitation, it is desirable for echocardiographers with experience in quantitative methods to measure quantitatively the degree of AR, including the RVol and fraction as descriptors of volume overload and the effective regurgitant orifice as a descriptor of the lesion severity. Similar to MR, quantitation of regurgitation can further subclassify regurgitation into four grades, with grade III having some overlap with characteristics of severe AR (Figure 25), hence the need for an integrative approach. Similar to MR, when the evidence from the different parameters is congruent, it is easy to grade AR severity. When different parameters are contradictory, one must look carefully for technical and physiologic reasons to explain these discrepancies and rely on the components that have the best quality of the primary data and that are the most accurate considering the underlying clinical condition. In situations where the assessment is difficult and indeterminate, provides contradicting echo/Doppler data that cannot be resolved, or conflicts with the clinical presentation, further testing is advised with either TEE or CMR.

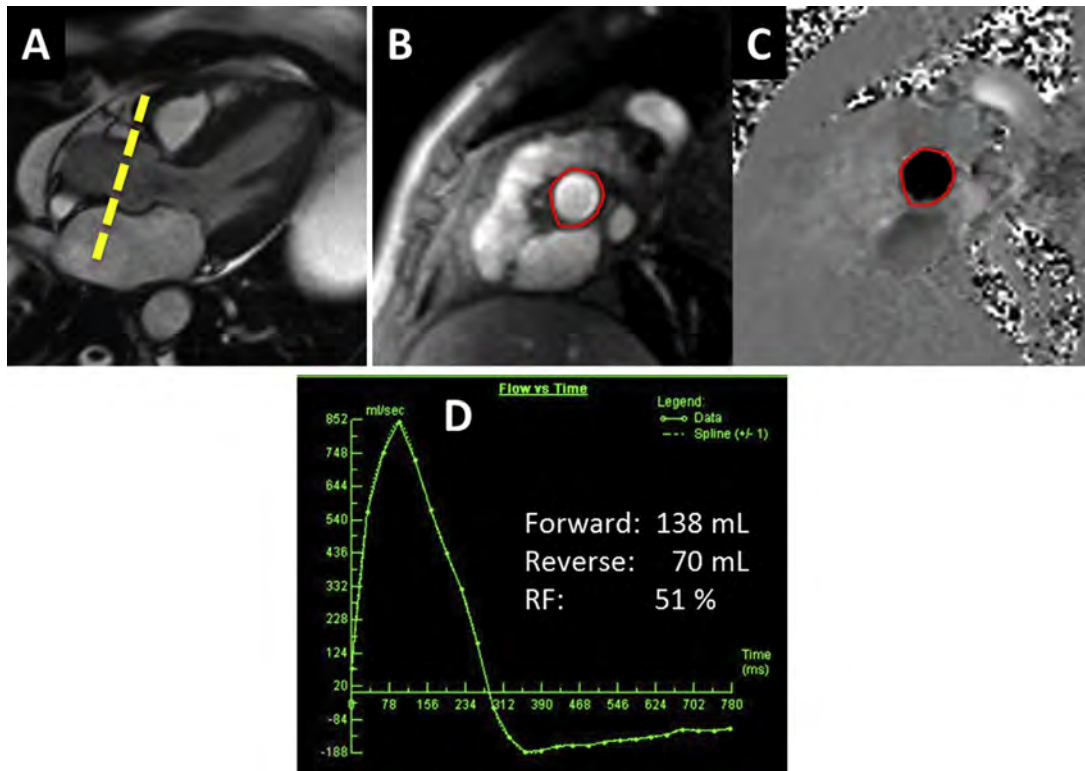


Figure 24 Phase-contrast CMR for assessment of aortic valve flow. (A) Phase-contrast CMR acquisition is prescribed in a plane perpendicular to the aortic root, just above the aortic valve (yellow dashed line). This produces two sets of images on which contours of the aortic wall are planimetered (red contours in panels B and C): magnitude images that provide anatomic location information (B) and phase image that encodes velocity in each pixel (C). A flow-time curve is generated (D) by integration of velocity and area data at each phase in the cardiac cycle. The reverse (regurgitant) volume is 70 mL, and the RF is 70 mL/138 mL or 51%.

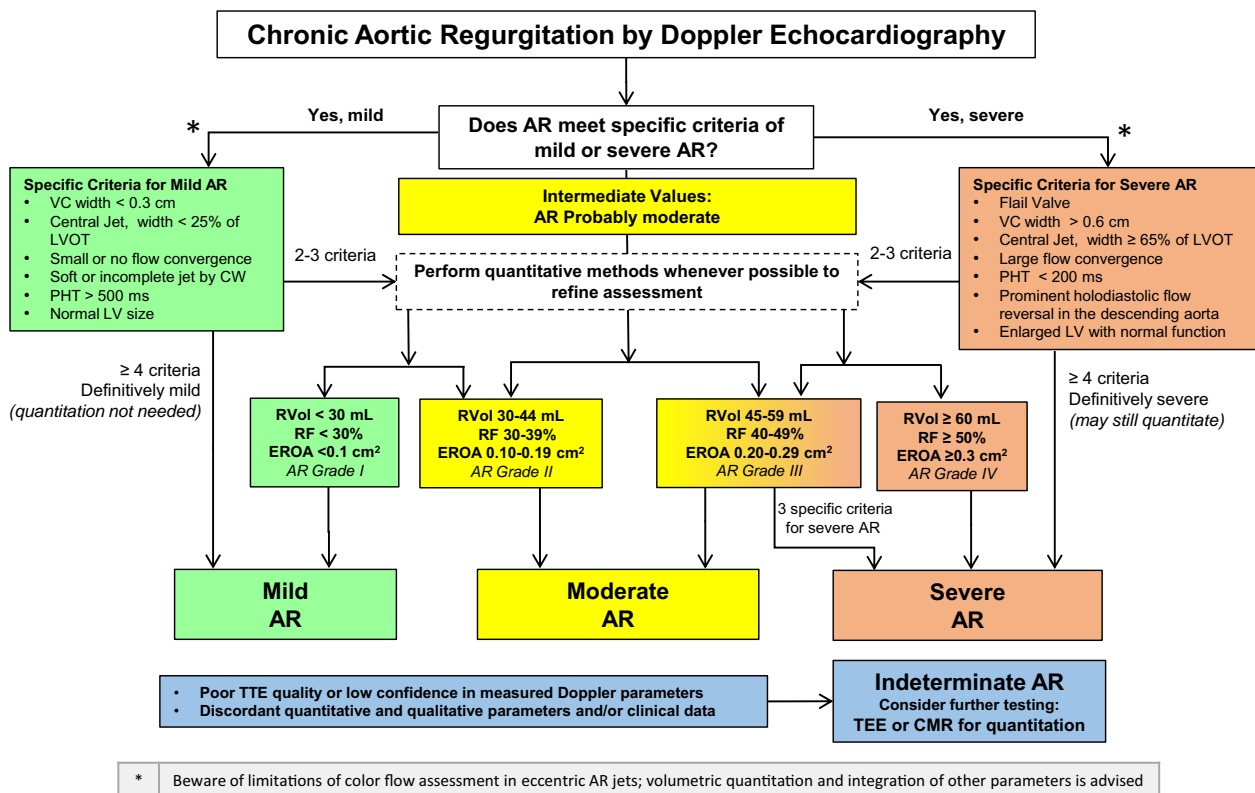


Figure 25 Algorithm for the integration of multiple parameters of AR severity. Good-quality echocardiographic imaging and complete data acquisition are assumed. If imaging is technically difficult, consider TEE or CMR. AR severity may be indeterminate due to poor image quality, technical issues with data, internal inconsistency among echo findings, or discordance with clinical findings. PHT, Pressure half-time.

Key Points

- When AR is detected, the evaluation starts with an assessment of the anatomy of the aortic valve and aortic root to determine the etiology and mechanism of the regurgitation, followed by an assessment of LV size, geometry, and function.
- No single measurement or Doppler parameter is precise enough to quantify AR in individual patients. Integration of multiple parameters is required (Tables 10 and 11 and Figures 20-22).
- The severity of AR can be graded using a combination of structural, qualitative Doppler, and semiquantitative parameters (Table 11 and Figure 25). When multiple parameters are concordant, AR severity can be determined with high probability, especially for mild or severe AR.
- It is important to assess LV size/volume, indexed to body surface area. Chronic severe AR almost always leads to dilated LV, and thus, normal chamber volumes are unusual with chronic severe AR (Table 11).
- In assessing AR by color Doppler, always evaluate the three components of the jet (flow convergence, VC, jet size in LV outflow) and jet direction. Beware of very eccentric AR directed at the septum or anterior MV, as AR severity parameters of jet size become less reliable.
- Perform quantitative measurements of AR severity when qualitative and semiquantitative parameters do not establish clearly the severity of AR, provided that the quality of the data is good.
- Acute severe AR may be more challenging to diagnose than chronic severe AR, particularly with color Doppler (short duration, tachycardia, low AR velocity, eccentric jet). A high index of suspicion should be maintained if conventional echo/Doppler parameters point to significant AR, with a low threshold for performance of TEE.
- Additional testing with TEE or CMR is indicated when TTE is suboptimal in patients with suspected AR, the mechanism for significant AR is not identified, the echo/Doppler parameters are discordant or inconclusive regarding the severity of AR, the aortic root and ascending aorta need better assessment, or a discrepancy is present between the TTE findings and the clinical setting.

V. TRICUSPID REGURGITATION

A small degree of TR is present in the majority of normal individuals. Hemodynamically significant TR may be responsible for significant morbidity and possibly mortality, independent of underlying conditions.^{9,211,212} TR may be difficult to detect on clinical examination because the murmur is often soft. It is important for the echocardiographer not only to recognize severe TR but also to try to elucidate its mechanism.

A. Anatomy of the Tricuspid Valve

The TV is the largest and most apically positioned valve and its functional anatomy, similar to the MV, can be divided into four components: the fibrous annulus, the three leaflets, the papillary muscles, and the chordal attachments.²¹³⁻²¹⁸ The tricuspid annulus is complex and dynamic, allowing it to change with varying loading conditions. Unlike the MV, there is no fibrous continuity with the corresponding semilunar valve. Three-dimensional echocardiography has been integral in our understanding of TV anatomy.²¹⁷ A normal annulus is triangular as well as saddle shaped (Figure 26).²¹⁹ When functional dilatation occurs, the annulus becomes more circular and planar,²²⁰ dilating in the septal to lateral direction.

B. Etiology and Pathology of Tricuspid Regurgitation

The most common cause of TR is secondary or functional regurgitation, due to annular dilatation from either right atrial or RV enlargement. Table 12 lists the common etiologies of TR. Annular dilatation, papillary muscle displacement, or a combination can cause significant TR.²²¹ This can occur in the setting of RV dysfunction, pulmonary hypertension, or left heart disease. In these conditions, the increased tethering forces result in leaflet malcoaptation and leaflet tethering and tenting.

The most common cause of primary TR is myxomatous degeneration.²²²⁻²²⁵ Although some degree of prolapse is common for the

nonplanar TV, actual “TV prolapse” is typically reserved for excessive billowing into the right atrium associated with redundancy of the tricuspid leaflets. This abnormality is seen in 20% of patients with concomitant MVP. Flail leaflets are not typically associated with myxomatous TV disease but rather with closed chest trauma²²⁶⁻²²⁸ or RV endomyocardial biopsy.²²⁹⁻²³¹ Pacemaker leads can result in significant TR by interfering with closure of the TV but rarely cause a flail leaflet or a perforation of the leaflet.²³²

C. Role of Imaging in Tricuspid Regurgitation

1. Evaluation of the Tricuspid Valve. a. Echocardiographic imaging. A comprehensive TTE examination of the TV requires a methodical approach to identify the pathology associated with TR.²³³ With 2D echocardiography, the three leaflets cannot be visualized simultaneously, and there is a great deal of variability as to which leaflets are visualized in a given view. The parasternal RV inflow view will always image the anterior leaflet in the near field, but in the far field, the leaflet may be the septal or the posterior leaflet.²³⁴ On short axis, the leaflet adjacent to the aorta is either the septal or anterior leaflet, and the leaflet adjacent to the RV free wall is usually the posterior leaflet.²¹⁷ In the apical four-chamber view, there is more certainty, with the anterior leaflet on the free wall and the septal leaflet adjacent to the septum. Significant annular dilatation is defined by an end-diastolic diameter ≥ 40 mm or >21 mm/m² in the four-chamber transthoracic view and is the main imaging criterion used to indicate severe TR in the current the ACC/AHA guidelines.¹ Compared with TTE, TEE is in general more limited in permitting optimal views due to off-angle imaging planes and the greater distance of the probe from the TV. Three-dimensional echocardiography provides unique en face views of the TV that enable simultaneous visualization of all three leaflets and the entire annulus (Figure 26).³ The addition of color flow Doppler to a full volume acquisition not only provides the ability to analyze the mechanism and locate the TR jet but also to quantify the size of the effective regurgitant orifice size by using cropping planes to display and measure the VCA.

b. CMR imaging. The normal TV with a thickness of <1 mm²³⁵ is difficult to visualize clearly with routine CMR cine SSFP imaging (Figure 27). The strengths of CMR in defining tricuspid anatomy include its ability to display the valve in any imaging plane. When the valve is thickened in pathological situations, the valve and TR are more readily visualized by CMR. In a study comparing echocardiography with CMR in patients with Ebstein’s anomaly, the posterior leaflets and TV fenestrations were better visualized by CMR.²³⁶ A limitation of CMR that can compromise visualization of TV leaflets is that flow cannot be separated from 2D structural imaging unlike color Doppler in echocardiography. In case of turbulent flow, the turbulence creates flow disturbance, which is of low signal intensity and can obscure the valve and make it difficult to visualize (Figure 28).

2. Evaluating Right Heart Chambers. The RV is usually dilated in the presence of hemodynamically significant TR. The position of the septum produces a D-shaped LV predominantly in diastole (RV volume overload pattern). When TR is due to pulmonary hypertension, septal flattening is present throughout the cardiac cycle, reflecting the diastolic and systolic overload of the RV (RV pressure overload pattern).

Tricuspid Valve

Ventricular perspective

Atrial perspective

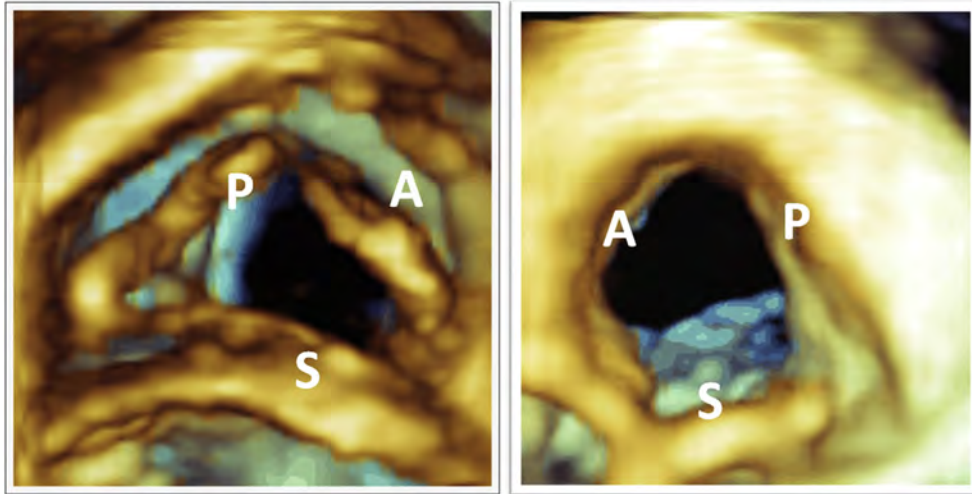


Figure 26 Three-dimensional echocardiography provides the only echocardiographic approach to visualize the three leaflets of the TV simultaneously. A, Anterior leaflet; P, posterior; S, septal.

Table 12 Etiology of TR

| Morphologic classification | Disease subgroup | Specific abnormality |
|-----------------------------|----------------------------|--|
| Primary leaflet abnormality | Acquired disease | Degenerative, myxomatous Rheumatic Endocarditis Carcinoid Endomyocardial fibrosis Toxins Trauma Iatrogenic (pacing leads, RV biopsy) Other (e.g., ischemic papillary muscle rupture) |
| | Congenital | Ebstein's anomaly TV dysplasia TV tethering associated with perimembranous ventricular septal defect and ventricular septal aneurysm Repaired tetralogy of Fallot Congenitally corrected transposition of the great arteries Other (giant right atrium) |
| Secondary (functional) | Left heart disease | LV dysfunction or valve disease |
| | RV dysfunction | RV ischemia RV volume overload RV cardiomyopathy |
| | Pulmonary hypertension | Chronic lung disease Pulmonary thromboembolism Left-to-right shunt |
| | Right atrial abnormalities | Atrial fibrillation |

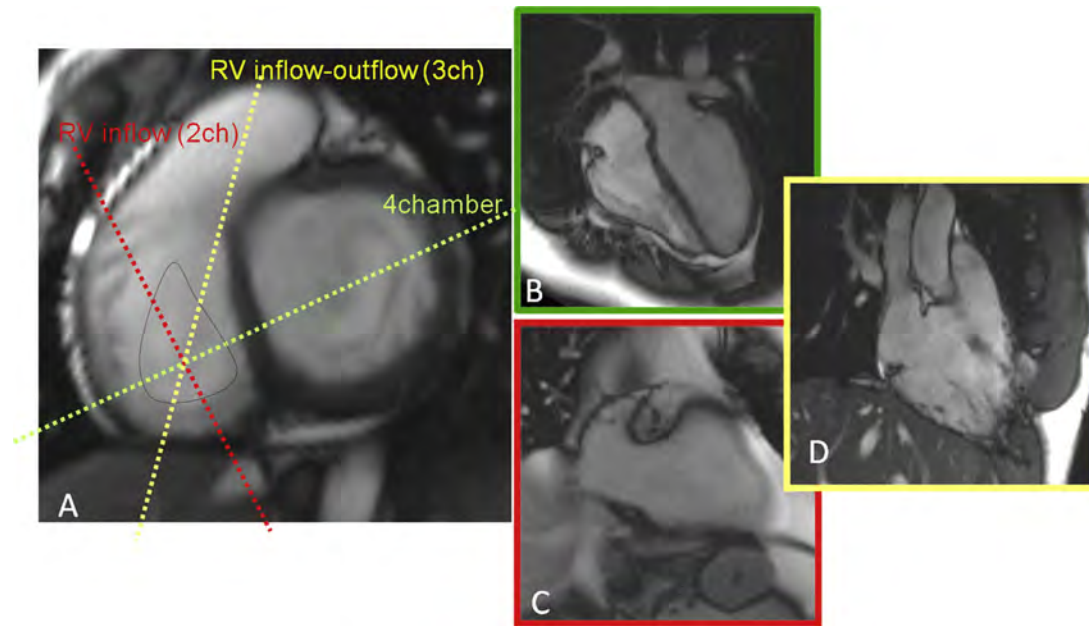


Figure 27 TV normal anatomy visualized by CMR. (A) Basal short-axis view when the tips of the three leaflets can be seen on the same plane (outlined by the *black triangle*). The relationship with the four-chamber view and RV inflow view are illustrated by the *dotted lines*. (B) Four-chamber view where the septal and anterior leaflets are seen. (C) The RV inflow (two-chamber) view where the anterior and posterior leaflets are seen. (D) RV inflow and outflow view (three-chamber view) can visualize posterior and septal leaflets.

Mild TR

Severe TR

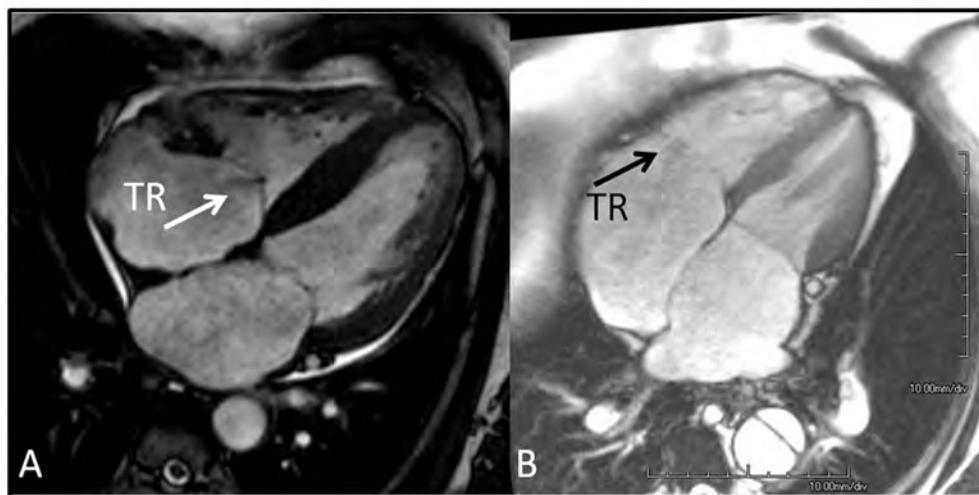


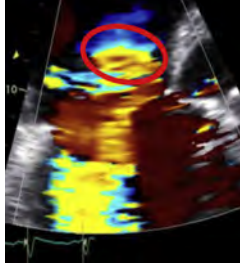

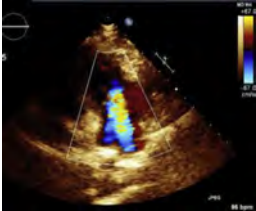
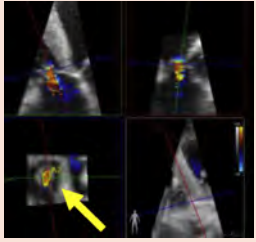
Figure 28 CMR cine SSFP visualization of mild (A) and severe (B) TR. Arrows point to the dephasing jet of TR. Severe TR may be more difficult to visualize, and the leaflet morphology may be obscured.

Parameters of RV systolic function are important in following the effects of chronic primary TR to detect deterioration of RV muscle function. RV systolic function is challenging in this setting as these parameters are load dependent. A tricuspid annular excursion measurement <1.6 cm and an RV fractional area change $<35\%$ are suggestive of RV dysfunction, although tricuspid annular excursion in particular may yield both false-positive and -negative results.²³³ In the presence of an anatomically normal valve, abnormal RV function is more likely the cause rather than the effect of TR. Significant chronic TR also causes

enlargement of the right atrium and inferior vena cava. Lastly, right atrial enlargement in patients with permanent atrial fibrillation and concomitant TV annular dilatation (>35 mm) may result in secondary TR.²³⁷


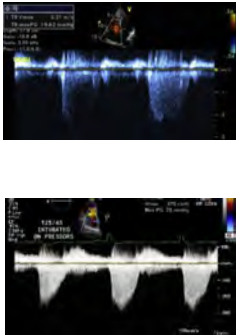
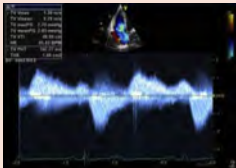
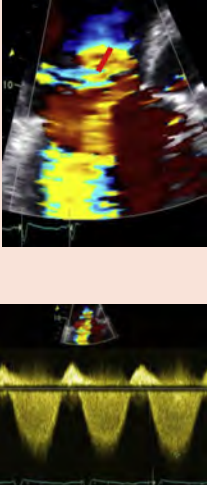
CMR is currently the reference standard for the quantitation of RV size and function.²³⁸ RV volume and function can be measured using the short-axis stack cine SSFP at the same time when the LV is assessed based on existing recommendations.^{6,69} Dedicated axial orientation cine is not necessary in evaluating the RV in the absence of complex congenital disease.²³⁹ In general,

Table 13 Doppler echocardiography in evaluating severity of TR

| Modality | Optimization | Example | Advantages | Pitfalls |
|------------------------------|---|---|---|--|
| Color flow Doppler 2D | | | | |
| Proximal flow convergence | <ul style="list-style-type: none"> Align direction of flow with insonation beam to avoid distortion of hemisphere from noncoaxial imaging Zoomed view Change baseline of Nyquist limit in the direction of the jet Adjust lower Nyquist limit to obtain the most hemispheric flow convergence | <p>Apical four color view</p>  | <ul style="list-style-type: none"> Rapid qualitative assessment | <ul style="list-style-type: none"> Multiple jets Nonhemispheric shape |
| VC | <ul style="list-style-type: none"> Zoomed view Apical four chamber view RV inflow view |  | <ul style="list-style-type: none"> Surrogate for regurgitant orifice size Independent of flow rate and driving pressure for a fixed orifice Less dependent on technical factors Good at identifying severe TR | <ul style="list-style-type: none"> Problematic in the presence of multiple jets In order to measure it, convergence zone needs to be visualized |
| Jet area | <ul style="list-style-type: none"> Four chamber, RV inflow or subcostal views |  | <ul style="list-style-type: none"> Qualitative | <ul style="list-style-type: none"> Dependent on the driving pressure and jet direction Direction and shape of jet may overestimate (central entrainment) or underestimate (eccentric, wall-impinging) jet area |
| Color flow Doppler 3D: 3D VC | <ul style="list-style-type: none"> Color flow sector should be narrow Align orthogonal cropping planes along the axis of the jet Choose a midsystolic cycle Noncoaxial jets or aliased flow may appear "laminar" but still represent regurgitant flow |  | <ul style="list-style-type: none"> Multiple jets of differing directions may be measured | <ul style="list-style-type: none"> Dynamic jets may be over- or underestimated Time consuming Limited spatial resolution will lead to overestimation |

(Continued)

Table 13 (Continued)

| Modality | Optimization | Example | Advantages | Pitfalls |
|--|---|---|--|--|
| Pulsed wave Doppler: Hepatic vein flow reversal | <ul style="list-style-type: none"> Align insonation beam with the flow in the hepatic vein |  | <ul style="list-style-type: none"> Simple supportive sign of severe TR Can be obtained with both TTE and TEE | <ul style="list-style-type: none"> Depends on compliance of the right atrium May not be reliable in patients with atrial fibrillation, paced rhythm with retrograde atrial conduction |
| CWD | | | | |
| Density of regurgitant jet | <ul style="list-style-type: none"> Align insonation beam with the flow |  | <ul style="list-style-type: none"> Simple Density is proportional to the number of red blood cells reflecting the signal Faint or incomplete jet is compatible with mild TR | <ul style="list-style-type: none"> Qualitative Perfectly central jets may appear denser than eccentric jets of higher severity Overlap between moderate and severe TR |
| Jet contour | <ul style="list-style-type: none"> Align insonation beam with the flow |  | <ul style="list-style-type: none"> Simple Specific sign of pressure equalization in low velocity, early peaking dense TR jet | <ul style="list-style-type: none"> Qualitative Affected by changes that modify RV and RA pressures |
| Quantitative Doppler: EROA, regurgitation volume: | | | | |
| PISA | <ul style="list-style-type: none"> Align insonation beam with the flow Lower the color Doppler baseline in the direction of the jet Look for the hemispheric shape to guide the best lower Nyquist limit CWD of regurgitant jet for peak velocity and VTI |  | <ul style="list-style-type: none"> Quantitative assessment of lesion severity (EROA) and volume overload (RVol) | <ul style="list-style-type: none"> Not valid for multiple jets, less accurate in eccentric jets Limited experience and evidence Typically lower RV pressures (than LV) lead to greater contour flattening and underestimation in proportion to V_a/V_{jet} |

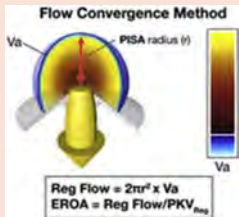


Table 14 Grading the severity of chronic TR by echocardiography

| Parameters | Mild | Moderate | Severe |
|---|---|--------------------------------------|---|
| Structural | | | |
| TV morphology | Normal or mildly abnormal leaflets | Moderately abnormal leaflets | Severe valve lesions (e.g., flail leaflet, severe retraction, large perforation) |
| RV and RA size | Usually normal | Normal or mild dilatation | Usually dilated* |
| Inferior vena cava diameter | Normal < 2 cm | Normal or mildly dilated 2.1- 2.5 cm | Dilated > 2.5 cm |
| Qualitative Doppler | | | |
| Color flow jet area [†] | Small, narrow, central | Moderate central | Large central jet or eccentric wall-impinging jet of variable size |
| Flow convergence zone | Not visible, transient or small | Intermediate in size and duration | Large throughout systole |
| CWD jet | Faint/partial/parabolic | Dense, parabolic or triangular | Dense, often triangular |
| Semi-quantitative | | | |
| Color flow jet area (cm ²) [†] | Not defined | Not defined | >10 |
| VCW (cm) [†] | <0.3 | 0.3-0.69 | ≥0.7 |
| PISA radius (cm) [‡] | ≤0.5 | 0.6-0.9 | >0.9 |
| Hepatic vein flow [§] | Systolic dominance | Systolic blunting | Systolic flow reversal |
| Tricuspid inflow [§] | A-wave dominant | Variable | E-wave >1.0 m/sec |
| Quantitative | | | |
| EROA (cm ²) | <0.20 | 0.20-0.39 | ≥0.40 |
| RVol (2D PISA) (mL) | <30 | 30-44 | ≥45 |

RA, Right atrium.

Bolded signs are considered specific for their TR grade.

*RV and RA size can be within the "normal" range in patients with acute severe TR.

[†]With Nyquist limit >50-70 cm/sec.

[‡]With baseline Nyquist limit shift of 28 cm/sec.

[§]Signs are nonspecific and are influenced by many other factors (RV diastolic function, atrial fibrillation, RA pressure).

^{||}There are little data to support further separation of these values.

right atrial and RV size measurements are larger by CMR than by echocardiography due to different handling of trabeculations.^{158,240}

D. Echocardiographic Evaluation of TR Severity

1. Color Flow Imaging. Color flow Doppler evaluation of TR severity involves a critical assessment of the components of the jet: jet area, VC, and flow convergence (Tables 13 and 14).

a. Jet area. Jet area is one of the color Doppler parameters of regurgitation severity. However, there can be considerable overlap of jet areas in patients with mild versus moderate TR. Furthermore, and similar to MR, regurgitant jets that are eccentric and wall impinging appear smaller than centrally directed jets with similar RVol (Figure 29). In general, a color Doppler jet area of >10 cm² is consistent with severe TR; however, since several hemodynamic and anatomic factors affect the appearance of a central jet, jet area is often considered a semi-quantitative parameter only. In wide-open, severe TR with no TV coaptation, the TR velocity may be so low that there is no aliasing of the jet velocity and TR may lose its appearance as a distinct jet.

b. Vena contracta. Visualization of the VCW is technically less demanding than the PISA method and can be utilized either semi-

quantitatively or qualitatively. When acquired from the apical four-chamber and RV inflow parasternal views, a TR VCW >0.7 cm identifies severe TR and is a marker of worse prognosis.²⁹ Three-dimensional color Doppler methods can be used to measure VCA and VCW; however, it is important to note that the imaging planes acquired by 2D and those displayed by 3D may not be identical. In comparing 2D and 3D color Doppler measures of the VC, maximal VC diameter is often larger by 3D Doppler imaging.²⁴¹ The 3D VCA correlates well with EROA, moderately well with VC diameter, and weakly with jet area/right atrial area ratio²⁴² and was best for organic TR and in patients in sinus rhythm. From current available data,^{243,244} a VCA > 0.4 cm² is a reasonable cutoff value for severe TR.

c. Flow convergence. The proximal convergence method is applicable in TR, but there is less experience with TR than with MR. Quantitation of TR using the PISA method has been validated in small studies⁵⁵ but is not commonly used clinically (Figure 30). The general application is similar to MR. The TR PISA method is subject to all the limitations of its application in MR. In particular, the contour flattening as blood gets closer to the orifice may be exaggerated with TR, since the peak TR velocity is generally less than in MR, thus producing more flattening and regurgitant flow underestimation. To the extent that the orifice is noncircular (as often happens in TR), the usual PISA approach will produce

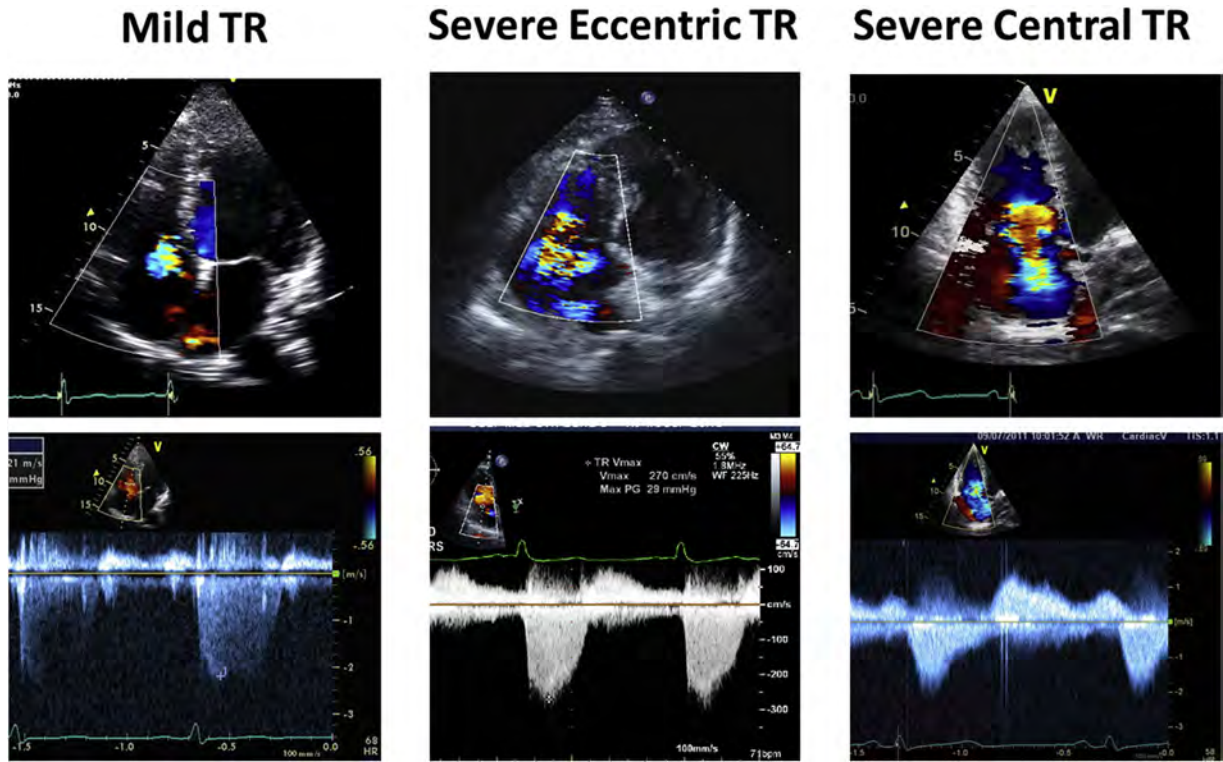


Figure 29 Echocardiographic examples of TR cases. In mild TR, a small narrow jet is seen with a narrow VC, no flow convergence, and a “faint” TR jet on CWD. In severe eccentric TR, there is a wide VC and the color flow jet entrains the lateral wall of the right atrium in this patient with a flail septal leaflet; a dense parabolic jet with early peaking is seen. In the severe central TR, the VC is > 7 mm, with a large flow convergence; CWD demonstrates dense triangulated jet with low velocity (2 m/sec) consistent with severe TR and ventricularization of right atrial pressure.

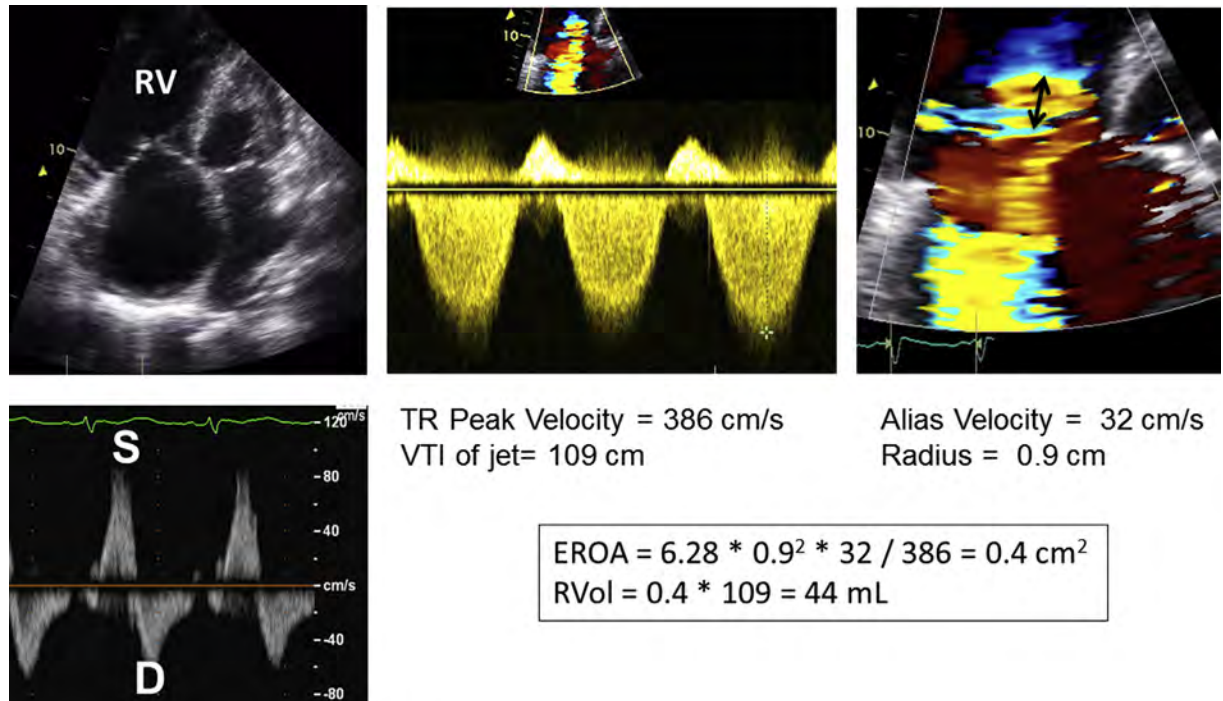


Figure 30 Measurement of EROA and RVol in a patient with severe TR associated with pulmonary hypertension. Severe right atrial enlargement and atrial septal deviation to the left is seen in addition to systolic reversal of hepatic vein flow. *D*, Diastolic velocity; *S*, systolic velocity. Calculations are consistent with severe TR.

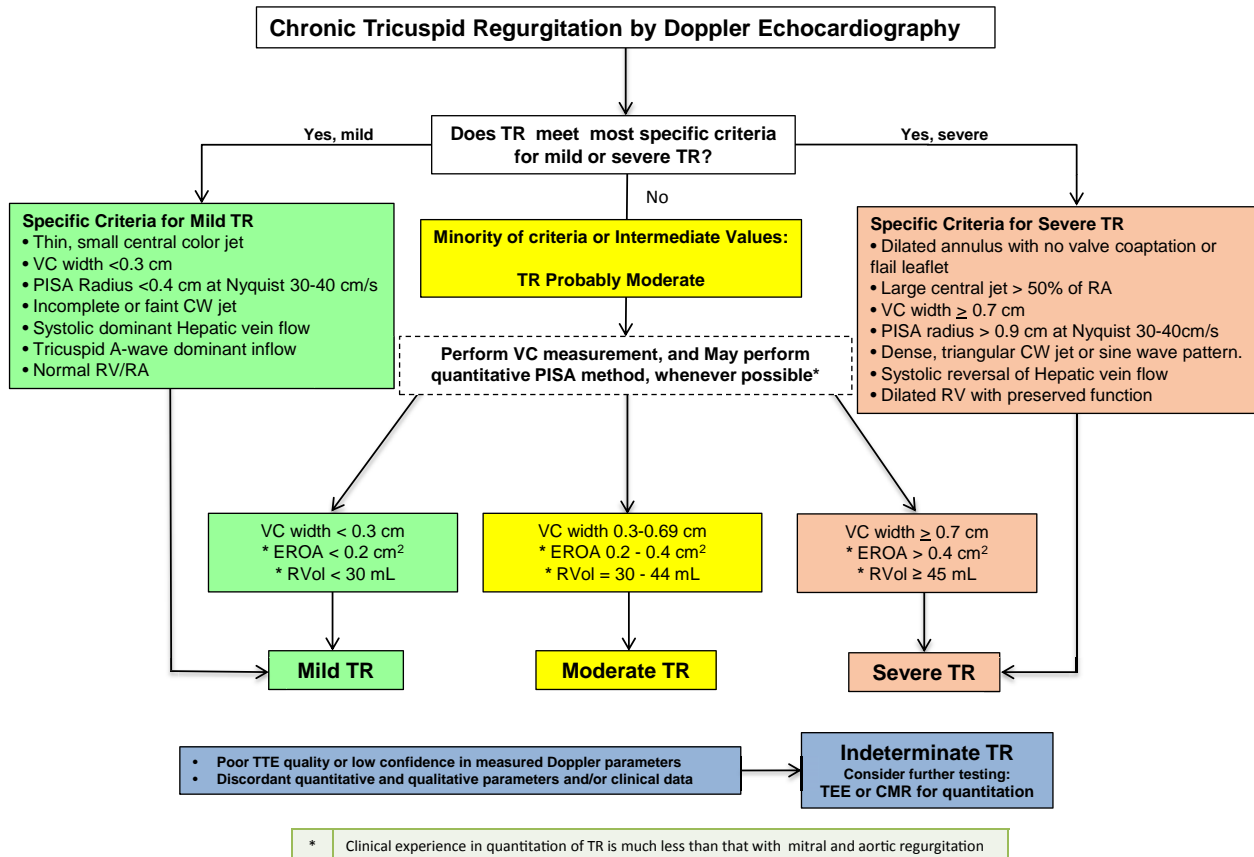


Figure 31 Algorithm for the integration of multiple parameters of TR severity. Good-quality echocardiographic imaging and complete data acquisition are assumed. If imaging is technically difficult, consider TEE or CMR. TR severity may be indeterminate due to poor image quality, technical issues with data, internal inconsistency among echo findings, or discordance with clinical findings.

further underestimation. On the other hand, if the TR arises eccentrically, then the proximal convergence zone will be constrained, producing flow overestimation. Using TTE, the 2D PISA method was compared to a single-beat 3D PISA method and to VCA and volumetric derivation of orifice area; EROA derived with 2D PISA underestimated regurgitant orifice area by the other methods.²⁴³

2. Regurgitant Volume. In theory, TR volume can be calculated by subtracting the flow across a nonregurgitant valve from the antegrade flow across the TV annulus. In contrast to MR and AR, this approach is rarely utilized for TR, partly because of difficulty in accurately estimating the noncircular annular inflow area and the lack of velocity uniformity across the annulus.

The threshold value of RVol for severe TR is unclear. A comparative study in patients with severe MR and TR observed that for the same 2D PISA EROA of ≥ 0.4 cm², RVols cutoffs were different for TR (≥ 45 mL/beat) than for MR (≥ 60 mL/beat),²⁴⁴ an obvious consequence of the typically lower TR velocity than MR, suggesting that in clinical practice different thresholds for severe TR and MR may need to be used for RVol, whereas a similar grading scheme can be employed for EROA cutoff. Further confirmation of these findings is needed using volumetric techniques.

3. Pulsed and Continuous Wave Doppler. It is important to note that TR jet velocity is not related to the volume of regurgitant flow. In fact, very severe TR is often associated with a low jet velocity (2 m/sec), with near equalization of RV and right atrial systolic pressures (Figure 29). Similar to MR, the features of the CWD TR jet that help in evaluating severity of regurgitation are the signal intensity and the contour of the velocity curve. With severe TR, a dense spectral recording is seen. A truncated, triangular jet contour with early peaking of the maximal velocity indicates elevated right atrium pressure and a prominent regurgitant pressure wave ("V wave") in the right atrium (Figure 29). It should be noted that this pattern may be present in patients with milder degrees of TR and severe elevation of right atrium pressure (reduced right atrial compliance). With severe TR and normal RV systolic pressure, the antegrade and retrograde CW flow signals across the valve can appear qualitatively very similar with a "sine wave" appearance, corresponding to the "to-and-fro" flow across the severely incompetent valve.

Pulsed wave Doppler examination of the hepatic veins helps corroborate the assessment of TR severity. With increasing severity of TR, the normally dominant systolic wave is blunted. With severe TR, systolic flow reversal occurs (Figure 30). However, hepatic vein flow patterns are also affected by right atrial and RV compliance, respiration, preload, pacemaker rhythms, complete heart block, and

atrial fibrillation and flutter. Systolic flow reversal is a specific sign of severe TR, provided that the modulating conditions mentioned above are accounted for during interpretation.

E. CMR Evaluation of TR Severity

CMR assessment of TR is less established compared with other regurgitant valvular lesions. Few indirect quantitative techniques have been used since direct measurement of tricuspid inflow is of limited value (substantial through-plane motion of the TV).²⁴⁵ RVol can be calculated by subtracting pulmonic forward volume from the RV SV and deriving a RF. Alternatively, in the absence of AR, aortic forward volume can be subtracted from the RV SV. Lastly, in the absence of other regurgitant lesions, LV SV can also be subtracted from RV SV to obtain TR RVol. There are no specific thresholds of RVol for TR severity by CMR. Instead, thresholds for RF have been borrowed from MR classification to grade TR severity ($\leq 15\%$ mild, 16%-25% moderate, 25%-48% moderate to severe, and $>48\%$ severe).⁸⁵

Additional qualitative methods to assess TR have been reported using CMR. Visual assessment based on spin dephasing in the right atrium has been used previously.²⁴⁶ However, newer SSFP sequences, unlike the early spoiled gradient echo sequences, tend to minimize spin dephasing; this is even less appreciated in severe TR and is therefore not recommended to grade regurgitation severity. Time-resolved imaging of contrast kinetics angiography and retrograde hepatic vein contrast appearance have also been used.²⁴⁷

The strength of CMR is its ability to quantitatively assess RVol, fraction, and ventricular and atrial remodeling. The limitations of CMR result both from errors in the RV volume assessment and issues in the acquisition of accurate phase-contrast images in the PA. It may be difficult to trace the enlarged trabeculated RV, which can extend above the tricuspid annulus into the atrial plane.²⁴⁸ Pulmonary outflow and aortic outflow were assessed in patients without an intracardiac shunt and the calculated Qp:Qs was found to be within 0.8-1.2. Therefore a 20% error can exist in either direction in the phase-contrast flow assessment of the PA.²⁴⁹ In addition, background phase, partial volume average from low spatial resolution and nonperpendicular plane selection, and complex jet flow pattern causing intravoxel dephasing and loss of phase coherence can all lead to inaccurate phase-contrast assessment.⁸² Indirect quantification of TR can amplify errors and lead to significant under- or overestimation. In addition, to date, categorization of TR severity by CMR has not been validated due to lack of adequate reference standards.

F. Integrative Approach in the Evaluation of TR

The ideal approach to evaluation of TR severity is to integrate multiple parameters of TR severity rather than emphasize or depend on a single measurement. This approach helps to mitigate the effects of technical or measurement errors, which are inherent to each method previously discussed. It is also important to distinguish between the volume of TR and its hemodynamic consequences, particularly when considering acute versus more chronic regurgitation.

The consensus of the committee is to propose an approach to TR evaluation that would first assess the severity of valve regurgitation by evaluating whether there is a majority of specific signs that would point towards either mild or severe regurgitation (Figure 31). If most of the signs and indices are concordant, then there is confidence in the interpretation and no further quantitation is needed. If the signs

or values of the qualitative or semiquantitative parameters are in the intermediate range between mild and severe, most likely the severity of TR is moderate. Although quantitation may be feasible, it is more challenging than in MR and AR; echocardiographers with experience in quantitation may quantitate RVols and EROA to further refine assessment of intermediate lesions; however, clinical experience with these measurements is far less than with MR and AR. Furthermore, in contrast to MR and AR, further subclassifying TR severity into four grades according to quantitative criteria has not been validated in the literature. In the cases where there is difficulty in the evaluation of regurgitation by TTE, significant internal inconsistency (signs of mild and severe TR that cannot be resolved) or discordant findings with the clinical presentation, further evaluation by other modalities may be warranted to more accurately assess the mechanism and severity of TR.

Key Points

- Physiologic mild TR is common in normal individuals.
- In patients with more than mild TR, identifying the mechanism of TR is important. TR is classified as primary or secondary (functional), and the precise mechanism of TR should be specified and reported (Table 12).
- No single Doppler and echocardiographic measurement or parameter is precise enough to quantify TR severity. Integration of multiple parameters is required (Tables 13 and 14). When multiple parameters are concordant, TR grade can be determined with high probability (especially for mild or severe TR).
- There is less experience with quantitation of TR severity with PISA or volumetric flow compared with MR and AR.
- Severe, wide-open TR may have low velocity, without aliasing or turbulence, and thus may be difficult to see as a distinct jet by color Doppler.
- The size of the right atrium and RV should be considered. Chronic severe TR almost always leads to dilated RV and right atrium. Conversely, normal chamber volumes are unusual with chronic severe TR.
- CMR assessment of TR is less established compared with other regurgitant valvular lesions. Few indirect quantitative techniques can be used.
- Additional testing with TEE or CMR is indicated when the TTE examination does not provide a mechanism for significant TR, the echo/Doppler parameters are discordant or inconclusive regarding the severity of TR, or there is discrepancy of echocardiographic findings with the clinical setting.

VI. PULMONARY REGURGITATION

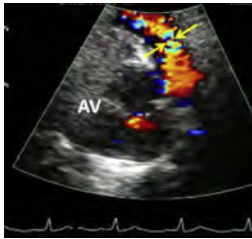
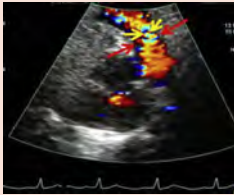
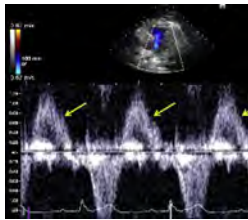
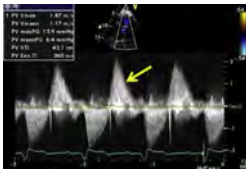
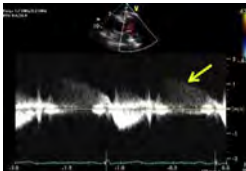
Trace to mild PR, similar to TR, is a common finding and reported to occur in almost 75% of the population^{250,251} and is of little hemodynamic significance. The primary goal of imaging is to identify and assess abnormal degrees of PR, its etiology, and effect on cardiac structure and function.

A. Anatomy and General Imaging Considerations

The PV is a semilunar valve with three cusps, located anterior and superior to the aortic valve. The PV cusps are thinner than those of the aortic valve. In the normal heart, the PA arises from a muscular infundibulum and therefore lacks fibrous continuity with the TV.²⁵² The plane of the PV is orthogonal to that of the aortic valve. Awareness of this spatial relationship is useful when the operator is attempting to define the optimal imaging window for PV imaging. Because the PV is an anterior structure, it offers challenges to imaging, particularly with TEE.

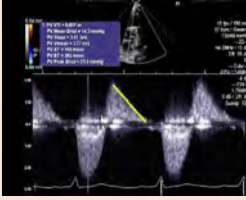
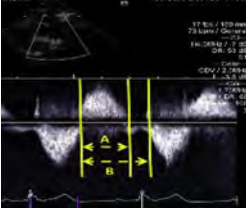

In addition to visualizing the valvular anatomy, the aims of imaging should include inspection of the RVOT, pulmonary annulus, main PA and proximal branches. The annulus and main PA may be dilated in patients with pulmonary hypertension and connective tissue disorders and in some patients with congenital heart disease. The RVOT is often dilated in patients with tetralogy of Fallot whose surgery involved enlargement of the RVOT, usually with a patch. Branch pulmonary stenosis may also contribute to more significant PR.

Table 15 Doppler echocardiography in evaluating severity of PR

| Modality | Optimization | Example | Advantages | Pitfalls |
|---|---|--|--|---|
| Color flow Doppler 2D | | | | |
| VC | <ul style="list-style-type: none"> Parasternal short-axis or subcostal views Zoomed view Should visualize proximal flow convergence, distal jet, and the “narrow” neck in a single view Measured in diastole immediately below PV |  | <ul style="list-style-type: none"> Surrogate for effective regurgitant orifice size Independent of flow rate and driving pressure for a fixed orifice Less dependent on technical factors | <ul style="list-style-type: none"> Not usable with multiple jets The direction of the jet (in relation to the insonation beam) will influence the appearance of the jet Cutoffs for various grades of PR not validated. Not easy to perform |
| VCW/PV annular diameter ratio | <ul style="list-style-type: none"> Parasternal short-axis view Zoomed view Optimize visualization of proximal PA |  | <ul style="list-style-type: none"> Simple sensitive screen for PR Rapid qualitative assessment | <ul style="list-style-type: none"> Underestimates PR in eccentric jets Overestimates PR in central jets PR jet may expand unpredictably below the orifice |
| Pulsed wave Doppler: flow reversal in the branch PA | <ul style="list-style-type: none"> Align insonation beam with the flow in the RPA and LPA Obtain pulsed wave Doppler from both branch PAs |  | <ul style="list-style-type: none"> Simple supportive sign of severe PR | <ul style="list-style-type: none"> Depends on compliance of the PA Brief velocity reversal is normal |
| CWD | | | | |
| Density of regurgitant jet | <ul style="list-style-type: none"> Align insonation beam with the flow PSAX view or subcostal views | <p>Severe PR with dense jet</p>  <p>Mild PR</p>  | <ul style="list-style-type: none"> Simple Density is proportional to the number of red blood cells reflecting the signal Faint or incomplete jet is compatible with mild PR | <ul style="list-style-type: none"> Qualitative Perfectly central jets may appear denser than eccentric jets of higher severity Overlap between moderate and severe PR |

(Continued)

Table 15 (Continued)

| Modality | Optimization | Example | Advantages | Pitfalls |
|---|--|--|---|---|
| Jet deceleration rate (pressure half-time) | <ul style="list-style-type: none"> Align insonation beam with the flow PSAX view or subcostal views |  | <ul style="list-style-type: none"> Simple Specific sign of pressure equalization Values < 100 msec consistent with severe PR | <ul style="list-style-type: none"> Poor alignment of Doppler beam may result in eccentric jets providing low PHT Affected by RV and PA pressure difference, e.g., RV diastolic dysfunction. |
| The PR index (A/B) | <ul style="list-style-type: none"> Align insonation beam with the flow PSAX view or subcostal views Ensure complete forward and regurgitant flow spectral Doppler |  | <ul style="list-style-type: none"> Uses combination of PR duration and duration of diastole Accounts for pressure differences between PA and RV | <ul style="list-style-type: none"> Affected by RV diastolic dysfunction and RV diastolic pressures. |
| Quantitative Doppler: RVol and fraction | | | | |
| $RVol = SV_{RVOT} - SV_{LVOT}$ $RF = RVol/SV_{RVOT}$ | <ul style="list-style-type: none"> Pulmonic annulus from PSAX view, measured during early ejection just below PV Pulsed Doppler in RVOT from PSAX Aortic annulus measured in early systole from PLA Pulsed Doppler in LVOT from apical window. |  | <ul style="list-style-type: none"> Quantitative, valid with multiple jets and eccentric jets. Provides lesion severity (RF) and volume overload (RVol); EROA not validated | <ul style="list-style-type: none"> Difficulties measuring RVOT diameter In case of AR, would need to use the mitral annulus site. Experience is scant |

LPA, Left pulmonary artery; PHT, Pressure half-time; PSAX, Parasternal short axis; RPA, Right pulmonary artery.

B. Etiology and Pathology

Primary PR due to abnormal PV leaflets is more common in congenital heart disease and after balloon valvuloplasty for pulmonic stenosis than acquired valve disease. Significant acquired PR is rare, occurring in <1% of patients, and is present in adults with pathologies such as rheumatic heart disease, endocarditis, carcinoid valve disease, or pergolide-induced disease.^{253,254} Rarely blunt chest trauma can lead to leaflet disruption and prolapse. Secondary PR is most common in patients with elevated PA pressure, although the volume of regurgitation is usually small. By definition, the PV leaflets are normal with secondary PR.

C. Right Ventricular Remodeling

Significant primary PR leads to an enlargement of the RV with preserved RV function and a volume overload pattern of the septum. Chronic severe PR may lead to RV dysfunction. However, RV dilation by itself is not a specific sign of significant PR since it can result

from a number of conditions, so it is important to correlate RV dilation with the severity of PR by Doppler. Dilation may also be localized to the RVOT as can be seen after a tetralogy repair. In secondary PR, RV dilation and function as well as septal motion relate more to the underlying disease state (e.g., pulmonary hypertension severity) than to the degree of PR, which is usually at most moderate.

D. Echocardiographic Evaluation of PR Severity

There is a paucity of data regarding the quantification of PR. This stems partly from the difficulty in visualizing PR, the fact that minor degrees of PR are common and have no clinical impact, and the low incidence of clinically significant PR in the adult. Most of the concepts for quantifying AR are applied to PR. The various parameters used and their advantages and limitations are listed in Table 15.

1. Color Flow Doppler. Color Doppler assessment of PR severity includes proximal jet width, color jet area, and jet length (Figure 32).

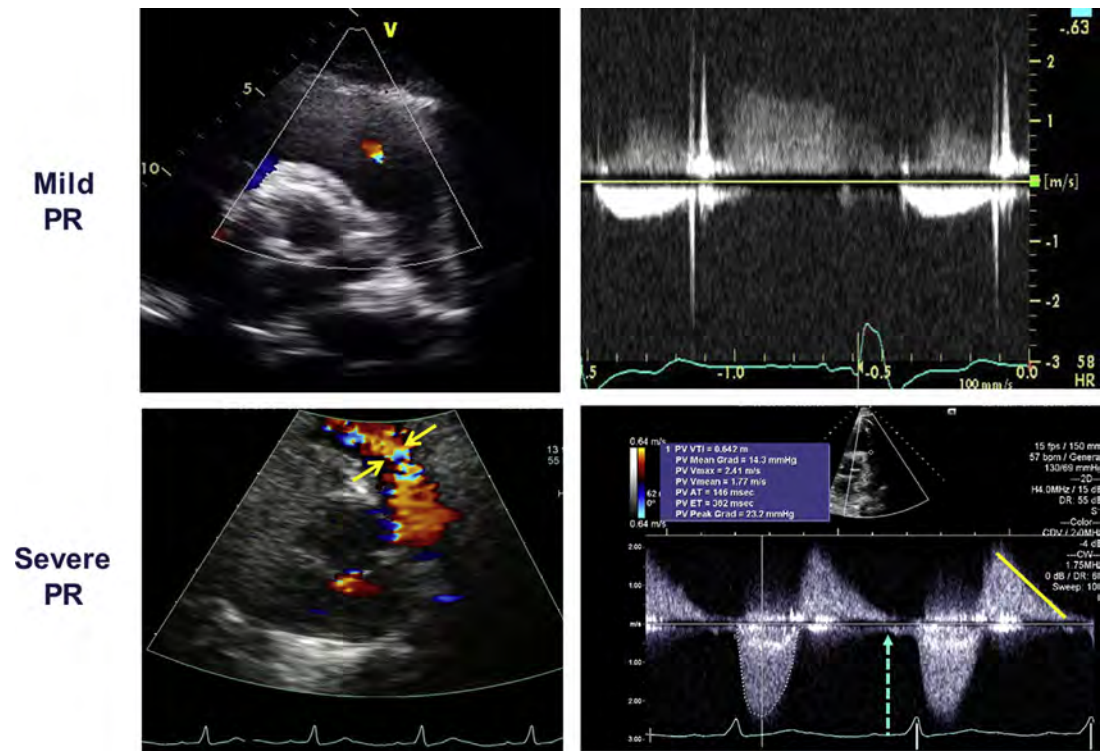


Figure 32 Examples of mild and severe PR depicting the difference in color jet, jet height (*between arrows*), and spectral density and deceleration of the PR jet by CWD. In severe PR, there is frequently early termination of the diastolic regurgitant flow (*green arrow*) with early equalization of RV and PA diastolic pressures.

A jet length of <10 mm is considered to represent insignificant PR,²⁵¹ particularly if narrow at the origin; however, as in the case of AR, jet length is sensitive to driving pressure. The jet area has been related to various degrees of PR at angiography; however, significant overlap is seen, and it can be difficult to measure reproducibly. The proximal jet width (VC) is probably the most widely used semiquantitative color Doppler method. This parameter is less dependent on driving pressures and is simple and more reproducible. The VCW of the PR is commonly expressed as a ratio relative to the PV annulus diameter. A ratio of >0.5 is correlated with severe PR measured by CMR.^{255,256} It is important to note that in severe PR with normal PA pressures (e.g., primary PR), the color jet can be difficult to detect as the PR jet velocities are low, laminar, and brief in duration due to rapid equilibration of pressures across the PV. In secondary PR with pulmonary hypertension, the jet is aliased, of high velocity, and usually holodiastolic. There are limited data on the role of 3D echocardiography in assessing PR.²⁵⁷

2. Pulsed and Continuous Wave Doppler. The density of the CW signal provides a qualitative measure of regurgitation. The CW pattern seen in mild PR shows a soft or faint signal with slow deceleration. In contrast, severe PR has a dense jet with rapid deceleration of the velocity due to the rapid equilibration of the diastolic pressure gradient between the PA and RV (*Figures 32 and 33*). This “to-and-fro” flow across the PV shows a characteristic “sine wave” shape. It is important to note that rapid deceleration by itself is not specific for severe PR and can be seen in conditions with decreased RV compliance. Judging the severity of PR in these situations will

depend on color Doppler characteristics of the PR jet and comparative flow considerations.

Few indices have been proposed to quantitate the deceleration of the PR velocity and its premature diastolic termination. A pressure half-time of <100 msec (or deceleration time of <260 msec) has been shown to be consistent with severe PR.²⁵⁸ A PR index has also been suggested, calculated as the ratio of PR duration by CWD to total diastolic time (*Figure 33*).²⁵⁹ A PR index of <0.77 was shown to correlate well with severe PR by CMR. However, these indices, as noted, are not specific for severe PR and have to be integrated with other findings in evaluating PR severity.

An additional sign of severe PR by pulsed Doppler is the presence of reverse flow in the PA. The presence of diastolic flow reversal in the branch pulmonary arteries had a sensitivity and specificity of 87% for severe PR compared with CMR. It is important to visualize and sample flow in the branch pulmonary arteries and not just in the main PA, as the specificity dropped to 39%.²⁵⁵

3. Quantitative Doppler. Quantitative pulsed Doppler methods can be used to measure PR RVol and fraction. The RVOT, however, is probably the most difficult site to measure SV because of its poor visualization and the changing size of the RVOT during the cardiac cycle. The RVOT is measured during early ejection (two to three frames after the R wave on the electrocardiogram) just below the PV in the parasternal short-axis view.²⁶⁰ Although not validated for quantitation of PR, flows in the RVOT can be compared to other sites to derive RVol and fraction.

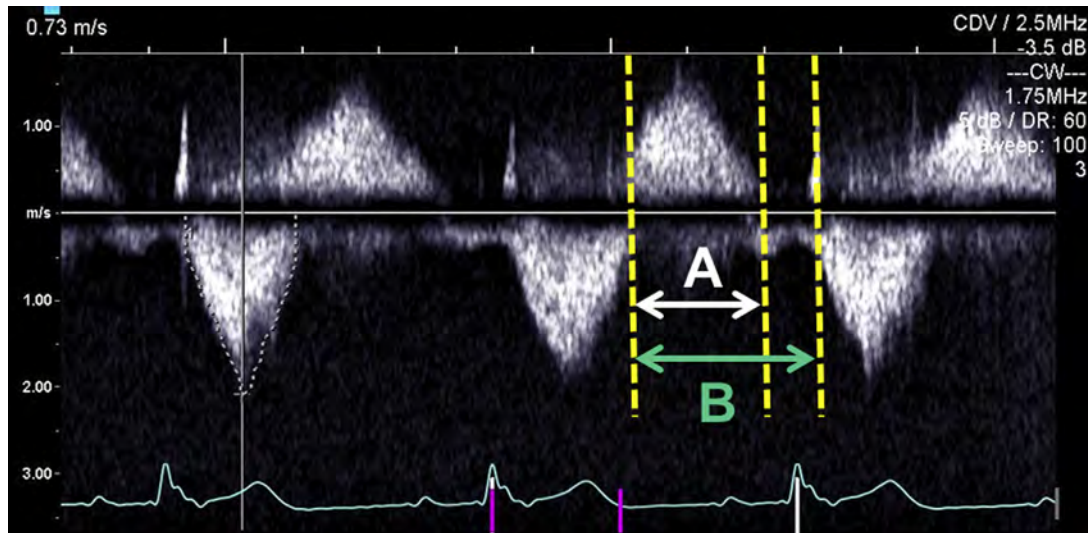


Figure 33 CWD of pulmonic flow. Calculation of pulmonic regurgitation index (PR index = A/B) is shown, an index of PR severity, quantitating early termination of diastolic regurgitant flow.

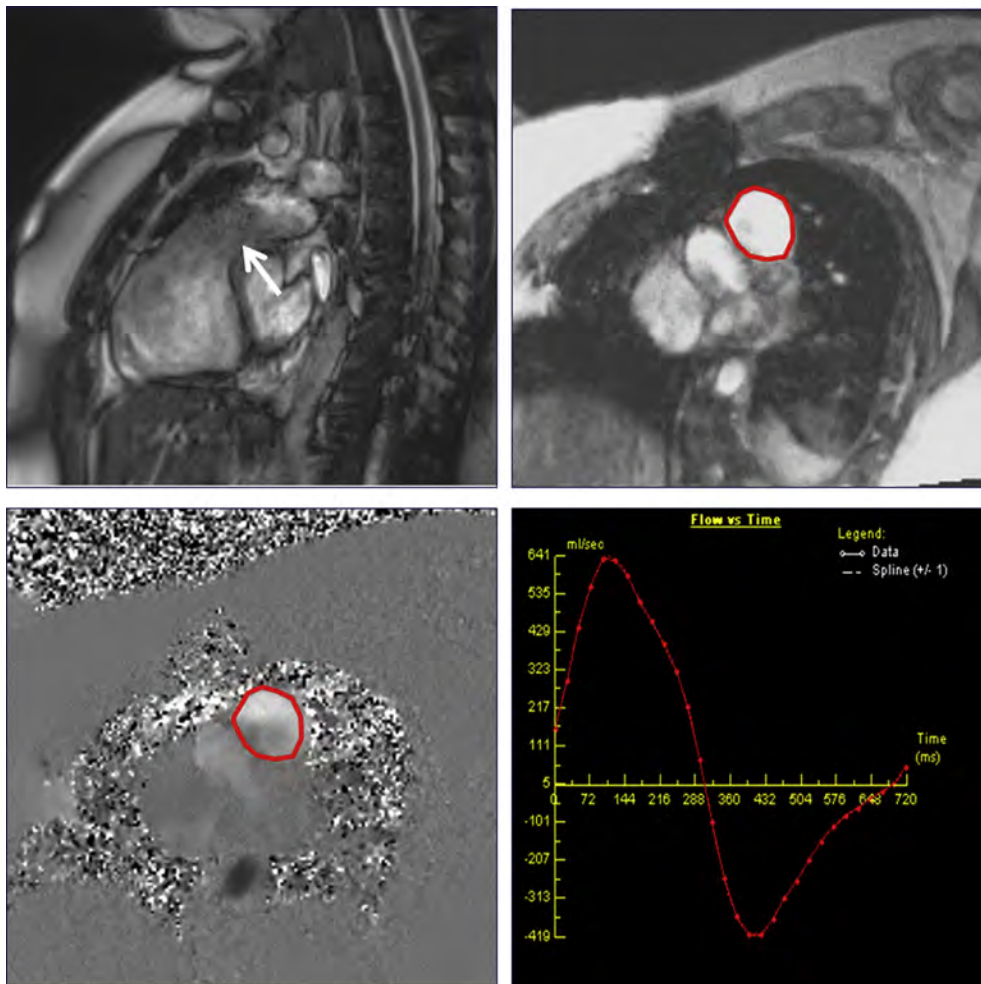


Figure 34 An example of severe PR (arrow) assessed by CMR. The red circles depict the magnitude image of the pulmonary artery (upper left panel) and the respective phase contrast image (lower left panel). Forward SV by phase contrast was 129 mL, and reverse (regurgitant) volume was 78 mL, yielding an RF of 60% (lower right panel).

Table 16 Echocardiographic and Doppler parameters useful in grading PR severity

| Parameter | Mild | Moderate | Severe |
|--|--|--------------------|---|
| Pulmonic valve | Normal | Normal or abnormal | Abnormal and may not be visible |
| RV size | Normal* | Normal or dilated | Dilated† |
| Jet size, color Doppler‡ | Thin (usually <10 mm in length) with a narrow origin | Intermediate | Broad origin; variable depth of penetration |
| Ratio of PR jet width/pulmonary annulus | | | >0.7§ |
| Jet density and contour (CW) | Soft | Dense | Dense; early termination of diastolic flow |
| Deceleration time of the PR spectral Doppler signal | | | Short, <260 msec |
| Pressure half-time of PR jet | | | <100 msec |
| PR index¶ | | <0.77 | <0.77 |
| Diastolic flow reversal in the main or branch PAs (PW) | | | Prominent |
| Pulmonic systolic flow (VTI) compared to systemic flow (LVOT VTI) by PW# | Slightly increased | Intermediate | Greatly increased |
| RF** | <20% | 20%-40% | >40% |

PW, Pulsed wave Doppler.

*Unless there are other reasons for RV enlargement.

†Exception: acute PR.

‡At a Nyquist limit of 50-70 cm/sec.

§Identifies a CMR-derived PR fraction $\geq 40\%$.

¶Defined as the duration of the PR signal divided by the total duration of diastole, with this cutoff identifying a CMR-derived PR fraction > 25%.

||Not reliable in the presence of high RV end diastolic pressure.

#Cutoff values for RVol and fraction are not well validated.

§Steep deceleration is not specific for severe PR.

**RF data primarily derived from CMR with limited application with echocardiography.

E. CMR Methods in Evaluating PR

CMR is currently the best method to quantitate PR and serially evaluate RV remodeling and function in patients with significant PR and congenital heart disease.²⁶¹ Several approaches can be used to quantify PR by CMR. These can be classified into two broad categories as direct and indirect methods resulting in calculations of RVol and fraction. The methodology of these approaches and their clinical use have been discussed earlier and previously detailed.^{6,69} There is some evidence that pulmonic RVol may better reflect the physiological consequence to the RV than RF.^{262,263} Other CMR techniques such as visual assessment of the degree of signal loss due to spin dephasing from the regurgitation²⁴⁶ can be used but are less validated and provide only a qualitative assessment.

The direct method based on the use of phase-contrast imaging with acquisition obtained from above the PV (Figure 34) is the preferred method, as it allows direct measurement of total pulmonic forward SV and RVol.²⁶⁴ The indirect methods are based on SV quantification by ventricular endocardial contouring with or without additional phase-contrast imaging. One method is to use the difference in RV and LV SVs.^{245,263,265} This technique is only valid in the absence of any other concomitant valvular regurgitation. A second indirect method is to use the difference between RV SV by endocardial contouring and aortic forward SV by phase-contrast imaging to calculate pulmonic RVol. This method is only valid in the absence

of TR. Other indirect techniques can be used but are less reliable. The best use of these indirect techniques is to confirm the findings of the direct technique.

There are no specific thresholds for PR severity by CMR; as in other regurgitant valves, these have been borrowed from the echo literature. One recommendation for PR severity uses a RF <20% to define mild PR, 20%-40% for moderate, and >40% for severe PR.²⁶⁶ RVol categories for PR severity by CMR have not been defined.

F. Integrative Approach to Assessment of PR

Trivial and mild PR is clinically very common²⁶⁷ and easily diagnosed. On the other hand, clinically significant PR is uncommon and is usually secondary to pulmonary hypertension and congenital heart disease. Echocardiography is the primary modality for assessment of PR. An integrative approach combining color, pulsed wave Doppler, and CW methods should be used in the grading of PR. The simplest and most robust method is PR jet width, and VC. Other Doppler measures have limitations, high variability, or limited validation. Table 16 summarizes the parameters for grading PR. Using these criteria, an algorithm was developed for the assessment of PR and separating mild from severe PR (Figure 35). If the majority or all criteria point to either mild or severe PR, the evaluation of the severity of PR is confident. If intermediate criteria or an overlap among them is present, the

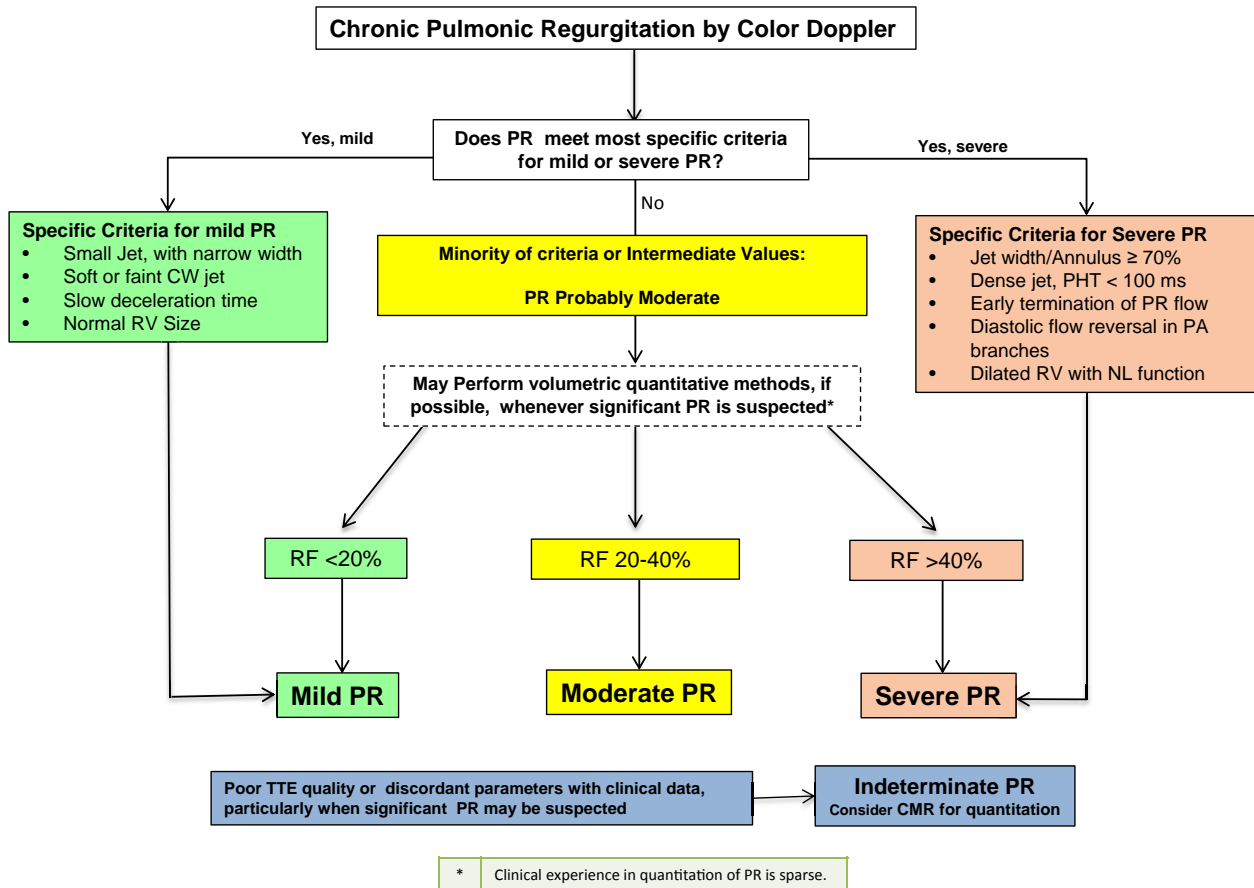


Figure 35 Algorithm for the integration of multiple parameters of PR severity. Good-quality echocardiographic imaging and complete data acquisition are assumed. If imaging is technically difficult, consider CMR or TEE. PR severity may be indeterminate due to poor image quality, technical issues with data, internal inconsistency among echo findings, or discordance with clinical findings. *PHT*, Pressure half-time.

Key Points

- Physiologic, mild PR is common in normal individuals.
- In patients with more than mild PR, identifying the mechanism of PR is important. PR is classified as primary or secondary (functional); primary PR is more common in congenital heart disease.
- No single Doppler and echocardiographic parameter is precise enough to quantify PR severity. Integration of multiple parameters is required (Tables 15 and 16 and Figure 35). When multiple parameters are concordant, PR grade can be determined with high probability (especially for mild or severe PR).
- There is little experience with quantitation of PR severity with Doppler echocardiography.
- Severe, primary PR with normal pulmonary pressures may be of very short duration and has low velocity; thus it may be difficult to see as a distinct jet by color Doppler.
- The size of the RV should be always considered. Chronic severe PR almost always leads to a dilated RV. Conversely, normal chamber volumes are unusual with chronic severe PR. In patients with PR secondary to pulmonary hypertension, the size and function of the RV are variable.
- CMR is an excellent modality for evaluation of the PV, PA and for quantitation of PR severity, using the direct phase-contrast method. It is the preferred method for quantitation of RV volume and function.
- Additional testing with CMR is indicated when the TTE examination does not provide a mechanism for significant PR, the echo/Doppler parameters are discordant or inconclusive regarding the severity of PR, or there is discrepancy of echocardiographic findings with the clinical setting. This indication is particularly relevant in patients with suspected or known congenital heart disease. TEE is not a preferred modality when information beyond TTE is needed.

severity of PR is likely moderate. Although quantitation may be feasible, it is more challenging than in MR and AR; echocardiographers may quantitate RVols and fractions to further refine assessment of intermediate lesions; however, clinical experience with these measurements is far less than with MR and AR and likely better obtained with CMR. Furthermore, in contrast to MR and AR, further subclassifying PR severity into four grades according to quantitative criteria has not been validated in the literature. CMR is indicated when there is concern for clinically significant

PR that cannot be reliably assessed by echocardiography, when the mechanism for PR is not clear, or when there is a discrepancy between severity by echocardiography and other clinical findings (e.g., only moderate PR with dilating RV). In adolescents and adults with congenital heart disease (e.g., repaired tetralogy, after pulmonary valvotomy) and when there is concern for more than moderate PR, CMR is indicated for quantification and follow-up of PR and RV size and function, especially when intervention such as PV replacement is being considered.²⁶¹

VII. CONSIDERATIONS IN MULTIVALVULAR DISEASE

The presence of multivalvular disease makes the assessment of valvular regurgitation more complex. When evaluating the impact of a second valve lesion on a regurgitant lesion, one must consider in addition to the impact on outcomes, whether the additional lesion modifies the actual severity of the primary lesion and whether it affects the quantitation and grading of the primary lesion. Table 17 indicates a few of the ways that the assessment of a given regurgitant lesion by Doppler echocardiography or CMR can be impacted by another concomitant valve lesion.

A. Impact of Multivalvular Disease on Echocardiographic Parameters of Regurgitation

1. Color Jet Area. A lesion or condition that results in a higher pressure gradient will affect color jet area as detailed earlier under general considerations. For example, the addition of aortic stenosis to MR will increase the RVol in proportion to the square root of the rise in LV pressure, assuming that the EROA remains the same (since jet velocity is related to the square root of the driving pressure gradient). The jet area, however, will be expected to increase more than this, since jet momentum is proportional to regurgitant orifice area $\times \Delta p$ and thus is increased above and beyond the increase in flow. Similarly, any lesion that increases pulmonary arterial pressure will worsen TR by similar amounts, with an exaggerated impact on jet area.

2. Regurgitant Orifice Area. Beyond the predictable changes in jet flow with driving pressure, one should also consider whether the second lesion will increase the size of the regurgitant orifice area. Functional MR is particularly prone to this, as the degree of coaptation can vary considerably with LV volume. For example, the further LV dilation from severe AR might increase the regurgitant orifice area in secondary MR and dramatically worsen the RVol. In contrast, one could imagine that a Barlow's-type MV might see a reduction in regurgitant orifice area when AR dilates the LV, making the mitral prolapse less pronounced.

3. Proximal Convergence and Vena Contracta. PISA and VC methods should generally not be influenced by another regurgitant jet, such as AR. Even in severe MR, the flow convergence region, from which PISA calculations are made, is usually within 1.5 cm of the mitral orifice. Unless AR is markedly eccentric directed posteriorly (e.g., a flail right coronary cusp), the AR jet is not likely to interfere with the flow convergence of the MR. One exception would be if the AR flow is severe enough that the forward flow through the LVOT "contaminates" the proximal convergence flow, pushing the aliasing radius outward. A potential solution for this is to increase the V_a , so that the MR PISA is clearly separated from the LVOT flow. The same general observation applies to VC methods, whether using a simple long-axis VCW or the more elegant 3D planimetry of the VCA described previously. There should be little direct impact on VC from a second valvular lesion.

4. Volumetric Methods. All the volumetric methods for quantifying valvular regurgitation require a reference SV against which flow through regurgitant valves can be compared. For example, in isolated MR, LVOT flow could be used as the reference SV. The forward plus mitral RVol could be obtained by either the difference in

LV end-diastolic volume and LV end-systolic volume obtained from 2D or 3D echo or by using PW Doppler to measure the SV through the mitral annulus. Subtracting LVOT SV from either of these "mitral" SVs will yield the mitral RVol. However, if AR ensues, then there is no measurement in the left heart that reflects pure systemic flow, as the LV SV includes both the AR and MR RVols. In such a case, one should seek a reference volume in the right heart, most commonly the RVOT, as the TV annulus site is challenging. Unfortunately, if all four valves have important regurgitation, or a shunt is present from an atrial or ventricular septal defect, then there may simply be no reference systemic SV to use. In such cases, direct measurement of forward and reversed flow through a given valve is the best option. Currently, this is most reliably performed with velocity encoded magnetic resonance imaging (see below), although there is hope that 3D echo could do this as well.

B. CMR Approach to Quantitation of Regurgitation in Multivalvular Disease

CMR methods for the quantification of valvular regurgitation can offer advantages over other methods in the setting of multivalvular disease. For example, the direct method of AR volume assessment via forward and reverse flow measurements in the aortic root is generally not affected by aortic stenosis, mitral stenosis or regurgitation, or right-sided valvular lesions. It is important to note that in the setting of concomitant aortic stenosis, the aortic forward flow may be underestimated (due to intravoxel dephasing from the stenotic jet).²⁶⁸⁻²⁷⁰ Although the aortic reverse volume assessment would not be affected, it will be useful to utilize the forward flow proximal to the lesion (i.e., LVOT) for the purposes of calculating RF.^{268,270} The principles discussed would also apply to the assessment of PR in the setting of concomitant valvular lesions. Table 17 highlights conditions where acquisition or quantitation of RVol and fraction would be different than discussed earlier.

The preferred indirect method for deriving mitral RVol (LV SV - aortic forward SV) will be unaffected by coexisting AR (as both LV SV and aortic forward SV will be increased by the amount of AR). However, calculation of mitral RF will require subtracting the AR RVol from the LV SV. Therefore mitral RF in combined MR and AR would be derived by the following: $MR\ RVol / (LVSV - AR\ RVol) * 100$. As the preferred method for TR assessment is analogous, the principles discussed would also apply to TR assessment in the setting of concomitant valvular lesions.

It is important to note, however, that alternative methods for quantifying regurgitation (aside from the preferred methods detailed above) that are often used as confirmatory checks may not be valid in the setting of multiple valvular lesions. Furthermore, assessments of regurgitant severity could be affected in the setting of intracardiac shunt lesions.

As there is a paucity of data on indications for CMR in the setting of multiple valvular lesions, it is reasonable to consider CMR for scenarios as outlined. Owing to the fact that CMR methods are generally independent of other valvular lesions, it may in fact be the preferred method in these situations. Additionally, CMR may be especially useful in the setting of mixed valve disease to fully determine the consequences of multiple lesions on cardiac morphology and function.

Key Points

- The presence of multivalvular disease makes the assessment of valvular regurgitation more complex.
- When evaluating the impact of a second valve lesion on a regurgitant lesion, one must consider, in addition to the impact on outcomes, whether the lesion (stenosis or regurgitation) modifies the actual severity of the primary regurgitant lesion and whether it affects the quantitation and grading of the primary lesion (Table 17).

Table 17 Impact of multivalvular disease on assessment of valvular regurgitation with Doppler echocardiography and CMR

| By this Valvular Lesion | Impact on this Regurgitant Lesion | | | |
|-------------------------|---|--|---|---|
| | AR | MR | PR | TR |
| AS | Little impact, although hemodynamically significant AR will increase AS gradient. For CMR: phase-contrast plane better in LVOT | For constant ROA, RVol increases in proportion to square root of excess pressure; jet area exaggerated beyond this. ROA may increase if LV dilates. | Little impact unless PH ensues. | Little impact unless PH ensues. |
| AR | NA | LV dilation may increase ROA (especially in secondary MR). Mixed regurgitant lesions render volumetric methods challenging, as one must find some location reflective of net forward flow (e.g., RVOT). For CMR: $MV\ RVol = LVSV - \text{aortic forward flow}$; $MR\ \text{Reg fraction} = \frac{MR\ RVol}{LVSV - AR\ RVol}$. | Little impact unless PH ensues. | Little impact unless PH ensues. |
| MS | Little direct impact, although the delayed LV filling might theoretically lengthen AR pressure half-time. | If MV is heavily calcified, may shadow and decrease jet area and appearance of jet. | Lesion most likely to increase PAP and thus worsen RVol and jet area. | Lesion most likely to increase PAP and thus worsen RVol and jet area. If RV dysfunction occurs, may increase ROA. |
| MR | Little direct impact, but mixed regurgitant lesions render volumetric methods challenging, as one must find some location reflective of net forward flow (e.g., RVOT). Rapid early filling may decrease AR pressure half-time | NA | Likely to increase PAP and thus worsen RVol and jet area. | Likely to increase PAP and thus worsen RVol and jet area. If RV dysfunction occurs, may increase ROA. |
| PS | Little direct impact | Little direct impact | Little impact, although PR will exacerbate PS gradient. For CMR: phase-contrast plane better in RVOT. | Increased RVSP will worsen RVol and jet area. If RV dysfunction occurs, may increase ROA. |
| PR | Little direct impact | Little direct impact | NA | Increased RV volume may increase ROA, which will worsen RVol and jet area. For CMR: $TV\ RVol = RVSV - \text{pulmonic forward flow}$. $TR\ \text{Reg fraction} = \frac{TR\ RVol}{RVSV - PR\ RVol}$. |
| TS | Little direct impact | Little direct impact | Little direct impact | Little direct impact, although TR will exacerbate TS gradient. |
| TR | Little direct impact | Little direct impact | Rapid RV filling from TR may further shorten PR pressure half-time, and color PR jet more brief. | NA |

AS, Aortic stenosis; MS, mitral stenosis; NA, not applicable; PAP, pulmonary artery pressure; PH, pulmonary hypertension; PS, pulmonic stenosis; Reg, regurgitant; ROA, regurgitant orifice area; RVSP, right ventricular systolic pressure; TS, tricuspid stenosis. CMR-related considerations are in bold.

VIII. INTEGRATING IMAGING DATA WITH CLINICAL INFORMATION

The optimal management of patients with valvular regurgitation requires excellent clinical judgment as well as excellent imaging skills. As irreversible LV or RV dysfunction can develop with these lesions before the onset of significant symptoms, it is possible to wait too long before referring patients for surgery or, in some cases, transcatheter intervention. It is also possible to overestimate severity of regurgitation and operate too early in the natural history, thus subjecting patients to the short-term risks of surgical complications and long-term risks of prosthetic valves when they otherwise might have done well without surgery for many years. Thus, accurate quantification of RVols and their hemodynamic impact are of paramount importance.

Data regarding the presence and severity of valvular regurgitation, whether obtained by echocardiography or CMR, need to be interpreted in context with the clinical presentation. Common scenarios include asymptomatic patients with newly diagnosed heart murmurs, patients with known valve disease undergoing serial imaging studies to assess severity of regurgitation and its hemodynamic impact, and patients with heart failure undergoing imaging to assess LV function in whom secondary MR may be suspected or unsuspected. Valvular regurgitation is also often identified as an incidental finding when imaging is performed for other purposes, such as patients after myocardial infarction or patients receiving chemotherapy, in whom previously undetected MR may result from LV systolic dysfunction or be unrelated. Significant but previously unrecognized TR is often detected during evaluation of patients with chronic MR and will require attention if MV surgery is recommended. Similarly, severe PR may be relatively silent for many years in patients following repair of tetralogy of Fallot and other congenital diseases. The indications for and frequency of imaging vary depending on the stages of the disease process as defined in the 2014 AHA/ACC guidelines for management of valvular heart disease¹: stage A, individuals without known disease but at risk for valvular regurgitation (such as patients with bicuspid aortic valves, MVP, previous rheumatic fever, previous myocardial infarction or dilated cardiomyopathy, previous repair of congenital heart disease); stage B, patients with asymptomatic mild to moderate valvular regurgitation with preserved LV or RV function; stage C, patients with asymptomatic severe valvular regurgitation (C1, normal ventricular systolic function; and C2, depressed ventricular systolic function); and stage D, symptomatic patients with severe valvular regurgitation.

Clinically significant MR almost always produces a systolic murmur, and the characteristics of the murmur should be taken into consideration in image interpretation. For example, a mitral murmur that is late systolic in timing rather than holosystolic suggests that the MR is not severe, in which case the timing of the Doppler signal may be more important than the magnitude of the VC and the calculated EROA by PISA in assessing overall severity of MR. An MR murmur that radiates to the posterior thorax is almost always indicative of severe MR; in such cases an eccentric MR jet may be difficult to quantify but the physical findings may prompt additional ancillary imaging findings such as LA dilation and reversal of systolic flow in the pulmonary veins. Symptomatic patients with apparently mild or moderate MR on resting echocardiographic studies, in whom the MR murmur changes dramatically with interventions such as the Valsalva maneuver or standing from a squatting position, may be candidates for exercise Doppler interrogation to determine

Key Points

- The optimal management of patients with valvular regurgitation requires both excellent clinical judgment as well as excellent imaging skills.
- Irreversible LV or RV dysfunction can develop with valvular regurgitation before the onset of clinical symptoms, hence the need for careful serial observations and periodic stress testing in patients with asymptomatic significant regurgitation.
- It is possible to overestimate severity of regurgitation and operate too early in the natural history, thus subjecting patients to the short-term risks of surgical complications and long-term risks of prosthetic valves when they otherwise might have done well without surgery for many years. Thus, accurate assessment and quantification of regurgitation severity parameters and their hemodynamic impact are of paramount importance.
- If TTE results are inconclusive or discordant with the clinical assessment, one should not hesitate to proceed to TEE, CMR, or possibly invasive hemodynamic evaluation for further assessment and clarification.

whether exercise-induced symptoms correlate with worsening of MR. Patients with LV dysfunction and secondary MR often have very soft murmurs even when the MR is severe, and an apical systolic murmur of any magnitude on physical exam in a patient with known LV systolic dysfunction should raise the possibility of clinically significant secondary MR. It is also important to recognize that even mild degrees of MR, which would be well tolerated for years in patients with primary MR, identify patients at considerable risk of heart failure and death in the setting of LV dysfunction and secondary MR.

In contrast, the diastolic murmur of AR is often barely audible or may be completely absent, and the only appreciable murmur may be a systolic outflow murmur related to the high SV. Additional physical findings such as a wide pulse pressure or bounding carotid pulses point toward significant AR rather than AS. AR is often first identified on echocardiograms performed to investigate a systolic murmur.

Similarly, TR is also often not identified clinically prior to echocardiography but identified as an important concomitant lesion in patients with MR. When TR results from primary disease of the TV, there are often no clinical manifestations when the TR is mild. However, severe TR caused by primary disorders is almost invariably associated with a systolic murmur with respiratory variation, elevated V waves in the jugular venous pulse, and an RV heave as evidence of RV volume overload. PR in the setting of normal PA pressure, such as following repair of tetralogy of Fallot, can go unrecognized as the murmur is usually soft and low pitched, whereas PR related to pulmonary hypertension creates a higher pitched murmur that is difficult to distinguish from AR.

As the clinical management of patients with severe MR or AR continues to evolve toward early surgical intervention,¹ it is important that early preemptive surgery be performed only in those with truly severe regurgitation. Similarly, surgery in symptomatic patients is recommended only when AR or MR is considered severe enough to be the cause of symptoms. Thus, quantifying severity of regurgitation with echocardiography or CMR is of paramount importance in determining whether asymptomatic or symptomatic patients are candidates for surgical or percutaneous intervention. In such cases, however, patient symptoms and all of the skills of the clinician such as meticulous physical examination and history taking are of equal importance to the results of the imaging itself to identify those with truly severe disease.

In patients with secondary TR associated with MV disease, surgical repair of severe TR is indicated at the time of MV surgery whether or not there are clinical signs of severe TR. In such situations, the decision for concomitant TV repair is driven principally by imaging evidence of severe TR or severe dilation of the tricuspid annulus.¹ In contrast, in patients with primary TR, the clinical presentation is also of great

importance, as the indications for surgical tricuspid repair or replacement are strongest in those with symptoms, declining exercise tolerance, or evidence of RV failure. However, TV surgery may also be considered in asymptomatic patients when there is evidence of severe TR associated with progressive RV dilation or systolic dysfunction. Diagnosing the etiology of primary TR is often challenging. Expert imaging with echocardiography or CMR is the key to reduce misdiagnoses.

Isolated PR in adults is usually innocuous and rarely severe. A high-pitched murmur of PR, however, may be an important clinical marker of primary or secondary pulmonary hypertension. In addition, PR following repair of tetralogy of Fallot is a common late complication of previous surgical repair with important clinical implications. Patients with previous tetralogy repair should be considered for surgery if severe PR is present in the setting of symptoms, declining effort tolerance, RV dilation/dysfunction, atrial or ventricular arrhythmias, or moderate to severe TR.²⁷¹ As the murmur of PR may itself be unimpressive, awareness of the high frequency of this late complication following otherwise successful repair, with appropriate referral for imaging, is essential. Similarly, hemodynamically important PR in the absence of pulmonary hypertension is a possible late outcome in patients who have undergone transcatheter or surgical PV repair or replacement for pulmonic stenosis and in patients with a pulmonary homograft following a Ross procedure. This emphasizes the need for long-term follow-up of such patients.

In asymptomatic patients with known valvular disease who are being followed serially, the timing of imaging studies changes when there are changes in the clinical situation. Exercise stress testing is used to assess functional capacity and equivocal symptoms. The onset of possible or definite symptoms or changes in the timing or intensity of the murmur should trigger repeat echocardiography or CMR. In patients with bicuspid aortic valves, a new murmur of AR could reflect an increase in severity or dilatation of the aortic sinuses or ascending aorta and is an indication for comprehensive imaging with echocardiography, CMR or both.

IX. FUTURE DIRECTIONS

Cardiovascular imaging has had a major impact in the diagnosis, prognosis, and management of patients with valvular heart disease. In general, regurgitation may present a challenge for most diagnostic techniques because of the dynamic nature of the lesion and its dependence on various hemodynamic and physiologic conditions. For all valvular regurgitation, irrespective of the modality, an integrative approach is recommended to achieve an accurate evaluation of the severity of the lesion and its clinical significance. This takes into account physiologic conditions that could alter the accuracy of certain parameters, emphasizes the quality of the primary data, and allows internal verification of the interpretation. Future developments should aim for advances in ultrasound and CMR techniques, more automation in quantitation to reduce variability, and more data on quantitation and grading of right heart lesions in relation to outcomes. In real-time 3D imaging, improvements in temporal and spatial resolution to enhance display of valve regurgitation and improve automation of flow convergence, VC, and the regurgitant jet would be welcome. Recent advances have included the use of 3D volume color Doppler acquisition followed by use of the velocity information intrinsic to color Doppler data to quantify SV and PISA in mitral,^{67,272-274} aortic,²⁷⁵ and TR.²⁴³ The important potential strengths of these methods include the

increased reproducibility of quantification, reduced dependency on shape and size assumptions, and improvement in work flow, allowing easier integration into routine clinical practice. In CMR, further improvements in quantitation of flow across mitral and TVs, taking into account annular motion, would further enhance the power of the technique to quantitate individual and multiple valve lesions.

REVIEWERS

This document was reviewed by members of the 2016-2017 ASE Guidelines and Standards Committee, ASE Board of Directors, ASE Executive Committee, and a representative for the Society for Cardiovascular Magnetic Resonance.

Reviewers included Deborah A. Agler, RCT, RDCS, FASE, Federico M. Asch, MD, FASE, Merri L. Bremer, EdD, RN, EDCS, ACS, FASE, Benjamin Byrd, MD, FASE, Hollie D. Carron, RDCS, FASE, Joao L. Cavalcante, MD, FASE, Scott D. Choyce, RDCS, RVT, RDMS, FASE, Frederick C. Cobey, MD, FASE, Meryl Cohen, MD, FASE, Patrick H. Collier, MD, PhD, FASE, Keith A. Collins, MS, RDCS, FASE, Mary C. Corretti, MD, FASE, Benjamin Eidem, MD, FASE, Mark K. Friedberg, MD, FASE, Neal Gerstein, MD, FASE, Edward A. Gill, MD, FASE, Yvonne E. Gilliland, MD, FASE, Robi Goswami, MD, FASE, Stephen Heitner, MD, FASE, Lanqi Hua, RDCS, FASE, Soo H. Kim, MD, MPH, RPVI, FASE, James N. Kirkpatrick, MD, FASE, Allan L. Klein, MD, FASE, Jonathan R. Lindner, MD, FASE, Rick Meece, ACS, RDCS, RCIS, FASE, Carol Mitchell, PhD, RDMS, RDCS, RVT, RT(R), ACS, FASE, Tasneem Naqvi, MD, FASE, Maryellen H. Orsinelli, RN, RDCS, FASE, Andy Pellett, PhD, RCS, RDCS, FASE, Patricia A. Pellikka, MD, FASE, Sue D. Phillip, RCS, FASE, Juan Carlos Plana, MD, FASE, Vera H. Rigolin, MD, FASE, Vandana Sachdev, MD, FASE, Anita Sadeghpour, MD, FASE, Liza Y. Sanchez, RCS, FASE, Elaine Shea, ACS, RCS, RCCS, FASE, Roman M. Sniecinski, MD, FASE, Raymond F. Stainback, MD, FASE, Cynthia Taub, MD, FASE, Seth Uretsky, MD, Steven Walling, RCS, RDCS, FASE, Neil J. Weissman, MD, FASE, Susan E. Wiegers, MD, FASE, and David H. Wiener, MD, FASE.

NOTICE AND DISCLAIMER

This report is made available by ASE as a courtesy reference source for members. This report contains recommendations only and should not be used as the sole basis to make medical practice decisions or for disciplinary action against any employee. The statements and recommendations contained in this report are primarily based on the opinions of experts, rather than on scientifically verified data. ASE makes no express or implied warranties regarding the completeness or accuracy of the information in this report, including the warranty of merchantability or fitness for a particular purpose. In no event shall ASE be liable to you, your patients, or any other third parties for any decision made or action taken by you or such other parties in reliance on this information. Nor does your use of this information constitute the offering of medical advice by ASE or create any physician-patient relationship between ASE and your patients or anyone else.

REFERENCES

1. Nishimura RA, Otto CM, Bonow RO, Carabello BA, Erwin JP 3rd, Guyton RA, et al. 2014 AHA/ACC guideline for the management of

- patients with valvular heart disease: executive summary: a report of the American College of Cardiology/American Heart Association Task Force on Practice Guidelines. *J Am Coll Cardiol* 2014;63:2438-88.
2. Zoghbi WA, Enriquez-Sarano M, Foster E, Grayburn PA, Kraft CD, Levine RA, et al. Recommendations for evaluation of the severity of native valvular regurgitation with two-dimensional and Doppler echocardiography. *J Am Soc Echocardiogr* 2003;16:777-802.
 3. Lang RM, Badano LP, Tsang W, Adams DH, Agricola E, Buck T, et al. EAE/ASE recommendations for image acquisition and display using three-dimensional echocardiography. *J Am Soc Echocardiogr* 2012;25:3-46.
 4. Lang RM, Tsang W, Weinert L, Mor-Avi V, Chandra S. Valvular heart disease. The value of 3-dimensional echocardiography. *J Am Coll Cardiol* 2011;58:1933-44.
 5. American College of Cardiology Foundation Task Force on Expert Consensus, Hundley WG, Bluemke DA, Finn JP, Flamm SD, Fogel MA, et al. ACCF/ACR/AHA/NASCI/SCMR 2010 expert consensus document on cardiovascular magnetic resonance: a report of the American College of Cardiology Foundation Task Force on Expert Consensus Documents. *J Am Coll Cardiol* 2010;55:2614-62.
 6. Schulz-Menger J, Bluemke DA, Bremerich J, Flamm SD, Fogel MA, Friedrich MG, et al. Standardized image interpretation and post processing in cardiovascular magnetic resonance: Society for Cardiovascular Magnetic Resonance (SCMR) board of trustees task force on standardized post processing. *J Cardiovasc Magn Reson* 2013;15:35.
 7. Enriquez-Sarano M, Avierinos JF, Messika-Zeitoun D, Detaint D, Capps M, Nkomo V, et al. Quantitative determinants of the outcome of asymptomatic mitral regurgitation. *N Engl J Med* 2005;352:875-83.
 8. Detaint D, Messika-Zeitoun D, Maalouf J, Tribouilloy C, Mahoney DW, Tajik AJ, et al. Quantitative echocardiographic determinants of clinical outcome in asymptomatic patients with aortic regurgitation: a prospective study. *JACC Cardiovasc Imaging* 2008;1:1-11.
 9. Topitsky Y, Nkomo VT, Vatury O, Michelena HI, Letourneau T, Suri RM, et al. Clinical outcome of isolated tricuspid regurgitation. *JACC Cardiovasc Imaging* 2014;7:1185-94.
 10. Grigioni F, Enriquez-Sarano M, Zehr KJ, Bailey KR, Tajik AJ. Ischemic mitral regurgitation: long-term outcome and prognostic implications with quantitative Doppler assessment. *Circulation* 2001;103:1759-64.
 11. Sandler H, Dodge HT, Hay RE, Rackley CE. Quantitation of valvular insufficiency in man by angiocardiology. *Am Heart J* 1963;65:501-13.
 12. Ben Zekry S, Nagueh SF, Little SH, Quinones MA, McCulloch ML, Karanbir S, et al. Comparative accuracy of two- and three-dimensional transthoracic and transesophageal echocardiography in identifying mitral valve pathology in patients undergoing mitral valve repair: initial observations. *J Am Soc Echocardiogr* 2011;24:1079-85.
 13. Mantovani F, Clavel MA, Michelena HI, Suri RM, Schaff HV, Enriquez-Sarano M. Comprehensive imaging in women with organic mitral regurgitation: implications for clinical outcome. *JACC Cardiovasc Imaging* 2016;9:388-96.
 14. Thomson HL, Basmadjian AJ, Rainbird AJ, Razavi M, Avierinos JF, Pellikka PA, et al. Contrast echocardiography improves the accuracy and reproducibility of left ventricular remodeling measurements: a prospective, randomly assigned, blinded study. *J Am Coll Cardiol* 2001;38:867-75.
 15. Mor-Avi V, Jenkins C, Kuhl HP, Nesser HJ, Marwick T, Franke A, et al. Real-time 3-dimensional echocardiographic quantification of left ventricular volumes: multicenter study for validation with magnetic resonance imaging and investigation of sources of error. *JACC Cardiovasc Imaging* 2008;1:413-23.
 16. Tribouilloy C, Shen WF, Quere JP, Rey JL, Choquet D, Dufosse H, et al. Assessment of severity of mitral regurgitation by measuring regurgitant jet width at its origin with transesophageal Doppler color flow imaging. *Circulation* 1992;85:1248-53.
 17. Thomas JD, Liu CM, Flachskampf FA, O'Shea JP, Davidoff R, Weyman AE. Quantification of jet flow by momentum analysis. An in vitro color Doppler flow study. *Circulation* 1990;81:247-59.
 18. Blevins R. *Applied Fluid Dynamics Handbook*. New York: Van Nostrand Reinhold; 1984.
 19. Chen CG, Thomas JD, Anconina J, Harrigan P, Mueller L, Picard MH, et al. Impact of impinging wall jet on color Doppler quantification of mitral regurgitation. *Circulation* 1991;84:712-20.
 20. Enriquez-Sarano M, Bailey KR, Seward JB, Tajik AJ, Krohn MJ, Mays JM. Quantitative Doppler assessment of valvular regurgitation. *Circulation* 1993;87:841-8.
 21. Stewart WJ, Currie PJ, Salcedo EE, Lytle BW, Gill CC, Schiavone WA, et al. Intraoperative Doppler color flow mapping for decision-making in valve repair for mitral regurgitation. Technique and results in 100 patients. *Circulation* 1990;81:556-66.
 22. Mascherbauer J, Rosenhek R, Bittner B, Binder J, Simon P, Maurer G, et al. Doppler echocardiographic assessment of valvular regurgitation severity by measurement of the vena contracta: an in vitro validation study. *J Am Soc Echocardiogr* 2005;18:999-1006.
 23. Grayburn PA, Appleton CP, DeMaria AN, Greenberg B, Lowes B, Oh J, et al. Echocardiographic predictors of morbidity and mortality in patients with advanced heart failure: the Beta-blocker Evaluation of Survival Trial (BEST). *J Am Coll Cardiol* 2005;45:1064-71.
 24. Hall SA, Brickner ME, Willett DL, Irani WN, Afridi I, Grayburn PA. Assessment of mitral regurgitation severity by Doppler color flow mapping of the vena contracta. *Circulation* 1997;95:636-42.
 25. Enriquez-Sarano M, Seward JB, Bailey KR, Tajik AJ. Effective regurgitant orifice area: a noninvasive Doppler development of an old hemodynamic concept. *J Am Coll Cardiol* 1994;23:443-51.
 26. Baumgartner H, Schima H, Kuhn P. Value and limitations of proximal jet dimensions for the quantitation of valvular regurgitation: an in vitro study using Doppler flow imaging. *J Am Soc Echocardiogr* 1991;4:57-66.
 27. Kizilbash AM, Willett DL, Brickner ME, Heinle SK, Grayburn PA. Effects of afterload reduction on vena contracta width in mitral regurgitation. *J Am Coll Cardiol* 1998;32:427-31.
 28. Tribouilloy CM, Enriquez-Sarano M, Bailey KR, Seward JB, Tajik AJ. Assessment of severity of aortic regurgitation using the width of the vena contracta: a clinical color Doppler imaging study. *Circulation* 2000;102:558-64.
 29. Tribouilloy CM, Enriquez-Sarano M, Bailey KR, Tajik AJ, Seward JB. Quantification of tricuspid regurgitation by measuring the width of the vena contracta with Doppler color flow imaging: a clinical study. *J Am Coll Cardiol* 2000;36:472-8.
 30. Zeng X, Levine RA, Hua L, Morris EL, Kang Y, Flaherty M, et al. Diagnostic value of vena contracta area in the quantification of mitral regurgitation severity by color Doppler 3D echocardiography. *Circ Cardiovasc Imaging* 2011;4:506-13.
 31. Little SH, Pirat B, Kumar R, Igo SR, McCulloch M, Hartley CJ, et al. Three-dimensional color Doppler echocardiography for direct measurement of vena contracta area in mitral regurgitation: in vitro validation and clinical experience. *JACC Cardiovasc Imaging* 2008;1:695-704.
 32. Yosefy C, Hung J, Chua S, Vaturi M, Ton-Nu TT, Handschumacher MD, et al. Direct measurement of vena contracta area by real-time 3-dimensional echocardiography for assessing severity of mitral regurgitation. *Am J Cardiol* 2009;104:978-83.
 33. Shanks M, Siebelink HM, Delgado V, van de Veire NR, Ng AC, Sieders A, et al. Quantitative assessment of mitral regurgitation: comparison between three-dimensional transesophageal echocardiography and magnetic resonance imaging. *Circ Cardiovasc Imaging* 2010;3:694-700.
 34. Bargiggia GS, Tronconi L, Sahn DJ, Recusani F, Raisaro A, De Servi S, et al. A new method for quantitation of mitral regurgitation based on color flow Doppler imaging of flow convergence proximal to regurgitant orifice. *Circulation* 1991;84:1481-9.
 35. Tribouilloy C, Shen WF, Rey JL, Adam MC, Lesbre JP. Mitral to aortic velocity-time integral ratio. A non-geometric pulsed-Doppler regurgitant index in isolated pure mitral regurgitation. *Eur Heart J* 1994;15:1335-9.
 36. Tribouilloy C, Avinee P, Shen WF, Rey JL, Slama M, Lesbre JP. End diastolic flow velocity just beneath the aortic isthmus assessed by pulsed

- Doppler echocardiography: a new predictor of the aortic regurgitant fraction. *Br Heart J* 1991;65:37-40.
37. Enriquez-Sarano M, Dujardin KS, Tribouilloy CM, Seward JB, Yoganathan AP, Bailey KR, et al. Determinants of pulmonary venous flow reversal in mitral regurgitation and its usefulness in determining the severity of regurgitation. *Am J Cardiol* 1999;83:535-41.
 38. Klein AL, Obarski TP, Stewart WJ, Casale PN, Pearce GL, Husbands K, et al. Transesophageal Doppler echocardiography of pulmonary venous flow: a new marker of mitral regurgitation severity. *J Am Coll Cardiol* 1991;18:518-26.
 39. Pennestri F, Loperfido F, Salvatori MP, Mongiardo R, Ferrazza A, Guccione P, et al. Assessment of tricuspid regurgitation by pulsed Doppler ultrasonography of the hepatic veins. *Am J Cardiol* 1984;54:363-8.
 40. Chen M, Luo H, Miyamoto T, Atar S, Kobal S, Rahban M, et al. Correlation of echo-Doppler aortic valve regurgitation index with angiographic aortic regurgitation severity. *Am J Cardiol* 2003;92:634-5.
 41. Schwammenthal E, Chen C, Benning F, Block M, Breithardt G, Levine RA. Dynamics of mitral regurgitant flow and orifice area. Physiologic application of the proximal flow convergence method: clinical data and experimental testing. *Circulation* 1994;90:307-22.
 42. Grose R, Strain J, Cohen MV. Pulmonary arterial V waves in mitral regurgitation: clinical and experimental observations. *Circulation* 1984;69:214-22.
 43. Pizzarello RA, Turnier J, Padmanabhan VT, Goldman MA, Tortolani AJ. Left atrial size, pressure, and V wave height in patients with isolated, severe, pure mitral regurgitation. *Cathet Cardiovasc Diagn* 1984;10:445-54.
 44. Ishii M, Jones M, Shiota T, Yamada I, Heinrich RS, Holcomb SR, et al. What is the validity of continuous wave Doppler grading of aortic regurgitation severity? A chronic animal model study. *J Am Soc Echocardiogr* 1998;11:332-7.
 45. Topilsky Y, Michelena H, Bichara V, Maalouf J, Mahoney DW, Enriquez-Sarano M. Mitral valve prolapse with mid-late systolic mitral regurgitation: pitfalls of evaluation and clinical outcome compared with holosystolic regurgitation. *Circulation* 2012;125:1643-51.
 46. Rokey R, Sterling LL, Zoghbi WA, Sartori MP, Limacher MC, Kuo LC, et al. Determination of regurgitant fraction in isolated mitral or aortic regurgitation by pulsed Doppler two-dimensional echocardiography. *J Am Coll Cardiol* 1986;7:1273-8.
 47. Lewis JF, Kuo LC, Nelson JG, Limacher MC, Quinones MA. Pulsed Doppler echocardiographic determination of stroke volume and cardiac output: clinical validation of two new methods using the apical window. *Circulation* 1984;70:425-31.
 48. Thavendiranathan P, Liu S, Datta S, Walls M, Nitinunu A, Van Houten T, et al. Automated quantification of mitral inflow and aortic outflow stroke volumes by three-dimensional real-time volume color-flow Doppler transthoracic echocardiography: comparison with pulsed-wave Doppler and cardiac magnetic resonance imaging. *J Am Soc Echocardiogr* 2012;25:56-65.
 49. Blumlein S, Bouchard A, Schiller NB, Dae M, Byrd BF 3rd, Ports T, et al. Quantitation of mitral regurgitation by Doppler echocardiography. *Circulation* 1986;74:306-14.
 50. Lang RM, Badano LP, Mor-Avi V, Afilalo J, Armstrong A, Ernande L, et al. Recommendations for cardiac chamber quantification by echocardiography in adults: an update from the American Society of Echocardiography and the European Association of Cardiovascular Imaging. *J Am Soc Echocardiogr* 2015;28:1-3914.
 51. Hundley WG, Kizilbash AM, Afridi I, Franco F, Peshock RM, Grayburn PA. Administration of an intravenous perfluorocarbon contrast agent improves echocardiographic determination of left ventricular volumes and ejection fraction: comparison with cine magnetic resonance imaging. *J Am Coll Cardiol* 1998;32:1426-32.
 52. Vandervoort PM, Rivera JM, Mele D, Palacios IF, Dinsmore RE, Weyman AE, et al. Application of color Doppler flow mapping to calculate effective regurgitant orifice area. An in vitro study and initial clinical observations. *Circulation* 1993;88:1150-6.
 53. Enriquez-Sarano M, Miller FA Jr, Hayes SN, Bailey KR, Tajik AJ, Seward JB. Effective mitral regurgitant orifice area: clinical use and pitfalls of the proximal isovelocity surface area method. *J Am Coll Cardiol* 1995;25:703-9.
 54. Tribouilloy CM, Enriquez-Sarano M, Fett SL, Bailey KR, Seward JB, Tajik AJ. Application of the proximal flow convergence method to calculate the effective regurgitant orifice area in aortic regurgitation. *J Am Coll Cardiol* 1998;32:1032-9.
 55. Rivera M, Vandervoort PM, Mele D, Siu S, Morris E, Weyman AE, et al. Quantification of tricuspid regurgitation by means of the proximal flow convergence method: a clinical study. *Am Heart J* 1994;127:1354-62.
 56. Rivera JM, Vandervoort PM, Thoreau DH, Levine RA, Weyman AE, Thomas JD. Quantification of mitral regurgitation with the proximal flow convergence method: a clinical study. *Am Heart J* 1992;124:1289-96.
 57. Buck T, Plicht B, Kahlert P, Schenk IM, Hunold P, Erbel R. Effect of dynamic flow rate and orifice area on mitral regurgitant stroke volume quantification using the proximal isovelocity surface area method. *J Am Coll Cardiol* 2008;52:767-78.
 58. Hung J, Otsuji Y, Handschumacher MD, Schwammenthal E, Levine RA. Mechanism of dynamic regurgitant orifice area variation in functional mitral regurgitation: physiologic insights from the proximal flow convergence technique. *J Am Coll Cardiol* 1999;33:538-45.
 59. Enriquez-Sarano M, Sinak LJ, Tajik AJ, Bailey KR, Seward JB. Changes in effective regurgitant orifice throughout systole in patients with mitral valve prolapse. A clinical study using the proximal isovelocity surface area method. *Circulation* 1995;92:2951-8.
 60. Pu M, Vandervoort PM, Griffin BP, Leung DY, Stewart WJ, Cosgrove DM 3rd, et al. Quantification of mitral regurgitation by the proximal convergence method using transesophageal echocardiography. Clinical validation of a geometric correction for proximal flow constraint. *Circulation* 1995;92:2169-77.
 61. Matsumura Y, Fukuda S, Tran H, Greenberg NL, Agler DA, Wada N, et al. Geometry of the proximal isovelocity surface area in mitral regurgitation by 3-dimensional color Doppler echocardiography: difference between functional mitral regurgitation and prolapse regurgitation. *Am Heart J* 2008;155:231-8.
 62. Iwakura K, Ito H, Kawano S, Okamura A, Kurotobi T, Date M, et al. Comparison of orifice area by transthoracic three-dimensional Doppler echocardiography versus proximal isovelocity surface area (PISA) method for assessment of mitral regurgitation. *Am J Cardiol* 2006;97:1630-7.
 63. Mitter SS, Wagner GJ, Barker AJ, Markl M, Thomas JD. Impact of assuming a circular orifice on flow error through elliptical regurgitant orifices: a computational fluid dynamics (CFD) analysis. *Circulation* 2015;132:A16560.
 64. Simpson IA, Shiota T, Gharib M, Sahn DJ. Current status of flow convergence for clinical applications: is it a leaning tower of "PISA"? *J Am Coll Cardiol* 1996;27:504-9.
 65. Yosefy C, Levine RA, Solis J, Vaturi M, Handschumacher MD, Hung J. Proximal flow convergence region as assessed by real-time 3-dimensional echocardiography: challenging the hemispheric assumption. *J Am Soc Echocardiogr* 2007;20:389-96.
 66. Little SH, Igo SR, Pirat B, McCulloch M, Hartley CJ, Nose Y, et al. In vitro validation of real-time three-dimensional color Doppler echocardiography for direct measurement of proximal isovelocity surface area in mitral regurgitation. *Am J Cardiol* 2007;99:1440-7.
 67. Thavendiranathan P, Liu S, Datta S, Rajagopalan S, Ryan T, Igo SR, et al. Quantification of chronic functional mitral regurgitation by automated 3-dimensional peak and integrated proximal isovelocity surface area and stroke volume techniques using real-time 3-dimensional volume color Doppler echocardiography: in vitro and clinical validation. *Circ Cardiovasc Imaging* 2013;6:125-33.
 68. Carr JC, Simonetti O, Bundy J, Li D, Pereles S, Finn JP. Cine MR angiography of the heart with segmented true fast imaging with steady-state precession. *Radiology* 2001;219:828-34.

69. Kramer CM, Barkhausen J, Flamm SD, Kim RJ, Nagel E, the Society for Cardiovascular Magnetic Resonance Board of Trustees Task Force on Standardized Protocols. Standardized cardiovascular magnetic resonance (CMR) protocols 2013 update. *J Cardiovasc Magn Reson* 2013;15:91.
70. Hori Y, Yamada N, Higashi M, Hirai N, Nakatani S. Rapid evaluation of right and left ventricular function and mass using real-time true-FISP cine MR imaging without breath-hold: comparison with segmented true-FISP cine MR imaging with breath-hold. *J Cardiovasc Magn Reson* 2003;5:439-50.
71. Hudsmith LE, Petersen SE, Francis JM, Robson MD, Neubauer S. Normal human left and right ventricular and left atrial dimensions using steady state free precession magnetic resonance imaging. *J Cardiovasc Magn Reson* 2005;7:775-82.
72. Maceira AM, Cosin-Sales J, Roughton M, Prasad SK, Pennell DJ. Reference left atrial dimensions and volumes by steady state free precession cardiovascular magnetic resonance. *J Cardiovasc Magn Reson* 2010;12:65.
73. Gleeson TG, Mwangi I, Horgan SJ, Craddock A, Fitzpatrick P, Murray JG. Steady-state free-precession (SSFP) cine MRI in distinguishing normal and bicuspid aortic valves. *J Magn Reson Imaging* 2008;28:873-8.
74. Evans AJ, Blinder RA, Herfkens RJ, Spritzer CE, Kuethe DO, Fram EK, et al. Effects of turbulence on signal intensity in gradient echo images. *Invest Radiol* 1988;23:512-8.
75. Krombach GA, Kuhl H, Bucker A, Mahnken AH, Spuntrup E, Lipke C, et al. Cine MR imaging of heart valve dysfunction with segmented true fast imaging with steady state free precession. *J Magn Reson Imaging* 2004;19:59-67.
76. Debl K, Djavdani B, Buchner S, Heinicke N, Fredersdorf S, Haimerl J, et al. Assessment of the anatomic regurgitant orifice in aortic regurgitation: a clinical magnetic resonance imaging study. *Heart* 2008;94:e8.
77. Buchner S, Debl K, Poschenrieder F, Feuerbach S, Riegger GA, Luchner A, et al. Cardiovascular magnetic resonance for direct assessment of anatomic regurgitant orifice in mitral regurgitation. *Circ Cardiovasc Imaging* 2008;1:148-55.
78. Chatzimavroudis GP, Oshinski JN, Franch RH, Walker PG, Yoganathan AP, Pettigrew RI. Evaluation of the precision of magnetic resonance phase velocity mapping for blood flow measurements. *J Cardiovasc Magn Reson* 2001;3:11-9.
79. Hundley WG, Li HF, Hillis LD, Meshack BM, Lange RA, Willard JE, et al. Quantitation of cardiac output with velocity-encoded, phase-difference magnetic resonance imaging. *Am J Cardiol* 1995;75:1250-5.
80. Sondergaard L, Lindvig K, Hildebrandt P, Thomsen C, Stahlberg F, Joen T, et al. Quantification of aortic regurgitation by magnetic resonance velocity mapping. *Am Heart J* 1993;125:1081-90.
81. Sondergaard L, Thomsen C, Stahlberg F, Gyomoe E, Lindvig K, Hildebrandt P, et al. Mitral and aortic valvular flow: quantification with MR phase mapping. *J Magn Reson Imaging* 1992;2:295-302.
82. Gatehouse PD, Rolf MP, Graves MJ, Hofman MB, Totman J, Werner B, et al. Flow measurement by cardiovascular magnetic resonance: a multi-centre multi-vendor study of background phase offset errors that can compromise the accuracy of derived regurgitant or shunt flow measurements. *J Cardiovasc Magn Reson* 2010;12:5.
83. Wilkoff BL, Bello D, Taborsky M, Vymazal J, Kanal E, Heuer H, et al. Magnetic resonance imaging in patients with a pacemaker system designed for the magnetic resonance environment. *Heart Rhythm* 2011;8:65-73.
84. Nishimura RA, Otto CM, Bonow RO, Carabello BA, Erwin JP 3rd, Guyton RA, et al. 2014 AHA/ACC guideline for the management of patients with valvular heart disease: a report of the American College of Cardiology/American Heart Association Task Force on Practice Guidelines. *Circulation* 2014;129:e521-643.
85. Gelfand EV, Hughes S, Hauser TH, Yeon SB, Goepfert L, Kissinger KV, et al. Severity of mitral and aortic regurgitation as assessed by cardiovascular magnetic resonance: optimizing correlation with Doppler echocardiography. *J Cardiovasc Magn Reson* 2006;8:503-7.
86. Myerson SG, d'Arcy J, Mohiaddin R, Greenwood JP, Karamitsos TF, Francis JM, et al. Aortic regurgitation quantification using cardiovascular magnetic resonance: association with clinical outcome. *Circulation* 2012;126:1452-60.
87. Myerson SG, d'Arcy J, Christiansen JP, Dobson LE, Mohiaddin R, Francis JM, et al. Determination of clinical outcome in mitral regurgitation with cardiovascular magnetic resonance quantification. *Circulation* 2016;133:2287-96.
88. Expert Panel on MR Safety, Kanal E, Barkovich AJ, Bell C, Borgstede JP, Bradley WG Jr, et al. ACR guidance document on MR safe practices: 2013. *J Magn Reson Imaging* 2013;37:501-30.
89. Honey M, Gough JH, Katsaros S, Miller GA, Thuraisingham V. Left ventricular cine-angio-cardiography in the assessment of mitral regurgitation. *Br Heart J* 1969;31:596-602.
90. Baron MG. Angiocardiographic evaluation of valvular insufficiency. *Circulation* 1971;43:599-605.
91. McCarthy KP, Ring L, Rana BS. Anatomy of the mitral valve: understanding the mitral valve complex in mitral regurgitation. *Eur J Echocardiogr* 2010;11:3-9.
92. Silbiger JJ. Novel pathogenetic mechanisms and structural adaptations in ischemic mitral regurgitation. *J Am Soc Echocardiogr* 2013;26:1107-17.
93. Chikwe J, Adams DH, Su KN, Anyanwu AC, Lin HM, Goldstone AB, et al. Can three-dimensional echocardiography accurately predict complexity of mitral valve repair? *Eur J Cardiothorac Surg* 2012;41:518-24.
94. Carpentier A. Cardiac valve surgery—the "French correction". *J Thorac Cardiovasc Surg* 1983;86:323-37.
95. Freed LA, Levy D, Levine RA, Larson MG, Evans JC, Fuller DL, et al. Prevalence and clinical outcome of mitral-valve prolapse. *N Engl J Med* 1999;341:1-7.
96. Levine RA, Handschumacher MD, Sanfilippo AJ, Hagege AA, Harrigan P, Marshall JE, et al. Three-dimensional echocardiographic reconstruction of the mitral valve, with implications for the diagnosis of mitral valve prolapse. *Circulation* 1989;80:589-98.
97. Ling LH, Enriquez-Sarano M, Seward JB, Tajik AJ, Schaff HV, Bailey KR, et al. Clinical outcome of mitral regurgitation due to flail leaflet. *N Engl J Med* 1996;335:1417-23.
98. Grigioni F, Enriquez-Sarano M, Ling LH, Bailey KR, Seward JB, Tajik AJ, et al. Sudden death in mitral regurgitation due to flail leaflet. *J Am Coll Cardiol* 1999;34:2078-85.
99. Levine HJ, Gaasch WH. Vasoactive drugs in chronic regurgitant lesions of the mitral and aortic valves. *J Am Coll Cardiol* 1996;28:1083-91.
100. Grigioni F, Tribouilloy C, Avierinos JF, Barbieri A, Ferlito M, Trojette F, et al. Outcomes in mitral regurgitation due to flail leaflets a multicenter European study. *JACC Cardiovasc Imaging* 2008;1:133-41.
101. Otsuji Y, Handschumacher MD, Liel-Cohen N, Tanabe H, Jiang L, Schwammenthal E, et al. Mechanism of ischemic mitral regurgitation with segmental left ventricular dysfunction: three-dimensional echocardiographic studies in models of acute and chronic progressive regurgitation. *J Am Coll Cardiol* 2001;37:641-8.
102. Godley RW, Wann LS, Rogers EW, Feigenbaum H, Weyman AE. Incomplete mitral leaflet closure in patients with papillary muscle dysfunction. *Circulation* 1981;63:565-71.
103. Levine RA, Schwammenthal E. Ischemic mitral regurgitation on the threshold of a solution: from paradoxes to unifying concepts. *Circulation* 2005;112:745-58.
104. Gorman JH 3rd, Jackson BM, Gorman RC, Kelley ST, Gikakis N, Edmunds LH Jr. Papillary muscle discoordination rather than increased annular area facilitates mitral regurgitation after acute posterior myocardial infarction. *Circulation* 1997;96(9 Suppl):II124-7.
105. Tibayan FA, Rodriguez F, Zasio MK, Bailey L, Liang D, Daughters GT, et al. Geometric distortions of the mitral valvular-ventricular complex in chronic ischemic mitral regurgitation. *Circulation* 2003;108(Suppl 1):II116-21.
106. Kwan J, Shiota T, Agler DA, Popovic ZB, Qin JX, Gillinov MA, et al. Geometric differences of the mitral apparatus between ischemic and dilated

- cardiomyopathy with significant mitral regurgitation: real-time three-dimensional echocardiography study. *Circulation* 2003;107:1135-40.
107. Carabello BA. Ischemic mitral regurgitation and ventricular remodeling. *J Am Coll Cardiol* 2004;43:384-5.
 108. Golba K, Mokrzycki K, Drozd J, Cherniavsky A, Wrobel K, Roberts BJ, et al. Mechanisms of functional mitral regurgitation in ischemic cardiomyopathy determined by transesophageal echocardiography (from the Surgical Treatment for Ischemic Heart Failure Trial). *Am J Cardiol* 2013;112:1812-8.
 109. Kaji S, Nasu M, Yamamuro A, Tanabe K, Nagai K, Tani T, et al. Annular geometry in patients with chronic ischemic mitral regurgitation: three-dimensional magnetic resonance imaging study. *Circulation* 2005;112(9 Suppl):1409-14.
 110. Boltwood CM, Tei C, Wong M, Shah PM. Quantitative echocardiography of the mitral complex in dilated cardiomyopathy: the mechanism of functional mitral regurgitation. *Circulation* 1983;68:498-508.
 111. Gertz ZM, Raina A, Saghy L, Zado ES, Callans DJ, Marchlinski FE, et al. Evidence of atrial functional mitral regurgitation due to atrial fibrillation: reversal with arrhythmia control. *J Am Coll Cardiol* 2011;58:1474-81.
 112. van Rosendaal PJ, Katsanos S, Kamperidis V, Roos CJ, Scholte AJ, Schalij MJ, et al. New insights on Carpentier I mitral regurgitation from multidetector row computed tomography. *Am J Cardiol* 2014;114:763-8.
 113. Khoury AF, Afridi I, Quinones MA, Zoghbi WA. Transesophageal echocardiography in critically ill patients: feasibility, safety, and impact on management. *Am Heart J* 1994;127:1363-71.
 114. Yoran C, Yellin EL, Becker RM, Gabbay S, Frater RW, Sonnenblick EH. Dynamic aspects of acute mitral regurgitation: effects of ventricular volume, pressure and contractility on the effective regurgitant orifice area. *Circulation* 1979;60:170-6.
 115. Gisbert A, Souliere V, Denault AY, Bouchard D, Couture P, Pellerin M, et al. Dynamic quantitative echocardiographic evaluation of mitral regurgitation in the operating department. *J Am Soc Echocardiogr* 2006;19:140-6.
 116. Shiran A, Merdler A, Ismir E, Ammar R, Zlotnick AY, Aravot D, et al. Intraoperative transesophageal echocardiography using a quantitative dynamic loading test for the evaluation of ischemic mitral regurgitation. *J Am Soc Echocardiogr* 2007;20:690-7.
 117. Mihalatos DG, Gopal AS, Kates R, Toole RS, Bercow NR, Lamendola C, et al. Intraoperative assessment of mitral regurgitation: role of phenylephrine challenge. *J Am Soc Echocardiogr* 2006;19:1158-64.
 118. Nagueh SF, Bierig SM, Budoff MJ, Desai M, Dilisizian V, Eidem B, et al. American Society of Echocardiography clinical recommendations for multimodality cardiovascular imaging of patients with hypertrophic cardiomyopathy: endorsed by the American Society of Nuclear Cardiology, Society for Cardiovascular Magnetic Resonance, and Society of Cardiovascular Computed Tomography. *J Am Soc Echocardiogr* 2011;24:473-98.
 119. Grigg LE, Wigle ED, Williams WG, Daniel LB, Rakowski H. Transesophageal Doppler echocardiography in obstructive hypertrophic cardiomyopathy: clarification of pathophysiology and importance in intraoperative decision making. *J Am Coll Cardiol* 1992;20:42-52.
 120. Sherrid MV, Wever-Pinzon O, Shah A, Chaudhry FA. Reflections of inflections in hypertrophic cardiomyopathy. *J Am Coll Cardiol* 2009;54:212-9.
 121. Mark JB, Chetham PM. Ventricular pacing can induce hemodynamically significant mitral valve regurgitation. *Anesthesiology* 1991;74:375-7.
 122. Alizadeh A, Sanati HR, Haji-Karimi M, Yazdi AH, Rad MA, Haghjoo M, et al. Induction and aggravation of atrioventricular valve regurgitation in the course of chronic right ventricular apical pacing. *Europace* 2011;13:1587-90.
 123. Sutton MG, Plappert T, Hilpisch KE, Abraham WT, Hayes DL, Chinchoy E. Sustained reverse left ventricular structural remodeling with cardiac resynchronization at one year is a function of etiology: quantitative Doppler echocardiographic evidence from the Multicenter In-Sync Randomized Clinical Evaluation (MIRACLE). *Circulation* 2006;113:266-72.
 124. Di Biase L, Auricchio A, Mohanty P, Bai R, Kautzner J, Pieragnoli P, et al. Impact of cardiac resynchronization therapy on the severity of mitral regurgitation. *Europace* 2011;13:829-38.
 125. Onishi T, Onishi T, Marek JJ, Ahmed M, Haberman SC, Oyenuga O, et al. Mechanistic features associated with improvement in mitral regurgitation after cardiac resynchronization therapy and their relation to long-term patient outcome. *Circ Heart Fail* 2013;6:685-93.
 126. van Bommel RJ, Marsan NA, Delgado V, Borleffs CJ, van Rijnsoever EP, Schalij MJ, et al. Cardiac resynchronization therapy as a therapeutic option in patients with moderate-severe functional mitral regurgitation and high operative risk. *Circulation* 2011;124:912-9.
 127. Panidis IP, Ross J, Munley B, Nestico P, Mintz GS. Diastolic mitral regurgitation in patients with atrioventricular conduction abnormalities: a common finding by Doppler echocardiography. *J Am Coll Cardiol* 1986;7:768-74.
 128. Lancellotti P, Moura L, Pierard LA, Agricola E, Popescu BA, Tribouilloy C, et al. European Association of Echocardiography recommendations for the assessment of valvular regurgitation. Part 2: mitral and tricuspid regurgitation (native valve disease). *Eur J Echocardiogr* 2010;11:307-32.
 129. Diebold B, Delouche A, Delouche P, Guglielmi JP, Dumepe P, Herment A. In vitro flow mapping of regurgitant jets. Systematic description of free jet with laser Doppler velocimetry. *Circulation* 1996;94:158-69.
 130. Altiok E, Hamada S, van Hall S, Hanenberg M, Dohmen G, Almalla M, et al. Comparison of direct planimetry of mitral valve regurgitation orifice area by three-dimensional transesophageal echocardiography to effective regurgitant orifice area obtained by proximal flow convergence method and vena contracta area determined by color Doppler echocardiography. *Am J Cardiol* 2011;107:452-8.
 131. Kahlert P, Plicht B, Schenk IM, Janosi RA, Erbel R, Buck T. Direct assessment of size and shape of noncircular vena contracta area in functional versus organic mitral regurgitation using real-time three-dimensional echocardiography. *J Am Soc Echocardiogr* 2008;21:912-21.
 132. Matsumura Y, Saracino G, Sugioka K, Tran H, Greenberg NL, Wada N, et al. Determination of regurgitant orifice area with the use of a new three-dimensional flow convergence geometric assumption in functional mitral regurgitation. *J Am Soc Echocardiogr* 2008;21:1251-6.
 133. Marsan NA, Westenberg JJ, Ypenburg C, Delgado V, van Bommel RJ, Roes SD, et al. Quantification of functional mitral regurgitation by real-time 3D echocardiography: comparison with 3D velocity-encoded cardiac magnetic resonance. *JACC Cardiovasc Imaging* 2009;2:1245-52.
 134. Biner S, Rafique A, Raffi F, Tolstrup K, Noorani O, Shiota T, et al. Reproducibility of proximal isovelocity surface area, vena contracta, and regurgitant jet area for assessment of mitral regurgitation severity. *JACC Cardiovasc Imaging* 2010;3:235-43.
 135. Grigioni F, Detaint D, Avierinos JF, Scott C, Tajik J, Enriquez-Sarano M. Contribution of ischemic mitral regurgitation to congestive heart failure after myocardial infarction. *J Am Coll Cardiol* 2005;45:260-7.
 136. Lancellotti P, Troisfontaines P, Toussaint AC, Pierard LA. Prognostic importance of exercise-induced changes in mitral regurgitation in patients with chronic ischemic left ventricular dysfunction. *Circulation* 2003;108:1713-7.
 137. Rossi A, Dini FL, Faggiano P, Agricola E, Ciccoira M, Frattini S, et al. Independent prognostic value of functional mitral regurgitation in patients with heart failure. A quantitative analysis of 1256 patients with ischaemic and non-ischaemic dilated cardiomyopathy. *Heart* 2011;97:1675-80.
 138. Pu M, Prior DL, Fan X, Asher CR, Vasquez C, Griffin BP, et al. Calculation of mitral regurgitant orifice area with use of a simplified proximal convergence method: initial clinical application. *J Am Soc Echocardiogr* 2001;14:180-5.
 139. Kizilbash AM, Hundley WG, Willett DL, Franco F, Peshock RM, Grayburn PA. Comparison of quantitative Doppler with magnetic resonance imaging for assessment of the severity of mitral regurgitation. *Am J Cardiol* 1998;81:792-5.

140. Dujardin KS, Enriquez-Sarano M, Bailey KR, Nishimura RA, Seward JB, Tajik AJ. Grading of mitral regurgitation by quantitative Doppler echocardiography: calibration by left ventricular angiography in routine clinical practice. *Circulation* 1997;96:3409-15.
141. Pu M, Griffin BP, Vandervoort PM, Stewart WJ, Fan X, Cosgrove DM, et al. The value of assessing pulmonary venous flow velocity for predicting severity of mitral regurgitation: a quantitative assessment integrating left ventricular function. *J Am Soc Echocardiogr* 1999;12:736-43.
142. Grayburn PA, Foster E, Sangli C, Weissman NJ, Massaro J, Glower DG, et al. Relationship between the magnitude of reduction in mitral regurgitation severity and left ventricular and left atrial reverse remodeling after MitraClip therapy. *Circulation* 2013;128:1667-74.
143. Lancellotti P, Cosyns B, Zacharakis D, Attena E, Van Camp G, Gach O, et al. Importance of left ventricular longitudinal function and functional reserve in patients with degenerative mitral regurgitation: assessment by two-dimensional speckle tracking. *J Am Soc Echocardiogr* 2008;21:1331-6.
144. Witkowski TG, Thomas JD, Debonnaire PJ, Delgado V, Hoke U, Ewe SH, et al. Global longitudinal strain predicts left ventricular dysfunction after mitral valve repair. *Eur Heart J Cardiovasc Imaging* 2013;14:69-76.
145. Messika-Zeitoun D, Bellamy M, Avierinos JF, Breen J, Eusemann C, Rossi A, et al. Left atrial remodeling in mitral regurgitation—methodologic approach, physiological determinants, and outcome implications: a prospective quantitative Doppler-echocardiographic and electron beam-computed tomographic study. *Eur Heart J* 2007;28:1773-81.
146. Leung DY, Griffin BP, Stewart WJ, Cosgrove DM 3rd, Thomas JD, Marwick TH. Left ventricular function after valve repair for chronic mitral regurgitation: predictive value of preoperative assessment of contractile reserve by exercise echocardiography. *J Am Coll Cardiol* 1996;28:1198-205.
147. Vahanian A, Baumgartner H, Bax J, Butchart E, Dion R, Filippatos G, et al. Guidelines on the management of valvular heart disease: the Task Force on the Management of Valvular Heart Disease of the European Society of Cardiology. *Eur Heart J* 2007;28:230-68.
148. Buchner S, Poschenrieder F, Hamer OW, Jungbauer C, Resch M, Birner C, et al. Direct visualization of regurgitant orifice by CMR reveals differential asymmetry according to etiology of mitral regurgitation. *JACC Cardiovasc Imaging* 2011;4:1088-96.
149. Gabriel RS, Kerr AJ, Raffel OC, Stewart FA, Cowan BR, Occlshaw CJ. Mapping of mitral regurgitant defects by cardiovascular magnetic resonance in moderate or severe mitral regurgitation secondary to mitral valve prolapse. *J Cardiovasc Magn Reson* 2008;10:16.
150. Han Y, Peters DC, Salton CJ, Bzymek D, Nezafat R, Goddu B, et al. Cardiovascular magnetic resonance characterization of mitral valve prolapse. *JACC Cardiovasc Imaging* 2008;1:294-303.
151. Chinitz JS, Chen D, Goyal P, Wilson S, Islam F, Nguyen T, et al. Mitral apparatus assessment by delayed enhancement CMR: relative impact of infarct distribution on mitral regurgitation. *JACC Cardiovasc Imaging* 2013;6:220-34.
152. Srichai MB, Grimm RA, Stillman AE, Gillinov AM, Rodriguez LL, Lieber ML, et al. Ischemic mitral regurgitation: impact of the left ventricle and mitral valve in patients with left ventricular systolic dysfunction. *Ann Thorac Surg* 2005;80:170-8.
153. Aurigemma G, Reichek N, Schiebler M, Axel L. Evaluation of mitral regurgitation by cine magnetic resonance imaging. *Am J Cardiol* 1990;66:621-5.
154. Pflugfelder PW, Sechtem UP, White RD, Cassidy MM, Schiller NB, Higgins CB. Noninvasive evaluation of mitral regurgitation by analysis of left atrial signal loss in cine magnetic resonance. *Am Heart J* 1989;117:1113-9.
155. Hundley WG, Li HF, Willard JE, Landau C, Lange RA, Meshack BM, et al. Magnetic resonance imaging assessment of the severity of mitral regurgitation. Comparison with invasive techniques. *Circulation* 1995;92:1151-8.
156. Kon MW, Myerson SG, Moat NE, Pennell DJ. Quantification of regurgitant fraction in mitral regurgitation by cardiovascular magnetic resonance: comparison of techniques. *J Heart Valve Dis* 2004;13:600-7.
157. Fujita N, Chazouilleres AF, Hartiala JJ, O'Sullivan M, Heidenreich P, Kaplan JD, et al. Quantification of mitral regurgitation by velocity-encoded cine nuclear magnetic resonance imaging. *J Am Coll Cardiol* 1994;23:951-8.
158. Maceira AM, Prasad SK, Khan M, Pennell DJ. Reference right ventricular systolic and diastolic function normalized to age, gender and body surface area from steady-state free precession cardiovascular magnetic resonance. *Eur Heart J* 2006;27:2879-88.
159. Maceira AM, Prasad SK, Khan M, Pennell DJ. Normalized left ventricular systolic and diastolic function by steady state free precession cardiovascular magnetic resonance. *J Cardiovasc Magn Reson* 2006;8:417-26.
160. Cawley PJ, Hamilton-Craig C, Owens DS, Krieger EV, Strugnell WE, Mitsumori L, et al. Prospective comparison of valve regurgitation quantitation by cardiac magnetic resonance imaging and transthoracic echocardiography. *Circ Cardiovasc Imaging* 2013;6:48-57.
161. Uretsky S, Gillam L, Lang R, Chaudhry FA, Argulian E, Supariwala A, et al. Discordance between echocardiography and MRI in the assessment of mitral regurgitation severity: a prospective multicenter trial. *J Am Coll Cardiol* 2015;65:1078-88.
162. Lopez-Mattei JC, Ibrahim H, Shaikh KA, Little SH, Shah DJ, Maragiannis D, et al. Comparative assessment of mitral regurgitation severity by transthoracic echocardiography and cardiac magnetic resonance using an integrative and quantitative approach. *Am J Cardiol* 2016;117:264-70.
163. Grayburn PA, Carabello B, Hung J, Gillam LD, Liang D, Mack MJ, et al. Defining "severe" secondary mitral regurgitation: emphasizing an integrated approach. *J Am Coll Cardiol* 2014;64:2792-801.
164. Cioffi G, Tarantini L, De Feo S, Pulignano G, Del Sindaco D, Stefanelli C, et al. Functional mitral regurgitation predicts 1-year mortality in elderly patients with systolic chronic heart failure. *Eur J Heart Fail* 2005;7:1112-7.
165. Marwick TH, Zoghbi WA, Narula J. Redrawing the borders: considering guideline revision in functional mitral regurgitation. *JACC Cardiovasc Imaging* 2014;7:333-5.
166. Beigel R, Siegel RJ. Should the guidelines for the assessment of the severity of functional mitral regurgitation be redefined? *JACC Cardiovasc Imaging* 2014;7:313-4.
167. Trichon BH, Felker GM, Shaw LKL, Cabell CH, O'Connor CM. Relation of frequency and severity of mitral regurgitation to survival among patients with left ventricular systolic dysfunction and heart failure. *Am J Cardiol* 2003;91:538-43.
168. Deja MA, Grayburn PA, Sun B, Rao V, She L, Krejca M, et al. Influence of mitral regurgitation repair on survival in the surgical treatment for ischemic heart failure trial. *Circulation* 2012;125:2639-48.
169. Michler RE, Smith PK, Parides MK, Ailawadi G, Thourani V, Moskowitz AJ, et al. Two-year outcomes of surgical treatment of moderate ischemic mitral regurgitation. *N Engl J Med* 2016;374:1932-41.
170. Anderson RH. Clinical anatomy of the aortic root. *Heart* 2000;84:670-3.
171. Carr JA, Savage EB. Aortic valve repair for aortic insufficiency in adults: a contemporary review and comparison with replacement techniques. *Eur J Cardiothorac Surg* 2004;25:6-15.
172. Shapira N, Fernandez J, McNicholas KW, Serra AJ, Hirschfeld K, Spagna PM, et al. Hypertrophy of nodules of Arantius and aortic insufficiency: pathophysiology and repair. *Ann Thorac Surg* 1991;51:969-72.
173. Bekeredjian R, Grayburn PA. Valvular heart disease: aortic regurgitation. *Circulation* 2005;112:125-34.
174. Michelena HI, Prakash SK, Della Corte A, Bissell MM, Anavekar N, Mathieu P, et al. Bicuspid aortic valve: identifying knowledge gaps and rising to the challenge from the International Bicuspid Aortic Valve Consortium (BAVCon). *Circulation* 2014;129:2691-704.
175. Sievers HH, Schmidtke C. A classification system for the bicuspid aortic valve from 304 surgical specimens. *J Thorac Cardiovasc Surg* 2007;133:1226-33.

176. Hahn RT, Roman MJ, Mogtader AH, Devereux RB. Association of aortic dilation with regurgitant, stenotic and functionally normal bicuspid aortic valves. *J Am Coll Cardiol* 1992;19:283-8.
177. Detaint D, Michelena HI, Nkomo VT, Vahanian A, Jondeau G, Sarano ME. Aortic dilatation patterns and rates in adults with bicuspid aortic valves: a comparative study with Marfan syndrome and degenerative aortopathy. *Heart* 2014;100:126-34.
178. Roberts WC, Vowels TJ, Ko JM, Filardo G, Hebel JF Jr, Henry AC, et al. Comparison of the structure of the aortic valve and ascending aorta in adults having aortic valve replacement for aortic stenosis versus for pure aortic regurgitation and resection of the ascending aorta for aneurysm. *Circulation* 2011;123:896-903.
179. Chan KL, Stinson WA, Veinot JP. Reliability of transthoracic echocardiography in the assessment of aortic valve morphology: pathological correlation in 178 patients. *Can J Cardiol* 1999;15:48-52.
180. El Khoury G, Glineur D, Rubay J, Verhelst R, d'Acoz Y, Poncelet A, et al. Functional classification of aortic root/valve abnormalities and their correlation with etiologies and surgical procedures. *Curr Opin Cardiol* 2005;20:115-21.
181. Boodhwani M, de Kerchove L, Glineur D, Poncelet A, Rubay J, Astarci P, et al. Repair-oriented classification of aortic insufficiency: impact on surgical techniques and clinical outcomes. *J Thorac Cardiovasc Surg* 2009;137:286-94.
182. Shiota T, Jones M, Agler DA, McDonald RW, Marcella CP, Qin JX, et al. New echocardiographic windows for quantitative determination of aortic regurgitation volume using color Doppler flow convergence and vena contracta. *Am J Cardiol* 1999;83:1064-8.
183. Griffin BP, Flachskampf FA, Siu A, Weyman AE, Thomas JD. The effects of regurgitant orifice size, chamber compliance, and systemic vascular resistance on aortic regurgitant velocity slope and pressure half-time. *Am Heart J* 1991;122:1049-56.
184. Griffin BP, Flachskampf FA, Reimold SC, Lee RT, Thomas JD. Relationship of aortic regurgitant velocity slope and pressure half-time to severity of aortic regurgitation under changing haemodynamic conditions. *Eur Heart J* 1994;15:681-5.
185. Reynolds HR, Jagen MA, Tunick PA, Kronzon I. Sensitivity of transthoracic versus transesophageal echocardiography for the detection of native valve vegetations in the modern era. *J Am Soc Echocardiogr* 2003;16:67-70.
186. Roldan CA, Qualls CR, Sopko KS, Sibbitt WL Jr. Transthoracic versus transesophageal echocardiography for detection of Libman-Sacks endocarditis: a randomized controlled study. *J Rheumatol* 2008;35:224-9.
187. La Canna G, Maisano F, De Michele L, Grimaldi A, Grassi F, Capritti E, et al. Determinants of the degree of functional aortic regurgitation in patients with anatomically normal aortic valve and ascending thoracic aorta aneurysm. *Transesophageal Doppler echocardiography study. Heart* 2009;95:130-6.
188. Keane MG, Wiegers SE, Yang E, Ferrari VZ, St John Sutton MG, Bavaria JE. Structural determinants of aortic regurgitation in type A dissection and the role of valvular resuspension as determined by intraoperative transesophageal echocardiography. *Am J Cardiol* 2000;85:604-10.
189. Thorsgard ME, Morrisette GJ, Sun B, Eales F, Kshetry V, Flavin T, et al. Impact of intraoperative transesophageal echocardiography on acute type-A aortic dissection. *J Cardiothorac Vasc Anesth* 2014;28:1203-7.
190. Otani K, Takeuchi M, Kaku K, Sugeng L, Yoshitani H, Haruki N, et al. Assessment of the aortic root using real-time 3D transesophageal echocardiography. *Circ J* 2010;74:2649-57.
191. Gallego Garcia de Vinuesa P, Castro A, Barquero JM, Araji O, Brunstein G, Mendez I, et al. Functional anatomy of aortic regurgitation. Role of transesophageal echocardiography in aortic valve-sparing surgery. *Rev Esp Cardiol* 2010;63:536-43.
192. le Polain de Waroux JB, Pouleur AC, Goffinet C, Vancraeynest D, Van Dyck M, Robert A, et al. Functional anatomy of aortic regurgitation: accuracy, prediction of surgical reparability, and outcome implications of transesophageal echocardiography. *Circulation* 2007;116(11 Suppl):I264-9.
193. Movsowitz HD, Levine RA, Hilgenberg AD, Isselbacher EM. Transesophageal echocardiographic description of the mechanisms of aortic regurgitation in acute type A aortic dissection: implications for aortic valve repair. *J Am Coll Cardiol* 2000;36:884-90.
194. Vanoverschelde JL, van Dyck M, Gerber B, Vancraeynest D, Melchior J, de Meester C, et al. The role of echocardiography in aortic valve repair. *Ann Cardiothorac Surg* 2013;2:65-72.
195. Roy DA, Schaefer U, Guetta V, Hildick-Smith D, Mollmann H, Dumonteil N, et al. Transcatheter aortic valve implantation for pure severe native aortic valve regurgitation. *J Am Coll Cardiol* 2013;61:1577-84.
196. Seiffert M, Bader R, Kappert U, Rastan A, Krapf S, Bleiziffer S, et al. Initial German experience with transapical implantation of a second-generation transcatheter heart valve for the treatment of aortic regurgitation. *JACC Cardiovasc Interv* 2014;7:1168-74.
197. Chatzimavroudis GP, Oshinski JN, Franch RH, Pettigrew RI, Walker PG, Yoganathan AP. Quantification of the aortic regurgitant volume with magnetic resonance phase velocity mapping: a clinical investigation of the importance of imaging slice location. *J Heart Valve Dis* 1998;7:94-101.
198. Fratz S, Chung T, Greil GF, Samyn MM, Taylor AM, Valsangiacomo Buechel ER, et al. Guidelines and protocols for cardiovascular magnetic resonance in children and adults with congenital heart disease: SCMR expert consensus group on congenital heart disease. *J Cardiovasc Magn Reson* 2013;15:51.
199. Chatzimavroudis GP, Walker PG, Oshinski JN, Franch RH, Pettigrew RI, Yoganathan AP. Slice location dependence of aortic regurgitation measurements with MR phase velocity mapping. *Magn Reson Med* 1997;37:545-51.
200. Kilner PJ, Gatehouse PD, Firmin DN. Flow measurement by magnetic resonance: a unique asset worth optimising. *J Cardiovasc Magn Reson* 2007;9:723-8.
201. Dulce MC, Mostbeck GH, O'Sullivan M, Cheitlin M, Caputo GR, Higgins CB. Severity of aortic regurgitation: interstudy reproducibility of measurements with velocity-encoded cine MR imaging. *Radiology* 1992;185:235-40.
202. Honda N, Machida K, Hashimoto M, Mamiya T, Takahashi T, Kamano T, et al. Aortic regurgitation: quantitation with MR imaging velocity mapping. *Radiology* 1993;186:189-94.
203. Ley S, Eichhorn J, Ley-Zaporozhan J, Ulmer H, Schenk JP, Kauczor HU, et al. Evaluation of aortic regurgitation in congenital heart disease: value of MR imaging in comparison to echocardiography. *Pediatr Radiol* 2007;37:426-36.
204. Iwamoto Y, Inage A, Tomlinson G, Lee KJ, Grosse-Wortmann L, Seed M, et al. Direct measurement of aortic regurgitation with phase-contrast magnetic resonance is inaccurate: proposal of an alternative method of quantification. *Pediatr Radiol* 2014;44:1358-69.
205. Sechtem U, Pflugfelder PW, Cassidy MM, White RD, Cheitlin MD, Schiller NB, et al. Mitral or aortic regurgitation: quantification of regurgitant volumes with cine MR imaging. *Radiology* 1988;167:425-30.
206. Neuhold A, Globits S, Frank H, Glogar D, Mayr H, Stiskal M, et al. Cine-MR for the quantification of regurgitation defects by a volume method. *Rofo* 1990;153:627-32.
207. Globits S, Mayr H, Frank H, Neuhold A, Glogar D. Quantification of regurgitant lesions by MRI. *Int J Card Imaging* 1990;6:109-16.
208. Bolen MA, Popovic ZB, Rajiah P, Gabriel RS, Zurick AO, Lieber ML, et al. Cardiac MR assessment of aortic regurgitation: holodiastolic flow reversal in the descending aorta helps stratify severity. *Radiology* 2011;260:98-104.
209. Nishimura RA, Otto CM, Bonow RO, Carabello BA, Erwin JP 3rd, Guyton RA, et al. 2014 AHA/ACC guideline for the management of patients with valvular heart disease: a report of the American College of Cardiology/American Heart Association Task Force on Practice Guidelines. *J Thorac Cardiovasc Surg* 2014;148:e1-132.
210. Hendel RC, Patel MR, Kramer CM, Poon M, Hendel RC, Carr JC, et al. ACCF/ACR/SCCT/SCMR/ASNC/NASCI/SCAI/SIR 2006 appropriateness criteria for cardiac computed tomography and cardiac magnetic resonance imaging: a report of the American College of Cardiology Foundation Quality Strategic Directions Committee

- Appropriateness Criteria Working Group, American College of Radiology, Society of Cardiovascular Computed Tomography, Society for Cardiovascular Magnetic Resonance, American Society of Nuclear Cardiology, North American Society for Cardiac Imaging, Society for Cardiovascular Angiography and Interventions, and Society of Interventional Radiology. *J Am Coll Cardiol* 2006;48:1475-97.
211. Behm CZ, Nath J, Foster E. Clinical correlates and mortality of hemodynamically significant tricuspid regurgitation. *J Heart Valve Dis* 2004;13:784-9.
 212. Nath J, Foster E, Heidenreich PA. Impact of tricuspid regurgitation on long-term survival. *J Am Coll Cardiol* 2004;43:405-9.
 213. Antunes MJ, Barlow JB. Management of tricuspid valve regurgitation. *Heart* 2007;93:271-6.
 214. Shah PM, Raney AA. Tricuspid valve disease. *Curr Probl Cardiol* 2008;33:47-84.
 215. Martinez RM, O'Leary PW, Anderson RH. Anatomy and echocardiography of the normal and abnormal tricuspid valve. *Cardiol Young* 2006;16(Suppl 3):4-11.
 216. Kostucki W, Vandenbossche JL, Friart A, Englert M. Pulsed Doppler regurgitant flow patterns of normal valves. *Am J Cardiol* 1986;58:309-13.
 217. Anwar AM, Geleijnse ML, Soliman OI, McGhie JS, Frowijn R, Nemes A, et al. Assessment of normal tricuspid valve anatomy in adults by real-time three-dimensional echocardiography. *Int J Cardiovasc Imaging* 2007;23:717-24.
 218. Fukuda S, Saracino G, Matsumura Y, Daimon M, Tran H, Greenberg NL, et al. Three-dimensional geometry of the tricuspid annulus in healthy subjects and in patients with functional tricuspid regurgitation: a real-time, 3-dimensional echocardiographic study. *Circulation* 2006;114(1 Suppl):I492-8.
 219. Rogers JH, Bolling SF. The tricuspid valve: current perspective and evolving management of tricuspid regurgitation. *Circulation* 2009;119:2718-25.
 220. Mahmood F, Kim H, Chaudary B, Bergman R, Matyal R, Gerstle J, et al. Tricuspid annular geometry: a three-dimensional transesophageal echocardiographic study. *J Cardiothorac Vasc Anesth* 2013;27:639-46.
 221. Spinner EM, Shannon P, Buice D, Jimenez JH, Veledar E, Del Nido PJ, et al. In vitro characterization of the mechanisms responsible for functional tricuspid regurgitation. *Circulation* 2011;124:920-9.
 222. Chandraratna PN, Lopez JM, Fernandez JJ, Cohen LS. Echocardiographic detection of tricuspid valve prolapse. *Circulation* 1975;51:823-6.
 223. Rippe JM, Angoff G, Sloss LJ, Wynne J, Alpert JS. Multiple floppy valves: an echocardiographic syndrome. *Am J Med* 1979;66:817-24.
 224. Schlamowitz RA, Gross S, Keating E, Pitt W, Mazur J. Tricuspid valve prolapse: a common occurrence in the click-murmur syndrome. *J Clin Ultrasound* 1982;10:435-9.
 225. Emine BS, Murat A, Mehmet B, Mustafa K, Gokturk I. Flail mitral and tricuspid valves due to myxomatous disease. *Eur J Echocardiogr* 2008;9:304-5.
 226. van Son JA, Danielson GK, Schaff HV, Miller FA Jr. Traumatic tricuspid valve insufficiency. Experience in thirteen patients. *J Thorac Cardiovasc Surg* 1994;108:893-8.
 227. Choi JS, Kim EJ. Simultaneous rupture of the mitral and tricuspid valves with left ventricular rupture caused by blunt trauma. *Ann Thorac Surg* 2008;86:1371-3.
 228. Reddy VK, Nanda S, Bandarupalli N, Pothineni KR, Nanda NC. Traumatic tricuspid papillary muscle and chordae rupture: emerging role of three-dimensional echocardiography. *Echocardiography* 2008;25:653-7.
 229. Braverman AC, Copen SE, Mudge GH, Lee RT. Ruptured chordae tendineae of the tricuspid valve as a complication of endomyocardial biopsy in heart transplant patients. *Am J Cardiol* 1990;66:111-3.
 230. Mielniczuk L, Haddad H, Davies RA, Veinot JP. Tricuspid valve chordal tissue in endomyocardial biopsy specimens of patients with significant tricuspid regurgitation. *J Heart Lung Transplant* 2005;24:1586-90.
 231. Sloan KP, Bruce CJ, Oh JK, Rihal CS. Complications of echocardiography-guided endomyocardial biopsy. *J Am Soc Echocardiogr* 2009;22:324.e1-4.
 232. Christogiannis Z, Korantzopoulos P, Pappas K, Pitsis A. Flail septal leaflet of the tricuspid valve due to rupture of chordae tendineae ten years after pacemaker implantation. *Int J Cardiol* 2014;176:e41-6.
 233. Rudski LG, Lai WW, Afilalo J, Hua L, Handschumacher MD, Chandrasekaran K, et al. Guidelines for the echocardiographic assessment of the right heart in adults: a report from the American Society of Echocardiography endorsed by the European Association of Echocardiography, a registered branch of the European Society of Cardiology, and the Canadian Society of Echocardiography. *J Am Soc Echocardiogr* 2010;23:685-713. quiz 786-8.
 234. Chan K-L, Veinot JP. *Anatomic Basis of Echocardiographic Diagnosis*. London: Springer; 2011.
 235. Rabkin E, Aikawa M, Stone JR, Fukumoto Y, Libby P, Schoen FJ. Activated interstitial myofibroblasts express catabolic enzymes and mediate matrix remodeling in myxomatous heart valves. *Circulation* 2001;104:2525-32.
 236. Attenhofer Jost CH, Edmister WD, Julsrud PR, Dearani JA, Savas Tepe M, Warnes CA, et al. Prospective comparison of echocardiography versus cardiac magnetic resonance imaging in patients with Ebstein's anomaly. *Int J Cardiovasc Imaging* 2012;28:1147-59.
 237. Shiran A, Najjar R, Adawi S, Aronson D. Risk factors for progression of functional tricuspid regurgitation. *Am J Cardiol* 2014;113:995-1000.
 238. Pennell DJ. Ventricular volume and mass by CMR. *J Cardiovasc Magn Reson* 2002;4:507-13.
 239. James SH, Wald R, Wintersperger BJ, Jimenez-Juan L, Deva D, Crean M, et al. Accuracy of right and left ventricular functional assessment by short-axis vs axial cine steady-state free-precession magnetic resonance imaging: inpatient correlation with main pulmonary artery and ascending aorta phase-contrast flow measurements. *Can Assoc Radiol J* 2013;64:213-9.
 240. Alfakih K, Plein S, Thiele H, Jones T, Ridgway JP, Sivananthan MU. Normal human left and right ventricular dimensions for MRI as assessed by turbo gradient echo and steady-state free precession imaging sequences. *J Magn Reson Imaging* 2003;17:323-9.
 241. Sugeng L, Weinert L, Lang RM. Real-time 3-dimensional color Doppler flow of mitral and tricuspid regurgitation: feasibility and initial quantitative comparison with 2-dimensional methods. *J Am Soc Echocardiogr* 2007;20:1050-7.
 242. Chen TE, Kwon SH, Enriquez-Sarano M, Wong BF, Mankad SV. Three-dimensional color Doppler echocardiographic quantification of tricuspid regurgitation orifice area: comparison with conventional two-dimensional measures. *J Am Soc Echocardiogr* 2013;26:1143-52.
 243. de Agustin JA, Viliani D, Vieira C, Islas F, Marcos-Alberca P, Gomez de Diego JJ, et al. Proximal isovelocity surface area by single-beat three-dimensional color Doppler echocardiography applied for tricuspid regurgitation quantification. *J Am Soc Echocardiogr* 2013;26:1063-72.
 244. Tribouilloy CM, Enriquez-Sarano M, Capps MA, Bailey KR, Tajik AJ. Contrasting effect of similar effective regurgitant orifice area in mitral and tricuspid regurgitation: a quantitative Doppler echocardiographic study. *J Am Soc Echocardiogr* 2002;15:958-65.
 245. van der Hulst AE, Westenberg JJ, Kroft LJ, Bax JJ, Blom NA, de Roos A, et al. Tetralogy of fallot: 3D velocity-encoded MR imaging for evaluation of right ventricular valve flow and diastolic function in patients after correction. *Radiology* 2010;256:724-34.
 246. Reddy ST, Shah M, Doyle M, Thompson DV, Williams RB, Yamrozik J, et al. Evaluation of cardiac valvular regurgitant lesions by cardiac MRI sequences: comparison of a four-valve semi-quantitative versus quantitative approach. *J Heart Valve Dis* 2013;22:491-9.
 247. Speiser U, Abas A, Henke C, Sandfort V, Jellinghaus S, Sievers B, et al. Time-resolved magnetic resonance imaging of contrast kinetics

- to identify severe tricuspid valve regurgitation. *Acta Cardiol* 2013;68:247-53.
248. Norton KI, Tong C, Glass RB, Nielsen JC. Cardiac MR imaging assessment following tetralogy of Fallot repair. *Radiographics* 2006;26:197-211.
249. Powell AJ, Maier SE, Chung T, Geva T. Phase-velocity cine magnetic resonance imaging measurement of pulsatile blood flow in children and young adults: in vitro and in vivo validation. *Pediatr Cardiol* 2000;21:104-10.
250. Choong CY, Abascal VM, Weyman J, Levine RA, Gentile F, Thomas JD, et al. Prevalence of valvular regurgitation by Doppler echocardiography in patients with structurally normal hearts by two-dimensional echocardiography. *Am Heart J* 1989;117:636-42.
251. Takao S, Miyatake K, Izumi S, Okamoto M, Kinoshita N, Nakagawa H, et al. Clinical implications of pulmonary regurgitation in healthy individuals: detection by cross sectional pulsed Doppler echocardiography. *Br Heart J* 1988;59:542-50.
252. Martinez RM, Anderson RH. Echocardiographic features of the morphologically right ventriculo-arterial junction. *Cardiol Young* 2005;15(Suppl 1):17-26.
253. Iung B, Vahanian A. Epidemiology of valvular heart disease in the adult. *Nat Rev Cardiol* 2011;8:162-72.
254. Iung B, Baron G, Butchart EG, Delahaye F, Gohlke-Barwolf C, Levang OW, et al. A prospective survey of patients with valvular heart disease in Europe: the Euro Heart Survey on Valvular Heart Disease. *Eur Heart J* 2003;24:1231-43.
255. Renella P, Aboulhosn J, Lohan DG, Jonnala P, Finn JP, Satou GM, et al. Two-dimensional and Doppler echocardiography reliably predict severe pulmonary regurgitation as quantified by cardiac magnetic resonance. *J Am Soc Echocardiogr* 2010;23:880-6.
256. Puchalski MD, Askovich B, Sower CT, Williams RV, Minich LL, Tani LY. Pulmonary regurgitation: determining severity by echocardiography and magnetic resonance imaging. *Congenit Heart Dis* 2008;3:168-75.
257. Mori Y, Rusk RA, Jones M, Li XN, Irvine T, Zetts AD, et al. A new dynamic three-dimensional digital color Doppler method for quantification of pulmonary regurgitation: validation study in an animal model. *J Am Coll Cardiol* 2002;40:1179-85.
258. Silversides CK, Veldtman GR, Crossin J, Merchant N, Webb GD, McCrindle BW, et al. Pressure half-time predicts hemodynamically significant pulmonary regurgitation in adult patients with repaired tetralogy of Fallot. *J Am Soc Echocardiogr* 2003;16:1057-62.
259. Li W, Davlouros PA, Kilner PJ, Pennell DJ, Gibson D, Henein MY, et al. Doppler-echocardiographic assessment of pulmonary regurgitation in adults with repaired tetralogy of Fallot: comparison with cardiovascular magnetic resonance imaging. *Am Heart J* 2004;147:165-72.
260. Zoghbi WA, Farmer KKL, Soto JG, Nelson JG, Quinones MA. Accurate noninvasive quantification of stenotic aortic valve area by Doppler echocardiography. *Circulation* 1986;73:452-9.
261. Valente AM, Cook S, Festa P, Ko HH, Krishnamurthy R, Taylor AM, et al. Multimodality imaging guidelines for patients with repaired tetralogy of fallot: a report from the American Society of Echocardiography: developed in collaboration with the Society for Cardiovascular Magnetic Resonance and the Society for Pediatric Radiology. *J Am Soc Echocardiogr* 2014;27:111-41.
262. Spiewak M, Biernacka EK, Malek LA, Misko J, Kowalski M, Milosz B, et al. Quantitative assessment of pulmonary regurgitation in patients with and without right ventricular tract obstruction. *Eur J Radiol* 2011;80:e164-8.
263. Wald RM, Redington AN, Pereira A, Provost YL, Paul NS, Oechslin EN, et al. Refining the assessment of pulmonary regurgitation in adults after tetralogy of Fallot repair: should we be measuring regurgitant fraction or regurgitant volume? *Eur Heart J* 2009;30:356-61.
264. Johansson B, Babu-Narayan SV, Kilner PJ. The effects of breath-holding on pulmonary regurgitation measured by cardiovascular magnetic resonance velocity mapping. *J Cardiovasc Magn Reson* 2009;11:1.
265. Rebergen SA, Chin JG, Ottenkamp J, van der Wall EE, de Roos A. Pulmonary regurgitation in the late postoperative follow-up of tetralogy of Fallot. Volumetric quantitation by nuclear magnetic resonance velocity mapping. *Circulation* 1993;88:2257-66.
266. Mercer-Rosa L, Yang W, Kutty S, Rychik J, Fogel M, Goldmuntz E. Quantifying pulmonary regurgitation and right ventricular function in surgically repaired tetralogy of Fallot: a comparative analysis of echocardiography and magnetic resonance imaging. *Circ Cardiovasc Imaging* 2012;5:637-43.
267. Klein AL, Burstow DJ, Tajik AJ, Zachariah PK, Taliencio CP, Taylor CL, et al. Age-related prevalence of valvular regurgitation in normal subjects: a comprehensive color flow examination of 118 volunteers. *J Am Soc Echocardiogr* 1990;3:54-63.
268. Muzzarelli S, Monney P, O'Brien K, Faletta F, Moccetti T, Vogt P, et al. Quantification of aortic flow by phase-contrast magnetic resonance in patients with bicuspid aortic valve. *Eur Heart J Cardiovasc Imaging* 2014;15:77-84.
269. Nordmeyer S, Riesenkampff E, Messroghli D, Kropf S, Nordmeyer J, Berger F, et al. Four-dimensional velocity-encoded magnetic resonance imaging improves blood flow quantification in patients with complex accelerated flow. *J Magn Reson Imaging* 2013;37:208-16.
270. O'Brien KR, Gabriel RS, Greiser A, Cowan BR, Young AA, Kerr AJ. Aortic valve stenotic area calculation from phase contrast cardiovascular magnetic resonance: the importance of short echo time. *J Cardiovasc Magn Reson* 2009;11:49.
271. Warnes CA, Williams RG, Bashore TM, Child JS, Connolly HM, Dearani JA, et al. ACC/AHA 2008 guidelines for the management of adults with congenital heart disease: a report of the American College of Cardiology/American Heart Association Task Force on Practice Guidelines (Writing Committee to Develop Guidelines on the Management of Adults With Congenital Heart Disease). Developed in Collaboration with the American Society of Echocardiography, Heart Rhythm Society, International Society for Adult Congenital Heart Disease, Society for Cardiovascular Angiography and Interventions, and Society of Thoracic Surgeons. *J Am Coll Cardiol* 2008;52:e143-263.
272. Thavendiranathan P, Liu S, Datta S, Walls M, Calleja A, Nitinunu A, et al. Automated 3D quantification of mitral regurgitation by real-time volume color flow Doppler: comparison with cardiac magnetic resonance imaging. *J Am Soc Echocardiogr* 2011;24:B3.
273. de Agustin JA, Marcos-Alberca P, Fernandez-Golfin C, Goncalves A, Feltes G, Nunez-Gil JJ, et al. Direct measurement of proximal isovelocity surface area by single-beat three-dimensional color Doppler echocardiography in mitral regurgitation: a validation study. *J Am Soc Echocardiogr* 2012;25:815-23.
274. Choi J, Heo R, Hong GR, Chang HJ, Sung JM, Shin SH, et al. Differential effect of 3-dimensional color Doppler echocardiography for the quantification of mitral regurgitation according to the severity and characteristics. *Circ Cardiovasc Imaging* 2014;7:535-44.
275. Choi J, Hong GR, Kim M, Cho JJ, Shim CY, Chang HJ, et al. Automatic quantification of aortic regurgitation using 3D full volume color doppler echocardiography: a validation study with cardiac magnetic resonance imaging. *Int J Cardiovasc Imaging* 2015;31:1379-89.