






Clinical Efficacy and Pathogenetic Substantiation of Adjuvant Extracorporeal Photochemotherapy in Pemphigus Vulgaris

A. V. Molochkov¹, Yu. V. Molochkova², A. V. Kildyushevsky³, O. V. Karzanov⁴
and M. G. Kartashova⁴

¹Head of the Chair of Dermatovenereology and Dermatooncology of Doctors Improvement Faculty Moscow Regional Research and Clinical Institute, Moscow, Russia

²Head of Department of Dermatovenereology of Moscow Regional Research and Clinical Institute, Moscow, Russia

³Leading Research Fellow, Surgical Hemocorrection and Detoxication Department of Moscow Regional Research and Clinical Institute, Moscow, Russia

⁴Senior Research Fellow, Department of Dermatovenereology of Moscow Regional Research and Clinical Institute, Moscow, Russia

Keywords: Pemphigus Vulgaris, Extracorporeal Photochemotherapy, Extracorporeal Blood Irradiator "Kit-A".

Abstract: This article reports on our clinical experience of application of extracorporeal photochemotherapy conducted with the ultraviolet extracorporeal blood irradiator or "KIT-A" (SJJ NPP "Cyclone-Test", Russia) as an adjuvant method in treatment of pemphigus vulgaris. We assess pathogenetic substantiation and clinical results of the proposed method as well as discussion on dynamics of immunological parameters in patients receiving actual treatment. Also current article analyzes the possibility of applying extracorporeal photochemotherapy method as an adjuvant treatment of pemphigus vulgaris with typical disease course.


1 INTRODUCTION


Pemphigus vulgaris (PV) is an autoimmune disorder of skin and mucous membranes histologically characterized by acantholysis resulting in the formation of intraepidermal blisters (Stanley, 1999). Despite PV is one of the well studied tissue-specific autoimmune diseases, autoantibodies against keratinocyte antigens are presented not only by anti-desmoglein antibodies. Number of studies have demonstrated that T-cells are also actively involved in the immunopathogenesis of this disease (Veldman, et al., 2003; Hertl & Riechers, 1999; Lin, et al., 1997). An increased number of T cells, mainly due to CD4, characterized by a Th2 - cytokine profile (IL-4, IL-6) capable to modulate B-cells pathogenic production of IgG4 are observed in PV patients peripheral blood (Edelson, 2000).


Therefore, reports on the application of extracorporeal photochemotherapy (ECP)- method proposed by R. Edelson for patients with T-cell skin lymphomas- in PV are of great interest (Edelson, et al., 1987). Currently ECP is considered as first line therapy for erythrodermic mycosis fungoides and Sézary syndrome (Scarlsbrick, et al., 2008). In clinical practice of our Institution ECP was also successfully used in patients with cutaneous T-cell lymphoma and other autoimmune dermatoses (Molochkov, et al., 2012; Molochkova, et al., 2019; Molochkov, et al., 2016; Kil'dyushevskiy A.V., et al., 2014).


The ECP method is based on the biological effect of 8-methoxypsoralene (8-MOP) and ultraviolet A (UVA) irradiation on mononuclear cells, collected by apheresis and reinfused to the patient after UVA exposure (Edelson, et al., 1987).


For a long time, until the clarification of the dendritic cells role, mechanism of ECP's therapeutic

^a <https://orcid.org/0000-0003-3388-9224>

^b <https://orcid.org/0000-0001-9021-6494>

^c <https://orcid.org/0000-0002-7079-8383>

^d <https://orcid.org/0000-0002-6176-1394>

^e <https://orcid.org/0000-0003-0376-2644>




Figure 1: Ultraviolet extracorporeal blood irradiator or "KIT-A" (SJJ NPP "Cyclone-Test", Russia).

effect has remained unclear. Thus S. Berger et al. had demonstrated not only induction of the programmed death of the tumour cell clone during ECP, but also an activation of monocytes with their subsequent transformation into the immature dendritic cells, which determined the mechanisms of immunological tolerance (Berger, et al., 2001).

Thereby the purpose of this research was to study efficiency of ECP conducted with the ultraviolet extracorporeal blood irradiator or "KIT-A" (SJJ NPP "Cyclone-Test", Russia) in treatment of PV and to explore the role of T-cell immunity in the pathogenesis of PV in order to justify development of new approaches in the PV treatment based on the extracorporeal photochemotherapy (ECP).

2 MATERIALS AND METHODS

Current study was performed on 28 PV patients (16 females, 12 males) hospitalized to the dermatovenerology department of Moscow Regional Scientific-Research Clinical Institute during acute phase of the disease and receiving ECP in combination with systemic corticosteroids. The mean age of patients was 54 years (range: 34 - 72). Diagnosis was made on the basis of a typical clinical picture of the disease and in every case was verified by cytological (acantholytic cells from the bottom of erosion), histological (intraepidermal fissures and blisters) and immunohistochemical (detection of specific antibodies of the IgG class) examinations. Duration of disease ranged from 1.5 months to 8 years (mean 1.2 years). 11 patients were suffering from the disease for more than 2 years and their condition had relapsing-remitting disease course; 17

patients were diagnosed PV for the first time. Clinical results were compared with a group of 34 patients (20 females, 14 males), mean age 58 years (range: 28-87), who received monotherapy with high doses of systemic corticosteroids. 19 patients of comparison group were diagnosed PV for the first time (duration of disease ranged from 2 month to 1.5 years), and 15 patients of comparison group had relapsing-remitting PV course with duration of disease from 1.5 to 6 years.

3 ECP TECHNIQUE APPLICATIONS

In our practice we accomplished collection of the peripheral blood mononuclear cells by apheresis, using the cell separator Haemonetics MCS + (USA) according to the PBSC (Peripheral Blood Stem Cell) protocol, with the following irradiation of the cells on the ultraviolet extracorporeal blood irradiator registered in the Federal Service for Surveillance in Healthcare of the Russian Federation (Roszdravnadzor), registration number RZN 2021/15867 "KIT-A", produced by SJJ NPP Cyclone-Test, Russia (Figure 1: a, b). The device is equipped with 72 LED emitters that generate electromagnetic energy with a wavelength of 365 ± 10 nm. The emitters are located in two planes in relation to the object - the upper and lower module with 36 emitters, respectively. Also, device is equipped with a tool for mixing of biological fluids in a plastic container and a fan to maintain the set temperature. The total power of ultraviolet radiation is not more than $5 \text{ mW} / \text{cm}^2$. The total exposure dose for 10 minutes is $3.0 \text{ J} / \text{cm}^2$. The exposure time is 7 minutes, which corresponds to a radiation

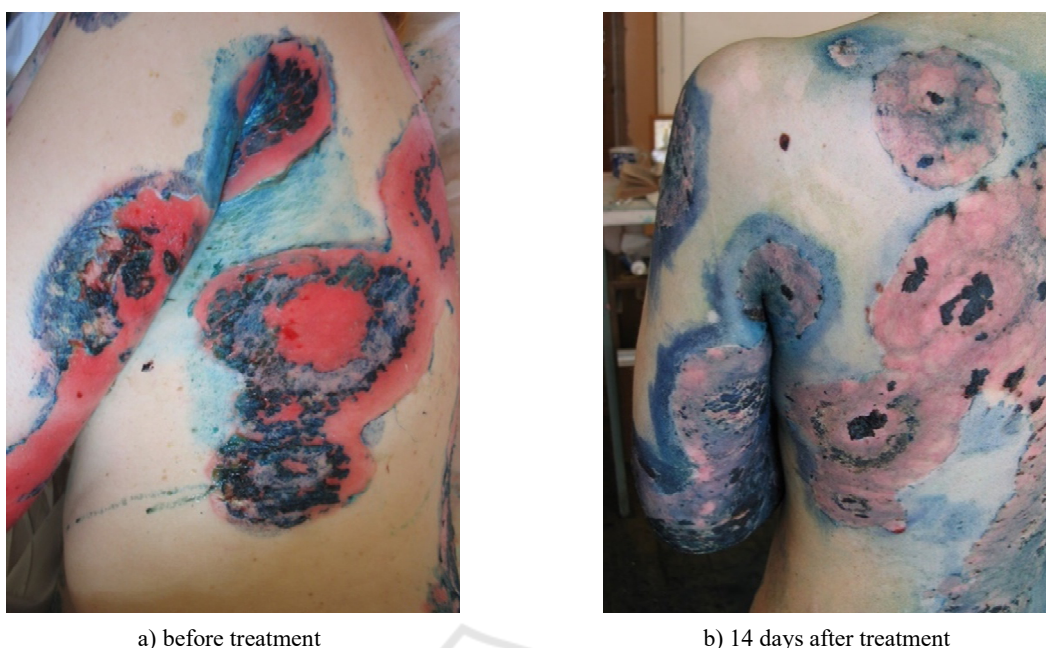

Figure 2: Female patient with pemphigus vulgaris. Widespread cutaneous process with extensive erosive surfaces. Treatment with prednisolone (100 mg / day, per os) for 10 days without clinical effect with daily appearance of new lesions. After adding the adjuvant therapy with ECP technique, new lesions ceased to develop; during the next 2 weeks was noted rapid epithelialization of erosions, which made it possible to start reducing the dose of systemic corticosteroids.

dose of 2.0 J / cm². Two hours before the ECP session patient took peroral photosensitizer (8-methoxypsoralen at the dose of 0.6 mg/kg). After the exposure to the UV irradiation, the cell suspension was reinfused to the patient for 30 min. Course of treatment included 4 sessions, procedure was carried out every 2 days.

4 RESULTS AND DISCUSSION

ECP sessions were well tolerated by all patients, no complications or side events were observed. On average, in 3-4 days after initiation of ECP therapy in every case we observed improvement of general well-being, and improvement of the cutaneous manifestations, particularly discontinuation or significant reduction of wound exudation or absence of a new lesions.

Epithelialization of epidermal defects, accompanied by the decrease in IgG deposits in the intercellular substance of the epidermis occurred in 7-14 days in all of the patients receiving treatment with ECP (Figure 2: a, b). Thus, all patients in this group had a complete clinical recovery.

In the comparison group, clinical recovery was noted in 31 (91%) patients. In the majority of patients (25 (74%)), complete epithelialization of

epidermal defects occurred in 15 – 22 days, in 6 (18%) patients, clinical recovery was achieved, but the effect was attained in a longer terms: from 1.5 to 2.5 months. In 3 (9%) patients, despite the ongoing treatment with high doses of corticosteroid drugs, clinical recovery was not achieved (1 patient had new lesions, 2 patients had persistent oral erosions).

During investigation on the effectiveness of provided treatment, it was noted that all complications and side effects in both groups (23 of the 28 patients in the control group (5 patients were lost to follow-up, because after the therapy they have left the country and 34 patients of comparison group) were associated with systemic corticosteroids. No complications associated with the ECP procedure occurred. In comparison, patients of the control group in average had 3.1 complications per patients vs 4.5 complications per patient in comparison group (Table 1). Also, in control group we didn't register such serious complications as sepsis, stroke, myocardial infarction, pneumonia, which occurred in comparison group and caused two deaths. Thus, high clinical efficacy of therapy in control group was combined with a significantly lower frequency of adverse reactions and complications (follow-up period 12-36 months).

Table 1: Identified Complications and Side Effects of Sisticemic Corticosteroid Therapy in Both Groups.

Complication	Control group (n=23)	Comparsion group (n=34)
Cushing’s syndrome	23	34
Arterial hypertension	14	19
Stroke	-	2
Myocardial infarction	-	1
Pneumonia	-	3
Sepsis	-	1
Osteoporosis	5	15
Cataract	2	4
Erosive and ulcerative lesion of the gastrointestinal tract	9	18
Diabetes	2	8
Mucosal candidiasis	6	23
Pyoderma	9	21
Erysipelas	1	1
Thrombophlebitis of the lower extremities	-	2
Total	71	152
Average (per one patient)	3.1	4.5

During the immunological study in patients with PV, there was found a high level of correlation ($r = 0.57, p < 0.05$) between the expression of the integrin adhesion molecule MAC-1 (CD11b) and natural killer (NK) cells (CD3-CD16 + CD56 +). Probably it indicates the presence of this molecule on NK cells, providing fixation of these cells on the vascular endothelium with the subsequent transendothelial migration into the lesion.

Patients with PV were characterized by the low level of CD25 expression, - α -chain of the IL-2 receptor ($1.89 \pm 1.9\%$, at the normal rate of $4.2 \pm 0.2\%$, $p < 0.05$), as well as reduced content of Treg cells with the phenotype: CD45RA + CD4 + CD25^{high}CD127^{low} / ^{neg} ($4.8 + 0.8\%$, with the normal rate of $9.6 + 0.8\%$ $p < 0.05$). The interaction of the CD25 molecule with its mediator IL-2 provides not only proliferation and differentiation of the effector cells, but primarily - activation and the proliferation of Treg cells. Functionally active Treg cells are characterized by the constitutive significant expression of the α -chain of the receptor to IL-2 (CD25), through which suppressor function of these cells is realized, providing the depletion of autoreactive T-cells by triggering the apoptosis processes in them, thus maintaining the tolerance to their own antigens. Decrease of expression of CD25 molecule leads to insufficient control and

maintenance of the immunological tolerance to the autoantigens in the periphery.

The detected immune disorders in patients with PV were considered to be pathogenetic substantiation for the immunomodulatory therapy of this disease with the application of ECP.

As a result of the ECP course, clinical recovery was achieved in all patients in 12 days on average, resulting in reduction of the starting systemic corticosteroid dosage during these period by 30% and significant decrease of the side effects and complications associated with high doses of systemic corticosteroids (Table 1).

During immunological study after ECP, there wasn't found any correlation between CD11b and CD3-CD16 + CD56 +, reflecting the absence of co-expression of the adhesion molecule on NK cells. Based on the obtained data, it could be concluded that application of ECP leads to modulation of co-expression of the leukocyte integrin adhesion molecule on the NK, which results in blockage of transendothelial migration of these cells to the lesion.

After the course of ECP in PV patients, there was also identified increased expression of the relative quantity of Treg cells (from $4.8 + 0.8\%$ to $13.3 + 2.3\%$, $p < 0.05$), which indicated the restoring of the Treg cells peripheral immunological tolerance control over the autoreactive clone of the

lymphocytes, escaped the negative selection in the thymus.

Thus, in short, it could be assumed that immunomodulatory effect of ECP in PV is based on the re-establishment of the receptor-ligand relations between immunocompetent cells, intercellular adhesion molecules and target cells - keratinocytes. An important role in this process is devoted to the restoration of the suppressor function of Treg cells in relation to the autoreactive clone of cytotoxic effector cells.

T-cell reactivity to self-antigens, as well as T- and B-cell interactions in the formation and progression of PV are not yet fully understood, therefore giving reasons for a detailed study of this problem. At the same time, the solution of cell-cell interactions is impossible without understanding of the role and significance of intercellular adhesion molecules and their ligands. The study of the function of the adhesive-ligand system in PV seems to be really important and crucial, since it concerns both the intercellular interactions of immunocompetent blood cells and the mechanisms of their transendothelial migration to the target cells (keratinocytes). Currently, the literature contains a great deal of new fundamental data relating the issues of the function and the classification of human adhesion molecules, however, their significance in the occurrence and progression of autoimmune diseases, in particular in PV, hasn't been sufficiently studied yet.

Therefore, our research indicates that the immunotherapeutic method - ECP conducted with an extracorporeal blood irradiator "KIT-A" (SJJ NPP "Cyclone-Test", Russia) is a highly effective and promising method of treatment PV, which requires deeper study for enhancing its clinical application.

5 CONCLUSION

High doses of systemic corticosteroids in combination with adjuvant therapy with cytostatics, traditionally used in PV, are quite effective in most cases, however, they are associated with the appropriate development of severe side effects such as myelosuppression, anemia, visceral cancer, hepatotoxic reactions, hemorrhagic cystitis, impaired renal function (Ahmed & Hombal, 1984; Bystryń & Steinman, 1996; Fairley et al., 1972; McDonald, 1985)

We consider that use of methods of adjuvant therapy, targeted at the main links of the immunopathogenesis of the disease to be the most promising direction for improvement of the

PV therapy. Only single observations of the mainly drug-resistant PV treatment with the use of ECP were published to date and summarized in 2020 with review of ECP use in 11 cases of a resistant PV (Knobler, et al., 2020).

Notably, this review outlines good clinical efficacy of therapy, with a minimal side effects, and the main factor supposed to limit the widespread use of current technique is the high cost of the procedure. "KIT-A" (SJJ NPP "Cyclone-Test", Russia), which is used in the described above ECP technique makes it possible to greatly reduce the cost of the procedure and thereby ensure the availability of ECP in wide clinical practice (including the treatment of uncomplicated PV variants). As for the clinical efficacy of proposed method, we obtained results, comparable to review of R. Knobler et al., but our study was conducted in patients with a typical course of the disease with the use of one ECP course, which consisted of 4 procedures (in comparison with 2-6 courses for resistant PV in R. Knobler, et al review) (Knobler, et al., 2020).

REFERENCES

- Stanley JR. Pemphigus. in: Freedberg IM Eisen AZ Wolff K Fitzpatrick's Dermatology in General Medicine. McGraw-Hill, New York, NY 1999: 654-666
- Veldman C., Stauber A., Wassmuth R., Uter W., Schuler G., Hertl M.; Dichotomy of Autoreactive Th1 and Th2 Cell Responses to Desmoglein 3 in Patients with Pemphigus Vulgaris (PV) and Healthy Carriers of PV-Associated HLA Class II Alleles. *Journal of immunology.* 2003; 170. 635-42. 10.4049/jimmunol.170.1.635
- Hertl M., Riechers R.; Analysis of the T cells that are potentially involved in autoantibody production in pemphigus vulgaris. *J Dermatol.* 1999; 26:748-752
- Lin M., Swartz S., Lopez A., Ding X., Fernandez-Vina M., Stastny P. et al.; Development, and characterization of desmoglein 3-specific T cells from patients with pemphigus vulgaris. *J Clin Invest* 1997; 99:31-40
- Edelson R.; Pemphigus — Decoding the Cellular Language of Cutaneous Autoimmunity. *The new England journal of medicine.* 2000; 343: 60-61
- Edelson R., Berger C., Gasparro F., Jegasothy B., Heald P., Wintroub B., Vonderheid E., Knobler R., Wolff K., Plewig G., et al.; Treatment of cutaneous T-cell lymphoma by extracorporeal photochemotherapy. Preliminary results. *N Engl J Med.* 1987; 316(6):297-303. doi: 10.1056/NEJM198702053160603
- Scarlsbrick J., Taylor P., Holtick U., Makar Y., Douglas K., Berlin G., Juvonen E., Marshall S.; Photopheresis Expert Group. U.K. consensus statement on the use of

- extracorporeal photopheresis for treatment of cutaneous T-cell lymphoma and chronic graft-versus-host disease. *Br J Dermatol.* 2008;158(4):659–78. doi: 10.1111/j.1365-2133.2007.08415.x
- Molochkov V.A., Kil'dyushevskii A.V., Molochkov A.V., Karzanov O.V., Iakubovskaia E.S., Fedulkina V.A.; Clinical and immunological aspects of extracorporeal photochemotherapy for psoriasis and psoriatic arthritis. *Terapevticheskii Arkhiv*, 2012; 84 (10), pp. 69-74.
- Molochkova Y.V., Molochkov V.A., Pimenova Y.A.; Lichen planus pigmentosus: report of effectiveness of extracorporeal photochemotherapy in recalcitrant case. *Hong Kong J. Dermatol. Venereol.* (2019) 27, 75-78.
- Molochkov V.A., Kil'dyushevskiy A.V., Karzanov O.V.; Treatment of the tumor stage of mycosis fungoides with extracorporeal photochemotherapy (a case descript). *Almanac of Clinical Medicine.* 2016;44(1):103-106. (In Russ.) <https://doi.org/10.18786/2072-0505-2016-44-1-103-106>
- Kil'dyushevskiy A.V., Karzanov O.V., Aleksandrova N.M.; Extra-corporeal photochemotherapy in the treatment of lymphomatoid papulosis and folliculotropic mycosis fungoides: case reports. *Almanac of Clinical Medicine.* 2014;(34):81-84. (In Russ.) <https://doi.org/10.18786/2072-0505-2014-34-81-84>
- Berger C., Xu A., Hanlon D., Lee C., Schechner J., Glusac E., Christensen I., Snyder E., Holloway V., Tigelaar R., Edelson R.; Induction of human tumor-loaded dendritic cells. *Int J Cancer.* 2001;91(4):438–47. doi: 10.1002/1097-0215(200002)9999:99993.0.CO;2-R.
- Ahmed AR, Hombal SM. Cyclophosphamide (Cytosan). A review on relevant pharmacology and clinical uses. *J Am Acad Dermatol.* 1984 Dec;11(6):1115-26. doi: 10.1016/s0190-9622(84)80193-0.
- Bystryn JC, Steinman NM. The adjuvant therapy of pemphigus. An update. *Arch Dermatol.* 1996 Feb;132(2):203-12.
- Fairley KF, Barrie JU, Johnson W. Sterility and testicular atrophy related to cyclophosphamide therapy. *Lancet.* 1972 Mar 11;1(7750):568-9. doi: 10.1016/s0140-6736(72)90358-3.
- McDonald CJ. Cytotoxic agents for use in dermatology. I. *J Am Acad Dermatol.* 1985 May;12(5 Pt 1):753-75. doi: 10.1016/s0190-9622(85)70097-7.
- European dermatology forum: Updated guidelines on the use of extracorporeal photopheresis 2020 - Part 2 R. Knobler, P. Arenberger, A. Arun, C. Assaf, M. Bagot, G. Berlin, A. Bohbot, P. Calzavara-Pinton, F. Child, A. Cho, L.E. French, A.R. Gennery, R. Gniadecki, H.P.M. Gollnick, E. Guenova, P. Jaksch, C. Jantschitsch, C. Klemke, J. Ludvigsson, E. Papadavid, J. Scarisbrick, T. Schwarz, R. Stadler, P. Wolf, J. Zic, C. Zouboulis, A. Zuckermann, H. Greinix *J Eur Acad Dermatol Venereol.* 2021 Jan; 35 (1): 27-49. Published online 2020 Sep 22. doi: 10.1111 / jdv.16889