

Compendium

Canine Brachycephalic Airway Syndrome: Surgical Management

Michelle Trappler, VMD
Kenneth W. Moore, DVM, DACVS

Abstract: Many surgical options have been described to treat various aspects of canine brachycephalic airway syndrome (BAS). This article describes the surgical management, postoperative care, and prognosis of this condition. The pathophysiology and medical therapy of BAS are described in a companion article.

For more information, please see the companion article, "Canine Brachycephalic Airway Syndrome: Pathophysiology, Diagnosis, and Nonsurgical Management"

Early intervention and correction of brachycephalic airway syndrome (BAS) abnormalities are recommended to halt progression of airway pathology. For example, it has been suggested that dogs undergo surgical correction of stenotic nares at 3 to 4 months of age.¹ Several surgical techniques exist to correct various components of BAS. Tracheostomy is recommended for patients with severe laryngeal collapse that does not respond to corrective surgical techniques.

Preoperative Considerations

Surgery should be performed in a facility with staff capable of monitoring for acute dyspnea and performing a tracheostomy in the immediate recovery period because existing pathology and intraoperative trauma to airway tissues often results in dramatic and immediate postoperative swelling of the airway. Perioperative IV corticosteroid therapy (dexamethasone: 0.05 to 0.1 mg/kg)² may help reduce the degree of airway swelling, but airway occlusion during or after extubation remains a potential complication. In one study, dogs that underwent tracheostomy had more significant postoperative complications and improved more slowly in the postoperative period

as a result of the tracheostomy procedure.³ Consequently, tracheostomy is only warranted in dogs that have complications during surgery and recovery.^{3,4} However, dogs undergoing surgical correction of BAS abnormalities should be clipped for tracheostomy, and the surgeon should be prepared to intervene if necessary.⁵

Surgical Management

The patient should be positioned in sternal recumbency with the chin resting on a well-padded surface. The maxilla should be suspended by rolled gauze or white tape hung between two IV poles or similar structures. The mandible can also be secured to the table ventrally with white tape (**FIGURE 1**). The cuff of the endotracheal

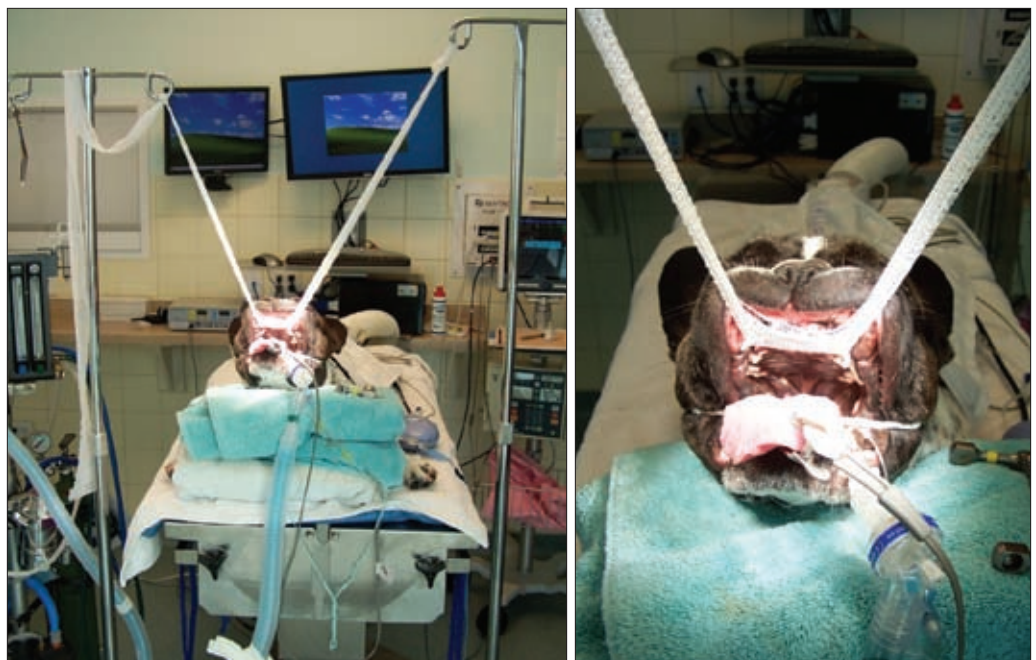


Figure 1. Patient positioning for airway surgery.

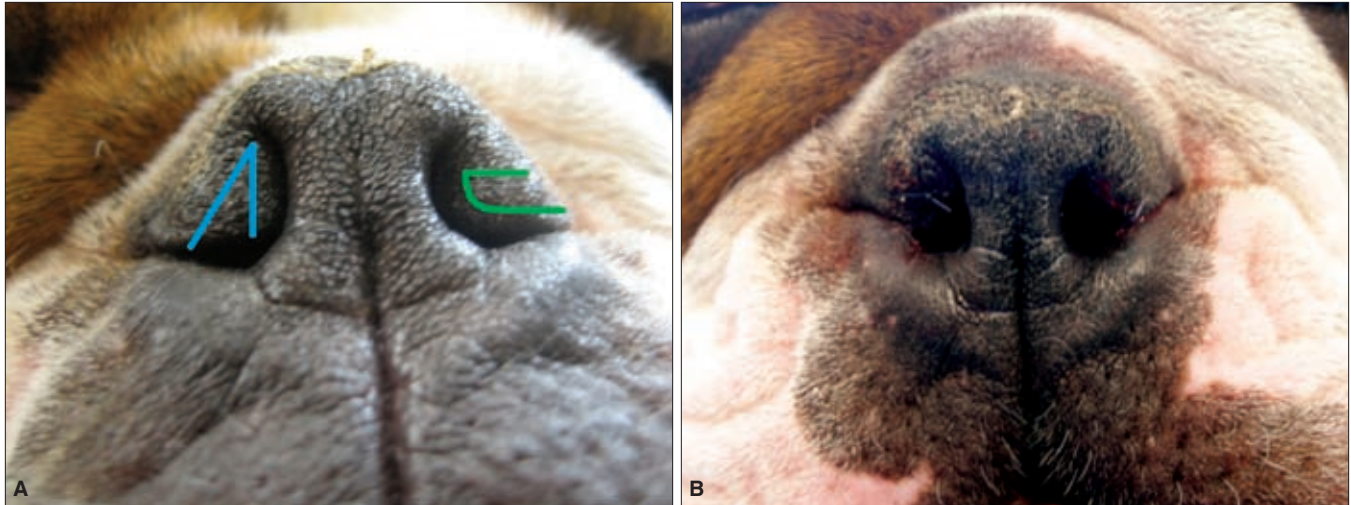


Figure 2. Stenotic nares before and after wedge resection. (A) Outline of vertical (blue) and horizontal (green) wedge incisions. The incisions should extend caudally to the alar cartilage, creating a pyramid-shaped wedge of excised tissue. (B) The same patient after vertical wedge nares resection.

tube should be checked before intubation and properly inflated and tested for leaks before preparation of the oral cavity. Gauze should be placed around the endotracheal tube at the level of the glottis to prevent fluid leakage, and the mouth should be gently wiped with gauze and a dilute antiseptic solution (Nolvadent; Fort Dodge Animal Health) or betadine.^{1,6} The nasal planum should be gently prepped with antiseptic scrub. Preoperative metoclopramide administration has been shown to decrease the incidence of intraoperative and postoperative regurgitation for patients undergoing corrective surgery for laryngeal paralysis⁷ and may be of benefit in dogs undergoing corrective surgery for BAS.

Stenotic Nares

Multiple techniques have been described for correction of stenotic nares. Regardless of the technique used, early correction is recommended to prevent progression of BAS and to improve prognosis.^{2,4,6,8} It has been suggested that dogs undergo surgical correction of stenotic nares at 3 to 4 months of age to decrease or prevent worsening of upper airway pathology.¹

The first procedure for correction of stenotic nares, amputation of the alae, was described by Trader in 1949.⁹ A recent study revisited this technique and showed excellent functional and cosmetic results in immature shih tzu puppies.⁶ Long-term follow-up showed complete resolution of the clinical signs associated with bilateral stenotic nares. Cosmetic results were reported that may be superior to results obtained with wedge resection techniques. However, hemorrhage may be more significant because the wounds are not closed surgically.⁶

Wedge resection techniques involve the removal of a pyramid-shaped section of the external nares in a vertical, horizontal, or lateral plane, depending on technique (FIGURE 2).^{1,10} The length of the base of the wedge determines the degree of opening of the nares. The caudal aspect of both incisions should meet at the alar cartilage, creating the depth of the wedge. Regardless of technique, the exposed edges are then apposed, pulling the alae out of the nasal

openings and increasing the diameter of the upper airway. Sutures should be placed only to appose tissues, as any tension on the suture line may cause patients to rub at the sutures. Vertical resection is performed by removing a wedge-shaped section of the nares with

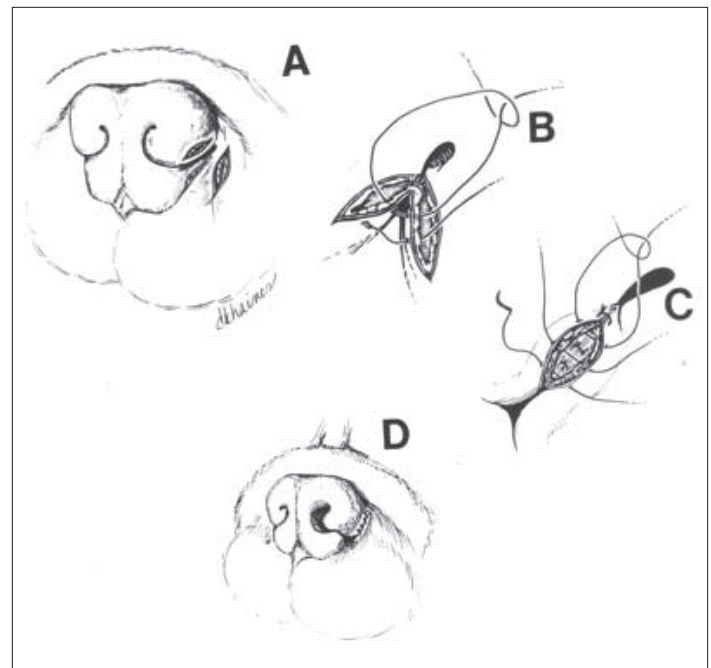


Figure 3. Illustration of the alapexy procedure. (A) Two elliptical incisions (5 to 10 mm long × 3 mm wide × 3 mm deep) are made with a no. 15 scalpel blade, one in the ventral lateral alar skin and one in the skin 3 to 5 mm lateral to the ala. (B) The edges of the incisions lying closest to each other are apposed with three to four sutures of 4-0 absorbable suture material in a simple interrupted or a simple continuous pattern. (C) The outer aspects of the incisions are apposed with three to four sutures of 3-0 or 4-0 nonabsorbable suture material in a simple interrupted pattern. (D) Finished alapexy after two-layer closure. Reprinted with permission from: Ellison GW. Alapexy: an alternative technique for repair of stenotic nares in dogs. JAAHA 2004;40:484-489.

the apex of the wedge at the dorsalmost aspect of the wing of the alae. Horizontal wedge resection involves the creation of a wedge in the medial to lateral direction, ending just dorsal to the mucosal edge of the nares. Care must be taken not to accidentally remove the mucosal surface because this area is essential for closure of the wedge. Lateral resection involves removal of the caudolateral edge of the nares and the adjacent skin and is described elsewhere.¹⁰

More recently, alapexy has been described (FIGURE 3).¹¹ This procedure involves the creation of two elliptical incisions, one in the ventrolateral alar skin and one in the adjacent pigmented skin 3 to 5 mm lateral to the ala. The two incisions are apposed, pulling the alae laterally and caudally.¹¹ The alae are anchored to the adjacent skin using a two-layer closure technique. Success rates for the alapexy technique were similar to those reported for wedge resection techniques,^{1,11} although alapexy involves more suturing and potentially longer surgical times.

No single procedure is recommended more than another for stenotic nares based on technique alone. The skill level of the surgeon, the conformation of the nares, and any previous intervention must be considered. Based on studies showing the success of early intervention in young patients with BAS,⁶ it is our opinion that general practitioners comfortable with the procedures should offer correction of the nares and an elongated soft palate at the time of spay or castration. In this situation, a simple nares amputation may be appropriate for the technical level of the surgeon. Alapexy is a good alternative in dogs with excessive flaccidity of the alar cartilage or in which wedge resection techniques have failed.

Elongated Soft Palate

The soft palate should be evaluated with the head and tongue in a neutral position and without an endotracheal tube present, as these factors influence the location of the soft palate.¹² In this position, a normal soft palate does not extend past the tip of the epiglottis or the mid to caudal aspect of the tonsillar crypt (FIGURE 4).^{1,3,4} Excessive palatal tissue should be excised so that the resulting

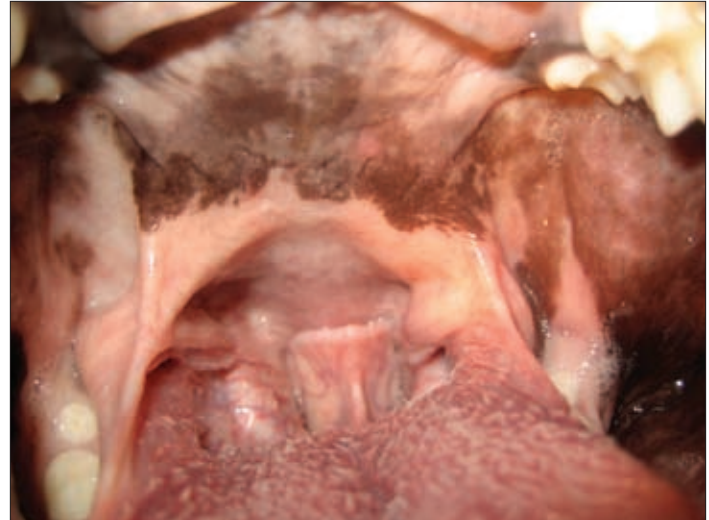

Figure 4. Evaluation of the soft palate. This palate extends beyond the tip of the epiglottis and the tonsillar crypts.

caudal aspect of the soft palate is in this position (FIGURE 5).^{1,2,4,10} Removal of too little tissue prevents movement of the epiglottis into a more natural position and does not relieve the respiratory obstruction, whereas removal of too much tissue can lead to aspiration, sinusitis, and rhinitis.^{1,2,4,10} Removal of too little tissue is preferred over removal of too much tissue because patients can undergo further surgery to correct a persistently long palate. Removal of too much tissue is difficult to correct and predisposes the dog to serious complications (e.g., aspiration pneumonia).^{1,2,4,10}

Soft palate excision has been the topic of much study. The conventional technique (sharp dissection) involves excision with a scalpel blade or Metzenbaum scissors and apposition of the oropharyngeal and nasopharyngeal mucosa in a simple, continuous pattern.¹ If conventional techniques are used, the use of absorbable suture material and the placement of buried knots is recommended

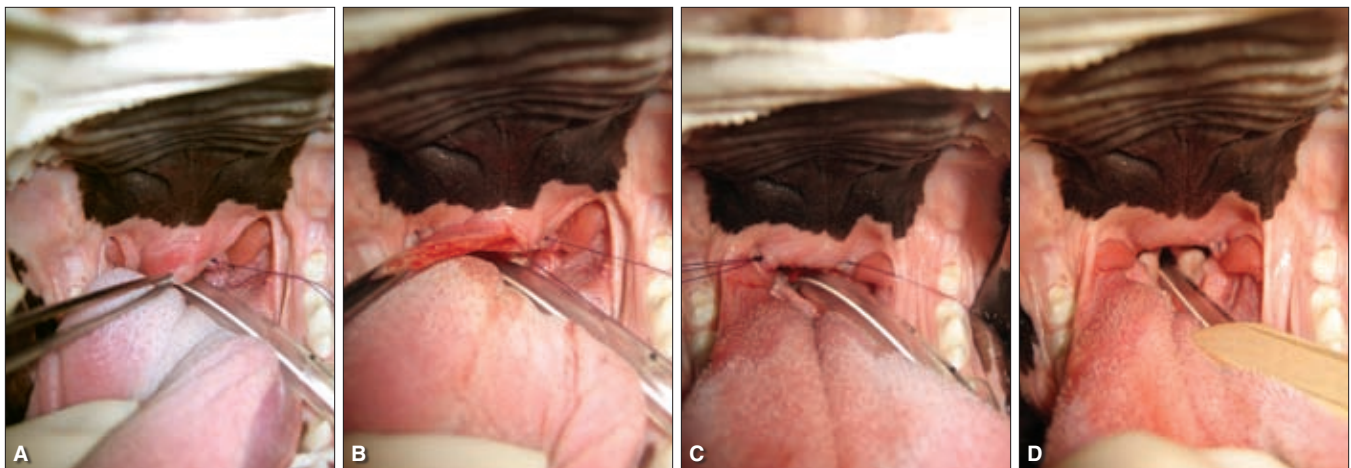


Figure 5. Soft palate resection with traditional technique. (A) The first suture is placed at the level of the cut, and a stay suture is used to aid in excision. (B) Midexcision. The palate is cut halfway across its width, and the dorsal and ventral mucosa are apposed. This “cut-sew-cut-sew” technique helps aid in mucosal apposition, which is essential for healing without scarring. (C and D) Postexcision. The soft palate is trimmed to the level of the midcaudal tonsillar crypt.

to decrease postoperative irritation of the upper airway and pharynx. Use of an electroscalpel (electrocautery) or crushing techniques has been shown to cause excessive postoperative edema, and these techniques are not currently recommended.^{1,13,14}

A study in 2001 compared sharp dissection with use of a carbon dioxide (CO₂) laser and found similar clinical outcomes for both techniques.³ The mean surgical time for the laser was shorter (309 seconds) than that for sharp dissection (704 seconds), but sharp dissection techniques are still relatively rapid.³ Biopsy samples taken at multiple time points during recovery showed similar results in the two groups, with all lesions healed or nearly healed within 14 days. In addition to faster surgery times, advantages of the laser included decreased hemorrhage, swelling, and postoperative pain. Another study comparing the use of a laser and traditional sharp dissection found similar results.¹⁴ These benefits are attributed to the coagulation properties of the laser, including sealing of small blood vessels, lymphatics, and nerve endings.³ Laser techniques require proper training and safety practices and selection of appropriate candidates.

Brdecka et al¹⁵ compared the use of a CO₂ laser and a bipolar sealing device (LigaSure, Valley Labs, Boulder, CO) that compresses tissue and cauterizes based on tissue impedance levels for soft palate resection in healthy dogs. The technique using the bipolar sealing device included compression and cauterization followed by trimming of the excess soft palate with Metzenbaum scissors. Mean surgical times with this device were shorter than those with the CO₂ laser (67.5 seconds versus 174.5 seconds). Histopathologic changes at 48 and 96 hours postoperatively were similar, but the depth of changes was greater with the bipolar sealing device (5.3 mm) than with the laser (0.34 mm). Use of the bipolar sealing device does not require the stringent safety precautions that a CO₂ laser demands. The authors recommended continued study of the bipolar sealing device for soft palate resection in dogs with BAS.¹⁵

Everted Laryngeal Saccules

Eversion of the laryngeal saccules is considered the first stage of laryngeal collapse.¹⁶ As noted in **TABLE 1** of the companion article, everted laryngeal saccules are generally not the most frequent manifestation of BAS. If the laryngeal saccules are everted, they appear as shiny, white convex structures protruding into the airway cranial to the vocal cords (**FIGURE 6**).¹⁰⁻¹² Some authors recommend temporary tracheostomy to aid in visualization and resection, but visualization and resection can be accomplished with temporary extubation or by pushing the endotracheal tube to one side. Once the saccules are visualized, they can be grasped with an Allis tissue forceps or long hemostats, retracted rostrally, and excised with a scalpel blade or Metzenbaum scissors. Alternatively, laryngeal cup forceps can be used to retract and remove the saccules.⁷ Hemorrhage is usually minimal and can be controlled with gentle pressure,^{1,2,4} and resection sites are left to heal by second intention.⁸

Advanced Laryngeal Collapse

Stage II laryngeal collapse is defined as loss of rigidity and medial displacement of the cuneiform processes of the arytenoid cartilage.¹⁶

Table 1. Outcomes in Dogs Treated Surgically for Brachycephalic Airway Syndrome

Study	Reported Results
Poncet et al 2006 ²⁰	<ul style="list-style-type: none"> • 3.3% (2/61) mortality • 94.1% (32/34) improved at >1 year postoperatively • Improvement independent of age, breed, diagnosis, and technique used for staphylectomy
Riecks et al 2007 ²³	<ul style="list-style-type: none"> • No perioperative mortality • 89.1% (41/46) improved at 19 to 77 months postoperatively • Of 46 dogs, 26 showed significant improvement; 15 showed some improvement • All dogs were reported to have some recurrence of signs
Torrez and Hunt 2006 ¹⁷	<ul style="list-style-type: none"> • 3.2% (2/62) mortality • 89.1% (41/46) showed significant improvement in respiratory signs within 6 weeks
Davidson et al 2001 ³	<ul style="list-style-type: none"> • 4.3% (2/46) perioperative mortality • Of 17 dogs, seven had no signs related to upper airway, five snored while sleeping, and five gagged or coughed after eating rapidly
Lorison et al 1997 ²¹	<ul style="list-style-type: none"> • 6.8% (8/117) mortality overall; mortality associated with aspiration pneumonia was 6.25% in non-bulldog breeds, 12.5% in bulldogs • Overall, 61% (34/56) of owners reported good to excellent outcomes at 6 months postoperatively • 45% (9/20) of English bulldog owners reported good to excellent outcomes at 6 months postoperatively • Results were independent of age

Stage III disease involves collapse of the corniculate processes of the arytenoid cartilage and loss of the dorsal arch of the rima glottidis.¹⁶ Stage II and III laryngeal collapse have been associated with a guarded prognosis.² A recent study showed that brachycephalic puppies aged 4.5 to 6 months had significant laryngeal changes associated with BAS¹⁶; five of seven dogs in this study had developed stage II or III laryngeal collapse by only 6 months of age. Despite the small size of this study, it supports the notion that BAS should be corrected early to prevent progression of airway pathology.

Torrez and Hunt¹⁷ found a favorable outcome in 76.4% of dogs (13 of 17) with moderate to severe laryngeal collapse treated for various components of BAS (owners of the remaining four dogs could not be contacted for follow-up). Animals that do not improve after correction of stenotic nares, elongated soft palate, and everted saccules often have advanced laryngeal collapse and can undergo permanent tracheostomy to bypass the upper airway.^{8,18} Partial laryngeal resection was previously performed in

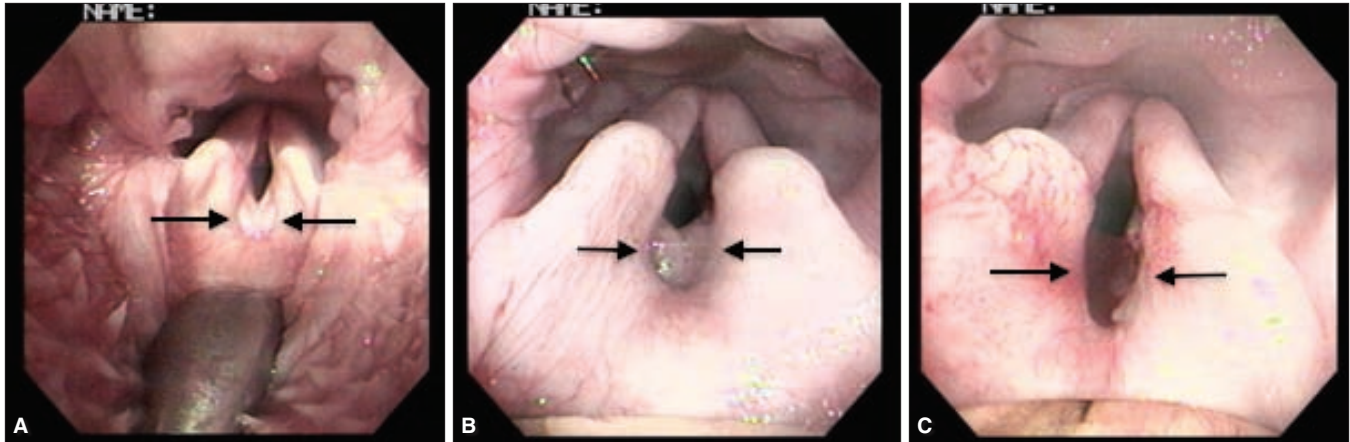


Figure 6. Everted laryngeal sacculles in two dogs. (A) Everted laryngeal sacculles (arrows). No edema is seen, and these sacculles were left in place. The dog had a significant improvement in respiratory signs with staphylectomy alone. This dog's nares were not stenotic. (B) Everted, edematous laryngeal sacculles are seen between the vocal cords as shiny, white, convex structures (arrows). These have been effectively described to one author of this article (M.T.) as resembling "inside-out pants pockets." (C) The same dog as in Figure 6B after resection of the sacculles.

patients with persistent airway dysfunction and laryngeal collapse after correction of other BAS components. One study¹⁹ showed a mortality of 50% for this procedure in dogs with concurrent BAS airway pathology, with surviving dogs at an increased risk of aspiration pneumonia. This technique is no longer recommended for treatment of laryngeal collapse.¹⁹

Permanent tracheostomy is now the recommended procedure for severe laryngeal collapse that has not responded to all other corrective techniques. This palliative procedure bypasses the upper airway and allows for relief of dyspnea caused by upper airway obstruction. This technique is well described elsewhere,¹⁸ but it is important to note that creation of the stoma should begin at the second tracheal ring, include three to four cartilage rings, and remove less than 33% of the circumference of the trachea. Care should be taken to assess the amount of adjacent skin and plan appropriate resection of loose skin to prevent postoperative skin-fold occlusion, as this is the most common long-term complication.¹⁸

Immediate postoperative management of a permanent tracheostomy is similar to that for temporary tracheostomy, discussed below.¹⁸ Long-term management of a permanent tracheostomy requires daily cleaning, regular trimming of hair around the stoma, and maintenance of a clean environment, including the air in the environment.¹⁸ Patients must not be allowed to swim or engage in other activities that cause aspiration of liquid or particulate matter.¹⁸ An increased risk of pulmonary infection may be expected but has not been reported.¹⁸

Surgical complications of permanent tracheostomy include stenosis of the stoma, wound infection, swelling, subcutaneous emphysema, and dehiscence. Good surgical planning, proper tissue handling, and good apposition of the tracheal mucosa to the adjacent skin help decrease the risk of these complications.¹⁸ Although this is considered a palliative procedure, most dogs have a good quality of life, with improved breathing and increased exercise tolerance.¹⁸ However, changes in vocalization or loss of ability to vocalize have been reported in up to 60% of patients

after permanent tracheostomy,¹⁸ and owners should be warned in advance of this potential outcome.

Tonsillectomy

Of the BAS studies reviewed, few mention enlargement of the tonsils.^{4,17,19,20,21} One study⁴ reported that inflammation of the tonsils (amygdalitis) was diagnosed in 15 of 73 dogs (20.5%). Another study²⁰ reported amygdalitis in 21.3% of cases (13 of 61), with only one patient undergoing resection of the tonsillar tissue. The authors of these studies report that resection was unnecessary for a good improvement and may increase local inflammation postoperatively.²⁰ A third study²¹ reported tonsillectomy in 29 dogs, but the authors eliminated tonsillectomy when comparing outcomes because they felt it exerted a minimal influence on overall results. It is thought that tonsillar inflammation resolves following correction of other upper airway abnormalities.^{19,20} In the Poncet study,²⁰ 10 dogs were reexamined 6 months postoperatively, and all 10 demonstrated significant improvement or complete resolution of all macroscopic abnormalities, including amygdalitis.²⁰ Because the additional inflammation created with tonsillectomy has little to no benefit, tonsillectomy is not recommended.^{4,17,19,20,21}

Temporary Tracheostomy

If a patient is displaying respiratory difficulty postoperatively, early intervention is recommended, as episodes of partial airway obstruction predispose patients to regurgitation, aspiration, and development of pneumonia. Multiple factors are involved in the decision to perform a postoperative temporary tracheostomy. Patient factors include the degree of preoperative airway swelling, the severity of the BAS components, and the extent of intraoperative trauma. The ease of recovery and the patient's disposition also play roles. Specific recommended monitoring parameters that may aid in the decision to perform temporary tracheostomy include capnography, pulse oximetry, and blood gas analysis, which

Key Points

- Patients should be clipped and aseptically scrubbed for tracheostomy before surgery, but this procedure should only be performed when necessary to relieve postoperative airway obstruction.
- Regardless of technique used, early correction of stenotic nares is recommended in dogs with BAS.
- The soft palate should be evaluated with the head and neck in a neutral position.
- Patients should be closely monitored in an appropriate facility for 24 to 48 hours after surgery. Placement of a temporary tracheostomy may be warranted and should be performed quickly if the patient is displaying signs of partial airway obstruction postoperatively.

the trachea. The annular ligament is incised transversely between the third and fourth or fourth and fifth tracheal rings, not extending the incision more than 50% of the circumference of the trachea. Nylon stay sutures should be placed around each of the rostral and caudal tracheal rings to facilitate placement and maintenance of the tracheostomy tube. It is helpful if these stay sutures are labeled with white tape and their respective positions (i.e., top and bottom) for later use if reinsertion of the tracheostomy tube is required. The tracheal lumen is suctioned to remove blood and mucus, and the tube is placed. The sternohyoid muscles and then adjacent skin are reapposed with one to two simple interrupted sutures. The tube is held in place with a gauze tie around the neck and/or with sutures to the adjacent skin.

Postoperatively, patients should be constantly monitored for dyspnea, vomiting, and regurgitation. The cannula or stoma must be frequently checked for mucus accumulation and occlusion, and removal and cleaning of the inner cannula or suctioning of the stoma site may be required. Use of suction should be minimized because suctioning can induce a vagal response, leading to gagging, retching, or vomiting.¹⁸ Patients can also experience transient hypoxia during suctioning of the airway.¹⁸ Patients should be nebulized or treated with humidified oxygen at the tracheostomy site.¹⁸ The newly exposed respiratory epithelium undergoes temporary cellular changes, but is expected to return to normal ciliated epithelium within 16 weeks.¹⁸

Postoperative Care

The endotracheal tube should remain in place as long as the patient will tolerate it during recovery.¹ Swelling of the airway,

can allow a good assessment of the patient's ventilatory status. These monitoring parameters are also excellent for monitoring patients after performance of a temporary tracheostomy.

The tracheostomy tube selected should be made of a nonreactive material and should be no larger than 50% of the diameter of the trachea.¹⁸ Cuffed or cannulated tubes are preferred. Placement of a temporary tracheostomy tube using a transverse incision of the annular ligament is described here; alternative methods are described elsewhere.¹⁸

A ventral midline incision is made starting at the level of the cricoid cartilage and extending 2 to 3 cm caudally. The sternohyoid muscles are separated to expose

decreased pharyngeal reflexes, hyperthermia, and the increased risk of aspiration necessitate close patient monitoring for at least 24 to 48 hours postoperatively.^{1,2} Blood gas monitoring can provide an excellent measure of the patient's ability to ventilate appropriately and help determine whether or when a tracheostomy is warranted. Prednisone (0.5 to 1.0 mg/kg IV or PO q8h for 24 to 48 hours postoperatively²) may be used to help decrease airway inflammation. Prednisone is preferred over dexamethasone SP when multiple doses are to be administered. NSAIDs are not often used because of the common use of perioperative corticosteroids and the potential gastrointestinal effects in these already predisposed patients. Supplemental oxygen may also be delivered via intranasal catheter, flow-by tubing, or oxygen cage.

Dogs should remain fasted for 12 to 24 hours after surgery.²² Water should be offered first; if it is well tolerated, small amounts of soft food can be offered. The diet should consist of only soft food for 10 to 14 days to minimize irritation of the upper airway.²² Hand-feeding of soft "meatballs" helps to slow ingestion and prevent dysphagia.¹

Client education is an essential part of long-term care and is especially important in the short-term postoperative period (i.e., the first 2 weeks). Owners should be advised to keep their pet in a cool environment, to provide moderate levels of activity, and to keep the pet in lean body condition.² Pets should be walked on a harness and not a collar to remove stress on the upper airway. These lifestyle changes should be maintained for the life of the patient to maximize successful outcomes.

Outcomes and Prognosis

Severe postoperative complications include airway swelling, vomiting, regurgitation, and aspiration.²³ As mentioned above, preoperative metoclopramide may help reduce the frequency of postoperative vomiting and regurgitation. If a patient begins to develop signs of exercise intolerance, coughing, or gagging, or if the owner reports vomiting or regurgitation, a thorough physical examination, thoracic auscultation, and thoracic radiography are indicated to look for evidence of aspiration pneumonia.

Other, less severe complications reported include dehiscence of the nares, persistent upper airway stertor/stridor, recurrence of less extreme upper airway signs, and voice change.²³ In studies published in the past 14 years, perioperative mortality has ranged between 3.2% and 6.8%.^{3,4,17,21,23} In most cases, mortality was associated with obstruction secondary to upper airway swelling or aspiration pneumonia.

Long-term outcomes following correction of BAS abnormalities are generally good (TABLE 1). Mortality reported in recent studies is usually below 5%, although one study²¹ had a higher mortality in general, and especially in English bulldogs (12.5% versus 6.25% in the general population). The high mortality in English bulldogs in this study was attributed to a high incidence of postoperative aspiration pneumonia.²¹ This may or may not be associated with the higher incidence of gastrointestinal disease in this breed. Reported success rates range from 61% to 94%,^{3,4,17,21,23} with most recent reports having success rates above 88%.^{4,17,23}

Conclusion

Early intervention and correction of BAS abnormalities are recommended to halt progression of airway pathology. Various surgical options exist for correction of the abnormalities associated with BAS. Prognosis depends on the severity of airway pathology, patient temperament, surgical repair, and whether a temporary tracheostomy is required in the postoperative period. Most patients improve after surgical correction of their BAS abnormalities.

References

1. Hedlund CS. Stenotic nares. In: Fossum TW, ed. *Small Animal Surgery*. 2nd ed. St Louis: Mosby; 2002:727-730.
2. Hendricks JC. Brachycephalic airway syndrome. *Vet Clin North Am Small Anim Pract* 1992;22(5):1145-1153.
3. Davidson EB, Davis MS, Campbell GA, et al. Evaluation of carbon dioxide laser and conventional incisional techniques for resection of soft palates in brachycephalic dogs. *JAVMA* 2001;219(6):776-781.
4. Poncet CM, Dupre GP, Freiche VG, et al. Prevalence of gastrointestinal tract lesions in 73 brachycephalic dogs with upper respiratory syndrome. *J Small Anim Pract* 2005;46(6):273-279.
5. Holt D. Surgery of the upper airway in the brachycephalic dog. *Proc ACVS Symp* 1998;1:25-31.
6. Huck JL, Stanley BJ, Hauptman JG. Technique and outcome of nares amputation (Trader's technique) in immature shih tzus. *JAAHA* 2008;44(2):82-85.
7. Greenberg MJ, Reems MR, Monnet E. Use of perioperative metoclopramide in dogs undergoing surgical treatment of laryngeal paralysis: 43 cases (1999-2006). *Vet Surg* 2007;36:E11.
8. Hedlund CS. Brachycephalic syndrome. In: Bojrab MJ, ed. *Current Techniques in Small Animal Surgery*. 4th ed. Philadelphia: Williams & Wilkins; 1998:357-362.
9. Trader RL. Nose operation. *JAVMA* 1949;114:210-211.
10. Monnet E. Brachycephalic airway syndrome. In: Slatter D, ed. *Textbook of Small Animal Surgery*. 3rd ed. Philadelphia: WB Saunders; 2003:808-813.
11. Ellison GW. Alapexy: an alternative technique for repair of stenotic nares in dogs. *JAAHA* 2004;40:484-489.
12. Harvey CE. Upper airway obstruction surgery. III. Everted laryngeal sacculle surgery in brachycephalic dogs. *JAAHA* 1982;18:545-547.
13. Bjorling D, McAnulty J, Swainson S. Surgically treatable upper respiratory disorders. *Vet Clin North Am Small Anim Pract* 2000;30(6):1227-1251.
14. Clark GN, Sinibaldi KR. Use of a carbon dioxide laser for treatment of elongated soft palate in dogs. *JAVMA* 1994;204(11):1779-1781.
15. Brdecka D, Rawlings C, Howerth E, et al. A histopathological comparison of two techniques for soft palate resection in normal dogs. *JAAHA* 2007;43(1):39-44.
16. Pink JJ, Doyle RS, Hughes JM, et al. Laryngeal collapse in seven brachycephalic puppies. *J Small Anim Pract* 2006;47(3):131-135.
17. Torrez CV, Hunt GB. Results of surgical correction of abnormalities associated with brachycephalic airway obstruction syndrome in dogs in Australia. *J Small Anim Pract* 2006;47(3):150-154.
18. Hedlund CS. Tracheostomy. *Probl Vet Med* 1991;3(2):198-209.
19. Harvey CE. Upper airway obstruction surgery. VIII. Overview of results. *JAAHA* 1982;18:567-569.
20. Poncet CM, Dupre GP, Freiche VG, Bouvy BM. Long-term results of upper respiratory syndrome surgery and gastrointestinal tract medical treatment in 51 brachycephalic dogs. *J Small Anim Pract* 2006;47(3):137-142.
21. Lorison D, Bright RM, White RAS. Brachycephalic airway obstructions syndrome: a review of 118 cases. *Canine Pract* 1997;22:18-21.
22. Hobson HP. Brachycephalic syndrome. *Semin Vet Med Surg (Small Anim)* 1995;10(2):109-114.
23. Riecks TW, Birchard SJ, Stephens JA. Surgical correction of brachycephalic syndrome in dogs: 62 cases (1991-2004). *JAVMA* 2007;230(9):1324-1328.



3 CE Credits

This article qualifies for 3 contact hours of continuing education credit from the Auburn University College of Veterinary Medicine. CE tests must be taken online at Vetlearn.com; test results and CE certificates are available immediately. Those who wish to apply this credit to fulfill state relicensure requirements should consult their respective state authorities regarding the applicability of this program.

1. Which statement regarding tracheostomy in dogs undergoing surgery for BAS is true?

- a. Preoperative temporary tracheostomy should be performed in all dogs.
- b. All dogs should be prepared for tracheostomy preoperatively.
- c. Tracheostomy is contraindicated in these patients due to the risk of infection.
- d. Postoperative temporary tracheostomy should be performed in all dogs.

2. Which technique(s) has/have been described for the correction of stenotic nares?

- a. amputation of the alae
- b. alapexy
- c. wedge resection
- d. all of the above

3. Which statement regarding an elongated soft palate is true?

- a. It can be ignored during surgical correction of BAS in many cases.
- b. It is best corrected using a CO₂ laser.
- c. It is identified when the soft palate extends past the tip of the epiglottis or the mid to caudal aspect of the tonsillar crypt.
- d. It is better to excise too much tissue than too little.

4. Which method of soft palate resection has been proven superior?

- a. sharp dissection
- b. CO₂ laser
- c. use of a bipolar sealing device
- d. none of the above; all three produce good results

5. Which statement(s) regarding everted laryngeal sacculles is/are true?

- a. They are considered stage I laryngeal collapse.
- b. They appear as shiny, white, convex structures cranial to the vocal cords.
- c. They are resected and left to heal by second intention.
- d. all of the above

6. Advanced laryngeal collapse

- a. is the same as laryngeal paralysis.
- b. is associated with a guarded prognosis.
- c. indicates congenital connective tissue disease.
- d. is a contraindication for surgery.

7. Tonsillectomy during corrective BAS surgery

- a. is not recommended.
- b. can improve overall outcome in the presence of laryngeal collapse.
- c. is required, as the inflammation of this tissue does not resolve after correction of other BAS abnormalities.
- d. should be performed if the tonsils are inflamed.

8. Which of the following is true regarding postoperative care of BAS patients?

- a. Patients should be sent home immediately after recovering from anesthesia.
- b. Patients should be closely monitored for dyspnea, and the surgeon should be prepared to intervene if necessary.
- c. Hard food should be offered within 6 hours of surgery.
- d. Anti-inflammatory doses of steroids are never indicated.

9. Recent studies report perioperative mortality for correction of BAS abnormalities of

- a. <5% in most cases.
- b. between 10% and 15%.
- c. between 25% and 30%.
- d. >50%.

10. After corrective surgery for BAS,

- a. about 25% of dogs require permanent tracheostomy.
- b. most patients have decreased exercise tolerance.
- c. most owners report a successful outcome.
- d. about 10% of dogs require further surgery.