

UC San Diego

UC San Diego Previously Published Works

Title

Intrinsic foot muscle deterioration is associated with metatarsophalangeal joint angle in people with diabetes and neuropathy

Permalink

<https://escholarship.org/uc/item/1j14t6vv>

Journal

Clinical Biomechanics, 28(9-10)

ISSN

0268-0033

Authors

Cheuy, Victor A
Hastings, Mary K
Commean, Paul K
[et al.](#)

Publication Date

2013-11-01

DOI

10.1016/j.clinbiomech.2013.10.006

Peer reviewed

Published in final edited form as:

Clin Biomech (Bristol, Avon). 2013 ; 28(0): 1055–1060. doi:10.1016/j.clinbiomech.2013.10.006.

Intrinsic Foot Muscle Deterioration is Associated with Metatarsophalangeal Joint Angle in People with Diabetes and Neuropathy

Victor A. Cheuy, MS¹, Mary K. Hastings, PT, DPT², Paul K. Commean, BEE³, Samuel R. Ward, PT, PhD⁴, and Michael J. Mueller, PT, PhD⁵

¹Applied Biomechanics Laboratory, Movement Science Program, Washington University School of Medicine, St. Louis, Missouri, USA

²Human Biodynamics Laboratory, Program in Physical Therapy, Washington University School of Medicine, St. Louis, Missouri, USA

³Electronic Radiology Laboratory, Mallinckrodt Institute of Radiology, Washington University School of Medicine, St. Louis, Missouri, USA

⁴Muscle Physiology Laboratory, Department of Orthopaedic Surgery, Department of Radiology, and Department of Bioengineering, University of California San Diego, San Diego, California, USA

⁵Applied Biomechanics Laboratory, Movement Science Program, Program in Physical Therapy, and Department of Radiology, Washington University School of Medicine, St. Louis, Missouri, USA

Abstract

Background—Metatarsophalangeal joint deformity is associated with skin breakdown and amputation. The aims of this study were to compare intrinsic foot muscle deterioration ratios (ratio of adipose to muscle volume), and physical performance in subjects with diabetic neuropathy to controls, and determine their associations with 1) metatarsophalangeal joint angle and 2) history of foot ulcer.

Methods—23 diabetic, neuropathic subjects [59 (SD 10) years] and 12 age-matched controls [57 (SD 14) years] were studied. Radiographs and MRI were used to measure metatarsophalangeal joint angle and intrinsic foot muscle deterioration through tissue segmentation by image signal intensity. The Foot and Ankle Ability Measure evaluated physical performance.

Findings—The diabetic, neuropathic group had a higher muscle deterioration ratio [1.6 (SD 1.2) vs. 0.3 (SD 0.2), $P < 0.001$], and lower Foot and Ankle Ability Measure scores [65.1 (SD 24.4) vs. 98.3 (SD 3.3) %, $P < 0.01$]. The correlation between muscle deterioration ratio and metatarsophalangeal joint angle was $r = -0.51$ ($P = 0.01$) for all diabetic, neuropathic subjects, but increased to $r = -0.81$ ($P < 0.01$) when only subjects with muscle deterioration ratios >1.0 were

© 2013 Elsevier Ltd. All rights reserved.

Corresponding Author: V.A.C., Movement Science Program, and Program in Physical Therapy, Washington University School of Medicine, Campus Box 8502, 4444 Forest Park Ave., St. Louis, MO 63108. Phone: 314-286-1441. cheuyv@wusm.wustl.edu.

Publisher's Disclaimer: This is a PDF file of an unedited manuscript that has been accepted for publication. As a service to our customers we are providing this early version of the manuscript. The manuscript will undergo copyediting, typesetting, and review of the resulting proof before it is published in its final citable form. Please note that during the production process errors may be discovered which could affect the content, and all legal disclaimers that apply to the journal pertain.

included. Muscle deterioration ratios in individuals with diabetic neuropathy were higher for those with a history of ulcers.

Interpretation—Individuals with diabetic neuropathy had increased intrinsic foot muscle deterioration, which was associated with second metatarsophalangeal joint angle and history of ulceration. Additional research is required to understand how foot muscle deterioration interacts with other impairments leading to forefoot deformity and skin breakdown.

Keywords

Intermuscular adipose tissue; muscle; foot deformity

INTRODUCTION

In the United States, over 60% of non-traumatic lower extremity amputations occur in individuals with diabetes, totaling over 65,000 amputations annually (CDC, 2011). A major risk factor is neuropathic plantar ulceration, which precedes amputation over 80% of the time (Lavery, 2012). Previous studies have shown that foot deformities, and the resulting changes in plantar pressure distribution, are major factors leading to ulceration (Robertson et al., 2002; Van Schie et al., 2004; Reiber et al., 1999; Boyko et al., 1999). A common forefoot deformity associated with high plantar pressures and skin breakdown is metatarsophalangeal joint (MTPJ) deformity (Robertson et al., 2002; Van Schie et al., 2004; Boyko et al., 1999; Boulton et al., 2008). The high plantar pressures are associated with a prominent metatarsal head that becomes exposed to plantar forces because of MTPJ hyperextension (Ahroni et al., 1999; Bus et al., 2005). Unfortunately, the causal factors of this deformity are not fully understood. Understanding the etiology of foot deformities would help improve interventions and develop preventative measures to affect change in the impairment cascade of deformity, ulceration, and amputation.

Potential risk factors for acquired MTPJ deformity in people with diabetes mellitus and peripheral neuropathy (DMPN) include intrinsic foot muscle (IFM) deterioration, poor fitting footwear, ruptures in the plantar fascia or the plantar plates of the MTPJ, and decreased ankle range of motion (Boulton, 1996; Bus et al., 2009; Kwon et al., 2009). IFM deterioration is commonly believed to be a factor in the development of MTPJ hyperextension deformities because without the flexion force of the IFMs as an antagonist to the extensor digitorum longus, there would be a muscular imbalance that would destabilize these joints. Specifically, the proximal phalanx will hyperextend as tendon and ligament deformation occurs on the plantar surface of the MTPJ, resulting in a prominent metatarsal head (Fortin and Myerson, 1995; Mizel and Yodlowski, 1995). The few studies that have investigated the relationship between IFM deterioration and deformity have shown conflicting results on the association, or lack thereof, between IFM deterioration and MTPJ hyperextension (Robertson et al., 2002; Van Schie et al., 2004; Bus et al., 2009; Bus et al., 2002). None of the studies have used a quantitative volumetric measure of intermuscular adipose tissue (IMAT) to calculate IFM deterioration; a measure that would allow researchers to better understand how IFM deterioration contributes to joint deformity.

The aims of this study were to 1) compare IFM deterioration and physical performance in participants with DMPN to control participants, 2) determine the associations between measures of IFM deterioration, second MTPJ hyperextension, and physical performance, and 3) determine how these associations differ between individuals with and without a history of ulceration. Our hypotheses are that 1) the DMPN group will have increased IFM ratios (ratio of IMAT to lean muscle volume) compared to controls; 2) IFM ratios will be correlated with the severity of the measure of MTPJ hyperextension and inversely correlated

with the measure of physical performance; and 3) those with a history of ulcers will have larger IFM ratios, and more severe MTPJ hyperextension and physical performance impairment.

RESEARCH DESIGN AND METHODS

Subjects

Thirty-five adult subjects participated in this study [22 male, 13 female; age 59 (SD 11) years], who were recruited from an ongoing study and from whom informed consent was obtained. The complete demographic summary is shown in Table 1. Twenty-three of the subjects had DMPN [age 59 (SD 10) years], meeting the inclusion criteria of having type 1 or 2 DM and the inability to sense a 5.07 Semmes-Weinstein monofilament on at least one location on the plantar foot (Diamond et al., 1989). Severity of peripheral neuropathy also was assessed using vibration perception threshold assessment with a biothesiometer at the plantar great toe and first metatarsal head; a 128 Hz tuning fork on the first metatarsal head; and joint position sense tested at the interphalangeal joint of the great toe and at the ankle joint. Taken together, these measures indicate that the DMPN subjects had a relatively severe sensory neuropathy (Table 1). Eleven DMPN subjects had medial column deformity, assessed by meeting 2 of the following criteria: calcaneal eversion $> 5^\circ$, medial longitudinal arch angle $< 130^\circ$, navicular height > 24 mm, and medial column peak plantar pressure > 29 N/cm² (Jonson and Gross, 1997; Menz and Munteanu, 2005). These subjects were selected to provide a spectrum of foot alignment angles. The remaining 12 control subjects [age 57 (SD 14) years] did not have a history of DM or PN, were able to sense the monofilament everywhere on the plantar foot, and were matched to the DMPN subjects by age, height, and weight. Exclusion criteria for all subjects were metal implants or pacemakers present, amputations to the lower extremity, and a weight greater than 181 kg (due to the weight limit on the MRI scanning table).

Image Acquisition and Data Collection

Weight bearing foot and ankle lateral radiographs were taken of all subjects (Figure 1A). The target foot for all subjects was the right foot unless the medial column deformity was present in the left. DMPN subjects with a left foot scan were then matched with a left foot scan in the control group. The radiographs were imported into iSite PACS software (Philips Healthcare Informatics, Foster City, CA), and the static foot alignment of second MTPJ angle was made to the nearest degree (Figure 1A). Second MTPJ angle is defined as the angle between the longitudinal axis of the second proximal phalanx and the longitudinal axis of the second metatarsal parallel to the dorsal cortex.

The coronal plane MR images of all subjects were collected using a Siemens Magnetom Trio 3T scanner (Siemens Medical Systems, Malvern, PA). The subjects were positioned supine with the target foot perpendicular to the table. The foot was placed in a head coil to achieve the best signal to noise ratio (Commean et al., 2011). The following MR parameters were used for all 35 subjects: spin echo pulse sequence, TR/TE = 5360/38 msec, field of view = 140 mm, bandwidth = 181 Hz/pixel, 35 slices, coronal orientation, signal averages = 1, flip angle = 141° , matrix = 384×384 , echo train length = 9, acquisition time ≈ 12 minutes, and voxel size $0.365 \times 0.365 \times 3.5$ mm.

The region of interest for each subject was defined as the talonavicular joint to the tarsometatarsal joint. The talonavicular joint was defined as the most distal portion of the talus on the navicular, and the tarsometatarsal joint was defined as the articulation between the intermediate cuneiform and second metatarsal bones. This region was selected because

each subject had usable data in this region from an ongoing study focused on the midfoot and hindfoot; therefore the forefoot region was not included.

Methods to segment muscle and IMAT volumes from the IFMs in these images have been previously reported (Cheuy et al., 2013). IMAT is defined as the visible adipose tissue beneath the muscle fascia, between muscles, and within the muscle (Commean et al., 2011). Briefly, a program developed using MatLab (Mathworks, Natick, MA) produces a histogram of all voxel intensities from the inputted MR slice (Figure 1B). In order to categorize the voxels into muscle and IMAT, an intensity threshold is calculated using a multiple Gaussian function fitting algorithm. The threshold corresponds to the minimum point between the maximum peaks of the two tissue types, as determined from the best-fit curve (Figure 1C, red line). This is calculated on an individual subject basis, unique to each MR image. An edge detection algorithm allows for the segmentation of subcutaneous fat from the IFMs, where the second derivative of intensities determines the border between the subcutaneous fat and the IFMs (Cheuy et al., 2013; Commean et al., 2011). The same edge detection methods are used to define the IFM compartment as the region of interest, which is then separated into muscle and IMAT volumes as determined by the threshold calculated earlier (Figure 1D,E). On an individual subject basis, the IFM deterioration (ratio of IMAT volume to lean muscle volume) of each MR slice was calculated and averaged over the region between the talonavicular and tarsometatarsal joints. The IFM ratio is a measure of muscle deterioration over the region of interest, and does not depend on the size of the IFM compartment. Total lean muscle and IMAT volume measures, however are dependent on foot size.

Physical performance was evaluated in each of the 35 subjects using the Activities of Daily Living (ADL) subscale of the Foot and Ankle Ability (FAAM) questionnaire. The FAAM is a reliable and validated self-report measure of physical function for individuals with musculoskeletal disorders of the lower extremities (Martin et al., 2005). The ADL is on a scale of 0 to 100%, 0 being the inability to perform any usual daily activities, and 100 being full ability to function.

Statistical Methods

SPSS (Version 19, Armonk, NY) was used to determine group differences in the IFM ratio, total lean muscle volume, total adipose tissue volume, total IFM compartment volume, second MTPJ angle, and the physical performance measure using Student's *t*-tests. Levene's test for equality of variances was used, and non-pooled *t*-tests (i.e. Welch's *t*-test) were used for unequal variances where appropriate. Pearson correlation coefficients were calculated between the IFM ratio measures, second MTPJ angle, and ADL subset scores of the FAAM for the 23 subjects with DM and PN. The Shapiro-Wilk test was used to test the normality of the residuals. Group differences and correlation coefficients were calculated similarly for DMPN subjects with and without a history of ulcers. A significance level of $P < 0.05$ was used for all analyses.

RESULTS

DMPN subjects had less lean muscle volume [18.2 (SD 11.0) vs. 31.6 (SD 12.8) cm³, $P < 0.01$] and more adipose tissue in the IFMs [17.9 (SD 10.5) vs. 9.3 (SD 3.8) cm³, $P < 0.01$] compared to controls (Figure 2A). The total volume within the IFM compartment was not different between the DMPN subjects and controls [36.1 (SD 11.8) vs. 40.9 (SD 14.9) cm³, respectively; $P = 0.31$]. DMPN subjects had more IFM deterioration [1.6 (SD 1.2) vs. 0.3 (SD 0.2), $P < 0.01$] and decreased ADL subscale scores [65.1 (SD 24.4) vs. 98.3 (SD 3.3), $P < 0.01$] compared to controls (Table 2). MTPJ angle was not different between groups [152

(SD 11) vs. 153 (SD 7) degrees, $P = 0.87$], and no correlation was found between the IFM ratio and the ADL subscale scores ($r = -0.15$, $P = 0.49$).

The correlation between the IFM ratio and MTPJ angle was $r = -0.51$ ($P = 0.01$), and the residuals were found to be normally distributed according to the Shapiro-Wilk test ($P = 0.08$) (Figure 2B). As IFM deterioration increases, the relationship between IFM deterioration and MTPJ angle appears to become less random and more linear. Given the appearance of a possible threshold effect beginning at an IFM ratio of 1.0 (equal parts fat and muscle), the DMPN group was divided into subgroups of those with ratios > 1.0 and ≤ 1.0 (Figure 2C). The > 1.0 group had more IFM deterioration [2.6 (SD 0.7) vs. 0.5 (SD 0.3), $P < 0.01$] compared to the ≤ 1.0 group, but no difference was found in MTPJ angle [150 (SD 12) vs. 155 (SD 9) degrees, $P = 0.26$] or ADL subscale scores [56.5 (SD 24) vs. 74.5 (SD 22), $P = 0.08$]. The correlation between IFM ratio and MTPJ angle for the > 1.0 group was $r = -0.81$ ($P < 0.01$); no correlation was found for the ≤ 1.0 group ($r = -0.31$, $P = .36$).

DMPN subjects with a history of ulcers (Table 3) had more IFM deterioration [2.2 (SD 1.0) vs. 1.2 (SD 1.1), $P < 0.05$] than DMPN subjects without a previous ulcer, but no difference was found in MTPJ angle [149 (SD 14) vs. 154 (SD 9) degrees, $P = 0.35$] or ADL subscale scores [60.0 (SD 18.5) vs. 67.9 (SD 27.1), $P = 0.47$]. The correlation between IFM ratio and MTPJ angle for the ulcer group was $r = -0.85$ ($P < 0.01$); no correlation was found for the group without a previous ulcer ($r = -0.23$, $P = .40$).

DISCUSSION

The results of this study show that IFM deterioration secondary to diabetic neuropathy is severe, with a ratio of IMAT to lean muscle volume approximately five times greater in the subjects with DMPN compared to controls. This marked deterioration was characterized by half as much lean muscle tissue and twice as much IMAT volume present in the IFM for the DMPN group. This study is the first to quantify adipose tissue and lean muscle tissue volumes in the neuropathic foot, using a volumetric analysis program that is reliable and validated on muscle and fat MR phantoms (Cheuy et al., 2013). The results support previous semi-quantitative studies that have estimated IFM tissue changes related to the neuropathic process: Andersen et al. (2004) found muscle volume was halved, Andreassen et al. (2009) found foot muscle volume decreased by approximately 30%, and Bus et al. (2002) found a 73% decrease in muscle cross sectional area distally in DMPN subjects compared to controls.

The total volume of the IFM compartment, as defined by tissue inside the muscular fascial plane, was not significantly different between the control and DMPN groups. This suggests the volume previously occupied by functional lean muscle tissue is replaced with IMAT. Vettor et al. (2009) and Aguiari et al. (2008) have found muscle satellite cells (MSCs) possess adipogenic potential, which can be driven by metabolic and cardiovascular abnormalities; a high glucose environment resulting in diabetic peripheral neuropathy will not only trigger adipose stem cells to differentiate, but induce MSCs to differentiate into adipose cells, perhaps accumulating into the IMAT we have measured. Understanding the molecular pathways that drive these processes is important for future studies treating the muscular deterioration characteristic of DMPN.

The IFM deterioration was moderately correlated with second MTPJ angle ($r = -0.51$) (Figure 2B). However, upon visual assessment, there appeared to be a differential relationship between the IFM deterioration and the MTPJ angle as the ratio increased past the value of 1.0 (i.e. IMAT volume = lean muscle tissue volume). To investigate this possibility, separate linear regression and correlation coefficients were calculated for the

subgroup of subjects with an IFM ratio ≤ 1.0 , and the subgroup with an IFM ratio > 1.0 (Figure 2C). The ≤ 1 subgroup did not have a correlation with MTPJ angle ($r = -0.31$, $P = .36$), but the > 1 subgroup did, with $r = -0.81$ ($P < 0.01$). These results suggest that when IFM deterioration exceeds a certain threshold, it begins to have a stronger effect on the degree of deformity. We hypothesize that those DMPN subjects with an IFM ratio ≤ 1.0 and increased MTPJ hyperextension have deformities driven by other factors, such as poor plantar fascia quality and/or tears in the fibrocartilage capsule of the MTPJ. However, once IFM deterioration exceeds a certain threshold, there is a more robust association with MTPJ angle. This observation may reflect the complex interaction of structural impairments in the foot that can lead to MTPJ deformity and deserves additional prospective study.

The relationship between IFM deterioration and MTPJ deformity has only been addressed by a few studies. The results of this study support a previous study that showed peroneal and tibial nerve conduction velocity were associated with weakness in muscles innervated by, respectively, the peroneal and tibial nerve ($r = -0.70$ and $r = -0.51$, $P < 0.01$) and foot deformities ($r = -0.60$ and $r = -0.59$, $P < 0.01$) (Van Schie et al., 2004). Similarly, Robertson et al. (2002) found a decrease in plantar muscle density (as measured by computed tomography) in DMPN subjects, hypothesized to be due to adipose tissue infiltration, and correlated with MTPJ hyperextension angle ($r = -0.41$, $P = 0.02$). Two other studies did not find a relationship between IFM deterioration and MTPJ angle, where decreases in total muscle cross sectional area accounted for deformity in only 2 of 8 DMPN subjects, and where a semi-quantitative 5-point atrophy scale did not correlate with MTPJ angle ($r = -0.14$, $P = 0.56$) (Bus et al., 2009; Bus et al., 2002). Our study used a quantitative volumetric analysis, and measured both the adipose tissue infiltration and the remaining muscle tissue (Cheuy et al., 2013). We found IFM deterioration was associated with MTPJ hyperextension in DMPN subjects, especially at high levels, suggesting a multi-factorial nature to the development of deformity. Future work incorporating quantitative measures of IFM deterioration at the forefoot and other risk factors for deformity development will help our understanding of the role of IFM deterioration and could potentially guide treatment options focusing on strengthening these muscles as either a preventative or early intervention measure against the impairment cascade of foot deformity, neuropathic plantar ulceration, and lower extremity amputation.

Deterioration of IFMs may contribute to MTPJ deformity in several ways. The increased muscle atrophy and IMAT infiltration into the IFM compartment may destabilize the MTPJ because the weakened flexion force can no longer control the extension force provided by the extensor digitorum longus (EDL) muscle. Limited control of MTPJ extension during gait and the high forces experienced by the second MTPJ during push-off result in increased tendon and ligament plastic deformation on the plantar surface of the MTPJ. With no major antagonists to extension, the proximal phalanx moves into hyperextension, causing the metatarsal head to be prominent on the plantar foot, exposed to repetitive, excessive pressures (Lavery et al., 1998). Previous studies have shown that DMPN subjects experience 36% higher peak plantar pressures (PPP) and 143% higher peak pressure gradients (defined as the spatial change in plantar pressure around the PPP location) in the forefoot than in the rearfoot during shod walking (Mueller, et al., 2005; Zou et al., 2007). These results provide some support for this hypothesis, but also suggest other factors, such as limited ankle dorsiflexion joint mobility, are important. IFM deterioration coupled with limited ankle joint mobility may result in a MTPJ hyperextension movement pattern during functional activities (Kwon et al., 2009). This movement pattern is defined as a substantial increase in MTPJ extension with active ankle dorsiflexion. The EDL may be recruited to assist in dorsiflexion of the stiff ankle joint and concurrent extension of the toes, raising the height of the toes and shortening foot length to aid in clearing the toes during swing. However, repetition of this movement pattern, particularly in those with poor MTPJ stability from IFM deterioration,

may lead to MTPJ deformity. We plan to use multi-segmental lower extremity kinematics to examine the association of this proposed movement pattern with limited ankle joint mobility and MTPJ deformity during walking and other functional activities.

ADL subscale scores of function were decreased over 30% in the DMPN subjects, which is expected when compared against healthy controls. The complications of the diabetic neuropathic foot are common and debilitating; physical performance suffers as the risk for ulceration and amputation increases over time without proactive interventions (Boulton et al., 2008). IFM deterioration was not associated with the ADL subscale score though, suggesting that the ratio may not be a good predictor of reported total foot function. The ADL assesses performance of activities not always specific to the IFM. While questions of the ability to perform heel raises, walk on uneven ground, and stair climb would be expected to be affected by IFM deterioration, questions of personal care, home responsibilities, and push-pull exercises would not.

Another interesting result of this study was that IFM deterioration was about 5 times greater in the DMPN group compared to the control group, and 2 times greater in those with DMPN and a history of ulcers group compared to those with DMPN without a history of ulcers (Table 2). Given that there were no differences in MTPJ angle between the groups with and without a history of ulcers, future research should consider a quantifiable measure of IFM volume deterioration as an indicator of general foot deterioration and risk for skin breakdown.

There are several limitations to consider in this study. The cross-sectional design only allowed for correlations and not cause-and-effect relationships. Lateral radiographs can be difficult to use for making alignment measures because they are only a two dimensional representation of a three dimensional deformity, and superimposed bones can make identifying individual structures challenging. The DMPN subjects that participated were from an ongoing study investigating midfoot deformity that did not recruit based on the presence of MTPJ hyperextension deformity. This deformity does not occur in all subjects with DM and PN, and those with medial column deformity may have a different pattern of deformity development that does not include the toes (Table 1). However, these DMPN subjects provided a continuous spectrum of MTPJ angle measures and IFM deterioration. Future work on these individuals will determine the relationships between IFM deterioration, clinical measures of medial column deformity (i.e. Meary's angle, calcaneal pitch), and changes in gait and functional task kinematics. Because the MR scans of the patients did not extend past the tarsometatarsal joint, IFM deterioration was not measured in the forefoot. Due to its proximity to the MTPJs, forefoot IFM deterioration may have a stronger relationship to MTPJ angle than midfoot and hindfoot muscle deterioration, and deserves additional study to determine if deformities are related to regional deterioration. Lastly, although a battery of tests was used to measure severity of PN (Semmes-Weinstein monofilaments, biothesiometer, tuning fork) we did not use a composite score to help characterize the sample as has been described by others (Richardson, 2002; Herman et al., 2012).

CONCLUSIONS

The results of this study show that participants with diabetes and neuropathy have increased IFM deterioration, which was associated with second MTPJ angle hyperextension and a history of ulceration. Additional research is required to understand how IFM deterioration interacts with impairments leading to forefoot deformity and skin breakdown.

Acknowledgments

We would like to acknowledge the assistance of Dr. John Kotyk in developing the MR scanning protocol for the foot.

We acknowledge funding support from grant numbers T32 HD007434, K12 HD055931, and R24HD050837 from grant sponsor National Center for Medical Rehabilitation Research of the National Institute of Child Health and Human Development of the National Institutes of Health and by grant number UL1 RR024992 from the grant sponsor National Center for Advancing Translational Sciences of the National Institutes of Health.

REFERENCES

- Aguiari P, Leo S, Zavan B, Vindigni V, Rimessi A, Bianchi K, et al. High glucose induces adipogenic differentiation of muscle-derived stem cells. *PNAS*. 2008; 105:1226–1231. [PubMed: 18212116]
- Ahroni JH, Boyko EJ, Forsberg RC. Clinical correlates of plantar pressure among diabetic veterans. *Diabetes Care*. 1999; 22:965–972. [PubMed: 10372250]
- Andersen H, Gjerstad MD, Jakobsen J. Atrophy of foot muscles: a measure of diabetic neuropathy. *Diabetes Care*. 2004; 27:2382–2385. [PubMed: 15451904]
- Andreassen CS, Jakobsen J, Ringgaard S, Ejksjaer N, Andersen H. Accelerated atrophy of lower leg and foot muscles- a follow-up study of long-term diabetic polyneuropathy using magnetic resonance imaging (MRI). *Diabetologia*. 2009; 52:1182–1191. [PubMed: 19280173]
- Boulton AJ. The pathogenesis of diabetic foot problems: an overview. *Diabet Med*. 1996; 13(Suppl 1):S12–16. [PubMed: 8741822]
- Boulton AJ, Armstrong DG, Albert SF, Frykberg RG, Hellman R, Kirkman MS, et al. Comprehensive foot examination and risk assessment: a report of the task force of the foot care interest group of the American diabetes association, with endorsement by the American association of clinical endocrinologists. *Diabetes Care*. 2008; 31:1679–1685. [PubMed: 18663232]
- Boyko EJ, Ahroni JH, Stensel V, Forsberg RC, Davignon DR, Smith DG. A prospective study of risk factors for diabetic foot ulcer. The Seattle Diabetic Foot Study. *Diabetes Care*. 1999; 22:1036–1042. [PubMed: 10388963]
- Bus SA, Yang QX, Wang JH, Smith MB, Wunderlich R, Cavanagh PR. Intrinsic muscle atrophy and toe deformity in the diabetic neuropathic foot: a magnetic resonance imaging study. *Diabetes Care*. 2002; 25:1444–1450. [PubMed: 12145248]
- Bus SA, Maas M, de Lange A, Michels RP, Levi M. Elevated plantar pressures in neuropathic diabetic patients with claw/hammer toe deformity. *J Biomech*. 2005; 38:1918–1925. [PubMed: 16023481]
- Bus SA, Maas M, Michels RPJ, Levi M. Role of intrinsic muscle deterioration in the etiology of claw toe deformity in diabetic neuropathy may not be as straightforward as widely believed. *Diabetes Care*. 2009; 32:1063–1067. [PubMed: 19279305]
- Centers for Disease Control and Prevention. National diabetes fact sheet: national estimates and general information on diabetes and prediabetes in the United States, 2011. U.S. Department of Health and Human Services, Centers for Disease Control and Prevention; 2011. p. 1-12.2011
- Cheuy VA, Commean PK, Hastings MK, Mueller MJ. Reliability and validity of a MR-based volumetric analysis of the intrinsic foot muscles. *J. Magn. Reson. Imaging*. 2013 doi: 10.1002/jmri.24069.
- Commean PK, Tuttle LJ, Hastings MK, Strube MJ, Mueller MJ. Magnetic resonance imaging measurement reproducibility for calf muscle and adipose tissue volume. *J. Magn. Reson. Imaging*. 2011; 34:1285–1294. [PubMed: 21964677]
- Diamond JE, Mueller MJ, Delitto A, Sinacore DR, Rose SJ. Reliability of a diabetic foot evaluation. *Phys. Ther*. 1989; 69:797–802. [PubMed: 2780806]
- Fortin PT, Myerson MS. Second metatarsophalangeal joint instability. *Foot Ankle Int*. 1995; 16:306–313. [PubMed: 7633590]
- Herman WH, Pop-Busui R, Braffett BH, Martin CL, Cleary PA, Albers JW, et al. Use of the Michigan Neuropathy Screening Instrument as a measure of distal symmetrical peripheral neuropathy in Type 1 diabetes: results from the Diabetes Control and Complications Trial/Epidemiology of Diabetes Interventions and Complications. *Diabet. Med*. 2012; 29:937–944. [PubMed: 22417277]

- Jonson SR, Gross MT. Intraexaminer reliability, interexaminer reliability, and mean values for nine lower extremity skeletal measures in healthy naval midshipmen. *J. Orthop. Sports Phys. Ther.* 1997; 25:253–263. [PubMed: 9083944]
- Kwon OY, Tuttle LJ, Johnson JE, Mueller MJ. Muscle imbalance and reduced ankle joint motion in people with hammer toe deformity. *Clin. Biomech.* 2009; 24:670–675.
- Lavery LA, Armstrong DG, Vela SA, Quebedeaux TL, Fleischli JG. Practical criteria for screening patients at high risk for diabetic foot ulceration. *Arch. Intern. Med.* 1998; 158:157–162. [PubMed: 9448554]
- Lavery LA. Effectiveness and safety of elective surgical procedures to improve wound healing and reduce re-ulceration in diabetic patients with foot ulcers. *Diabetes Metab. Res. Rev.* 2012; 28(Suppl 1):60–63. [PubMed: 22271725]
- Martin RL, Irrgang JJ, Burdett RG, Conti SF, Van Swearingen JM. Evidence of Validity for the Foot and Ankle Ability Measure (FAAM). *Foot & Ankle Int.* 2005; 26:968–983.
- Menz HB, Munteanu SE. Validity of 3 clinical techniques for the measurement of static foot posture in older people. *J. Orthop. Sports Phys Ther.* 2005; 35:479–486. [PubMed: 16187508]
- Mizel MS, Yodlowski ML. Disorders of the lesser metatarsophalangeal joints. *J. Am. Acad. Orthop. Surg.* 1995; 3:166–173. [PubMed: 10790665]
- Mueller MJ, Zou D, Lott DJ. “Pressure gradient” as an indicator of plantar skin injury. *Diabetes Care.* 2005; 28:2908–2912. [PubMed: 16306553]
- Reiber GE, Vileikyte L, Boyko EJ, del Aguila M, Smith DG, Lavery LA, et al. Causal pathways for incident lower-extremity ulcers in patients with diabetes from two settings. *Diabetes Care.* 1999; 22:157–162. [PubMed: 10333919]
- Richardson JK. The clinical identification of peripheral neuropathy among older persons. *Arch Phys Med Rehabil.* 2002; 83:1553–1558. [PubMed: 12422324]
- Robertson DD, Mueller MJ, Smith KE, Commean PK, Pilgram T, Johnson JE. Structural changes in the forefoot of individuals with diabetes and a prior plantar ulcer. *J. Bone Joint Surg. Am.* 2002; 84-A:1395–1404. [PubMed: 12177270]
- Van Schie CH, Vermigli C, Carrington AL, Boulton AJ. Muscle weakness and foot deformities in diabetes: relationship to neuropathy and foot ulceration in caucasian diabetic men. *Diabetes Care.* 2004; 27:1668–1673. [PubMed: 15220244]
- Vettor R, Milan G, Franzin C, Sanna M, De Coppi P, Rizzuto R, et al. The origin of intermuscular adipose tissue and its pathophysiological implications. *Am. J. Physiol. Endocrinol. Metab.* 2009; 297:987–998.
- Zou D, Mueller MJ, Lott DJ. Effect of peak pressure and pressure gradient on subsurface shear stresses in the neuropathic foot. *J. Biomech.* 2007; 40:883–890. [PubMed: 16677657]

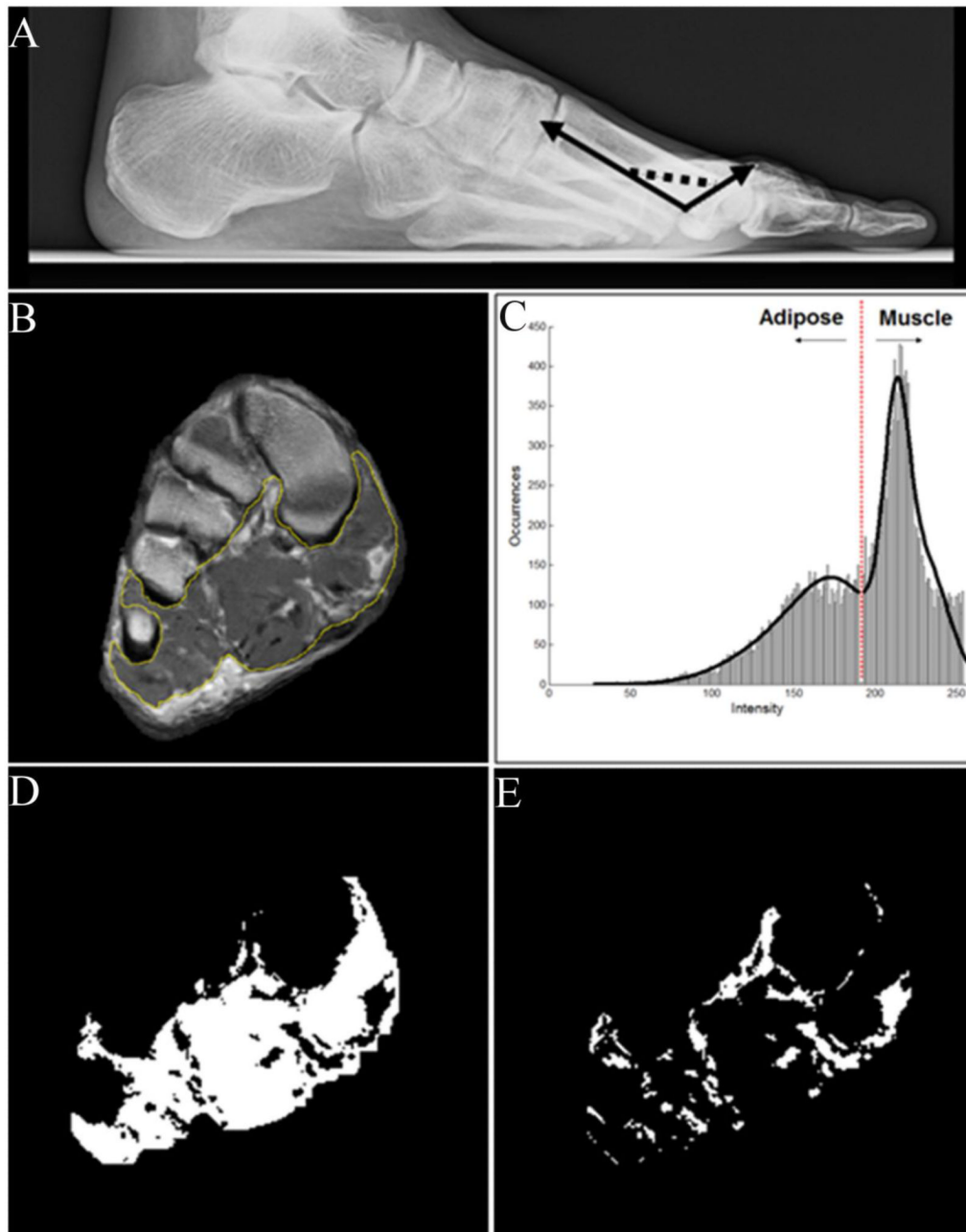
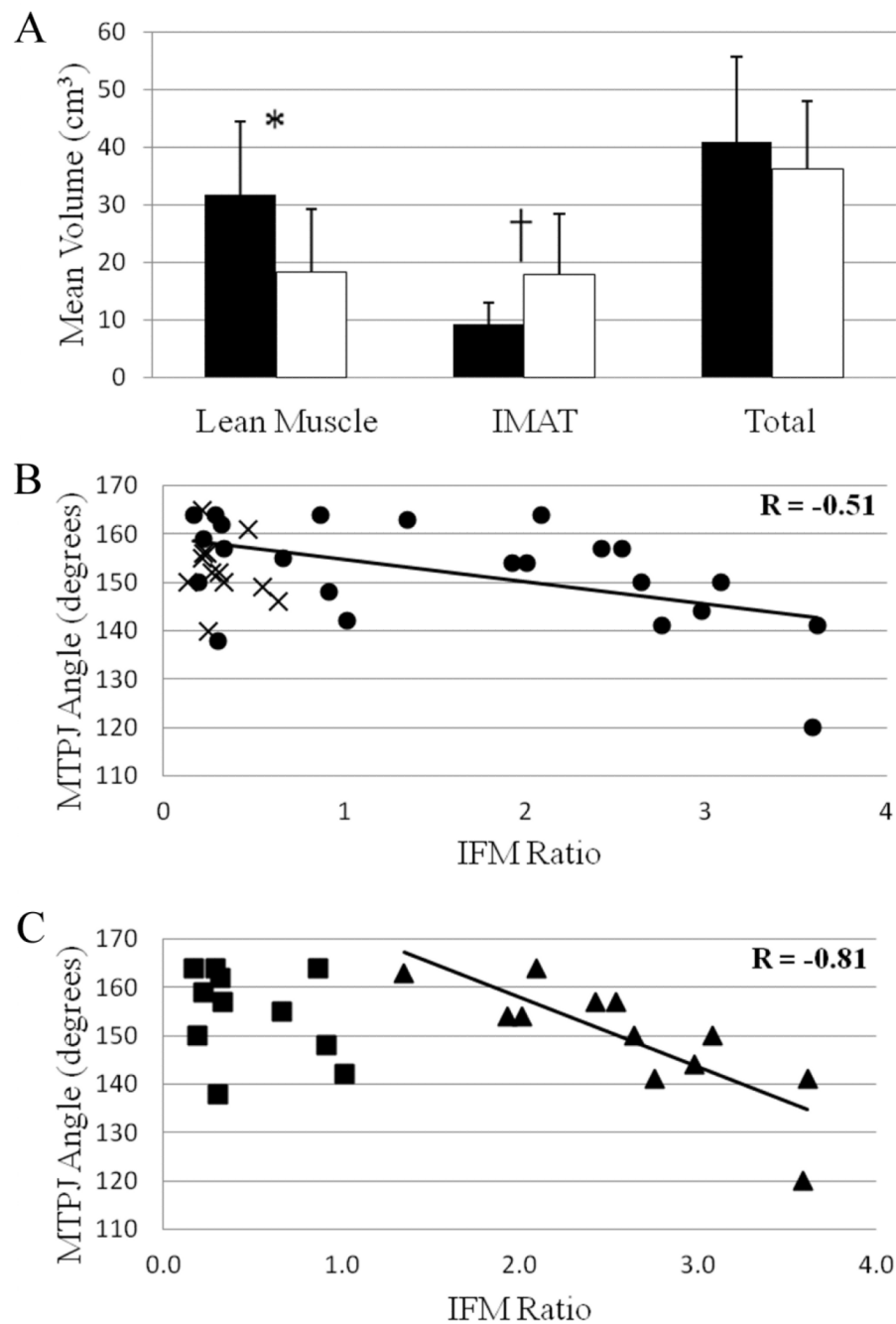


Figure 1.

A) Lateral radiograph measure of the second metatarsophalangeal joint angle. B) Example MR image with the intrinsic foot muscle group highlighted. C) Histogram of signal intensities with the multiple-Gaussian-functions fitting algorithm applied. D) Lean muscle tissue and E) adipose volumes calculated as determined by the threshold between tissue types.

**Figure 2.**

A) Mean volume of lean muscle, adipose tissue, and total intrinsic foot muscle from the hindfoot to the midfoot (Black bars = control group, white bars = DMPN group. * $P = 0.003$, † $P = 0.001$ between groups). B) Scatter plot of the second metatarsophalangeal joint (MTPJ) angle versus the IFM ratio (IMAT / lean muscle volume) for the control (X) and DMPN (●) subjects, including regression line and R^2 of correlation for the DMPN group. C) Scatter plot of the MTPJ angle versus the IFM deterioration ratio for DMPN subjects with a ratio ≤ 1.0 (■) and with a ratio > 1.0 (▲), including regression line and R^2 of correlation in the > 1.0 subgroup.

Table 1

Subject characteristics.

	Control (n = 12)	DMPN (n = 23)
Age (yrs)	57 (14)	59 (10)
Sex (male/female)	8/4	14/9
Type 1 / Type 2 DM	–	3 / 20
Duration of DM (yrs)	–	18 (10)
Vibration perception threshold- biothesiometer (L / R)		
Plantar great toe (V)	18 (12) / 22 (15)	43 (13) / 41 (13)
1 st metatarsal head (V)	15 (9) / 21 (15)	40 (14) / 40 (13)
Vibration sense present- tuning fork (L / R)		
1 st metatarsal head	12 / 12	6 / 7
Joint position sense present (L / R)		
Great toe	12 / 12	14 / 14
Ankle joint	12 / 12	20 / 23
History of Ulceration	–	8
Medial Column Deformity	–	11
Target Foot (L / R)	5 / 7	11 / 12
Height (cm)	174 (12)	173 (9)
Weight (kg)	108 (30)	109 (27)
BMI (kg/m ²)	35 (8)	36 (8)
HbA1c (%)	5.7 (0.3)	8.0 (2.1)

Table 2

Control and DMPN group differences.

	Control		DMPN	
	<i>Total</i> (<i>n</i> = 12)	<i>Total</i> (<i>n</i> = 23)	<i>History of Ulcers</i> (<i>n</i> = 8)	<i>No History of Ulcers</i> (<i>n</i> = 15)
IFM Ratio	0.3 (0.2)	1.6 (1.2)*	2.2 (1.0)	1.2 (1.1) [†]
MTPJ Angle (deg)	153 (7)	152 (11)	149 (14)	154 (9)
FAAM (ADL subscale %)	98.3 (3.3)	65.1 (24.4)*	60.0 (18.5)	67.9 (27.1)

* P < 0.01 compared to controls;

[†] P < 0.05 compared to DMPN with history of ulcers.

Table 3

Individuals with DMPN and a history of ulceration.

Foot Ulcer Location	IFM Ratio	MTPJ Angle (degrees)
1 st metatarsal head	2.9	144
1 st & 5 th metatarsal heads	3.6	120
Cuboid	2.7	141
Information unavailable	2.6	150
Heel & Hallux	2.4	157
Hallux	1.9	154
Medial side	1.3	163
Information unavailable	0.3	164