

# UC Davis

## UC Davis Previously Published Works

### Title

An Update on Feline Chronic Gingivostomatitis.

### Permalink

<https://escholarship.org/uc/item/5cc4c1h4>

### Journal

The Veterinary clinics of North America. Small animal practice, 50(5)

### ISSN

0195-5616

### Authors

Lee, Da Bin  
Verstraete, Frank JM  
Arzi, Boaz

### Publication Date

2020-09-01

### DOI

10.1016/j.cvsm.2020.04.002

Peer reviewed



Since January 2020 Elsevier has created a COVID-19 resource centre with free information in English and Mandarin on the novel coronavirus COVID-19. The COVID-19 resource centre is hosted on Elsevier Connect, the company's public news and information website.

Elsevier hereby grants permission to make all its COVID-19-related research that is available on the COVID-19 resource centre - including this research content - immediately available in PubMed Central and other publicly funded repositories, such as the WHO COVID database with rights for unrestricted research re-use and analyses in any form or by any means with acknowledgement of the original source. These permissions are granted for free by Elsevier for as long as the COVID-19 resource centre remains active.

# An Update on Feline Chronic Gingivostomatitis

Da Bin Lee, DVM<sup>a</sup>, Frank J.M. Verstraete, DrMedVet, MMedVet<sup>a,b</sup>, Boaz Arzi, DVM<sup>b,\*</sup>

## KEYWORDS

- Feline • Gingivostomatitis • Surgical therapy • Medical therapy • Oral mucosa • Inflammation

## KEY POINTS

- Feline chronic gingivostomatitis seems to be a manifestation of an aberrant immune response to chronic antigenic stimulation.
- Multicat environments play an important role and are associated with this multifactorial disease.
- The current standard of care involves dental extractions of at least all premolar and molar teeth, with or without medical management, rather than medical therapy alone.
- Future regenerative therapies, currently in development, show promise for management of feline chronic gingivostomatitis.

## INTRODUCTION

Feline chronic gingivostomatitis (FCGS) is a severe, immune-mediated, oral mucosal inflammatory disease of cats. The typical location of the ulcerative and/or proliferative inflammatory lesions is lateral to the palatoglossal folds, previously referred to as the fauces.<sup>1–3</sup> Clinically, a proliferative and ulcerative phenotype of the disease can be observed (Fig. 1). Occasionally, the proliferative form of the disease is so severe as to prevent retraction of the tongue (Fig. 2). Although FCGS is a familiar condition encountered in veterinary practice, with a reported prevalence ranging from 0.7% to 12.0%,<sup>4–6</sup> there is much confusion regarding the cause and subsequent treatment of the disease.<sup>6,7</sup> This article reviews the current knowledge on the etiopathogenesis of FCGS and describes the leading treatment modalities.

## ETIOPATHOGENESIS

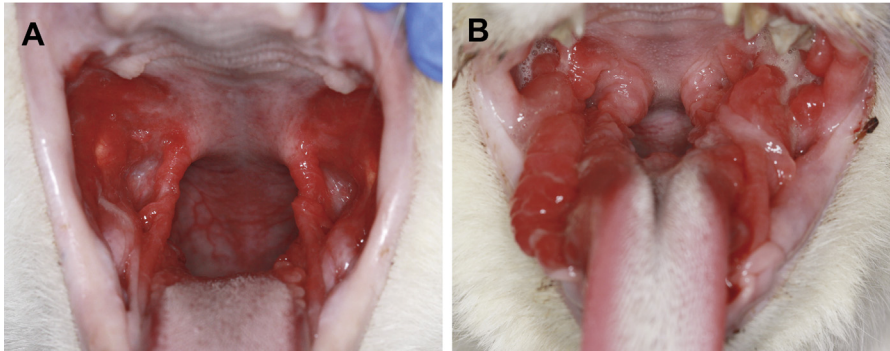
The cause of FCGS remains elusive despite extensive investigations. A multitude of conditions and infectious agents have been implicated without proof of causation,

---

<sup>a</sup> Dentistry and Oral Surgery Service, William R. Pritchard Veterinary Medical Teaching Hospital, University of California - Davis, 1 Garrod Drive, Davis, CA 95616, USA; <sup>b</sup> Department of Surgical and Radiological Sciences, School of Veterinary Medicine, University of California - Davis, 1 Garrod Drive, Davis, CA 95616, USA

\* Corresponding author.

E-mail address: [barzi@ucdavis.edu](mailto:barzi@ucdavis.edu)



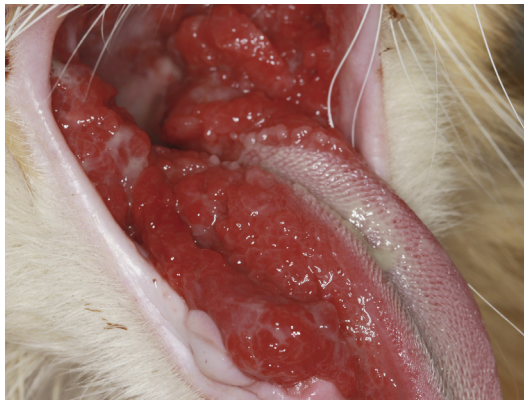**Fig. 1.** The hallmark of FCGS is inflammation in the caudal oral cavity in the area lateral to the palatoglossal folds. Ulcerative (A) and proliferative (B) phenotypes can be observed.

including infectious pathogens such as feline calicivirus (FCV), feline herpesvirus (FHV-1), feline immunodeficiency virus (FIV), feline leukemia virus (FeLV), and various bacteria, as well as noninfectious factors such as dental disease, environmental stress, and hypersensitivity.<sup>8–23</sup> Little or no new information has been forthcoming in this regard.

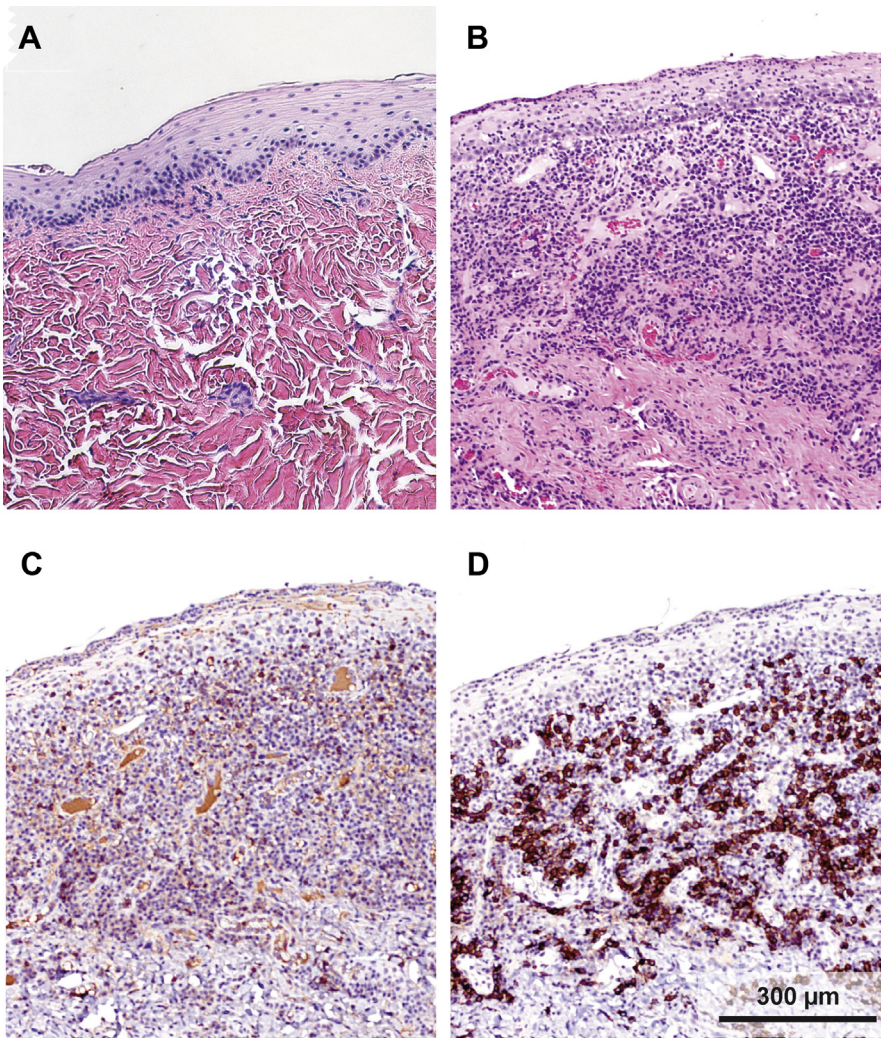
#### ***Systemic and Local Consequences of Feline Chronic Gingivostomatitis***

The chronic inflammatory nature of the disease is suggested by the predominant presence of lymphocytes and plasma cells in affected oral tissues, with fewer neutrophils, Mott cells, and mast cells.<sup>24,25</sup> Immunohistochemical staining has revealed the infiltration of cluster of differentiation (CD) 3+ T lymphocytes within the epithelium and subepithelial stroma, and restriction of CD20+ B lymphocytes mainly to the subepithelial stroma (**Fig. 3**).<sup>26,27</sup>

Increased levels of CD8+ (cytotoxic) T cells, compared with CD4+ (helper) T cells, have been detected locally as well as in the systemic circulation, suggesting that the inflammatory response seen in FCGS is a cytotoxic cell-mediated immune response to antigenic stimulation likely from intracellular pathogens such as viruses.<sup>7,26,27</sup>



**Fig. 2.** Occasionally, the proliferative inflammation can be so severe as to prevent the tongue from retracting into its normal and functional position.



**Fig. 3.** On histology, the healthy oral mucosa of cats is composed of squamous epithelium with a rare presence of inflammatory cells (A). However, in cats affected by FCGS, ulceration of the squamous epithelium is observed with profound inflammatory infiltration comprising mostly granulocytes, lymphocytes, plasma cells, and mast cells (B) (hematoxylin-eosin [H&E] staining, original magnification  $\times 10$ ). Immunohistochemistry of FCGS mucosal inflammation indicates that most of the T lymphocytes (CD3 cells) are present in the epithelium (C) and most of the B lymphocytes (CD20 cells) are present in the submucosa (D) (original magnification  $\times 10$ ).

Moreover, in 2 studies, a decreased CD4/CD8 ratio was found in most cats diagnosed with FCGS, with a normal percentage of CD4+ T cells and an increased percentage of CD8+ T cells in circulation.<sup>26,27</sup> In humans, a low CD4/CD8 ratio is typically associated with immune dysfunction, immune senescence, and chronic inflammation, and is seen in immunodeficiency or autoimmune diseases such as human immunodeficiency virus/acquired immunodeficiency syndrome, systemic lupus erythematosus, and

neoplasia, supporting the notion that an aberrant immune response is also involved in FCGS.<sup>28</sup> Interestingly, systemic administration of autologous mesenchymal stem cells (MSCs) in cats has been shown to normalize the CD4/CD8 ratio because of normalization of the percentage of CD8+ T cells, reinforcing the finding that CD8+ T cells play a noteworthy role in the pathophysiology of FCGS.<sup>27</sup>

### **Potential Viral Causes**

---

FCV, FHV-1, FIV, and FeLV have been implicated in FCGS. Demonstration of causal relationships have not been successful, but, of these agents, FCV seems to have the most consistent evidence of being associated with FCGS.<sup>9,12,18–20,29–31</sup> A recent study found the incidence of FCV to be significantly higher in cats with FCGS (60%) compared with control cats (24%) as well as cats with feline resorptive lesions (23%).<sup>32</sup> Regardless, well-known risk factors for these viruses include free-roaming behavior and living in multicat environments such as shelters, shared households, and breeding catteries. This finding is worth exploring given that the etiopathogenesis of FCGS is likely multifactorial.

### **Environmental Stressors**

---

A recent study investigated the association of multicat environments and outdoor access with the prevalence of FCGS.<sup>33</sup> It was revealed that the prevalence of FCGS was higher in multicat than single-cat households, and that each additional cat in the household increased the odds of FCGS by more than 70%. Association between outdoor access and FCGS was lacking, suggesting that factors relating to multicat environments may be necessary in addition to an infectious cause to trigger the development of FCGS. Examples mentioned in the article include the favoring of high rates of viral evolution and cyclic reinfections in susceptible individuals caused by chronic exposure to viruses shed by chronic carriers in multicat environments, as well as the stress of living in such environments.<sup>33,34</sup>

### **Feline Chronic Gingivostomatitis and Periodontitis**

---

The association between FCGS and periodontitis has been proved in a retrospective case-control study where full-mouth dental radiographs of 101 cats with FCGS and 101 control cats with other oral diseases were evaluated.<sup>10</sup> This study revealed that not only do cats with FCGS have generalized, advanced periodontitis but they are also significantly more likely to have external inflammatory root resorption. The findings underscore that dental radiography plays an essential role in the diagnosis and evaluation of cats with FCGS, and that the treatment of associated periodontitis, likely contributing to persistent oral inflammation, is integral in the treatment of FCGS.

### **Bacterial Burden in Feline Chronic Gingivostomatitis**

---

Bacterial organisms are thought to play a role in the pathogenesis of FCGS. The oral microbial diversity is less in cats with FCGS than in healthy cats, with the predominant species being *Pasteurella multocida* subsp. *multocida*.<sup>17</sup> Consistent with previous studies, a recent study found higher abundance of gram-negative and anaerobic bacteria in FCGS and periodontitis.<sup>21</sup> The phylum Bacteroidetes and the genus *Peptostreptococcus* were more abundant in cats with FCGS than in healthy cats and cats with periodontitis. The findings suggest that *Filifactor* and *Peptostreptococcus* may play a role in periodontitis of FCGS. In contrast with the study mentioned previously, this study found higher bacterial diversity in the oral microbiota of cats with FCGS and periodontitis, suggesting a possible role of bacterial biofilms in the pathophysiology both of these oral diseases.

### ***Feline Chronic Gingivostomatitis and Esophagitis***

---

It has recently been found that esophagitis seems to occur concurrently with FCGS.<sup>35</sup> In a controlled study involving 58 cats with FCGS, evidence of esophagitis was found via esophagoscopy in 98% of cats with FCGS, compared with control cats. Interestingly, none of the cats showed clinical signs of gastrointestinal disease. In addition, microscopic evidence of inflammation and metaplasia was found on histopathologic evaluation of grossly normal-appearing tissues. Endoscopic reexamination of 2 cats that were treated for FCGS and no longer showed clinical signs of that disease also showed macroscopic healing of esophagitis. One cat that had a relapse of FCGS showed worsening of esophagitis despite appropriate treatment of esophagitis. Prior medications, salivary and esophageal lumen pH, and chronicity of FCGS signs do not correlate with the degree of esophagitis. The investigators speculated that the virulent oral microbiota of cats with FCGS is transmitted to the esophagus via the saliva, where the production of certain proinflammatory cytokines may contribute to the development of esophagitis. In light of the findings of this study, diagnosis and treatment or empiric treatment of esophagitis may be considered in cats affected by FCGS, especially considering that both diseases share some clinical signs (ie, ptyalism, nausea, and inappetence).<sup>35</sup>

### **LEADING TREATMENT MODALITIES**

In general, there are 2 approaches to the treatment of FCGS: surgical and medical. However, on its own, medical treatment typically does not have favorable long-term outcomes, making the current standard of care surgical intervention by means of dental extractions with or without additional medical management. A wide range of therapies has been suggested. However, only the most common and promising (based on scientific evidence) modalities are discussed in this article.

#### ***Pain Management***

---

Regardless of modality, all treatment options require adequate pain management. Appropriate therapy depends on factors including comorbidities (eg, renal or hepatic disease), concurrent medications being administered (eg, corticosteroids), patient compliance, and the owner's perception of oral pain. Typically, long-term pain management includes administration of opioids (eg, buprenorphine) complemented with gabapentin. A recent randomized, prospective, blinded, controlled, crossover study showed that buccal administration of buprenorphine had a significant effect on reducing pain scores with low interindividual variations in plasma concentration in cats with FCGS.<sup>36</sup>

#### ***Surgical Treatment***

---

A few studies have shown that partial- (all premolar and molar teeth) or full-mouth extraction provides the best long-term results.<sup>37–39</sup> These studies report substantial improvement or resolution of FCGS in approximately 70% to 80% of cats, with approximately 20% to 30% of cats showing minimal or no improvement.

A retrospective case series involving 95 cats with FCGS treated with full-mouth or partial-mouth extractions with concurrent medical management revealed that 28.4% of cats achieved complete resolution, 39% achieved substantial clinical improvement, 26.3% had little improvement, and 6.3% had no improvement (refractory).<sup>37</sup> Of the patients that achieved substantial improvement or complete resolution, most (68.8%) required medical management with antimicrobial, antiinflammatory, or analgesic medications for a finite period after the 2-week immediate postoperative

period. Those that had little or no improvement still required medical management at the final recheck examination. A more recent study of 56 cats treated with dental extractions for FCGS showed that 51.8% achieved clinical cure or very significant improvement within a median time of 38 days.<sup>38</sup>

Moreover, extent of dental extractions seems to have no impact on outcome.<sup>37,38</sup> Therefore, partial-mouth extraction (plus other teeth that independently have indications for extraction, such as severe periodontitis, retained tooth roots, or resorptive lesions) as the first stage of treatment is the highest evidence-based recommendation. It also has the advantages of reduction in anesthetic time, surgeon fatigue, and surgical trauma. If there is no positive response within 1 to 4 months after partial-mouth extraction, full-mouth extractions may be pursued as the second stage of treatment based on the findings of Druet and Hennet.<sup>37</sup>

### **Medical Management**

---

As already mentioned, most cats with FCGS require medical management in addition to surgical treatment, and some depend on lifelong medications. Because FCGS is an immune-mediated inflammatory disease, the basis of medical therapy has been immunosuppression or immunomodulation.<sup>5</sup>

#### **Corticosteroids**

Prednisolone is often used as a short-acting corticosteroid to control inflammation. In a randomized, double-blinded, prospective, controlled study of calicivirus-positive cats with FCGS refractory to dental extractions, it was used as the control (at 1 mg/kg/d tapering over 3 weeks) to recombinant feline interferon omega.<sup>40</sup> In the study, 23% of 11 cats that received treatment with prednisolone achieved substantial improvement, of which 7% achieved clinical remission.<sup>40</sup> Because of the potential deleterious side-effects of long-term corticosteroid administration, it should only be used as needed for symptomatic treatment, on a tapering course.

#### **Recombinant feline interferon omega**

Interferons (IFNs) are a group of signaling proteins that have the ability to interfere with viral replication.<sup>40</sup> Recombinant feline interferon omega (rFeIFN- $\omega$ ) is marketed for use in canine parvovirus, FeLV, and FIV infections. Interferons also have antiviral activity against FHV-1, FCV, and feline coronavirus.<sup>41</sup> Oromucosal absorption of IFN has been shown to stimulate immunomodulation via oropharyngeal lymphoid tissues, whereas gastrointestinal absorption destroys the glycoprotein.<sup>42,43</sup> In a controlled, randomized, double-blinded study of oromucosal administration of rFeIFN- $\omega$  for 3 months in 19 cats, substantial improvement was seen in 45%, of which 10% achieved clinical remission. However, the results were not statistically significant between the 2 groups, implying that rFeIFN- $\omega$  is at least as effective as short-term prednisolone in the treatment of FCV-positive cats with refractory FCGS.<sup>40</sup> A recent controlled study showed that subcutaneous administration of rFeIFN- $\omega$  may be effective for the treatment of FCGS in FCV-positive cats by inhibiting the replication of FCV.<sup>44</sup> Furthermore, a novel rFeIFN (rFeIFN- $\alpha$ 15) has been produced via transgenic silkworms that may carry a lower allergy risk, compared with the baculovirus expression system in silkworms by which the current form of rFeIFN- $\omega$  is produced.<sup>45</sup>

#### **Cyclosporine**

Cyclosporine provides immunosuppressive effects primarily via inhibition of T-cell activation by reducing interleukin-2 expression, a proinflammatory cytokine involved in a positive feedback loop that increases T-cell numbers.<sup>46,47</sup> It may also have inhibitory effects on B-cell reproduction.<sup>48</sup> In a small retrospective case series that



examined the efficacy of oral cyclosporine in 8 cats not previously treated with extractions, 4 (50%) of the cats were reported to achieve clinical remission, whereas the rest had partial to fairly good improvement.<sup>49</sup> In a randomized, controlled, double-blinded, prospective clinical trial where oral cyclosporine was administered to 9 cats that had previously been treated with extractions, there was a statistical significance in the number of cats experiencing significant clinical improvement over the 6-week study period between the treatment group (77.8%) and the placebo group (14.3%).<sup>50</sup> Long-term observation was continued in 11 cats, of which 5 (45.5%) were clinically cured after receiving cyclosporine for 3 or more months.<sup>50</sup>

### **Mesenchymal stem cells**

Mesenchymal stem cells (MSCs) are fibroblastlike, multipotent stem cells that have immunomodulatory effects through inhibition of T-cell proliferation, alteration of B-cell function, downregulation of major histocompatibility complex II on antigen-presenting cells, and inhibition of dendritic cell maturation.<sup>27,51-53</sup> The efficacy of both autologous and allogeneic, fresh, adipose-derived MSCs administered intravenously has been studied in cats with refractory FCGS.<sup>26,27</sup>

Treatment with autologous adipose-derived MSCs in 7 cats resulted in a positive response rate of 71.4% reflected by clinical remission in 42.8%, substantial improvement in 28.6% of the cats, and no response in 28.6% of cats over a follow-up period of 6 to 24 months.<sup>27</sup>

A subsequent clinical trial examining the efficacy of allogeneic adipose-derived MSCs in 7 cats resulted in lower clinical efficacy with delayed clinical and histologic resolution compared with autologous therapy.<sup>26</sup> Of the 7 cats, 28.6% achieved clinical remission, 28.6% achieved substantial improvement, and 42.8% were nonresponders.<sup>26</sup>

Clinical trials involving MSCs are currently ongoing and have expanded into a multicenter study to include control cats and to further investigate mechanism of action, biomarkers, efficacy of therapy before surgical treatment, as well as efficacy in cats with comorbidities<sup>52</sup> (for more on MSC in feline medicine, see Webb's article, "Stem Cell Therapy and Cats: What Do We Know at this Time?" in this issue).

### **SUMMARY**

Although the exact etiopathogenesis of FCGS remains unclear, it seems to be a manifestation of an inappropriate immune response to antigenic stimulation, potentially potentiated or exacerbated by viral infection. Furthermore, environmental stressors such as multicat environments seem to be an important contributing factor. The current first line of treatment involves dental extractions of at least the premolar and molar teeth as opposed to medical therapy alone. Following surgical treatment, outcome can be divided into approximate thirds for cats achieving remission, substantial improvement, and little to no improvement. Most cats that undergo surgical treatment need concurrent medical therapy for control of inflammation, some requiring lifelong medical management. New modalities such as MSC therapy show promise. In addition, the importance of analgesic therapy cannot be overemphasized.

### **DISCLOSURE**

The authors have no financial disclosures to acknowledge.

### **REFERENCES**

1. Available at: <https://avdc.org/avdc-nomenclature/AVDC>. Accessed August 15, 2019.

2. Lommer MJ. Oral inflammation in small animals. *Vet Clin North Am Small Anim Pract* 2013;43(3):555–71.
3. Arzi B, Murphy B, Baumgarth N, et al. Analysis of immune cells within the healthy oral mucosa of specific pathogen-free cats. *Anat Histol Embryol* 2011;40(1):1–10.
4. Healey KA, Dawson S, Burrow R, et al. Prevalence of feline chronic gingivostomatitis in first opinion veterinary practice. *J Feline Med Surg* 2007;9(5):373–81.
5. Winer JN, Arzi B, Verstraete FJM. Therapeutic management of feline chronic gingivostomatitis: a systematic review of the literature. *Front Vet Sci* 2016;3:54.
6. Girard N, Servet E, Biourge V, et al. Periodontal health status in a colony of 109 cats. *J Vet Dent* 2009;26(3):147–55.
7. Harley R, Gruffydd-Jones TJ, Day MJ. Immunohistochemical characterization of oral mucosal lesions in cats with chronic gingivostomatitis. *J Comp Pathol* 2011;144(4):239–50.
8. Lommer MJ, Verstraete FJM. Radiographic patterns of periodontitis in cats: 147 cases (1998-1999). *J Am Vet Med Assoc* 2001;218(2):230–4.
9. Lommer MJ, Verstraete FJM. Concurrent oral shedding of feline calicivirus and feline herpesvirus 1 in cats with chronic gingivostomatitis. *Oral Microbiol Immunol* 2003;18(2):131–4.
10. Farcas N, Lommer MJ, Kass PH, et al. Dental radiographic findings in cats with chronic gingivostomatitis (2002-2012). *J Am Vet Med Assoc* 2014;244(3):339–45.
11. White SD, Rosychuk RA, Janik TA, et al. Plasma cell stomatitis-pharyngitis in cats: 40 cases (1973-1991). *J Am Vet Med Assoc* 1992;200(9):1377–80.
12. Reubel GH, George JW, Higgins J, et al. Effect of chronic feline immunodeficiency virus infection on experimental feline calicivirus-induced disease. *Vet Microbiol* 1994;39(3–4):335–51.
13. Pedersen NC. Inflammatory oral cavity diseases of the cat. *Vet Clin North Am Small Anim Pract* 1992;22(6):1323–45.
14. Diehl K, Rosychuk RA. Feline gingivitis-stomatitis-pharyngitis. *Vet Clin North Am Small Anim Pract* 1993;23(1):139–53.
15. Dolieslager SM, Bennett D, Johnston N, et al. Novel bacterial phylotypes associated with the healthy feline oral cavity and feline chronic gingivostomatitis. *Res Vet Sci* 2013;94(3):428–32.
16. Dolieslager SM, Lappin DF, Bennett D, et al. The influence of oral bacteria on tissue levels of Toll-like receptor and cytokine mRNAs in feline chronic gingivostomatitis and oral health. *Vet Immunol Immunopathol* 2013;151(3–4):263–74.
17. Dolieslager SM, Riggio MP, Lennon A, et al. Identification of bacteria associated with feline chronic gingivostomatitis using culture-dependent and culture-independent methods. *Vet Microbiol* 2011;148(1):93–8.
18. Dowers KL, Hawley JR, Brewer MM, et al. Association of Bartonella species, feline calicivirus, and feline herpesvirus 1 infection with gingivostomatitis in cats. *J Feline Med Surg* 2010;12(4):314–21.
19. Quimby JM, Elston T, Hawley J, et al. Evaluation of the association of Bartonella species, feline herpesvirus 1, feline calicivirus, feline leukemia virus and feline immunodeficiency virus with chronic feline gingivostomatitis. *J Feline Med Surg* 2008;10(1):66–72.
20. Belgard S, Truyen U, Thibault JC, et al. Relevance of feline calicivirus, feline immunodeficiency virus, feline leukemia virus, feline herpesvirus and Bartonella henselae in cats with chronic gingivostomatitis. *Berl Munch Tierarztl Wochenschr* 2010;123(9–10):369–76.

21. Rodrigues MX, Bicalho RC, Fiani N, et al. The subgingival microbial community of feline periodontitis and gingivostomatitis: characterization and comparison between diseased and healthy cats. *Sc Rep* 2019;9(1):12340.
22. Waters L, Hopper CD, Gruffydd-Jones TJ, et al. Chronic gingivitis in a colony of cats infected with feline immunodeficiency virus and feline calicivirus. *Vet Rec* 1993;132(14):340–2.
23. Lee M, Bosward KL, Norris JM. Immunohistological evaluation of feline herpesvirus-1 infection in feline eosinophilic dermatoses or stomatitis. *J Feline Med Surg* 2010;12(2):72–9.
24. Arzi B, Murphy B, Cox DP, et al. Presence and quantification of mast cells in the gingiva of cats with tooth resorption, periodontitis and chronic stomatitis. *Arch Oral Biol* 2010;55(2):148–54.
25. Rolim VM, Pavarini SP, Campos FS, et al. Clinical, pathological, immunohistochemical and molecular characterization of feline chronic gingivostomatitis. *J Feline Med Surg* 2017;19(4):403–9.
26. Arzi B, Clark KC, Sundaram A, et al. Therapeutic efficacy of fresh, allogeneic mesenchymal stem cells for severe refractory feline chronic gingivostomatitis. *Stem Cells Transl Med* 2017;6(8):1710–22.
27. Arzi B, Mills-Ko E, Verstraete FJM, et al. Therapeutic efficacy of fresh, autologous mesenchymal stem cells for severe refractory gingivostomatitis in cats. *Stem Cells Transl Med* 2016;5(1):75–86.
28. McBride JA, Striker R. Imbalance in the game of T cells: what can the CD4/CD8 T-cell ratio tell us about HIV and health? *PLoS Pathog* 2017;13(11):e1006624.
29. Knowles JO, McArdle F, Dawson S, et al. Studies on the role of feline calicivirus in chronic stomatitis in cats. *Vet Microbiol* 1991;27(3–4):205–19.
30. Addie DD, Radford A, Yam PS, et al. Cessation of feline calicivirus shedding coincident with resolution of chronic gingivostomatitis in a cat. *J Small Anim Pract* 2003;44(4):172–6.
31. Poulet H, Brunet S, Soulier M, et al. Comparison between acute oral/respiratory and chronic stomatitis/gingivitis isolates of feline calicivirus: pathogenicity, antigenic profile and cross-neutralisation studies. *Arch Virol* 2000;145(2):243–61.
32. Thomas S, Lappin DF, Spears J, et al. Prevalence of feline calicivirus in cats with odontoclastic resorptive lesions and chronic gingivostomatitis. *Res Vet Sci* 2017; 111:124–6.
33. Peralta S, Carney PC. Feline chronic gingivostomatitis is more prevalent in shared households and its risk correlates with the number of cohabiting cats. *J Feline Med Surg* 2019;21(12):1165–71.
34. Buffington CA. External and internal influences on disease risk in cats. *J Am Vet Med Assoc* 2002;220(7):994–1002.
35. Kouki MI, Papadimitriou SA, Psalla D, et al. Chronic gingivostomatitis with esophagitis in cats. *J Vet Intern Med* 2017;31(6):1673–9.
36. Stathopoulou TR, Kouki M, Pypendop BH, et al. Evaluation of analgesic effect and absorption of buprenorphine after buccal administration in cats with oral disease. *J Feline Med Surg* 2018;20(8):704–10.
37. Jennings MW, Lewis JR, Soltero-Rivera MM, et al. Effect of tooth extraction on stomatitis in cats: 95 cases (2000–2013). *J Am Vet Med Assoc* 2015;246(6):654–60.
38. Druet I, Hennet P. Relationship between feline calicivirus load, oral lesions, and outcome in feline chronic gingivostomatitis (caudal stomatitis): retrospective study in 104 cats. *Front Vet Sci* 2017;4:209.
39. Hennet P. Chronic gingivo-stomatitis in cats: long-term follow-up of 30 cases treated by dental extractions. *J Vet Dent* 1997;14:15–21.

40. Hennes PR, Camy GA, McGahie DM, et al. Comparative efficacy of a recombinant feline interferon omega in refractory cases of calicivirus-positive cats with caudal stomatitis: a randomised, multi-centre, controlled, double-blind study in 39 cats. *J Feline Med Surg* 2011;13(8):577–87.
41. Ueda Y, Sakurai T, Kasama K, et al. Pharmacokinetic properties of recombinant feline interferon and its stimulatory effect on 2',5'-oligoadenylate synthetase activity in the cat. *J Vet Med Sci* 1993;55(1):1–6.
42. Cummins JM, Krakowka GS, Thompson CG. Systemic effects of interferons after oral administration in animals and humans. *Am J Vet Res* 2005;66(1):164–76.
43. Schellekens H, Geelen G, Meritet JF, et al. Oromucosal interferon therapy: relationship between antiviral activity and viral load. *J Interferon Cytokine Res* 2001;21(8):575–81.
44. Matsumoto H, Teshima T, Iizuka Y, et al. Evaluation of the efficacy of the subcutaneous low recombinant feline interferon-omega administration protocol for feline chronic gingivitis-stomatitis in feline calicivirus-positive cats. *Res Vet Sci* 2018;121:53–8.
45. Minagawa S, Nakaso Y, Tomita M, et al. Novel recombinant feline interferon carrying N-glycans with reduced allergy risk produced by a transgenic silkworm system. *BMC Vet Res* 2018;14(1):260.
46. Robson D. Review of the properties and mechanisms of action of cyclosporine with an emphasis on dermatological therapy in dogs, cats and people. *Vet Rec* 2003;152(25):768–72.
47. Matsuda S, Koyasu S. Mechanisms of action of cyclosporine. *Immunopharmacology* 2000;47(2–3):119–25.
48. Winslow MM, Gallo EM, Neilson JR, et al. The calcineurin phosphatase complex modulates immunogenic B cell responses. *Immunity* 2006;24(2):141–52.
49. Vercelli A, Raviri G, Cornegliani L. The use of oral cyclosporin to treat feline dermatoses: a retrospective analysis of 23 cases. *Vet Dermatol* 2006;17(3):201–6.
50. Lommer MJ. Efficacy of cyclosporine for chronic, refractory stomatitis in cats: A randomized, placebo-controlled, double-blinded clinical study. *J Vet Dent* 2013;30(1):8–17.
51. Clark KC, Fierro FA, Ko EM, et al. Human and feline adipose-derived mesenchymal stem cells have comparable phenotype, immunomodulatory functions, and transcriptome. *Stem Cell Res Ther* 2017;8(1):69.
52. Quimby JM, Borjesson DL. Mesenchymal stem cell therapy in cats: Current knowledge and future potential. *J Feline Med Surg* 2018;20(3):208–16.
53. Taechangam N, Iyer SS, Walker NJ, et al. Mechanisms utilized by feline adipose-derived mesenchymal stem cells to inhibit T lymphocyte proliferation. *Stem Cell Res Ther* 2019;10(1):188.