

UC Davis

Dermatology Online Journal

Title

Persistent blaschkitis responsive to high potency topical steroids

Permalink

<https://escholarship.org/uc/item/2vg933vz>

Journal

Dermatology Online Journal, 21(11)

Authors

Liddell, Lucette Teel
Matinpour, Keyan
Mir, Mohsin
[et al.](#)

Publication Date

2015

DOI

10.5070/D32111029287

Copyright Information

Copyright 2015 by the author(s). This work is made available under the terms of a Creative Commons Attribution-NonCommercial-NoDerivatives License, available at <https://creativecommons.org/licenses/by-nc-nd/4.0/>

Peer reviewed

Case presentation

Persistent blaschkitis responsive to high potency topical steroids

Lucette Teel Liddell BA¹, Keyan Matinpour MD¹, Mohsin Mir MD¹, Colt McCain MD², Abdul Hafeez Diwan MD²

Dermatology Online Journal 21 (11): 7

¹Departments of Dermatology, and ²Pathology Baylor College of Medicine, Houston, Texas

Correspondence:

Keyan Matinpour, MD
Dermatology Resident
1977 Butler Blvd, Suite E6.200
Houston, Texas 77030
kmatinpour@gmail.com

Abstract

Blaschkitis is an acquired, rare dermatosis distributed along the lines of Blaschko. The papulovesicular eruption generally resolves in weeks and shows minimal response to topical steroids. Herein, we present a case of blaschkitis in an adult male who had lesions present for one year, which showed significant improvement after two weeks of topical clobetasol ointment.

Keywords: blaschkitis, blaschko's lines, lichen striatus

Case synopsis

A 30-year-old man presented with a one-year history of an occasionally pruritic rash on his left back, arm, and hand. Physical exam disclosed multiple skin-colored papules coalescing into a whorled and linear plaque extending from the left back to the left arm. Punch biopsy was performed. Histopathologic examination revealed nonspecific spongiotic and perivascular dermatitis with eosinophils.

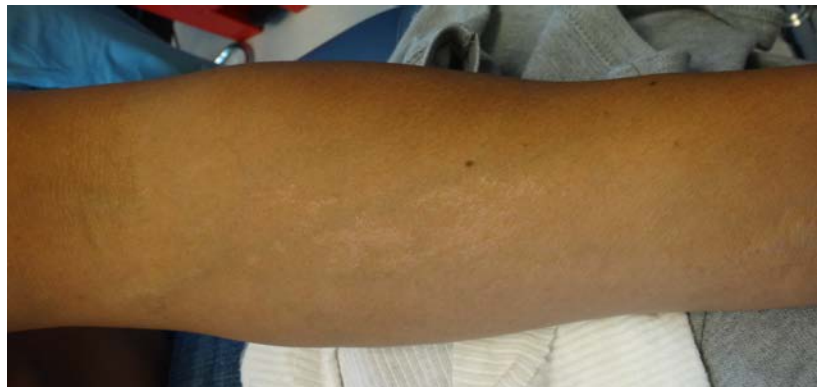
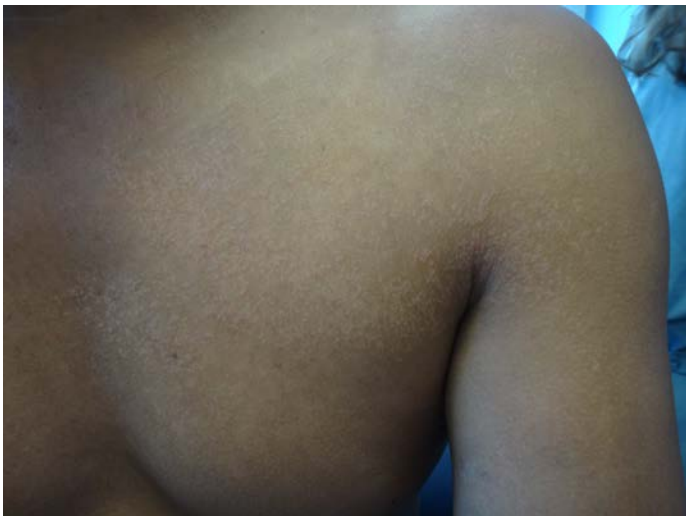
Figure 1. Multiple skin colored to hypopigmented , 1-3mm papules coalescing into plaques on the left upper chest and shoulder.**Figure 2.** Multiple skin colored to hypopigmented , 1-3mm papules coalescing into plaques on the left forearm.

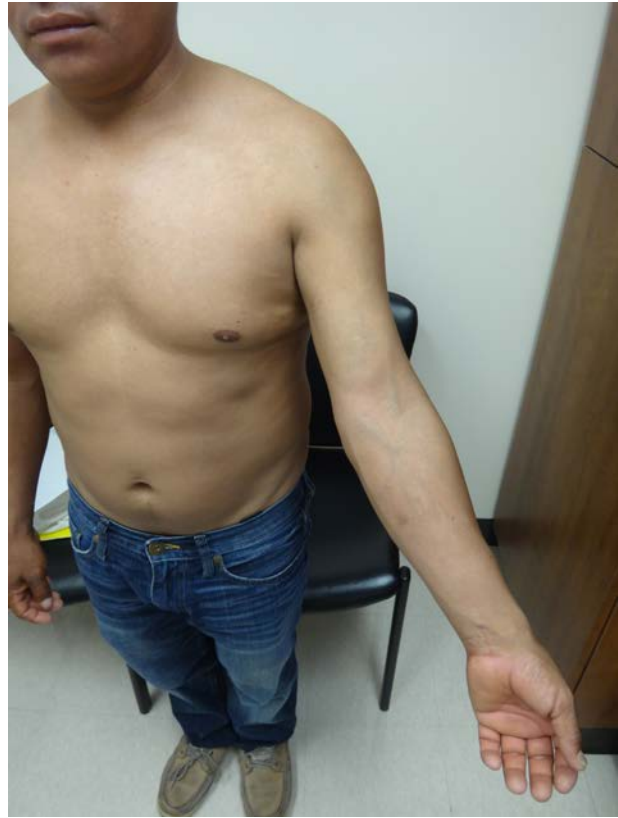
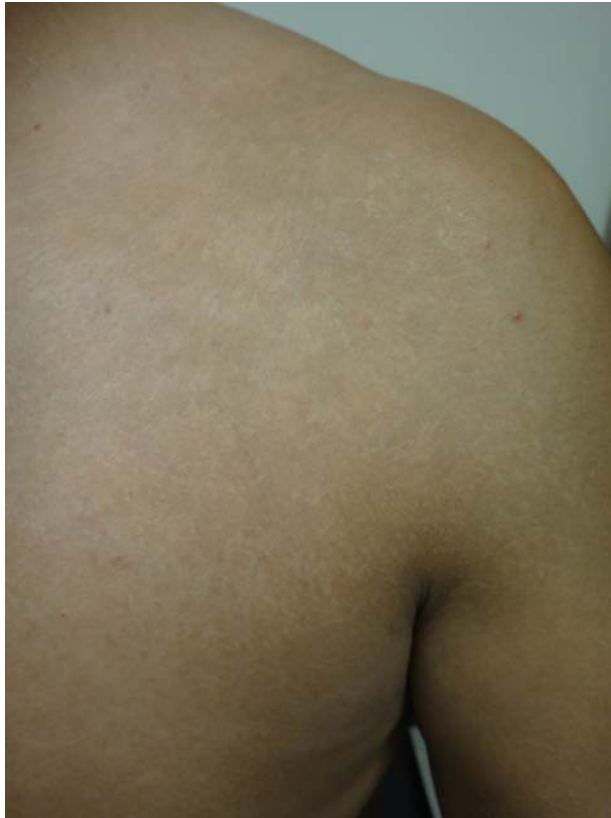
Figure 3. Multiple hypopigmented , 1-3mm macules and papules coalescing into patches and plaques on the left chest. **Figure 4.** Multiple hypopigmented , 1-3mm macules and papules coalescing into patches and plaques on the left chest, upper arm and forearm.

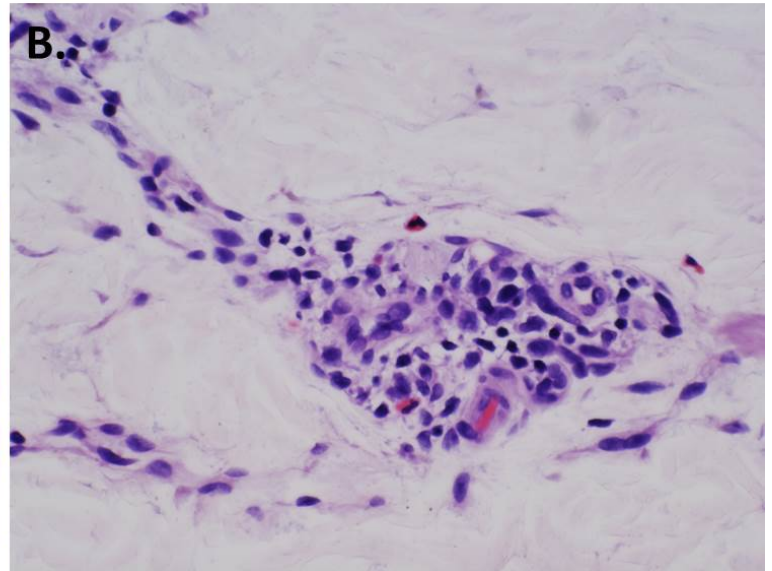
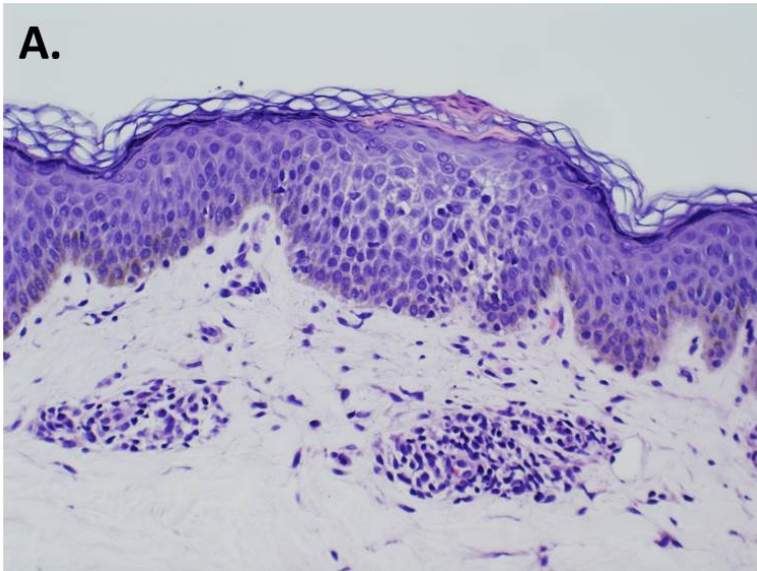


Figure 5. The punch biopsy highlighted focal epidermal spongiosis and a mild superficial perivascular lymphocytic infiltrate with scattered eosinophils (A 20x, B 40x).

Discussion

Blaschkitis is a rare dermatosis distributed along the lines of Blaschko, a pattern of contours on the surface of the body thought to represent the migratory pathways of epidermal cells during embryonic development [1, 2]. It presents with pruritic papules and vesicles in characteristic V- or S-shaped configurations on the trunk and may assume a linear pattern on the extremities [3]. Blaschkitis predominantly occurs in adult males and is rarely seen in children. It resolves spontaneously within a few weeks, but often recurs for years after the initial eruption [4].

The diagnosis of blaschkitis can be made by clinical appearance, natural history, and histopathology. A biopsy showing spongiotic dermatitis is suggestive and may help distinguish it from other cutaneous disorders arising in Blaschko lines, such as lichen striatus [4]. Muller et al. recently proposed that blaschkitis exist with lichen striatus on a spectrum of acquired blaschko-linear dermatoses [3]. However, differences in presentation and histopathology justify separate diagnoses. Lichen striatus is a non-vesicular eruption of classically flat topped, non scaly, smooth papules occurring primarily in children, which exhibits a very distinct lichenoid lymphocytic infiltrate with histiocytes in the dermal papillae on histopathology. The spongiotic eczematous dermatitis of blaschkitis, by contrast, is less specific histologically and occurs primarily in adults. While blaschkitis tends to relapse, lichen striatus arises in a single episode, and is classically not recurrent [5]. Thus, despite some overlap in presentation by their acute onset and distribution, blaschkitis and lichen striatus are distinct entities. Reporting a case of blaschkitis in a pediatric patient, Keegan maintains that blaschkitis and lichen striatus are not childhood and adult forms of the same disease [4].

The mechanism for the pattern of reaction in blaschkitis is thought to be a localized T cell response mediated against keratinocytes displaying genetic mosaicism [3]. Presumably, post-zygotic somatic mutations or an X-linked inactivation of a chromosome during embryogenesis produces an abnormal clone of keratinocytes which proliferate along the lines of Blaschko. Triggered by viral infection, certain medications, or emotional stress, the immune system recognizes these keratinocytes and induces blaschkitis [4]. Metronidazole and certolizumab have been implicated [6, 7].

Blaschkitis generally resolves spontaneously within a few weeks but often recurs in subsequent episodes. When a treatment is pursued, the lesions show minimal response to topical steroids but systemic steroids have worked. Severe dryness may be combated with an emollient [8]. Of note, the afore-mentioned case of metronidazole-induced blaschkitis resolved after 10 days of topical betamethasone cream.

This case demonstrates an unusual presentation of blaschkitis. Although characteristically distributed, the lesions persisted one year without resolution and improved significantly with topical clobetasol ointment. Histopathology showing nonspecific spongiotic findings was inconsistent with lichen striatus, thus supporting a diagnosis of blaschkitis. This case demonstrates that topical steroid treatment may be pursued despite failure in precedent cases of blaschkitis.

References

1. Bologna JL, Orlow SJ, Glick SA. Lines of Blaschko. *J Am Acad Dermatol* 1994 Aug; 31(2 Pt 1):157-92. [PMID:8040398]
2. Litvinov IV, Jafarian F. Images in clinical medicine. Lichen striatus and lines of Blaschko. *N Engl J Med* 2012 Dec; 367(25): 2427. [PMID:23252528]
3. Muller CS, Schmaltz R, Vogt T, Pfohler C. Lichen striatus and blaschkitis: reappraisal of the concept of blaschkolinear dermatoses. *Br J Dermatol* 2011 Feb; 164(2): 257-62. [PMID:20849467]
4. Keegan BR, Kamino H, Fangman W, Shin HT, Orlow SJ, Schaffer JV. "Pediatric blaschkitis": expanding the spectrum of childhood acquired Blaschko-linear dermatoses. *Pediatr Dermatol* 2007 Nov-Dec; 24(6): 621-7. [PMID:18035983]
5. Bologna JL, Jorizzo JL, Schaffer JV. *Genodermatoses: blaschkitis*. *Dermatology*, 3rd ed. China: Saunders Elsevier, 2012. 956.
6. Brinkmeier T, Herbst RA, Schaller J, Kuegler K, Pirker C, Beiteke U, Grosshans E, Frosch PJ. Drug-induced blaschkitis. *Acta Derm Venereol* 2004; 84(4): 314-5. [PMID:15339081]
7. Couderc M, Soubrier M. Blaschkitis under certolizumab for rheumatoid arthritis. *Joint Bone Spine* 2014 Jul; 81(4): 372-3. [PMID:24439961]
8. Hale EK. Acquired Blaschko dermatitis. *Dermatol Online J* 2001 Feb; 7(1): 8. [PMID:11328629]