

UC Davis

Dermatology Online Journal

Title

Lupus and scleroderma overlap features in a 28-year-old man with anti-PL-12 anti-synthetase syndrome

Permalink

<https://escholarship.org/uc/item/5vc6g7b6>

Journal

Dermatology Online Journal, 23(9)

Authors

Rana, Jasmine
Moy, Andrea Primiani
Piris, Adriano
et al.

Publication Date

2017

DOI

10.5070/D3239036485

Copyright Information

Copyright 2017 by the author(s). This work is made available under the terms of a Creative Commons Attribution-NonCommercial-NoDerivatives License, available at <https://creativecommons.org/licenses/by-nc-nd/4.0/>

Peer reviewed

Lupus and scleroderma overlap features in a 28-year-old man with anti-PL-12 anti-synthetase syndrome

Jasmine Rana BA, Andrea Primiani Moy MD, Adriano Piris MD, Gideon P. Smith MD PhD

Department of Dermatology, Massachusetts General Hospital and Harvard Medical School, Boston, Massachusetts

Corresponding Author: Jasmine Rana, Harvard Medical School, 6107 Ave Louis Pasteur, Boston, MA 02115, Tel: 425-533-4923, E-mail: jasmine_rana@hms.harvard.edu

Abstract

A 28-year-old man with clinically and laboratory diagnosed anti-PL-12 anti-synthetase syndrome (AS) in 2009 developed cutaneous lupus lesions, discoid lupus lesions, and sclerodactyly with finger-tip ulcerations four years following his AS diagnosis. Laboratory tests including +ANA, +anti-dsDNA antibody, +anti-Smith antibody, and +anti-RNP antibody in 2014 confirmed the diagnosis of progression to an overlap syndrome including systemic lupus erythematosus. The patient now also has clinical findings (sclerodactyly, Raynaud phenomenon, finger-tip ulcerations) consistent with scleroderma overlap. In each stage of his evolving connective tissue disease, cutaneous findings have been central to the recognition and monitoring of his overlap syndromes.

Keywords: anti-PL-12, anti-synthetase, lupus, scleroderma, myositis, overlap, MCTD

Introduction

Anti-synthetase syndrome (AS) is a rare syndrome in the inflammatory myopathy family that is defined by laboratory presence of an anti-aminoacyl-tRNA synthetase (anti-ARS) antibody and hallmark clinical symptoms: fevers, interstitial lung disease (~80%), mechanic's hands (~70%), Raynaud phenomenon (~60%), and polyarthritis (~60%), [1]. Myositis may be clinically asymptomatic or mild in AS, especially when it is associated with certain antibodies, particularly anti-PL-12 and anti-PL-7 antibodies [1, 2].

Aminoacyl-tRNA synthetase is a cytoplasmic enzyme that catalyzes the binding of a specific amino acid to tRNA during protein synthesis. To date there are nine

known anti-ARS antibodies and each targets a t-RNA synthetase specific for a different amino acid [3]. The anti-Jo-1 antibody is the most common anti-ARS antibody (25-30% estimated prevalence in patients with polymyositis or dermatomyositis), followed by anti-PL-7 antibody (5-10%), and anti-PL-12 antibody (<5%), [4].

We present a 28-year-old patient diagnosed with the rare anti-PL-12 subtype of AS in 2009 who subsequently developed clinical and laboratory evidence of a systemic lupus erythematosus (SLE) overlap syndrome and sclerodermatous skin findings suggestive of an additional scleroderma overlap syndrome. This case is presented to highlight a unique overlap presentation in a patient with AS and underscore the importance of monitoring patients with inflammatory myopathies for connective tissue overlap diseases that may chiefly present cutaneously, as in this patient.

Case Synopsis

In 2009, a 20-year-old man, a college student, with a history of arthralgias, dyspnea, pericarditis, recurrent fevers, periorbital edema and erythema, and poikilodermic rash on his trunk and arms was diagnosed with anti-synthetase syndrome (AS) based on his aforementioned clinical findings and +anti-PL-12 antibody. Chest CT and lung biopsy were consistent with interstitial lung disease.

A punch biopsy of the patient's poikilodermic eruption (left upper arm) during a subsequent hospitalization showed increased dermal mucin with leukocytoclastic vasculitis and interface vacuolar changes consistent with a reactive dermatitis secondary to AS (**Figure 1**).

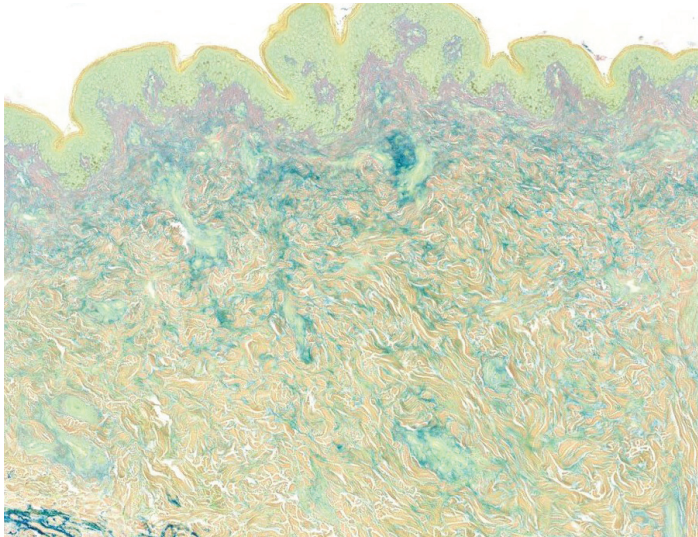


Figure 1. A punch biopsy of the patient's left upper arm in 2012 shows leukocytoclastic vasculitis with focal interface vacuolar changes. This Alcian blue stain shows increased dermal mucin.

At the time of initial AS diagnosis, he had a negative ANA at 1:40 and 1:160. Anti-Ro antibody was positive at 70.5 (normal 0-19.9 ODU), anti-dsDNA antibody was negative at 1:10, and anti-RNP antibody was negative at 0.296 (normal < 0.600 OD U). CK was elevated at 3659 (normal 60-400 U/L in men). Other than his poikiloderma, he exhibited no cutaneous eruptions consistent with SLE. He had no photosensitivity, no Raynaud phenomenon, and no sclerodactyly. He was treated with prednisone and methotrexate and later transitioned to chronic prednisone and azathioprine.

The patient had a complicated course following his AS diagnosis with numerous hospitalizations for acute inflammatory symptoms. Approximately 4 years after initial AS diagnosis, the patient was hospitalized for high fevers, acute respiratory distress syndrome, and pancytopenia in 2014. Serologies at this time were consistent with SLE. Negative at initial diagnosis of AS, ANA was now positive at 1:2560 with a speckled nuclear pattern and anti-dsDNA antibody was positive at 1:40. Anti-Smith antibody was positive at 235 (normal 0-19.9 OD U), anti-Ro antibody was positive at 169 (normal 0-19.9 OD U), and anti-RNP antibody was positive at 264 (normal 0-19.9 OD U). C3 and C4 were low. Lupus anticoagulant was also positive. Anti-Scl-70 antibody was negative at 3.73 (normal 0-19.9 OD U) and anti-RNA polymerase antibody was negative at < 10 (normal < 20 U). The patient's acute symptoms resolved with solumedrol, IVIG, anakinra (IL-1 inhibitor), and rituximab.

Despite his rocky course complicated by recurrent hospitalizations, the patient, now 28 years old, is currently doing well on prednisone 5 mg daily, hydroxychloroquine 400 mg daily, and rituximab 1000 mg every six months, which have helped with pulmonary, joint, and skin symptoms. His lung function has improved (FEV1/FVC = 83% predicted in 2016 vs. FEV1/FVC = 88% in 2009 around time of AS diagnosis). However, even on this treatment regimen, he developed discoid (**Figure 2A**) and cutaneous lupus lesions, which are being treated with intralesional and topical steroids. In the interim since his AS diagnosis, the patient also developed Raynaud phenomenon, sclerodactyly with ulcerations, and hyperkeratotic scale on his hands consistent with mechanic's hands (**Figure 2B and 2C**).

The patient currently undergoes annual age-appropriate screening for cancer and PFTs. He is also screened with UA, BUN/Cr, C3, C4, dsDNA, ESR, and CRP to monitor for activity of systemic lupus, particularly renal impairment.

Case Discussion

Anti-PL-12 anti-synthetase syndrome (AS) is so rare that its exact prevalence is unknown. This is compounded by the fact that the anti-PL-12 antibody is not always assessed and lab testing was only recently made available. It is estimated that 25% of patients with polymyositis or dermatomyositis have AS, which amounts to a prevalence estimate of 3-4/100,000 worldwide [5]. AS tends to be more predominant in women than men (as high as 13:1 in some studies), [6]. Because the clinical presentation of AS can be variable and non-specific (e.g. fevers, dyspnea, arthritis), the diagnosis of AS is generally made after an establishment of myositis and when, on further testing, the patient is shown to have a positive anti-ARS antibody and presents with one or more AS symptoms [3, 6].

Since the patient's original anti-PL-12 AS diagnosis (a case discussion about his initial presentation was previously published in 2012 [7]), we have continued to closely follow this patient in dermatology clinic. We re-present this patient now to discuss how he went on to develop autoimmune overlap features in the years following his initial AS diagnosis, including 1) systemic lupus overlap as evidenced by cutaneous

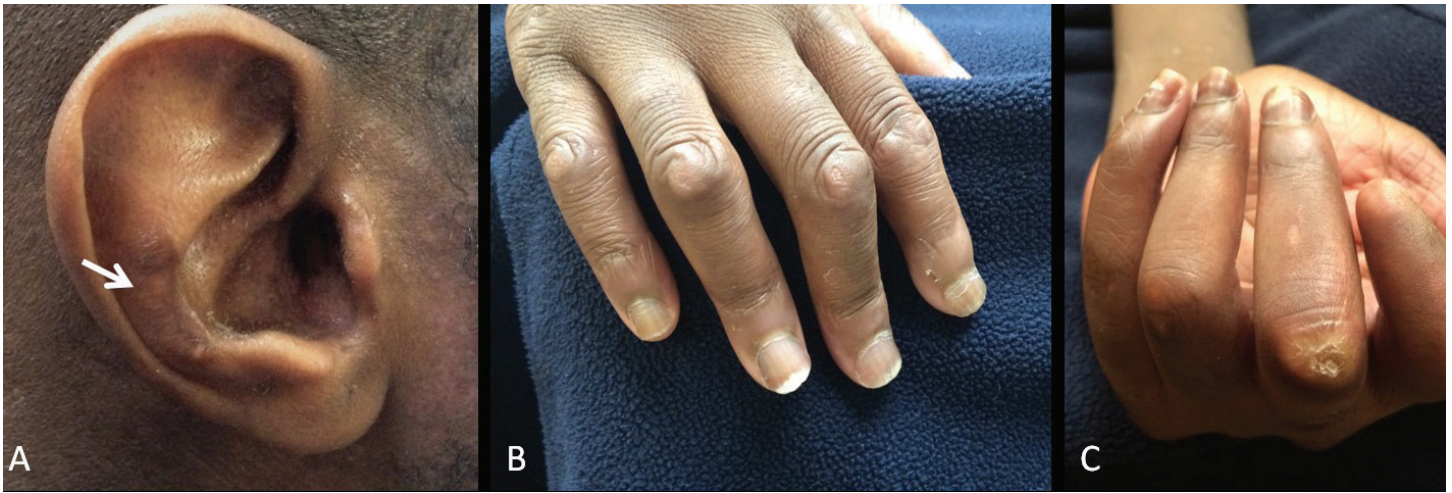

Figure 2. New onset discoid lupus erythematosus lesions (A, arrow) and sclerodactyly in the patient's right (B) and left hand (C) evidenced by narrow tapering, shiny distal skin, associated skin atrophy, and joint contractures.

and discoid lupus lesions with +ANA, +anti-dsDNA antibody, +anti-Smith antibody, +anti-Ro antibody, +anti-RNP antibody, and +lupus anticoagulant antibody (meets ACR criteria for systemic lupus diagnosis [8]) and 2) possible scleroderma overlap as evidenced by sclerodactyly with finger-tip ulcerations. Despite negative anti-Scl-70 antibody and anti-RNA polymerase antibody, the patient meets 2013 ACR/EULAR criteria for scleroderma diagnosis with clinical symptoms (sclerodactyly, Raynaud phenomenon, finger-tip ulcerations) alone [9].

A discussion of overlap syndromes with AS is limited by the new classification of AS a separate clinical entity (around 1990) and debate in the literature about AS being a myositis overlap syndrome in itself [10]. Generally recognized as a discrete connective tissue disease syndrome (with the presence of an anti-ARS antibody being essential to diagnosis), AS has rarely been reported to present with overlap presentations [10-13]. To the best of our knowledge, though likely underreported, this is the first case report of a patient with AS who developed serologies and cutaneous manifestations of systemic lupus erythematosus (SLE) with a concomitant scleroderma clinical overlap.

Although rare, overlap syndromes should be considered in the differential for patients with inflammatory myopathies if new clinical symptoms develop so that treatment regimens and appropriate organ-specific screening (e.g. renal impairment in systemic lupus and esophageal and pulmonary

involvement in scleroderma) can be initiated. Variability in presentation has made prevalence of overlap syndromes difficult to determine [14]. In one retrospective cohort study, a non-insignificant proportion of participants with inflammatory myopathies (31 out of 220) were diagnosed with overlap syndromes (48.4% scleroderma, 29.0% SLE, 22.6% rheumatoid arthritis), [15].

Although this AS patient manifests with clear lupus and scleroderma symptoms, we are cautious to label him definitively as "AS with lupus and scleroderma overlap" in the setting of his evolving clinical picture (despite the fact that this tentative diagnosis is guiding our screening tests at present, as mentioned above). The patient's negative anti-RNP antibody profile in 2009 that subsequently became positive in 2014 remains a diagnostic conundrum. Although anti-RNP can be positive in systemic lupus, it may also suggest that this patient may be better classified as mixed connective tissue disease (MCTD) given his overlapping features of myositis, lupus, and scleroderma and his high-titer ANA in 2009 with a nuclear speckled pattern. MCTD would be atypical as it generally presents with positive anti-RNP early in a disease course with non-specific symptoms that later evolve into a MCTD overlap [16]. The patient exhibited classic symptoms of AS early in his disease course, but this, of course, does not exclude an evolving MCTD picture. Time remains the best predictor for whether or not he will evolve into a discrete connective tissue disease [17]; diagnostic certainty may allow better prediction of his risk for

malignancy, pulmonary disease progression, and renal failure. With regard to treatment, this patient's pulmonary, joint, and skin manifestations anecdotally improved most significantly with the initiation of rituximab. The patient was initiated on the standard rheumatoid arthritis protocol in 2014 (two doses of 1,000 mg IV rituximab separated by two weeks, every six months). In 2015, following a standard re-dosing of rituximab, the patient missed his week two infusion. On checking his B-cell depletion and clinical activity, however, he seemed well controlled and so the decision was made to try him on one dose of 1,000 mg rituximab every six months as it appeared adequate and was consistent with what has been done for some patients with rheumatoid arthritis [18, 19]. The patient remains well-controlled on the lower dosing.

Retrospective and prospective studies show that many rituximab-treated AS patients (who were often refractory to other immunosuppressive medications like our patient) had improved or stabilized lung function and exhibited improvement in lab and clinical markers of myopathy, but this needs to be further evaluated in larger controlled studies [20-22].

Conclusion

This case was presented for discussion of a rare subtype of anti-PL-12 AS with a focus on evolving lupus and scleroderma overlap features that have guided screening and aggressive immunosuppressive treatment. Dermatologists play a vital role in monitoring patients with connective tissue disease for overlap syndromes as they can recognize cutaneous manifestations of these diseases and ensure that appropriate work-up and screening are initiated.

References

- Lazarou IN, Guerne PA. Classification, diagnosis, and management of idiopathic inflammatory myopathies. *J Rheumatol*. 2013 May;40(5):550-64. [PMID: 23504386].
- Hervier B, Wallaert B, Hachulla E, Adoue D, Lauque D, et al. Clinical manifestations of anti-synthetase syndrome positive for anti-alanyl-tRNA synthetase (anti-PL12) antibodies: a retrospective study of 17 cases. *Rheumatology (Oxford)*. 2010 May;49(5):972-6. [PMID: 20156976].
- Chatterjee S, Prayson R, Farver C. Antisynthetase syndrome: not just an inflammatory myopathy. *Cleve Clin J Med*. 2013 Oct;80(10):655-66. [PMID: 24085811].
- Kalluri M, Sahn SA, Oddis CV, Gharib SL, Christopher-Stine L, et al. Clinical profile of anti-PL-12 autoantibody Cohort study and review of the literature. *Chest*. 2009 Jun;135(6):1550-6. [PMID: 19225060].
- Jan Tore Gran and Øyvind Molberg (2011). *The Antisynthetase Syndrome, Idiopathic Inflammatory Myopathies - Recent Developments*, Prof. Jan Tore Gran (Ed.), ISBN: 978-953-307-694-2, InTech, Available from: <http://www.intechopen.com/books/idiopathic-inflammatory-myopathies-recent-developments/the-antisynthetase-syndrom>
- Solomon J, Swigris JJ, Brown KK. Myositis-related interstitial lung disease and antisynthetase syndrome. *J Bras Pneumol*. 2011 Jan-Feb;37(1):100-9. [PMID: 21390438].
- Christopher-Stine L, Robinson DR, Wu CC, Mark EJ. Case records of the Massachusetts General Hospital Case 37-2012 A 21-year-old man with fevers, arthralgias, and pulmonary infiltrates. *N Engl J Med*. 2012 Nov 29;367(22):2134-46. [PMID: 23190225].
- Tan EM, Cohen AS, Fries JF, Masi AT, McShane DJ, et al. The 1982 revised criteria for the classification of systemic lupus erythematosus. *Arthritis Rheum*. 1982 Nov;25(11):1271-7. [PMID: 7138600].
- van den Hoogen F, Khanna D, Fransen J, Johnson SR, Baron M, et al. 2013 classification criteria for systemic sclerosis: an American college of rheumatology/European league against rheumatism collaborative initiative. *Ann Rheum Dis*. 2013 Nov;72(11):1747-55. [PMID: 24092682].
- Jury EC, D'Cruz D, Morrow WJ. Autoantibodies and overlap syndromes in autoimmune rheumatic disease. *J Clin Pathol*. 2001 May;54(5):340-7. [PMID: 11328831].
- Ishikawa Y, Yukawa N, Kawabata D, Ohmura K, Fujii T, et al. A case of antisynthetase syndrome in a rheumatoid arthritis patient with anti-PL-12 antibody following treatment with etanercept. *Clin Rheumatol*. 2011 Mar;30(3):429-32. [PMID: 21221686].
- Meyer A, Lefevre G, Bierry G, Duval A, Ottaviani S, et al. In antisynthetase syndrome, ACPA are associated with severe and erosive arthritis: an overlapping rheumatoid arthritis and antisynthetase syndrome. *Medicine (Baltimore)*. 2015 May;94(20):e523. [PMID: 25997035].
- Wang CH, Wang NC, Lin TY, Chen CH. Anti-Jo-1 myositis and the antiphospholipid syndrome showing right ventricular thrombus: a novel overlap syndrome with atypical presentation. *Mod Rheumatol*. 2014 Sep;24(5):865-8. [PMID: 24517557].
- Gaubitz M. Epidemiology of connective tissue disorders. *Rheumatology (Oxford)*. 2006 Oct;45 Suppl 3:iii3-4. [PMID: 16987829].
- Aguila LA, Lopes MR, Pretti FZ, Sampaio-Barros PD, Carlos de Souza FH, et al. Clinical and laboratory features of overlap syndromes of idiopathic inflammatory myopathies associated with systemic lupus erythematosus, systemic sclerosis, or rheumatoid arthritis. *Clin Rheumatol*. 2014 Aug;33(8):1093-8. [PMID: 24989017].
- Ortega-Hernandez OD, Shoenfeld Y. Mixed connective tissue disease: an overview of clinical manifestations, diagnosis and treatment. *Best Pract Res Clin Rheumatol*. 2012 Feb;26(1):61-72. [PMID: 22424193].
- Williams HJ, Alarcon GS, Joks R, Steen VD, Bulpitt K, et al. Early undifferentiated connective tissue disease (CTD) VI An inception cohort after 10 years: disease remissions and changes in diagnoses in well established and undifferentiated CTD. *J Rheumatol*. 1999 Apr;26(4):816-25. [PMID: 10229402].
- Trouvin AP, Jacquot S, Grigioni S, Curis E, Dedreux I, et al. Usefulness of monitoring of B cell depletion in rituximab-treated rheumatoid arthritis patients in order to predict clinical relapse: a prospective observational study. *Clin Exp Immunol*. 2015 Apr;180(1):11-8. [PMID: 25370437].
- Bredemeier M, de Oliveira FK, Rocha CM. Low- versus high-dose rituximab for rheumatoid arthritis: a systematic review and meta-analysis. *Arthritis Care Res (Hoboken)*. 2014 Feb;66(2):228-35. [PMID: 23983134].

20. Allenbach Y, Guiguet M, Rigolet A, Marie I, Hachulla E, et al. Efficacy of Rituximab in Refractory Inflammatory Myopathies Associated with Anti- Synthetase Auto-Antibodies: An Open-Label, Phase II Trial. *PLoS One*. 2015 Nov 5;10(11):e0133702. [PMID: 26539981].
21. Andersson H, Sem M, Lund MB, Aaløkken TM, Günther A, et al. Long-term experience with rituximab in anti-synthetase syndrome-related interstitial lung disease. *Rheumatology (Oxford)*. 2015 Aug;54(8):1420-8. [PMID: 25740830].
22. Sem M, Mollberg O, Lund MB, Gran JT. Rituximab treatment of the anti-synthetase syndrome: a retrospective case series. *Rheumatology (Oxford)*. 2009 Aug;48(8):968-71. [PMID: 19531628].