

AperTO - Archivio Istituzionale Open Access dell'Università di Torino

## Double-J ureteral stenting in nine cats with ureteral obstruction

### **This is the author's manuscript**

*Original Citation:*

*Availability:*

This version is available <http://hdl.handle.net/2318/106747> since

*Published version:*

DOI:10.1016/j.tvjl.2012.03.020

*Terms of use:*

Open Access

Anyone can freely access the full text of works made available as "Open Access". Works made available under a Creative Commons license can be used according to the terms and conditions of said license. Use of all other works requires consent of the right holder (author or publisher) if not exempted from copyright protection by the applicable law.

(Article begins on next page)



## UNIVERSITÀ DEGLI STUDI DI TORINO

This Accepted Author Manuscript (AAM) is copyrighted and published by Elsevier. It is posted here by agreement between Elsevier and the University of Turin. Changes resulting from the publishing process - such as editing, corrections, structural formatting, and other quality control mechanisms - may not be reflected in this version of the text. The definitive version of the text was subsequently published in *Veterinary Journal*. 2012 Oct;194(1):60-5. doi: 10.1016/j.tvjl.2012.03.020.  
<http://www.sciencedirect.com/science/article/pii/S109002331200130X>

You may download, copy and otherwise use the AAM for non-commercial purposes provided that your license is limited by the following restrictions:

- (1) You may use this AAM for non-commercial purposes only under the terms of the CC-BY-NC-ND license.
- (2) The integrity of the work and identification of the author, copyright owner, and publisher must be preserved in any copy.
- (3) You must attribute this AAM in the following format: Creative Commons BY-NC-ND license (<http://creativecommons.org/licenses/by-nc-nd/4.0/deed.en>),  
<http://www.sciencedirect.com/science/article/pii/S109002331200130X>

## Double-J ureteral stenting in nine cats with ureteral obstruction

S. Nicolì<sup>a</sup>, E. Morello<sup>a</sup>, M. Martano<sup>a</sup>, L. Pisoni<sup>b</sup>, P. Buracco<sup>3\*</sup>

<sup>a</sup> *Dipartimento di Patologia Animale, School of Veterinary Medicine, University of Turin, 10059 Grugliasco, Turin, Italy*

<sup>b</sup> *Dipartimento Clinico Veterinario, School of Veterinary Medicine, University of Bologna, 40064 Ozzano dell'Emilia, Bologna, Italy*

Corresponding author. Tel.: +39 011 6709063. E-mail address: paolo.buracco@unito.it

### Keywords:

Cat

Ureteral stenting

Ureterotomy

Segmental ureterectomy

Neoureterocystostomy

### ABSTRACT

Ureteral stenting is a common practice in human medicine and has recently been reported in dogs and cats to provide urinary diversion for ureteral obstructions caused by ureteroliths, strictures, neoplasia, and in an attempt to prevent postoperative complications following ureteral anastomosis. The aim of this report is to describe a surgical technique of ureteral stenting and the follow-up and complications in nine cats.

Number 3 French double-J catheters were used during open surgery for ureterotomy/ureterolith removal in eight cats and for segmental ureterectomy/end-to-end anastomosis in one cat for a localized benign stricture. Neoureterocystostomy was necessary in eight of the cats. Uroperitoneum did not occur. Stents were still in place in 7/9 animals after 357-1565 days (median 1277 days). A minor complication (stent migration) occurred in one cat, but stent removal was not required. Major complications were encrustation and persistent stranguria (in one cat each), requiring stent removal at 90 and 123 days, respectively. The first cat had a new stent inserted but was euthanased 3 months later for progressive renal failure. Despite the small number of cats, both the outcome and long-term stent tolerance observed in most cases suggest that ureteral stenting is a safe, adjunctive measure to ureteral surgery, mainly for concomitant ureteral and renal pelvic stones to prevent further obstruction and avoid pyelotomy/nephrotomy. However, smaller stents should be used to decrease the need for ureteral surgery.

### Introduction

Endoscopic placement of long-term indwelling ureteral stents in humans was first reported in 1967 (Zimskind et al., 1967) and endo-urological procedures and ureteral stenting are now standard procedures in human urology. Ureteral stenting is used to bypass either benign (including ureteroliths) or malignant strictures and to provide urinary diversion after ureteral anastomosis in order to prevent complications such as urine leakage and postsurgical strictures (Goldfischer and Gerber, 1997; Chen and Bagley, 2001; Patel and Newman, 2004; Corcoran et al., 2009).

Surgical treatment of ureteral obstructions in cats (i.e. ureterotomy, partial ureterectomy, neoureterocystostomy) often carries a relatively high complication rate (Kyles et al., 2005a; Mehl et al., 2005; Zaid et al., 2011). More recently, the placement of indwelling ureteral stents by non-invasive procedures (cystoscopy), minimally invasive techniques (nephrostomy needle access through a laparotomy approach and fluoroscopic guidance) or via a direct surgical ureteral approach have been reported (Weisse et al., 2006; Berent et al., 2007, 2011; Nicolì et al., 2009; Berent, 2011; Zaid et al., 2011). It is generally believed that complications may be potentially reduced by the use of ureteral stents.

The objective of this paper is to describe feline ureteral stenting and to present the complications and follow-up in nine cases. At present, the veterinary literature on this topic is sparse.

### Materials and methods

Cats with unilateral ureteral obstruction caused by ureteroliths or ureteral wall disease receiving a combination of ureteral surgery and a ureteral stent placement between January 2007 and January 2011 were included. All cases received written owner consent. Work-up consisted of clinical examination, complete blood count and biochemical tests, urinalysis and urine culture (from urine collected by cystocentesis), abdominal radiographs (lateral and dorso-ventral views) and abdominal ultrasound evaluation.

Methadone (Eptadone, Molteni Farmaceutici; 0.3 mg/kg IM) was administered to all cats and general anaesthesia was induced with propofol (Propofol, Fresenius Kabi; 4-6 mg/kg IV to effect) and maintained with isoflurane in oxygen. Analgesia was provided with a target controlled infusion of fentanyl (Fentanest, Pfizer Animal Health). ECG tracings, indirect arterial pressure, pulse rate, oxygen saturation and end-tidal CO<sub>2</sub> were monitored. Marbofloxacin (Marbocyl, ATI; 2 mg/kg IV) was injected at induction of anaesthesia and then every 2 h for longer procedures.

After a ventral midline celiotomy, a longitudinal ureterotomy was performed directly over the calculus. Ipsilateral nephroliths were not removed. Ureters were stented with a number 3 French 10 cm paediatric ureteral double-J stent (Optisoft, Opti-Med; Fig. 1) as follows: (1) the soft end of the 0.021 inch nitinol guide-wire (Pediatric Ureteral Stent Set 3 Fr. Opti-Med) was introduced from the ureterotomy site into the bladder; (2) the guide-wire was retrieved through a small cystotomy incision; (3) the stent was introduced over-the-guide-wire from the bladder up to the ureterotomy site; (4) the guide-wire was removed; (5) the soft end of the guide-wire was re-introduced in a retrograde direction from the bladder up to the renal pelvis; (6) the proximal stent was positioned into the renal pelvis; (7) the guide-wire was removed; and (8) the bladder was closed with a continuous suture pattern using 4/0 polyglecaprone 25 (Monocryl, Ethicon, Johnson and Johnson) and the ureter was closed with an interrupted suture pattern using 7/0 to 8/0 poly-amide (Daclon, SMI) or polydioxanone (PDS, Ethicon, Johnson & Johnson).

**Fig. 1.** Number 3 French paediatric ureteral double J stent.



If there were difficulties with stent insertion, the ureter was amputated distally (for small papillae) or just distally to the obstruction (if the post-obstructed ureter had reduced luminal diameter), spatulated and re-implanted into the bladder according to either the Lich-Gregoir or the modified Leadbetter-Politano techniques (Mehl et al., 2005). All the procedures involving ureters were performed using an operating microscope. Correct stent placement was assessed with an intra-operative radiograph (Fig. 2). Chemical analysis of removed stones was performed.

Postoperatively, marbofloxacin (2 mg/kg PO every 24 h) was administered for 1 week with buprenorphine (Temgesic, Schering Plough; 0.01 mg/kg PO every 8 h for 2-3 days), and meloxicam (Metacam, Boehringer Ingelheim; 0.1 mg/kg PO the first day and then 0.05 mg/kg PO every 24 h for 3 days). During the first 72 h, cats were monitored by blood gas analysis (paying particular attention to electrolyte levels), blood tests (packed cell volume, blood urea nitrogen, creatinine, and total plasma protein), abdominal ultrasound and, when appropriate, abdominal radio-graphs. An increase in blood urea nitrogen and potassium concentrations were considered, together with the abdominal ultrasound findings, the earliest and most reliable indicators of urine leakage from the surgical sites.

Periodic follow-up examination consisted of clinical examination, blood tests (complete blood count; blood urea nitrogen; plasma creatinine, albumin, and blood gas analysis), urinalysis, urine culture and urine protein:creatinine ratio when indicated, and abdominal ultrasonographic and radiographic evaluation. Following a recheck examination at 15 days and 3 months after surgery, owners were asked to have their cat examined at least every 6 months for stent-related complications (abdominal radiograph and ultrasound), and renal function. In particular cats were re-evaluated for clinical status, complete blood count, urea, creatinine, electrolytes and albumin, urinalysis, urine culture, and urine protein:creatinine ratio (when indicated).

#### *Statistical analysis*

The distribution of the values of blood creatinine, urea nitrogen and potassium were tested for normality with the Shapiro-Wilk test ( $P > 0.05$ ). Renal parameters (blood creatinine and urea nitrogen) were compared using the Wilcoxon test (GraphPad Prism Software, version 4.0); in particular, the pre-stenting values of each parameter were compared to the corresponding postoperative 3-day and 3-month values. Postoperative 3-day values were also compared to the 3-month values. Pre-stenting serum potassium values were also compared with the 3-day results. Statistical significance was set at  $P < 0.05$ .

#### **Results**

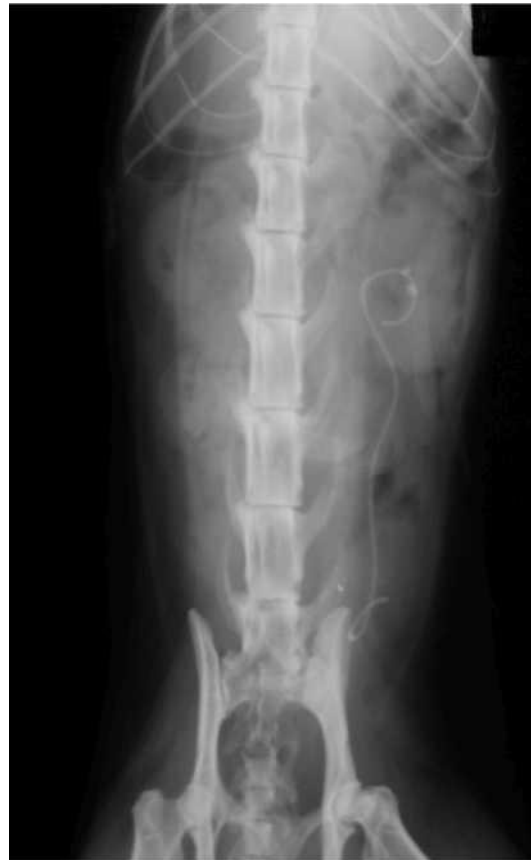Nine referred cats (3 Persian, 5 domestic shorthair, 1 Maine Coon) were included in the study. Median age and weight were 4.7 years (range 1-7) and 3.6 kg (range 2.2-7), respectively. There were five spayed females and four castrated males.

Clinical signs at presentation included anorexia ( $n = 5$ ), vomit-ing ( $n = 3$ ), polyuria and polydipsia ( $n = 2$ ), and stranguria ( $n = 2$ ). Preoperative values of blood urea, creatinine and potassium are listed in Table 1; values of both preoperative blood urea and creatinine were not normally distributed (Table 2). Preoperatively, *E. coli* was isolated from one urine sample (cat 6). An upper urinary tract stone was suspected radiographically in six cats. Abdominal ultrasound examinations revealed renal pelvis dilatation/hydronephrosis of varying degrees ( $n = 7$ ); signs of ureteritis (wall thickening, peri-ureteral soft tissue reactivity) at the level of the obstruction ( $n = 4$ ); unilateral ureteroliths variably localized in the distal half of the ureter ( $n = 6$ ); ipsilateral renal pelvic uroliths ( $n = 5$ ); and ureteral obstruction without mineralization ( $n = 1$ ). The combination of the radiographic and ultrasonographic findings revealed eight cats with unilateral ureteral uroliths (cats 1-7 and 9), of which five (62.5%; cats 3, 4, 5, 7, 9) had concomitant ipsilateral nephroliths. One cat (cat 8) had a localized

proximal ureteral obstruction of unknown origin.

Median interval between presentation at the clinic and surgery was 3 days (range 0-11 days). Preoperative treatment consisted of Ringer's lactate IV only. Ureterotomy for ureterolith removal was performed in eight cats. Two of the eight cats were also admitted for surgery because of concomitant ureteroliths and ureteritis that were interpreted as early stage obstruction, even though a proximal ureteral dilatation indicating obstruction was not clearly demonstrated at the preoperative ultrasound. Mineral analysis revealed seven oxalate ureteroliths and one struvite ureterolith. In the five cats with unremoved nephroliths, stones spontaneously migrated into the ureter along the stent without causing further obstruction (Fig. 3; cat 3) and were eliminated during urination. Cat 8 presented a 3 mm mural obstruction in the proximal third of the ureter and underwent a 1 cm ureterectomy, stenting, and end-to-end ureteral anastomosis. Histopathology of the excised tract revealed an unspecific chronic fibrosing ulcerative ureteritis.

**Fig. 2.** Dorsoventral radiographic view of a ureteral stent. Two stones in the renal pelvis were left in place (cat 3).



	Preoperative			Postoperative (72 h)			Postoperatively (3 months)		Follow up (days)	Complications and status
	BUN	Crea	K	BUN	Crea	K	BUN*	Crea		
Case 1	86	7.3	4.6	77	5.5	4.2	73	3.47	1565	None, alive
Case 2	39	3.1	4.4	51	2.4	3.95	44	3.5	1549	Slight migration but stent not removed. Alive
Case 3	35	2.7	5.5	37	2.5	4.97	16	1.7	1541	None, Alive
Case 4	>600	24	6	63	6.1	5.2	90	5.5	90 + 90	Encrustation at 90 days. Stent removed and second stenting. Euthanasia after further 90 days for progressive renal disease
Case 5	14	1.54	4.5	14	1.2	3.7	50	1.4	1277	None, alive
Case 6	51	4.4	5.6	59	4.4	4.4	26	1.8	697	None, alive (preoperatively positive for <i>Escherichia</i> )
Case 7	51	3.4	5	23	1.5	3.64	26	1.9	662	Slight stranguria, spontaneously resolved in 2 weeks. Alive
Case 8	175	5.5	4.35	128	3.4	3.6	169	3.7	357	(Ureterectomy for ureteritis) None, alive
Case 9	85.5	2.28	3.6	44.2	1.54	3.4	45.3	2.6	142	Persistent stranguria → stent removal at day 123. Alive

BUN, blood urea nitrogen – normal range, 7–27 mg/dL; Crea, blood creatinine – normal range, 0.5–1.8 mg/dL; K, blood potassium (K) – normal range, 3.5–5.8 mEq/L.

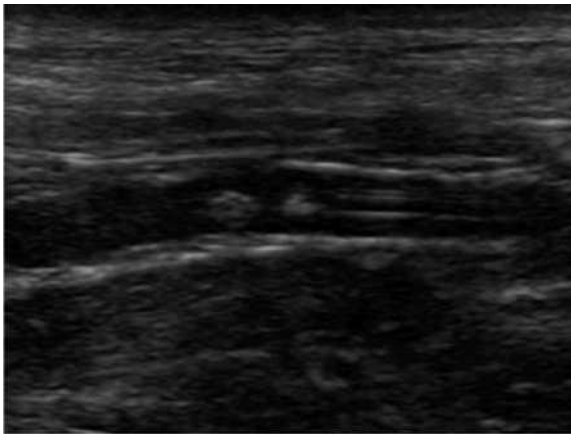
**Table 1** Selected blood concentrations before stent placement, postoperatively at 72 h and 3 months. Follow-up duration and major complications occurred.

	Mean ± SD	Median	Range
Pre-operative BUN (mg/dL)	126.3 ± 183.7	51 <sup>a</sup>	14–600
3-day BUN (mg/dL)	55.13 ± 33.64 <sup>b</sup>	51	14–128
3-month BUN (mg/dL)	59.92 ± 47.13	45.3 <sup>a</sup>	16–169
Preoperative Crea (mg/dL)	6.024 ± 6.967	3.4 <sup>a</sup>	1.54–24
3-day Crea (mg/dL)	3.171 ± 1.801 <sup>b</sup>	2.5	1.2–6.1
3-month Crea (mg/dL)	2.841 ± 1.325 <sup>b</sup>	2.6	1.4–5.5
Preoperative K (mEq/L)	4.839 ± 0.7524 <sup>b</sup>	4.6	3.6–6
3-day K (mEq/L)	4.118 ± 0.6323 <sup>b</sup>	3.95	3.4–5.2

<sup>a</sup> Values not normally distributed.

<sup>b</sup> Values normally distributed.

**Table 2** Descriptive statistics for blood urea nitrogen (BUN) creatinine (Crea) and potassium (K).



**Fig. 3.** Ultrasonographic appearance of ureteral stones along the stent without ureteral dilatation (cat 3).

In 8/9 cats, the ureter was amputated and re-implanted using the Lich-Gregoir technique (seven cats) or the modified Leadbetter-Politano technique in one animal (cat 9), due to the small size of the ureteral papilla (three cats) and/or the post-obstruction endoluminal reduction (five cats) impeding stenting. Even though of decreased intraluminal diameter, the ureter distal to the ureterotomy site was spared as much as possible to allow a tension-free neo-ureterocystostomy. In one cat (cat 7, a 7 kg Maine Coon), both the ureter and the ureteral papilla were large enough to allow stenting without neoureterocystostomy. After intraoperative radiographic evaluation of the correct ureteral stenting (Fig. 2), an incorrectly placed stent requiring stent repositioning occurred in two cats (cats 2, 3). Median operative and hospitalization times were 120 min (range 100–160) and 5 days (range 3–8), respectively.

Serum creatinine and urea nitrogen at the 3rd postoperative day and at 3 months postoperatively are reported in Tables 1 and 2. Urea nitrogen values at 3 months after surgery were not normally distributed. Both blood creatinine and urea nitrogen showed a statistically significant improvement when the 3rd postoperative day values were compared with the preoperative values or when the 3-month values were compared with both the preoperative and the 3-day values ( $P < 0.05$ ). A significant decrease in serum potassium (Tables 1 and 2) was also noted when preoperative values were compared with the 3-day values ( $P < 0.05$ ). Finally, the planned recheck abdominal ultrasonography revealed a progressive but incomplete decrease in the dilatation of both the ureter and the renal pelvis.

The overall survival time was 142–1565 days (median 1277 days); 8/9 cats (88.9%) were still alive at the time of writing, and 7/9 (77.8%) stents were still in place (range 357–1565 days, median 1277). Uroperitoneum was not observed in this series of cats. The only complications recorded, in one cat each, were stranguria, encrustation and slight stent migration. Stranguria developed in two animals immediately after surgery. In cat 7 it resolved spontaneously within 2 weeks; in cat 9, following exclusion of any potential cause of stranguria including infection (urine culture), a protracted, but intermittent, medical treatment with phenoxybenzamine (Dibenzylan, Esparma; 5 mg/kg PO every 12 h), buprenorphine (0.01 mg/kg PO every 6 h), and meloxicam (0.1 mg/kg PO the first day then 0.025 mg/kg PO every 12 h for not more than 3 days a week), was prescribed. In the latter cat, the stent was not removed because of the presence of stones along the stent and renal pelvis. When it was evident that all of the ureteral stones had reached the bladder, the stent was removed (123 days after placement) and resolution of stranguria occurred in a few days.

In cat 4, stent encrustation was detected radiographically 3 months after surgery. The stent was surgically removed (Fig. 4) and substituted with a new one, but the cat was euthanased 3 months later for progressive renal failure (blood urea nitrogen and creatinine concentrations of 111 mg/dL and 9 mg/dL, respectively). In cat 2, 21 months after surgery, radiographs revealed a slight cranial migration of the distal pigtail of the stent into the ureter without evidence of either pyelectasia or hydroureter. It was decided

to leave the stent in place and the cat was strictly monitored for further stent migration or clinical progression.

## Discussion

Ureteroliths are a frequent cause of ureteral obstruction in cats. In this retrospective case series, clinical signs at presentation were similar to those already described (Kyles et al., 2005b; Zaid et al., 2011). Diagnosis is based on clinical examination, abdominal ultra-sound, plain abdominal radiographs and/or descending urography/percutaneous antegrade pyelography (Berent, 2011). In our series, abdominal plain radiographs were used to diagnose urolithiasis in 66.7% of cases and this finding agrees with other reports (Kyles et al., 2005b).




Fig. 4. Appearance of the stent after surgical removal (cat 4).

Abdominal ultrasound accuracy was comparable to radiology and, beyond showing the obstruction based on either stone visualization and/or dilatation of ureter and/or renal pelvis in most cases, it also identified peri-ureteral reactivity at the obstruction site in some cases. This finding was also recently reported in the veterinary literature by Zaid et al. (2011). The use of both radiology and ultrasound to evaluate the upper urinary tract has been recommended as it allows a higher diagnostic sensitivity (90%) than radiology or ultrasound alone (Kyles et al., 2005b). This was also the case in our series and preoperative imaging findings were con-firmed at surgery. Computed tomography, as reported by Kyles et al. (2005b), was not used here.

Surgery is required to relieve obstructions due to either oxalate or struvite obstructive ureteroliths. All cats in the present series were surgically treated and no medical treatment for ureteroliths and/or renal pelvis stones was attempted. Ureteral surgery may consist of ureterotomy, partial ureterectomy with end-to-end anastomosis or ureter re-implantation into bladder (Fossum, 2007). Postoperative complications in cats may be numerous, including urine leakage and uroperitoneum in the immediate postoperative period, and urolithiasis recurrence with obstruction and stricture thereafter (Kyles et al., 2005a; Berent, 2011; Zaid et al., 2011). In humans it has been shown that ureteral stenting helps to prevent such complications (Sieben et al., 1978; Mitty et al., 1983; McMullin et al., 1993).

In humans, many studies have dealt with both size and new stent material and, as biocompatibility represents an important concern, bioabsorbable stents have been proposed (Talja et al., 2002). Paediatric stents have been used in veterinary medicine (Berent et al., 2007, 2011; Nicoli et al., 2009; Berent, 2011; Zaid et al., 2011). Different approaches for ureteral stent placement, including open surgical, cystoscopic, and percutaneous radiological approaches have been described (Berent, 2011). Number 3 French paediatric stents were used in this case series and the correct placement of the stent was assessed using an intraoperative radio-graph; however, the use of fluoroscopy (which was not available at the time we recruited these cases) would have greatly helped both the insertion of the stent into the ureter and its correct placement (Berent, 2011), thus avoiding stent repositioning as occurred in two cats.

The mean inner ureteral diameter of a healthy adult cat is 0.4 mm and the papilla may be smaller (Berent, 2011). In most cats in the present series, an endoluminal reduction was observed in all the ureters distal to the obstruction. A true stricture was found in one cat only as a result of a chronic fibrosing ulcerative ureteritis requiring ureterectomy, and as there was no previous history of ureterolithiasis, ureteral surgery or haematuria, this was considered to be of unknown origin. It has been reported that strictures may be primary (idiopathic) or secondary; in the latter case, a potential cause may be a previous damage of the ureteral wall caused by either the passage of an ureterolith or bleeding (from either the kidney, possibly as essential hematuria, or ureter) and/or clot formation, which are all factors that could explain ureteral wall damage, predisposing to either new ureterolith or stricture formation (Zaid et al., 2011). Circumcaval ureter, a reported cause of ureteral obstruction (Zaid et al., 2011), was not seen in this case series.

A common surgical problem encountered here (8/9 animals; 88.9%) was the need to amputate the ureter and to perform a neo-ureterocystostomy as a consequence of using a number 3 French ureteral stent and the small size of the ureteral papilla or the post-obstruction ureteral tract. Since all ureteroliths were located in the distal half of the ureter, there was no need for renal descensus and/or psoas cystopexy (Hardie and Kyles, 2004) in order to make neoureterocystostomy feasible. A number 2.5 French multifenestrated ureteral stent has subsequently become available (Vet Stent Ureter, Infiniti Medical LLC) but it was not used in this series of cats. The use of a smaller stent may have helped prevent ureteral surgery in most cats, as recently reported (Berent, 2011; Zaid et al., 2011). The interventional procedures reported by these authors relied on the use of fluoroscopy and ultrasound to guide ureteral stenting. A ureteropyelogram is used to identify the site of the ureteral lesion/obstruction. In order to avoid ureterotomy, the introduction of the stent

may be antegrade, also through a percutaneous approach, from the renal pelvis into the ureter, or retrograde through a cystoscopic approach (Berent, 2011). In our opinion these novel minimally invasive procedures using a smaller stent may help to avoid ureteral surgical procedures in most instances. In most of the cases here, surgery was necessary because it was impossible to pass through the vesicoureteral junction with a number 3 French stent. However, even though all of our cases were approached surgically for ureteral stenting, complications such as urine leakage resulting in uroperitoneum and stricture did not occur.

Complications of ureteral stenting in humans include stent migration, encrustation, flank pain, infection, dysuria, and haematuria. At present, preventive measures include stent removal or substitution after 3-6 months (Chen and Bagley, 2001; Haleblan et al., 2008). Indwelling ureteral stents seem to be tolerated longer in cats than humans. Long-term (up to 780 days) tolerance without major complications was observed in 17/18 cats in one study (Berent et al., 2009). In the present series, most stents were not removed and were left in place for long periods. They were well tolerated in all but two cats that required stent removal (for encrustation and stranguria, respectively), and surgical removal was easily performed.

Nevertheless, it should be noted that stent removal may be easily accomplished cystoscopically in females or under fluoroscopic guidance in males using a basket or a grasper, thus avoiding surgery. One self-limiting, short-term stranguria was observed in our series and has been reported by other authors (Zaid et al., 2011). However, even a persistent stranguria, initially controllable only medically and finally requiring stent removal, was observed in one other cat, but, as any potential cause of stranguria (such as feline lower urinary tract disease, urinary tract infections, primary urinary tumours, secondary tumours, results of traumatic lesions causing external compression, and benign proliferative growth) were excluded, the cause remained unknown. However, as stranguria disappeared following stent removal, it may be speculated that the stent, since it protruded slightly into the bladder, may have acted as a chronic intravesical foreign body. A minor stent migration occurred in one cat; as this was an incidental finding (and the animal was asymptomatic), the stent was left in place and further migration and/or clinical worsening did not occur.

Infection was a minor problem in this study (with only one preoperative positive urine culture) and postoperative infection was not seen. However, in the cat with persistent stranguria requiring stent removal, even though bacteria were not isolated from urine, infection was still suspected. The low infection rate recorded in this series is in contrast with other reports that documented a 25-50% positivity of postoperative urine cultures, even when the cats were asymptomatic (Berent et al., 2009; Zaid et al., 2011).

After stenting, a complete resolution of the post-obstructive dilatation of the renal pelvis should not be expected, as the stent 'J tail' in the pelvis may not allow it (Zaid et al., 2011). This should be taken in consideration during the follow-up. Moreover, in humans, a passive dilatation of the ureter after stenting has also been reported (Hubert and Palmer, 2005). This may facilitate the migration of nephroliths and ureteroliths along the ureter into the bladder (Berent et al., 2007; Berent, 2011). This occurred also in our series.

Despite the fact that obstructive ureteroliths were all unilateral, there was a high prevalence of renal damage before and after stenting, indicating a pre-existing impairment of renal function in the contralateral kidney or pre-renal azotemia. This was also shown by Zaid et al. (2011). Ureteral stenting resulted in an improvement of all the tested renal biochemical values. Regarding renal function, it should be noted that although meloxicam was used here in an attempt to control inflammation, it cannot be recommended in cats with a renal compromise and in general it should be avoided.

The limitations of the present study are its retrospective nature, the limited number of cats included, the use of number 3 French diameter ureteral stents instead of smaller stents now available, and the lack of a control group of cats with ureteral calculi treated with ureterotomy alone. Despite these limitations, the use of ureteral stents after ureteral surgery planned for the relief of ureter obstructions may be considered safe and effective but further studies to confirm these findings are now required.

## Conclusions

Based on the long-term stent tolerance and the relatively few complications recorded in this retrospective case series, ureteral stenting was safe and effective. Ureteral stenting should mainly be considered for cats with concomitant ureteral and renal pelvis stones to avoid pyelotomy or nephrotomy (especially when there is impaired renal function) so preventing further ureteral obstruction caused by migrating stones. When a ureter is stented, nephroliths may move along it and reach the bladder. Interventional placement of the smallest ureteral stent available (endoscopically or through a nephrostomy needle access via laparotomy and fluoroscopic guidance) to avoid ureteral surgery and to decrease the operative time and the risk of complications such as urine leak-age and stricture, is recommended. However, if fluoroscopic equipment and/or small ureteral catheters are not readily available, surgery (ureterotomy/partial ureterectomy and neouretero-cystostomy) may be considered. In all cases, after stenting, periodical monitoring to check for complications that potentially may require removal and/or replacement of the stent, is warranted.

## Conflict of interest statement

None of the authors of this paper has a financial or personal relationship with other people or organisations that could inappropriately influence or bias the content of the paper.

## Acknowledgements

The authors wish to thank Drs. A. Zatelli, P. D'Ippolito and F. Nizi (Clinica Veterinaria Pirani, Reggio Emilia, Italy) for providing clinical assistance with some of the cases.



## References

- Berent, A.C., Mayhew, P., Aronson, L., Weisse, C., 2007. Applications of ureteral stenting for benign and malignant disease in small animals [Abstract]. *Veterinary Surgery* 36, E3.
- Berent, A.C., 2011. Ureteral obstructions in dogs and cats: A review of traditional and new interventional diagnostic and therapeutic options. *Journal of Veterinary Emergency and Critical Care* 21, 86-103.
- Berent, A.C., Weisse, C., Beal, M.W., Brown, D.C., Todd, K., Bagley, D., 2011. Use of indwelling double-pigtail stents for treatment of malignant ureteral obstruction in dogs: 12 cases (2006-2009). *Journal of the American Veterinary Medical Association* 238,1017-1025.
- Berent, A.C., Weisse, C., Bagley, D., Adan, C., Todd, K., Solomon, J., 2009. Ureteral stenting for feline ureterolithiasis. Technical and clinical outcome. In: *Proceedings of the American College of Veterinary Internal Medicine Forum*, Montréal, Canada (June 2-6), p. 686.
- Chen, G.L., Bagley, D.H., 2001. Fluoroscopic placement of double-pigtail ureteral stent. *Diagnostic and Therapeutic Endoscopy* 7,175-180.
- Corcoran, A., Smaldone, M., Ricchiuti, D.D., Averch, T.D., 2009. Management of benign ureteral strictures in the endoscopic era. *Journal of Endourology* 23, 1909-1912.
- Fossum, T.W., 2007. Surgery of the kidney and ureter. In: *Small Animal Surgery*, Third Ed. Mosby Elsevier, St. Louis, Missouri, MO, USA, pp. 635-662.
- Goldfischer, E., Gerber, G., 1997. Endoscopic management of ureteral strictures. *Journal of Urology* 157, 770-775.
- Haleblian, G., Kijvikai, K., de la Rosette, J., Preminger, G., 2008. Ureteral stenting and urinary stone management: A systematic review. *Journal of Urology* 179, 424-430.
- Hardie, E.M., Kyles, A.E., 2004. Management of ureteral obstruction. *Veterinary Clinics of North America: Small Animal Practice* 34, 989-1010.
- Hubert, K.C., Palmer, J.S., 2005. Passive dilation by ureteral stenting before ureteroscopy: Eliminating the need for active dilation. *Journal of Urology* 174, 1079-1080.
- Kyles, A.E., Hardie, E.M., Wooden, B.G., Adin, C.A., Stone, E.A., Gregory, C.R., Mathews, K.G., Cowgill, L.D., Vaden, S., Nyland, T.G., Ling, G.V., 2005a. Management and outcome of cats with ureteral calculi: 153 cases (1984-2002). *Journal of the American Veterinary Medical Association* 226, 937-944.
- Kyles, A.E., Hardie, E.M., Wooden, B.G., Adin, C.A., Stone, E.A., Gregory, C.R., Mathews, K.G., Cowgill, L.D., Vaden, S., Nyland, T.G., Ling, G.V., 2005b. Clinical, clinicopathologic, radiographic and ultrasonographic abnormalities in cats with ureteral calculi: 163 cases (1984-2002). *Journal of the American Veterinary Medical Association* 226, 932-936.
- Mehl, M.L., Kyles, A.E., Pollard, R., Jackson, J., Kass, P.H., Griffey, S.M., Gregory, C.R., 2005. Comparison of 3 techniques for ureteroneocystostomy in cats. *Veterinary Surgery* 34, 114-119.
- McMullin, N., Khor, T., King, P., 1993. Internal ureteric stenting following pyeloplasty reduces length of hospital stay in children. *British Journal of Urology* 72, 370-372.
- Mitty, H.A., Train, J.S., Dan, S.J., 1983. Antegrade ureteral stenting in the management of fistulas, strictures and calculi. *Radiology* 149, 433-438.
- Nicoli, S., Zatelli, A., D'Ippolito, P., Martano, M., Morello, E., Campione, S., Buracco, P., 2009. Ureteral double pig tail stenting in dogs and cats. Preliminary clinical results [abstract]. *Veterinary Surgery* 38, E11.
- Patel, R., Newman, R., 2004. Ureteroscopic management of ureteral and ureteroenteral strictures. *Urologic Clinics of North America* 31,107-113.
- Sieben, D.M., Howerton, L., Amin, M., Holt, H., Lich Jr., R., 1978. The role of ureteral stenting in the management of surgical injury of the ureter. *Journal of Urology* 119, 330-331.
- Talja, M., Multanen, M., Valimaa, T., Tormala, P., 2002. Bioabsorbable SR-PLGA horn stent after antegrade endopyelotomy: A case report. *Journal of Endourology* 16, 299-302.
- Weisse, C., Berent, A., Todd, K., Clifford, C., Solomon, J., 2006. Evaluation of palliative stenting for the management of malignant urethral obstructions in dogs. *Journal of American Veterinary Medical Association* 229, 226-234.
- Zaid, M.S., Berent, A.C., Weisse, C., Caceres, A., 2011. Feline ureteral strictures: 10 cases (2007-2009). *Journal of Veterinary Internal Medicine* 25, 222-229.
- Zimskind, P.D., Fetter, T.R., Wilkerson, J.L., 1967. Clinical use of long-term indwelling silicone rubber ureteral splints inserted cystoscopically. *Journal of Urology* 97, 840-844.