

AperTO - Archivio Istituzionale Open Access dell'Università di Torino

Repairing nerve gaps by vein conduits filled with lipoaspirate-derived entire adipose tissue hinders nerve regeneration.

This is the author's manuscript

Original Citation:

Availability:

This version is available <http://hdl.handle.net/2318/121463> since

Published version:

DOI:10.1016/j.aanat.2012.10.012

Terms of use:

Open Access

Anyone can freely access the full text of works made available as "Open Access". Works made available under a Creative Commons license can be used according to the terms and conditions of said license. Use of all other works requires consent of the right holder (author or publisher) if not exempted from copyright protection by the applicable law.

(Article begins on next page)



UNIVERSITÀ DEGLI STUDI DI TORINO

This Accepted Author Manuscript (AAM) is copyrighted and published by Elsevier. It is posted here by agreement between Elsevier and the University of Turin. Changes resulting from the publishing process - such as editing, corrections, structural formatting, and other quality control mechanisms - may not be reflected in this version of the text. The definitive version of the text was subsequently published in [*Annals of Anatomy*, volume 195, issue 3, May 2013, doi:10.1016/j.aanat.2012.10.012].

You may download, copy and otherwise use the AAM for non-commercial purposes provided that your license is limited by the following restrictions:

- (1) You may use this AAM for non-commercial purposes only under the terms of the CC-BY-NC-ND license.
- (2) The integrity of the work and identification of the author, copyright owner, and publisher must be preserved in any copy.
- (3) You must attribute this AAM in the following format: Creative Commons BY-NC-ND license (<http://creativecommons.org/licenses/by-nc-nd/4.0/deed.en>), <http://dx.doi.org/10.1016/j.aanat.2012.10.012>

Repairing nerve gaps by vein conduits filled with lipoaspirate-derived entire adipose tissue hinders nerve regeneration

Papalia I, Raimondo S, Ronchi G, Magaouda L, Giacobini-Robecchi MG, Geuna S.

^a Department of Biomorphology and Biotechnologies, University of Messina, Italy

^b Neuroscience Institute of the Cavalieri Ottolenghi Foundation (NICOF), University of Turin, 10043, Italy ^c Department of Clinical and Biological Sciences, University of Turin, 10043, Italy

Summary

In spite of great recent advancements, the definition of the optimal strategy for bridging a nerve defect, especially across long gaps, still remains an open issue since the amount of autologous nerve graft material is limited while the outcome after alternative tubulization techniques is often unsatisfactory. The aim of this study was to investigate a new tubulization technique based on the employment of vein conduits filled with whole subcutaneous adipose tissue obtained by lipoaspiration.

In adult rats, a 1 cm-long defect of the left median nerve was repaired by adipose tissue–vein-combined conduits and compared with fresh skeletal muscle tissue-vein-combined conduits and autologous nerve grafts made by the excised nerve segment rotated by 180°. Throughout the postoperative period, functional recovery was assessed using the grasping test. Regenerated nerve samples were withdrawn at postoperative month-6 and processed for light and electron microscopy and stereology of regenerated nerve fibers.

Results showed that functional recovery was significantly slower in the adipose tissue-enriched group in comparison to both control groups. Light and electron microscopy showed that a large amount of adipose tissue was still present inside the vein conduits at postoperative month-6. Stereology showed that all quantitative morphological predictors analyzed performed significantly worse in the adipose tissue-enriched group in comparison to the two control groups.

On the basis of this experimental study in the rat, the use of whole adipose tissue for tissue engineering of peripheral nerves should be discouraged. Pre-treatment of adipose tissue aimed at isolating stromal vascular fraction and/or adipose derived stem/precursor cells should be considered a fundamental requisite for nerve repair.

Introduction

Evidence has accumulated over the years that an optimal nerve guide must be based on two main components: (1) a tubular scaffold which bridges the nerve gap avoiding dispersion of regenerating axons; (2) a filler which promotes axon regeneration and Schwann cell migration both mechanically and biologically. As regards conduits, various types of biological and synthetic scaffolds have proved to be effective inadequately guiding nerve regeneration (Siemionow et al., 2010; Sinis et al., 2011). Among conduits of biological origin, a consensus seems to exist regarding the use of autologous veins because of their ubiquitous availability as well their distensibility facilitating the fashioning of guides of appropriate size (Chiu and Strauch, 1990; Terzis and Kostas, 2007). Also regarding luminal fillers, the second key element in bio-engineered nerve guides, a plea has been made for new approaches, and these are currently being explored worldwide and, similarly to conduits, both biological and synthetic material may be sought (Yan et al., 2009). As regards biological fillers, these can be both entirely autologous tissues, such as a piece of muscle (Battiston et al., 2009), as well as tissue extracts, such as stem/precursor cells (Erba et al., 2010). One of the tissues that has received a great deal of attention in tissue engineering over the last years is adipose tissue due to its extensive availability, the ease of its withdrawal from the same patient and the demonstration that it possesses stem cells (Zuk et al., 2001; Stosich and Mao, 2007; Cherubino et al., 2011; Gimble and Nuttall, 2011). The demonstration that adipocyte-derived mesenchymal stem cells retain the ability to differentiate, *in vitro*, into Schwann cell-like cells (Kingham et al., 2007) has opened interesting perspectives of adipose tissue employment in peripheral nerve reconstruction.

All previous experimental studies have pre-manipulated adipose tissue with the goal of extracting the stromal vascular fraction and/or its stem/precursor cells (Zhang et al., 2010; Tse et al., 2010; Lopatina et al., 2011; Wei et al., 2011; di Summa et al., 2011).

To further explore the potential of adipose tissue autotransplantation in nerve tissue engineering, the aim of this study has been to investigate whether whole adipose tissue; i.e. without physical and chemical pre-manipulation, used as a vein conduit filler could be effective in sustaining nerve regeneration along a 1-cm-long median nerve gap in the rat. The rationale for the study has been the consideration that, if the transplantation of whole adipose tissue aspirates had been successful, it could have been also accepted in the short term in the clinic because of the ease of its employment.

2. Materials and methods

Experiments were carried out on twenty Wistar adult female rats weighting 225...250 g (Charles River, Italy) at the Laboratory of Microsurgery of the Ecole de Chirurgie de Paris. Approval for this study was obtained from the local Institution's Animal Care and Ethics Committee. Animals were operated under deep anesthesia using ketamine (40 mg/250 g) and chlorpromazine (3.75 mg/250 g) with the aid of an operating microscope (Zeiss OPMI 7).

For adipose tissue...vein-combined (ATV C) nerve repair (n = 5), the left median nerve was approached from the anterior aspect and a 10-mm-long nerve segment was removed starting 3 mm downstream from its origin. The gap was then repaired by entubulation using a scaffold made with a segment of epigastric vein filled with adipose tissue withdrawn by lipoaspiration from dorsal panniculus adiposus, a fatty layer of the subcutaneous tissues underlying the corium and superficial to the vestigial layer of muscle (Fig. 1). The adipose tissue was not centrifuged and/or chemically manipulated. The dissection of the vein was completed immediately prior to the nerve transection via an anterior approach. The conduit was sutured using three or four stitches of 9-0 monofilament nylon for each nerve stump.

Two different groups were used as controls: in the first control group (n = 5), the gap was bridged by means of the excised segment rotated by 180° (autograft). In the second control group, the gap was repaired by entubulation using a muscle...vein-combined (MV C) scaffold made with a segment of epigastric vein filled with fresh skeletal muscle (Geuna et al., 2003; Tos et al., 2007). MV C conduit controls were preferred to empty vein nerve repair, since this type of biological tubulization has been proven as one of the more effective alternatives to nerve autograft (Battiston et al., 2009; Geuna et al., 2004) and thus was chosen as the tubulization benchmark for ATV C conduits.

2.1. Functional assessment

Functional assessment throughout the postoperative period was carried out every month by the grasping test (Papalia et al., 2003a,b) using the BS-GRIP Grip Meter (2Biological Instruments, Varese, Italy). The device measures the weight that the animal manages to hold with its grip when it is pulled by its tail and assesses median nerve function (Tos et al., 2009). Each animal was tested three times and the average value was recorded.

2.2. Histology and stereology

At postoperative month-6, the repaired nerves were carefully dissected, withdrawn and processed for light and electron microscopic analysis. Specimens were immediately fixed in a solution containing 2.5% glutaraldehyde and 0.5% sucrose in 0.1 M Sörensen phosphate buffer (pH 7.2) for 4...6 h (Raimondo et al., 2009). The specimens were then washed in a solution containing 1.5% sucrose in 0.1 M Sörensen phosphate buffer for a period of 6...12 h, post-fixed in 2% osmium tetroxide, dehydrated and embedded in Glauert's embedding mixture (Di Scipio et al., 2008).

Semi-thin sections perpendicular to the main axis of the repaired nerves were cut on an Ultracut UCT ultramicrotome (Leica, Wetzlar, Germany), and stained with toluidine blue. Stereology of regenerated nerve fibers was carried out on a DM4000B micro-scope equipped with a DF C320 digital camera and an IM50 image manager system (Leica Microsystems, Wetzlar, Germany) at a final magnification of 6600× which enables accurate identification of myelinated nerve fibers. One section from each nerve specimen was randomly selected and the total cross-sectional area (A) of the whole nerve profile was measured at low magnification. Sampling of nerve fibers was then carried out using a systematic random sampling protocol. Yet, in order to avoid the bias due to the edge effect, we adopted a two-dimensional disector procedure which is based on sampling the tops of fibers (Geuna et al., 2012). The total number of nerve fibers (N) was then estimated based on the mean fiber density (D) calculated by dividing the total number of nerve fibers within each sampling field by the sampling field area according to the following formula: $N = D \cdot A$.

The 2D-disector probe was also used to select an unbiased representative sample of myelinated nerve fibers in order to measure the circle-fitting diameter of fiber (D) and axon (d). Based on these data, myelin thickness was calculated for each nerve fiber $[(D - d)/2]$.

From the same tissue blocks, ultra-thin sections (50...70 nm) were also cut using the same ultramicrotome and placed on copper grids. Grids were then stained with uranyl acetate and lead citrate and observed on a JEM-1010 transmission electron microscope (JEOL, Tokyo, Japan) operating at 80 kV and equipped with a MegaView-III digital camera and a Soft-Imaging-System (SIS, Münster, Germany) for the computerized acquisition of the images.

2.3. Statistics

Statistical analysis was performed using the one-way repeated measures analysis of variance (RM-ANOVA) test. All statistical tests were performed using the software Statistica per discipline biomediche (McGraw-Hill, Milano, Italia).

3. Results

Careful postoperative surveillance showed that well-being was maintained for all animals throughout the postoperative period without occurrence of auto-mutilation, ulcers or joint contractures.

Results of functional assessment by the grasping test (Fig. 2) showed that, except for postoperative month-1, at which all animals showed complete functional loss, for all other time-points until the end of experiment at month-6, rats of the ATV C repair group showed a significantly ($p < 0.05$) lower recovery of motor function in comparison to MV C and control autograft repair groups. Statistical comparison between the latter two control groups showed that none of the observed numerical differences at the different time points were significant ($p > 0.05$).

Fig. 3(A, B) shows the light microscopic appearance of the ATV C scaffolds at the time of withdrawal (postoperative month-6). The presence of a large amount of adipose tissue inside the conduit

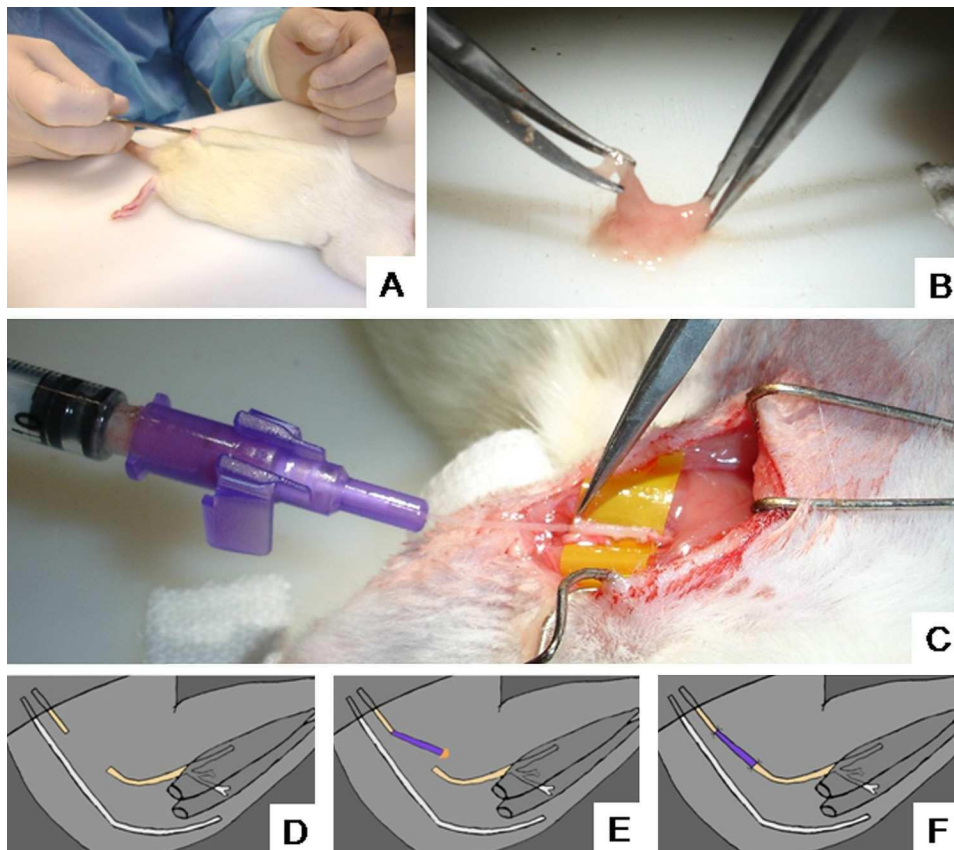


Fig. 1. Preparation of the adipose tissue-enriched vein scaffold. Lipoaspiration (A) is followed by mechanical trituration of adipose tissue (B) and its insertion inside the vein (C). The surgical procedure is summarized in the schematic drawings in pictures (D...E).

was still detectable at this late stage after repair and the total area occupied by nerve tissue was very limited.

Transmission electron microscopic observation (Fig. 4) showed clear signs of atrophic nerve regeneration in ATVC group. The nerve fascicles were small and included few axons with thin myelin sheathing (Fig. 4A...C). Schwann cells (which can be morphologically distinguished from “broblasts and perineurial cells because of their round-shaped profile) were small and poor in cytoplasmic organelles and often showed an irregularly shaped nucleus with chromatin condensation, a typical ultrastructural sign of pre-apoptotic status (Fig. 4D...F).

Fig. 5 shows the results of the design-based stereological analysis of normal and regenerated sciatic nerves at the end of the experiment (month-6). ATVC-repaired nerves have a significantly

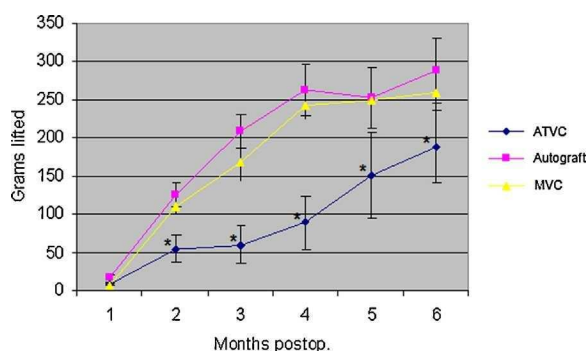


Fig. 2. Results of grasping test assessment throughout the postoperative period. ATVC = adipose tissue...vein-combined conduits. MVC = muscle...vein-combined conduits. * Significantly different from autograft group ($p < 0.05$). Results are presented as mean \pm standard deviation.

($p < 0.05$) lower total number of myelinated axons as well as significantly ($p < 0.01$) lower mean fiber diameter and myelin thickness in comparison to autograft and MVC-repair nerves.

4 . Discussion

The use of adipose tissue in tissue engineering has become very popular over the last years, generating great expectations in the general public (Stosich and Mao, 2007; Gimble and Nuttall, 2011; Brown et al., 2010; Locke et al., 2011; Moseley et al., 2006). It is now being proposed as a regenerative tool for various tissues and organs, including peripheral nerves (Zhang et al., 2010; Tse et al., 2010; Lopatina et al., 2011; Wei et al., 2011; di Summa et al., 2011), because it offers an effective and minimally invasive procedure for obtaining stem cells (Kern et al., 2006). In this experimental study, we wish to go beyond previous studies that used pre-manipulated adipose tissue for nerve reconstruction (with the goal of extracting the stromal vascular fraction and/or stem/precursor cells) by investigating the possibility of increasing the effectiveness of reconstruction of peripheral nerve defects using vein conduits filled with whole (i.e. not centrifuged and/or chemically treated) lipoaspirate-derived adipose tissue. Results showed that nerve regeneration and functional recovery in adipose tissue-filled vein conduit group was significantly worse in comparison to autografts and skeletal muscle-filled vein conduits.

A limitation of this study is certainly represented by the single time point assessment since morphological analysis of nerve regeneration at shorter postoperative times would have definitely provided us with more information about the regeneration process. Yet, the adoption of other control experimental groups, e.g. empty vein-repair, would have provided us with further comparative

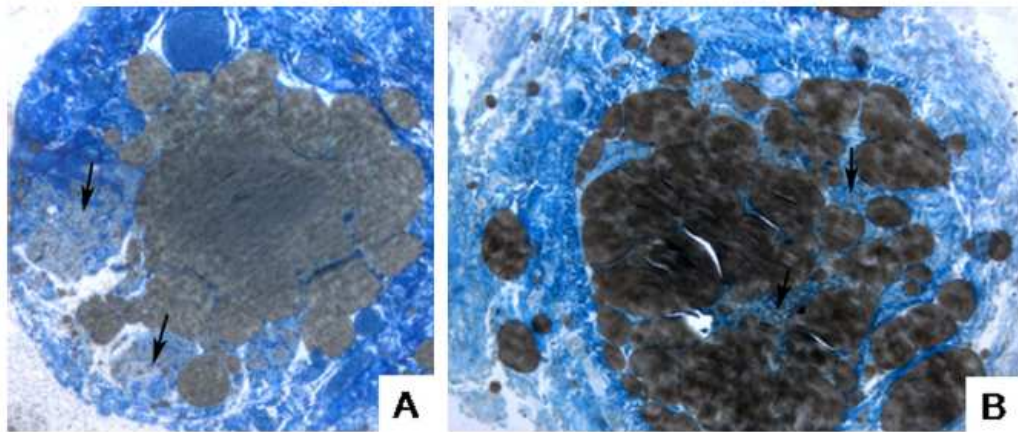


Fig. 3. Light microscopy of adipose tissue-vein-combined conduits at postoperative month-6 showing the long-term persistence of a large amount adipose tissue inside the nerve guide. Although limited by the presence of the adipose tissue, some fascicles of regenerated nerve fibers can be detected (arrows). Original magnification = 100 \times .

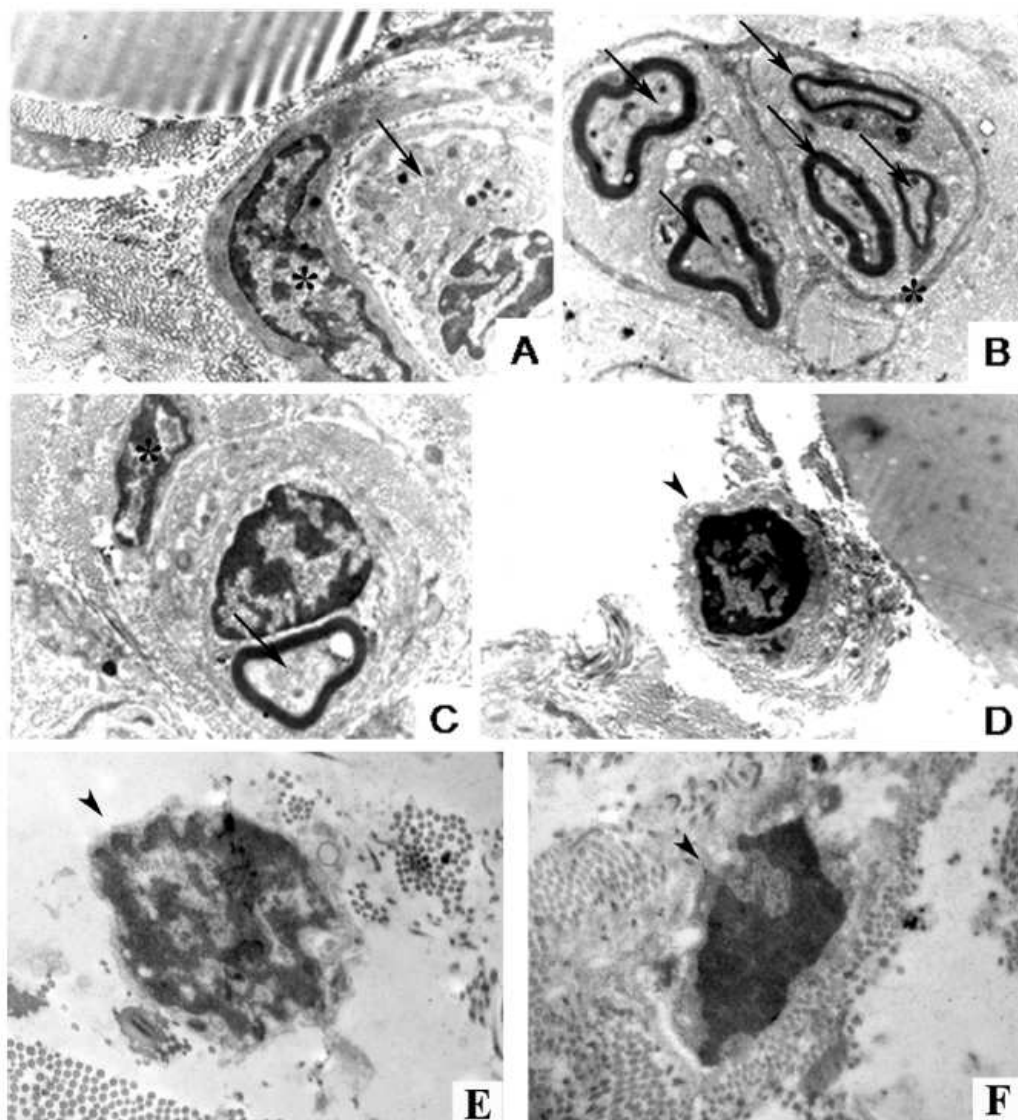


Fig. 4. Electron microscopy of adipose tissue-vein-combined conduits at postoperative month-6. Nerve fascicles delimited by perineurial cells (asterisks) appear atrophic, with few and small axons inside (arrows) (A-C). Also, Schwann cells (arrowheads) are recognizable because of their round-shaped profile, appear atrophic with a small amount of cytoplasm and an irregularly shaped nucleus with chromatin condensation (D-F), a typical ultrastructural sign of pre-apoptotic status. Original magnifications: A = 12,000 \times , B = 8,000 \times , C, D = 10,000 \times , E = 25,000 \times , F = 30,000 \times .

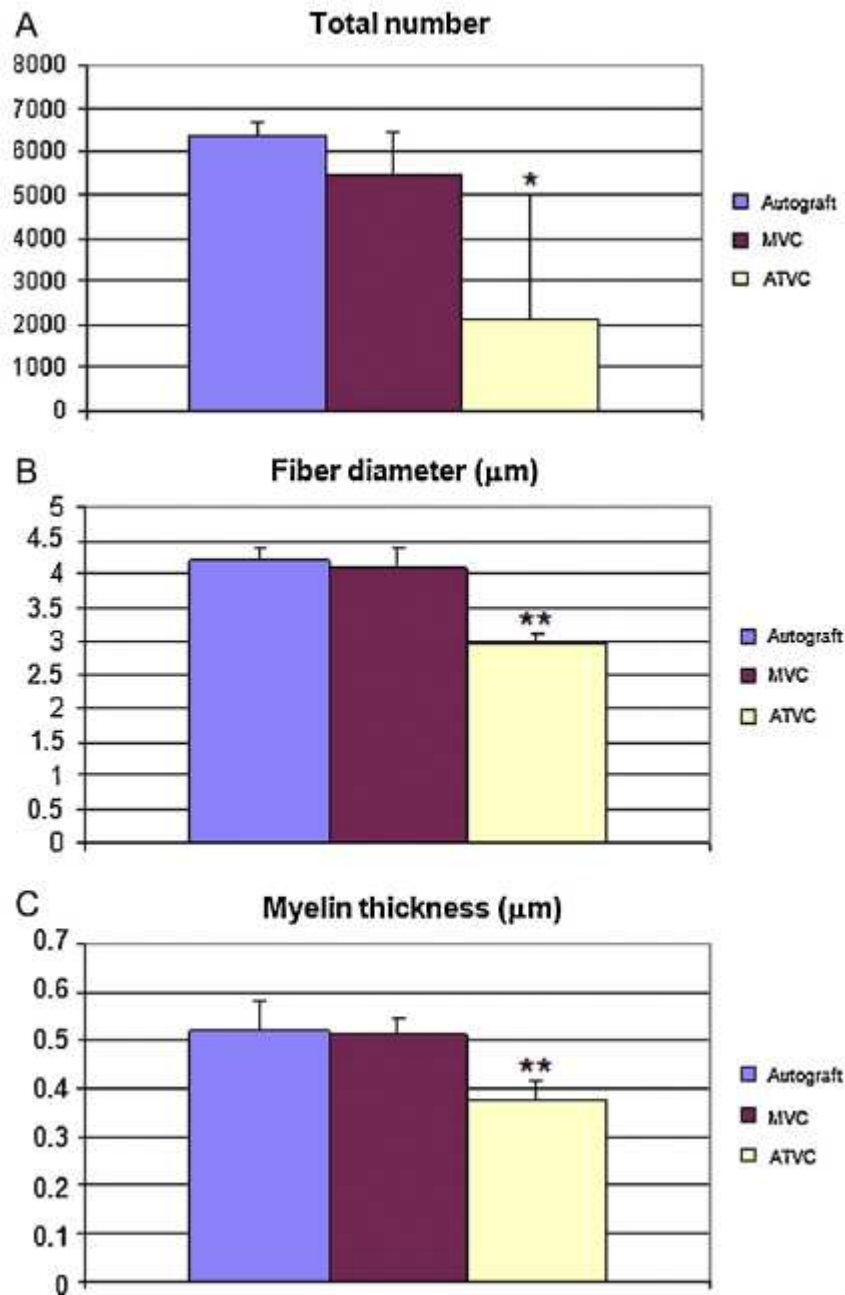


Fig. 5. Stereology of regenerated nerve fibers reporting the total number, mean fiber diameter and mean myelin thickness. Results are presented as mean \pm standard deviation. * $p < 0.05$; ** $p < 0.01$.

information on nerve recovery. However, the failure of nerve regeneration was so clear, in comparison to controls, and conclusive as to the inadequateness of ATVC for nerve reconstruction, that the completion of the study with more time points and control groups appeared unjustified both economically and, especially, ethically. In fact, the Ethical Committee imposes a minimum number of animals following the 'Three Rs' (replacement, reduction and refinement of animal studies) concept put forward by Russell and Burch (1992). On the other hand, the decision to interrupt the study opened a critical point as to the divulgation of the negative results obtained. Actually, positive result bias is another emerging ethical issue in biomedical research and appears to be particularly relevant in peripheral nerve reconstruction and tissue engineering studies (Raimondo et al., 2011). In fact, besides the unwillingness of many researchers to publish negative results (because this is erroneously perceived to be a failure of the scientist), in

peripheral nerve repair research, positive result bias might be even more pronounced since long-term experimental protocols are usually required and, therefore, when ineffectiveness or negative effects appear in experimental data, the study will be probably interrupted and its results not considered suitable for being submitted for publication (Raimondo et al., 2011). If this occurs, it will have a negative consequence on scientific advancement, since publication of negative results prevents repetition of unsuccessful experiments and facilitates focusing research resources on the most promising approaches. For these reasons, we decided to submit the experimental data in our hands for publication in spite of the above-mentioned limitations of the study. The morphological observations reported in our study also throw light on the mechanisms underlying the negative outcome of adipose tissue-filled vein conduits. In fact, it resulted clearly that, even a long time after surgery, a large amount of autotransplanted adipose tissue was still present inside the vein conduit. It can thus be hypothesized that the long-time survival of adipose tissue inside the nerve guide has negatively interfered with regenerating axons and migrating Schwann cells both mechanically, by occluding a large part of the conduit lumen, and metabolically, by consuming nutrients and oxygen. Altogether it results that physical or chemical extraction of the stem cell fraction is a requisite for employing adipose tissue for nerve reconstruction and we hope that our results will prevent unwary surgeons to attempt dangerous whole adipose tissue autotransplants in human subjects under the pressure of the rising popularity of adipose tissue-based tissue engineering.

Acknowledgments

The authors wish to thank Josette Legagnaux and Jean Luc Vignes and the Laboratoire de Microchirurgie de l'Ecole de Chirurgie de Paris for the valuable expert and technical assistance. This work was supported by grants from the MIUR, from the Compagnia di San Paolo and from the Regione Piemonte (Progetto Ricerca Sanitaria Finalizzata).

References

- Battiston, B., Raimondo, S., Tos, P., Gaidano, V., Audisio, C., Scevola, A., Perroteau, I., Geuna, S., 2009. Tissue engineering of peripheral nerves. *Int. Rev. Neurobiol.* 87, 227–249.
- Brown, S.A., Levi, B., Lequeux, C., Wong, V.W., Mojallal, A., Longaker, M.T., 2010. Basic science review on adipose tissue for clinicians. *Plast. Reconstr. Surg.* 126, 1936–1946.
- Cherubino, M., Rubin, J.P., Miljkovic, N., Kelmendi-Doko, A., Marra, K.G., 2011. Adipose-derived stem cells for wound healing applications. *Ann. Plast. Surg.* 66, 210–215.
- Chiu, D.T., Strauch, B., 1990. A prospective clinical evaluation of autogenous vein grafts used as a nerve conduit for distal sensory nerve defects of 3 cm or less. *Plast. Reconstr. Surg.* 86, 928–934.
- Di Scipio, F., Raimondo, S., Tos, P., Geuna, S., 2008. A simple protocol for paraffin-embedded myelin sheath staining with osmium tetroxide for light microscope observation. *Microsc. Res. Tech.* 71, 497–502.
- di Summa, P.G., Kalbermatten, D.F., Pralong, E., Raffoul, W., Kingham, P.J., Terenghi, G., 2011. Long-term in vivo regeneration of peripheral nerves through bioengineered nerve grafts. *Neuroscience* 181, 278–291.
- Erba, P., Mantovani, C., Kalbermatten, D.F., Pierer, G., Terenghi, G., Kingham, P.J., 2010. Regeneration potential and survival of transplanted undifferentiated adipose tissue-derived stem cells in peripheral nerve conduits. *J. Plast. Reconstr. Aesthet. Surg.* 63, 811–817.
- Geuna, S., Raimondo, S., Nicolino, S., Boux, E., Fornaro, M., Tos, P., Battiston, B., Perroteau, I., 2003. Schwann-cell proliferation in muscle–vein combined conduits for bridging rat sciatic nerve defects. *J. Reconstr. Microsurg.* 19, 119–123.
- Geuna, S., Tos, P., Battiston, B., Giacobini-Robecchi, M.G., 2004. Bridging peripheral nerve defects with muscle–vein combined guides. *Neurol. Res.* 26, 139–144.
- Geuna, S., Raimondo, S., Fornaro, M., Giacobini-Robecchi, M.G., 2012. Morpho-quantitative stereological analysis of peripheral and optic nerve fibers. *Neuroquantology* 10, 76...86.
- Gimble, J.M., Nuttall, M.E., 2011. Adipose-derived stromal/stem cells (ASC) in regenerative medicine: pharmaceutical applications. *Curr. Pharm. Des.* 17, 332...339.
- Kern, S., Eichler, H., Stoeve, J., Klüter, H., Bieback, K., 2006. Comparative analysis of mesenchymal stem cells from bone marrow, umbilical cord blood, or adipose tissue. *Stem Cells* 24, 1294...1301.

- Kingham, P.J., Kalbermatten, D.F., Mahay, D., Armstrong, S.J., Wiberg, M., Terenghi, G., 2007. Adipose-derived stem cells differentiate into a Schwann cell phenotype and promote neurite outgrowth in vitro. *Exp. Neurol.* 207, 267...274.
- Locke, M., Feisst, V., Dunbar, P.R., 2011. Concise review: human adipose-derived stem cells: separating promise from clinical need. *Stem Cells* 29, 404...411.
- Lopatina, T., Kalinina, N., Karagyaur, M., Stambolsky, D., Rubina, K., Revischin, A., Pavlova, G., Parfyonova, Y., Tkachuk, V., 2011. Adipose-derived stem cells stimulate regeneration of peripheral nerves: BDNF secreted by these cells promotes nerve healing and axon growth de novo. *PLoS ONE* 6, e17899.
- Moseley, T.A., Zhu, M., Hedrick, M.H., 2006. Adipose-derived stem and progenitor cells as fillers in plastic and reconstructive surgery. *Plast. Reconstr. Surg.* 118, 121S...128S.
- Papalia, I., Geuna, S., Tos, P.L., Boux, E., Battiston, B., Stagno d'Alcontres, F., 2003a. Morphologic and functional study of rat median nerve repair by terminolateral neurotaphy of the ulnar nerve. *J. Reconstr. Microsurg.* 19, 257...264.
- Papalia, I., Tos, P., Stagno d'Alcontres, F., Battiston, B., Geuna, S., 2003b. On the use of the grasping test in the rat median nerve model: a re-appraisal of its efficacy for quantitative assessment of motor function recovery. *J. Neurosci. Methods* 127, 43...47.
- Raimondo, S., Fornaro, M., Di Scipio, F., Ronchi, G., Giacobini-Robecchi, M.G., Geuna, S., 2009. Methods and protocols in peripheral nerve regeneration experimental research: part II. Morphological techniques. *Int. Rev. Neurobiol.* 87, 81...103.
- Raimondo, S., Fornaro, M., Tos, P., Battiston, B., Giacobini-Robecchi, M.G., Geuna, S., 2011. Perspectives in regeneration and tissue engineering of peripheral nerves. *Ann. Anat.* 193, 334...340.
- Russell, W.M., Burch, R.L., 1992. *The Principles of Humane Experimental Technique* Universities Federation for Animal Welfare (UFAW). Blackwell Publishing, Hertfordshire.
- Siemionow, M., Bozkurt, M., Zor, F., 2010. Regeneration and repair of peripheral nerves with different biomaterials: review. *Microsurgery* 30, 574...588.
- Sinis, N., Kraus, A., Drakotos, D., Doser, M., Schlosshauer, B., Müller, H.W., Skouras, E., Bruck, J.C., Werdin, F., 2011. Bioartificial reconstruction of peripheral nerves using the rat median nerve model. *Ann. Anat.* 193, 341...346.
- Stosich, M.S., Mao, J.J., 2007. Adipose tissue engineering from human adult stem cells: clinical implications in plastic and reconstructive surgery. *Plast. Reconstr. Surg.* 119, 71...83.
- Terzis, J.K., Kostas, I., 2007. Vein grafts used as nerve conduits for obstetrical brachial plexus palsy reconstruction. *Plast. Reconstr. Surg.* 120, 1930...1941.
- Tos, P., Battiston, B., Nicolino, S., Raimondo, S., Fornaro, M., Lee, J.M., Chirila, L., Geuna, S., Perroteau, I., 2007. Comparison of fresh and predegenerated muscle-vein-combined guides for the repair of rat median nerve. *Microsurgery* 27, 48...55.
- Tos, P., Ronchi, G., Papalia, I., Sallen, V., Legagneux, J., Geuna, S., Giacobini-Robecchi, M.G., 2009. Methods and protocols in peripheral nerve regeneration experimental research: part I. Experimental models. *Int. Rev. Neurobiol.* 87, 47...79.
- Tse, K.H., Sun, M., Mantovani, C., Terenghi, G., Downes, S., Kingham, P.J., 2010. In vitro evaluation of polyester-based scaffolds seeded with adipose derived stem cells for peripheral nerve regeneration. *J. Biomed. Mater. Res. A* 95, 701...708.
- Wei, Y., Gong, K., Zhang, Z., Wang, A., Ao, Q., Gong, Y., Zhang, X., 2011. Chitosan/silk brain-based tissue-engineered graft seeded with adipose-derived stem cells enhances nerve regeneration in a rat model. *J. Mater. Sci. Mater. Med.* 22, 1947...1964.
- Yan, H., Zhang, F., Chen, M.B., Lineaweaver, W.C., 2009. Conduit luminal additives for peripheral nerve repair. *Int. Rev. Neurobiol.* 87, 199...225.
- Zhang, Y., Luo, H., Zhang, Z., Lu, Y., Huang, X., Yang, L., Xu, J., Yang, W., Fan, X., Du, B., Gao, P., Hu, G., Jin, Y., 2010. A nerve graft constructed with xenogeneic acellular nerve matrix and autologous adipose-derived mesenchymal stem cells. *Biomaterials* 31, 5312...5324.
- Zuk, P.A., Zhu, M., Mizuno, H., Huang, J., Futrell, J.W., Katz, A.J., Benhaim, P., Lorenz, H.P., Hedrick, M.H., 2001. Multilineage cells from human adipose tissue: implications for cell-based therapies. *Tissue Eng.* 7, 211...228.