

## PICTURES IN DIGESTIVE PATHOLOGY

### Boerhaave's syndrome: diagnostic gastroscopy

Rocío Ferreiro-Iglesias<sup>1</sup>, Manuel Narciso Blanco-Freire<sup>2</sup>, Manuel Paz-Novo<sup>2</sup> and J. Enrique Domínguez-Muñoz<sup>1</sup>

Departments of <sup>1</sup>Gastroenterology and <sup>2</sup>Surgery. Hospital Clínico Universitario de Santiago. Santiago de Compostela, A Coruña. Spain

#### CASE REPORT

A 47-year-old man was attended at the Emergency Room for severe chest pain after eating sausage, with subsequent vomiting and mild upper gastrointestinal bleeding. In the chest radiography we could not see abnormalities. He referred previous episodes of choking without consulting. The urgent gastroscopy detected tertiary contractile activity (nutcracker esophagus) and a foreign body in the lower third of the esophagus. After removing the food bolus, we observed a 4 cm longitudinal tear compatible with esophageal rupture or Boerhaave's syndrome in the right posterior wall of the lower esophagus, proximal to the gastroesophageal junction. Thoracic-abdominal computed tomography (TC) confirmed a perforation of the lower esophagus, with pneumothorax and cervical and chest emphysema. Surgical treatment was indicated: esophageal suture, myotomy and gastric fundoplication. The patient presented good evolution.

#### DISCUSSION

Boerhaave's syndrome is a rare syndrome, but with high mortality (35%). Mackler triad is very characteristic: vomit-

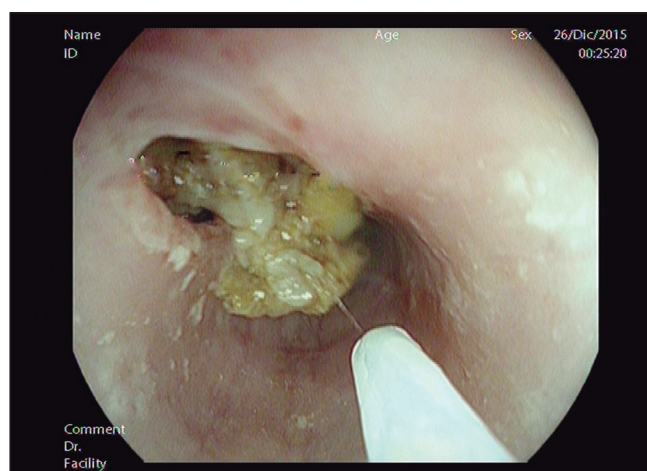

Fig. 1. Endoscopic image. A foreign body in the lower third of the esophagus.

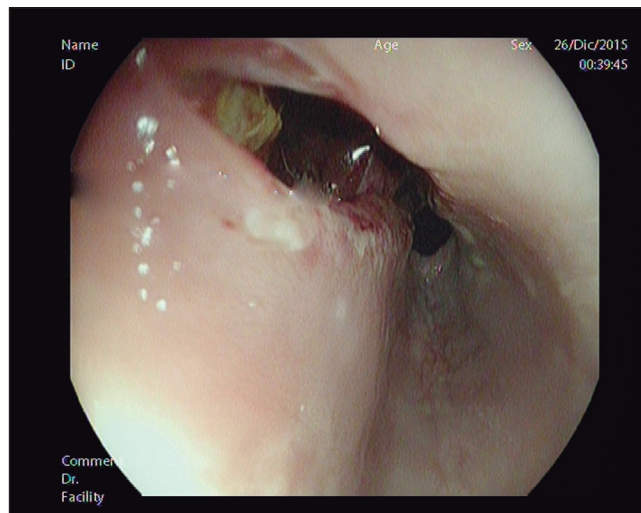


Fig. 2. Endoscopic image. A 4 cm longitudinal tear in the right posterior wall of the lower esophagus, proximal to the gastroesophageal junction, with adherent clot.

ing, retrosternal pain, and cervical subcutaneous emphysema; but it rarely occurs (1). Chest radiography is useful, showing abnormalities in up to 90% of patients (2). The differential diagnosis includes cardiorespiratory disorders: acute myocardial infarction, spontaneous pneumothorax, pericarditis or pneumonia. The role of endoscopy is small, mainly limited to prosthesis placement in high-risk surgical patients (3). In our case the chest radiograph was initially normal, probably related to bolus impaction and in presence of upper gastrointestinal bleeding gastroscopy was performed, allowing us to perform early diagnosis and treatment.

#### REFERENCES

1. Salvador Baudet J, Arencibia A, Soler M, et al. Spontaneous esophageal rupture. Boerhaave's syndrome. *Rev Esp Enferm Dig* 2011;103:482-3. DOI: 10.4321/S1130-01082011000900008
2. Vallböhmer D, Hölscher AH, Hölscher M, et al. Options in the management of esophageal perforation: Analysis over a 12-year period. *Dis Esophagus* 2010;23:185-90. DOI: 10.1111/j.1442-2050.2009.01017.x
3. Rodríguez-Infante A, Granero-Castro P, Álvarez-Pérez JA, et al. Atypical localization in Boerhaave's syndrome. *Rev Esp Enferm Dig* 2012;104:555-7. DOI: 10.4321/S1130-01082012001000012