



Review

Parosteal Osteosarcoma of the skull: Pathophysiological and imaging review

Hajra Idrees^{a,*}, Raza Zarrar^{b,2}, Bilal Mujtaba^a

^a The University of Texas MD Anderson Cancer Center, 1515 Holcombe Blvd., Houston, TX, United States of America

^b Baptist Hospitals of Southeast Texas, 3080 College St, Beaumont, TX, United States of America

ARTICLE INFO

Keywords:

Parosteal
Osteosarcoma
Temporal bone
Skull
Sarcoma

ABSTRACT

Parosteal Osteosarcoma (POS) is a well-differentiated low-grade malignant sarcoma occurring at the bone surface. POS of the skull is exceedingly rare, with only 4 temporal bone cases reported in modern literature. This tumor may resemble a multitude of entities, hence identifying it is critical. This may be achieved through a combination of clinical, histopathological, and imaging diagnostic techniques. POS may recur locally or dedifferentiate, the latter having a worse prognosis. This review aims to update the reader regarding the management of the rare Parosteal Osteosarcoma located in the skull bone.

1. Introduction and classification

Parosteal Osteosarcoma (POS) is a rare low-grade bone tumor arising from the outer layer of the cortex. In 1951 Geschickter and Copeland were the first to describe this tumor. The first reported POS in the craniofacial location was reported in 1961 [16,15,8].

Sarcoma may arise from bone or connective tissue with the former called bone sarcoma [Fig. 1]. Osteosarcoma is a subtype of bone sarcomas. Osteosarcoma develop in bone manufacturing osteoblastic cells and therefore may produce osteoid. Osteosarcoma are further divided based on their location within the bone. 'Central osteosarcoma' originate intramedullary, whereas the much rarer 'Surface osteosarcoma' arise from the peripheral part of the bone. WHO further subclassifies Surface osteosarcomas into Parosteal, Periosteal, and the high-grade surface Osteosarcoma. On histologically, POS is the most well differentiated low grade variant, low to intermediate grade is the Periosteal osteosarcoma, whereas the High-Grade Surface osteosarcoma is the least differentiated variant of the three. The origin of these sub types Varies. The high-grade surface osteosarcoma arises from the bone surface, POS from the outer periosteum while periosteal osteosarcoma originates from the inner periosteum [9,6,11,16,10,1,5,2,13,4,3].

Alternatively, Zarbo and Carlson classified osteosarcomas according to the site of origin into conventional (intramedullary), juxtacortical and extra-skeletal osteosarcomas. The Juxtacortical variant originates on the

external surface of the bone (periosteum, connective tissue), and includes both intermediate or high grade periosteal, and POS variants [17].

POS is further categorized as either conventional POS (CPOS) or Dedifferentiated POS (DPOS). Both may be either histologically low, intermediate (predominantly chondroblastic periosteal osteosarcoma) or high grade. High grade DPOS coexists with the usual low-grade POS. This is more commonly seen at the time of presentation in Synchronous DPOS, or at the time of recurrence with Metachronous DPOS [9,6,11,1,13].

2. Incidence

POS is an uncommon tumor of the human body, found exceedingly rarely in the skull. This carcinoma is most prevalent in the mandible and maxillary bones. To date, temporal bone POS has only 4 reported cases in literature [9].

Only a minute fraction of DPOS lesions are in the skull; current literature spots only 2 skull DPOS cases. In a study done by the Rizzoli Institute, out of the 29 patients diagnosed with DPOS, only 1 of them had a skull lesion. [12,6,11,14,16,10].

* Corresponding author.

E-mail address: hidrees@mdanderson.org (H. Idrees).

¹ ORCID: 0000-0003-2283-616X.

² ORCID: 0000-0003-3349-9285.

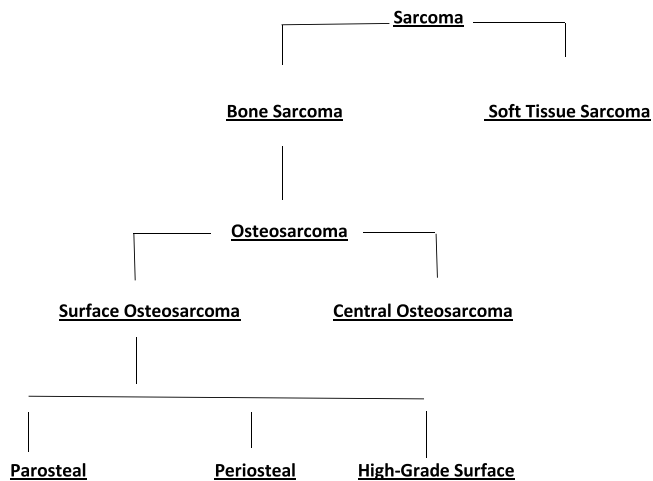


Fig. 1. Classification of sarcoma.

3. Presentation

POS most commonly presents in females in their thirties as a slowly progressing painless swelling on the surface of the bone; hence it may be mistaken for a benign lesion. Lasting for years, the mass is non-lobular, expansile, exophytic and osseous in nature, with a potential for overlying mucosal ulceration, and may decrease range of motion of the adjacent joint. Whilst majority of cases reported are painless, lack paresthesia and lymphadenopathy, a dull aching pain with local tenderness may also be felt by some patients.

In contrast, DPOS may present with pain, with an older mean age of 36 years. Jaw POS may present in older age males, with a peak age of 39 years, and a higher histological grade. One study found up to 65 % DPOS patients presenting with medullary canal invasion, when compared to only 28 % in CPOS [12,9,6,11,14,16,10,13].

4. Etiology

Osteosarcomas may result from radiation therapy and a multitude of other causes. Radiation that inadequately destroys all viable cells may induce malignant transformation in cells. Other risk factors include preexisting bone abnormalities, hereditary retinoblastoma, Li–Fraumeni syndrome and Rothmund–Thomson syndrome [9].

Hypotheses suggest DPOS, along with CPOS, may originate from a common nest of mesenchymal cells, which subsequently differentiate along separate cellular lineages [14].

POS patients genetically show amplified genes CDK4 and MDM2, both important in cell cycle regulation with gene protein products usually showing coordinate overexpression. In difficult cases, immunohistochemical stains for CDK4 and MDM2 prove noteworthy since lesions excluding POS and central low-grade osteosarcoma, rarely appear positive for these markers [10].

5. Pathology

Macroscopically, POS are ill-defined, hard or ossified, broad based exophytic tumors with a regular external surface which may outgrow its base of origin. A cartilaginous cap has been observed in about a quarter case. The margins are well demarcated and lobulated, although surrounding soft tissue invasion is seen. On sectioning the tumor, a homogeneous solid ivory bone resembling mass, composed of intermixed bone, fibrous, and cartilaginous tissue involving the periosteum is seen [6,11,10].

The most well recognized pattern of POS is the Streamer pattern. It is well-differentiated and biphasic, consisting of a spindle cell stroma phase alongside a trabecular bone phase. Since it is low in grade, the

stroma constitutes fibroblastic spindle cells with moderate cellularity and minimal atypia immersed in a background of collagen. The nuclei are oval with tapered ends, 1–2 nucleoli, scattered chromatin, low mitotic activity and rare mitotic figures. Bone trabeculae comprise parallel mature woven bone scattered in the stroma, which may coalesce over time to form a large mass. Osteoblastic rimming, osteoclastic giant cells, and irregular cement lines may also be seen. [16,10].

Other variants include cartilaginous foci or differentiations, seen in up to 40–55 % POS cases, where irregularly arranged chondrocytes display mild to moderate pleomorphism and occasional binucleation. Another rare variant identified contained combined well differentiated lipo-sarcomatous elements [16,10].

CPOS may also be classified according to tumor histological grade. Broders Grade 1 tumors display minimal atypia and mitotic activity. Broders Grade 2 tumor spindle cells appear increasingly crowded, pleomorphic with elevated atypia. Broders Grade 3 and 4 are high grade anaplastic tumors with an increased mitotic rate. Therefore these tumors features overlap with those of osteoblastic osteosarcomas, fibroblastic osteosarcomas, giant cell-rich osteosarcomas, and chondroblastic osteosarcomas [6].

Certain studies have observed up to 10 % POS cases dedifferentiating into a high-grade osteosarcoma, presenting with a significantly worse prognosis. Therefore it is pertinent to microscopically distinguish DPOS from high-grade tumors. Histologically, DPOS presents as a nonhomogeneous solid gritty mass with soft tan sarcomatous areas, and possible focal necrosis and hemorrhage. Cortical destruction and medullary canal invasion may also be seen. Primary DPOS occurs when a high-grade sarcoma is found juxtaposed to a low-grade POS at presentation. Less commonly, secondary DPOS may be seen after multiple recurrences of a low-grade tumor. POS may dedifferentiate into many varieties of high-grade sarcomas, including fibroblastic, osteoblastic, or chondroblastic osteosarcoma; fibrosarcoma; malignant fibrous histiocytoma; and rhabdomyosarcoma [12,6,11,14,16,10].

6. Imaging

Radiographically, POS of the skull are round or oval, sessile, cauliflower like, lobulated, exophytic bone growths arising from the outer table or external cortex of the skull, with irregular mineralization. These lesions are considered radio-dense forming a sunburst pattern, since the base is denser than its periphery [12,16,10].

6.1. Features

Several distinct features help distinguish POS from other entities. The String sign is a characteristic cleavage plane seen in up to 30–65 % of cases. It is a radiolucent cleavage line which consists of partially eroded, thickened, unmineralized periosteum with poor to well defined margins. Periosteal reaction is minimal. Reflective of entrapped soft tissue, this periosteum cleavage line is sandwiched between two layers namely, the outer table of the skull or cortex, and the overlying tumor. The cortex of the skull may be normal, have reactive sclerosis, or may even show evidence of bony erosion or destruction. Various other radiological features have also been observed, including cotton wool with a distinct margin, patchy radiopacity, a diffuse hazy opacification with few fine bony spicules radiating from the lower border of the lesion, and many interlacing coalescing trabeculae of varying thickness forming a meshwork from the lower border of the cortex on Three Dimensional Computerized Tomography (3D CT) [12,16,10].

6.2. CT/MRI

Computed Tomography (CT) or Magnetic Resonance Imaging (MRI) scans are preferred over conventional radiographic imaging for accurately diagnosing POS. The bone cortex and medullary cavity are better visualized by cross sectional imaging via CT or MRI, but many other

reasons also come in play. Firstly, anatomically the characteristic radiolucent cleft on routine radiographs may be of hurdle. Especially with the jaw where tangential view or CT scans [Image 1] may prove beneficial, although this radiolucent cleft may obliterate as the tumor enlarges. Secondly, cross-sectional imaging with a CT scan may better demonstrate the architecture of the lesion. Tumor confinement, attachment to the cortex, cortical erosions, radiating bony trabeculae, hyperdense homogeneous compact bone like mass attached to the cortex by a short pedicle, a layer of hypodense tissue separating the sharply defined posterior margins from the maxillary cortex, irregularly thickened anterior margins overlying the mucosa with no local infiltration. These features may also be important to distinguish these lesions from benign or low-grade osteosarcomas, or other processes, although underlying bone sclerosis may also be seen in benign POS. Although the CT scan may not be able to differentiate a benign from a low-grade osteosarcoma. Thirdly, the CT scan provides a preoperative evaluation of the tumor elaborating the heterogeneity of the tumor, satellite nodules, and the extent of skull involvement. Lastly, the CT or MRI stages the tumor and detects DPOS. Intramedullary extension or satellite lesions in surrounding soft tissue are accurately identified. An MRI is advised when recurrence and bone marrow involvement is suspected, while a CT scan is diagnostic for evaluating cortical integrity and to rule out metastasis, specifically Scintigraphy and chest CT to confirm the presence of a solitary tumor [12,11,16,10].

DPOS presents as an ill-defined soft tissue mass confined or adjacent to the ossified tumor. MRI, especially Gadolinium enhanced MRI, is instrumental in identifying DPOS due to a multitude of reasons. Firstly, Gadolinium enhanced MRI distinguishes the histologically high from the low-grade variant, since low-grade lesions display low signal intensity on Transverse Relaxation time (T1- and T2) weighted images, while high-grade, necrotic, fat, inflamed and hemorrhagic lesions correlate to high T2 signal intensity areas. Contrast enhancing demonstrates these areas to guide biopsy, where DPOS enhancement is dense relative to its marginally enhancing low-grade counterpart. Occasionally biopsy sampling DPOS within a densely calcified POS is troublesome, and if needle biopsy under fluoroscopic guidance also fails, CT and MRI imaging can identify the areas with the highest probability of DPOS for biopsy. Secondly, skull infections may imitate osseous skull lesions,

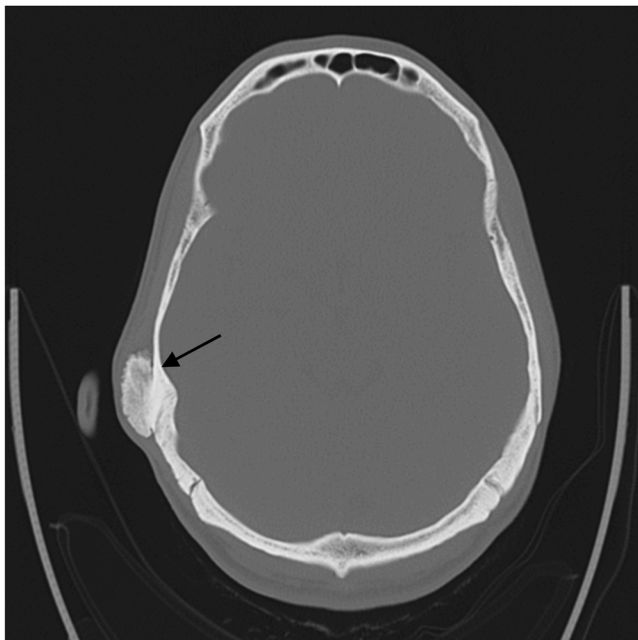


Image 1. CT scan without contrast: parosteal osteosarcoma of the temporal bone: Solid bony nodule (arrow) measuring 3.1×1.2 cm located on the right temporal bone.

which may be differentiated with the help of a Diffusion weighted MRI. Thirdly, Gadolinium enhanced MRI is useful for monitoring responsiveness to chemotherapy by highlighting non-enhancing chemotherapy induced necrosis regions within the enhancing DPOS. This is helpful since a discrepancy was observed in the necrosis highlighted by Gadolinium enhanced MRI, when compared to the lesion histology, although dynamic enhanced MRI is preferred for monitoring in this scenario. Here an early phase steep and rapid uptake represents a viable tumor, whereas a gradual and delayed enhancement signals inflammation. Other studies suggest a correlation between angiographic vascularity, and high-grade or DPOS lesions. T2-weighted MRI has traditionally been preferred over the CT scan for diagnosing DPOS, since MRI better distinguishes DPOS from fat and necrosis. Whereas on CT, DPOS appears less radiopaque and iso-dense with the brain, when compared to POS, suggesting a liposarcoma. Low attenuation on CT may signal DPOS, but fibrosis, cartilage and entrapped soft tissue may also present similarly [12,14,7,10] (Image 2).

7. Differential diagnosis

POS is a highly misdiagnosed tumor. Accurate diagnosis requires correlation of clinical, radiographic, and histologic features, since an alternate diagnosis may significantly alter the prognosis and treatment plan. Additionally, high grade POS (Broders Grade 3 and 4) has a high mitotic rate and anaplasia; hence may overlap with osteoblastic osteosarcomas, fibroblastic osteosarcomas, giant cell-rich osteosarcomas, and chondroblastic osteosarcomas [6,11,14,16,10].

Osteochondroma is difficult to differentiate from POS since they both share morphological and clinical features, peak age occurrence, and up to a quarter of POS patients may also present with a cartilaginous cap. Osteochondroma clinically appears as a pedunculated sessile mass covered by a thin cartilage cap. Histologically, its chondrocytes form perpendicular columns displaying polarity; clusters of lacunae superficially and small immature chondrocytes at the base of the lesion. Endochondral ossification is seen in the underlying trabecular bone, between which adipose or marrow tissue may be seen. In comparison, POS chondrocytes are more pleomorphic, with occasional binucleation and irregular columnar arrangement and polarity. Around 15 % may have focal fat between the trabecular bone, but a high proportion of spindle cell stroma is always present. On imaging, osteochondromas show continuity of cortex and medulla with the base of the lesion, which rarely may also occur in POS. Intramedullary osteochondroma may present as aggressive exophytic nodules with rapid expansion and medullary involvement. *High grade surface osteosarcomas* macroscopically present similar to POS, although are much more rapidly progressing. Histologically, the tumor spindle cells show marked nuclear atypia with lace-like osteoid production. *Periosteal Osteosarcomas* may resemble intermediate grade chondroblastic osteosarcomas due to their lobulated well-defined periphery comprising poorly differentiated malignant cartilaginous tissue, although characteristic comb like new bone formation at the adjacent cortex distinguishes it from the latter. Radiographically, periosteal osteosarcoma has an intact cortex with radiating calcified spicules, lacks bone marrow involvement, a poorly defined periphery, and a less dense or homogenous tumor matrix than POS. POS also displays a lack of continuity with cortical bone with possible medullary involvement on a panorex, outgrows its base of origin whilst arising from the outer cortex hence not elevating the periosteum. In contrast, Periosteal Osteosarcoma forms the Codman triangle by elevating the periosteum and displays a confined fusiform pattern of growth. *Osteogenic Sarcoma* holds a much worse prognosis than POS. It presents as a cellular pleomorphic anaplastic stroma forming amorphous islands of osteoid, with cartilage and fibrous tissue. *Noras lesion* has cartilage capping and distinct zones which distinguish it from POS. On Imaging, it mimics tori and exotosis on imaging. *Chondrosarcoma* may present as an aggressive, rapidly expanding exophytic nodule displaying medullary involvement on imaging. *Fibrous*

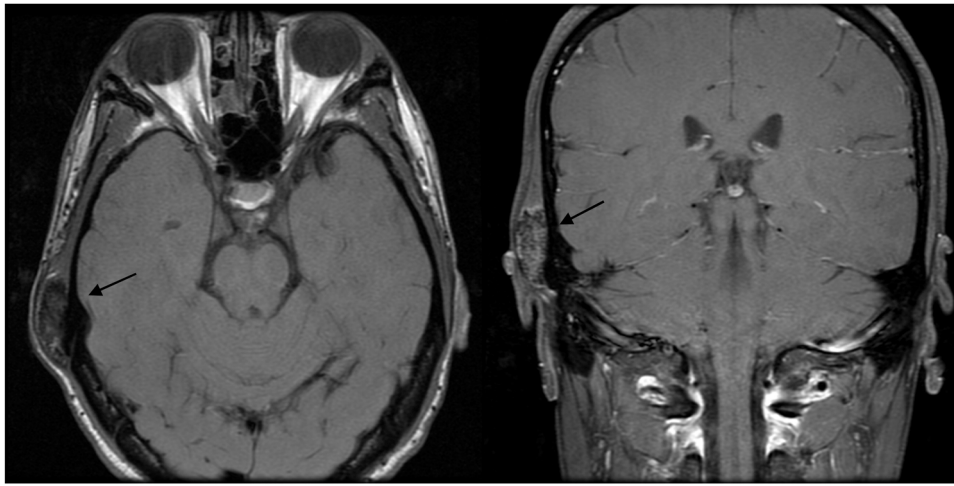


Image 2. MRI skull: parosteal osteosarcoma of skull: Densely calcified mass (arrows) measuring $3.6 \times 1.5 \times 3.0$ cm involving the inferior aspect of the squamous portion of the right temporal bone that is immediately superior to the petrous portion.

dysplasia's although pathologically distinct and intramedullary, may be misleading on small biopsy due to POS occasionally presenting in a similar manner. This pattern constitutes a Chinese calligraphy resembling irregular arrangement of trabecular bone, or an exophytic mass (fibrous dysplasia protuberans). Notably skull, jaw and ribs are the most common fibrous dysplasia locations. *Ossifying Fibroma's* desmoplastic fibroma like pattern may be seen uncommonly in POS on histopathology, although in POS a predominance of spindle cell stroma with abundant collagen bundles may be noted. It is usually seen in the periphery of the POS tumor, infiltrating into the adjacent soft tissue. Here imaging is of pertinence since desmoplastic fibromas aren't osteogenic hence the lesion appears less dense on radiographs. *Myositis ossificans* are clinically very rapidly progressing tumors. Histologically, the spindle cell component displays reactive myofibroblasts, abundant cytoplasm, frequent mitotic figures and the secondary zoning phenomenon, comprising centrally located plump spindle cells due to immature osteoid production, and peripheral mature trabecular bone. On imaging when involving the periosteum, it may present identically to the POS. *Osteomas* are composed of mature bone hence lacking the spindle cell proliferation, cellular pleomorphism, anaplasia and mitotic activity commonly seen in POS. The low-grade intraosseous osteosarcoma histology may overlap with that of POS. Fortunately on imaging, peripheral osteomas are more radio dense due to absent cartilaginous areas, and close fine trabecular striae resemble a feathers edge. Reactive processes due to *trauma* e.g. fractures, calluses, and ossifying hematomas may simulate mature bone tumors. This would necessitate a thorough clinical history. *Hyperostosis* on biopsy will show hyperplastic lamellar bone which differentiated it from POS. On imaging, *Tori and exostosis* occur at the same site, are painless slow growing masses with limited growth potential and can attach to the jaw cortex via a pedicle or wide base. Histopathology is preferred for diagnosis purposes [6,11,14,16,10].

8. Prognosis and treatment

CPOS has a favorable prognostic profile in comparison to conventional osteosarcomas and periosteal osteosarcomas. Craniofacial POS present as slow growing, low-grade tumors, with a metastatic rate of just 5 % metastatic rate. Unfortunately they may recur following local excision, an overlapping characteristic also seen in long bone POS. Aggressive extension of the tumor into the medullary cavity may occur in up to 22–58 % patients, although fortunately this doesn't seem to significantly affect the prognosis of this tumor. Mandibular POS has seen to hold improved outcomes when compared to maxillary bone POS. This may be due to the higher recurrence rate, increased intramedullary

involvement, and dedifferentiation to high grade sarcoma observed in POS of the maxillary bone [12,9,6,11,16,10].

Differentiating CPOS from benign lesions may prove bothersome. This may be due to the tendency of benign lesions to recur following limited local excision. A resultant recurrent or long-standing POS lesion mistaken to be benign may have evolved into an increasingly aggressive tumor. This necessitates a radical surgical excision or En bloc surgical resection with a wide cut of normal bone and negative margins, since the wide margins remove any satellite lesions and prevent local spread along the bone surface. This may be followed by chemotherapy if histologically malignant features, or recurrence is seen [12,9,11,16].

DPOS with transformation to a higher-grade sarcoma is important to recognize due to its worse prognosis. This is because of the accelerated tumor growth and tendency to recur and metastasize. 10 % POS dedifferentiate to a high-grade osteosarcoma. This demands radical treatment which constitutes wide excision with adjuvant chemotherapy, and occasional limb amputation. Although, one study noted up to 80 % patients treated with wide surgical excision alone survived; similar survival rates were also observed in the combined surgery and chemotherapy cohort. Likewise this treatment plan doesn't eliminate the chance of local recurrence, as a series noted out of the seven patients who experienced local recurrence, four had undergone chemotherapy and four patients had inadequate surgical margins. Both Metachronous and synchronous variants of DPOS have similar outcomes although patients with tumors that histologically show Broders Grade 4 dedifferentiation had a worse prognosis. The high-grade component of the lesion should be identified to surround the area with normal tissue. Preoperative chemotherapy should also be administered. Another study noted 62 % of their DPOS patients experiencing radiographic lucency, hence they encouraged biopsy of lucent areas, and if not present, hypervascular lesions, since DPOS may be difficult to diagnose with needle or incisional biopsy. If in proximity to a neurovascular bundle, reduction of the tumor burden via neoadjuvant chemotherapy may make the lesion more resectable and save the limb. Medullary canal invasion has not been associated with tumor aggressiveness, although in one study, out of the nine patients who died, seven had metastases, noting a metastatic rate of 31 %, comparing to 5 % seen in CPOS [12,6,14,16].

9. Conclusion

Overall, POS is a well-differentiated low-grade malignant sarcoma found at the bone surface. POS in the skull may resemble a multitude of entities, which it may successfully be distinguished from through

combined clinical, histopathological and imaging diagnosis. POS may recur locally but with a good prognosis and low potential for systemic metastasis. Dedifferentiation of this tumor may occur, with a low-grade POS and high grade sarcomatous component simultaneously, or with transformation into a high-grade sarcoma, associated with accelerated growth and a worse prognosis. Surgery with wide surgical margins alone or associated with chemotherapy is the treatment of choice. Metastasis being the major cause of treatment failure, identification of DPOS in a timely fashion and ablation of the metastasis is key [6,14].

Ethical Statement for Solid State Ionics

Hereby, I/insert author name/consciously assure that for the manuscript /insert title/ the following is fulfilled:

- 1) This material is the authors' own original work, which has not been previously published elsewhere.
- 2) The paper is not currently being considered for publication elsewhere.
- 3) The paper reflects the authors' own research and analysis in a truthful and complete manner.
- 4) The paper properly credits the meaningful contributions of co-authors and co-researchers.
- 5) The results are appropriately placed in the context of prior and existing research.
- 6) All sources used are properly disclosed (correct citation). Literally copying of text must be indicated as such by using quotation marks and giving proper reference.
- 7) All authors have been personally and actively involved in substantial work leading to the paper, and will take public responsibility for its content.

Funding Statement

I testify that no funding was received for this work.

Declaration of Competing Interest

The authors declare that they have no known competing financial interests or personal relationships that could have appeared to influence the work reported in this paper.

Acknowledgements (If any)

None.

Source of support

Not applicable.

References

- [1] (<http://tumorsurgery.org/tumor-education/bone-tumors/types-of-bone-tumors/parosteal-osteosarcoma.aspx>).
- [2] (https://en.wikipedia.org/wiki/Long_bone).
- [3] (<https://www.hopkinsmedicine.org/health/conditions-and-diseases/sarcoma/bone-sarcomas>).
- [4] (<https://www.hopkinsmedicine.org/health/conditions-and-diseases/sarcoma/osteosarcoma>).
- [5] (<https://www.mayoclinic.org/diseases-conditions/sarcoma/symptoms-causes/syc-20351048>).
- [6] F. Bertoni, P. Bacchini, E.L. Staals, P. Davidovitz, Dedifferentiated parosteal osteosarcoma: the experience of the Rizzoli Institute, *Cancer* 103 (11) (2005) 2373–2382, <https://doi.org/10.1002/cncr.21039> (PMID: 15852358).
- [7] H. Futani, A. Okayama, S. Maruo, G. Kinoshita, R. Ishikura, The role of imaging modalities in the diagnosis of primary dedifferentiated parosteal osteosarcoma, *J. Orthop. Sci.* 6 (3) (2001) 290–294, <https://doi.org/10.1007/s007760100050> (PMID: 11484126).
- [8] C.F. Geschickter, M.M. Copeland, Parosteal osteoma of bone: a new entity, *Ann. Surg.* 133 (6) (1951) 790–807, <https://doi.org/10.1097/00000658-195106000-00006> (PMID: 14838523; PMID: PMC1616939).
- [9] S. Gupta, S. Parikh, S. Goel, Parosteal osteosarcoma of mandible: a rare case report, *J. Cancer Res. Ther.* 14 (2) (2018) 471–474, <https://doi.org/10.4103/0973-1482.176420> (PMID: 29516945).
- [10] J.F. Hang, P.C. Chen, Parosteal osteosarcoma, *Arch. Pathol. Lab. Med.* 138 (5) (2014) 694–699, <https://doi.org/10.5858/arpa.2013-0030-RS> (PMID: 24786129).
- [11] K.M. Hewitt, G. Ellis, R. Wiggins, B.G. Bentz, Parosteal osteosarcoma: case report and review of the literature, *Head Neck* 30 (1) (2008) 122–126, <https://doi.org/10.1002/hed.20658> (PMID: 17615569).
- [12] R. Mangla, M. Mangla, S. Li, A. Abdelbaki, I. Bansal, A. Kumar, Y. Kumar, Dedifferentiated parosteal osteosarcoma of the calvaria, *Proc. (Bayl. Univ. Med. Cent.)* 31 (1) (2018) 76–78, <https://doi.org/10.1080/08998280.2017.1391047> (PMID: 29686561; PMID: PMC5903526).
- [13] H. Nouri, M. Ben Maitigue, L. Abid, N. Nouri, A. Abdelkader, M. Bouaziz, M. Mestiri, Surface osteosarcoma: clinical features and therapeutic implications, *J. Bone Oncol.* 4 (4) (2015) 115–123, <https://doi.org/10.1016/j.jbo.2015.07.002> (PMID: 26730360; PMID: PMC4678793).
- [14] D.N. Parmar, P.J. Luthert, I.A. Cree, R.P. Reid, G.E. Rose, Two unusual osteogenic orbital tumors: presumed parosteal osteosarcomas of the orbit, *Ophthalmology* 108 (8) (2001) 1452–1456, [https://doi.org/10.1016/s0161-6420\(01\)00650-9](https://doi.org/10.1016/s0161-6420(01)00650-9) (PMID: 11470699).
- [15] S.O.M.M. Peimer R, Juxtacortical osteogenic sarcoma of the mandible, *Arch. Otolaryngol.* 74 (1961) 532–536, <https://doi.org/10.1001/archotol.1961.00740030543009> (PMID: 13915080).
- [16] S.R. Puranik, R.S. Puranik, P.K. Ramdurg, G.R. Choudhary, Parosteal osteosarcoma: report of a rare juxtacortical variant of osteosarcoma affecting the maxilla, *J. Oral Maxillofac. Pathol.* 18 (3) (2014) 432–436, <https://doi.org/10.4103/0973-029X.151340> (PMID: 25949002; PMID: PMC4409192).
- [17] R.J. Zarbo, E.R. Carlson, Malignancies of the jaws, in: J.A. Regezi, J.J. Sciubba, R. C. Jordan (Eds.), *Oral Pathology: Clinical Pathologic Correlations*, 4th ed., Saunders, St. Louis, Missouri, 2003, pp. 321–825.