

Mucoepidermoid Carcinoma of Sublingual Salivary Gland: A Rare Case Report

K. Sankar, G. Vasupradha¹, N. Jaipal

Department of Oral and Maxillofacial Surgery, Mahatma Gandhi Post Graduate Institute of Dental Sciences, Puducherry, ¹Department of Oral Pathology, Adhiparasakthi Dental College and Hospital, Melmaruvathur, Tamil Nadu, India

Abstract

Rationale: Sublingual salivary gland tumours are very rare but are mostly malignant. As very limited literature is available, we present a rare case of mucoepidermoid carcinoma (MEC) of sublingual salivary gland. **Patient Concerns:** A 56-year-old female presented with an asymptomatic swelling of 15-year duration in the floor of the mouth and chin region. **Diagnosis:** Mandibular occlusal view, computed tomography scan, and ultrasonogram revealed calcification and the tumour to be of salivary origin. Incisional biopsy showed clear cell changes. **Treatment:** The sublingual and submandibular salivary gland along with the associated nodes was excised through transoral approach with midline osteotomy. **Outcomes:** The histopathologic diagnosis of excised specimen was “Intermediate grade MEC” with clear cell changes, stromal hyalinization, and local invasion. The patient was followed up for 12 months, and there was no evidence of any recurrence. **Takeaway Lessons:** Sublingual salivary gland malignancies show early invasion and a higher rate of metastases, thus requiring a vigilant intervention.

Keywords: Clear cells, mucoepidermoid carcinoma, sublingual salivary gland, ultrasonogram

INTRODUCTION

Sublingual salivary gland tumours are very rare (<1% incidence) and 80%–90% are malignant. Their clinical presentation varies from slow-growing indolent painless mass to painful locally aggressive and metastatic lesion. They pose a diagnostic challenge as there is considerable overlap among their various histologic subtypes mandating more researches at molecular level. Their unfavorable anatomic location offers the privilege for an early invasion and metastasis adding to the ordeal in their management.^[1] Due to lesser incidence, limited literature is available; hence, we present a case of long-standing asymptomatic swelling of sublingual salivary gland that was nonetheless mucoepidermoid carcinoma (MEC).

PATIENT CONCERNS

A 56-year-old female presented with an asymptomatic swelling of 15-year duration in the floor of the mouth and chin region that gradually increased in size.

Clinical findings

Extraoral examination revealed a soft-to-firm nontender swelling in the left submental and submandibular

region [Figure 1]. Left submandibular lymph node was of size 1 cm and nontender on palpation.

On intraoral examination, a localized, smooth, well-defined, nontender swelling approximately of size 4 cm × 2 cm in the floor of the mouth extending from 31 to 38 region was noticed [Figure 2]. Bi-digital palpation of the salivary gland revealed a blood-filled exudate through the ductal opening.

Diagnostic aids

Mandibular occlusal radiograph and computed tomography scan showed flecks of calcifications medial to the left mandibular cortex [Figure 3] that suggested “chronic sialadenitis secondary to sialolith.” As tumours from floor of the mouth could also obstruct submandibular duct and cause

Address for correspondence: Dr. G. Vasupradha, Department of Oral Pathology, Adhiparasakthi Dental College and Hospital, Melmaruvathur, Tamil Nadu, India. E-mail: vasu.govind@gmail.com

Received: 04-06-2020

Last Revised: 22-07-2020

Accepted: 05-12-2020

Published: 19-02-2021

This is an open access journal, and articles are distributed under the terms of the Creative Commons Attribution-NonCommercial-ShareAlike 4.0 License, which allows others to remix, tweak, and build upon the work non-commercially, as long as appropriate credit is given and the new creations are licensed under the identical terms.

For reprints contact: WKHLRPMedknow_reprints@wolterskluwer.com

How to cite this article: Sankar K, Vasupradha G, Jaipal N. Mucoepidermoid carcinoma of sublingual salivary gland: A rare case report. Ann Maxillofac Surg 2021;11:183-6.

Access this article online

Quick Response Code:



Website:
www.amsjournal.com

DOI:
10.4103/ams.ams_252_20

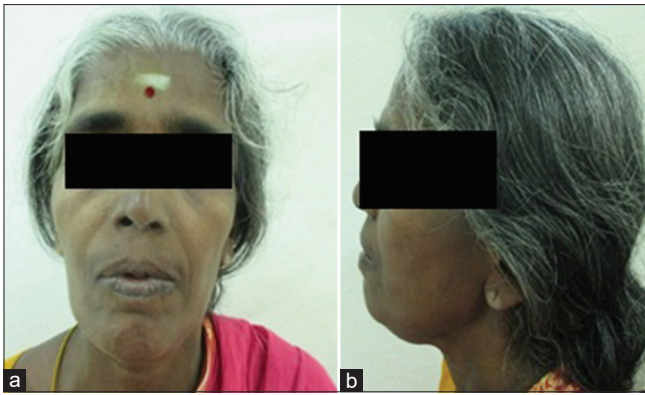

Figure 1: (a and b) Extraoral photograph showing a left submandibular swelling

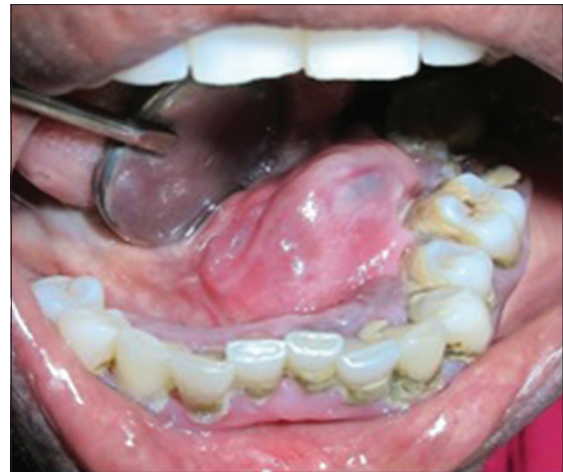

Figure 2: Intraoral photograph showing a single, smooth, sessile swelling elevating the tongue

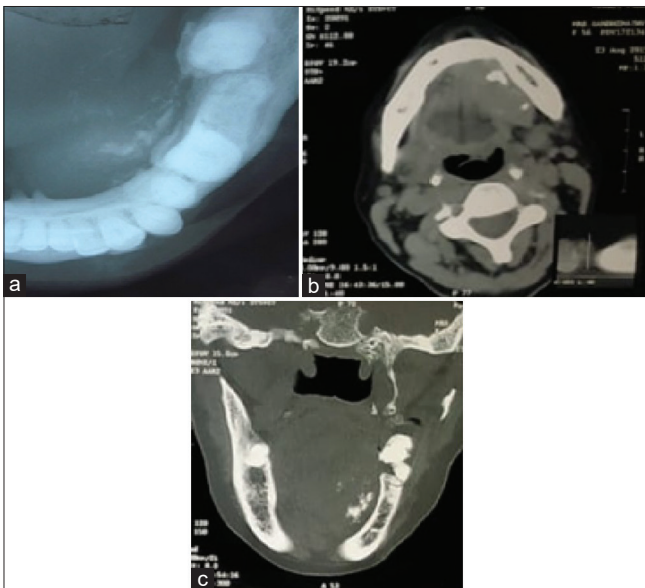


Figure 3: (a-c) Mandibular occlusal radiograph and computed tomography axial section showing flecks of calcification in the left sublingual region with intact mandibular cortex

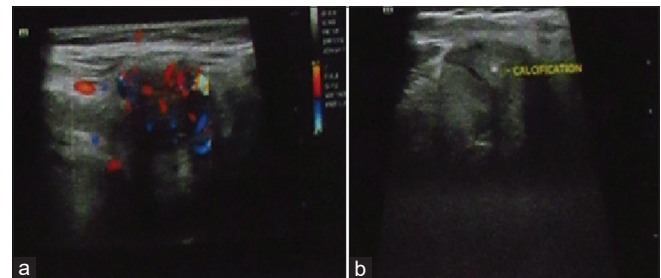


Figure 4: (a and b) Ultrasonographic evaluation showing hypervascular masses with multifocal calcification and altered echotexture in level I and II left side lymph nodes and normal echo in the right side

retro-obstructive sialadenitis, ultrasonogram was performed which showed the swelling was of salivary origin. The findings such as hypervascular masses with multifocal calcification and altered echotexture with nodal involvement [Figure 4] and also increased clear cell changes in incisional biopsy were more in favor of malignancy.

Treatment

Under general anaesthesia, sublingual and submandibular salivary gland along with the associated nodes was excised through transoral approach with midline osteotomy [Figure 5].

Outcomes

The histopathology of the excised specimen revealed mucous cells, intermediate cells, and epidermoid cells with minimal cellular atypia arranged in lobules and sheath forms. Areas of cystic degeneration and stromal hyalinization with clear cell changes in the periphery and invasion into bone and muscle

fibers were evident. The final diagnosis was “intermediate grade MEC with clear cell changes” [Figure 6].

Follow-up

The patient was unwilling for postoperative radiotherapy. The patient was followed up for 12 months with no evidence of any recurrence.

DISCUSSION

MEC is the most common salivary gland malignancy.^[2] It is common in fourth to sixth decades and shows female predilection. Major salivary glands are involved in 50%–60% of cases, and only 2%–4% of cases occur in sublingual salivary gland.^[3]

It is characterized by three cell types, namely, mucous cells, epidermoid cells, and intermediate cells. Clear cells are often seen. Different point-based scoring systems have been proposed for histologic grading [Table 1]. Low-grade lesions are characterized by prominent cystic degeneration, numerous mucous cells, and extracellular mucin. Cellular pleomorphism and mitoses are rare. In intermediate grade, the cystic component is less and smaller in size, intermediate cells predominate, mucus cells are scattered, and epidermoid cells tend to form large solid islands of tumour. Nuclear

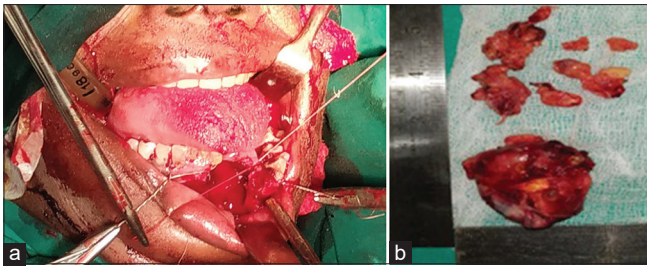


Figure 5: (a and b) Surgical excision of the deep lobe of submandibular salivary gland and sublingual salivary gland through extraoral and intraoral approach under general anaesthesia

atypia and mitoses are rare, but prominent nucleoli are evident.^[1]

High-grade lesions exhibit epidermoid and intermediate cells in solid sheets with considerable cytologic atypia, prominent nucleoli, and numerous mitoses. Mucus cells are sparse. It can be differentiated from epidermoid carcinoma by the presence of glandular or small cystic component and stains for mucin such as mucicarmine and periodic acid Schiff-diastase resistant. It stains positive for cytokeratin (CK) 5, CK6, CK7, CK8, CK14, CK18, CK19, EMA, and carcinoembryonic antigen and negative for CK20, smooth muscle actin, and S100. p63 is a useful marker to differentiate from acinic cell carcinoma and low-grade lesions from mucous retention cysts and papillary cystadenoma.^[2]

Ultrasonogram enables to evaluate the gland parenchyma and ductal dilatation. Features such as heterogeneous echotexture, indistinct margins, regional lymph node enlargement, and absence of distal acoustic enhancement are highly suggestive of malignancy.^[4]

Low-grade lesions are managed by surgical excision, while high-grade tumours are excised along with involved nodes. There is no definitive management for intermediate grade and largely depends on the staging and extent of invasion.^[1] Tumours in submandibular gland and base of the tongue have a poor outcome due to increased rate of invasion and metastases.

The role of radiotherapy is controversial. Some evidences indicate better local control and disease-free survival with 5000–7000 rad (50–70 Gy) of irradiation over a period of 5–6 weeks. Photon-based radiation of 70 Gy is recommended for unresectable tumours.^[5] Radiotherapy improved 5-year survival rates by up to 51%. However, instances of radiation-induced sarcoma, especially in younger patients, have restricted the radiotherapy from routine use following surgery. Postoperative radiotherapy is generally reserved for tumours with high-grade or unresectable tumours.

The overall 5-year survival rate is 92%–100% for low grade, 62%–92% for intermediate grade, and 0%–43% for high-grade tumours. Recurrence rate is 10% for low-grade tumours and 75% for high-grade lesions. Recurrence rate is high in tumours with positive margin irrespective of their histological grade.^[6]

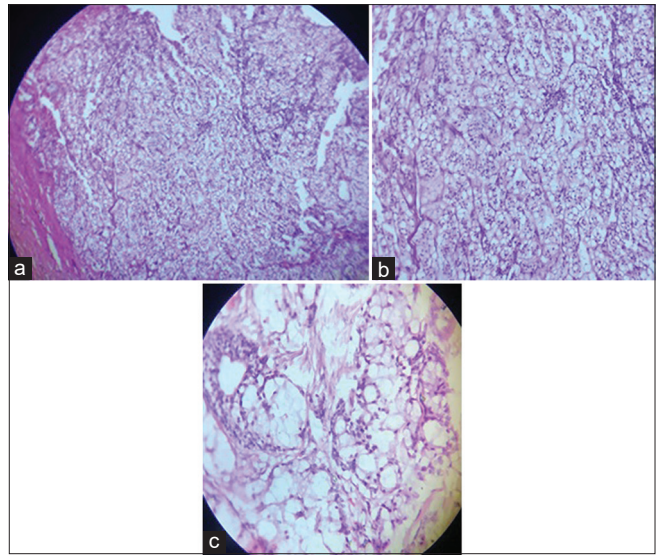


Figure 6: H and E, stained section showing clear cell changes, mucous cells, intermediate cells, epidermoid cells (a and b), and areas of cystic degeneration (c)

Table 1: Point-based scoring system for mucoepidermoid carcinoma

Histologic parameter	Points
(a) AFIP scoring system	
Intracystic component <20%	2
Neural invasion	2
Necrosis	3
Mitosis (4 or more per 10 HPF)	3
Anaplasia	4
Grading	
Low grade	0-4
Intermediate grade	5-6
High grade	7-14
(b) Brandwein scoring system	
Intracystic component <25%	2
Tumour invades in small nests and islands	2
Pronounced nuclear atypia	2
Lymphatic and/or vascular invasion	3
Bony invasion	3
>4 mitoses per 10 HPF	3
Perineural spread	3
Necrosis	3
Grading	
Low grade	0
Intermediate grade	2-3
High grade	4 or more

HPF: High power field, AFIP-Armed Forces Institute of Pathology

Nakagaki *et al.*^[7] reported a case of low-grade MEC with metastases and death. Kumar *et al.*^[3] reported a case where fine-needle aspiration cytology (FNAC) suggested retention cyst but was low-grade MEC with regional metastasis. Sumanth *et al.*^[8] reported a case where FNAC suggested adenoid cystic carcinoma but was high-grade MEC. Hyalinization, dystrophic

calcification, and intratumoural bone formation were reported by Maruse *et al.*^[9] In most of these cases, the swelling was only for 2 months, but our case is unique in that the swelling was present asymptotically for 15 years.

Strength and limitations

Recent researches have shown chromosomal rearrangements exclusive to MEC, especially t (11;19)(q21;p13) in gene CRTC1-MAML2 (prevalence: 40%–80%), t (11;15)(q21;q26) in gene CRTC3-MAML2 (prevalence ~ 5%), 9p21.3 in gene CDKN2A deletion (prevalence ~ 35%).^[10] Gene amplification of HER2 and epidermal growth factor receptor in high-grade lesions and increased expression of genes basic leucine zipper and W2 domains 1/eukaryotic initiation factor, 5-mimic protein 2 have been demonstrated.^[11] The results are promising to give deeper insight in tumour pathogenesis.

Lack of specific grading scheme till date for MEC is a major limitation.^[10]

Future perspectives

Targeted therapy is likely to revolutionize the treatment of MEC in future. Doublet therapy using carboplatinum and paclitaxel or cisplatin and gemcitabine have shown 26% and 24% response rates, respectively. Tocilizumab (humanized antihuman interleukin-6R antibody) has shown to sensitize MEC to chemotherapy (cisplatin or paclitaxel) by reducing the fraction of cancer stem cells without any added toxicity in preclinical models.^[11] A combination of nuclear factor-κB and histone deacetylase inhibitors are found to be effective against MEC.^[12]

CONCLUSION

Sublingual salivary gland tumours are mostly malignant. There is no definite treatment protocol for intermediate-grade MEC. Multimodal approach to be followed considering the tumour location, clinical stage, histological grade, extent of invasion, metastases, and recurrence.

Declaration of patient consent

The authors certify that they have obtained all appropriate patient consent forms. In the form, the patient has given her consent for her images, and other clinical information

to be reported in the journal. The patient understands that name and initials will not be published, and due efforts will be made to conceal identity, but anonymity cannot be guaranteed.

Financial support and sponsorship

Nil.

Conflicts of interest

There are no conflicts of interest.

REFERENCES

1. Nance MA, Seethala RR, Wang Y, Chiosea SI, Myers EN, Johnson JT, *et al.* Treatment and survival outcomes based on histologic grading in patients with head and neck mucoepidermoid carcinoma. *Cancer* 2008;113:2082-9.
2. Zhu S, Schuerch C, Hunt J. Review and updates of immunohistochemistry in selected salivary gland and head and neck tumors. *Arch Pathol Lab Med* 2015;139:55-66.
3. Kumar AN, Nair PP, Thomas S, Raman PS, Bhambal A. Mucoepidermoid carcinoma of sublingual gland: A malignant neoplasm in an uncommon region. *BMJ Case Rep.* 2011 May 12;2011:bcr0220113864. doi: 10.1136/bcr.02.2011.3864. PMID: 22696723; PMCID: PMC3094775.
4. Kovacević DO, Fabijanić I. Sonographic diagnosis of parotid gland lesions: correlation with the results of sonographically guided fine-needle aspiration biopsy. *J Clin Ultrasound* 2010;38:294-8.
5. Lin HH, Limesand KH, Ann DK. Current state of knowledge on salivary gland cancers. *Crit Rev Oncog* 2018;23:139-51.
6. Seethala RR. An update on grading of salivary gland carcinomas. *Head Neck Pathol* 2009;3:69-77.
7. Nakagaki T, Ogi K, Abe M, Dehari H, Miyazaki A, Hasegawa T, *et al.* Low-grade mucoepidermoid carcinoma with regional lymph node metastasis: A case report and genetic review of criteria for grading. *J Oral Maxillofac Surg Pathol* 2016;28:189-92.
8. Sumanth KN, Mainali A, Ongole R, Pai MR. Mucoepidermoid carcinoma: "A mimicker"? *J Nepal Dent Assoc* 2009;10:31-4.
9. Maruse Y, Kawano S, Kiyoshima T, Goto Y, Matsubara R, Chikui T, *et al.* Case of mucoepidermoid carcinoma of the sublingual gland accompanied with extensive dystrophic calcification and intratumoural bone formation. *Head Neck* 2015;37:E161-4.
10. Seethala RR, Stenman G. Update from the 4th edition of the World Health Organization classification of head and neck tumours: Tumors of the salivary gland. *Head Neck Pathol* 2017;11:55-67.
11. Mochizuki D, Adams A, Warner KA, Zhang Z, Pearson AT, Misawa K, *et al.* Anti-tumor effect of inhibition of IL-6 signaling in mucoepidermoid carcinoma. *Oncotarget* 2015;6:22822-35.
12. Wagner VP, Martins MD, Martins MAT, Almeida LO, Warner KA, Nor JE, Squarize CH, Castilho RM. Targeting histone deacetylase and NFκB signaling as a novel therapy for mucoepidermoid carcinomas. *Sci Rep* 2018;8:2065.