

The Lymphatic System of the Dog

by Hermann Baum

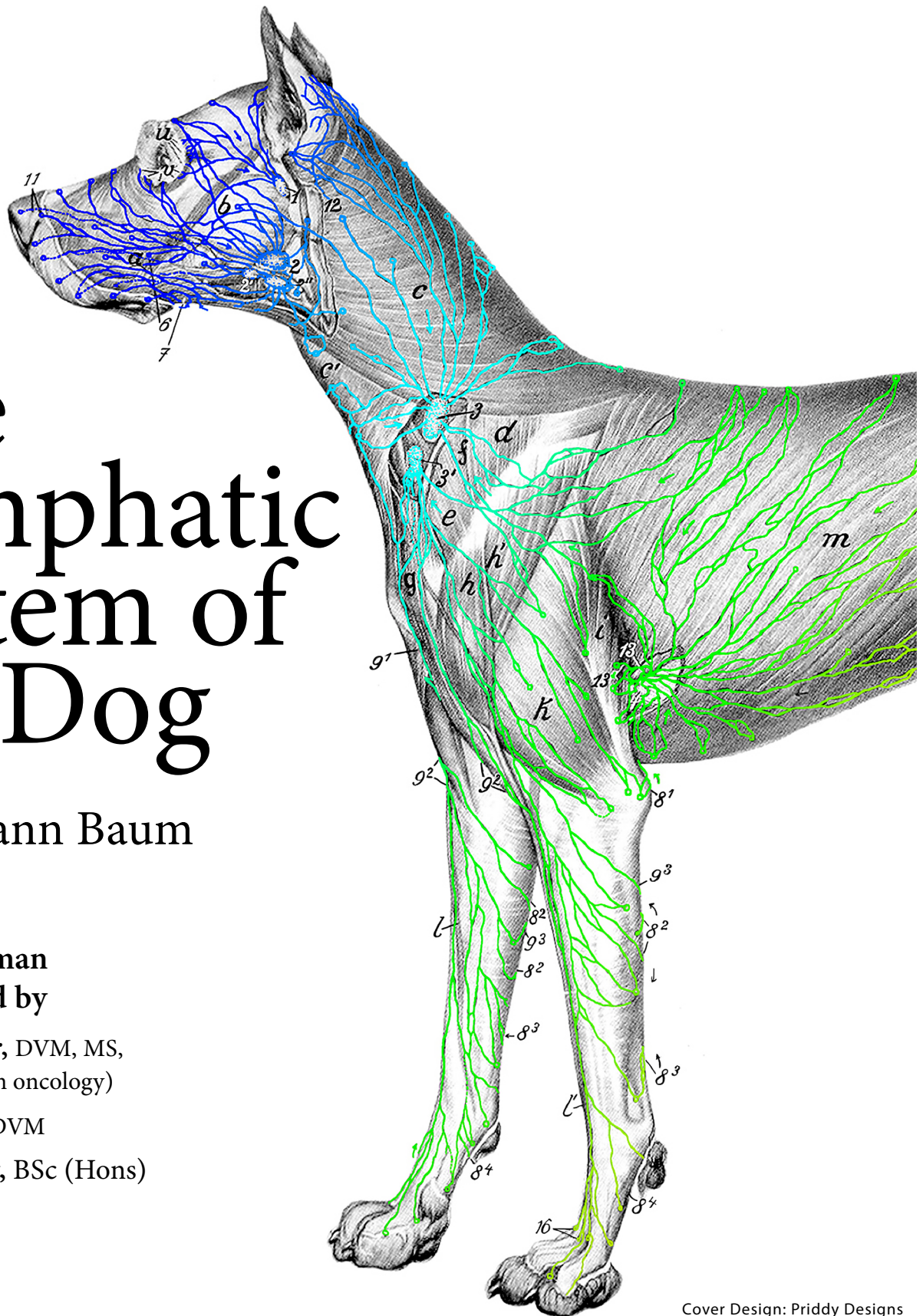
Original German
text translated by

Monique Mayer, DVM, MS,
DACVR (Radiation oncology)

Leonie Bettin, DVM

Kaelyn Bellamy, BSc (Hons)

Isabell Stamm



Cover Design: Priddy Designs

The Lymphatic System of the Dog by Hermann Baum is licensed under a Creative Commons Attribution-NonCommercial-ShareAlike 4.0 International License, except where otherwise noted.

CONTENTS

About Hermann Baum	1
University of Saskatchewan Contributions	6
Contributors	6
Acknowledgements	7
Introductory Videocast by Dr. Hiroo Suami, MD, PhD	7
Staging of the Canine Cancer Patient	8
Overview	
Dedication	9
Preface	10
Introduction	11
Hemal Lymph Nodes	13
Methodology	14
Terminology and Phrasing	17
Methodology References	24

SECTION 1: LYMPH NODE LOCATION AND DRAINAGE PATTERNS

1.1 Lymph Nodes of the Head	26
General	26
Parotid Lymph Centre	26
Mandibular Lymph Centre	28
Retropharyngeal Lymph Centre	34
1.2 Lymph Nodes of the Neck	38
General	38
Superficial Cervical Lymph Centre	38
Deep Cervical Lymph Centre	42
1.3 Lymph Nodes of the Forelimb	46
General	46
Axillary Lymph Nodes	46
Accessory Axillary Lymph Nodes	49
1.4 Lymph Nodes of the Pelvic Limb	51
General	51
Popliteal Lymph Nodes	51
Medial Femoral Lymph Nodes	54
Superficial Inguinal Lymph Nodes	56

1.5 Lymph Nodes of the Thorax and Associated Organs	60
General	60
Intercostal Lymph Nodes	60
Sternal Lymph Nodes	61
Mediastinal Lymph Nodes	64
Bronchial Lymph Centre	68
1.6 Lymph Nodes of the Abdominal and Pelvic Walls	73
General	73
Lumbar Aortic Lymph Nodes	74
Medial Iliac Lymph Nodes	75
Hypogastric (Internal Iliac) Lymph Nodes	80
Sacral Lymph Nodes	82
Deep Inguinal Lymph Nodes	85
1.7 Lymph Nodes of the Abdominal And Pelvic Organs	87
General	87
Hepatic Lymph Nodes	88
Splenic Lymph Nodes	90
Gastric Lymph Nodes	91
Omental Lymph Nodes	91
Duodenal Lymph Nodes	92
Jejunal Lymph Nodes	92
Colic Lymph Nodes	95
Renal Lymph Nodes	97

SECTION 2: LYMPHATIC TRUNKS AND LYMPHATIC DRAINAGE OF ORGANS

2.1 Lymphatic Trunks	100
General	100
Thoracic Duct	100
Left and Right Tracheal Ducts	103
Intestinal Trunk	104
Lumbar Trunk (Pelvic Lymph Trunk)	105
2.2 Lymph Vessels of the Skin	106
General	106
Lymphosomes of the Dog	107
Lymph Vessels of the Skin of the Head	108
Lymph Vessels of the Skin of the Neck	108
Lymph Vessels of the Skin of the Forelimb	108
Lymph Vessels of the Skin of the Dorsal, Lateral, and Ventral Thoracic Wall	109
Lymph Vessels of the Skin of the Ventral and Cranial-Ventral Thoracic Wall	109
Lymph Vessels of the Skin of the Dorsal, Lateral, and Ventral Abdominal Wall	110

Lymph Vessels of the Skin of the Pelvic Limbs and Tail.	110
2.3 Lymph Vessels of the Fasciae	113
General.	113
Lymph Vessels of the Antebrachial Fascia.	113
Lymph Vessels of the Lumbodorsal Fascia.	114
Lymph Vessels of the <i>Fascia Lata</i>	114
Lymph Vessels of the <i>Fascia Cruris</i>	115
2.4 Lymph Vessels of the Skeletal Muscles and Their Tendons and Tendon Sheaths	116
General.	116
Lymph Vessels of the Head Muscles.	116
Lymph Vessels of the Muscles of the Neck and Thorax.	116
Lymph Vessels of the Muscles of the Trunk.	117
Lymph Vessels of the Muscles of the Forelimb.	118
Lymph Vessels of the Muscles of the Pelvic Limbs.	118
Lymph Vessels of the Tail Muscles.	120
Lymph Vessels of the Abdominal Muscles.	120
Lymph Vessels of the Muscles of the Skin.	120
2.5 Lymph Vessels of the Bones	121
General.	121
Lymph Vessels of the Bones of the Head.	121
Lymph Vessels of the Bones of the Trunk (Vertebrae, Ribs, and Sternum).	121
Lymph Vessels of the Bones of the Forelimb.	122
Lymph Vessels of the Bones of the Pelvic Limbs.	122
2.6 Lymph Vessels of the Joints	123
General.	123
Lymph Vessels of the Temporomandibular Joint.	123
Lymph Vessels of the Forelimb Joints.	123
Lymph Vessels of the Joints of the Pelvic Limb.	124
2.7 Lymph Vessels of the Diaphragm, Pleura, and Peritoneum	125
General.	125
Lymph Vessels of the Diaphragm.	125
Lymph Vessels of the Costal Pleura.	127
Lymph Vessels of the Mediastinum.	129
Lymph Vessels of the Peritoneum.	131
Lymph Vessels of the Omentum.	131
2.8 Lymph Vessels of the Digestive Organs	133
General.	133
Lymph Vessels of the Upper and Lower Lips.	133
Lymph Vessels of the Tongue.	134
Lymph Vessels of the Mucous Membrane of the Free Floor of the Oral Cavity.	136

Lymph Vessels of the Gingivae	136
Lymph Vessels of the Cheek	138
Lymph Vessels of the Hard Palate	138
Lymph Vessels of the Soft Palate and Tonsil	139
Lymph Vessels of the Major Salivary Glands (Sublingual, Submaxillary, and Parotid Gland)	140
Lymph Vessels of the Pharynx	141
Lymph Vessels of the Esophagus	141
Lymph Vessels of the Stomach	144
Lymph Vessels of the Intestine	146
Lymph Vessels of the Liver and Gallbladder	149
Lymph Vessels of the Pancreas	151
Lymph Vessels of the Spleen	152
2.9 Lymph Vessels of the Respiratory Organs	153
General	153
Lymph Vessels of the Nose	153
Lymph Vessels of the Larynx	154
Lymph Vessels of the Trachea	155
Lymph Vessels of the Lungs	156
Lymph Vessels of the Thymus	157
Lymph Vessels of the Thyroid Gland	157
2.10 Lymph Vessels of the Urinary Organs	160
General	160
Lymph Vessels of the Kidneys	160
Lymph Vessels of the Ureter	161
Lymph Vessels of the Urinary Bladder	161
Lymph Vessels of the Female Urethra	162
Lymph Vessels of the Adrenal Glands	162
2.11 Lymph Vessels of the Male Genital Organs	163
General	163
Lymph Vessels of the Scrotum	163
Lymph Vessels of the Testis	163
Lymph Vessels of the <i>Ductus Deferens</i>	164
Lymph Vessels of the <i>M. Cremaster</i> and the <i>Tunica Vaginalis Communis</i>	164
Lymph Vessels of the Prostate	164
Lymph Vessels of the Prepuce	165
Lymph Vessels of the Penis and the Glans	165
Lymph Vessels of the Male Urethra	166
2.12 Lymph Vessels of the Female Genital Organs	167
General	167
Lymph Vessels of the Ovary	167
Lymph Vessels of the Uterus	167
Lymph Vessels of the Vagina	168

Lymph Vessels of the Vaginal Vestibule	168
Lymph Vessels of the Vulva and Clitoris	168
Lymph Vessels of the Mammary Glands (Appended Section)	169
2.13 Lymph Vessels of the Pericardium, Heart, and Aorta	171
Lymph Vessels of the Pericardium, Heart, and Aorta	171
2.14 Lymph Vessels of the Eye	176
Lymph Vessels of the Eye	176
2.15 Lymph Vessels of the Ear	177
Lymph Vessels of the Ear	177
2.16 Lymph Vessels of the Nervous System	178
Lymph Vessels of the Nervous System	178

FIGURES

Figure 1: Lymph Vessels of the Kidney	181
Figures 2-7: Schemata of the Left Tracheal Duct	182
Figures 8-12: Schemata of the Right Tracheal Duct and Right Lymphatic Duct	183
Figure 13: Lymph Vessels of the Skin of Dogs	184
Figure 14: Lymph Vessels of the Tongue, Tongue Muscles, Soft Palate, and Larynx of the Dog	185
Figure 15: Lymph Vessels of the Salivary Glands of the Dog	186
Figure 16: Medial Retropharyngeal Lymph Nodes and Cervical Lymph Nodes of the Dog	187
Figure 17: Lymph Vessels of the Mediastinum, Pericardium, Diaphragm, Aorta, and Esophagus in the Dog	188
Figure 18: Right Side of the Thoracic Cavity of the Dog	189
Figure 19: Lymph Vessels of the Pleura of the Dog	190
Figure 20: Lymph Vessels of the Lungs and Tracheobronchial Lymph Nodes of the Dog	191
Figure 21: Left Side of the Dog's Heart with Injected Lymph Vessels	192
Figure 22: Bronchial Lymph Center of the Dog	193
Figure 23: Lymph Vessels of the Cervical Part of the Trachea and Esophagus of the Dog	194
Figure 24: Lymph Vessels and Lymph Nodes of the Abdominal Cavity of the Dog	195
Figure 25: Lymph Vessels of the Small Intestine and the Omentum	196
Figure 26: Lymph Vessels and Lymph Nodes from the Stomach, Spleen, Pancreas, Duodenum, and Large Intestine of the Dog	197
Figure 27: Lymph Vessels of the Kidneys and Lymph Nodes Along the Abdominal Aorta and its Terminal Branches	198
Figure 28: Lymph Vessels of the Liver of the Dog	199
Figure 29: Lymph Vessels of Reproductive Organs of the Female Dog	200
Figure 30: Lymph Vessels of the Mammary Gland of the Dog	201
Figure 31: Lymph Vessels of the Urinary and Reproductive Organs of the Male Dog	202
Figure 32: Lymph Vessels of the Urinary and Reproductive Organs of the Male Dog	203

Figure 33: Lymph Vessels of the Joints of the Toes of the Forelimb. 204
Figure 34: Lymph Vessels of the Stifle, Tarsal, and Toe Joints of the Hindlimb. 205
Figure 35: Lymph Vessels of the Carpal Joint and Toe Joints of the Dog’s Forelimb. 206
Figure 36: Lymph Vessels of the Joints of the Forelimb of the Dog (Medial Side). 207
Figure 37: Lymph Vessels of the Hip, Stifle, and Tarsal Joints of the Dog. 208
Figure 38: Lymph Vessels of the Testis. 209

BIBLIOGRAPHY. 211

About Hermann Baum

HERMANN BAUM – HIS PERSONALITY AND HIS WORK

Authored by G. Michel

An English translation of a German article published in Mh. Vet.-Med. 38 (1983): 551-554

Animal Production and Veterinary Medicine Section of the Karl Marx University Leipzig, Scientific Department of Anatomy, Histology and Embryology (Head: Vet.-Rat Prof. Dr. sc. G. Michel)

SUMMARY



The work and personality of Hermann Baum will be honoured in a memorial lecture. His activities in teaching and the development of textbooks, in research, and as Dean of the Faculty of Veterinary Medicine in Leipzig and Rector of the University of Leipzig will be emphasized. Working alongside Wilhelm Ellenberger, these activities made Professor Baum not only a leading veterinary anatomist, but also an exemplary representative of veterinary medicine.

On March 16, 1932, the University of Leipzig held a moving funeral service to bid farewell to the veterinary anatomist Professor Dr. Dr. h. c. Hermann Baum, who died after a long and severe illness in the midday hours of March 13, 1932.

Anyone reading the obituary of Hermann Baum will realize what a great personality he was. Today, 50 years after his death, we will emphasize not only this, but, in the sense of Marxist historical research, also the impact of his personality and work in society on our own activities in teaching and research. We must take into account the impressive characters that contributed to our subject areas. Hermann Baum is one of the greatest of these characters, and his work still forms the basis of our work in many areas.

Hermann Baum was born in Plauen on December 25, 1864, the son of freight forwarder Hermann Baum. He attended secondary school in Plauen and then took up the study of veterinary medicine at the former veterinary school in Dresden. At that time, the veterinary school in Dresden had reached a high point, with such outstanding teachers as Leisering, Sußdorf, Siedamgrotzky, Johne, Müller, and above all Ellenberger. Baum showed an early interest in morphology during his studies. Ellenberger recognized this interest and soon recruited Baum to work in his institute. Already as a student, Hermann Baum wrote his first publications on *The Morphological-Histological Changes of the Resting and Ac-*

tive Liver Cell. In doing so, he demonstrated his particular aptitude for morphological work. On January 1, 1888, after obtaining his license to practice veterinary medicine, Hermann Baum joined Ellenberger's institute, which at that time still included anatomy, histology, embryology, and physiology, as an assistant. In addition to Baum's work in teaching and research, and the completion of his dissertation on *The Arterial Anastomoses of the Dog and the Significance of the Collateral Circulation of Animals* in 1889, Ellenberger immediately assigned him the task of detailing the anatomy of the dog for students of veterinary medicine and for researchers. Baum dedicated himself to this task with great zeal, and *Anatomy of the Dog*, published together with Ellenberger, was available as early as 1891. It was a very modern work for that time, proving Hermann Baum's great ability as a textbook author. It is still often consulted today but unfortunately has not been reprinted.

After receiving his doctorate in 1889 in Erlangen (the veterinary school in Dresden did not yet have the right to award doctorates), he was appointed Prosector in 1891, Associate Professor in 1897 and Professor Ordinarius of Anatomy at the Dresden Veterinary University in 1898.

Hermann Baum's development was influenced by Wilhelm Ellenberger. This was clearly evident in Baum's first works in the fields Ellenberger was involved in, such as physiology and pharmacology. Through their joint work and the influence of Ellenberger during Baum's early years, a unique relationship of cooperation and trust developed between them, to which veterinary anatomy owes many important works and which made the institution in Dresden and later in Leipzig one of the leading institutes of veterinary anatomy and physiology. Hermann Baum's greatness was demonstrated by the fact that, among other things, he soon became recognized for his own work, took over the anatomy department in 1889 and gave it its own unique character.

The work of Hermann Baum proves that even in those days a university teacher achieved the highest impact through the unity of teaching and research. Hermann Baum has been described as an excellent teacher. According to his obituary written by Scheunert, Baum's anatomical talent allowed him to share what he saw in vivid clarity through the written word. His clear diction enabled him to unite the anatomy of individual structures into a viable whole, with the overall function emerging beyond mere description, a goal that every anatomist strives for and only a few have succeeded as Hermann Baum did.

His commitment to teaching was demonstrated in his unflagging activity in the dissecting room. Here, he found a way to work directly with his students. Baum considered dissection absolutely necessary to learning and developed this area into a vital basis of anatomical teaching. In this approach, he gave us an example of how the highest impact in anatomical education can be achieved simply by combining lectures with dissection. Hermann Baum also showed that anatomical teaching can only be successful with appropriate and always up-to-date teaching materials. His intensive efforts to develop and revise textbooks were certainly not an end in themselves, but a compelling necessity for him as a responsible university teacher. His efforts to develop teaching materials were not only evident in the writing of textbooks, but also in his commitment to the expansion of anatomical learning collections. Under his tenure in Leipzig, the anatomical collection became a respected attribute of the institute and, at the same time, an integral part of the student training. This was demonstrated by the immediate vicinity of the

anatomical collection to the dissecting room and from the way the collection was built up and the quality of the preparations. Professor Schwarze, together with his Senior Preparator Mr. Petzold, deserves special credit for having rebuilt this collection in the spirit of Hermann Baum after its almost complete destruction in the Second World War. This was done in conjunction with the post-war rebuilding of the Institute, which was completed in 1957, and for which we would like to express our gratitude today, 25 years later, and do so with the obligation to maintain and continually modernize what has been created. The constant revision of textbooks was Baum's heart's desire. Two days before his death, he was still negotiating with a representative of a publishing house about the 17th edition of Ellenberger-Baum. This last edition, completed by Grau and Cohrs in the spirit of the editor, is considered to be the most mature work among his textbooks, and many veterinary anatomists still like to turn to the 17th edition when they want to find a certain detail. The 17th edition, in particular, shows Baum's signature style, which he ultimately imprinted on all works of anatomy published together with Ellenberger, and demonstrates the qualities that Baum developed in his many years of collaboration with Ellenberger. This applies not only to the *Manual of Comparative Anatomy of Domestic Animals*, simply referred to as Ellenberger-Baum, which increasingly showed Baum's style in the nine revised editions he published, but also to the *Topographical Anatomy of the Horse* and the *Manual of Anatomy for Artists*. His constant connection to histology is expressed in the elaborate details of the chapter *Circulatory Apparatus in the Manual of Microscopic Anatomy of Domestic Animals*.

Hermann Baum's teaching activities were based on extensive research. After writing his first two papers as a student, he first tackled various questions in the area of anatomy and, under the influence of Ellenberger, also in the areas of physiology and pharmacology. From 1911 onward, his work was exclusively concerned with the lymphatic system of domestic animals. In this field, together with his Preparator, Mr. Kurzweg, he achieved truly great things. No fewer than 53 independent journal articles and 5 comprehensive monographs, including *The Lymphatic System of Pigs*, completed and published after his death by his student Grau, were dedicated to this subject. These works provide a comprehensive picture of Baum's achievements in this field of research. He always placed particular emphasis on the care taken in his work. Despite the difficulties of the methodology, he examined every detail in as many individual animals as possible. For example, 160 cattle and calves were used for his studies on the bovine lymphatic system. Together with Mr. Kurzweg, he spent whole evenings, even nights, according to reports by his former co-workers, in order to clarify certain questions. He is a shining example through his responsibility to scientific work and at the same time his recognition of the activity of technical staff. He was also an outstanding example of responsibility to his numerous students. Hermann Baum understood how to found a "school". The former Veterinary Anatomical Institute in Leipzig became known worldwide as a centre of lymphatic research through his and his students' work. Hermann Baum came to the forefront in university policy work relatively late in his career. He was certainly overshadowed by Ellenberger in this area, although he deserves credit for supporting Ellenberger in his work developing the Dresden Medical School. However, Baum's support was always based on his own ideas. Hermann Baum's own personal opinions were particularly evident during the discussions on the transfer of the Dresden Veterinary School to the University of Leipzig, and the planning of the new institute.

While fully supporting Ellenberger's general plan in principle, Baum had his own thoughts on the matter, which at times put the intimate friendship between the two to a severe test. If Ellenberger was the initiator, Baum was to a greater extent the organizer, and it was, therefore, a natural consequence that he was elected the first Dean of the University of Leipzig and that the immediate tasks of the incorporation of the veterinary college in 1923 fell to him. However, it is significant that in the ceremony on the occasion of the incorporation he singled out Ellenberger as the "father of the idea and the tireless driving force behind its implementation" and thus the "intellectual creator of the new veterinary school". Hermann Baum did not stop at words of thanks. His vow to prove himself worthy of the university's trust through his scientific achievements as a teacher and researcher still applies today at our progressive university. In his speech, he is quoted: "There should not be a lack of areas for this kind of activity, because with the enormous increase in the value of farm animals it will be necessary to research the breeding, nutrition, and preservation of these species even more extensively than has been done so far." These words reflect the long-term vision of the work of the Faculty of Veterinary Medicine.

Through his intensive work at his university, Hermann Baum soon earned the trust of the entire senate. He was elected Rector of the University of Leipzig on November 1st, 1930. For him, this certainly fulfilled the one hope expressed in his 1923 speech at the incorporation of the veterinary college, which was that the Faculty of Veterinary Medicine would grow as if it was a seed planted by the university, the mother tree. It is a special honour that a representative of such a young college became Rector of such a venerable university after such a short time of affiliation.

Hermann Baum fulfilled the office of Rector with all his energy, despite his increasing illness and the difficulties of the time due to the increased rise of Nazism. He expressed this in a letter to Professor Kallius in the following words: "In addition, my year as Rector has been an unusually difficult one, more difficult than any of the preceding years. The political conditions among the students and student groups have taken on forms that no one would have suspected before and which could embitter even the most enthusiastic Rector. In Leipzig, the conditions were particularly bad because the city was chosen by the National Socialists as a Sturmblock. That there was no major catastrophe despite this is still often like a dream to me today." Even if these words already contain a certain resignation, they still show the sense of duty and responsibility with which Hermann Baum took on every position that he held, and at the same time his attitude towards National Socialism.

This characterizes his personality as a university teacher of his time. As a bourgeois scholar with close ties to student associations and a strong humanist attitude, he was always concerned with the position and development of his subject area in the context of the traditions of the university. He was an extremely conscientious personality. It was written in his obituary that he did not cancel a single lecture in 42 years until his illness, that he was always found in close contact with his students in the dissecting room and that he spent evenings, even nights, repeating experiments and proving findings; these behaviours are an expression of his attitude towards teaching and research. In his inaugural speech as Rector, he spoke about adaptation. Of particular interest are his remarks in this speech on the functional adaptation of the organism. They confirm that Baum was not only a descriptive anatomist, but that he also recognized the importance of functional anatomy. His expositions on the adaptation of the

organism to environmental influences and, based on this, the question of the inheritance of acquired characteristics, are an overview of the knowledge of that time, shaped by numerous examples from his own experience. This viewpoint is a foundation of modern morphology, in that we, as morphologists, should not only rigidly describe anatomical structures in the dead animal, but in their interaction with their living environment. Hermann Baum was a strong comparative anatomist. This is particularly evident from his work in the Anatomical Society. He sought discussion and was rarely absent from the meetings during the long years of his membership in the Society. In his lectures and discussions, he strove to connect the work of all anatomists, particularly cooperation with human anatomists. This is particularly evident from his collaboration in the Nomenclature Commission, where he endeavoured to bring the nomenclature of human and veterinary anatomy into agreement. Intensive discussions and extensive correspondence took place. In some preserved copies of letters to Professor Stieve and Professor Kallius, Baum's clear arguments are expressed, often spiced with a dash of humour, with which he championed a cause. The fact that Baum's passionate advocacy of this project was not successful may have had various causes and certainly advantages as well as disadvantages. Baum's behaviour in this matter is particularly indicative of his endeavour to promote comparative anatomy, an endeavour which, despite separate nomenclatures, is still a common need for human and veterinary anatomists in their collaboration today. Hermann Baum's character embodied cordiality and balance, despite all the hardship he imposed on himself and thus on his colleagues. His constant willingness to help and his sense of humour made working at his side a joy, and this is reflected in the number of his students. His collegial attitude was particularly emphasized. At the same time, he could be tough and energetic when it came to defending a cause, as his remarks and letters testify.

Hermann Baum was a great anatomist. He received numerous honours. In 1904 he was appointed Royal Saxon Medical Councillor, in 1909 Senior Medical Councillor and in 1915 Privy Councillor. In 1910 he was appointed as a member of the *Kaiserlich Leopoldinisch-Carolinische Deutsche Akademie der Naturforscher* (Academy of Natural Scientists) in Halle. He received high orders as well as honorary memberships in various societies and was appointed honorary doctor of the medical faculty in Leipzig in 1923. Influenced by his collaboration with Wilhelm Ellenberger, Hermann Baum gave anatomy a new profile. This is reflected in his overall work in teaching, in his preparation of textbooks, in his expansion of the anatomical learning collections and in his research. Through his constant striving, his sense of duty, his selfless work, and his commitment to the discipline, he still serves as a role model for us, his successors, 50 years after his death. Not only his name, but above all his work, remain unforgettable and will always be an inspiration for us.

Author: Vet.-Rat Prof. Dr. sc. G. Michel, DDR – 7010 Leipzig, Semmelweisstraße 4

Image: Hermann Baum. Source: Universität Leipzig Faculty of Veterinary Medicine. Permission. CC BY-NC Courtesy of Universität Leipzig Faculty of Veterinary Medicine.

University of Saskatchewan Contributions

CONTRIBUTORS

Kaelyn Bellamy

BSc (Hons), Anatomy and Cell Biology, University of Saskatchewan

Copyeditor, formatting and layout, interactive activity creation

Leonie Bettin, DVM

PhD student, Department of Veterinary Microbiology, University of Saskatchewan

Technical accuracy check of translation, copyeditor, learning tool development

Anthony Carr, Dr med vet, DACVIM

Professor, Small Animal Clinical Sciences, Western College of Veterinary Medicine,
University of Saskatchewan

Translation accuracy consultation

Kristine Dreaver-Charles

Instructional Designer, Distance Education Unit, University of Saskatchewan

Open textbook consultation

Monique Mayer, DVM, MS, DACVR (Radiation Oncology)

Professor, Small Animal Clinical Sciences, Western College of Veterinary Medicine,
University of Saskatchewan

Translation, clinical notes and flashcard authorship, copyeditor

John Ogresko

Media Production, University of Saskatchewan

Media development

Isabell Stamm

Veterinary student, class of 2022, Western College of Veterinary Medicine,
University of Saskatchewan

Translation, learning tool development

ACKNOWLEDGMENTS

This project was supported by a grant from the University of Saskatchewan Open Textbook Creation/Adaptation Fund and by the Western College of Veterinary Medicine Research Office.

We would like to thank the following people for their valuable contributions during the translation of Dr. Baum's work:

Venessa Ibsen

Veterinary student, class of 2023
Western College of Veterinary Medicine,
University of Saskatchewan

Prof. Dr. habil. M. Füll

Dipl. E C B H M
Klinik für Klautiere
Universität Leipzig

Prof. Dr. med. vet. Christoph K.W. Mülling

Professur für Veterinär-Anatomie
Fachtierarzt für Anatomie
Geschäftsführender Direktor
Veterinär-Anatomisches Institut
Veterinärmedizinische Fakultät der Universität Leipzig

Dr. Rolf -Bernhard Essig

Free author
Bamberg, Germany

INTRODUCTORY VIDEOCAST by Dr. Hiroo Suami, MD, PhD

This videocast discusses cutting edge applications of Dr. Hermann Baum's 1918 work on the canine lymphatic system to human cancer patient research. Dr. Hiroo Suami, MD, PhD, from the Australian Lymphoedema Education, Research and Treatment (ALERT) at Macquarie University highlights examples of how comparative aspects of canine lymphatic anatomy and function, described over 100 years ago, are benefitting human patients with lymphedema today.

The videocast can be found here:

<https://player.vimeo.com/video/592762108?h=9e97c29595>

STAGING OF THE CANINE CANCER PATIENT

An important clinical application of Dr. Baum's work is staging of dogs diagnosed with cancer. Staging a cancer patient involves determining the anatomical extent of disease, which is classified according to the extent of primary tumour (T), involvement of regional lymph nodes (N) and presence of distant metastases (M) (the TNM staging system). For example, for thyroid tumours, lymph nodes are classified as N0 (no evidence of regional lymph node involvement), N1 (ipsilateral regional lymph node involved), and N2 (bilateral regional lymph node involvement). NX is used when the regional lymph nodes are not assessed.¹

The stage of cancer will affect a patient's prognosis, as well as the treatment plan recommended by an oncologist. For example, a lymph node group known to contain metastases may be included in radiation treatment.

Knowledge of the biological behaviour of a tumour will determine the importance of staging regional lymph nodes. Some malignant tumour types are more likely to involve regional lymph nodes; examples of these tumour types in the dog include mast cell tumours, thyroid tumours, oral melanoma and anal sac tumours. Staging of regional lymph nodes may be accomplished through physical examination, imaging (ultrasonography, computed tomography [CT], lymphography, lymphoscintigraphy, positron emission tomography [PET], magnetic resonance imaging [MRI]) and cytological or histological examination. In order to decide which regional lymph nodes draining a tumour should be assessed, a clinician must understand the lymphatic drainage patterns. For example, lymph vessels leaving the non-diseased thyroid gland drain to the medial retropharyngeal lymph node, the deep cervical lymph nodes, and the cranial mediastinal lymph nodes, and these lymph nodes should be considered when staging a dog with a malignant thyroid tumour.

Cancer may change the normal pattern of lymphatic drainage. Oncologists may use lymphography (injection of a contrast agent to image lymphatic drainage), lymphoscintigraphy (injection of a radioactive tracer to image lymphatic drainage) or injection of dye to identify the first lymph node(s) draining a patient's tumour. This lymph node(s) is called the sentinel lymph node (SLN). The presence or absence of tumour cells in the SLN predicts the lymphatic spread of a tumour and may predict outcome, as well as guide treatment.² Lymph node size alone is not specific or sensitive for regional metastasis but can be used to evaluate response to treatment. Computed tomography is the preferred imaging method for measurement of lymph node size, based on reproducibility of measurements. Size measurements should be made on the plane of acquisition (usually the transverse plane). Lymph nodes less than 1 cm in diameter are considered non-pathological in response evaluation of dogs with solid tumours.³

1 Owen, L. N., and World Health Organization. *TNM Classification of Tumours in Domestic Animals*. 1st. ed. Geneva: World Health Organization, 1980

2 Tuohy JL, Milgram J, Worley DR, Dernell WS. A review of sentinel lymph node evaluation and the need for its incorporation into veterinary oncology. *Vet Comp Oncol*. 2009 Jun;7(2):81-91

3 Nguyen SM, Thamm DH, Vail DM, London CA. Response evaluation criteria for solid tumours in dogs (v1.0): a Veterinary Cooperative Oncology Group (VCOG) consensus document. *Vet Comp Oncol*. 2015 Sep;13(3):176-83

The Lymphatic System of the Dog

by Hermann Baum

Dedicated to my mentor, Professor Doctor Wilhelm Ellenberger,
with gratitude and admiration from the author, Hermann Baum.

This book is also available online under:

<https://openpress.usask.ca/k9lymphaticsystem/>

PREFACE

After publishing *The Lymphatic System of Cattle* in 1912 with the Hirschwald publishing house in Berlin [6], I have now followed up with *The Lymphatic System of the Dog*, using a similar approach.

Even upon a superficial observation of the gross macroscopic lymph nodes and lymph vessels in various species of animals, I am convinced that there are great differences in the macroscopic behaviour of the lymphatic system, both lymph nodes and lymph vessels, between individual animal species. Under no circumstances can the findings in one species be applied to another species, and the lymphatic system of each species must be examined individually. I have recently expressed this opinion and attempted to support its accuracy in an article published in *Anatomischer Anzeiger*, 1918, Vol. 51: Can Conclusions Drawn from the Anatomical Behaviour of the Lymphatic System of One Animal Species be Applied to Another Animal Species? The Differences Between the Lymphatic system of the Cow and the Dog.

The present work is a treatise in the commemorative publication for the 70th birthday of Professor Ellenberger. The commemoration did not allow this work to be expanded upon further, and the extensive details on joint, bone, and muscle lymph vessels have been published in other journals. Only the results of my initial investigations are included in this work.

I would like to thank my publisher for making the printing of this work possible, despite the unfavourable conditions that war has presented.

April 1918

Dr. Baum

INTRODUCTION

This study of the canine lymphatic system was carried out using the same methods as those applied to cattle (see Baum [6]), although the research was performed independently. As in cattle, the lymph vessels of all organs in dogs were macroscopically traced when injected, with the exception of small portions of the bones and joints, the middle and inner ear, the muscles of the eye, and the eyeball (*bulbus oculi*). All the lymph nodes, their drainage areas, and their efferent duct behaviour were carefully examined, using the techniques described in *The Lymphatic System of Cattle* [6], pages 3 to 10 (see the Methodology section for an excerpt from this publication).

The available literature has been considered but is of limited use due to its mostly general nature. This applies to the veterinary anatomical works *Anatomy of the Dog* by Ellenberger-Baum [18], *Anatomy of Domestic Animals* by Ellenberger-Baum [17], *Anatomy of Domestic Animals* by Martin [23], *Anatomy* by Chauveau-Arloing [15], and *Anatomic Images of Domestic Mammals*, 1829, by Gurlt [20]. These texts provide detailed canine anatomy but are not always specifically cited in this manuscript as the lymphatic system information is too general and furthermore outdated by my extensive investigations. There are several more specific publications on lymph nodes and lymph vessels in dogs listed in the bibliography at the end of this work; including multiple articles that I have published [3–13]. The content of my previous work is of course considered in every respect in the current publication. Of them, Merzdorf's research on the lymph nodes of the dog is prominent [24]. It was carried out as a preparation for the current comprehensive publication at my institute, under my direction, and therefore the material from those studies included in this work are not specifically referenced.

The number of lymph nodes in dogs is relatively small, both in terms of the number of lymph node groups and the number of lymph nodes in each individual group. This results in dogs being the domestic animal with the smallest number of lymph nodes and lymph node groups. The sizes of the lymph nodes vary between 1 mm to 7.5 cm (though, in notable cases, the jejunal lymph nodes of large dogs may be up to 20 cm in size). However, the number of lymph nodes over 2 cm in length is very low, even in large dogs. The lymph nodes of the dog are relatively large when compared to the lymph nodes of humans, horses, and pigs. The shape of lymph nodes in the dog fluctuates widely. The majority of lymph nodes are round or oval, or elongated or bean-shaped, and somewhat flattened. There are additionally a number of irregular shapes: some lymph nodes are dumbbell-shaped, lobed, S-shaped, or horseshoe-shaped (see middle tracheobronchial lymph nodes), or very elongated and extremely flattened, almost ribbon-shaped (see hepatic lymph nodes).

A hilus appearing macroscopically as an obvious indentation is not present in all lymph nodes, at most present in about 50 to 60% of canine lymph nodes. In about another 20% of lymph nodes, the hilus appears only as a slight inward projection of the capsule. In elongated lymph nodes, it usually appears as a longitudinal groove on one side of the lymph node.

According to my observations, the number of efferent vessels of the dog's lymph nodes varies between 1 and 10, but is most commonly between 1 and 3. This does not always mean that only 1 to 3 efferent

vessels emerge from a particular lymph node – there can be many more tiny efferent lymph vessels emerging from a lymph node, at times upwards of 50. However, these tiny vessels unite to form 2, 3, or up to 10 larger vessels, usually so quickly that one can hardly distinguish and count the tiny vessels when they first emerge from the lymph node. Larger numbers of vessels (6 to 10) will again combine to form 3 to 5 larger vessels. In most cases, the exact number of efferent vessels cannot be counted because the vessels continuously divide and reunite to form networks.

It is difficult to identify all the afferent vessels for a lymph node because the entire drainage area cannot be easily injected in a single sample, but the number of afferent vessels is certainly greater than the number of efferent vessels.

My investigations into the lymphatic system of dogs have confirmed the general behaviour of the lymph vessels that I reported in cattle (see page 7 of *The Lymphatic System of Cattle* [6]). This is particularly true for my finding that, contrary to previous belief, lymph vessels may enter directly into the venous system and that lymph vessels enter the thoracic duct without having passed through a lymph node. The number of vessels that behave in this manner is considerably greater than I assumed after my observations in cattle, and in a large number of cases, these lymph vessels come from outside the thoracic and abdominal cavity, more specifically from organs located at a great distance from the thoracic duct. For example, lymph vessels from certain muscles, including the *M. trapezius*, *M. longissimus dorsi*, *M. sternohyoideus*, *M. obliquus capitis caudalis*, and *M. obliquus externus abdominis*, as well as lymph vessels from the thyroid gland and testes, open directly into the thoracic duct and thus drain directly into the venous system. Remarkably often, in one-quarter to one-half, or even up to two-thirds of cases, this was seen for lymph vessels from organs with internal secretion, including the kidneys and adrenal glands, the thyroid gland, and the testes (details, [8] and [Figure 1](#)).

I found that the general behaviour of lymph vessels between cattle and dogs differed in only a single, but very important, aspect: the network formation by larger lymph vessels. Network formation by larger lymph vessels is seldom observed in cattle, though it appears to be quite common in dogs. This is easily demonstrated when, as an example, the drawings of skin lymph vessels of the cow and the dog are compared. The rich network of lymph vessels in the dog makes the exact number of lymph vessels, both those that are associated with blood vessels and those that are not, difficult to count. The number of lymph vessels not associated with blood vessels appears to be considerably less in the dog than in the cow.

All the diagrams of the canine lymphatic system in this publication were illustrated by the artist Georg Münch from Dresden. Mr. Münch carried out this difficult task with great devotion, patience, and artistic understanding, and I am indebted to him for his work.

HEMAL LYMPH NODES

I cannot say with certainty that hemal lymph nodes occur in dogs, but if they do, they are rare. In my extensive research into the canine lymphatic system, which included hundreds of dogs (or at least parts of them), I noticed only 3 lymph nodes of unknown origin, as they were dark in colour.

Two of these lymph nodes of unknown origin were located on the cervical trachea, and 1 was located on the aortic arch. Two of these lymph nodes were examined under a microscope, and they did not appear to be hemal lymph nodes. One of these microscopically examined nodes was determined to be a lymph node with numerous pigment cells resulting from hemorrhage in the drainage area, and the other was a strongly anthracotic lymph node. The third case involved a lymph node that was also identified as a possible hemal lymph node due to its external appearance (scarlet red to dark red in colour). When it was injected to confirm the diagnosis, no efferent vessels were found, suggesting that it was, in fact, a hemal lymph node. Because of the injection, however, the node could not be microscopically examined.

METHODOLOGY

This Methodology section is an excerpt from *The Lymphatic System of Cattle*, Pages 3-10, as I examined the canine lymph nodes, their drainage areas, and their efferent duct behaviour using the techniques described in that publication. References for this chapter are included below.

Regarding the technique for macroscopic visualization of the lymph vessels, I did not limit myself to a single method alone, although by far in most cases, and for most organs, I used the puncture injection method in principle as described by Gerota [9]. For the injection liquid, I used the following solution: Prussian blue oil paint or Berlin blue oil paint, which are available in tinfoil tubes, placed in a crucible, then rubbed with pure turpentine oil until a uniform and thin paste is formed. The amount of turpentine oil is subjective – I don't use as much as Gerota specifies (2 g of oil paint and 3 g of turpentine oil), but rather the other way around: 3 g of paint and 2 g of turpentine oil. Then, around 3 to 5 times the amount of ether is added, and the mixture is filtered through window cleaning leather (deerskin), not through canvas. For a syringe, I use the Record syringe (*Rekordspritze*)¹ with metal cannulas as recommended by Bartels [1], however, based on my experience, I believe that the construction of the syringe does not matter, and this belief is supported by the fact that almost everyone who has dealt in depth with lymph vessel injections has either invented or constructed their own injection syringe.

What is important, in my experience, is: 1. the use of cannulas that are as narrow as possible and 2. the greatest possible practice and patience. The narrower the cannula, the more evenly the pressure exerted by the injecting force (hand) will be, and the more evenly and gradually an increase in pressure is possible. This is very important with puncture injections. The lower the pressure initially applied and the more evenly it can be exerted and increased, the lower the risk of extravasation at the puncture site, and thus the greater the likelihood of injecting the lymph vessels. I used metal cannulas that were only 0.29 mm thick, which I was unable to obtain for a long time, and which I only received after great efforts by the mechanic of the veterinary university in Dresden, Mr. Eugen Albrecht. Metal cannulas have a great advantage over glass cannulas in that they do not break off as easily when penetrating solid tissue, and in that they can still be used even with very firm tissue (e.g. the bone tissue of young animals or the cartilage tissue), while glass cannulas cannot be used at all for these tissues.

Of course, it is not only the use of narrow cannulas that lead to success, but also skill, practice, experience, and other small tricks that will be mentioned in the individual chapters – even indefinable imponderables may play a role. For instance, after my first unsuccessful attempts to inject fascia lymph vessels, I almost threw the musket into the grain², because I no longer believed in success, until I finally

¹ One of the first glass and metal hypodermic syringes, designed for simple cleaning and made to be taken apart and put back together with simplicity. Introduced by the Berlin medical instrument maker Dewitt Herz in 1906. <https://www.woodlibrarymuseum.org/museum/record-syringe>

² The German idiom “throw the musket into the grain”, or “die Flinte ins Korn werfen“ means nearly the same as the English idiom “throw in the towel”, in the sense of giving up. It has been in continuous use since the 17 century. The idiom has a military background; around 400 years ago, soldiers did not wear uniforms and would instead be recognized by their weapons, especially the big and quite unwieldy rifles or muskets. It was easy to desert the battlefield if you could get rid of the musket, and in high grown grain no one would see it and recognize you as a deserter. However, you gave up the battle and the cause you fought for. (Credit: Dr. Rolf Essig, free author, Bamberg).

succeeded in an injection. All at once, success was just as frequent as failure had been before, although I was unable to identify what I was doing differently.

In addition to puncture injection, I also used other methods. I successfully filled the lymph vessels of the tonsils by rubbing the coloured liquid onto the surface of the tonsils with a blunt object (scalpel handle, leather, etc.), and the lymph vessels of the joint cavities by introducing the coloured liquid into the intact joint cavity and then mimicking the natural movements of the joint for different lengths of time. The lymph vessels of the tendon sheaths can be filled even more easily, and it is only necessary to introduce the coloured liquid into the intact tendon sheath and to massage the filled tendon sheath lightly in order to inject the lymph vessels very nicely in a very short time. I filled the lymph vessels of the intestine not only by puncture injections, but also by introducing so much coloured liquid into a piece of intestine that had been tied off twice that it was completely full of liquid. The piece of intestine was then massaged until its lymph vessels were filled, which often happened very quickly after some length of massage. The lymph vessels of the uterine mucous membrane can be demonstrated using a similar method. Finally, in addition to puncture injections, the lymph vessels of the parietal pleura and the parietal peritoneum were filled by injecting the coloured liquid into both the pleural and peritoneal cavities and then using a special, albeit simple, pump to imitate the animal's respiratory movements for a longer time. All these methods, the details of which are to be described in the respective chapters of this book, will eventually lead to the goal, and one must not be discouraged by initial failures.

I would like to draw your attention to another special method of injecting lymph vessels, which, given its great simplicity, is of particular value, because it enables injection of the lymph vessels of those sites and organs in which the other methods, specifically the puncture method, fail, such as the softer organs, adipose tissue, muscles (especially the eye muscles), etc. In such sites and organs, assuming the lymph vessels begin with small openings or equivalent structures, I placed coloured dye in the extravascular space using a low-grade injection and then lightly kneaded and massaged the area until the lymph vessels filled. In principle, this is the same method that I used in the aforementioned methods to demonstrate the lymph vessels of the tonsils, joints, tendon sheaths, intestines, pleura, and peritoneum, in that all of these methods are based on lymph vessels starting with small openings or physiologically equivalent structures, and that the coloured liquid is mechanically pressed or pushed through the openings into the lymph vessels. One could even explain the success of puncture injection in this way. As already mentioned, I have used this simple method with great success where other methods, including the puncture method, failed, especially with muscles (primarily the muscles of the globe), but above all with the renal fat, where I could only manage to fill the lymph vessels using this method. As far as I know, this method has not been published, only referred to in a statement by Oelsner [13]. Oelsner tried to inject the lymph vessels of the pectoralis major muscle by puncture injection, but did not succeed. He stated "but if small amounts of Gerotaschen dye [9] were placed extravascularly in the muscle, and then a thin spatula was used to distribute the dye by gentle stroking, the small vessels running parallel to the muscle fibers filled with the dye every time, and these vessels then filled a fine network of vessels on the sternum, confirming that these were indeed lymph vessels. These lymph vessels perforated the intercostal spaces close to the sternum on the side opposite the muscle, accompanying the blood ves-

sels, and drained to the sternal lymph nodes”. This information came to my attention only later, after I, independently of Oelsner, had often used the method I describe with success.

I carried out my examinations only on fresh bovine cadavers, most of which I obtained from the Dresden slaughterhouse, and used for injections until putrefaction started. Based on the extraordinarily large number of injections I carried out, I agree with Bartels [1] that the injections generally work best on organs that are as fresh as possible, or still warm. In contrast to Bartels, however, I found that most organs don't need to be warm to achieve a successful injection, and that it does not matter if the organ is fresh or a few days old. There are some individual organs that are an exception to this statement, however. Based on my observations, lymph vessel injections in the liver are much easier when the organ is as fresh as possible as opposed to when it is a few days old. In addition, when injecting the lymph vessels of muscle, one must of course not do so during the *rigor mortis* period. For most organs, the age of the animal also does not affect the success of the injection, that is to say, injection is just as easy in adult cows as it is in calves. There are, again, some individual organs that are an exception to this. The articular lymph vessels of young animals could be injected more easily than in old animals, and the bone lymph vessels were easy to inject only in young animals. The same applies to the cartilaginous lymph vessels, especially those of the larynx cartilage, in which injection was only successful in very young animals. If the lymph vessels were injected and their examination could not be completed quickly, the organs were then wrapped in cloths soaked with formalin solution in order to delay the onset of putrefaction. Some of the injected preparations were preserved in a 4% formalin solution.

I will use limited references in this book, since, as already mentioned, the general literature on lymph vessels is not applicable to my work. The comparative anatomical literature is also of little use, since, as will be described elsewhere, both lymph node groups and lymph vessels in the individual animal species show such great differences that comparisons between species are difficult to make, and the findings in one animal species do not apply to another species. Instead, it is necessary to examine and describe the lymphatic system of each animal species individually, if the descriptions are to be correct and valuable for practical applications. Based on this notion, only the literature that refers to the lymphatic system of cattle could be useful to my work. However, there is a limited amount of these references and almost all of them are incomplete, therefore making the existing literature of little value to my work. This even applies to information in textbooks on veterinary anatomy and meat inspection. A reference of purely historical interest is included: Duvernoy [8], Haller's teacher, is said to have shown the entire lymphatic system of a cow. Unfortunately, however, nothing has been handed down about his technique.

TERMINOLOGY AND PHRASING

As far as terminology, I endeavoured to retain the previous names of lymph node groups as much as possible, and for purely practical reasons have done so in isolated cases even where another name would undoubtedly have been more correct. In other cases, however, the previous names could not be retained for reasons that will be given in the relevant sections. Many lymph nodes or groups of lymph nodes had to be renamed because they had previously been described either only very inadequately and without specific naming, or not described at all. In many cases, I have had to divide the individual lymph node groups into subgroups and give them special names, because otherwise an exact description of the afferent and efferent pathways of individual lymph nodes and the relationship of lymph vessels of individual organs to the lymph nodes would not have been possible. I have also endeavoured to name individual lymph nodes and lymph node groups as closely as possible to the corresponding lymph nodes and lymph node groups in humans and in accordance with the definitions of the Basle Nomina Anatomica (i.e. to use a valid, comparative anatomical name as a basis). However, this approach could only be followed for a relatively small number of lymph nodes and groups of lymph nodes, and not for the majority. The individual lymph node groups are so extraordinarily different in individual animal species in terms of location, drainage area, occurrence in general, number of nodes, etc., that a valid, comparative anatomical name is not possible for many. For the same reason, the classification of the lymph nodes is very uncertain and will always depend on the author's individual opinion. I don't know of a single, decisive system by which individual lymph nodes and groups of lymph nodes could be named. It would undoubtedly be more correct to name the lymph nodes after their drainage area.

However, even if this approach were attempted for a single animal species, it would still not be possible because, almost without exception: 1. the lymph vessels of individual organs drain to different lymph nodes and 2. the individual lymph nodes or groups of lymph nodes receive lymph vessels from different organs, as shown by the study of the lymph vessels of the organs and the drainage areas of the lymph nodes. For example, of the lymph nodes that drain the lymph vessels of the lungs, some also additionally drain the lymph vessels of the heart, while others also additionally drain the lymph vessels of the diaphragm and esophagus. Another example is the lymph vessels of the diaphragm, which drain to at least 4 different lymph node groups; these lymph nodes would be impossible to group together given the differences in the remaining areas that they drain. Therefore, one is forced to name the lymph nodes and groups of lymph nodes according to their location and, as far as possible, to take their drainage areas into account. Naturally, this classification and naming of the lymph nodes remain inadequate and unreliable, and individual lymph node groups will always be inconsistently named by different investigators, depending on whether the lymph vessels and thus the drainage areas of the lymph nodes of the particular animal species have been studied in detail or less closely examined. One can already see these differences in the description and naming of human lymph nodes, even though, at this time, the human lymphatic system is the best and most precisely known. Almost every investigator suggests dif-

ferent nomenclature (for example, see the chapter on the naming and classification of human bronchial lymph nodes in the work by Bartels, page 175 [1]).

It is even more challenging to compare the lymphatic system of several animal species, because, as already mentioned, the individual lymph node groups in different species are not at all similar in terms of location, occurrence and drainage area. Therefore, one must describe the lymphatic system of each animal species individually, albeit while preserving the comparative anatomical aspects as much as possible. I therefore cannot agree with Bartels, pages 36, 68 and 69 [1], that in principle there is agreement in the location of the lymph vessels and lymph nodes between mammals and humans, and that the only difference is the greater number of lymph nodes in humans.

If there are 1 – 2 or 1 – 3 lymph nodes that are associated with each other, or part of a group, it can be difficult to decide whether the lymph nodes should be referred to in the singular or plural, and even after careful consideration this often remains a matter of opinion. I approached such cases in the following way: if there is only one lymph node, which can be double in the minority of cases, then I speak in the singular (e.g. mandibular lymph node, lateral retropharyngeal lymph node). If there are 1–3 or more lymph nodes, then I speak in the plural, although such groups may often include only 1 node. I have consistently replaced the earlier, outdated, and unjustified term “lymph glands” with the more correct term “lymph nodes”; consequently, the Latin name “*Lymphoglandula*” should be replaced by “*Lymphonodus*“. However, I did not decide to change the Latin names, because the term “*Lymphoglandula*” has been adopted by the Basle Anatomical Nomenclature and is accordingly still used in all anatomical writing at this time¹.

Considering the above, I did not include the general behaviour of the lymph nodes; for this information refer to the chapter I published previously: *Histology of the Circulatory Organs* in Ellenberger: *Handbook of the Comparative Microscopic Anatomy of Domestic Animals*, Berlin 1906–1911. I have only included descriptions of behaviour when my findings contradicted previous information and views, or when the behaviour has not been previously described. My findings are supported by the numerous investigations I performed on a very large number of animals.

The size of the bovine lymph nodes fluctuates within the broadest limits; from the size of the head of a pin up to 1 meter and 20 centimeters in length, although the vast majority of lymph nodes do not exceed a size of 5 cm and the lymph nodes exceeding 10 cm in length are found almost exclusively in the mesentery of the small intestine. In calves 3 to 6 weeks in age, the lymph nodes are about half the size of those in adult animals. The shape of lymph nodes in cattle is variable, with no consistent shape. In most cases, the lymph nodes are irregularly rounded or oval, and at the same time somewhat compressed, so that they do not appear quite as thick as they are long and wide. Frequently, the lymph nodes are long, even up to 1.2 meters in length. I found other shapes frequently; these included curved, even horseshoe-shaped lymph nodes, ring-shaped constrictions, local thickenings and other irregular shapes. A hilus is observed in approximately 70% of lymph nodes, and in elongated lymph nodes is usually in

¹ The English translation uses the terms ‘*Ln.*’ and ‘*Lnn.*’ for *lymphonodus* and *lymphonodi*, respectively, to be consistent with current anatomical writing, while the original German version used the term ‘*Lgl.*’ for *lymphoglandula* and *lymphoglandulae*.

the form of a longitudinal groove on one side of the lymph node. Occasionally there is a partial fusion of two adjacent lymph nodes; I observed this especially in the jejunal lymph nodes. According to my observations, the number of efferent vessels of individual lymph nodes fluctuates between 1 and 12, and in most lymph nodes between 1 and 3. The largest number of efferent vessels were observed for the parotid lymph node and the long caudal mediastinal lymph node and the long mesenteric lymph nodes; for very long mesenteric lymph nodes, the number of efferent vessels can be considerably larger, for example, in the case of a 23 cm long node, 43 efferent vessels were counted.

The number of afferent vessels is very difficult to determine because the entire drainage area of a lymph node cannot be injected during one examination but is certainly greater than the number of efferent vessels: on average, about twice as large. Due to limited time examining cattle, I did not try to quantify the influence of age on the macroscopic behaviour of the lymph nodes, but I believe that Merzdorf's [12] finding in dogs, that the lymph nodes of older animals are relatively smaller and lighter than the lymph nodes of younger adult animals, also applies to cattle.

I cannot say with certainty whether individual lymph nodes can completely disappear in old age, but I do not believe that this is the case, and it certainly is not a common finding. As far as the related question, whether new lymph node formation can occur during life, I cannot provide a definite answer. Based on my work involving extirpation of lymph nodes, which I will report in detail later, I can state that after extirpation of lymph nodes, new lymph nodes can form either in the same or in another, more distant location. These observations agree with those of Bayer [2, 6] and Ritter [7, 14], who also observed the formation of new lymph nodes after extirpation of lymph nodes in dogs.

Regarding the location and number of the lymph nodes, it can generally only be stated that the lymph nodes are located individually or in groups at certain locations in the body and that the number of lymph nodes in cattle is generally small (compared to humans and horses) and that the individual lymph nodes are relatively large. While the individual lymph node groups in the horse consist of many small nodes, in the cow the groups consist of a few, relatively large nodes. General statements on the location of the lymph nodes in cattle cannot be made. It is certainly not possible to state that lymph nodes are very often located in the bifurcation angles of veins, as Bartels [1] observed for human lymph nodes; this applies to only 10% of all lymph node groups in cattle.

The lymph nodes that receive dye after injection of an organ are referred to as regional, or corresponding, lymph nodes of that organ; conversely, one can say that the organ is a tributary to these lymph nodes. According to the prevailing view, however, a group of lymph nodes is never regional for just one organ, and rarely is an organ tributary to a single group of lymph nodes [1]. Based on my many investigations and observations, I can generally agree with this view, but not explicitly. I found that there are quite a few organs (e.g. many muscles, tendons, tendon sheaths, joints, bones, mammary glands, testes, ovaries, etc.) from which lymph vessels drain to only one group of lymph nodes; in other words, they are tributary to a single group of lymph nodes. I also found groups of lymph nodes that did drain just one organ, for example, as far as I can tell, the pericardial lymph nodes receive efferent vessels only from the pericardium.

My investigations into the general behaviour of the lymph vessels also led to both new information and corrections of previous information. This applies to the occurrence of lymph vessels. For a long time, as a result of unsuccessful injections, it was assumed that many organs were without lymph vessels (even bones, joints, tendons, tooth pulp, etc.), but we now know beyond doubt that most of these organs have lymph flow (see the relevant chapters). There are, however, certain tissues and organs in which lymph vessels have not yet been proven with certainty (e.g. epithelia, cartilage, the membranes of the eyeball and the central nervous system), while in other organs (e.g. tendon sheaths and fatty tissue) the existence of lymph vessels has not been investigated. Bartels, page 68 [1], is of the opinion that lymph vessels exist in all organs and tissues supplied by blood vessels, and that only in tissues and organs which are completely lacking blood vessels would lymph vessels be absent. Only future investigations will determine if this opinion is correct. Based on my investigations, I can only say that the cartilage of cattle (specifically the larynx and tracheal cartilage), i.e. organs without blood vessels, have lymph vessels, at least insofar as I could easily inject lymph vessels from this cartilage using a puncture injection technique. On the other hand, I have not succeeded in detecting lymph vessels in the parenchyma of hemal lymph nodes and in the parenchyma of the spleen, i.e. organs which undoubtedly have blood vessels, although that could be due to the special behaviour of the blood vessels of these organs.

An important law, which Bartels calls the circuit, or switching, law, is that all lymph vessels (with the exception of their end branches) pass through at least one, and usually several, lymph node(s) before they terminate in the venous system. According to my investigations, this law applies to the overwhelming majority of lymph vessels, but there can be isolated exceptions to the law. In addition to the 2 to 3 such exceptions described in the literature, I can add 4 additional exceptions; I clearly saw one lymph vessel each from the heart and pericardium of the cow drain directly to the thoracic duct, and two lymph vessels from the adrenal glands drain directly to the *cisterna chyli* (for full details see [4]). It must be acknowledged, however, that these 4 lymph vessels were the only ones among the thousands of lymph vessels that I viewed and examined, and that they all came from organs that lie in the vicinity of the thoracic duct and the *cisterna chyli*.

Another related question is whether lymph vessels (apart from the large terminal trunks of the lymphatic system) can open directly into veins. This question has always been a controversial one, and for a time it appeared that authors were equally divided on the question. Recently, Bartels [1] summarized the existing literature and passed a devastating judgment on those authors who, even today, want to accept the possibility of a direct confluence of lymph vessels and veins. After the publication of Bartels' summary, Sylvester [16] examined whether lymph vessels drain into veins. He observed the lymphatic system of 30 monkeys belonging to 6 genera of South American monkeys and found that, without exception, both the intestinal trunk and the lymphatic trunk of the pelvic limbs opened into the venous system at the level of the renal veins, namely into a renal vein or into the caudal vena cava. Huntington [10] made similar observations on *Macropus rufus*. Based on my extensive investigations and observations, I have also commented on this question and explained my position in detail in an article in *Anatomischer Anzeiger* [5]; I refer the reader to this article, and only emphasize here that I have made several impeccable observations that argue in favour of lymph vessels flowing directly into

veins; I have observed that 1. rarely, lymph vessels can flow into the thoracic duct and the *cisterna chyli* without having passed a lymph node, and thus drain directly into the venous system (see above), and 2. that the efferent vessels of lymph nodes, including those that are far from the thoracic inlet, can open directly into veins. I have definitively observed several of these cases. Other cases that I have examined and described in the article mentioned above support at least the possibility or probability that lymph vessels can open directly into veins.

In most cases, however, it is not possible to prove beyond a doubt that an injected vessel is truly a lymph vessel, for if an injected vessel opens into a vein, the objection is always raised that it was not a lymph vessel but instead a small vein that was filled during the puncture injection. Given our current knowledge of the differences between small veins and lymph vessels, especially when they are filled with blue dye, this objection certainly cannot be refuted and therefore the question of whether lymph vessels can flow directly into veins cannot be proved using this methodology. I will not include a detailed discussion of whether a microscopic examination in each individual case would help determine if the vessel in question is a very small vein or a lymph vessel.

I attempted to do this, however, when a vessel is filled with blue injection material it loses all features that distinguish lymph vessels from veins (i.e. the nucleated epithelium of the blood vessels that lymph vessels should be without [15], or the much thinner epithelium of the lymph capillaries compared to blood capillaries [11]). Even on examination of macroscopic behaviour, one cannot always decide whether the vessel is a vein or a lymph vessel with certainty, even if the observer has extensive experience in lymph vessel behaviour. Even though in most cases one can recognize injected lymph vessels by their unequal lumen, which is often constricted or bulging, their very thin walls and winding path, which is more meandering than that of comparable-sized veins, lymph vessels cannot always be distinguished from veins. Even very experienced investigators will not always be able to determine with certainty whether a vessel is a lymph vessel or a small vein.

Regarding further the behaviour of lymph vessels relative to blood vessels, most textbooks and special publications state that larger lymph vessels join blood vessels, interweaving with them to form meshes. I cannot agree with this opinion either. I believe it is one of those statements, of which there is certainly quite a number in the anatomical literature, that has been established based on limited findings and then, without being critically examined, continue for a long time in the field of anatomy. According to my observations, the statement does not technically apply to the lymph vessels of any organ, although it must be acknowledged that in some organs most of the lymph vessels run with the veins. It perhaps can be applied to the lymph vessels of the testicle, and those of the ovary and uterus, stomach, intestines, etc., but for the lymph vessels of most organs the statement does not apply. For details, see the relevant descriptions of the lymph vessels of the skin, the muscles, and other organs. The fact that some lymph vessels accompany blood vessels is obvious, but this applies only to the minority of all lymph vessels.

When I state that lymph vessels drain into a certain lymph node, there is always the possibility that in an individual case they actually bypass the lymph node and join the efferent vessels leaving the lymph node.

When assessing vaccinations, the spread of infectious substances, etc., it is important to consider that lymph vessels can pass across the midline and drain into lymph nodes of the contralateral half of the body. These midline crossings, which are particularly observed in the lymph vessels of organs adjacent to the median plane, have long been known and described in humans. I have also been able to detect them in cows, to an even greater extent than has been described in humans, and have compiled the relevant findings in a special article [3], the main content of which is as follows: In the cow, there are lymph vessels that cross the median plane and drain to lymph nodes in the other half of the body. This applies in particular to the lymph vessels of the median parts of the outer skin, the tip of the tongue, the hard palate and gums, the lower lip, the thyroid, the trachea and esophagus, the lungs, the thymus, the kidneys, *M. longus colli* and the efferent vessels of the mammary lymph nodes.

Lymph vessels are known to exhibit an abundance of anastomoses and thus form networks. This applies in particular to the initial parts of lymph vessels and to the smallest lymph vessels; these form rich networks in almost all parts of the body, in almost all tissues and organs. However, the larger or coarser lymph vessels and the lymphatic trunks form fewer networks because they anastomose less frequently; in addition, the anastomoses in the larger vessels arise mainly when several lymph vessels merge, and much less often when the lymph vessels divide, and their sub-branches connect with neighbouring lymph vessels. I would particularly like to emphasize this point, because I suspect that in general it is mistakenly assumed that there is abundant anastomotic and network formation for the larger lymph vessels and the lymph vessel trunks. My illustrations, which are as true to life as possible, provide the best information about this behaviour. While larger lymph vessels divide, possibly even repeatedly, it can easily be proven that this does not occur as often as is generally assumed. Also, the statement contained in most textbooks: "There is no communication between the lymph vessels of two anatomically separated organs" is not supported by my investigations, because such communications can occur, although they are rare (see lymph vessels of the pancreas and duodenum).

Under normal conditions, the lymph contained in lymph vessels, or the contrast injected into the lymph vessels, flows only in one direction, namely centripetally, due to the complete functioning of the valves. When injecting a cadaver, however, exceptions to this rule often occur, and retrograde filling is observed. I have often observed lymph vessels filling backward to the next lymph node, especially from the thoracic duct. I have also observed afferent lymph vessels filling backward from a lymph node after injection of contrast material into different circumstances.

Finally, a word about the very controversial question of whether lymph vessels begin with open stomata. The question of the origin of lymph vessels has been answered differently at different times, according to advances in our knowledge of physiology and to the perfection of technical aids. I do not want to elaborate on this question here but refer to my publication on the histology of the circulatory organs in the *Handbook of the Comparative Microscopic Anatomy of Domestic Animals* by Ellenberger, vol. II, Berlin 1911, as well as to special publications on histology and the work of Bartels [1]. I will also not discuss the theory that lymph vessels start with tiny openings, the so-called stomata, developed by v. Recklinghausen. afferent lymph vessels. It is recognized that in living animals retrograde metastasis can occur under certain cir I will only mention that, based on the results of my injections, especially the

methods I used for injecting the lymph vessels of the tonsils, tendon sheaths, joint cavities, muscles, the pleura, the peritoneum, the intestine and the fatty tissue, I have become firmly convinced that the lymph vessels in mammals (especially in the cow) begin with open stomata or functionally equivalent devices.

METHODOLOGY REFERENCES

1. Bartels, Das Lymphgefäßsystem (des Menschen). Jena 1909.
2. Bayer, Ueber Regeneration und Neubildung der Lymphdrüsen. Prager Zeitschr. F. Heilk. 1885. Bd. 6. S. 105-130.
3. Baum, Uebertreten von Lymphgefäßen über die Medianebene nach der Anderen Seite. Deutsche Tierärztliche Wochenschr. 19. Jahrg. No. 26.
4. Baum, Können Lymphgefäße, ohne einen Lymphknoten passiert zu haben, in den Ductus Thoracicus einmünden? Zeitschr. F. Infektionskrankh., parasitäre Krankh. u. Hygiene d. Haustiere. Bd. 9. 5. Heft. 1911.
5. Baum, Können Lymphgefäße direkt in Venen einmünden? Anat Anzeiger. 39. Bd. No 21. u. 22. 1911.
6. Baum, Ueber die Bedeutung des Fettgewebes für den Aufbau Lymphatischer Neubildungen. Prager Zeitschr. F. Heilk. 1891. Bd. 12. S. 517-552.
7. Baum, Die Neubildung von Lymphdrüsen beim Karzinom und Sarkom. Deutsche Zeitschr. f. Chir. 1907. Bd. 86. S. 532-546.
8. Duvernoy, Nach Ludwig, Christ. Friedr., William Cruikshanks und anderer neue Beiträge zur Geschichte (Bd. 3. S. 107-154. Bibliogr. v. 1500-1800). Zitiert nach Bartels.
9. Gerota, Zur Technik der Lymphgefäßinjektion. Anat. Anzeiger. 1896. Bd. 12. S. 216.
10. Huntington, Ueber die Histogenese des Lymphatischen Systemes beim Säugerembryo. Anat. Anz. Ergänzungsheft zu Bd. 37. 1910. S. 76.
11. Kölliker, Handbuch der Gewebelehre des Menschen. 6. Aufl.
12. Merzdorf, Untersuchungen über das Makroskopisch-Anatomische Verhalten des Lymphknoten des Hundes und über den Einfluss des Lebensalters auf das Relative Gewicht der Lymphknoten. Inaugural-Dissertation. Dresden 1911.
13. Oelsner, Anatomische Untersuchungen über die Lymphwege der Brust, mit Bezug auf die Ausbreitung des Mammakarzinoms. Med. Dissertation. Breslau. Archiv. f. klinische Chirurgie 1901. Bd. 64. S. 134.
14. Ritter, Die Neubildung von Lymphdrüsen Mammakarzinom. Deutsche Zeitschr. f. Chir. 1905. Bd. 79. S. 260-268.
15. Sappey, Description et Iconographie des Vaisseaux Lymphatiques, considérés chez l'Homme et les Vertébrés. Paris 1885.
16. Sylvester, On the Presence of Permanent Lymphatico-Venous Communications at the Level of the Renal Veins in adult South American Monkeys. Anat. Anz. Ergänzungsheft zu Bd. 37. 1910. S. 111.

SECTION 1

LYMPH NODE LOCATION AND DRAINAGE PATTERNS

Section 1 contains a description of the location of the lymph nodes of the dog and their afferent and efferent drainage areas.

1.1 LYMPH NODES OF THE HEAD

GENERAL

The lymph nodes of the head are organized into the following lymph centres: parotid (*lymphocentrum parotideum*), mandibular (*lymphocentrum mandibulare*) and retropharyngeal (*lymphocentrum retropharyngeum*).

PAROTID LYMPH NODE

The parotid lymph node (*Ln. parotidea*) ([Figure 13: 1](#)) is found as a large lymph node on each side of the head. It is observed to be between 1.0 to 2.5 cm long, 0.5 to 1.5 cm wide, and 0.4 to 1.0 cm thick. It is located just caudal to the temporomandibular joint and is partially covered by the parotid gland, with a portion protruding rostrally from the parotid gland. This latter portion of the lymph node lies on the caudal margin of the mandible and the *M. masseter*, where it is covered only by a thin layer of fatty connective tissue, skin muscles, and skin. The lymph node can also be located in the angle formed by the dorsal buccal nerve and the zygomatic branch of the facial nerve. The dorsal buccal nerve is found along the ventral border of the lymph node, while the zygomatic branch of the facial nerve lies adjacent to its caudal border. The superficial temporal nerve emerges at the medial border of the lymph node with branches of the corresponding artery and vein, which are initially medial to the lymph node.

Occasionally, a second small parotid lymph node can be found and may be located dorsally or ventrally from ([Figure 14: s'](#)), or on the caudal border of, the main parotid lymph node. This second parotid lymph node was observed 4 times out of 36 cases; once on both the right and left sides, and 3 times on only one side.

A small, sometimes double, lymph node ([Figure 14: s''](#)) may be located further caudal to the parotid lymph node and under the parotid gland – it is not a parotid lymph node as reported by Merzdorf [24], but a lateral retropharyngeal lymph node.

The absolute weight of the parotid lymph node on both sides varies between 0.02 and 3.00 g, and the relative weight (relative to the weight of the dog's body) from 0.0002 to 0.0098%.

AFFERENT DRAINAGE

The parotid lymph node receives afferent lymph vessels from the skin of the caudal half of the bridge of the nose, the forehead, the eyelids, the rostral half of the dorsal aspect of the head, the area of the zygomatic arch and the *M. masseter*, and the skin of the ear. The parotid lymph node also drains the temporomandibular joint, various head bones (nasal, frontal, parietal, zygomatic, temporal, and mandible) and various muscles of the head (*M. zygomaticus*, *M. temporalis*, and *M. masseter*, facial skin muscles),

the outer nose, outer ear (muscles and concha), parotid gland, and the eyelids, lacrimal caruncle, and lacrimal gland.

EFFERENT DRAINAGE

Two to 3 efferent vessels leave the parotid lymph node and either pass between the parotid lymph node and the *M. digastricus*, or under the *M. digastricus*, and over both surfaces of the great hyoid branch towards the medial retropharyngeal lymph node. If the lateral retropharyngeal lymph node is present, the efferent vessels of the parotid lymph node will also drain to this lymph node.

CLINICAL NOTES

Computed tomographic (CT) image of an enlarged right parotid lymph node (arrows). Normal-sized parotid lymph nodes are often difficult to identify on CT images as they are located immediately adjacent to the parotid gland, which is similar to the lymph node in CT density.

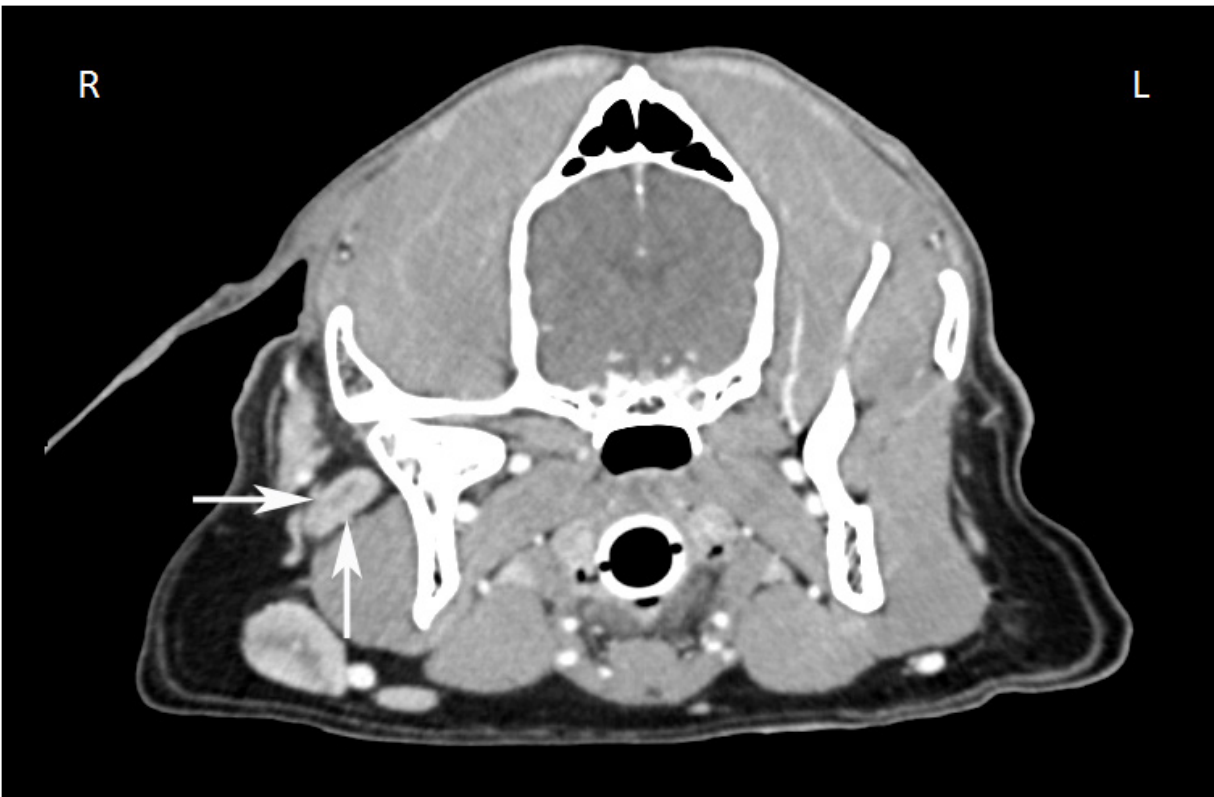

Image credit: Dr. Monique Mayer, Western College of Veterinary Medicine, University of Saskatchewan (used under CC BY-NC).

MANDIBULAR LYMPH CENTRE

A. MANDIBULAR LYMPH NODES

The mandibular lymph nodes (*Lnn. mandibulares*) (Figure 13: 2, 2', 2''; 15: v, v¹, v², v³) were examined in 36 dogs. They form a cluster of 2 to 5 lymph nodes on each side. The length of the individual lymph nodes varies from 1.0 to 5.5 cm, the width from 0.75 to 3.0 cm, and the thickness from 0.5 to 1.0 cm. The mandibular lymph nodes are located caudolaterally to the angular process of the mandible, and are underneath the skin, the facial skin muscle, and the superficial fascia.

The external maxillary vein divides the individual lymph nodes into a dorsal and ventral group (*Lnn. mandibulares dorsales* and *ventrales*). The dorsal group (Figure 13: 2) may consist of 1 to 2 lymph nodes. If there are 2 lymph nodes present, they rest between the border of the *M. masseter* and the ramus of the mandible on one side and the mandibular gland on the other, extending to the caudoventral part of the *M. masseter* and the oroventral border of the mandibular gland. The ventral group (Figure 13: 2', 2'') consists of 1 to 2 lymph nodes, or rarely of 3, or even 4 lymph nodes, which are located on the *M. digastricus*, with their ventromedial margin on the *M. mylohyoideus* and their caudal and ventromedial borders adjoining the lingual vein. As a result, the ventral group of mandibular lymph nodes inserts into the triangle formed by the external maxillary vein and the lingual vein prior to their convergence. In one observed case, the more caudal of the 2 ventral lymph nodes was on the caudoventral border of the lingual vein, i.e. outside the aforementioned triangle formed by the veins, on the lateral surface of the horns of the hyoid bone, or the *M. keratopharyngeus*.

The number and grouping of the mandibular lymph nodes have been found to be inconsistent, both between different individuals as well as in the same dog between the right and left sides. The numbers of lymph nodes on the right side were as follows: 2 lymph nodes in 19 cases, 3 lymph nodes in 11 cases, 4 lymph nodes in 4 cases, and 5 lymph nodes in 2 cases. On the left side, 2 lymph nodes were found in 17 cases, 3 in 12 cases, 4 in 5 cases, and 5 in 2 cases. In most cases there are 2 lymph nodes on both the right and on the left sides, however, I only found the same number of lymph nodes on both sides in the same individual in 20 cases.

The right dorsal group consisted of 1 lymph node in 33 cases and 2 lymph nodes in 3 cases, and the left dorsal group of 1 lymph node in 31 cases and 2 lymph nodes in 5 cases. The right ventral group was composed of 1 lymph node in 22 cases, 2 in 9 cases, 3 in 4 cases, and 4 in 1 case, while in the left ventral group there was 1 lymph node in 20 cases, 2 in 11 cases, and 3 in 5 cases. I found that in general, there are 1 to 2 mandibular lymph nodes in the dorsal group, where 1 lymph node was found in the majority of cases, present dorsal to the external maxillary vein, and 1 to 3 lymph nodes in the ventral group, where 1 lymph node was found again in the majority of cases, located ventral to the vein. The same number of lymph nodes in both dorsal and ventral groups on the right and left sides were found in 16 cases. In 12 cases, the dorsal and ventral group each consisted of 1 lymph node, in 3 cases the dorsal group consisted of 1 lymph node and the ventral group of 2 lymph nodes, and in

In 1 case the dorsal and ventral group each consisted of 2 lymph nodes. I therefore cannot agree with Schweitzer [26], who stated that there are always 3 individual lymph nodes in each group. The absolute weight of the mandibular lymph nodes on both sides varied between 0.2100 and 21.08 g, the relative weight between 0.0082% and 0.044%.

AFFERENT DRAINAGE

The mandibular lymph nodes receive afferent lymph vessels from the skin in the following areas: outer nose, lips, bridge and lateral region of the nose, cheek, intermandibular region, *M. masseter*, forehead, zygomatic arch, eyelid, parotid region and cranial half (to third) of the front neck region. The lymph nodes also receive lymph vessels from the upper and lower lip, the tip of the tongue, the gums, the cheek, the hard and soft palate, the mucous membrane of the free floor of the oral cavity and the sublingual gland, the outer nose and nasal cavity, the eyelids, lacrimal caruncle, lacrimal gland, zygomatic gland and temporomandibular joint, as well as from various head bones (incisive, nasal, maxillary, frontal, zygomatic, palatine and mandible), various head muscles (*M. levator nasolabialis*, *caninus*, *levator labii superioris*, *zygomaticus*, *depressor labii inferioris*, *masseter*, *temporalis* and *digastricus*, cheek muscles, and *M. mylohyoideus*), and muscles of the skin of the face and neck.

EFFERENT DRAINAGE

The efferent vessels of the mandibular lymph nodes (Figure 16: m, m^1, m^2, m^3) open into the medial retropharyngeal lymph node (Figure 16: a) and the lateral retropharyngeal lymph node, if present. However, some of the efferent vessels from the mandibular lymph nodes usually drain to the retropharyngeal lymph nodes on the opposite side (Figure 16: n). Efferent vessels connect the ventral mandibular lymph nodes with each other, and with the dorsal mandibular lymph nodes. I found that the efferent vessels connecting the ventral and dorsal groups only flowed from the dorsal to the ventral group (Figure 13: $2, 2', 2''$; 15: v, v^1, v^2, v^3 ; 16: m, m^1, m^2, m^3). From each individual lymph node, a large number of efferent vessels arise (usually from 8 to 10), running along the pharyngeal muscles towards the medial retropharyngeal lymph node, forming anastomoses and networks before combining into 3 to 5 vessels and entering the retropharyngeal lymph nodes (Figure 16: m, m^1, m^2, m^3).

A smaller number of efferent vessels leaving the mandibular lymph nodes turn to travel over the surface of the *M. sternohyoideus* and the pharyngeal muscles and enter the medial retropharyngeal lymph node on the contralateral side. In one observed case, an efferent vessel leaving a dorsal mandibular lymph node ran superficially towards the lateral retropharyngeal lymph node (Figure 15: v, n). According to Schweitzer [26], the mandibular lymph nodes on either side of the head are connected via the efferent vessels, but I could not confirm this finding in any of the numerous cases I examined.

B. BUCCAL LYMPH NODES

Translator's note: Baum's *The Lymphatic System of the Dog* did not include a description of the buccal lymph nodes (*Ln. buccales*). These lymph nodes are found in fewer than 10% of dogs, and are located dorsal to the *M. zygomaticus* and rostral to the *M. masseter*, in the region of the facial or the superior labial vein¹.

CLINICAL NOTES

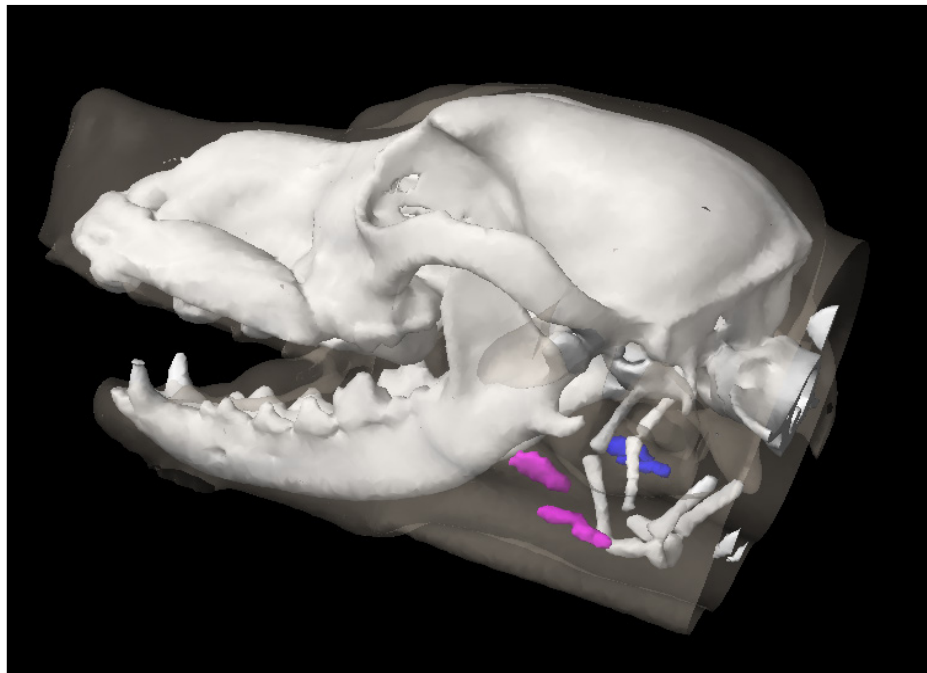
The mandibular lymph nodes are one of three lymph node groups that can often be manually palpated; the other two lymph node groups are the superficial cervical (prescapular) and popliteal lymph nodes. This may allow fine needle aspiration to be performed without imaging guidance.

Some of the efferent vessels of the mandibular lymph nodes always drain to the retropharyngeal lymph node on the opposite side, and therefore the contralateral retropharyngeal lymph node should be assessed in a dog with metastases in a mandibular lymph node.

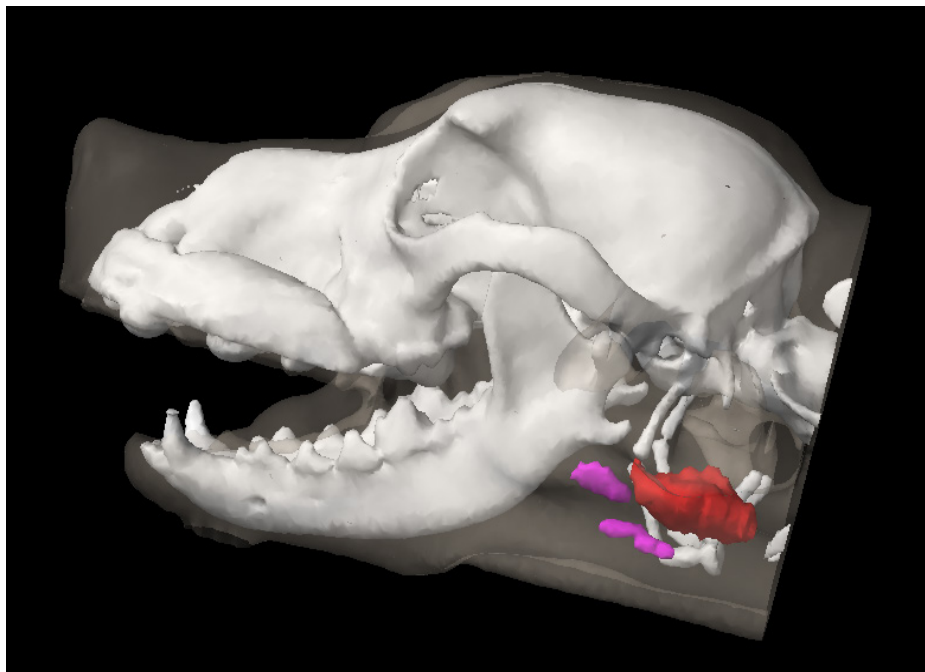
A normal-sized mandibular lymph node on manual palpation of a dog with oral melanoma should still be cytologically or histologically assessed; in a study of 100 dogs with oral malignant melanoma, 30% of dogs with normal-sized lymph nodes on palpation had evidence of lymph node metastasis on cytology or histology². This finding is likely applicable to other cancers, as early growth of cancer cells within a lymph node may not change the size of the lymph node.

1 Casteleyn CR, van der Steen M, Declercq J, Simoens P. The buccal lymph node (lymphonodus buccalis) in dogs: occurrence, anatomical location, histological characteristics and clinical implications. *Vet J.* 2008 Mar;175(3):379-83.

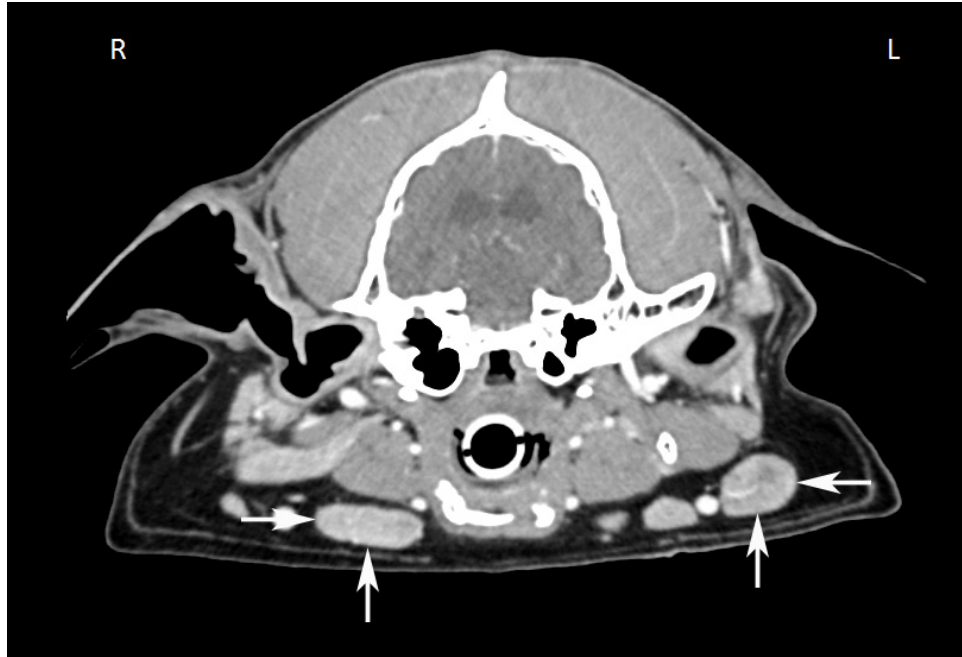
2 Williams LE, Packer RA. Association between lymph node size and metastasis in dogs with oral malignant melanoma: 100 cases (1987-2001). *J Am Vet Med Assoc.* 2003 May 1;222(9):1234-6.



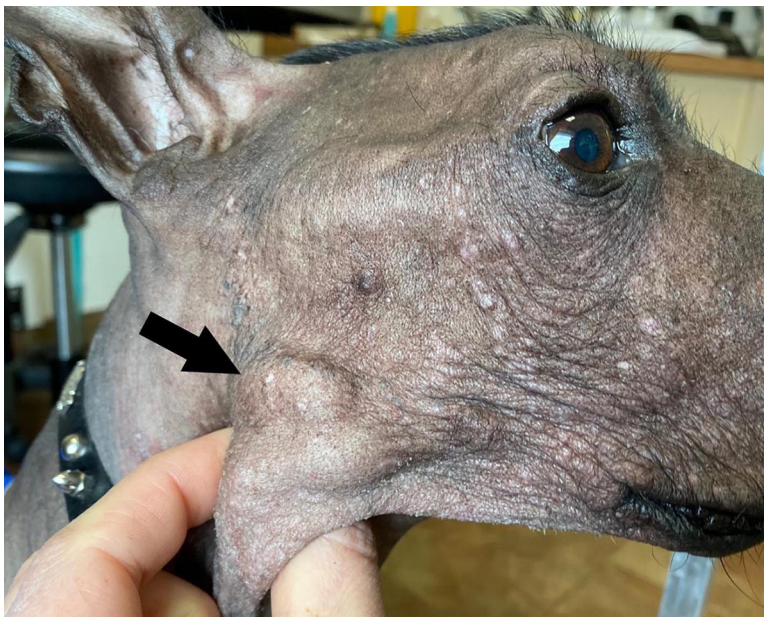The left (pink) and right (blue) mandibular lymph node groups (3D image from a CT scan). Image credit: Dr. Monique Mayer, Western College of Veterinary Medicine, University of Saskatchewan (used under CC BY-NC).



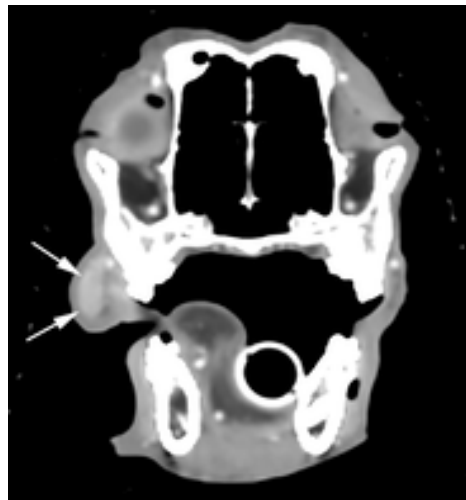
The mandibular lymph nodes (pink) are located rostral to the mandibular gland (red) (3D image from a CT scan). The normal (non-diseased) lymph nodes are also smaller and more moveable than the mandibular gland, which is relatively fixed in position. The lymph nodes will slip between the fingers when palpated. Image credit: Dr. Monique Mayer, Western College of Veterinary Medicine, University of Saskatchewan (used under CC BY-NC).



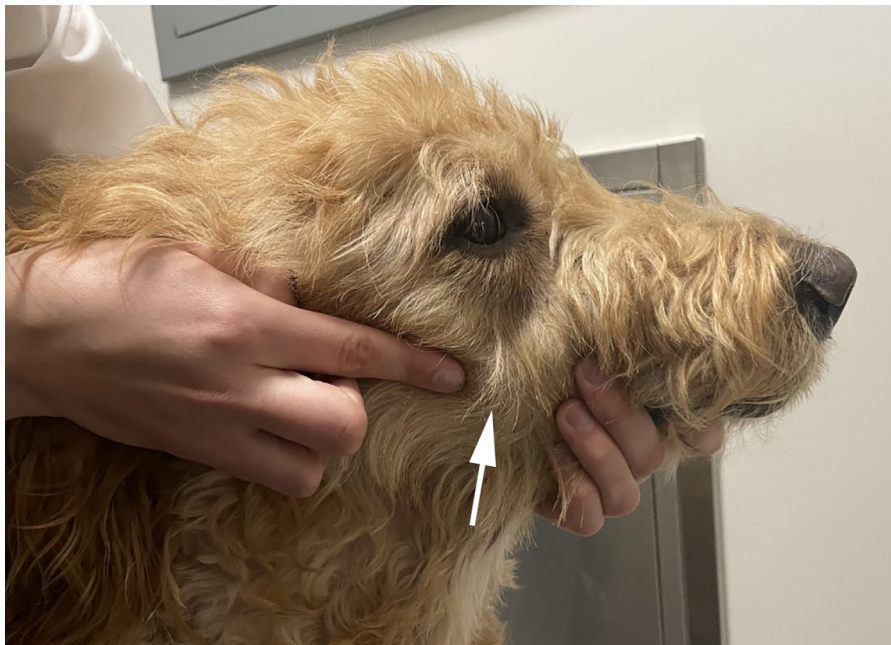Computed tomographic (CT) image of bilaterally enlarged mandibular lymph nodes (arrows) in a dog with systemic histiocytosis. Image credit: Dr. Monique Mayer, Western College of Veterinary Medicine, University of Saskatchewan (used under CC BY-NC).



A canine patient diagnosed with multicentric lymphoma. The right mandibular lymph nodes (arrow) are markedly enlarged and visible as oval-shaped swellings under the skin. Image credit: Dr. Louis-Philippe de Lorimier, Centre Vétérinaire Rive-Sud (used under CC BY-NC).



A buccal lymph node (arrows), lateral to the zygomatic process of the maxilla, on a computed tomographic (CT) image of a dog with multicentric lymphoma. Image credit: Dr. Monique Mayer, Western College of Veterinary Medicine, University of Saskatchewan (used under CC BY-NC).



The same dog as in the CT image above. The clinician's finger and the arrow show the location of the palpable, enlarged buccal lymph node. Image credit: Dr. Monique Mayer, Western College of Veterinary Medicine, University of Saskatchewan (used under CC BY-NC).

RETROPHARYNGEAL LYMPH CENTRE

The retropharyngeal lymph nodes include a medial retropharyngeal lymph node (*Ln. retropharyngeus medialis*) and, occasionally, a lateral retropharyngeal lymph node (*Ln. retropharyngeus lateralis*).

A. MEDIAL RETROPHARYNGEAL LYMPH NODE

The medial retropharyngeal lymph node (Figure 16: *a*) is an elongated, flattened lymph node on each side of the head, 1.5 to 8.0 cm long, 0.5 to 1.0 cm wide, and 0.5 to 1.0 cm thick, with a lateral and medial side, two blunted margins, and two blunted ends. It lies dorsally on the lateral wall of the pharynx (Figure 16: *12*), immediately caudal to the *M. digastricus* (Figure 16: *14*), and ventromedial to the free edge of the atlas wing, enveloped in fatty connective tissue. The caudal end usually extends to the caudal border of the *M. cricopharyngeus*. The rostral half of the medial retropharyngeal lymph node is located medially to the mandibular gland, and the caudal half is located medially to the *M. sternomastoideus* and *M. cleidomastoideus*, as well as to the ventral branch of the accessory nerve which enters the *M. sternomastoideus*. The medial retropharyngeal lymph node is located laterally to the *M. longus capitis* (Figure 16: *13*) and the pharyngeal muscles (*M. cricopharyngeus* and *thyropharyngeus*) (Figure 16: *12*), as well as the vessels and nerves associated with these muscles (common carotid artery, origin of occipital and internal carotid arteries, pharyngeal and cranial laryngeal branches of vagus nerve, hypoglossal nerve, and sympathetic trunk including the depressor nerve).

In 10 of 47 cases, there were either 2 medial retropharyngeal lymph nodes on both sides or on one side (Figures 8; 16: *a, a'*); in 2 cases on both sides, in 2 cases only on the left side, and in 6 cases only on the right side. When 2 lymph nodes are present, they are observed to be stacked, with the dorsal lymph node (Figure 16: *a'*) always being considerably smaller than the ventral lymph node, rarely more than 1.0 cm in length, even in large dogs. The smaller dorsal lymph node is located on the dorsomedial border of the larger ventral lymph node and does not protrude caudally beyond it.

If the dorsal lymph node is located towards the caudal end of the main ventral node, it may be mistaken for a cranial cervical lymph node; however, on examination of the drainage area, I have shown that this smaller dorsal lymph node is indeed a second medial retropharyngeal lymph node (see cranial cervical lymph node). In rare cases, the main medial retropharyngeal lymph node does not quite extend to the *M. digastricus*. Conversely, if the lymph node is unusually large, it extends to the cranial end of the thyroid gland(s) – in 1 case I examined, the main lymph node reached the dorsomedial margin of the thyroid gland (Figure 10: *a*). In these cases, the caudal end of the lymph node covers the cranial portion of the trachea.

The absolute weight of the lymph node(s) on both sides varied between 0.32 and 21.84 g, and the relative weight between 0.0135% and 0.0691%.

AFFERENT DRAINAGE

The medial retropharyngeal lymph node(s) receive afferent lymph vessels from the skin of the pinna, lymph vessels from the *M. omotransversarius*, *brachiocephalicus*, *sternomastoideus*, *rhomboideus*, *splenius longissimus capitis*, *semispinalis capitis*, *longus colli*, *longus capitis* and *rectus capitis ventralis*, the *Mm. recti capitis dorsales* and *Mm. obliqui capitis*, the *M. sternohyoideus* and *sternothyroideus*, as well as from various head bones (parietal, occipital, temporal, sphenoidal, palatine and mandible), the 1st and 2nd cervical vertebrae, various head muscles (*M. masseter*, *digastricus*, *pterygoideus*, and hyoid muscles), the tongue, the gingiva, the mucous membrane of the free floor of the oral cavity, the hard and soft palate, the tonsil, the parotid, mandibular and sublingual glands, the pharynx and esophagus, the nasal cavity, larynx, thyroid, trachea (initial part) and ear (muscles and labyrinth), the temporomandibular joint and the nervous system, as well as the efferent vessels from the mandibular, parotid and lateral retropharyngeal lymph nodes. If the medial retropharyngeal lymph node is double ([Figures 8; 16: a, a'](#)), then the afferent vessels can drain into both lymph nodes.

As would be expected, if only 1 or 2 afferent lymph vessels are injected, they usually only drain into 1 of the 2 lymph nodes. When a second medial retropharyngeal lymph node is present, all or at least most of the afferent lymph vessels from the neck muscles mentioned above drain into it, reaffirming that this second node is a retropharyngeal lymph node and not a cranial cervical lymph node.

EFFERENT DRAINAGE

Many small efferent vessels emerge from the medial retropharyngeal lymph node, however, these immediately combine to form 3 to 5 larger efferent vessels. These vessels then combine to form the left and right tracheal duct ([Figures 2, 4, 6, 8, 9, 10, 11, 12 and 16: a](#)). One or 2 of these efferent vessels usually drain into a cranial cervical lymph node, if one is present ([Figures 6 and 9: a, b](#)). If there are 2 medial retropharyngeal lymph nodes on top of one another, the efferent vessels of the main lymph node behave as described above. In this case, usually 1 efferent vessel arises from the smaller dorsal lymph node, and either quickly merges with the efferent vessels of the larger ventral lymph node or converges with them to form the tracheal duct ([Figure 16: a'](#)).

B. LATERAL RETROPHARYNGEAL LYMPH NODE

The lateral retropharyngeal lymph node ([Figure 14: s''](#) and [15: u](#)) is a small, rarely double lymphnode that is found in only about a third of all cases (see below). This lymph node lies in the fatty connective tissue ventromedial to the edge of the atlas, on the dorsal border of the mandibular gland, and along the terminal tendon of the *M. sternomastoideus* or on the origin of the *M. digastricus* near the cartilaginous auditory canal (*Cartilago tubae auditivae*). The lymph node is either completely or partially covered by the parotid gland. In the latter case, the lymph node can be observed to protrude slightly beyond the caudal border of the parotid gland ([Figures 14: s''; 15: u](#)). In 39 cases I examined in more detail, 27 dogs had no lateral retropharyngeal lymph node on either side. Of the

remaining 12 cases, 8 dogs had a single lymph node on each side, 2 dogs had 1 lymph node on the right and 2 on the left, 1 dog had 1 lymph node on the left and 2 on the right, and 1 dog had 2 lymph nodes on the right 3 on the left. Most of the lymph nodes were 0.50 to 0.75 cm in size.

AFFERENT DRAINAGE

The lateral retropharyngeal lymph node(s) receive afferent lymph vessels from muscles located on the 1st and 2nd cervical vertebrae (*M. cleidocervicalis*, *sternomastoideus*, *splenius*, *obliqui capitis*, *semispinalis capitis*, *dorsal recti*, *longissimus capitis*, and the muscles of the cervical skin), as well as lymph vessels from the caudal ear muscles and the pinna, and the efferent vessels of the mandibular and parotid lymph nodes. Notably, the lymph vessels draining the skin were never observed to flow into the node.

Based on the drainage area described above, this lymph node evidently corresponds to the lateral retropharyngeal lymph node in cattle, and thus is not a parotid lymph node as reported by Merzdorf [24].

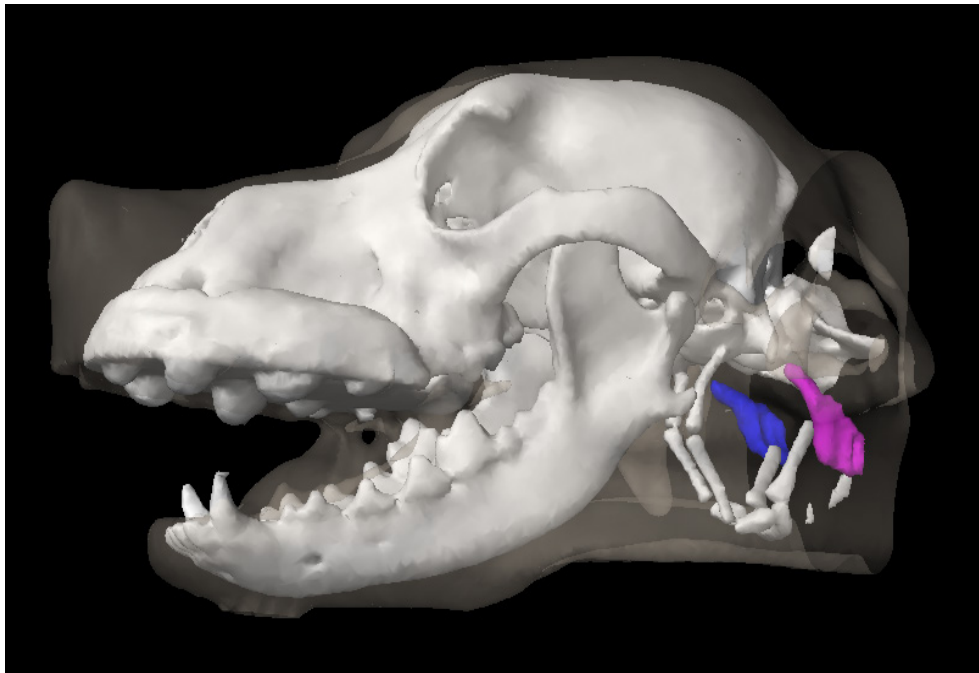
EFFERENT DRAINAGE

One to 2 efferent vessels have been observed to emerge from each lateral retropharyngeal lymph node which drain into the medial retropharyngeal lymph node(s). The lateral retropharyngeal lymph nodes may also receive lymph from the medial retropharyngeal lymph node via retrograde flow.

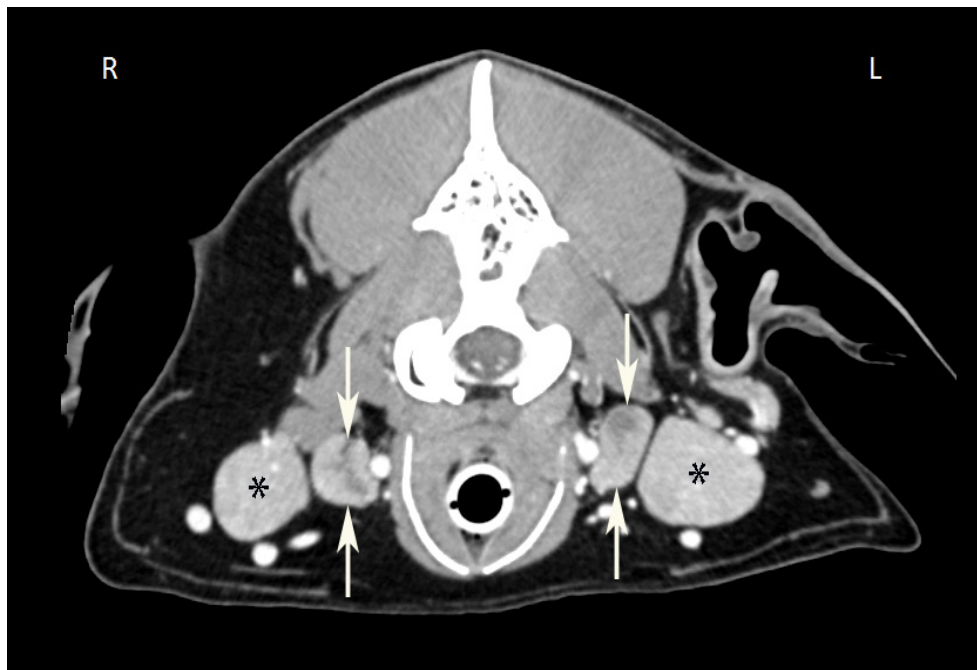CLINICAL NOTES

Medial Retropharyngeal Lymph Nodes

The deep location of the medial retropharyngeal lymph nodes does not allow fine needle aspiration without imaging guidance unless the lymph nodes are markedly enlarged; usually, ultrasound is used to guide the needle tip into the lymph node.



The left (pink) and right (blue) medial retropharyngeal lymph nodes (3D image from a CT scan). Image credit: Dr. Monique Mayer, Western College of Veterinary Medicine, University of Saskatchewan (under CC BY-NC)



Computed tomographic (CT) image of bilaterally enlarged medial retropharyngeal lymph nodes (white arrows), located medial to the mandibular glands (black asterisks). Image credit: Dr. Monique Mayer, Western College of Veterinary Medicine, University of Saskatchewan (used under CC BY-NC).

1.2 LYMPH NODES OF THE NECK

GENERAL

The lymph nodes of the neck are organized into the following lymph centres: superficial cervical (*lymphocentrum cervicale superficiale*) and deep cervical (*lymphocentrum cervicale profundum*). The deep cervical lymph centre is divided into 3 subgroups: the cranial cervical lymph node (*Ln. cervicalis profundus cranialis*), the middle cervical lymph node (*Ln. cervicalis profundus medius*) and the caudal cervical lymph node (*Ln. cervicalis profundus caudalis*).

SUPERFICIAL CERVICAL LYMPH CENTRE

There is a group of superficial cervical lymph nodes ([Figure 13: 3, 3'](#)) on each side of the body, consisting of 2 individual lymph nodes in the majority of cases (16 of 27 dogs examined), though either 1, 3, or 4 lymph nodes may be observed (see below). The lymph nodes are connected to one another and to their surrounding area by loose and usually extremely fatty connective tissue. They lie one above the other, just cranial to the *M. supraspinatus* on the side of the neck. The lymph nodes are quite superficial and are only covered by the outer skin, the superficial fascia (including the *M. cutaneus colli* [Figure 13: c](#)), and the superficial neck muscles, including the *M. trapezius* ([Figure 13: d](#)), *M. brachiocephalicus* ([Figure 13: g](#)), and *M. omotransversarius* ([Figure 13: e](#)). Medially ([Figure 16: d, d', d''](#)), the lymph nodes abut the *M. serratus ventralis* ([Figure 16: 8](#)), the *M. scalenus* ([Figure 16: 9](#)) and *M. longus capitis* ([Figure 16: 13](#)), and usually the trachea and the esophagus (on the left side). The caudal margin and occasionally the medial surface of the lymph nodes border on the omocervical trunk and the superficial cervical vein and artery. Thin branches from these vessels extend over the lymph nodes, separated from them by fatty connective tissue.

The dorsal lymph node ([Figure 13: 3](#)) is usually located just below the skin and the neck fascia, in a triangle formed by the *M. trapezius cervicalis* ([Figure 13: d](#)), *M. brachiocephalicus* ([Figure 13: g](#)) and *M. omotransversarius* ([Figure 13: e](#)). Only the ventral aspect of the lymph node is covered by the *M. omotransversarius*, while the dorsal end usually extends slightly below the *M. trapezius* ([Figure 13: d](#)).

The ventral lymph node ([Figure 13: 3'](#)) is covered by the *M. brachiocephalicus* ([Figure 13: g](#)) and the *M. omotransversarius*. The ventral lymph node often extends so far ventrally ([Figure 16: d'](#)) that the lymphnode, or at least its ventral aspect, is medial to the trachea and, on the left side, the esophagus ([Figure 16: 7](#)), common carotid artery, internal jugular vein, vagus nerve, and sympathetic nerves, including the depressor nerve and the recurrent nerve.

Exceptions to the number of lymph nodes noted in the 27 examined cases include 1 case in which only 1 lymph node was present on each side ([Figure 2: d](#)) and 1 case in which 3 lymph nodes were present

on each side (Figure 16: d, d^1, d^2). Relatively frequently, the number of individual lymph nodes on the left and right side were different; in 2 cases there were 2 lymph nodes on the right and 1 on the left, in 1 case there was 1 on the right and 2 on the left, in 1 case there were 3 on the right and 2 on the left, in 3 cases there were 2 on the right and 3 on the left, and in 2 cases there were 4 on the right (Figure 8: d, d^1, d^2, d^3) and 3 on the left. If 3 lymph nodes are present, they are either stacked on top of one another (as in Figure 16: d, d^1, d^2), or appear as 2 distinct dorsal lymph nodes and 1 ventral lymph node (Figure 9: d, d^1, d^2). In the 1 case in which 4 lymph nodes were present on the right side, there was 1 dorsal, 1 ventral and 2 middle lymph nodes (located one behind the other) (Figure 8: d, d^1, d^2, d^3).

The superficial cervical lymph nodes can be quite large. I found lymph nodes in large dogs that were 7.4 cm long, 3.4 cm wide, and 2.1 cm thick. Their shape is also different (as shown in Figures 2-4, 8-10, 11 and 16: d, d^1, d^2); most of the lymph nodes are oval and somewhat flattened. The absolute weight of the superficial cervical lymph nodes on both sides varied between 0.32 and 83.92 g, the relative weight between 0.0044% and 0.1583%.

AFFERENT DRAINAGE

The superficial cervical lymph nodes receive afferent lymph vessels from: the skin of the caudal part of the dorsal head region, the pinna, the parotid and neck areas, the caudal half of the cranial neck region, the forelimb digits, the metacarpus, carpus and forearm, most of the lateral side of the upper shoulder, upper foreleg region, and the medial side of the humerus region, the anterior thorax, and the cranial part of the ventral thorax. The lymph nodes also often drain the skin of the masseter region, the antebrachial fascia, most of the shoulder muscles (*M. deltoideus, supraspinatus, infraspinatus, teres minor, subscapularis*) as well as the *Mm. interossei* of the forepaw, the extensors and flexors of the 1st and 5th digits, and the tendons of the *M. extensor carpi radialis, extensor digitorum communis* and *lateralis, extensor carpi ulnaris, abductor pollicis longus*, as well as the *M. flexor digitalis sublimis* and *profundus*, most of the trunk limb muscles (*M. trapezius, omotransversarius, brachiocephalic, sternomastoid, rhomboid, serratus ventralis* and the *Mm. pectorales*), the *M. splenius, sternohyoideus* and *sternothyroideus* and the neck skin muscle, all bones of the forelimb, the carpal joint, the forepaw digit joints and the pinna.

If 2 to 3 lymph nodes are present, the lymph vessels from distal to mid-brachium (from the skin, muscles, tendons, fasciae, joints and bones) and the shoulder muscles, usually only drain into the ventral superficial cervical lymph node. The lymph vessels from the neck drain into the dorsal (or both dorsal, if multiple are present) lymph nodes, and the lymph vessels from the ventral neck, the skin of the shoulder, and the brachium region drain into both dorsal and ventral lymph nodes.

EFFERENT DRAINAGE

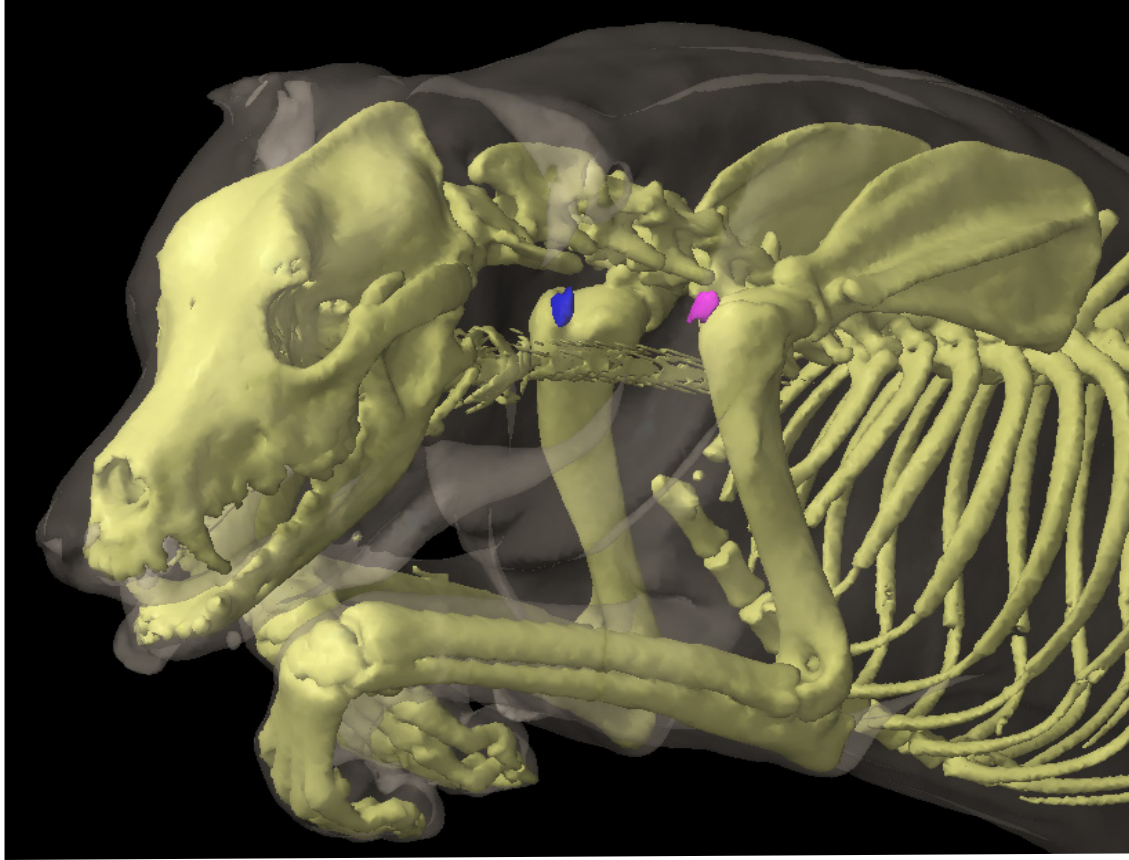
If there is only 1 superficial cervical lymph node (e.g. Figure 2), then 6 to 8 efferent vessels (Figure 2: g) arise from the lymph node, quickly merging to form 1 to 3 vessels that descend over the *M. serratus ventralis* and *scalenus supracostalis*.

On the left side, the efferent vessels either open into the end of the left tracheal duct ([Figure 3: g](#)), into the (frequently bifurcated) end of the thoracic duct ([Figure 5: g](#)), into both the left tracheal duct and the thoracic duct ([Figure 2, Figure 6: g](#)), or adjacent to the thoracic duct directly into the venous system (common jugular vein) ([Figure 7: g](#)). On the right side, the efferent vessels either open into the right tracheal duct ([Figure 8: g](#)), unite with the right tracheal duct to form a short right lymphatic trunk ([Figure 10, Figure 11: h](#)), or, rarely, open directly into the venous system. The drainage patterns of the efferent vessels of the superficial cervical lymph nodes have so many variations that it is almost impossible to describe all of them, though I have attempted to illustrate some of the most common patterns in Figures 2-7, 8-12 and in [Figure 16: d, d', d'', and g](#). If there are several lymph nodes, the 2 to 4 efferent vessels of the dorsal lymph node either enter directly into the ventral lymph node (Figure 9: d^2), or combine to form 1 to 2 vessels, which in turn merge with the efferent vessels of the ventral lymph node, forming 1 to 3 small vessels which show the behaviour described above ([Figure 3, Figure 4: d, d', g](#)).

I also found cases in which some of the efferent vessels of the dorsal lymph node drained into the ventral lymph node while others merged with the efferent vessels of the ventral lymph node (Figure 6: d, d'), and cases in which the efferent vessels of the dorsal lymph node merged into 1 to 2 vessels which flowed directly to the tracheal duct, or towards the thoracic duct and the common jugular vein (Figure 10: d, d'). Some of these drainage patterns are demonstrated in Figures 2-7, 8-11, and in Figure 16: g .

CLINICAL NOTES

The superficial cervical lymph nodes are commonly called the 'prescapular' lymph nodes in the clinic, based on their location cranial to the scapula. Other lymph node groups with common names based on location include the mandibular lymph nodes ('submandibular'; ventral to the mandible) and the medial iliac lymph nodes ('sublumbar'; ventral to the lumbar vertebrae).



Left (pink) and right (blue) normal-sized superficial cervical lymph nodes (3D image from a CT scan). Image credit: Dr. Monique Mayer, Western College of Veterinary Medicine, University of Saskatchewan (used under CC BY-NC).

DEEP CERVICAL LYMPH CENTRE

The deep cervical lymph nodes (Figures 2, 6, 8, 9, 11, 12 and 16: *b*, *b'*, *c*, *c'*) are located on the cervical part of the trachea.

In dogs, in contrast to humans, cattle and horses, the deep cervical lymph nodes are present in sparse numbers, and rarely (3 out of 61 examined dogs) (Figures 4 and 10), absent entirely. If they are present, they can be found along the length of the cervical portion of the trachea. Nevertheless, the deep cervical lymph nodes may be divided into 3 subgroups: the cranial cervical lymph node (Figures 2, 6, 8, 9 and 16: *b*, *b'*), the middle cervical lymph node (Figures 8, 12 and 16: *c'*), and the caudal cervical lymph node (Figures 6, 8, and 16: *c*). These 3 subgroups may not be present in all cases or may not be clearly demarcated if present. Some of the deep cervical lymph nodes are very small, hardly the size of a pinhead, and can easily be missed on macroscopic examination if the efferent vasculature has not been injected. A range of sizes up to 10 mm was observed, and the shapes are the usual round or oval.

A. CRANIAL CERVICAL LYMPH NODES

The cranial cervical lymph node (Figures 2, 6, 8, 9 and 16: *b*, *b'*) is located near the thyroid gland (Figure 16: *I*), and is found in only approximately one-third of dogs, almost always as a single lymph node. If a lymph node is located near the thyroid gland, between the caudal end of the medial retropharyngeal lymph node and the caudal end of the thyroid gland, I refer to it as a cranial cervical lymph node. More specifically, the lymph node is either on the dorsomedial border of the thyroid gland adjacent to the trachea and common carotid artery (Figure 2: *b*), or on the craniodorsal aspect of the thyroid gland, between the thyroid gland and the medial retropharyngeal lymph node (Figure 16: *b*). In the latter case, the cranial cervical lymph node can be found proximate to the pharynx and may even reach the medial retropharyngeal lymph node or overlap it; in these cases, it can be difficult to determine whether the lymph node is a medial retropharyngeal lymph node or a cranial cervical lymph node. I would determine a lymph node in this location to be a cranial cervical lymph node because I have observed in many cases that lymph vessels draining to the medial retropharyngeal lymph node when the cranial cervical lymph node is absent do not drain into the cranial cervical lymph node when it is present. At times, a cranial cervical lymph node lying at the caudal end of the thyroid gland (Figure 11: *b*) may not be clearly demarcated from the middle cervical lymph node, if present.

The cranial cervical lymph node is absent in most dogs (Figures 4 and 10). It was not found in 45 of 64 cases examined. In the 19 cases in which it was found, there was 1 lymph node on each side (Figures 2 and 16: *b*) in 12 cases, 1 lymph node on the left in 1 case, 1 lymph node on the right in 3 cases, 1 lymph node on the left and 2 lymph nodes on the right in 1 case (Figure 9: *b*, *b'*), and 2 lymph nodes on both sides in 2 cases (Figures 6, 8 and 11: *b*, *b'*).

The accessory thyroid glands or the external parathyroid glands may be confused with the cranialcer-

vical lymph node. Microscopic examination will confirm identification, but as the accessory thyroid glands and parathyroid glands lack efferent vessels, injection into the structure to see if it has efferent vessels will determine if it is indeed a lymph node.

AFFERENT DRAINAGE

The cranial cervical lymph node receives afferent lymph vessels from the larynx, thyroid, trachea, and esophagus, and drains the efferent vessels of the medial retropharyngeal lymph node.

EFFERENT DRAINAGE

One to 2 efferent vessels arise from the lymph node, and merge with the left or right tracheal duct (see tracheal duct and Figures 2, 16: *b*). If there are 2 cranial cervical lymph nodes present, then the efferent vessels of the more caudal lymph node merge with the tracheal duct (Figures 6, 8, 9, 11), while the efferent vessels of the cranial lymph node either open into the caudal lymph node (Figure 6: *b*), drain into the tracheal duct (Figure 8: *b*), or show both of the aforementioned behaviours (Figure 9: *b*).

B. MIDDLE CERVICAL LYMPH NODES

A middle cervical lymph node (Figures 8, 12, 16: *c'*; 23: 3), i.e. a lymph node located caudal to the thyroid gland in the central part of the neck near the trachea, was only found in 4 of 50 cases; in 1 case on both sides, in 1 case on the left, in 1 case on the right and 1 case on the ventral aspect of the trachea. In 2 cases, the lymph node was very small, no more than 2 to 3 mm in size, whereas in the other 2 cases, it was 3 to 5 mm in size. These small lymph nodes can be easily missed if the afferent vessels are not injected (see tracheal duct).

AFFERENT DRAINAGE

The middle cervical lymph node receives afferent lymph vessels from the thyroid, trachea and esophagus.

EFFERENT DRAINAGE

On average, 1 efferent vessel arises from the lymph node, coursing caudally alongside the trachea and draining into either the caudal cervical lymph node (Figures 8, 16: *c'*, *c*; 23: 3, 4), the end of the thoracic duct, the right lymphatic duct, the tracheal duct (Figure 12: *c'*), or into a cranial mediastinal lymph node.

C. CAUDAL CERVICAL LYMPH NODES

The caudal cervical lymph node (Figures 6, 8, 16: c; 23: 4) is also absent in the majority of cases, and in 39 of 56 examined cases, it could not be detected at all. In the 17 cases in which the lymph node was present, it was located at the caudal end of the cervical trachea within 4 cm cranial of the neck of the 1st rib, covered by the anterior neck muscles (*M. sternohyoideus*, *sternothyroideus* and *brachicephalicus*). Of the 17 cases with a lymph node present, there was 1 unpaired lymph node on the ventral side of the trachea (11 cases), 1 lymph node on each side of the trachea (2 cases), 1 lymph node on the left side and 1 lymph node on the ventral side of the trachea (1 case), or either 3 (2 cases) or 4 (1 case) consecutive lymph nodes on the ventral side of the trachea. In the case of 4 lymph nodes, all of which were only 1.5 to 2.5 mm in size, the cranial lymph node may instead have been a middle cervical lymph node, as the demarcation between the two subgroups is minimal. In another case, the lymph node found was only the size of a pinhead – so small that it could easily have been overlooked (see cranial cervical lymph nodes, above).

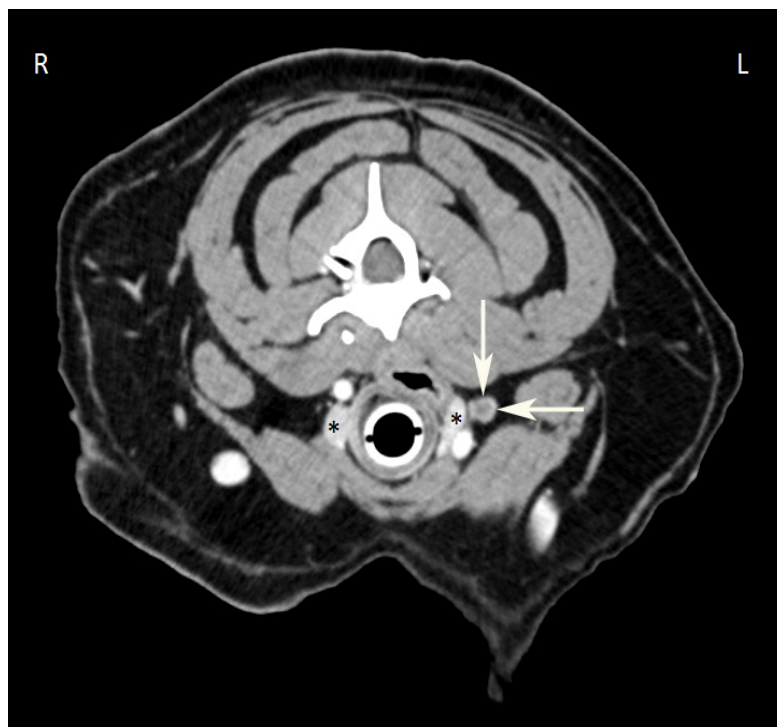AFFERENT DRAINAGE

If the caudal cervical lymph node(s) are present, some of the lymph vessels that would typically enter the thoracic cavity and drain to the mediastinal lymph node instead drain into the caudal cervical lymph node(s). These include lymph vessels draining muscles such as the *M. splenius*, *sternohyoideus*, *sternothyroideus*, *sternocostalis*, *scalenus*, *serratus ventralis*, *longus colli*, *longus capitis*, and more. However, not all the lymph vessels draining these muscles enter the caudal cervical lymph node(s); some bypass it and drain into the mediastinal lymph node. Direct drainage into the caudal cervical lymph node(s) was observed for the last 5 to 6 cervical vertebrae, the thyroid, trachea and esophagus, and the efferent vessels of the middle cervical lymph node(s).

EFFERENT DRAINAGE

Each caudal cervical lymph node has 1 to 2 efferent vessels. If there is more than 1 lymph node, the efferent vessel of the most cranial lymph node usually drains into the lymph node caudal to it, and only the efferent vessel of the most caudal lymph node (or if there is only one lymph node, the efferent vessel from it), opens either into the end of the thoracic duct (Figure 6: c), into the right lymphatic trunk (on the right side) (Figure 8: e), into the end of the tracheal duct, or into a cranial mediastinal lymph node (Figures 16: c, l; 23: 4, 6). In the latter case, the efferent vessels often form extensive networks.

CLINICAL NOTES



Contrast-enhanced computed tomographic (CT) image of an enlarged left deep cervical lymph node (arrows). The thyroid gland (asterisks) is visible on this slice. The blood vessels appear white due to iodinated contrast. The atomic number of an element determines its density on CT, and iodine has an atomic number (Z) equal to 53 (soft tissue has an effective atomic number of around 7). The thyroid gland is also hyperdense (white) compared to other soft tissue structures because it accumulates iodine. Image credit: Dr. Monique Mayer, Western College of Veterinary Medicine,

University of Saskatchewan (used under CC BY-NC).

1.3 LYMPH NODES OF THE FORELIMB

GENERAL

There is usually only one forelimb lymph node, the axillary lymph node (*Ln. axillaris*). Occasionally, a second lymph node can be found, usually located on the lateral thoracic wall in the 3rd intercostal space, which, based on its drainage region, is simply an extension of the axillary lymph node (see axillary lymph node); therefore I have named this lymph node the accessory axillary lymph node (*Ln. axillaris accessorius*).

AXILLARY LYMPH NODES

The axillary lymph node (Figures 16: e; 36: d) is almost always a single lymph node; in 29 out of 33 cases I found only 1 lymph node, and in 4 cases there were 2 lymph nodes: 1 lymph node on each side (1 case), 2 on the left side (1 case), and 2 on the right side (2 cases). The length of the main lymph node varied between 0.3 and 5 cm, the width between 0.2 and 5 cm, and the thickness between 0.2 and 1.7 cm. The lymph node usually has an almost round shape and is relatively flattened.

The axillary lymph node lies in abundant fatty tissue on the medial side of the shoulder at the level of the shoulder joint, however, depending on the size of the dog, it may be found 2 to 5 cm caudal from the shoulder joint in the triangle formed by the subscapular and brachial arteries and veins. The lateral surface of the lymph node abuts the *M. teres major* (Figure 36: 2), and the medial surface of the lymph node abuts the *M. pectoralis profundus*, but most commonly the *M. transversus costarum* near the *M. scalenus supracostalis* at the level of the 1st intercostal space or the 2nd rib (Figure 16: e). The lymph node is therefore enclosed between the *M. teres major* on one side and the *M. transversus costarum* and *M. pectoralis profundus* on the other side. The caudal pectoral nerve, frequently divided, runs over either the medial surface or ventral border of the lymph node, and the thoracodorsal artery and vein run along the dorsal border of the lymph node.

The absolute weight of the lymph node on both sides fluctuated between 0.09 and 36.82 g, and the relative weight between 0.0012% and 0.0695%.

AFFERENT DRAINAGE

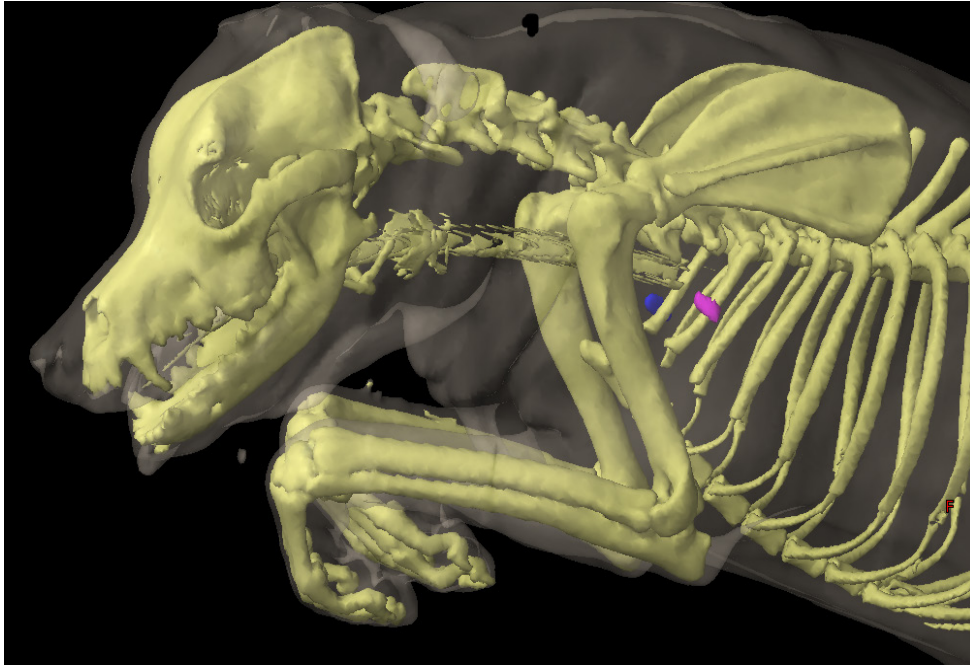
The axillary lymph node(s) drain the lymph vessels from the skin of the region of the dorsal, lateral, and ventral thoracic and abdominal wall located between the shoulder muscles and a transverse plane at the level of the last rib, from the skin on the lateral side of the shoulder, the brachium and the olecranon, lymph vessels from the antebrachial fascia, all muscles of the forelimb and their tendons, as well as the *M. trapezius*, *brachiocephalicus*, *latissimus dorsi* and *pectoralis profundus*, and the abdominal muscles. The axillary lymph node also drains the lymph vessels from nearly all bones of the forelimb (with

the exception of the phalanges, and the shoulder, elbow and carpal joints), the mammary gland, and the efferent vessels of the accessory axillary lymph node.

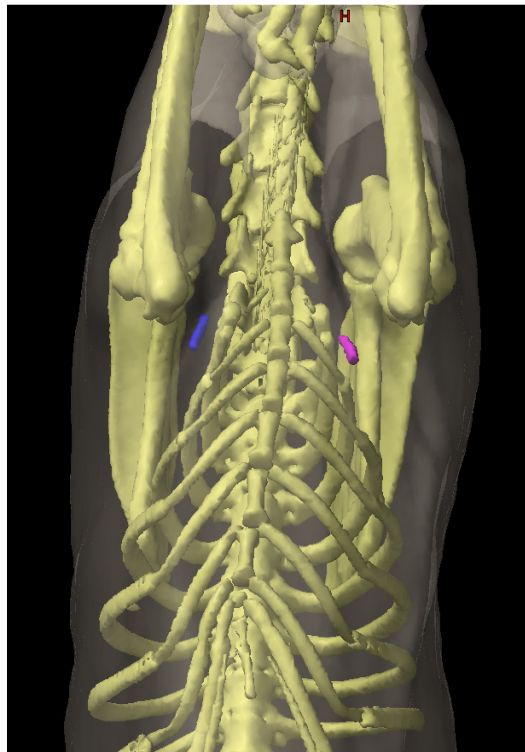
EFFERENT DRAINAGE

Four to 5 efferent vessels emerge from the lymph node, and almost always quickly merge to form a single larger vessel ([Figure 16: e](#)). This larger vessel, often forming large dilations, runs cranioventrally over the *M. transversus costarum* to the 1st rib, where it crosses the medial side of the axillary vein at its origin, and then the lateral side of the initial part of the common jugular vein, often bifurcating into 2 to 3 terminal branches. On the left side, the vessel – or its terminal branches – drain into the thoracic duct or one of its terminal branches, directly into the external jugular vein, or into the end of the left tracheal duct. On the right side, the vessel – or its terminal branches – drain into the end of the right tracheal duct, the right lymphatic trunk or one of its terminal branches, or directly into the end of the external jugular vein. The terminal drainage is therefore highly variable; some of these variations for the left side are shown in [Figures 3, 5](#), and [16: e](#), and for the right side in [Figures 9 and 10: e](#). If there are 2 axillary lymph nodes ([Figures 7: e, e¹; 16: e](#)), some of the 2 to 3 efferent vessels of the caudal lymph node open into the cranial lymph node, and some merge with the efferent vessels of the cranial lymph node.

CLINICAL NOTES



Left (pink) and right (blue) normal-sized axillary lymph nodes on a left oblique view (3D image from a CT scan). Image credit: Dr. Monique Mayer, Western College of Veterinary Medicine, University of Saskatchewan (used under CC BY-NC).



Left (pink) and right (blue) normal-sized axillary lymph nodes on a ventral oblique view (3D image from a CT scan). Image credit: Dr. Monique Mayer, Western College of Veterinary Medicine, University of Saskatchewan (used under CC BY-NC).

ACCESSORY AXILLARY LYMPH NODES

The accessory axillary lymph node ([Figures 13: 4; 16: e'](#)) is a relatively small, infrequent lymph node. It was found in only 10 of 43 cases: 6 times on both sides, 3 times only on the right, and 1 time only on the left. The lymph node was always found alone. It is located 4 to 8 cm dorsal to the olecranon, just dorsal to the *M. pectoralis profundus* and just ventral to the *M. latissimus dorsi*, close to the angle formed between them at the caudal border of the muscles of the shoulder and brachium on the 3rd and 4th ribs, most often in the 3rd intercostal space.

The lymph node is covered only by the skin and the *M. cutaneous trunci* (Figure 13: *m*), although in rare cases, it is located on the medial side of the *M. latissimus dorsi*.

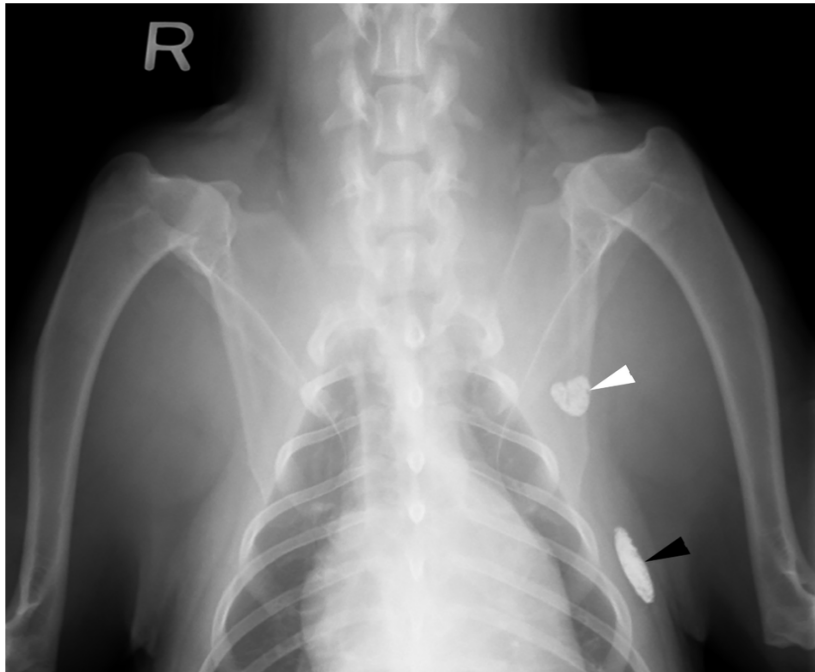
AFFERENT DRAINAGE

The accessory axillary lymph node drains the lymph vessels of the skin on the lateral and ventral thoracic wall and on the caudal aspect of the lateral and medial side of the humerus and olecranon, the lymph vessels from the *M. cutaneous trunci*, the *M. pectoralis profundus*, and from the mammary gland. If the accessory axillary lymph node is absent, the afferent vessels from the aforementioned structures drain directly to the axillary lymph node, providing evidence that the accessory axillary lymph node is associated with the axillary lymph node. This is in contrast to Merzdorf [24], who named this lymph node the cubital lymph node. Based on its location, the accessory axillary lymph node in dogs may be compared to the infraspinous lymph node in cattle, although the lymph node in cattle has a completely different drainage region than the lymph node in dogs.

EFFERENT DRAINAGE

The efferent vessels from the accessory axillary lymph node merge to form 2 to 3 vessels (Figure 16: *e, e'*), which form anastomoses among themselves, and drain into the axillary lymph node.

CLINICAL NOTES



Contrast uptake in the left axillary (white arrowhead) and accessory axillary (black arrowhead) lymph nodes on a ventrodorsal radiograph of the cranial thorax in a healthy dog. Image credit: Dr. Monique Mayer, Western College of Veterinary Medicine, University of Saskatchewan (used under CC BY-NC).

1.4 LYMPH NODES OF THE PELVIC LIMB

GENERAL

This section describes the lymph nodes of the pelvic limb, excluding the pelvis but including the ventral pelvic wall and portions of the ventral abdominal wall.

The lymph nodes of the pelvic limbs include the popliteal lymph node (*Ln. popliteus*), the inconstant medial femoral lymph node (*Ln. femoralis medialis*), and the superficial inguinal lymph nodes (*Lnn. inguinales superficiales*). The deep inguinal lymph node (*Ln. inguinalis profundus*) is located within the abdominal cavity and is therefore included with the lymph nodes of the abdominal cavity wall (see lymph nodes of the abdominal wall).

POPLITEAL LYMPH NODES

The popliteal lymph node ([Figure 13: 5](#)) is almost always a single lymph node, as 2 popliteal lymph nodes on the right side were found in only 1 of 37 cases. In large dogs, the popliteal lymph node can reach a length of 5.0 cm, a width of 3.4 cm, and a thickness of 1.4 cm.

The location of the lymph node is just as constant as its quantity. It lies in the caudal aspect of the stifle joint between the *M. biceps femoris* and *M. semitendinosus* ([Figure 13: p, q](#)), on the caudal surface of the *M. gastrocnemius* ([Figure 16](#)), and is usually within an ample amount of fatty tissue. Since the lymph node usually protrudes slightly caudally over the *M. biceps femoris* and *M. semitendinosus* (shown in [Figure 13](#)), the lymph node, together with the fat pad between the two muscles, comes into direct contact with the skin.

The absolute weight of the lymph node on both sides varied between 0.04000 and 19.07 g, the relative weight between 0.0007% and 0.036%.

AFFERENT DRAINAGE

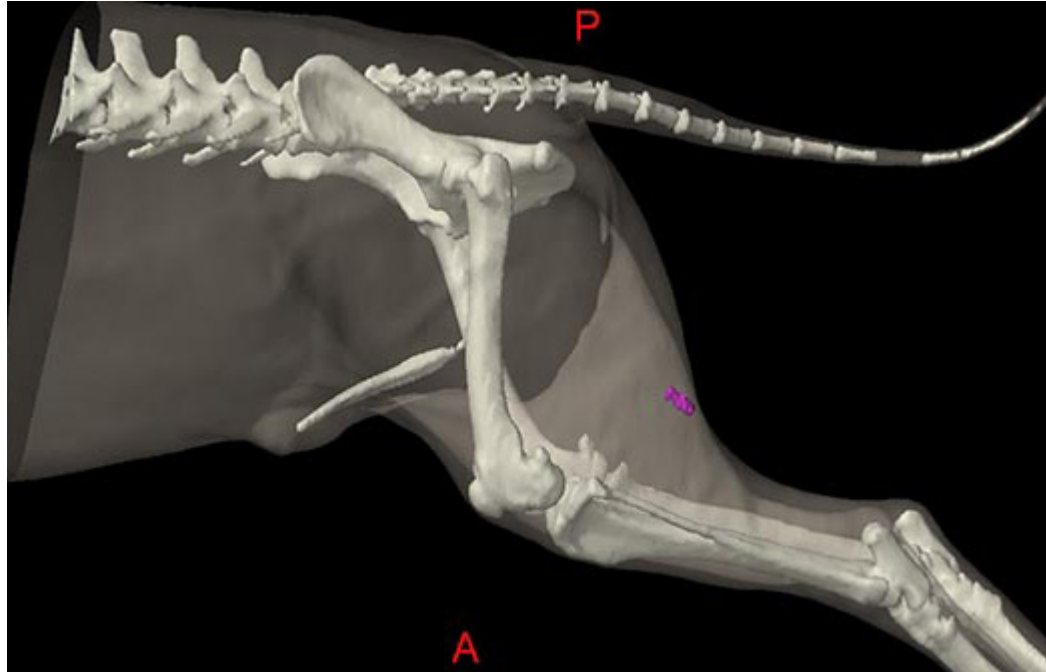
The popliteal lymph node drains lymph vessels from the skin of the caudal half of the lateral side of the stifle joint and lower leg, the lateral, flexor, and extensor aspects of the tarsus, the skin of the metatarsus and the hind digits, the lymph vessels from the fascia cruris, the tibia, the fibula, the tarsal and metatarsal bones, the phalanges of the toes, the tarsal joint and the interphalangeal joints, the lymph vessels from the *M. biceps*, *semitendinosus*, *semimembranosus*, *quadriceps*, *extensor digitalis pedis brevis*, and the *Mm. interossei*, and the lymph vessels from the tendons of the *M. tibialis anterior*, *extensor digitalis pedis longus* and *lateralis*, *peroneus longus*, *gastrocnemius*, and *flexor digitalis pedis sublimis* and *profundus*.

EFFERENT DRAINAGE

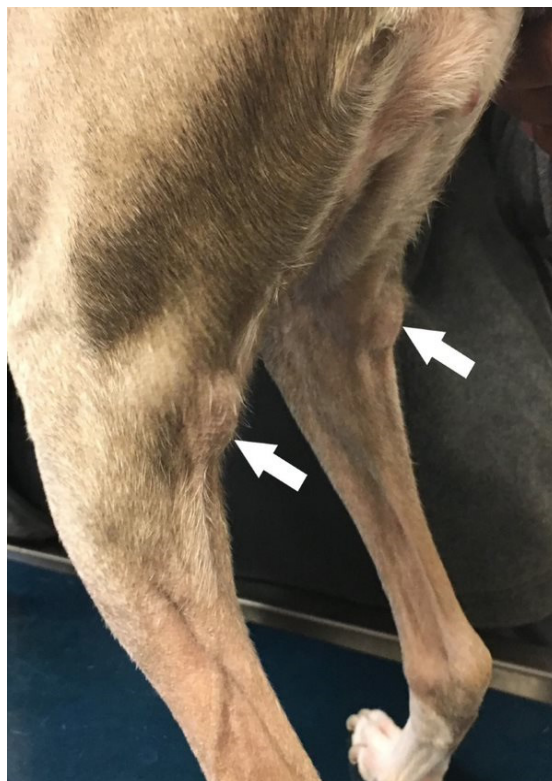Eight to 10 efferent vessels emerge from the popliteal lymph node ([Figure 34: a'](#)) and, accompanied by the small saphenous vein, run along the medial side of the *M. biceps* and *gastrocnemius* to the caudal aspect of the stifle joint, forming networks and finally merging to form 2 to 4 vessels. These vessels then travel medially, just above the origin of the *M. gastrocnemius*, in the angle between the *M. semimembranosus*, the *M. adductor*, and the femur, through the femoral canal to the medial iliac lymph node. If either a medial femoral lymph node or deep inguinal lymph node is present, one of the efferent vessels usually enters it.

In one case where a left popliteal lymph node was observed, in addition to the efferent vessels described above, I found another efferent vessel that arose directly under the skin at the border between the *M. biceps* and *semitendinosus*, entered the pelvic cavity and drained into the left medial sacral lymph node. This left medial sacral lymph node drained to the hypogastric lymph nodes and then, via the efferent vessels of the hypogastric node, to both medial iliac lymph nodes. In this pattern, lymph from the left popliteal lymph node drained into the left medial sacral lymph node, the hypogastric lymph nodes, and both of the medial iliac lymph nodes.

CLINICAL NOTES



Left normal-sized popliteal lymph node (pink) on the caudal aspect of the stifle joint (3D image from a CT scan). Image credit: Dr. Monique Mayer, Western College of Veterinary Medicine, University of Saskatchewan (used under CC BY-NC).



Rear limbs of a canine patient diagnosed with multicentric lymphoma. The right and left popliteal lymph nodes (arrows) are markedly enlarged. Image credit: Dr. Samuel Hocker, Kansas State University (used under CC BY-NC).

MEDIAL FEMORAL LYMPH NODES

A medial femoral lymph node ([Figures 13: t; 37: e](#)) has not been previously described, and is uncommon: it was found only 5 times in 40 examined cases. It was found once on both sides, once on the left side, and 3 times on the right side. It is a small lymph node, often no more than 1 cm long in large dogs and usually only 2 to 3 mm in length in small dogs.

It is found on the medial side of the thigh, at the distal end of the femoral canal, medial to the distal end of the *M. pectineus* or *M. adductor*, between the *M. sartorius* and *M. gracilis*, and in the fatty connective tissue under the fascia on the caudal border of the femoral vessels.

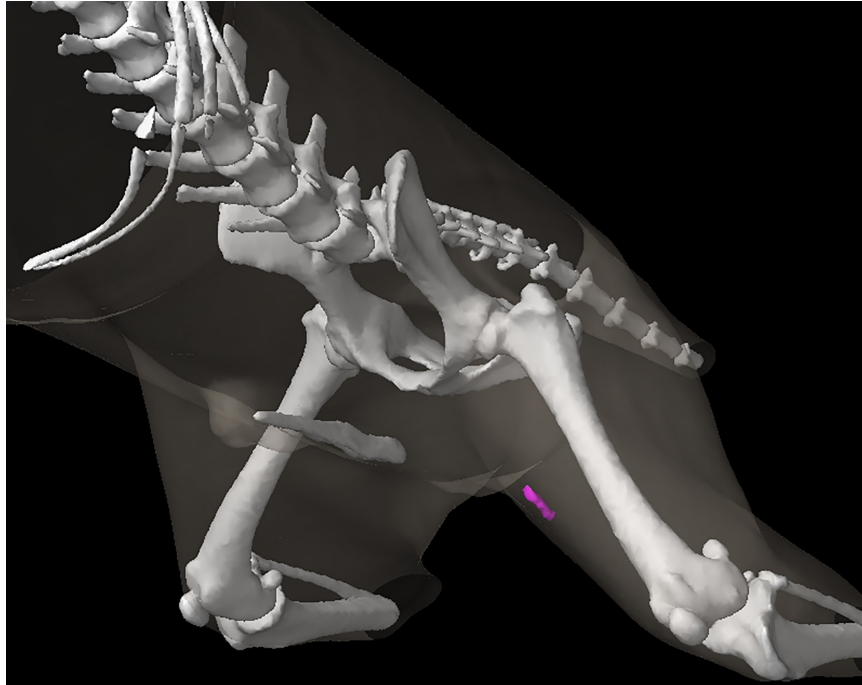
AFFERENT DRAINAGE

The medial femoral lymph node drains lymph vessels from the skin on the medial side of the stifle joint, the lower leg and the foot, the *fascia cruris*, the stifle and tarsal joints, the patella, the tibia, the tarsal and metatarsal bones, the Achilles, the superficial and deep flexor tendons, the *Mm. interossei pedis* and *M. extensor digitalis pedis brevis*, as well as the efferent vessels of the popliteal lymph node. However, it is not uncommon for the described lymph vessels to not enter the medial femoral lymph node even when it is present.

EFFERENT DRAINAGE

One to 2 efferent vessels arise from the lymph node and ascend within the femoral canal to drain into the medial iliac lymph node ([Figures 37: e'; 27: II](#)). A deep inguinal lymph node was not present in the examined cases.

CLINICAL NOTES



Left normal-sized medial femoral lymph node (pink) on the medial thigh (3D image from a CT scan). Image credit: Dr. Monique Mayer, Western College of Veterinary Medicine, University of Saskatchewan (used under CC BY-NC).

SUPERFICIAL INGUINAL LYMPH NODES

A. SUPERFICIAL INGUINAL LYMPH NODES OF MALE DOGS

The superficial inguinal lymph nodes of male dogs (Figures 31, 32: 4) form a group of 1 to 3 (usually 2) lymph nodes on each side, which lie in the very fatty subcutaneous tissue on the dorsolateral edge of the penis, between the penis and the ventral abdominal wall, 0.5 to 1.0 cm cranial from the spermatic cord. The lymph nodes lie along the cranial border of the medial surface of the *M. gracilis*, and ventral to the aponeurosis of the *M. obliquus externus abdominis*.

A different number of lymph nodes on the right and left sides were often observed. The size of the lymph nodes is highly variable: they were 5 mm to 6.8 cm in length, 2.5 cm in width, and 1.5 cm in thickness.

The position of the superficial inguinal lymph node(s) in relation to the external pudendal artery and vein, which run through the fat surrounding the lymph nodes, is as follows: if there is 1 lymph node, it is located medial to the vessels, between the vessels and the ventral abdominal wall, and protrudes cranially and caudally over the vessels. If there are 2 lymph nodes, 1 is almost always located on the cranial border of the vessels and the second on the caudal border of the vessels, so that the vessels pass (in the craniomedial direction) between both lymph nodes. More infrequently, 1 lymph node may be medial to the vein and the other caudal to it. If there are 3 lymph nodes, 1 is cranial to the external pudendal artery and vein, and the other 2 lie immediately adjacent to one another, caudal to the vessels. One of the 2 caudal lymph nodes may be located medial to the spermatic cord. The cranial lymph node may be located more deeply, while the caudal lymph nodes are located more superficially.

The absolute weight of the lymph nodes on both sides varied between 0.02 g and 23.23 g, the relative weight between 0.0003% and 0.0719%.

EFFERENT DRAINAGE

The superficial inguinal lymph nodes on one side are usually connected to one another by efferent vessels (Figure 31: 7). In addition, the efferent vessels of the individual lymph nodes will merge to form 1 to 2 larger vessels, which run caudodorsally over the medial surface of the spermatic cord, accompanying the external pudendal artery and vein, eventually entering the abdominal cavity along the external iliac artery and vein, and finally draining into the medial iliac lymph node (Figures 31: 1; 27: 11). If a deep inguinal lymph node (Figure 27: 8) is present, some or all the efferent vessels enter this lymph node.

B. SUPERFICIAL INGUINAL LYMPH NODES OF FEMALE DOGS (LNN. SUPRAMAMMARI, MAMMARY LYMPH NODES, FIGURE 30: 1)

Of 7 bitches examined, 4 had only 1 superficial inguinal lymph node on each side, 2 had 2 lymph nodes on each side, and 1 had 2 lymph nodes on the right side and 1 lymph node on the left side. In large dogs, the lymph nodes are up to 1 to 2 cm long, up to 1 cm wide, and up to 0.5 cm thick.

Depending on the size of the dog, the lymph nodes on each side lie 2 to 4 cm cranial to the *pecten ossis pubis* and 1 to 1.25 cm lateral to the *linea alba*, and are therefore located between the ventral abdominal wall, the mammary tissue, and the skin of the ventral abdominal wall, close to the region where the skin of the ventral abdominal wall becomes the skin of the medial surface of the thigh. The external pudendal artery and vein, running in the cranial direction, usually lie along the lateral border of the lymph node. If there are two lymph nodes on one or both sides, they are then either located immediately adjacent to one another, or one is lateral and one is medial to the aforementioned vessels. The lateral lymph node usually then extends to the lateral edge of the mammary tissue and often protrudes slightly beyond it.

The absolute weight of the lymph nodes on both sides varied between 0.15 g and 1.16 g, and the relative weight between 0.0012% and 0.0178%.

EFFERENT DRAINAGE

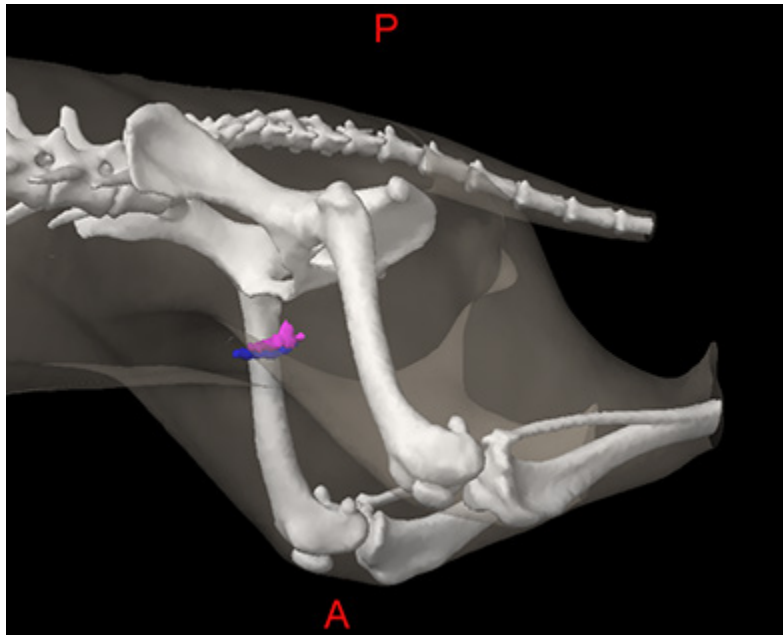
The efferent vessels in the female dog behave essentially the same as in the male. From each lymph node, they merge to form 1 to 2 larger vessels that enter the abdominal cavity with the external pudendal artery and vein (Figure 27: 11) and then accompany the external iliac artery and vein to drain to the medial iliac lymph nodes (Figure 27: 4²). If a deep inguinal lymph node is present (Figure 27: 8), then all or some of the efferent vessels open into it (Figure 27: 11').

AFFERENT DRAINAGE IN BOTH MALES AND FEMALES

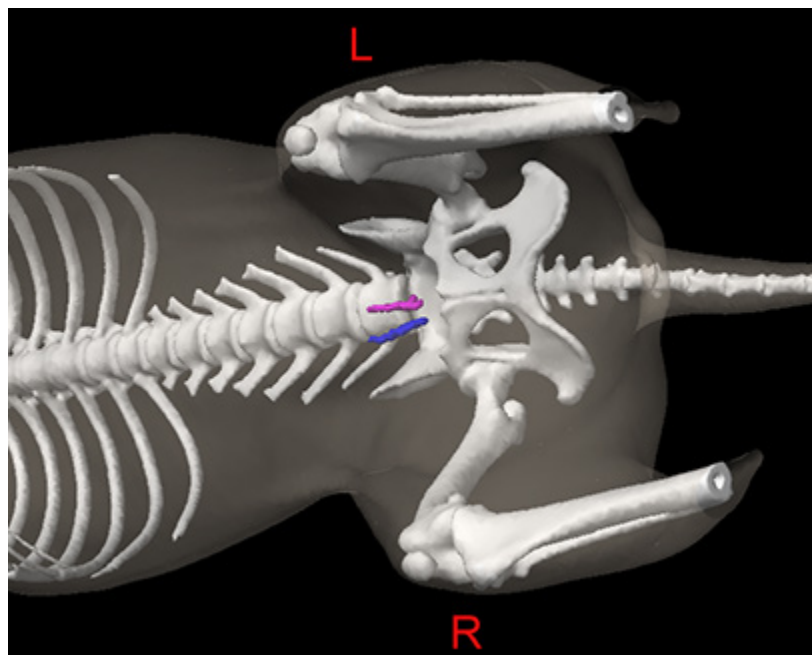
The superficial inguinal lymph nodes drain lymph vessels from the skin of the ventral half of the portion of the abdominal wall located caudally from a transverse plane at the level of the last rib, including the lymph vessels of the skin of the prepuce and scrotum, the skin of the mammary gland, the skin of the caudal part of the pelvis, and of the tail, the lateral and medial sides of the thigh, the medial side and the cranial half of the lateral side of the stifle joint, the medial side and the cranial half of the lateral side of the lower leg (including the anterior border), the medial, the flexor, and the extensor sides of the tarsus, metatarsus, and digits, the lymph vessels of the abdominal skin muscles, the lymph vessels of the vulva, clitoris, and mammary glands, the scrotum, prepuce, and penis (including glans), and finally the lymph vessels of the male urethra.

CLINICAL NOTES

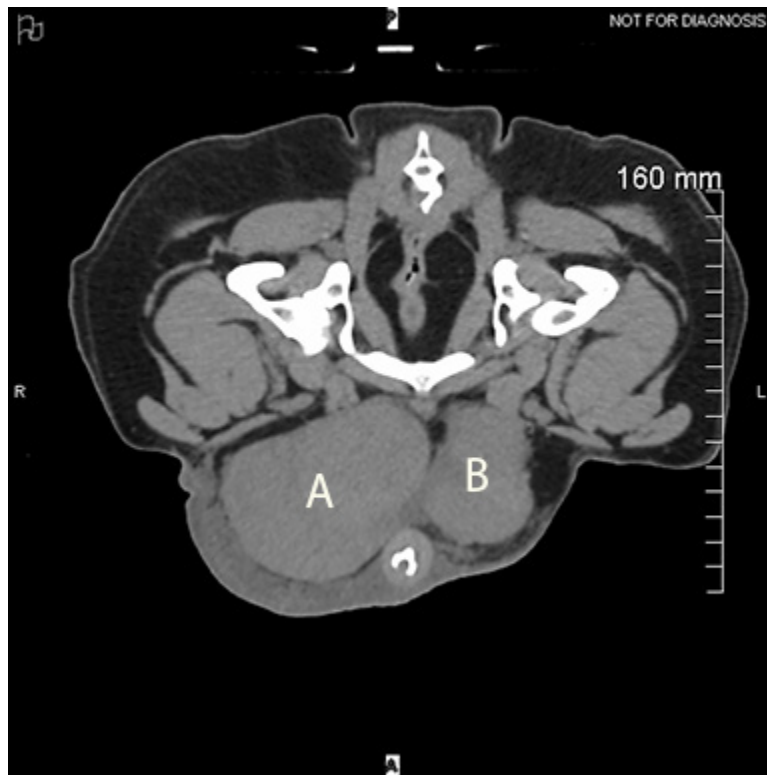
The superficial inguinal lymph nodes on each side are usually connected to one another by efferent vessels.



Left (pink) and right (blue) normal-sized superficial inguinal lymph nodes, lateral oblique view (3D image from a CT scan). Image credit: Dr. Monique Mayer, Western College of Veterinary Medicine, University of Saskatchewan (used under CC BY-NC).



Left (pink) and right (blue) normal-sized superficial inguinal lymph nodes, ventral oblique view (3D image from a CT scan). These lymph nodes are located close to the ventral midline and are easy to find on computed tomographic (CT) scans, because they are soft tissue dense structures surrounded by hypodense fat. Image credit: Dr. Monique Mayer, Western College of Veterinary Medicine, University of Saskatchewan (used under CC BY-NC).



Computed tomographic (CT) image of markedly enlarged right (A) and left (B) superficial inguinal lymph nodes containing metastatic disease in a male dog. Image credit: Dr. Monique Mayer, Western College of Veterinary Medicine, University of Saskatchewan (used under CC BY-NC).

1.5 LYMPH NODES OF THE THORAX AND ASSOCIATED ORGANS

GENERAL

The thoracic lymph nodes (*Lnn. thoracis*) are divided into the dorsal thoracic lymph centre (*lymphocentrum thoracicum dorsale*), which includes the intercostal lymph nodes (*Lnn. intercostales*) that are attached to the dorsal thoracic wall near the costovertebral joints, and the ventral thoracic lymph centre (*lymphocentrum thoracicum ventrale*), which includes the sternal lymph nodes (*Lnn. sternales*) that are attached to the ventral thoracic wall on the sternum, near the internal mammary artery and vein.

In contrast to cattle (see Baum [6] pages 26 and 27), both of the lymph node groups are uncommon in the dog. The intercostal lymph nodes were absent in most dogs, and, when they were present, were always found to be a single lymph node on one side, while the sternal lymph nodes were usually only found as 1 lymph node on each side. Therefore, both groups should be addressed individually. The lymph nodes of the thoracic organs are also much less numerous than in cattle. In dogs, only the mediastinal and bronchial lymph centres (*lymphocentrum mediastinale* and *bronchale*) are found, with the former consisting only of a single group of lymph nodes, the cranial mediastinal lymph nodes (*Lnn. mediastinales craniales*).

INTERCOSTAL LYMPH NODES

The intercostal lymph node (Figures 17: g, 18: 9) was found in only 14 of 54 cases: in 5 cases on the left side, in 7 cases on the right side, and in 2 cases on both sides. In all cases, it was found as a single lymph node. It was found either in the 5th or 6th intercostal space, near the costovertebral joint, or directly at the 6th costovertebral joint, underneath the pleura, in the fat on the intercostal artery and vein, and on the right side, just dorsal to the azygos vein (Figure 18: h). The size of the lymph node ranged from 2 to 7 mm.

AFFERENT DRAINAGE

If an intercostal lymph node is present, it usually drains some of the lymph vessels that pass through the last 6 to 8 intercostal spaces into the thoracic cavity and run cranial along the thoracic vertebrae and the *M. longus colli* to the cranial mediastinal lymph node. The intercostal lymph nodes also drain some of the lymph vessels from the *M. subscapularis*, *longissimus dorsi*, *ileocostalis*, *trapezius*, and *rhomboideus thoracalis*, as well lymph vessels from the *M. latissimus dorsi*, *serratus ventralis*, *obliquus abdominis externus* and *internus*, *transversus abdominis*, *serratus dorsalis inspiratorius*, *spinalis* and *semispinalis dorsi* and *cervicis*, the *Mm. intercostales*, the ribs and the scapula, and also the lymph vessels from the pleura, the aorta, the thoracic vertebrae, and the nervous system.

EFFERENT DRAINAGE

One to 3 efferent vessels emerge from the intercostal lymph node, running cranioventrally on the *M. longus colli*, forming networks of vessels that delimit large islands, and terminating upon draining into a cranial mediastinal lymph node (see [Figures 17](#) and [18](#)).

STERNAL LYMPH NODES

The sternal lymph nodes are shown in [Figures 17: c](#), [18: 6](#), and [19: 2](#). As previously mentioned, the ventral thoracic lymph centre usually consists of a single sternal lymph node on each side. This lymph node can be unpaired and then is found either on one side or in a median location. Rarely, the lymph node is either absent, or 2 are found on one side. In 35 examined cases, there was 1 lymph node on each side in 21 cases, 1 on the right side in 4 cases, 1 on the left side in 3 cases, an unpaired median lymph node in 3 cases, 2 laying above one another on the left side in 2 cases and on the right side in 1 case, and in 1 case absent entirely.

When a lymph node is present on either side, it is found just cranial to the *M. transversus thoracis*, immediately medial to either the 2nd costal cartilage or the 2nd inter-cartilage space, enclosed in fat, and on the cranioventral border of the internal mammary artery and vein on the sternum (or between the artery and the sternum), filling the space between them with its associated fat. When a single lymph node is present, it may be on either side in the location described above, or it may be located in the middle, ventromedial to the bilateral internal mammary artery and vein, and on a transverse plane at the level of the 2nd costal cartilage or the 2nd inter-cartilage space. If there are 2 lymph nodes stacked one behind the other on one side, they are both in the location described above, but the caudal lymph node may additionally lie between the internal mammary artery and vein.

The size of the lymph nodes varies between 3 and 20 mm in length. The absolute weight of all lymph nodes, i.e. the lymph nodes on both sides, ranged between 0.02 and 1.82 g, and the relative weight between 0.005% and 0.009%. The shape of the lymph nodes is generally oval and somewhat flattened, and the median unpaired lymph nodes are more frequently lobed or dumbbell-shaped. The lymph nodes on both sides can lie so close together that they appear to be a single lymph node.

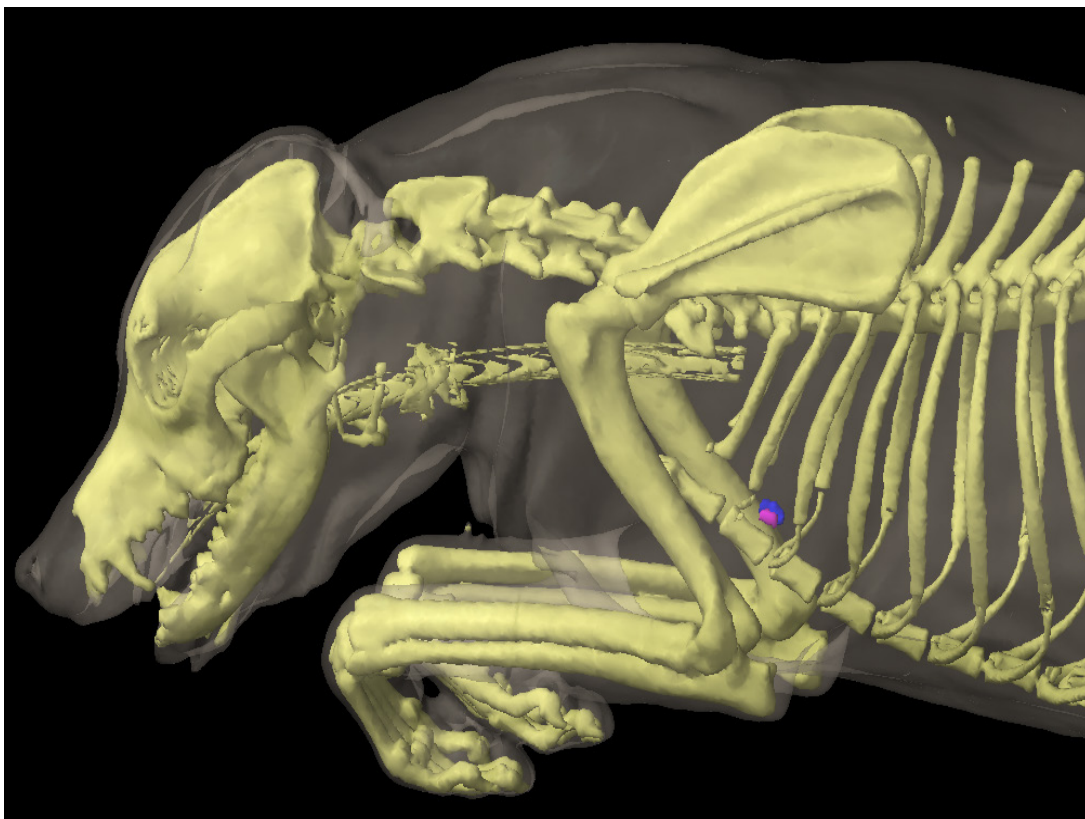
AFFERENT DRAINAGE

The sternal lymph node drains lymph vessels from the *Mm. pectorales*, *M. serratus ventralis*, *Mm. intercostales*, *M. transversus costarum* and *thoracis*, and all the abdominal muscles, the lymph vessels of the ribs and the sternum, the lymph vessels of the diaphragm and mediastinum, the pleura and the peritoneum, the thymus, and the mammary gland. In 1 case in which no sternal lymph node was found, the afferent vessels (at least those that were able to be injected and thus have their drainage pattern assessed), opened into a cranial mediastinal lymph node.

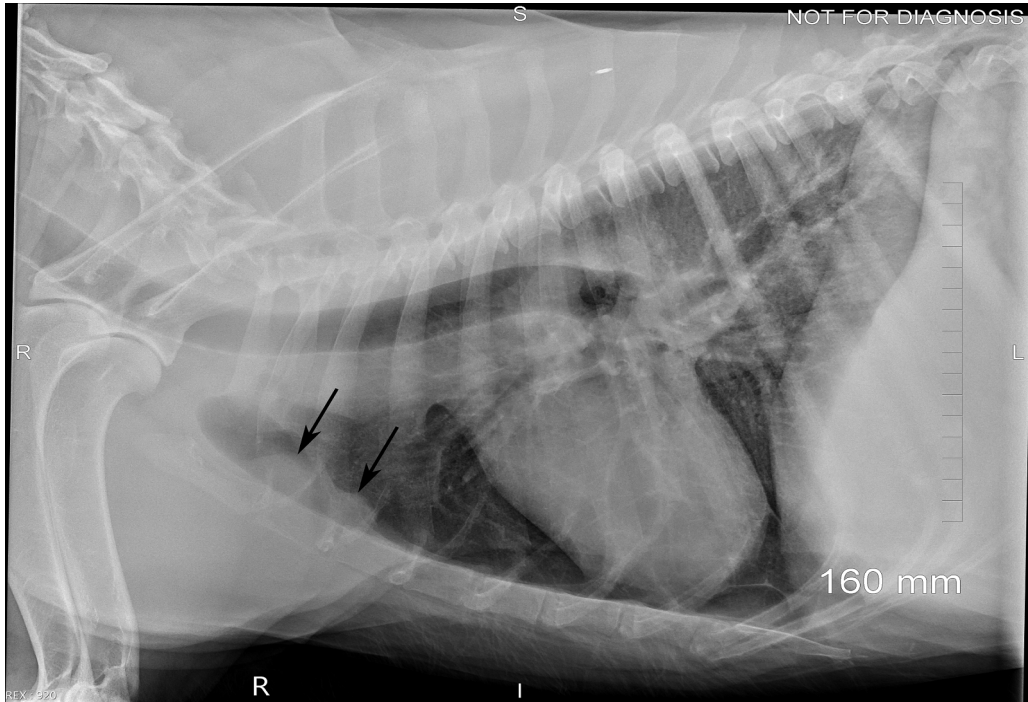
EFFERENT DRAINAGE

One to 3 lymph vessels emerge from each sternal lymph node, forming networks near the internal mammary artery and vein, usually immediately cranioventral to the vessels, and drain to a cranial mediastinal lymph node (almost always the main cranial mediastinal lymph node). If there are 2 lymph nodes located one behind the other on one side, the efferent vessels of the caudal lymph node usually drain partly to the cranial lymph node, with the remainder merging with the efferent vessels of the cranial lymph node.

CLINICAL NOTES



Left (pink) and right (blue) normal-sized sternal lymph nodes (3D image from a CT scan). These lymph nodes are dorsal to the sternum, usually at the level of the 2nd sternebra. Image credit: Dr. Monique Mayer, Western College of Veterinary Medicine, University of Saskatchewan (used under CC BY-NC).



Enlarged sternal lymph nodes on a lateral thoracic radiograph (arrows). Normal-sized lymph nodes are not visible on radiographs. Image credit: Dr. Monique Mayer, Western College of Veterinary Medicine, University of Saskatchewan (used under CC BY-NC).

MEDIASTINAL LYMPH NODES

Mediastinal lymph nodes, i.e. lymph nodes located in the mediastinum, occur infrequently in dogs, in much fewer numbers and in much fewer groups than in cattle. While in cattle there are cranial, middle, caudal, dorsal, and ventral mediastinal lymph nodes (see Baum [6] page 29), in dogs there are only the cranial mediastinal lymph nodes, i.e. lymph nodes that lie between the 1st rib and the heart in the precardiac mediastinum.

The cranial mediastinal lymph nodes are sometimes joined by a lymph node, which is, strictly speaking, a middle mediastinal lymph node, as it lies in the cardiac mediastinum. This lymph node is sometimes found on the left side of the pericardium, where the aortic arch emerges, near the cranial border of the pericardium (Figure 17: a^2), and sometimes on the right or dorsal side of the trachea, just cranial to the azygos vein (Figure 18: 3^2), at times partly or entirely between the trachea and azygos vein. The middle mediastinal lymph node only rarely occurs, is usually poorly distinguishable from the cranial mediastinal lymph nodes, and shares the same afferent drainage. For these reasons, the middle and cranial mediastinal lymph nodes are described together in the following sections, and the term mediastinal lymph nodes is used, but these descriptions are almost exclusively of the behaviour of the cranial mediastinal lymph nodes.

One of the mediastinal lymph nodes is notably constant in its occurrence and position and lies in the 1st intercostal space, just cranial to the costocervical vein. This lymph node will be described in more detail below, and to facilitate the description of its afferent drainage, it will be referred to as the main (cranial) mediastinal lymph node. A caudal mediastinal lymph node was not found in any of the numerous cases examined. The tracheobronchial (*bifurcationis*) lymph node (Figure 17: b, b' ; 18: 1, 2) can be easily mistaken for a caudal mediastinal lymph node and has been previously identified as such (by Ellenberger-Baum [18], Chaveau-Arloing [15] and Bucher [14]).

The mediastinal lymph nodes are embedded in fat and lie in an unorganized manner towards the midline of the body, between the pleurae of the mediastinum in the precardiac mediastinal space. In young animals, they are partly enclosed by the thymus. Since the left and right mediastinal lymph nodes behave differently as a result of the different anatomical topography between the sides, the lymph nodes on the left and right sides should be considered separately, even though a sharp distinction between the two groups is not possible in many cases.

A. LEFT MEDIASTINAL LYMPH NODES

Left side (Figure 17: a, a^1, a^2): the number, size, and position of the lymph nodes are highly variable. One to 6 individual lymph nodes have been observed, which can reach a length of up to 3 cm, a width of 0.8 cm, and a thickness of 0.5 cm in large dogs.

They lie, mostly embedded in a small fat pad, on the left surface of the large vessels running through

the precordial mediastinal space (specifically, the cranial vena cava, the brachiocephalic artery, the left subclavian artery, and the costocervical vein [Figure 17: 9, 10, 11, 14]) and extend from the thoracic inlet towards the cranial border of the aortic arch, or in rare cases, onto the aortic arch and the pericardium (see above and Figure 17: *a*²). If there are a large number of lymph nodes (3 to 6), 1 of the lymph nodes (the main cranial mediastinal lymph node) (Figure 17: *a*) is always located at the 1st intercostal space, immediately cranial to the costocervical vein (between this vein and the internal mammary artery) and to the left of the brachiocephalic artery and cranial vena cava. Less frequently, there are 2 lymph nodes, and, in this case, the 2nd lymph node lies in the thoracic inlet either on the left common carotid artery or the left subclavian vein. Rarely, the caudal part of the main mediastinal lymph node can be located over the left (lateral) side of the costocervical vein. This lymph node appears to correspond to the costocervical lymph node of cattle (see Baum [6] page 19).

The remaining mediastinal lymph nodes lie caudal to the costocervical vein, between it and the aortic arch, and either on the left side of the brachiocephalic artery, the cranial vena cava, or both (Figure 17: *a*¹). One of the mediastinal lymph nodes found between the brachiocephalic artery and the left subclavian artery, or between the brachiocephalic artery and the cranial vena cava, may be located quite deep. In this case, the lymph node usually extends to the ventral edge of the trachea, between the two aforementioned vessels, and can also be exposed from the right side (see below and Figure 18: 3⁴). If there is only 1 lymph node on the left side, it is always the main mediastinal lymph node.

B. RIGHT MEDIASTINAL LYMPH NODES

Right side: the behaviour of the mediastinal lymph nodes on the right side (Figure 18: 3, 3¹, 3², 3³) is significantly different from the mediastinal lymph nodes on the left side due to the different anatomical topography. As on the left, the number and size of the lymph nodes are inconsistent: there may also be 1 to 6 lymph nodes (usually 2 to 3), which range in size from 3 mm to 3 cm, occasionally 4 cm long, up to 0.8 cm wide, and up to 0.7 cm thick.

The lymph nodes are usually located between the thoracic inlet and the azygos vein in fatty connective tissue, the amount of which depends on the dog's nutritional status, and are located on the right side of the organs located in the mediastinal space, or sometimes between these organs, which include the trachea (Figure 18: *r*), the right subclavian artery and vein (Figure 18: *l*), the cranial vena cava (Figure 18: *g*), the azygos vein (Figure 18: *b*), and the costocervical vein (Figure 18: *n*).

The mediastinal lymph nodes on the right side also appear to be scattered across the precordial mediastinal space in an unorganized manner, but upon careful examination, a certain regularity in the location of the lymph nodes can be found. Usually, a main mediastinal lymph node (Figure 18: 3) is found on the cranioventral border of the right costocervical vein (Figure 18: *n*), in the angle between this vein and the cranial vena cava (a small part of the node usually covers both vessels), and on the right subclavian artery and the caudal cervical ganglion. Less commonly, the lymph node was either absent (2 cases) or doubled (2 cases). In one of the latter cases, the 2nd lymph node was observed

on the cranial border of the right subclavian artery, immediately cranial to the junction of the vertebral and costocervical arteries. In 4 cases, the main mediastinal lymph node extended past the medial side of the azygos vein so far that it overlapped the vessel both cranially and caudally. If there is only 1 mediastinal lymph node on the right side, it is the main mediastinal lymph node. Variable numbers of mediastinal lymph nodes can be found on the trachea between the azygos vein and the costocervical vein ([Figure 18: 3¹, 3²](#)): the lymph nodes are most often located on the dorsal right surface of the trachea, and less commonly on the middle surface or on its transition to the ventral surface. Rarely, there is a lymph node ventral to the right subclavian vein, between the right axillary vein and the right internal mammary vein ([Figure 18: 3⁵](#)). As already mentioned above, the lymph node located between the brachiocephalic artery and the cranial vena cava on the ventral edge of the trachea ([Figure 18: 3⁴](#)) must be exposed by lifting the cranial vena cava.

The absolute weight of the entire mediastinal lymph nodes (i.e. the right and left sides) ranged between 0.08 and 5.03 g, the relative weight between 0.0012% and 0.168%.

MEDIASTINAL LYMPH NODE DRAINAGE

AFFERENT DRAINAGE

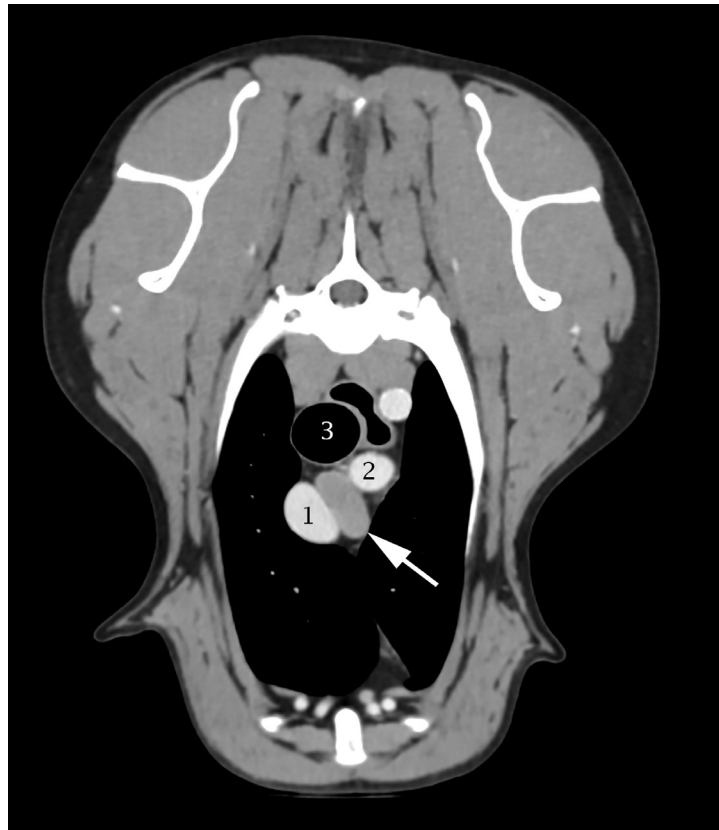The mediastinal lymph nodes drain lymph vessels from the *M. subscapularis*, *trapezius*, *latissimus dorsi*, *rhomboideus*, and *serratus ventralis*, the *Mm. intercostales*, the *M. transversus costarum*, *serratus dorsalis inspiratorius*, *splenius*, *ileocostalis*, *longissimus dorsi*, *longissimus cervicis*, *longissimus capitis*, *spinalis* and *semispinalis dorsi* and *cervicis*, the *M. semispinalis capitis*, *longus colli*, *scalenus*, *sternohyoideus*, *sternothyroideus*, *obliquus abdominis externus* and *internus*, and *transversus abdominis*, as well as the lymph vessels of the scapula, the last 6 cervical vertebrae, the thoracic vertebrae and ribs, the lymph vessels of the trachea and esophagus, the thyroid, the thymus, the mediastinum and *pleura costalis*, the heart, the aorta, the nervous system, and also the efferent vessels of the intercostal, sternal, middle and caudal cervical, tracheobronchial (*bifurcationis*), and pulmonary lymph nodes. The lymph vessels draining the aforementioned muscles and bones almost always drain into the main mediastinal lymph node.

EFFERENT DRAINAGE

When several mediastinal lymph nodes are present, the more caudally located lymph nodes drain via 1 to 3 efferent vessels into the more cranial lymph nodes (e.g. in [Figure 18](#), node 3² drains to the two lymph nodes labelled 3¹, and 3³ drains to the lymph nodes labelled 3¹ and 3, and in [Figure 17](#), lymphnode a¹ drains to lymph node a). The efferent vessels from the cranial lymph nodes, specifically from the main mediastinal lymph node, open into the end of the thoracic duct, sometimes into the left tracheal duct on the left side, and either into the end of the right tracheal duct or the right lymphatic trunk on the right side. It is not uncommon for individual efferent vessels to cross the median plane and drain into mediastinal lymph nodes on the contralateral side, into the contralateral tracheal duct, or from a lymph node on the right side into the end of the thoracic duct (e.g. the lymph vessel labelled *h* in [Figure 17](#) and labelled *10*

in Figure 18). The efferent vessels often form rich networks in which the smallest lymph nodes, which are barely perceptible to the naked eye, are frequently embedded.

CLINICAL NOTES



Post-contrast computed tomographic (CT) image of an enlarged mediastinal lymph node (white arrow), close to the cranial vena cava (1), the brachiocephalic trunk (2) and the trachea (3). Image credit: Dr. Monique Mayer, Western College of Veterinary Medicine, University of Saskatchewan (used under CC BY-NC).

BRONCHIAL LYMPH CENTRE

The bronchial lymph centre includes all lymph nodes located on the bifurcation of the trachea and the bronchi: (1) the tracheobronchial lymph nodes (previously the *Lnn. bifurcationis*) ([Figures 20](#) and [22: 1, 2, 3](#)), which include the left ([Figure 22: 1](#)), right ([Figure 22: 1](#)) and middle ([Figure 22: 1](#)) tracheobronchial lymph nodes, which lie on the left, right and caudal side of the bifurcation, respectively, and (2) the pulmonary lymph nodes ([Figures 20](#) and [22: 4, 4'](#)), which lie on the bronchi before they enter the lungs, almost always on their dorsal side. I call these pulmonary lymph nodes even though they are not located in the lungs, because they only receive lymph vessels from the lungs, and because they correspond to the pulmonary lymph nodes located on the bronchi in cattle, although in that species the lymph nodes are within the lungs (Baum [\[6\]](#) page 36). I also have chosen not to divide the lymph nodes located on the bifurcation of the trachea and the bronchi into as many separate subgroups as is done in man, in whom the lymph nodes include the bifurcation lymph node (at the angle of the bifurcation), the tracheobronchial lymph nodes (at the angles between the trachea and the bronchi), the bronchopulmonary lymph nodes (at the branching angles of the bronchi), and the pulmonary lymph nodes (in the lung tissue).

Such an extensive subgrouping of the bronchial lymph nodes cannot be applied to the anatomy of other species and would create confusion as to which subgroup each lymph node should be assigned to. The pulmonary lymph nodes in the dog are comparable to the bronchopulmonary lymph nodes in man. The descriptions I provide refer only to the lymph nodes that are visible macroscopically and not to microscopically detectable lymph nodes or the smallest lymph nodes.

A. TRACHEOBRONCHIAL LYMPH NODES

The tracheobronchial lymph nodes ([Figures 17: b, b'](#), [18: 1, 2, 20](#) and [22: 1, 2, 3](#)) are fairly constant in number and position. In 34 closely examined cases, there were always 3 lymph nodes: 2 of the lymph nodes were consistently found at the right and left bifurcation, lateral to the border between the trachea and bronchi (the right and left tracheobronchial lymph node, respectively), and the 3rd lymph node in bifurcation angle (the middle tracheobronchial lymph node). The size of the lymph nodes ranged from 6 mm to 3.2 cm. The middle tracheobronchial lymph node was always the largest. The lymph nodes are conspicuous because they are mostly black in colour (due to the deposition of dust and other particles through filtration).

The right tracheobronchial lymph node ([Figures 18, 20](#), and [22: 2](#)) lies in the angle between the trachea and the right main bronchus, cranial to the bronchus for the right apical lobe (currently known as the right cranial lobe) of the lung (as shown in [Figure 20](#)) and often contacting the bronchus with its caudal surface ([Figure 18: s'](#)). The lymph node is bordered craniodorsally by the azygos vein ([Figure 18: h](#)), and ventrally by the branches of the pulmonary artery and vein that supply the right apical lung lobe (right cranial lung lobe). The right apical lung lobe (right cranial lung lobe) borders the right tracheobronchial lymph node laterally.

The left tracheobronchial lymph node ([Figures 17: b, 20; 22: 1](#)) is in a comparable position to the right lymph node, in the angle between the trachea and the left main bronchus. The left lymph node is bordered craniodorsally by the thoracic aorta (Figure 17: 3), though its cranial part may extend between the trachea and the aorta. Ventrally, it is bordered by the left branch of the pulmonary artery. The lymph node's left side, which is covered by the left apical lung lobe (currently known as the cranial segment of the left cranial lung lobe), is crossed by the left vagus nerve.

The middle tracheobronchial lymph node ([Figures 17: b'; 18: 1; 20,](#) and [22: 3](#)) is located in the bifurcation angle and extends from one main bronchus to the other in a slightly convex, cranial arc, so that it is almost horseshoe-shaped, with a middle section and two legs (see Figure 20: 3). It also extends slightly outwards on the dorsal aspect of the two main bronchi. It is bordered dorsally by the esophagus and caudoventrally by the pulmonary veins, and it is crossed by the vagus nerves laterally on both sides.

The absolute weight of all the tracheobronchial lymph nodes ranged from 0.25 g to 6.78 g, and the relative weight from 0.0011% to 0.0256%.

AFFERENT DRAINAGE

The tracheobronchial lymph nodes drain lymph vessels from the thoracic portion of the esophagus, the end of the trachea, the bronchi and lungs, the mediastinum and diaphragm, the heart, and the aorta, as well as the efferent vessels of the pulmonary lymph nodes.

EFFERENT DRAINAGE

Two to 4 efferent vessels arise from each tracheobronchial lymph node, some of which drain into another tracheobronchial lymph node, and some of which drain into 1 or more mediastinal lymph nodes. Some of the efferent vessels of the right tracheobronchial lymph node travel over the dorsal and ventral surfaces of the right main bronchus into the middle tracheobronchial lymph node, and others drain into the right mediastinal lymph node ([Figures 18: u; 20: 2](#)). Some of the efferent vessels of the middle tracheobronchial lymph node ([Figures 17: b'; 18: 1 and 20: 3](#)) travel both dorsally and ventrally over the left main bronchus and drain to the left tracheobronchial lymph node, and some drain directly to the mediastinal lymph nodes on both the right and left sides. In one case, an efferent vessel from the middle tracheobronchial lymph node passed over the left tracheobronchial lymph node without opening into it. One to 2 efferent vessels from the left tracheobronchial lymph node ([Figures 17: b; 20: 1](#)) travel over the left side, or over both sides, of the aortic arch to one of the left mediastinal lymph nodes, usually either to the lymph node located on the left side of the cranial vena cava (Figure 17: a'), or to the lymph node located on the brachiocephalic artery, sometimes to both aforementioned lymph nodes. In 3 cases, none of the efferent vessels from the left tracheobronchial lymph node drained into either the middle or right tracheobronchial lymph nodes, or at most there

was drainage only observed up to the 1st valve. Drainage from the middle tracheobronchial lymph node to the right tracheobronchial lymph node was also rare.

B. PULMONARY LYMPH NODES

The pulmonary lymph nodes ([Figures 20, 22: 4, 4'](#)) are usually small, ranging from 4 to 10 mm in length, although, in rare cases, they may be considerably larger (up to 20 mm in length). The lymph nodes are located on the extrapulmonary aspect of the left and right bronchi, usually on the dorsal side. The pulmonary lymph nodes are not consistently found – on the contrary, they are absent in the majority of cases; in 41 examined cases, they were found in only 14. Of these 14 cases, a lymph node on the right bronchus was present in 10, and a lymph node on the left bronchus was present in 4. In 1 of the latter cases, the node seemed to originate from the left side of the middle tracheobronchial lymph node. The pulmonary lymph nodes are usually black in colour due to the deposition of dust and other particles.

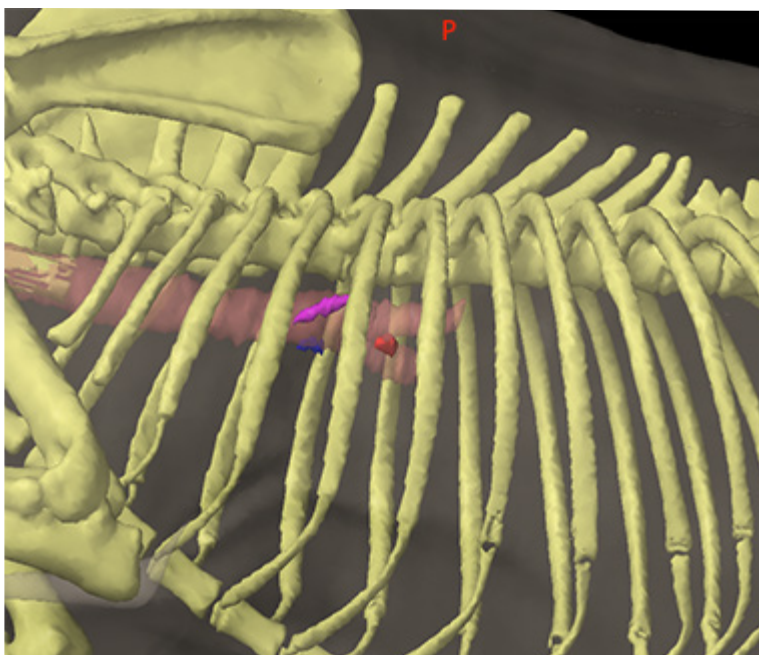
AFFERENT DRAINAGE

The pulmonary lymph nodes drain lymph vessels from the bronchi and the lungs.

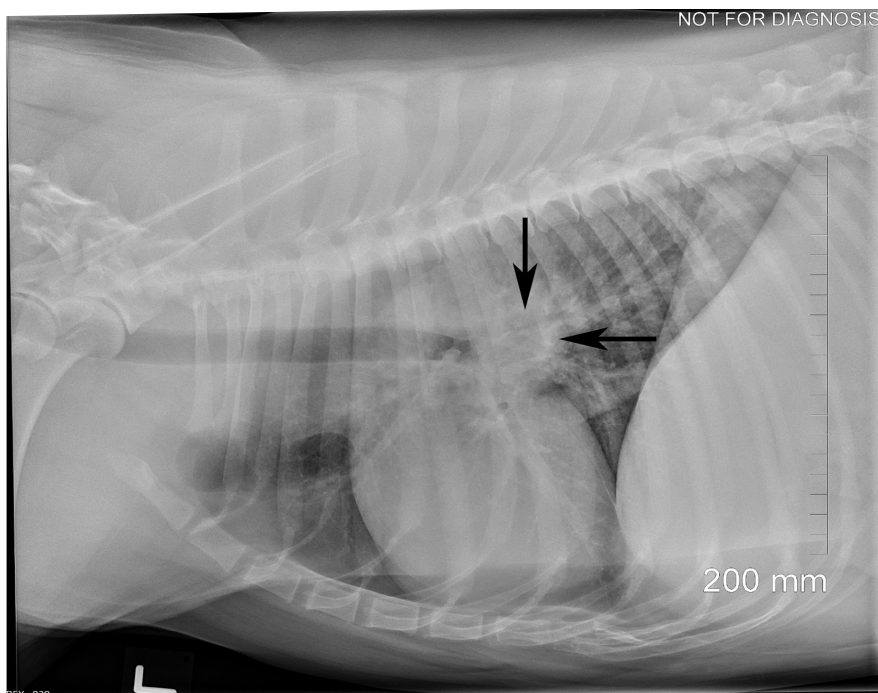
EFFERENT DRAINAGE

One to 2 efferent vessels arise from each pulmonary lymph node and drain into either an ipsilateral tracheobronchial lymph node or mediastinal lymph node, or to both a tracheobronchial and mediastinal lymph node, as shown in [Figure 20: 4, 4'](#).

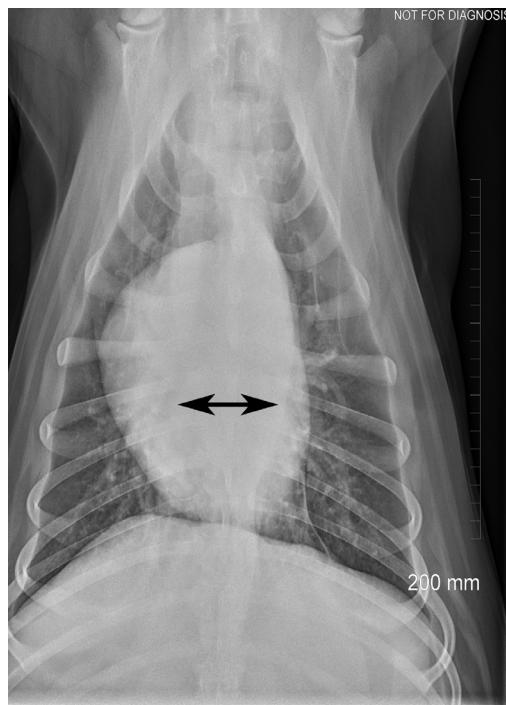
CLINICAL NOTES



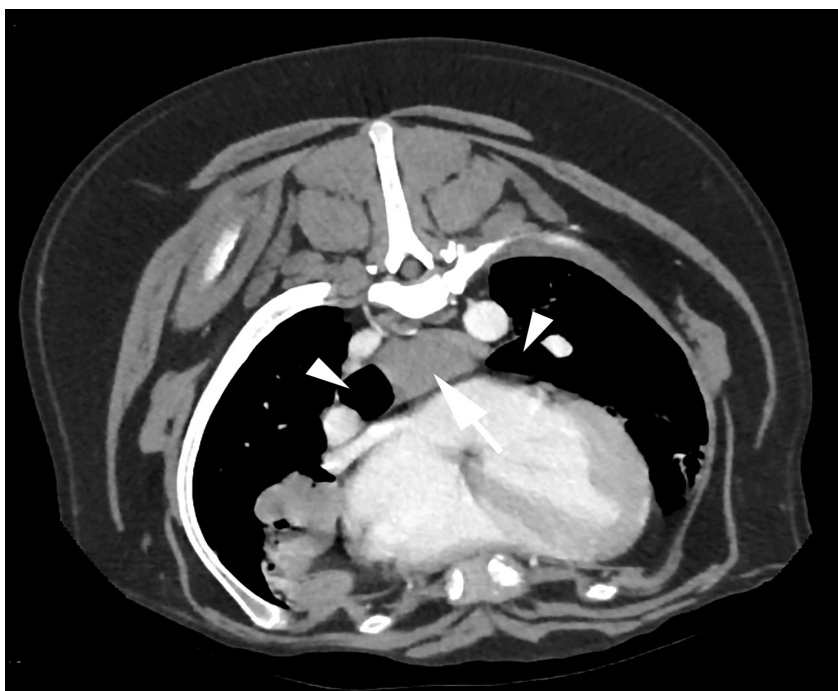
Left (pink), right (blue) and middle (red) normal-sized tracheobronchial lymph nodes (3D image from a CT scan). The trachea and initial part of the bronchi are shown in light brown. Image credit: Dr. Monique Mayer, Western College of Veterinary Medicine, University of Saskatchewan (used under CC BY-NC).



Lateral thoracic radiograph of a dog with enlarged tracheobronchial lymph nodes. Radiographic signs include increased opacity in the perihilar region (arrows). Normal-sized lymph nodes are not visible on radiographs. Image credit: Dr. Monique Mayer, Western College of Veterinary Medicine, University of Saskatchewan (used under CC BY-NC).



Dorsoventral thoracic radiograph of the same dog as in the lateral radiograph above. Radiographic signs include increased opacity and widening between the bronchi (black double arrow). Image credit: Dr. Monique Mayer, Western College of Veterinary Medicine, University of Saskatchewan (used under CC BY-NC)



Transverse computed tomographic (CT) slice of a dog showing an enlarged middle tracheobronchial lymph node (white arrow), located between the bronchi (white arrowheads). Image credit: Dr. Monique Mayer, Western College of Veterinary Medicine, University of Saskatchewan (used under CC BY-NC).

1.6 LYMPH NODES OF THE ABDOMINAL AND PELVIC WALLS

GENERAL

The lymph nodes of the abdominal and pelvic cavities can be divided into the parietal (wall) lymph nodes located on the abdominal and pelvic walls, and the visceral (organ) lymph nodes located on the abdominal organs (viscera).

Almost all the parietal lymph nodes are located near the abdominal aorta and the caudal vena cava, as well as their respective terminal branches. When the lymph nodes are located cranial to the deep circumflex iliac artery, and lie on the aorta and cranial vena cava, they are termed the lumbar aortic lymph nodes (*Lnn. lumbales aorticae*), while nodes located caudal to the deep circumflex iliac artery in the area of the terminal division of the aorta and caudal vena cava have so far been grouped under the general term of iliac lymph nodes (*Lnn. iliaci*) (Ellenberger-Baum [18], Chauveau-Arloing [15]).

However, because the lymph nodes in this group have different afferent drainage areas, I will divide them into 2 groups: the medial iliac lymph nodes (*Lnn. iliaci mediales*), which consist of a lymph node on the right and left sides between the point of origin of the deep circumflex iliac artery and the external iliac artery, and the hypogastric¹ lymph nodes (*Lnn. hypogastricae*), now termed the internal iliac lymph nodes (*Lnn. iliaci interni*), which are located at the angle of division of the aorta between the two hypogastric arteries (currently termed the internal iliac arteries). The iliac lymph nodes correspond to the medial iliac lymph nodes of cattle, while lymph nodes corresponding to the lateral iliac lymph nodes in cattle are not observed in dogs. The hypogastric lymph nodes correspond to the sacral hypogastric lymph nodes in cattle (see Baum [6], page 3). I could not find any lymph nodes in the dog that were comparable to the *lumbales propriae* lymph nodes located between the transverse processes of the lumbar vertebrae of cattle. Additional parietal lymph nodes include the sacral lymph nodes and the deep inguinal lymph node.

The sacral lymph nodes are found as a continuation of the hypogastric lymph nodes and are located on the dorsolateral wall of the pelvic cavity. They are divided into 2 groups: the medial sacral lymph node (*Ln. sacralis medialis*), located on the medial sacral artery, and the lateral sacral lymph node (*Ln. sacralis lateralis*), located on the lateral pelvic wall, lateral to the hypogastric artery and vein (internal iliac artery and vein). The deep inguinal lymph node (*Ln. inguinalis profundus*) is the only parietal lymph node that lies on the lateral abdominal wall.

¹ Baum calls these hypogastric lymph nodes, however, they are called internal iliac lymph nodes in Miller's Anatomy of the Dog (5th edition).

LUMBAR AORTIC LYMPH NODES

The lumbar aortic lymph nodes (Figures 24: 5, 6; 26: *h* and 27: 1, 1', 2, 3, 3') lie in the region of the lumbar spine, on the aorta and caudal vena cava, and extend from the crura of the diaphragm to the deep circumflex iliac arteries. In the region of the deep circumflex iliac arteries, they are sometimes not clearly demarcated from the medial iliac lymph nodes (see medial iliac lymph nodes). With the exception of the most cranial lumbar aortic lymph nodes (see below), the lumbar aortic lymph nodes may be absent, though notably, in some cases, up to 17 individual lymph nodes were found. The lymph nodes are small, usually very small, with sizes around 1 to 2 mm.

In addition, these lymph nodes are often not clearly defined from the surrounding connective and fatty tissue and are almost always enclosed in fat, resulting in them being quite difficult to find; they may be overlooked if they have not been made visible by injection of their efferent vessels. Therefore, the previous statement that the lumbar aortic lymph nodes were absent in some individual cases should be taken with consideration of this difficulty in identification. For the same reason, I have not reported the absolute and relative weight of the lumbar aortic lymph nodes. The lymph nodes are not arranged in a consistent pattern; instead, they are randomly embedded in a thick pad of fat, and are found dorsally, ventrally, and laterally around the aorta and caudal vena cava, as well as between these vessels. As a result, a more extensive division into subgroups, e.g. into *Lnn. retroaortici*, *praeaortici* and *paraaortici*, or into *Lnn. retrovenosi*, *praevenosi* and *paravenosi*, as in humans, is not possible in dogs.

The lumbar aortic lymph node located most cranially on each side is the most consistent in terms of occurrence, number, and position. As this cranial-most lymph node also has a different afferent drainage area than the other lumbar aortic lymph nodes, it will be termed the cranial lumbar aortic lymph node and discussed in more detail.

The left cranial lumbar aortic lymph node (Figures 27: 1; 28: 3) is occasionally a double lymph node, usually 1 to 2 cm long in large dogs, and is located on both the left crus of the diaphragm and the left lumbar muscles, on the left side of the aorta at the level of, or slightly caudal to, the point at which the cranial mesenteric artery branches off. The lymph node is in contact with the *A. and V. lumboabdominalis*. This vein is usually found along the ventral side of the lymph node (Figure 28: 1); while the artery is also found along the ventral side of the lymph node, it more often passes closely in front of the lymph node

The right cranial lumbar aortic lymph node (Figures 27: 1'; 28: 3') is usually found slightly more caudal, on the right crus of the diaphragm and the right lumbar muscles, and is mostly covered ventrally by the right renal vein (as in Figure 28), though it may also be found more medially under the caudal vena cava (as in Figure 27). One may be inclined to call this lymph node a renal lymph node, but as the afferent drainage area is the same as the left cranial lumbar aortic lymph node (see below), it should be considered a cranial lumbar aortic lymph node, even if it drains lymph vessels from the right kidney. This also applies to the left cranial lumbar aortic lymph node, which also drains some of the lymph vessels of the left kidney. On the left side, there is usually another lymph node that lies on the blood vessels leading to

the renal hilum, which one may also be inclined to call a renal lymph node. However, because this lymph node does not have a constant position (and may even be absent), does not drain all the lymph vessels of the left kidney, and cannot be clearly distinguished from the lumbar aortic lymph nodes, I prefer not to consider it as a subgroup (renal lymph node) distinct from the lumbar aortic lymph nodes, and therefore do not discuss it separately as a renal lymph node.

AFFERENT DRAINAGE

The lumbar aortic lymph nodes drain lymph vessels from the lumbar vertebrae, the lumbar muscles, the *M. longissimus dorsi*, *ileocostalis lumborum*, the kidney and ureter, the ovary and uterus, the testes, epididymis and ductus deferens, the *tunica vaginalis communis*, the *M. cremaster*, the aorta, the nervous system, and the efferent vessels from the left colic lymph nodes and the medial iliac lymph nodes. Specifically, the cranial lumbar aortic lymph node receives lymph vessels (shown in [Figures 27, 28](#)) from the last thoracic vertebrae and last ribs, the lumbar muscles, the *M. latissimus dorsi*, the *Mm. intercostales*, the *M. longissimus dorsi* and *iliocostalis*, *obliquus abdominis externus* and *internus*, *transversus abdominis*, as well as lymph vessels of the lumbodorsal fascia, mediastinum, costal pleura, and lymph vessels from the diaphragm, peritoneum, liver, kidney, adrenal gland, aorta, and nervous system.

EFFERENT DRAINAGE (FIGURE 27)

One to 3 efferent vessels leave individual lumbar aortic lymph nodes, draining either into cranially located lumbar aortic lymph nodes, or directly into the *cisterna chyli*, or joining with the efferent lymph vessels of the other lumbar aortic lymph nodes and the medial iliac lymph nodes to form the pelvic lymphatic trunk (see pelvic lymphatic trunk). The efferent vessels of the cranial lumbar aortic lymph nodes drain directly to the *cisterna chyli* ([Figure 24: 12](#)).

MEDIAL ILIAC LYMPH NODES

The medial iliac lymph node ([Figure 24: 7, 7'](#); [26: 1](#); [27: 4, 4¹, 4²](#); [32: 1](#)) is usually found as one elongated, slightly flattened lymph node on each side of the body. It is adjacent to the aorta on the left side ([Figures 24: 7'; 27: 4¹, 4²](#)) and to the caudal vena cava on the right side ([Figure 24: 7; 27: 4](#)), between the deep circumflex iliac artery ([Figure 27: i](#)) and the external iliac artery. The lymph node is 6 cm long, 2.2 cm wide, and 1.5 cm thick in large dogs. In 13 of 33 cases, the number of lymph nodes deviated from this description: in 2 cases there was 1 lymph node on the left and 2 on the right, in 8 cases 1 on the right and 2 on the left, in 2 cases 1 on the right and 3 on the left, and in 1 case, 2 lymph nodes each on both the right and left sides. Since the number of cases in which there was more than 1 lymph node on each side is quite high, one could speak of the medial iliac lymph node in the plural. I do not, however, because the cases in which there is only 1 lymph node on each side is still predominate in number, and because the lymph vessels from one limb only open into the lymph node on the ipsilateral side, and were not

observed to cross the median plane and flow into the contralateral lymph node. The medial iliac lymph node is usually ventral to the bodies of the 5th and 6th lumbar vertebrae and ventromedial to the lumbar muscles at the angle between the aorta and the cranial edge of the external iliac artery on each side.

The right lymph node ([Figure 24: 7](#); [27: 4](#)) lies on the side of the abdominal aorta, ventral to the caudal vena cava and right common iliac vein. This lymph node usually starts just caudally from the deep circumflex iliac artery ([Figure 27: i](#)) and extends to the right external iliac artery ([Figure 27: k](#)), at the cranial edge of which it sometimes bends laterally to accompany the artery for a short distance. Rarely, part of the lymph node is located to the right of the caudal vena cava on the ventromedial side of the flat tendon of the *M. psoas minor*. Quite often, the cranial one-quarter or one-third of the lymph node protrudes over the deep circumflex iliac artery, so that it is crossed by the artery on its dorsalside (as [Figure 27](#) shows). The lymph node may also extend so far caudally that it lies between the external iliac artery and the common iliac vein on the right side, and is therefore crossed on its ventral side by the external iliac artery.

The left lymph node ([Figure 24: 7'](#); [27: 4¹, 4²](#)) is usually found at the angle between the abdominal aorta and the cranial edge of the left external iliac artery and frequently extends to some degree along the latter. The lymph node extends dorsally to the tendons of the *M. psoas minor* and the *M. iliopsoas* and usually extends from the deep circumflex iliac artery to the left external iliac artery. Not infrequently, however, the cranial one-quarter to one-third of the left lymph node protrudes beyond the deep circumflex iliac artery (as shown in [Figure 24](#)), and may extend in a caudal direction over the dorsal side of the external iliac artery to the hypogastric artery, or up to, or even over, the dorsal aspect of the common iliac vein. In cases where 2 or 3 lymph nodes are present on one side, they are generally found together, one behind the other, and were only rarely observed to be positioned next to each other. In these cases, either 1 lymph node is located just cranial to the deep circumflex iliac artery and the other lymph node just caudal to it (as shown in [Figure 24](#)), or 1 lymph node extends from the deep circumflex iliac artery to the external iliac artery and the other is located caudal to it.

If a medial iliac lymph node is located just cranial to the deep circumflex iliac artery, it may be difficult to distinguish from a lumbar aortic lymph node, and it is possible that it should be identified as such. In support of this being a lumbar aortic lymph node, it was found that when such a lymph node is present, the lymph vessels ascending in the femoral canal do not drain into it, but drain first into the caudal of the 2 lymph nodes, and only through the efferent vessels of the caudal lymph node does the lymph reach this lymph node. However, in support of the lymph node being a medial iliac lymph node, frequently there is only 1 lymph node that protrudes cranially over the deep circumflex iliac artery in such a way that the cranial portion of the lymph node is only connected to the rest of the lymph node by a parenchymal bridge. Thus, one could get the impression that if the parenchymal bridge were absent, the cranial portion would be considered an independent medial iliac lymph node just cranial to the deep circumflex iliac artery. In 1 case with 3 lymph nodes, 1 lymph node was dorsal to the deep circumflex iliac artery, 1 lymph node was ventral to the deep circumflex iliac artery, and the 3rd lymph node was caudal to the deep circumflex iliac artery on the craniolateral border of the external iliac artery. For the absolute and relative weight of the medial iliac lymph node see the hypogastric lymph nodes.

AFFERENT DRAINAGE (FIGURES [24](#), [26](#), [27](#), [29](#), [31](#), AND [32](#))

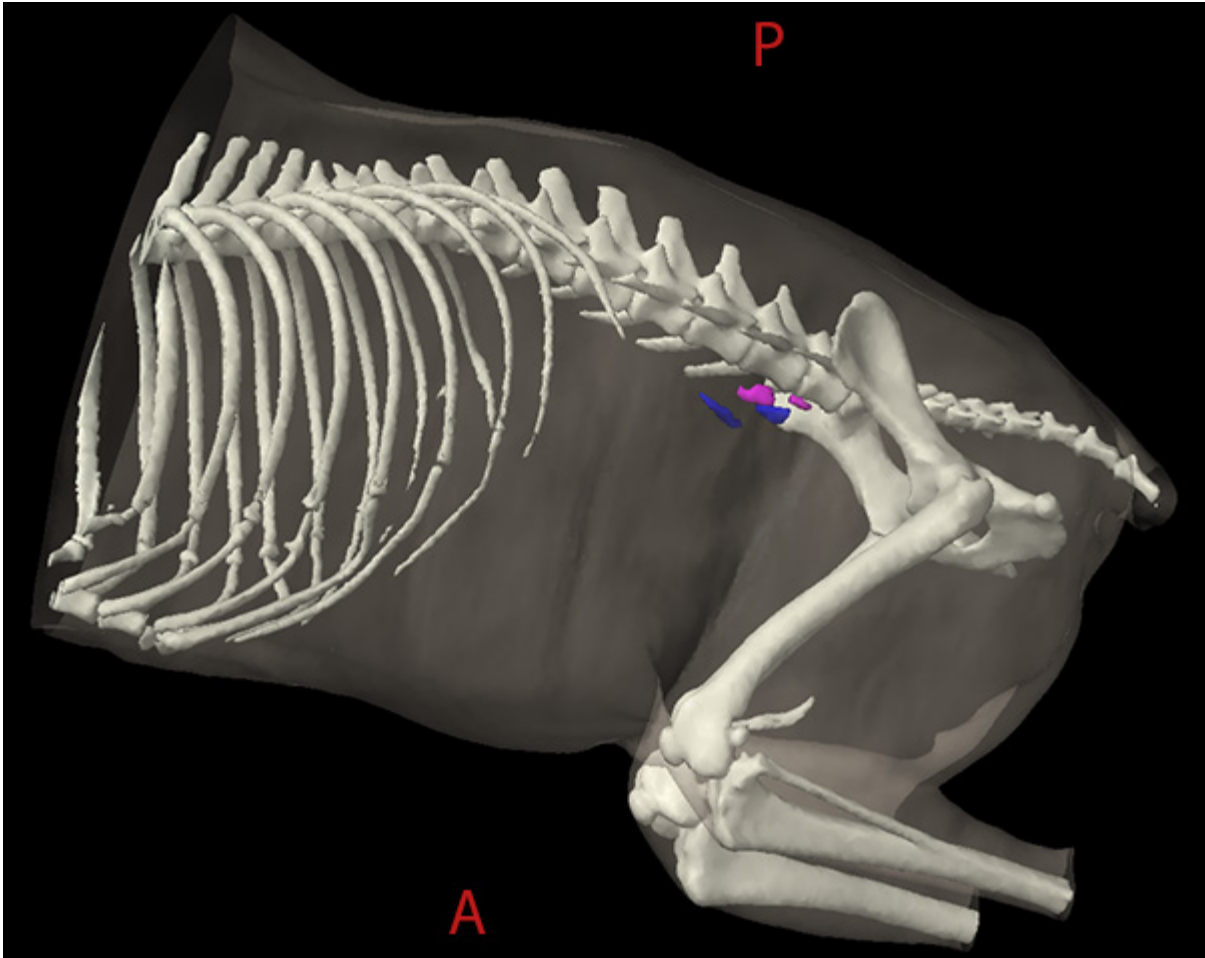
The medial iliac lymph node drains lymph vessels from the skin of the dorsal half of the part of the abdominal wall that is located caudally from a transverse plane cutting through the last rib, from the skin of the pelvic region and the base of the tail and the cranial half of the lateral side of the thigh and stifle joint, lymph vessels from the *fascia lumbodorsalis*, *fascia lata* and *fascia cruris*, lymph vessels of all muscles in the pelvis, thigh, lower thigh and foot, including the lumbar muscles with the exception of the *M. obturatorius internus*, lymph vessels of the tendons of the *M. tibialis anterior*, *M. extensor digitalis lateralis*, *M. peroneus longus*, *M. gastrocnemius*, *M. flexor digitalis sublimis* and *profundus*, lymph vessels of all abdominal muscles and of the abdominal skin muscle, lymph vessels of the hip, knee and tarsal joints, lymph vessels of the pelvis, femur, patella, tibia and fibula and tarsal and metatarsal bones, lymph vessels of the colon, rectum and anus, lymph vessels of the uterus, vagina, vaginal vestibule and vulva, lymph vessels of the testicles, epididymis, *ductus deferens*, *tunica vaginalis communis*, *M. cremaster*, the prostate and the male and female urethra, lymph vessels of the urinary bladder and ureter, lymph vessels of the aorta, the peritoneum and the nervous system, as well as the efferent lymph vessels of the popliteal lymph node, medial femoral lymph node, deep inguinal lymph node, superficial inguinal lymph nodes, left colic lymph nodes, sacral lymph node, and hypogastric lymph nodes.

EFFERENT DRAINAGE (FIGURES 24 AND 27)

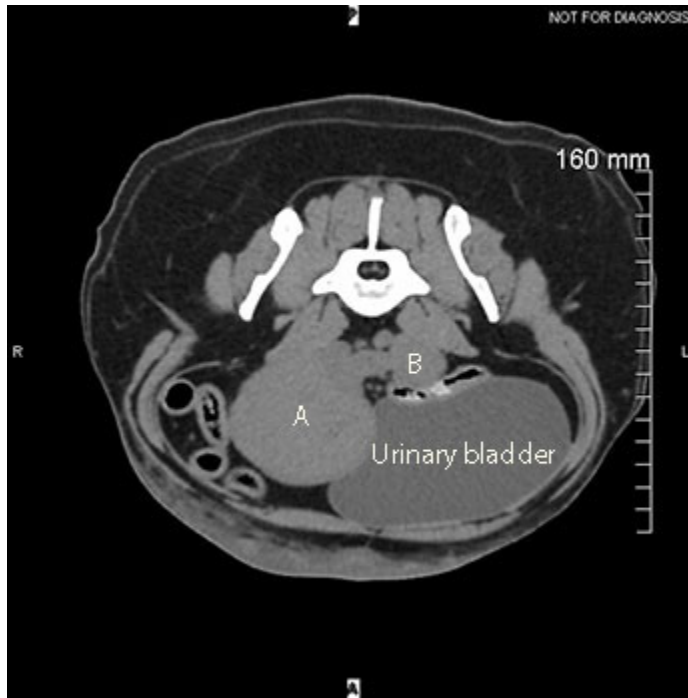
The efferent vessels of the medial iliac lymph node merge to form several trunks, some of which drain to a lumbar aortic lymph node, and some of which merge with the efferent vessels of the lumbar aortic lymph nodes to form the pelvic lymphatic trunk. The medial iliac lymph nodes on each side are connected to each other by efferent lymph vessels, as are the lymph nodes on one side if there is more than one present.

CLINICAL NOTES

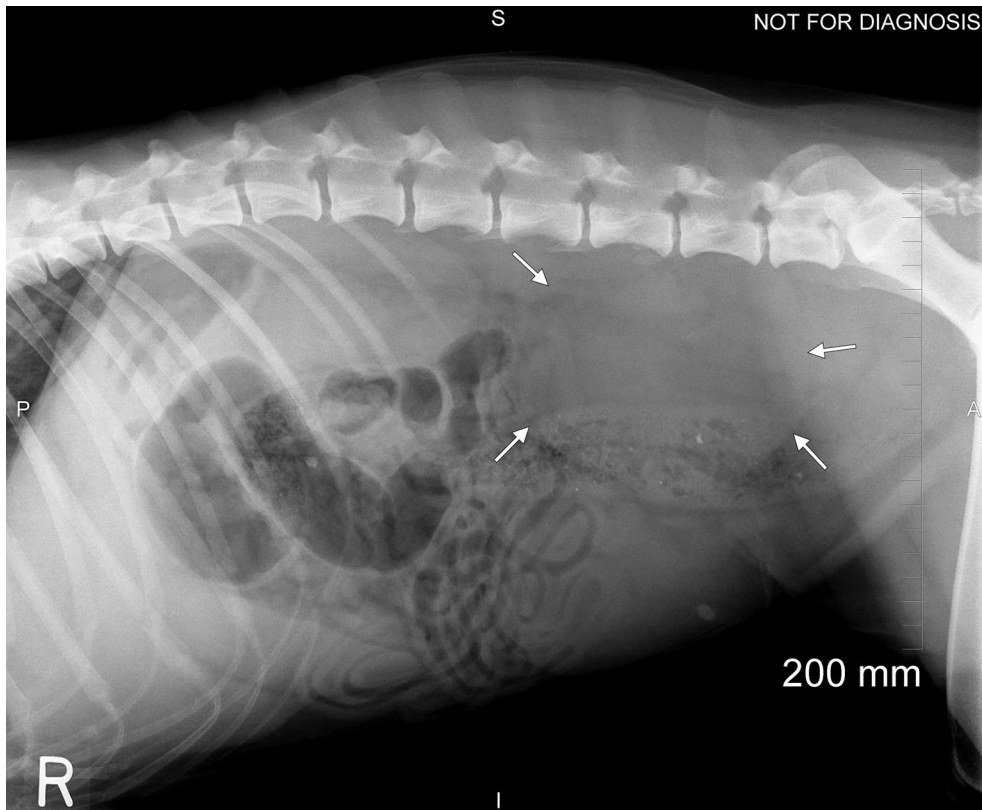
The medial iliac lymph nodes on each side are connected to each other by efferent lymph vessels, and cancer cells shed from a malignant tumour on one side could therefore travel to the medial iliac lymph node(s) on both sides.



Left (pink) and right (blue) normal-sized medial iliac lymph nodes (3D image from a CT scan).
Image credit: Dr. Monique Mayer, Western College of Veterinary Medicine, University of Saskatchewan (used under CC BY-NC).



Computed tomographic (CT) image of enlarged right (A) and left (B) medial iliac lymph nodes containing metastatic disease in a dog with anal sac adenocarcinoma. Image credit: Dr. Monique Mayer, Western College of Veterinary Medicine, University of Saskatchewan (used under CC BY-NC).



Lateral abdominal radiograph of a dog with anal sac adenocarcinoma metastasized to the medial iliac lymph nodes. The arrows outline the largest lymph node. Image credit: Dr. Sally Sukut, Western College of Veterinary Medicine, University of Saskatchewan (used under CC BY-NC).

HYPOGASTRIC (INTERNAL ILIAC) LYMPH NODES

The hypogastric lymph nodes include all lymph nodes found ventral to the body of the last, or occasionally the second to last, lumbar vertebrae, ventral to the *M. sacrococcygeus ventralis*, which arises from the last lumbar vertebra, in the angle that the left and right hypogastric arteries form with each other at their origin (Figures 24: 8; 27: 5; 29: 4). The number and location of these lymph nodes varied quite significantly. In 22 dogs, the hypogastric lymph nodes consisted of 2 elongated, somewhat flattened lymph nodes, 1 on the right and 1 on the left side of the median sacral artery, between it and the corresponding hypogastric artery (Figure 24: 8). As a rule, the node did not extend to the apex of the described angle formed between the median sacral artery and the left or right hypogastric arteries. In 6 cases, only 1 lymph node was found: in 3 dogs the lymph node was on the right, and in 1 dog, it was on the left; in the other 2 dogs, the lymph node was mostly midline on the median sacral artery. In cases with more than 1 lymph node on each side, there was 1 lymph node on the right and 2 lymph nodes on the left (1 case) (Figure 27: 5), 1 lymph node on the right and 3 lymph nodes on the left, lying one behind the other (2 cases), and 2 lymph nodes lying one behind the other on each side (2 cases). In 2 of the cases in which 2 or 3 lymph nodes lay one behind the other on the left, the cranial-most lymph node extended so far cranially that it contacted the dorsal side of the left hypogastric artery and reached the caudomedial border of the left common iliac vein. In 1 case, the cranial end of the left cranial lymph node reached the left external iliac artery, inserting itself between the left hypogastric artery and the left common iliac vein. Conversely, the lymph node was sometimes located very caudal, in those cases only ventral to the last lumbar vertebra. When 2 lymph nodes were present on the same side, the caudal-most lymph node was always ventral to only the last vertebra.

The above descriptions show that the hypogastric lymph nodes can be considered as a single group, like the medial sacral lymph nodes. For the absolute and relative weights of the hypogastric lymph nodes, see below.

AFFERENT DRAINAGE (FIGURES 24, 26, 27, 29, 31, AND 32)

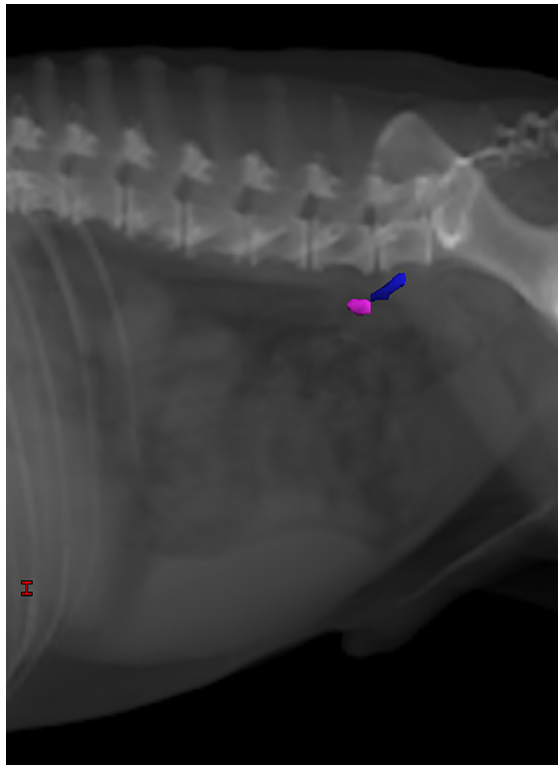
The hypogastric lymph nodes drain lymph vessels from the *M. psoas minor*, *quadratus lumborum*, the *Mm. glutei*, the *M. biceps femoris*, *semitendinosus* and *semimembranosus*, *quadratus femoris*, *obturatorius internus* and *externus*, and the tail muscles, lymph vessels of the pelvis and femur, the lumbar, sacral, and caudal vertebrae, lymph vessels of the colon, rectum and anus, the uterus, vagina, vaginal vestibule, vulva and clitoris, lymph vessels of the testicle, epididymis, *ductus deferens*, prostate, penis, lymph vessels of the bladder and ureter, the male and female urethra and the nervous system, and the efferent lymph vessels from the deep inguinal and sacral lymph nodes.

EFFERENT DRAINAGE

The efferent vessels leaving each hypogastric lymph node merge to form 2 to 3 network-forming trunks, which flow on both the ventral and dorsal sides of the external iliac artery and vein to the medial iliac lymph nodes, as shown in [Figures 23](#) and [27](#).

The absolute and relative weights were determined for the medial iliac and hypogastric lymph nodes on both sides. The absolute weight varied from 0.21 g to 20.94 g, and the relative weight from 0.0021% up to 0.0427%.

CLINICAL NOTES



A left lateral digitally reconstructed radiograph showing a hypogastric (internal iliac) lymph node (blue) located ventral to the last lumbar vertebra and caudal to a medial iliac lymph node (pink). Digitally reconstructed radiographs (DRRs) are generated from computed tomographic scans and can be used to view the position of three-dimensional structures, such as lymph nodes or tumours, relative to two-dimensional radiographic anatomy. Image credit: Dr. Monique Mayer, Western College of Veterinary Medicine, University of Saskatchewan (used under CC BY-NC).

SACRAL LYMPH NODES

The sacral lymph nodes ([Figures 24: 9, 10; 27: 6, 7; 29: 7; 32: 5](#)) are lymph nodes located on the inner aspect of the roof and dorsolateral walls of the pelvic cavity, caudal to the hypogastric lymph nodes, and are sometimes very difficult to distinguish from the hypogastric nodes. The sacral lymph nodes only occur in about half of all cases and, moreover, are easy to overlook because they are usually small lymph nodes that are always enclosed in fat. The sacral lymph nodes can be divided into the medial sacral lymph node, located at the roof of the pelvic cavity, and the lateral sacral lymph node, located at the dorsolateral wall of the pelvic cavity.

A. MEDIAL SACRAL LYMPH NODES

The medial sacral lymph node ([Figures 24: 9; 27: 6](#)) lies caudal to the body of the last lumbar vertebra on either the ventral surface of the sacrum or the *M. sacrococcygeus ventralis*, immediately lateral to the median sacral artery (as shown in [Figure 27](#)), which it sometimes covers. The medial sacral lymph node may be located so close to the sacral promontory that it cannot be clearly separated from the hypogastric lymph nodes. In 30 closely examined dogs, medial sacral lymph node(s) were found in 17 cases: 6 times on both sides, 4 times only on the left side, and 2 times only on the right side. In 5 cases, there was only 1 lymph node located on the median, directly on the ventral side of the median sacral artery (as shown in [Figure 23](#)). In 2 cases, the lymph node was doubled on one side. The size of the lymph node ranged from 3 to 15 mm. For the absolute and relative weights, see lateral sacral lymph nodes (below).

AFFERENT DRAINAGE (FIGURES [24](#), [26](#), [27](#), [29](#), [31](#), AND [32](#))

The afferent drainage area is difficult to determine due to the inconsistent occurrence of the lymph node. It has been shown that lymph vessels from the tail muscles, sacrum, caudal vertebrae and pelvis (ischium) flow into the lymph node. No lymph vessels of the muscles of the pelvis and thigh drained into the lymph node, although lymph vessels of several muscles (e.g. the *M. biceps* and *M. semitendinosus*), accompanied by the sciatic nerve, ran near the lymph node but did not enter it.

EFFERENT DRAINAGE

One to 3 efferent vessels arise from each lymph node, some of which always drain to the hypogastric lymph nodes, some to the medial iliac lymph node, and some rarely to the lateral sacral lymph node (as shown in [Figures 26](#) and [34](#)).

B. LATERAL SACRAL LYMPH NODES

The lateral sacral lymph node ([Figures 24: 10](#) and [27: 7](#)) lies on each side on the medial side of the *M. piriformis* in the fat between the *M. sacroccygeus ventralis* and the *M. coccygeus*. Usually, the lymph node is partially inserted between the two muscles and is bordered by the hypogastric artery and vein. In 30 dogs examined in more detail, the lateral sacral lymph node was found in only 8 dogs: 6 times on both sides and 1 time each only on the left and right side. In 2 cases, there were 2 lymph nodes lying one behind the other on the left side. The size of the lymph node ranged from 3 to 14 mm. For the relative and absolute weights, see below.

AFFERENT DRAINAGE

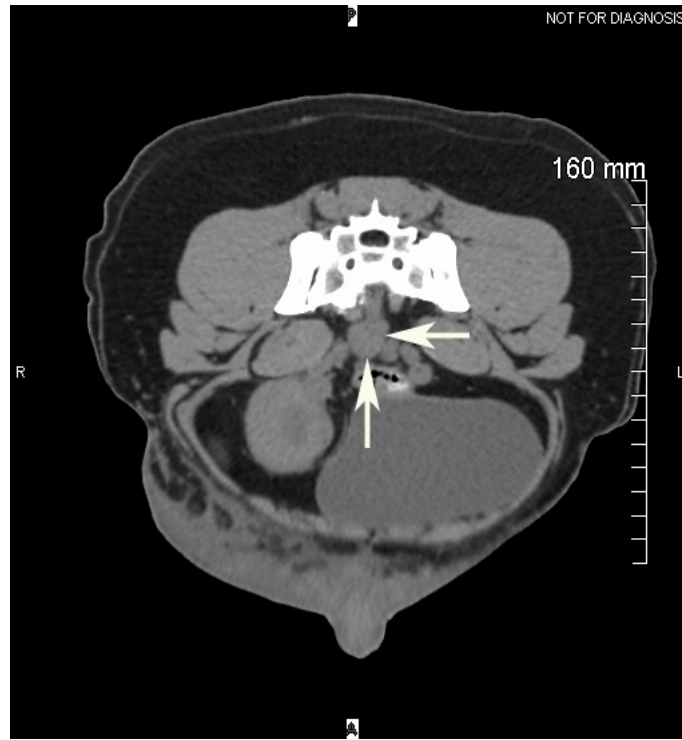
As with the medial sacral lymph node, the infrequent occurrence of the lateral sacral lymph node makes it is very difficult to determine the afferent drainage area. It was shown that the lateral sacral lymph node drains lymph vessels from the sacrum, the caudal vertebrae, the pelvis and femur, from the elevator muscles of the tail and the *Mm. gemelli*, from the uterus, vagina, vaginal vestibule, vulva and clitoris, the prostate, penis, and the male and female urethra. Of the muscles of the pelvis and thigh, only the lymph vessels of the *Mm. gemelli* drained to the lateral sacral lymph node, although lymph vessels draining other muscles (e.g. the *M. gluteus medius*), together with the sciatic nerve, came near the lymph node but did not enter it.

EFFERENT DRAINAGE

Some of the efferent lymph vessels of the lateral sacral lymph node drain to the hypogastric lymph nodes, some to the medial iliac lymph node, and sometimes, some also drain to the contralateral medial or lateral sacral lymph node. The vessels also form a complex network caudal to the hypogastric lymph nodes on the ventral side of the last lumbar vertebra ([Figures 24 and 27](#)).

The absolute and relative weights were determined for all sacral lymph nodes found on both sides. The absolute weight ranged from 0.01 g to 3.13 g, and the relative weight from 0.0004% to 0.0057%.

CLINICAL NOTES



Computed tomographic (CT) image of an enlarged sacral lymph node (arrows) containing metastatic disease, located ventral to the sacrum. Image credit: Dr. Monique Mayer, Western College of Veterinary Medicine, University of Saskatchewan (used under CC BY-NC).

DEEP INGUINAL LYMPH NODES

The deep inguinal lymph node ([Figure 27: 8](#)) is a small lymph node that is found inconsistently in a minority (about one-third) of cases. Of 50 examined dogs, it was only found in 18. Of these 18 dogs, it was found on both sides (5 dogs), only on the left (1 dog), or only on the right (12 dogs), while in the remaining 32 dogs, it was absent. The lymph node is 2 to 11 mm in size and lies on the ventral surface of the tendon of the *M. psoas minor*, at the point where the muscle attaches to the ileopectineal crest, just caudal to the external iliac vein ([Figure 27: k](#)). In regard to the surrounding vessels, the lymph node lies at the angle formed by the external iliac vein and the hypogastric vein ([Figure 27: l'](#)) before both vessels join the common iliac vein (without extending to the apex of the angle), and just dorsal to the branch of the deep femoral artery.

The identification of this lymph node is uncertain. Merzdorf [24] has identified it as a lateral hypogastric lymph node but subsequently added: “whether this is a deep inguinal lymph node is an unanswered question”. Ellenberger-Baum [18] and Chauveau-Arloing [15] both include this lymph node under the classification of medial iliac lymph nodes. I instead identify the lymph node as a deep inguinal lymph node because the afferent drainage area corresponds to that of the deep inguinal lymph node identified in cattle (see Baum [6], page 41). The deep inguinal lymph node should be considered an accessory to the medial iliac lymph node group, or at least as a lymph node split off from the medial iliac group, because when the deep inguinal lymph node is absent its afferent vessels drain directly to the medial iliac lymph nodes in both the dog and the cow. Despite this, it should be given a separate name, because it corresponds to the deep inguinal lymph nodes present in some animal species (e.g. horses) and is located in the femoral canal.

AFFERENT DRAINAGE

The deep inguinal lymph node drains some of the lymph vessels ascending in the femoral canal. In the absence of the deep inguinal lymph node, these vessels drain directly to the medial iliac lymph nodes. This behaviour was demonstrated for the lymph vessels draining the following structures: the *Mm. glutei*, the *M. tensor fasciae latae*, *biceps*, *semitendinosus*, *semimembranosus*, *gracilis*, *pectineus*, *adductor*, *sartorius*, *quadratus femoris*, *obturatorius externus*, *quadriceps*, *M. tibialis anterior* and tendon, *M. extensor digitalis longus* and *lateralis*, *Mm. peronei*, *M. gastrocnemius* and tendon, *M. flexor digitalis sublimis* and *profundus* and tendons, *M. popliteus*, *Mm. interossei pedis*, *M. extensor digitalis pedis brevis* and *M. obliquus abdominis internus*, the lymph vessels of the *fascia lata* and *cruris*, of the hip, stifle and tarsal joints and of the femur, patella, tibia, fibula, tarsal and metatarsal bones and the peritoneum, and the efferent lymph vessels from the popliteal lymph node and the superficial inguinal lymph nodes. Often, however, no lymph vessels from the above structures drained into the deep inguinal lymph node, even when the lymph node was present.

EFFERENT DRAINAGE

Several efferent vessels emerge from the deep inguinal lymph node. They immediately merge to form 1 to 2 vessels, which travel over the external iliac vein and the external iliac artery (both surfaces) to the medial iliac lymph node, and occasionally also to the hypogastric lymph nodes, as shown in [Figure 27: 8](#) and [Figure 37: f'](#).

1.7 LYMPH NODES OF THE ABDOMINAL AND PELVIC ORGANS

GENERAL

The canine visceral lymph nodes are notably different from other animal species in that (1) they are sparse in comparison to other species (2) there are fewer groupings of lymph nodes than in most other species (e.g. humans, cattle). This is especially true for the stomach, liver, and pancreas. At the most, the following lymph node groups can be categorized for the abdominal cavity viscera:

1. **Hepatic lymph nodes** (*Lnn. portarum*)¹, which lie on the trunk of the portal vein and drain the liver, stomach, pancreas, and duodenum
2. **Splenic lymph nodes** (*Lnn. lienales*) on the splenic vein
3. Occasionally, a **gastric lymph node** (*Ln. gastricus*) on the stomach
4. Occasionally, an **omental lymph node** (*Ln. omentalis*) in the omentum
5. Almost always, a **duodenal lymph node** (*Ln. duodenalis*) on the duodenum
6. **Jejunal lymph nodes** (*Lnn. jejunales*) on the jejunum and ileum
7. **Colic lymph nodes** (*Lnn. colici*) for the whole colon

The visceral lymph nodes are generally quite difficult to find because, due to their mostly light gray or less commonly brown color, they are barely demarcated from the surrounding mesenteric fat; this is especially true in cases in which the lymph nodes are so flattened that they appear almost ribbon-like (see hepatic lymph nodes). They can be found more easily by palpation of the entire mesentery and, above all, by injecting lymph vessels that drain to the lymph nodes. A total of 10 to 22 visceral lymph nodes were found in each of the 24 dogs examined. Most of the lymph nodes were of variable size, found individually or in groups, between the sheets of the intestinal mesentery and the omentum, and on the portal vein and its branches.

The sizes of the visceral lymph nodes are highly variable. With the exception of the lymph nodes located in the jejunal mesentery, which can be up to 20 cm long, 2 cm wide, and 1 cm thick, the visceral lymph nodes can reach a size of up to 6 cm in length, 1.5 cm in width, and 1 cm in thickness in large dogs, or be as small as a few millimeters. It is important to note that it is not uncommon for their shapes to be irregular, and so flattened that they appear to be ribbon-shaped. A ribbon shape was particularly common for the hepatic lymph nodes (see hepatic lymph nodes).

¹ According to the *Nomina Anatomica Veterinaria*, the *Lnn. portarum* have been renamed to *Lnn. hepatici [portales]*. We have chosen to use the term hepatic instead of portal in the English translation.

HEPATIC LYMPH NODES

The hepatic lymph nodes are located on the trunk of the portal vein and can be divided into two groups: the left hepatic lymph nodes ([Figures 26: c; 28: 1](#)) and the right hepatic lymph nodes ([Figures 25: s; 26: b; and 28](#)). The drainage areas of both the right and left lymph nodes are the liver, stomach, pancreas, and duodenum.

A. LEFT HEPATIC LYMPH NODES

The left hepatic lymph node ([Figures 26: c, 28: 1](#)) is a somewhat elongated, usually slightly flattened lymph node, located to the left of and slightly dorsal to the trunk of the portal vein ([Figure 26: 14](#)), dorsal on the initial part of the duodenum ([Figure 26: 2](#)), and at the apex of the pancreatic loop ([Figure 26: 3, 3'](#)). The lymph node usually extends caudally to the gastrosplenic vein. In 5 of 25 cases, the caudal one-quarter of the lymph node extended beyond the gastrosplenic vein, and in 4 cases the lymph node bent at the gastrosplenic vein and extended along the vein's cranial border towards the junction of the gastric vein and the splenic vein. In 4 cases, there was a 2nd, smaller lymph node, which, in 2 of the cases, lay on the caudal border of the gastrosplenic vein. In another case, there were 3 left hepatic lymph nodes. The left hepatic lymph node is the structure that is often termed the Pancreas of Aselli and is also named as such in the *Anatomy of the Dog* by Ellenberger and Baum. The size of the lymph nodes ranged from 1 to 6 cm, and the lymph nodes were at times so flattened that they appeared ribbon-shaped.

AFFERENT DRAINAGE

The left hepatic lymph node drains lymph vessels from the esophagus, stomach, liver and gall bladder, the pancreas, diaphragm, mediastinum and peritoneum, as well as the efferent lymph vessels of the gastric lymph node and the right hepatic lymph nodes.

EFFERENT DRAINAGE

The efferent lymph vessels emerging from the left hepatic lymph node merge to form 2 to 3 vessels, which join the efferent lymph vessels of the splenic lymph nodes (see splenic lymph nodes) to form the intestinal trunk, or the network of vessels acting as the intestinal trunk. There is retrograde flow to the splenic lymph nodes from the efferent vessels of the left hepatic lymph node. If there are several left hepatic lymph nodes, efferent vessels connect these lymph nodes, just as efferent vessels connect the left hepatic lymph node with the right hepatic lymph nodes ([Figure 24: 1](#)).

B. RIGHT HEPATIC LYMPH NODES

The right hepatic lymph nodes ([Figures 25: 3; 26: b; and 28: 2](#)) are a group of 1 to 5 lymph nodes of various sizes, located on the right side of the trunk of either the portal vein or the mesenteric vein. The number of right hepatic lymph nodes is highly variable. In 3 of 24 cases, there was only a single elongated, flat lymph node, which extended caudally from the gastroduodenal vein to the ileocolic vein and the right colic lymph node. In 9 cases, 2 lymph nodes, located one behind the other, were found at the described location. In the remaining cases, 3 to 5 lymph nodes were observed at the same location, almost always located one behind the other. In only 1 case, 2 of the lymph nodes were located one behind the other, while the 3rd lymph node extended across the dorsal aspect of the portal vein to the left hepatic lymph node. It is not uncommon for these lymph nodes to be so flat that they appear ribbon-shaped. Their sizes ranged between 1 and 5 cm.

AFFERENT DRAINAGE

The right hepatic lymph nodes drain the lymph vessels from the stomach, duodenum, pancreas, liver, and gall bladder, as well as the efferent lymph vessels of the duodenal lymph node, the omental lymph node, and the left hepatic lymph node.

EFFERENT DRAINAGE

The efferent vessels of the right hepatic lymph node(s) merge to form 4 to 8 larger vessels, which run over both of the surfaces of the portal vein towards the cranial mesenteric artery and contribute to the network of vessels acting as the intestinal trunk. If there are several lymph nodes present, they are also connected to one another in the same way that efferent vessels connect the right hepatic lymph nodes with the left hepatic lymph node ([Figure 24: 2](#)).

SPLENIC LYMPH NODES

The splenic lymph nodes are shown in [Figures 26: d, d'](#) and [28: 8, 8'](#)). The splenic lymph nodes consist of a group of lymph nodes that occur in the dorsal wall of the omental bursa in very inconstant numbers (1 to 5 lymph nodes) and size and are grouped around the splenic artery and vein, along with their two terminal branches. These lymph nodes lie on either the cranial or caudal border of the splenic vein, after both gastric veins have branched off (Figure 26: *d*), either at the angle formed by the branches (Figure 26: *d'*), or on the terminal branches of the veins, but are most commonly found either on the cranial border of the splenic vein, or at the angle formed by the branches of the gastric veins. Rarely, one of the splenic lymph nodes may extend to the right over the gastric vein, in such a way that it is in direct contact with the left hepatic lymph node. The sizes of the splenic lymph nodes range between 5 mm and 4 cm.

AFFERENT DRAINAGE

The splenic lymph nodes drain lymph vessels from the esophagus, stomach and pancreas, spleen and liver, diaphragm, mediastinum, and omentum, as well as the efferent lymph vessels of the gastric lymph node.

EFFERENT DRAINAGE

If several splenic lymph nodes are present ([Figures 24: 3, 3'](#); [26: d, d'](#)), they are connected to one another through their efferent vessels. However, individual efferent vessels may also merge directly with the 2 to 3 efferent vessels of the lymph node located furthest to the left on the trunk of the splenic vein, as shown in [Figure 23](#), contributing to the vessels of the intestinal trunk or the vessel network that represents it (see intestinal trunk). The efferent vessels of the splenic lymph nodes unite with the efferent vessels of the left hepatic lymph node, allowing for retrograde flow.

GASTRIC LYMPH NODES

The gastric lymph node ([Figure 26: o](#)) is a small, rarely doubled lymph node that is located on the lesser curvature of the stomach near the pylorus, though it is not always present. It was found 10 times in 14 examined cases, and its size ranged from 5 to 25 mm.

AFFERENT DRAINAGE

The gastric lymph node drains the lymph vessels from the esophagus, stomach, liver, diaphragm, mediastinum, and peritoneum.

EFFERENT DRAINAGE

The 1 to 2 efferent vessels leaving the node drain into the left hepatic lymph node ([Figure 26: c](#)), and occasionally into one of the splenic lymph nodes as well, located on the trunk of the splenic vein. If there are 2 gastric lymph nodes, they are then connected by efferent vessels, but are otherwise as described above.

OMENTAL LYMPH NODES

The omental lymph node ([Figure 25: l](#)) is 4 to 10 mm in size, and is found in only about half of all cases. It is sometimes found as a double lymph node and may even be tripled. It is embedded in the dorsal wall of the omental bursa about 2 to 5 cm from the duodenum. It was found 6 times in 12 examined dogs; 1 lymph node was found in 3 dogs, 2 lymph nodes were found in 2 dogs, and 3 lymph nodes were found in 1 dog.

AFFERENT DRAINAGE

The omental lymph node drains the lymph vessels of the omentum (but not the lymph vessels of the duodenum).

EFFERENT DRAINAGE (FIGURE 25)

The efferent vessels of the omental lymph node usually merge to form a single small vessel that travels over the pancreas to either a right hepatic or right colic lymph node, uniting along the way with one of the efferent vessels of the duodenal lymph node. Because of this connection, retrograde flow can be observed from the duodenal lymph node to the omental lymph node. Another efferent vessel of the omental lymph node may also be found to drain directly to the duodenal lymph node.

DUODENAL LYMPH NODES

The duodenal lymph node ([Figures 25: 2; 26: a](#)) is a smaller lymph node that is either found on the *flexura prima duodeni*, between the intestinal wall and the right lobe of the pancreas, or just ventral to the pancreas on the medial side of the duodenum, but not between the lobes of the pancreas. Of 24 cases examined, the lymph node was absent in 2.

AFFERENT DRAINAGE

The duodenal lymph node drains lymph vessels from the stomach, duodenum, pancreas, and omentum, as well as the efferent vessels of the omental lymph node.

EFFERENT DRAINAGE (FIGURES 25 AND 26)

Four to 6 efferent vessels leave the duodenal lymph node and soon merge to form 1 to 2 larger vessels, which travel over the ventral aspect of the pancreas into the right hepatic lymph node. One of the vessels often merges with the efferent lymph vessel of the omental lymph node, allowing for retrograde flow.

JEJUNAL LYMPH NODES

The jejunal lymph nodes ([Figure 25: 6, 6¹, 6²](#)) are the lymph nodes of the jejunum and ileum. They are fairly constant in number and location. They were frequently found to consist of 2 elongated, flattened nodes that taper to somewhat of a point at both ends and were located between the sheets of the long jejunal mesentery, near the jejunal arterial and venous trunks ([Figure 25: 11](#)). Both lymph nodes usually extend from the cranial mesenteric root to the point where the trunks of the jejunal arteries and veins divide into their terminal branches.

One of the lymph nodes ([Figure 25: 6](#)) is usually dorsal and slightly to the right of the aforementioned vascular trunks and is therefore referred to as the right jejunal lymph node, while the second ([Figure 25: 6¹, 6²](#)) is located to the left of the other lymph node and ventrally to the vessels, and is thus referred to as the left jejunal lymph node (see also [Figure 24: 4, 4¹, 4², 4³](#)).

The right jejunal lymph node ([Figure 25: 6](#)) usually lies between the trunk of the jejunal veins and the ileum and can be seen more clearly from the dorsal side of the mesentery. It usually extends to the right colic lymph node ([Figure 25: 5](#)), and there are often 2, or even 3, right jejunal lymph nodes. If there are 2 lymph nodes, the more caudal lymph node is the main lymph node – it may also be discernible as the much larger one. The other lymph node, which is much smaller, is cranial to the main lymph node but is usually still found either between the trunk of the jejunal vein and the ileum, or directly on the trunk of the vein. If there is a 3rd lymph node, it is also quite small and either lies in front of the trunk of the aforementioned vein, or on the border of the vein facing away from the ileum. Occasionally, the smaller lymph nodes are located between the main lymph node and the ileum. In 25 cases examined, 1 lymph node was found in 20 cases, 2 lymph nodes were found in 4 cases, and 3 lymph nodes were found in 1 case.

The left jejunal lymph node ([Figure 25: 6¹](#)) can be seen more clearly from the ventral view of the mesentery. It sometimes extends to the ventral aspect of the middle colic lymph node ([Figure 25: 7](#)). Additionally, there may also be 1 to 2 smaller lymph nodes, either cranial to the main left jejunal lymph node ([Figure 25: 6²](#)) or caudal to it. In 1 case, there were 2 smaller cranial and 2 smaller caudal lymph nodes in addition to the main lymph node, so that there were a total of 5 lymph nodes on the left side. In 25 cases examined, there was 1 lymph node in 21 cases, 2 lymph nodes in 2 cases, 3 lymph nodes in 1 case, and 5 lymph nodes in 1 case.

The sizes of the jejunal lymph nodes range from 0.5 cm to 20 cm in length, 4 mm to 2 cm in width, and 3 mm to 1 cm in thickness.

AFFERENT DRAINAGE

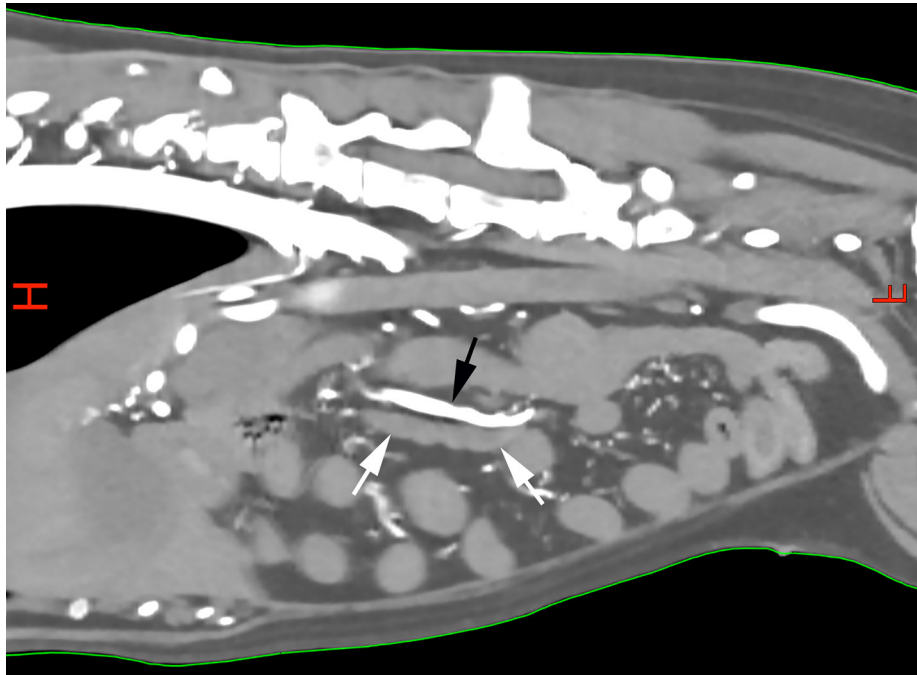
The jejunal lymph nodes drain lymph vessels from the jejunum, ileum, and pancreas.

EFFERENT DRAINAGE

A very large number of efferent vessels emerge from each of the larger jejunal lymph nodes ([Figures 24: 4, 4¹, 4², 4³; 25: 6, 6¹, 6²](#)). These vessels merge with the efferent vessels from neighbouring jejunal lymph nodes, as well as with the efferent vessels from the right colic, middle colic, hepatic, and splenic lymph nodes, forming an extensive vascular network.

From this network, several larger lymph vessels arise and merge to form the intestinal trunk(s) (see intestinal trunk). Due to this network, when the efferent vessels of one lymph node are injected, the injected material fills the efferent vessels of other lymph nodes. Usually, the efferent vessels of the right jejunal lymph node also drain to the right colic lymph node, and the efferent vessels from the left jejunal lymph node drain to the middle colic lymph node, just as the jejunal lymph nodes are connected with each other.

CLINICAL NOTES



Jejunal lymph node (white arrows) ventral to the cranial mesenteric artery (black arrow) on a sagittal multiplanar reconstruction from a contrast-enhanced CT scan of the abdomen of a dog with multicentric lymphoma. Image credit: Dr. Monique Mayer, Western College of Veterinary Medicine, University of Saskatchewan (used under CC BY-NC).

COLIC LYMPH NODES

The colic lymph nodes (Figure 26: *e, f, f, g, g*) are the large intestinal lymph nodes. Since no lymph nodes are found in the ileocecal mesentery, the mesocecum, or the mesorectum, the lymph nodes draining the large intestine are limited to the lymph nodes of the colon, or the colic lymph nodes. The colic lymph nodes can be found individually, or in groups, between the sheets of the short mesocolon or mesorectum. There are anywhere from 3 to 8 such lymph nodes, ranging from 3 mm to 2.5 cm in length. The colic lymph nodes are divided into the right colic, the middle colic, and the left colic lymph node groups.

A. RIGHT COLIC LYMPH NODES

The right colic lymph node (Figures 25: 5, 26: *e*) is an occasionally doubled lymph node which lies just behind the origin of the ascending colon (Figure 26: 7), between the sheets of the mesocolon where the ileocolic vein branches, and more specifically, to the left of the border between the cecum (Figure 26: 6), the ascending colon (Figure 26: 1), and the ileum (Figure 26: 8), at the origin of the branches of the ileocolic vein.

In 25 examined cases, there was 1 lymph node in 19 cases, 2 lymph nodes in 5 cases, and 3 lymph nodes in 1 case.

EFFERENT DRAINAGE

The efferent vessels of the right colic lymph node (Figure 26: *e*) join with the efferent vessels of the jejunal lymph nodes to form an extensive vascular network, from which the lymph vessels converge to form the intestinal trunk (see intestinal trunk).

B. MIDDLE COLIC LYMPH NODES

The middle colic lymph node (Figures 25: 7; 26: *f, f*) is found in the mesentery of the transverse colon (Figure 26: 8), either where the left colic vein joins the middle colic vein (Figure 26: 12), or slightly towards the portal vein from this location. If there is only 1 lymph node, then it is usually situated either against the caudal border of the vein or on the vein itself, and if there are 2 lymph nodes, they are then situated on both borders of the vein (as shown in Figure 26). Usually, the lymph node is located relatively far from the transverse colon, in the mesentery near the jejunal lymph nodes (5 to 7 cm from the transverse colon in large dogs, when the mesentery is tightened), and is sometimes covered on the ventral side by the jejunal lymph nodes (Figure 25: 6²). If there are 2 or 3 middle colic lymph nodes and also a right colic lymph node, then the 2 lymph node groups may almost border each other.

In 25 examined cases, the middle colic lymph nodes were absent in 6 cases, 1 lymph node was present in 12 cases, 2 lymph nodes were present in 5 cases, and 3 or 4 lymph nodes were present in 1 case each.

EFFERENT DRAINAGE (FIGURE 26: F, F)

If there are several lymph nodes, then the individual lymph nodes of the group are usually connected to one another through their efferent vessels. Additionally, several (2 to 4) efferent vessels arise from each lymph node and merge with their neighbouring efferent lymph vessels. The vessels formed in this way drain to the intestinal trunk (Figure 26), and thus these lymph nodes directly drain into the *cisterna chyli*.

C. LEFT COLIC LYMPH NODES

The left colic lymph nodes (Figure 26: g, g) are a group of 2 to 5 lymph nodes, which are in the mesocolon near the mesorectum, where the caudal mesenteric artery and its terminal branches approach the intestine. They are sometimes either found slightly dorsal to the cranial hemorrhoidal artery, which runs towards the thorax, sometimes on the left colic vein near the intestine (in large dogs, when the mesentery is tightened, the lymph node is 2 to 3 cm away from the intestine) or sometimes in the angle between these two vessels.

EFFERENT DRAINAGE (FIGURE 26: G, G)

The individual lymph nodes of the group are usually connected to one another, and only once did I fail to identify these connections through injection of dye solutions. In addition, 1 to 3 efferent vessels emerge from each lymph node, and flow into the medial iliac lymph node (Figure 26: i), the lumbar aortic lymph nodes (Figure 26: h), the middle colic lymph node (Figure 26: f), and occasionally directly into the intestinal trunk (Figure 26: n). The 1 to 2 lymph vessels leading to the middle colic lymph node run irregularly in the mesentery or merge with the corresponding lymph vessels draining the descending colon.

AFFERENT DRAINAGE OF ALL COLIC LYMPH NODES

The colic lymph nodes all drain the lymph vessels of the ileum, cecum, and colon, and the efferent vessels of the left colic lymph nodes drain to the middle colic lymph node.

The absolute weight of the lymph nodes described under Section 1.7 (including the hepatic, splenic, gastric, omental, duodenal, jejunal, and colic lymph nodes), ranged between 0.78 and 27.94 g, and the relative weight between 0.0159% and 1.433%

RENAL LYMPH NODES

There is almost always 1 (but sometimes 2, especially on the left side) lymph node(s) ([Figure 27: 1', 2](#)) on the blood vessels leading to the renal hilus, but I have included it in the lumbar aortic lymph nodes and not as a separate renal lymph node, for the reasons given in the section on lumbar aortic lymph nodes.

SECTION 2

LYMPHATIC TRUNKS AND LYMPHATIC DRAINAGE OF ORGANS

A general description of lymph vessels has already been made in the Introduction at the start of the book. In the following sections, I will also describe the lymph vessels of individual organs and organ systems.

2.1 LYMPHATIC TRUNKS

GENERAL

The lymph vessels of individual organs merge to form several main collecting trunks, the largest and most important of which is the thoracic duct. These trunks also include the large lymphatic trunks which drain the lymph vessels of the head and neck, the abdominal and pelvic cavity organs, and the pelvic limbs; these are termed the right and left tracheal ducts (*ductus trachealis dexter* and *ductus trachealis sinister*), the right lymphatic trunk (*truncus lymphaticus dexter*), the intestinal trunk (*truncus intestinalis*), and the lumbar trunk (*truncus lumbalis*), respectively.

THORACIC DUCT

The thoracic duct begins with a dilation, the *cisterna chyli*, which lies in the aortic hiatus ([Figures 24: 12; 27: 9](#)). Its cranial end narrows to the actual thoracic duct, which is initially located to the right of the median plane, more specifically on the right dorsal border of the thoracic aorta ([Figure 18: 11](#)), up to the 5th or 6th thoracic vertebra. At this point, it gradually crosses to the left side and extends into the precardial mediastinum, connecting to the thoracic inlet ([Figure 17: 15](#)), where it then joins the venous system ([Figures 2 to 7: i, i', i'', i'''](#); 17: 15).

A. CISTERNA CHYLI (PARS ABDOMINALIS OF THE DUCTUS THORACICUS)

The *cisterna chyli* ([Figures 24: 12 and 27: 9](#)) is usually located to the right of and dorsally to the aorta, and usually either extends from the 4th to the 1st lumbar vertebra, less commonly from the 3rd or 2nd lumbar vertebra to either the 1st lumbar vertebra or last thoracic vertebra, or from the 4th lumbar vertebra only to the 2nd lumbar vertebra. Sometimes, the *cisterna chyli* is located more to the dorsal side of the aorta, sometimes more to the right side, and sometimes even ventrally.

The *cisterna chyli* is shaped like an elongated sack, widest in the middle and tapering towards the caudal and cranial ends, though it can also have irregular shapes. The usually doubled, or reticulated, pelvic lymphatic trunk flows into the caudal end of the *cisterna chyli* ([Figures 24: 11; 27: 10](#)), while from the cranial end, the thoracic duct emerges as a gradual narrowing of the *cisterna chyli*, without a sharp distinction between it and the *cisterna chyli* ([Figure 18: 11](#)). If there is only one wide pelvic lymphatic trunk, it merges into the *cisterna chyli* without being sharply distinct from it.

The shape of the *cisterna chyli* is very variable, particularly due to the varying behaviours of the intestinal trunk, which opens into the middle part of the *cisterna chyli* (see intestinal trunk). If the *cisterna chyli* is extremely reticulated, as is often the case, it is not uncommon for it to seem as though the *cisterna chyli* delimits islands through which the corresponding lumbar arteries pass (Huber [[21](#)]).

In addition to the above description of the location of the *cisterna chyli*, it should be added that it is located on the right and dorsal sides of the aorta, between the crura of the diaphragm and the lumbar muscles, on the ventral side of the respective vertebrae, dorsal to the renal artery and vein, and, in its caudal part, to the left of the caudal vena cava (i.e. between the caudal vena cava and the aorta).

B. THORACIC DUCT PROPER

The thoracic duct emerges from the *cisterna chyli* without much distinction (see above) at the 1st lumbar vertebra. It initially runs cranially (Figure 18: 11) on the right-dorsal border of the thoracic aorta, and the ventral border of the azygos vein to the 6th thoracic vertebra, then gradually passes to the left side between the azygos vein and the aorta and then between the aorta and the 5th thoracic vertebra, to run in the precardial mediastinum to the thoracic inlet (Figure 17: 15).

The initial part of the thoracic duct located on the aorta (Figure 18: 11) is rarely just a simple vessel; in most cases it forms coarse networks, leading to the formation of islands through which the intercostal arteries often pass. The initial part of the thoracic duct is infrequently doubled, and if a second duct is present, it lies on the left dorsal border of the thoracic aorta and either emerges separately from the *cisterna chyli* or branches off from the main duct shortly after its origin. It then reunites with the main duct when it crosses from the right to the left side (in rare cases, the ducts merge more cranially). If there are 2 ducts, they are always connected to one another by numerous transverse branches, which also leads to island formation. The branching can be so extensive that the entire thoracic duct consists of a coarse network of lymph vessels. In 1 case, the thoracic duct was observed to emerge as 3 ducts from the *cisterna chyli*.

The terminal portion of the thoracic duct (Figure 17: 15), located in the precardial mediastinum, lies between the *M. longus colli* (Figure 17: 2) and the left subclavian artery (Figure 17: 11) on the left side of the esophagus and crosses near and inside the thoracic inlet on the medial side of the costocervical artery and vein (Figure 17: 14) and the vertebral artery (if it arises independently and not from the costocervical trunk). Immediately cranial to the thoracic inlet, the thoracic duct crosses the lateral side of the left common carotid artery and the medial side of the omocervical trunk (currently termed the superficial cervical artery). The thoracic duct drains into the venous system, just cranial (1 to 3 cm in large dogs) to the 1st rib (see below). The terminal portion of the thoracic duct consists of a simple vessel in about half of all cases, and in the other half of cases, the terminal portion of the duct consists of a coarse network of branches delimiting islands, although not as extensive of a network as present in the initial portion of the duct. The structure of the most terminal portion of the thoracic duct is so highly variable that all variations cannot be described; some of them are shown in Figures 2, 3, 4, 5, 6, 7 and 17. The figures show that the terminal portion of the thoracic duct is rarely simple and undivided (Figures 4, 7). In this case, the thoracic ducts may open either into the left common jugular vein, or at the border of the cranial vena cava with the left common jugular vein, usually on the dorsal or lateral, but occasionally on the ventral or medial, side. However, the thoracic duct most commonly opens at the angle where the common jugular vein branches into both

left jugular veins on the dorsal side.

There is usually an ampoule-shaped widening of the thoracic duct (shown in [Figure 7: i](#)) shortly before it opens into the venous system, but this widening narrows down again so that the opening of the duct into the vein is always very small (about 1 mm in large dogs). In most cases, the terminal portion of the thoracic duct is divided into 2, even 3, or 4 branches ([Figures 2, 3, 5, 6](#) and [17](#)), which all open separately into the venous system. One of these branches behaves as described above for the undivided thoracic duct, while the other terminal branch or branches enter the venous system separately, either at the point where the cranial vena cava divides into the axillary vein and the shortleft common jugular vein, or into the left common jugular vein, or in the angle between the axillary vein and the left common jugular vein, as shown in [Figures 2, 3, 5](#) and [6](#) by *i*, *i'*, *i''* and *i'''*. In 1 case, 1 terminal branch opened into the trunk of the right common jugular vein. It is not uncommon for the individual terminal branches to be connected to one another by transverse vessels, forming islands ([Figure 6](#)). The terminal branches can also widen into an ampoule shape just before they enter the venous system. The efferent vessels of the axillary ([Figures 2, 3, 4, 5: e](#)) and cranial mediastinal ([Figure 17: a](#)) lymph nodes, and usually those of the caudal cervical ([Figure 6: c](#)), middle cervical and superficial cervical ([Figures 2, 4, 6: g](#)) lymph nodes, as well as the left tracheal duct ([Figures 2, 3, 4, 5](#) and [6: f](#)), drain either into the end of the thoracic duct or its terminal branches. In most cases, a small valve was either found at the opening of the thoracic duct into the venous system, or the duct opened into the pocket of a larger venous valve. The connection between the thoracic duct and the venous system seems to always be tightly sealed ([Huber \[21\]](#)).

WIDTH OF THE THORACIC DUCT

In the case of a simple vessel, the width remains mostly constant throughout its entire length and is about 3 to 4 mm in large dogs. When coarse networks with islands are formed, the widths of the vessels are smaller.

VALVES IN THE THORACIC DUCT

The duct has many valves, which are separated by a distance of about 1 to 3 cm in large dogs. Valves are absent in the portion of the thoracic duct that is located between the 11th to 12th thoracic vertebra and the pelvis. The valves are usually fully closed, even in dead animals.

LEFT AND RIGHT TRACHEAL DUCTS

The left tracheal duct (Figures 16 and 2-7: *f*) and right tracheal duct (Figures 8-12: *f*) are two larger lymph vessel trunks, around 2.5 to 4 mm thick in large dogs when filled, which lie on each side of the trachea in the neck region. They arise on each side from the union of the efferent vessels of the medial retropharyngeal lymph node (Figures 2, 4, 6; 8-12; 16: *a, a'*), which usually occurs near the lymph node at the initial part of the trachea, though may less commonly occur further caudally (Figure 10), at times even as far as the cranial edge of the caudal one-third of the neck (Figure 9).

The left tracheal duct runs on the left side of the trachea and esophagus (Figure 16: 6, 7), while the right tracheal duct runs on the right side of the trachea, first together with the common carotid artery and the internal jugular vein on the dorsomedial border of the thyroid gland (Figure 16: 1) (though the right tracheal duct may be somewhat separated from the vessels on the thyroid gland) and then continue together with or near the aforementioned vessels to close to the thoracic inlet. On each side, the tracheal duct receives the efferent vessels of the cranial cervical lymph node (Figures 2, 6; 8, 9, 11; 16: *b, b'*), occasionally one of the efferent vessels of a middle cervical lymph node (Figure 12: *c'*) and of a caudal cervical lymph node (Figure 8: *c*), and the lymph vessels draining the thyroid gland (see lymph vessels of the thyroid gland and Figure 2: 1). The tracheal duct may divide and form an island with a smaller branch (Figure 16: *i, 4*) that later merges back with the main duct. In some cases, there may be several smaller branches.

The terminal part of the tracheal duct behaves differently on the right and left sides. The terminal part of the left tracheal duct usually receives 1 to 2 efferent vessels from the superficial cervical lymph node (see superficial cervical lymph centre and Figures 2, 3, 4, 6; 16: *d, d'*) and may receive an efferent vessel from the left axillary lymph node (Figure 16: *e* and axillary lymph nodes). The left tracheal duct opens somewhat cranially from the left 1st rib (in large dogs 1 to 3 cm from the rib) into the terminal part of the thoracic duct, though a branch of the left tracheal duct may open directly into the venous system. This drainage pattern is highly variable. Of the numerous variations, only the patterns that occur most frequently are listed:

1. The left tracheal duct opens into the end of the thoracic duct (Figure 16);
2. The terminal portion of the left tracheal duct bifurcates, and one branch opens into the end of the thoracic duct, with the other opening into the common jugular vein (Figure 4); the end of the left tracheal duct may even divide into 3 branches (Figure 7);
3. The left tracheal duct opens into a branch of the terminal portion of the thoracic duct (Figures 2, 3, 5, 6).

The terminal part of the right tracheal duct (Figures 8-11: *f*) merges with the efferent vessel(s) of the right superficial cervical lymph node (Figures 8-11: *g*) near the thoracic inlet, 2 to 3 cm cranial from the 1st right rib in large dogs (Figures 8-12: 5). The union of the two results in a short lymphatic trunk,

only 1.5 cm long, even in large dogs, which is approximately twice as thick as the right tracheal duct before the union (4 to 6 mm). This short lymphatic trunk is commonly called the right lymphatic trunk, although there is no specific reason for this separate name.

The right lymphatic trunk ([Figures 8-11: h](#)) lies on the right side of the trachea and the right subclavian vein in front of the right 1st rib and opens either into the right subclavian vein, cranial to its connection to the cranial vena cava, or in the angle between the internal and external jugular veins. The branching and merging of the right lymphatic trunk may form one or several islands. Occasionally, branches of the right lymphatic trunk may enter the venous system directly; the most common variations are shown in [Figures 8-11: h, h'](#). An efferent vessel from the right axillary lymph node usually opens into the right lymphatic trunk or into one of its terminal branches (see axillary lymph nodes and [Figures 9, 10: e](#)).

INTESTINAL TRUNK

The intestinal trunk ([Figure 24: 13, 13](#)) is a large lymph vessel, which originates near the cranial mesenteric artery from the confluence of the efferent vessels of the middle and right colic lymph nodes, the splenic lymph nodes ([Figure 24: 3, 3'](#)), the left hepatic lymph node ([Figure 24: 2](#)), the right hepatic lymph nodes ([Figure 24: 1](#)), the jejunal lymph nodes ([Figure 24: 4, 4¹, 4², 4³](#)), and the more cranially located lumbar aortic lymph nodes ([Figure 24: 5](#)), including the cranial lumbar aortic lymph node ([Figure 24: 6](#)).

The intestinal trunk travels upwards on the right side of the cranial mesenteric artery ([Figure 24: p](#)), but may be slightly cranial and to the right of it, and opens into approximately the middle of the *cisterna chyli* ([Figure 24: 12](#)). The confluence of these efferent vessels into the intestinal trunk is not clearly defined because of the extensive network formation by the efferent vessels (see following).

In some cases, the intestinal trunk may be doubled or even tripled, or individual lymph vessels of the aforementioned network may open separately into the *cisterna chyli* (as in [Figure 24](#)), and there may even be no distinct intestinal trunk(s) at all, instead, several thicker vessels of varying sizes emerge from the extensive network of the efferent vessels of the jejunal lymph nodes, middle and right colic lymph nodes, splenic lymph nodes, etc. (the *rete intestinale* or intestinal network) and open separately into the *cisterna chyli*. These thicker vessels emerging from the extensive network of efferent vessels enter the *cisterna chyli* at different points; they may first either cross over the left or right side of the aorta and sink in the dorsal wall of the *cisterna chyli*.

The aforementioned intestinal network frequently extends very close to the *cisterna chyli*, often so close to it that the small lymphatic trunks leaving the network and opening into the *cisterna chyli* are very short. The aorta may in fact even be wrapped in a network of lymph vessels.

Since the efferent vessels of the lymph nodes mentioned above are connected in a network, it was noted that when the efferent vessels of one of the lymph nodes are filled, the efferent vessels of the other lymph nodes fill in a retrograde manner; this occurs to a greater extent if the outflow of the lymph is impeded

for any reason: i.e. if congestion of this portion of the lymphatic system occurs, lymph from one of the lymph nodes (e.g. a jejunal lymph node) can then flow to all the other lymph nodes (the right and middle colic lymph nodes, hepatic lymph nodes, splenic lymph nodes, and other jejunal lymph nodes).

LUMBAR TRUNK (PELVIC LYMPH TRUNK)

The lumbar trunk ([Figures 24: 11; 27: 10](#)) has an extraordinarily large number of variations. Usually, there are 2 lumbar trunks, a larger one on the left-dorsal or the dorsal border of the aorta, and a smaller one on the right-ventral border of the aorta (Figure 24: *i*), as shown in Figure 24.

Each of the two trunks originates from the efferent vessels of the medial iliac lymph node (Figures 24: 7, 7¹; 27: 4, 4¹). Both trunks, however, are connected to one another by numerous transverse and oblique connecting branches, which run over the two surfaces of the aorta, particularly the ventral surface, so that a coarse network of lymph vessels is created (Figure 24), which delimits numerous islands. Individual branches that separate from this network usually open directly into the *cisternachyli*. It is not unusual for one of the lymphatic trunks to flow around a large island.

Sometimes the left dorsal trunk is absent, and only the right ventral trunk is present, which then becomes larger, as Figure 27 shows. Nonetheless, even when the left dorsal trunk is absent, there is still a branched network of lymph vessels surrounding the aorta, as shown in Figure 27. The lumbar trunk may also merge into the *cisterna chyli* with nearly no distinct boundary (see above). Occasionally, there are 3 connected lumbar trunks: a right-ventral trunk, a right-dorsal trunk, and a left-dorsal or directly dorsal trunk; the latter is larger than the other two.

2.2 LYMPH VESSELS OF THE SKIN

GENERAL

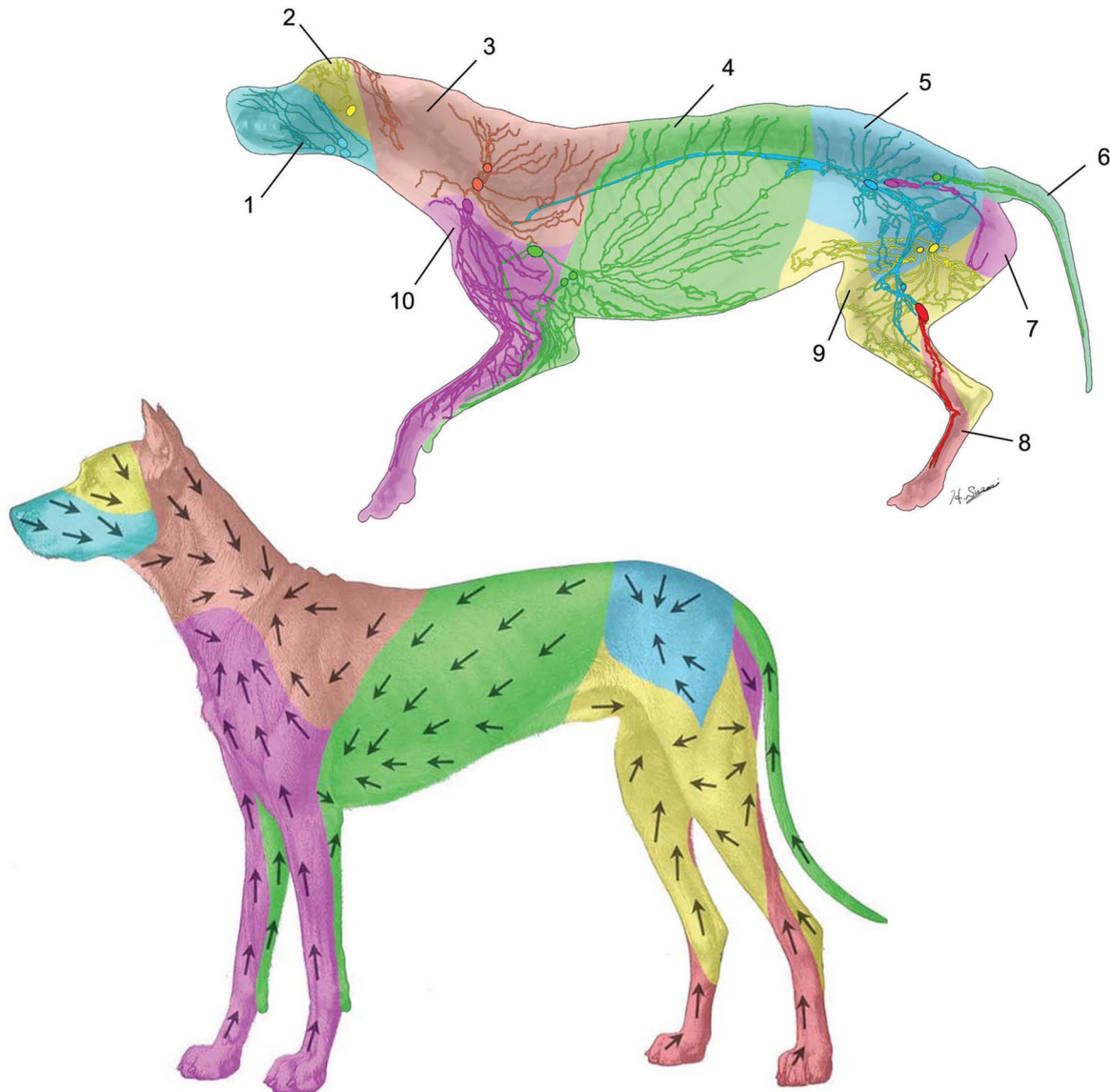
I have described the behaviour of the lymph vessels of the dog's skin in a special article in the *Anatomischer Anzeiger*, Vol. 50, 1917; in the following section, therefore, only the more important results will be described, and reference to the published article is recommended for further details. My investigations into the general behaviour of the skin lymph vessels have shown that:

1. Several (2 to 4) lymph vessels can fill up from one puncture site;
2. Skin lymph vessels in dogs can cross the median plane and open into lymph nodes on the other side of the body (this applies mainly to lymph vessels from the median areas of the skin);
3. In dogs, as in other species, the skin can be divided into defined areas according to the specific lymph nodes that drain those areas.

Lymph vessels on the borders between individual areas will very often drain to the lymph nodes for both areas (for example, in [Figure 13](#), this is demonstrated by the lymph vessels of the skin of the lateral and ventral thoracic wall). In dogs, the lymph vessels of the skin form coarse networks as they travel to and from the lymph nodes (also shown in Figure 13) to a much greater extent than that of the cow. There is limited information regarding the behaviour of the cutaneous lymph vessels in relation to the cutaneous blood vessels. It is, however, certain that the statement made in most textbooks, that the skin lymph vessels usually accompany the larger skin veins, does not apply to the dog, as can be seen in Figure 13. However, the statement that some of the lymph vessels do run with the larger skin veins is certainly correct.

LYMPHOSOMES OF THE DOG

Source: Suami H, Yamashita S, Soto-Miranda MA, Chang DW. Lymphatic territories (lymphosomes) in a canine: an animal model for investigation of postoperative lymphatic alterations. PLoS One. 2013 Jul 24;8(7):e69222. Images used with permission from Dr. Hiroo Suami.



Colour-Coded Diagram of 10 Superficial Lymphatic Territories (Lymphosomes) of the Integument showing Afferent Lymph Vessels and Lymph Nodes (top image), and Direction of Lymph Flow (bottom image): 1 mandibular; 2 parotid; 3 dorsal superficial cervical; 4 axillary; 5 medial iliac; 6 lateral sacral; 7 hypogastric (internal iliac); 8 popliteal; 9 superficial inguinal; 10 ventral superficial cervical. The number of lymph nodes in each lymphosome varied from 1 to 3. The lymph vessels were interconnected within the same lymphosome but not with the neighbouring territory. Source: Suami H, Yamashita S, Soto-Miranda MA, Chang DW. (2013). Lymphatic Territories (Lymphosomes) in a Canine: An Animal Model for Investigation of Postoperative Lymphatic Alterations. PLoS ONE 8(7): e69222 (images used under CC BY 4.0).

LYMPH VESSELS OF THE SKIN OF THE HEAD

The lymph vessels of the skin of the head ([Figure 13](#)) mostly drain to the mandibular lymph nodes (Figure 13: 2, 2', 2''), and less frequently to the parotid lymph node (Figure 13: 1) and superficial cervical lymph nodes (Figure 13: 3). The lymph vessels of the skin of the lips and the outer nose, the cheek area, the rostral half of the lateral nasal region, and the bridge of the nose drain to the mandibular lymph nodes, whereas the lymph vessels of the skin of the caudal part of the dorsum of the nose, the lateral region of the nose, the eyelids, the forehead region, and the region of the zygomatic arch mostly drain to the parotid lymph node, and to a lesser extent to the mandibular lymph nodes.

The lymph vessels of the skin of the intermandibular region drain to the mandibular lymph nodes, often crossing the median plane, the lymph vessels of the skin of the rostral crest of the head region drain to the parotid lymph node, the lymph vessels of the skin of the caudal crest of the head region drain to the superficial cervical lymph nodes, the lymph vessels of the skin of the masseter and parotid regions drain to the mandibular and superficial cervical lymph nodes, and the lymph vessels of the skin of the pinna drain mostly to the superficial cervical lymph nodes and to a lesser extent to the medial retropharyngeal and parotid lymph nodes (for details, see the lymph vessels of the pinna).

LYMPH VESSELS OF THE SKIN OF THE NECK

The lymph vessels of the skin of the back of the neck drain to the superficial cervical lymph nodes (Figure 13: 3), the lymph vessels of the skin of the cranial half of the front of the neck drain to the mandibular lymph nodes (Figure 13: 2, 2', 2''), and the lymph vessels of the skin of the caudal half of the front of neck drain to the superficial cervical lymph nodes (Figure 13: 3, 3').

LYMPH VESSELS OF THE SKIN OF THE FORELIMB

The lymph vessels of the skin of the forelimb mainly drain to the superficial cervical lymph nodes (Figure 13: 3, 3'), to a lesser extent the axillary lymph node and possibly the accessory axillary lymph node (Figure 13: 4). The efferent vessels from the paw and antebrachium merge to form 3 to 6 larger vessels, of which some travel proximally with the accessory cephalic vein on the cranial aspect of the antebrachium, and some with the antebrachial cephalic vein on the medial side of the antebrachium, up to the caudal side of the antebrachium and the medial side of the elbow joint. From here, the lymph vessels travel proximally, some together with the superficial connecting branch of the cephalic vein, to the external jugular vein, and some on the superficial pectoral muscles, on the *pars clavicularis* of the *M. brachiocephalicus* (Figure 13: g) and over the *M. deltoideus* (Figure 13: h), to all drain into the superficial cervical lymph nodes, most likely to the ventral-most lymph node in the group (Figure 13: g').

The lymph vessels of the skin of the lateral side of the elbow joint, including the olecranon, and from the lateral side of the upper limb area, all drain, as shown in Figure 13, to the superficial cervical lymph nodes.

The lymph vessels of the skin on the caudal aspect of the shoulder, brachium, and elbow joint (Figure 13: 13', 8¹) run around the posterior border of the shoulder and brachium muscles to the medial aspect, and accompany the lymph vessels of the lateral thoracic wall to drain to the axillary lymph node. Some of these vessels will drain first to the accessory axillary lymph node if present.

Most of the lymph vessels of the skin on the medial side of the brachium, including the elbow joint, drain to the superficial cervical lymph nodes. Only the lymph vessels (or some of the lymph vessels) from a small area of the skin on the medial side of the olecranon and on the medial side of the brachium near its caudal border turn directly upwards, joining the lymph vessels draining the lateral thoracic wall, and drain into the axillary lymph nodes, with some draining to the accessory axillary lymph node if present.

LYMPH VESSELS OF THE SKIN OF THE DORSAL, LATERAL, AND VENTRAL THORACIC WALL

The lymph vessels of the dorsal, lateral and ventral thoracic wall, in the region caudal to the muscles of the shoulder and brachium (Figure 13), drain to the axillary lymph node (Figure 13: 13) and to a lesser extent to the superficial cervical lymph nodes (Figure 13: 3, 3'). Lymph drainage to the superficial cervical lymph nodes occurs from the area of the skin adjacent to the caudal angle of the scapula, as shown in Figure 13. If an accessory axillary lymph node (Figure 13: 4) is present, some of the lymph vessels mentioned above first drain into it before draining into the axillary lymph node.

LYMPH VESSELS OF THE SKIN OF THE VENTRAL AND CRANIAL-VENTRAL THORACIC WALL

The lymph vessels of the skin of the ventral thoracic wall (Figure 13), in the region caudal to the olecranon, drain together with the lymph vessels of the lateral thoracic wall (see lymph vessels of the skin of the dorsal, lateral and ventral thoracic wall) to the axillary lymph node (Figure 13: 13). If an accessory axillary lymph node (Figure 13: 4) is present, some of the lymph vessels drain into it first. The lymph vessels of the skin of the remaining part of the ventral thoracic wall and those of the skin of the cranial thoracic wall drain to the superficial cervical lymph nodes. In the female dog, lymph vessels, particularly those of the skin of the cranial 2 or 3 teats, may enter the thoracic cavity and drain into the sternal lymph node (see lymph vessels of the mammary glands).

LYMPH VESSELS OF THE SKIN OF THE DORSAL, LATERAL, AND VENTRAL ABDOMINAL WALL

A. CRANIAL TO A TRANSVERSE PLANE THROUGH THE LAST RIB

The lymph vessels of the part of the abdominal wall ([Figure 13](#)) that is cranial to the transverse plane that occurs upon cutting through the last rib all drain into the axillary lymph node, accompanying the lymph vessels of the lateral wall of the chest (see lymph vessels of the lateral wall of the chest).

B. CAUDAL TO A TRANSVERSE PLANE THROUGH THE LAST RIB

The lymph vessels of the part of the abdominal wall that is caudal to the aforementioned transverse plane either drain into the superficial inguinal lymph nodes ([Figure 13: 15](#)) (specifically, the lymph vessels of the skin on the ventral abdominal wall and the ventral half of the lateral abdominal wall) or to the medial iliac lymph node ([Figure 13: 14](#)) (specifically, the lymph vessels of the skin on the dorsal abdominal wall and the dorsal half of the lateral abdominal wall).

LYMPH VESSELS OF THE SKIN OF THE PELVIC LIMBS AND TAIL

The lymph vessels of the skin of the pelvic limbs and the tail ([Figure 13](#)) drain to the medial iliac lymph node, the superficial inguinal lymph nodes, the medial femoral lymph node, and the popliteal lymph node.

A. SKIN OF THE PELVIS

The lymph vessels of the skin of the pelvis drain to the medial iliac lymph node (from the cranial two-thirds to three-quarters of the pelvic area), and to the superficial inguinal lymph nodes (from the caudal one-quarter to one-third of the pelvic area). The latter lymph vessels ([Figure 13: 8](#)) run to the ischial tuberosity and accompany the lymph vessels draining the skin of the tail around the ischial tuberosity to the medial surface of the thigh, travelling along it to the superficial inguinal lymph nodes.

B. SKIN AT THE BASE OF THE TAIL

The lymph vessels of the skin at the base of the tail drain to the medial iliac lymph node, and the lymph vessels of the skin from the rest of the tail drain to the superficial inguinal lymph nodes, turning ventrally around the medial part of the ischial tuberosity ([Figure 13: 8^s](#)).

C. SKIN OF THE LATERAL THIGH

The lymph vessels of the skin of the cranial half of the lateral thigh (Figure 13: 8⁷) course around the cranial border of the thigh muscles and drain to the superficial inguinal lymph nodes. The lymph vessels of the skin of the caudal half of the lateral thigh (Figure 13: 8⁶) also drain to the superficial inguinal lymph nodes; most of the vessels wrap around the caudal border of the thigh to the medial side, whereas a smaller number of vessels accompany the lymph vessels of the skin of the cranial half of the lateral thigh. It is not uncommon for one of the lymph vessels of the skin on the lateral side of the thigh to merge with the lymph vessels of the skin of the pelvis, which drain to the medial iliac lymph node (Figure 13: 14). Lymph vessels of the medial side of the thigh drain to the superficial inguinal lymph nodes, and if a medial femoral lymph node is present, some of the vessels will additionally drain into this lymph node.

D. SKIN OF THE LATERAL SIDE OF THE STIFLE JOINT

The lymph vessels of the skin on the cranial half of the lateral side of the stifle joint (Figure 13: 8⁸) curve around the cranial border of the thigh to drain into the superficial inguinal lymph nodes, while the lymph vessels of the skin of the caudal half of the lateral stifle drain into the popliteal lymph node (Figure 13: 5). The lymph vessels of the skin of the medial side of the stifle joint drain to the superficial inguinal lymph nodes, as shown in Figure 13. If a medial femoral lymph node is present (Figure 13: *t*), some of these lymph vessels will drain to it.

E. SKIN OF THE TARSUS

The lymph vessels of the skin of the lateral side of the tarsus drain to the popliteal lymph node (Figure 13: 5), those from the skin on the medial side drain to the superficial inguinal lymph nodes (as shown in Figure 13), and those from the skin on the cranial and caudal sides drain to both lymph node groups. If a medial femoral lymph node (Figure 13: *t*) is present, some of the lymph vessels that otherwise drain to the superficial inguinal lymph nodes will instead drain into it.

F. SKIN OF THE METATARSUS AND TOES

The lymph vessels of the skin of the dorsal and medial sides of the metatarsus and toes travel first to the cranial side of the tarsus: from there, most of the lymph vessels travel over the lateral side of the lower leg to the popliteal lymph node (Figure 13: 5), while 1 or 2 of the lymph vessels (as shown in Figure 13: 17') curve to the medial side of the lower leg and join with the lymph vessels draining to the superficial inguinal lymph nodes. If a medial femoral lymph node (Figure 13: *t*) is present, some of the lymph vessels usually drain to it first. Some of the lymph vessels of the skin of the lateral metatarsus and toes travel over the caudolateral border of the tarsus to the popliteal lymph node (Figure 13: 5), while others curve towards the cranial side of the tarsus (Figure 13: 8⁹) and join the lymph vessels mentioned above, so that 1-2 lymph vessels from the lateral side of the metatarsus will drain to the

superficial inguinal lymph nodes.

Some of the lymph vessels of the skin of the plantar side of the metatarsus and toes join with the lymph vessels draining the skin of the lateral side, while others join the lymph vessels draining the skin of the medial side.

2.3 LYMPH VESSELS OF THE FASCIAE

GENERAL

The general behaviour of the fasciae lymphatics appears to be the exact same in the dog as in the cow. As in the cow, small lymph vessels that emerge from the lymphatic vascular networks for the most part travel on the surface of the fasciae and only penetrate through after a lengthy distance in order to continue on the inner surface of the fasciae. Occasionally, however, the lymph vessels that arise from the networks draining the injection site are already located under the fasciae, i.e. on its inner surface. I was able to demonstrate these lymph vessels in the antebrachial fascia, specifically. The lymph vessels of the antebrachial fascia, lumbodorsal fascia, *fascia lata*, and *fascia cruris* were all noted.

LYMPH VESSELS OF THE ANTEBRACHIAL FASCIA

The lymph vessels of the antebrachial fascia mostly drain to the axillary lymph node, though minimal drainage to the superficial cervical lymph nodes may also be present. The lymph vessels of the fascia that drain to the latter lymph nodes originate from the fascia that covers the dorsolateral side of the antebrachium near the elbow joint. The vessels then curve towards the cephalic vein and travel with it to one of the ventral superficial cervical lymph nodes. All the other lymph vessels of the antebrachial fascia drain to the axillary lymph node. The lymph vessels of the fascia covering the muscles on the caudal side of the antebrachial bones (*fascia antebrachia volaris*) behave as follows:

A. MEDIAL ANTEBRACHIAL FASCIA

The small lymph vessels arising from the lymphatic network of the *fascia antebrachii volaris* curve away from the medial part of the fascia, some towards the radial artery (those from the middle part of this section of fascia), some towards the ulnar artery (those from the distal part of this section of fascia), and some accompany the median artery to the elbow joint. Near the latter, they are joined by the lymph vessels which originate from the proximal part of the *fascia antebrachii volaris* and which either pass between the *M. pronator teres* and the *M. flexor carpi radialis*, or directly through the latter to the median artery. One lymph vessel draining this section of fascia tends to curve over the caudomedial side of the elbow joint towards the brachium and its blood vessels.

B. LATERAL ANTEBRACHIAL FASCIA

The lymph vessels developing from the lateral part of the *fascia antebrachii volaris* emerge from the proximal and middle part of this section of fascia, some through the antebrachial interosseous space, and some between the *M. flexor carpi ulnaris* and the humeral head of the *M. flexor digitalis profun-*

duson one side, and the ulnar head of the *M. flexor digitalis profundus* on the other. These lymph vessels travel more deeply over the medial side of the radius and ulna, cranially towards the median artery, joining the lymph vessels emerging from the antebrachial interosseous space. From the distal part of this section of fascia, the lymph vessels run more deeply between the tendons of the *M. extensor carpi ulnaris* and *M. flexor carpi ulnaris* and, from here, either ascend in the interosseous space or travel over the caudomedial side of the radius to join the lymph vessels from the distal part of the medial section of the *fascia antebrachii volaris* (see section A above). Almost all the lymph vessels of the antebrachial fascia meet near the elbow joint in the vicinity of the median artery, proceeding to accompany the artery and the blood vessels of the brachium as 2 or 3 trunks, and joining the lymph vessels coming from the caudomedial side of the elbow joint (see above), finally terminating by draining into the axillary lymph node.

LYMPH VESSELS OF THE LUMBODORSAL FASCIA

The lymph vessels of the lumbodorsal fascia mostly drain to the cranial lumbar aortic lymph node, and to a smaller extent the medial iliac lymph nodes. These lymph vessels form extensive networks on the fascia. The lymph vessels that arise from the network first travel on the surface of the fascia and then penetrate it to reach the inner surface. The lymph vessels from the cranial three-quarters of the lumbodorsal fascia converge, curving around the lateral border of the *M. longissimus dorsi*. The most cranial of these lymph vessels even run through the last or second to last intercostal space. They then travel along the ventral side of the lumbar muscles, usually accompanied by the *A. and V. lumboabdominalis*, and their branches, to the cranial lumbar aortic lymph node.

The lymph vessels of the caudal quarter of the lumbodorsal fascia merge to form 1 to 2 vessels which travel to the ventral side of the lumbar muscles, just cranial to the lateral iliac angle and around the lateral border of the *M. longissimus dorsi*, and from there travel to the medial iliac lymph node. No lymph vessels were observed draining to the hypogastric lymph nodes.

LYMPH VESSELS OF THE FASCIA LATA

The lymph vessels of the *fascia lata* all travel to the femoral canal, and from there drain into the medial iliac lymph node, as well as to the deep inguinal lymph node, if present. The lymph vessels may take one of two routes to the femoral canal. From the lymph vessel networks on the fascia, 2 to 3 lymph vessels emerge from the caudal half of the fascia and usually travel caudally on the surface of the fascia, then penetrate both the fascia and the cranial border of the *M. biceps* in order to travel with the lymph vessels of this muscle, just above the *M. gastrocnemius* and between the *M. adductor* and *M. semimembranosus* via the caudal side of the femur to the femoral canal. Three to 5 lymph vessels emerge from the networks of the cranial half of the fascia and converge while travelling towards ap-

proximately the middle of the cranial thigh, merging to form at most 2 larger vessels. These vessels then penetrate the cranial belly of the *M. sartorius* and pass under the caudal belly of the same muscle (i.e. over its lateral side) towards the femoral canal, where they join the other lymph vessels and drain with them into the medial iliac lymph node. If a deep inguinal lymph node is present, some of these lymph vessels also usually drain into it.

LYMPH VESSELS OF THE *FASCIA CRURIS*

A small number of the lymph vessels of the *fascia cruris* drain to the popliteal lymph node, though most drain to the medial iliac lymph node and some to the deep inguinal and medial femoral lymph nodes, when present. However, the lymph vessels draining to the medial iliac lymph node take very different paths.

A. MEDIAL SIDE OF THE LOWER LEG

Almost all the lymph vessels of the *fascia cruris* on the medial side of the lower leg join the great saphenous vein and ascend with it to the femoral canal and then to the medial iliac lymph node.

B. LATERAL SIDE OF THE LOWER LEG

i. Proximal (Upper) Half

From this part of the fascia, the lymph vessels run obliquely caudodorsally, penetrating either the aponeurosis (*endaponeurosis*) or the cranial border of the *M. biceps*, and enter the popliteal fossa between the *M. gastrocnemius lateralis* and the stifle joint capsule. From there, the vessels course to the femoral canal where they join the lymph vessels described in A, above.

ii. Distal (Lower) Half

From this part of the fascia, some of the lymph vessels join the small saphenous vein and rise with it to drain to the popliteal lymph node, whereas others travel under the fascia and more deeply between the *M. extensor digitalis longus* and the peroneus muscles, and accompany the anterior tibial artery and vein to the popliteal fossa, where they join with the lymph vessels described in A, above, ascending with them to the medial iliac lymph node.

Some of the lymph vessels of the fascia of the cranial border of the lower leg join the lymph vessels on the lateral side, and some join the lymph vessels on the medial side. If a deep inguinal lymph node is present, some of the aforementioned lymph vessels ascending in the femoral canal will drain to it. If a medial femoral lymph node is present, some of the lymph vessels accompanying the great saphenous vein will drain to it. Rarely, some of the lymph vessels that usually ascend in the femoral canal show somewhat different behaviour, wherein they travel more deeply between the *M. pectineus* and adductor muscles towards the deep femoral artery, and accompany this artery before then rejoining the other lymph vessels of the femoral canal in the abdominal cavity.

2.4 LYMPH VESSELS OF THE SKELETAL MUSCLES AND THEIR TENDONS AND TENDON SHEATHS

GENERAL

I have described the behaviour of the lymph vessels of the muscles, their tendons, and tendon sheaths in detail in the 1917 Veterinary College report [11], so I will limit the following section to the more important findings of my investigations. For more detail, particularly on the general behaviour of these lymph vessels (technique, behaviour relative to the blood vessels, number of lymph node groups belonging to the individual muscles, etc.) one can refer to the aforementioned report. One point should be emphasized, however: the muscular lymph vessels in the dog also form networks to a much greater extent than is the case in the cow.

LYMPH VESSELS OF THE HEAD MUSCLES

The lymph vessels of the muscles of the head (with the exception of the muscles of the eye, the ear, the muscles in the lips, the muscles of the tongue, and the muscles of the hyoid bone, which are described elsewhere) mostly drain to the mandibular lymph nodes, though a smaller number of them drain to the parotid and medial retropharyngeal lymph nodes.

The lymph vessels of the individual head muscles drain to the following lymph nodes: the *M. levator nasolabialis*, *M. caninus*, *M. levator labii superioris proprius*, *M. depressor labii inferioris*, and the cheek muscles drain into the mandibular lymph nodes, the *M. pterygoideus* into the medial retropharyngeal lymph node, the *M. temporalis* and *M. zygomaticus* into the mandibular and parotid lymph nodes, the *M. digastricus* into the mandibular and medial retropharyngeal lymph nodes, and the *M. masseter* into the mandibular, medial retropharyngeal, and parotid lymph nodes.

LYMPH VESSELS OF THE MUSCLES OF THE NECK AND THORAX

The lymph vessels draining the muscles located on the neck and thorax (*Mm. intercostales*, *M. transversus costarum*, *M. serratus dorsalis inspiratorius*, *M. splenius*, *M. iliocostalis*, *M. longissimus dorsi* and *cervicis* and *capitis*, *M. spinalis et semispinalis dorsi* and *cervicis*, *Mm. recti capitis dorsales*, *Mm. obliqui capitis*, *M. sternohyoideus* and *sternothyroideus*, *M. scalenus*, *M. longus colli* and *capitis*, *M. rectuscapitis ventralis*, *M. transversus thoracis*) drain to a large number (8 to 9) of lymph node groups: the cranial mediastinal lymph nodes (almost exclusively to the main cranial mediastinal lymph node), the intercostal lymph node, the sternal lymph node, the lumbar aortic lymph nodes (including the cranial lumbar aortic lymph node), the superficial and deep cervical lymph nodes, and the retropharyngeal lymph nodes.

The lymph vessels of the *M. serratus dorsalis inspiratorius*, *M. longissimus cervicis*, *M. spinalis*, *M. semispinalis dorsi* and *cervicis*, and *M. scalenus* drain to the cranial mediastinal lymph nodes, though if an intercostal lymph node is present, some of the lymph vessels will also drain to it. The *M. transversus thoracis* drains only to the sternal lymph node, the *M. recti capiti dorsales*, the *M. obliqui capitis*, and the *M. rectus capitis ventralis* to the retropharyngeal lymph nodes, the *M. transversus costarum* to the sternal and cranial mediastinal lymph nodes, the *Mm. intercostales* to the sternal, cranial mediastinal, intercostal, and cranial lumbar aortic lymph nodes, the *M. ileocostalis* and *longissimus dorsi* to the lumbar aortic lymph nodes (including the cranial lumbar aortic lymph node) and the cranial mediastinal lymph nodes, the *M. longissimus capitis* to the retropharyngeal lymph nodes and the cranial mediastinal lymph nodes, the *M. longus capitis* and the *M. longus colli* to the medial retropharyngeal, cranial mediastinal, and caudal cervical lymph nodes, and finally the *M. splenius*, *M. sternohyoideus*, and *M. sternothyroideus* drain to the medial retropharyngeal, cranial mediastinal, caudal cervical, and superficial cervical lymph nodes.

LYMPH VESSELS OF THE MUSCLES OF THE TRUNK

The lymph vessels of the trunk muscles (*M. trapezius*, *M. omotransversarius*, *M. brachiocephalicus*, *M. sternomastoideus*, *M. latissimus dorsi*, *M. pectorales*, *M. rhomboideus* and *M. serratus ventralis*) drain to 8 different groups of lymph nodes: the superficial cervical lymph nodes, the axillary and accessory axillary lymph nodes, the retropharyngeal lymph nodes, the cranial mediastinal lymph nodes (almost exclusively to the main cranial mediastinal lymph node), the intercostal lymph node, the cranial lumbar aortic lymph node, and the sternal lymph node.

The lymph vessels of the *M. omotransversarius* and *M. sternomastoidus* drain into the retropharyngeal and superficial cervical lymph nodes, the *M. trapezius* into the superficial cervical lymph nodes, the axillary lymph node and the cranial mediastinal lymph nodes, the *M. brachiocephalicus* into the superficial cervical lymph nodes, the axillary lymph node and the retropharyngeal lymph nodes, the *M. latissimus dorsi* into the axillary lymph node, the cranial mediastinal lymph nodes, the intercostal lymph node and the cranial lumbar aortic lymph node, the *M. pectoralis superficialis* into the superficial cervical lymph nodes and the axillary lymph node, whereas the *M. pectoralis profundus* drains into the superficial cervical, the axillary and the accessory axillary, and the sternal lymph nodes, the *M. rhomboidus* into the superficial cervical lymph nodes, the medial retropharyngeal lymph nodes, the cranial mediastinal lymph nodes and the intercostal lymph node, and the *M. serratus ventralis* into the cranial mediastinal lymph nodes, the intercostal lymph node, the sternal lymph node and the superficial cervical lymph nodes.

LYMPH VESSELS OF THE MUSCLES OF THE FORELIMB

The lymph vessels of the muscles of the forelimb mostly drain to the axillary lymph node, and, to a smaller extent, into the superficial cervical, cranial mediastinal, and intercostal lymph nodes. Lymph vessels of all the muscles of the shoulder and brachium (*M. deltoideus*, *M. supraspinatus*, *M. infraspinatus*, *M. teres minor*, *M. subscapularis*, *M. teres major*, *M. coracobrachialis*, *M. biceps brachii*, *M. brachialis*, *M. triceps* with its three heads, *M. anconeus* and *M. tensor fasciae antebrachii*) drain to the axillary lymph node. The lymph vessels of some of the muscles (namely the *M. deltoideus*, *supraspinatus*, *infraspinatus*, *teres minor* and *subscapularis*) additionally drain into the superficial cervical lymph nodes. The lymph vessels from a single muscle (*M. subscapularis*) drain into either the cranial mediastinal lymph nodes or the intercostal lymph node, in addition to the axillary lymph node and superficial cervical lymph nodes.

The lymph vessels of the muscles of the antebrachium (*M. brachioradialis*, *M. extensor carpi ulnaris*, *M. supinator*, *M. abductor pollicis longus*, *M. pronator quadratus*, *M. pronator teres*, *M. flexor carpi radialis*, *M. flexor carpi ulnaris*, *M. flexor digitalis sublimis* and *M. flexor digitalis profundus*) drain without exception to the axillary lymph node, but this behaviour is limited to the actual muscles: only a very small number of the lymph vessels of the tendons and tendon sheaths drain to the axillary lymph node and, instead, most drain into the superficial cervical lymph nodes. The lymph vessels of the tendons of the *flexor carpi ulnaris* and *flexor carpi radialis* drain only to the axillary lymph node, and the lymph vessels of the tendons of the *extensor carpi radialis*, *extensor digitalis communis*, *extensor digitalis lateralis*, *extensor carpi ulnaris*, *M. abductor pollicis longus*, *flexor digitalis sublimis*, and *flexor digitalis profundus* drain to both to the axillary lymph node and the superficial cervical lymph nodes. The lymph vessels from the antebrachial and carpal parts of the *flexor digitalis sublimis* and *flexor digitalis profundus* drain to the axillary lymph node, while the lymph vessels from the metatarsal and toe parts of these tendons drain to the superficial cervical lymph nodes, a finding that is consistent with the behaviour I observed in the cow. Notably, the lymph vessels of the *Mm. interossei* at the metacarpus as well as the adductors, abductors and flexors of the 1st and 5th toe drain not only to the superficial cervical lymph nodes, but also to the axillary lymph node.

LYMPH VESSELS OF THE MUSCLES OF THE PELVIC LIMBS

The lymph vessels of the muscles of the pelvic limbs, including the lumbar muscles and their tendons, mostly drain to the medial iliac lymph node, the hypogastric lymph nodes, and the popliteal lymph node, with minimal additional drainage to the lumbar aortic lymph nodes (including the cranial lumbar aortic lymph node). If a lateral sacral lymph node is present, a small number of the lymph vessels draining these muscles will also drain into this lymph node. Likewise, when a deep inguinal lymph node is present, some of the muscular lymph vessels that ascend in the femoral canal may additionally enter this lymph node. If the deep inguinal lymph node is absent, which is often the case, these lymph vessels will all drain directly to the medial iliac lymph node. Nonetheless, even if the deep inguinal

lymph node is present, none of the lymph vessels may drain into it. The lymph vessels of the Achilles, the superficial and deep flexor tendons, and *Mm. interossei pedis* behave in the following manner with respect to the medial femoral lymph node: if the lymph node is present, then some of the lymph vessels drain to it. The lymph vessels of some of the lumbar muscles (*M. psoas minor*, *M. ileopsoas*, and *M. quadratus lumborum*) drain to both the lumbar aortic lymph nodes and the medial iliac lymph node, while those of *M. psoas minor* and *M. quadratus lumborum* drain to the hypogastric lymph nodes.

Of the remaining thigh muscles, the lymph vessels of the *M. tensor fasciae latae*, *M. gracilis*, *M. pectineus*, *M. adductor*, *M. sartorius*, and *Mm. gemelli* drain to the medial iliac lymph node, and additionally to the deep inguinal lymph node, when present. The lymph vessels of the *M. obturator internus* drain to the hypogastric lymph nodes, the lymph vessels of the *Mm. glutei* and the *M. obturator externus* to the medial iliac lymph node and possibly to the deep inguinal lymph node and the hypogastric lymph nodes, the lymph vessels of the *M. quadriceps* to the medial iliac lymph node and possibly to the deep inguinal lymph node and popliteal lymph node, the lymph vessels of the *M. biceps femoris*, *M. semitendinosus*, and *M. semimembranosus* to the medial iliac lymph node, and, when a deep inguinal lymph node is present some drain to it, as well as to the hypogastric and popliteal lymph nodes. It was also observed that the *Mm. gemelli* lymph vessels drain to the lateral sacral lymph node.

The lymph vessels of the muscles located on the lower leg, the *M. tibialis anterior*, *M. extensor digitorum longus*, *M. extensor digitorum lateralis*, *M. peroneus longus*, *M. gastrocnemius*, *M. flexor digitorum sublimis* and *profundus*, and the *M. popliteus*, drain to the medial iliac lymph node, and usually to the deep inguinal lymph node, when present. The lymph vessels draining the tendons and tendon sheaths of the *M. extensor digitorum longus* drain to the popliteal lymph node, those of the *extensor digitorum lateralis*, *peroneus longus* and *M. tibialis anterior* drain to the popliteal lymph node, the medial iliac lymph node and possibly to the deep inguinal lymph node, those of the *M. gastrocnemius* and *M. flexor digitorum sublimis* and *profundus* drain into the popliteal lymph node, the medial iliac lymph node, and possibly into the deep inguinal and medial femoral lymph nodes.

For the muscles of the foot, the lymph vessels of the *extensor digitorum pedis brevis* and the *Mm. interossei* drain to the medial iliac lymph node, the popliteal lymph node, and possibly to the deep inguinal and medial femoral lymph nodes as well.

LYMPH VESSELS OF THE TAIL MUSCLES

Some of the lymph vessels of the muscles that raise the tail drain to the lateral sacral lymph node and others drain to the medial sacral lymph node, though, if the sacral lymph nodes are absent, these lymph vessels drain directly to the hypogastric lymph nodes. The lymph vessels of the muscles that lower the tail drain directly to the hypogastric and medial sacral lymph nodes. Rarely, a lymph vessel from these muscles may drain directly to the medial iliac lymph node, bypassing the hypogastric and medial sacral lymph nodes entirely.

LYMPH VESSELS OF THE ABDOMINAL MUSCLES

The lymph vessels of the abdominal muscles drain to the medial iliac lymph node, the cranial lumbar aortic lymph node, the intercostal lymph node, the cranial mediastinal lymph nodes, specifically the main cranial mediastinal lymph node, and the sternal lymph node. The lymph vessels of the *M. obliquus abdominis externus*, *M. obliquus abdominis internus* and *M. transversus abdominis* drain to all the aforementioned lymph node groups, and the lymph vessels of the *M. rectus abdominis* drain to the medial iliac lymph node and the sternal lymph node. In 1 case in which the deep inguinal lymph node was present, the lymph vessels from the *M. obliquus abdominis internus* drained to it, but since this lymph node rarely occurs, this finding is not significant.

LYMPH VESSELS OF THE MUSCLES OF THE SKIN

The lymph vessels of the neck and facial skin muscles drain to the superficial cervical lymph nodes, the mandibular lymph nodes, the parotid lymph node, and the lateral retropharyngeal lymph node. Some of the lymph vessels of the abdominal skin muscles drain to the axillary lymph node and to the accessory axillary lymph node, when present, some drain to the medial iliac lymph node, and some drain to the superficial inguinal lymph nodes.

2.5 LYMPH VESSELS OF THE BONES

GENERAL

The lymph vessels of all the bones of the trunk, the shoulder, and the pelvic limbs, and almost all the bones of the head were injected 2 to 3 times, on average, from each individual bone. More injections were made only when the results from the individual injections were inconsistent. I used the same technique as I described in my work *The Lymphatic System of Cattle* [6]. In the following section, the results will not be described in detail, but only briefly, because a detailed description of these lymphvessels can be found in the *Anatomischer Anzeiger* 1918, Vol. 50 [12].

LYMPH VESSELS OF THE BONES OF THE HEAD

The lymph vessels of the head bones (including the mandible) all drain to the mandibular lymph nodes, the parotid lymph node, and the medial retropharyngeal lymph node. The drainage of the individual bones are as follows: the lymph vessels of the incisive and maxillary bones drain to the mandibular lymph nodes, those of the occipital and sphenoid bones drain to the medial retropharyngeal lymph node, those of the nasal, frontal, and zygomatic bones drain to the parotid lymph node and medial retropharyngeal lymph node, and those of the mandible drain to the parotid lymph node, medial retropharyngeal lymph node, and the mandibular lymph nodes.

LYMPH VESSELS OF THE BONES OF THE TRUNK (VERTEBRAE, RIBS, AND STERNUM)

The lymph vessels of the bones of the trunk mainly drain to lymph nodes located near the spine (medial retropharyngeal lymph node, caudal cervical lymph node, intercostal lymph node, lumbar aortic lymph nodes, hypogastric lymph nodes, sacral lymph nodes) as well as to the cranial mediastinal lymph nodes, almost exclusively the main cranial mediastinal lymph node, and to the sternal lymph node.

The lymph vessels of the cervical vertebrae drain to the medial retropharyngeal lymph node, the caudal cervical lymph node, and the cranial mediastinal lymph nodes, those of the thoracic vertebrae drain to the cranial mediastinal lymph nodes, the cranial lumbar aortic lymph node, and, if an intercostal lymph node is present, also to it, those of the lumbar vertebrae drain to the lumbar aortic lymph nodes (excluding the cranial lumbar aortic lymph node) and to the hypogastric lymph nodes, those of the sacrum drain to the hypogastric lymph nodes and the lateral and medial sacral lymph nodes, those of the coccygeal vertebrae drain to the lateral sacral lymph node and the hypogastric lymph nodes, those of the ribs drain to the cranial mediastinal lymph nodes, the sternal lymph node, and, if an intercostal lymph node is pres-

ent, also to it, and those of the sternum drain to the sternal lymph node.

LYMPH VESSELS OF THE BONES OF THE FORELIMB

The lymph vessels of the bones of the forelimb almost all drain to the axillary lymph node and the superficial cervical lymph nodes (and always to the ventral lymph node in this group), and only a negligibly small number drain to the cranial mediastinal lymph nodes (in the situations where this was the case, the lymph vessels always drained to the main cranial mediastinal lymph node).

The lymph vessels of the individual bones of the phalanges of the toes drain only to the superficial cervical lymph nodes, those of the metacarpal and carpal bones, radius, ulna, and humerus drain to the axillary lymph node and the superficial cervical lymph nodes, and those of the scapula drain to the axillary lymph node, superficial cervical lymph nodes, and the main cranial mediastinal lymph node.

LYMPH VESSELS OF THE BONES OF THE PELVIC LIMBS

The lymph vessels of the bones of the pelvic limbs mostly drain to both the medial iliac lymph node and the popliteal lymph node, as well as to a lesser extent to the hypogastric, the lateral sacral, the deep inguinal and the medial femoral lymph nodes. However, since the latter 3 lymph nodes only rarely occur, this finding is not that important. The lymph vessels of the individual bones drain as follows:

Those of the pelvis drain to the medial iliac, hypogastric, and lateral sacral lymph nodes, those of the femur drain to the medial iliac, hypogastric, and deep inguinal lymph nodes, those of the patella drain to the medial iliac, medial femoral, and deep inguinal lymph nodes, those of the fibula drain to the medial iliac, popliteal, and deep inguinal lymph nodes, those of the tibia and the tarsal and metatarsal bones drain to the medial iliac, popliteal, medial femoral, and deep inguinal lymph nodes, and those of the phalanges drain to the popliteal lymph node.

2.6 LYMPH VESSELS OF THE JOINTS

GENERAL

The following section will only briefly describe the lymph nodes that the lymph vessels of the individual joints drain to. I will not include more detailed information, including the paths the lymph vessels take, the deviations from normal behaviour, etc., because I have already described this in a special article in *Anatomischer Anzeiger*, Vol. 49, 1916, page 512 [9]. Please refer to this article for full details. Only one point should be emphasized: from each individual joint, 2 to 5 lymph vessels arise, merging as they travel away from the joint to form 2 to 3 trunks which form a notable number of coarse networks.

The lymph vessels of the temporomandibular joint, the joints of the shoulder, and the pelvic limbs were injected, and the findings are described in the subsequent sections.

LYMPH VESSELS OF THE TEMPOROMANDIBULAR JOINT

Some of the lymph vessels of the temporomandibular joint drain to the parotid lymph node, and some drain to the mandibular lymph nodes. The lymph vessels that drain to the parotid lymph node consist of 1 to 2 small vessels that emerge from the caudal side of the joint and run directly to the parotid lymph node. The lymph vessel that drains to the mandibular lymph node emerges on the medial side of the joint, between the maxillary tuberosity and the coronoid process of the mandible, travels towards the oral border of the *M. masseter*, and, from there, to the mandibular lymph nodes, specifically to the dorsal mandibular lymph node. In one observed case, a lymph vessel of the temporomandibular joint drained directly to the medial retropharyngeal lymph node.

LYMPH VESSELS OF THE FORELIMB JOINTS

Some of the lymph vessels of the forelimb joints drain to the axillary lymph node and some drain to the superficial cervical lymph nodes. The lymph vessels of the shoulder joint (Figure 36: *c, c, c'*) and the elbow joint (Figure 36: *a*) all drain to the axillary lymph node (Figure 36: *d*), those of the toe joints (Figures 33: *t*; 35: 3, 4, 5, 6) drain to the superficial cervical lymph nodes (Figure 33: 3'), and those of the carpal joint (Figures 35: 1, 1, 1', 1'; 36: *b, b', b''*) drain to both groups of lymph nodes. The lymph vessels that drained to the superficial cervical lymph nodes always drained to the ventral lymph node of that group.

LYMPH VESSELS OF THE JOINTS OF THE PELVIC LIMB

The lymph vessels of the hip joint ([Figure 37: a, a'](#)) and stifle joint ([Figures 34: 1, 2; 37: b, c](#)) drain to the medial iliac lymph node (Figure 37: g), those of the toe joints (Figure 34: 5-8) drain to the popliteal lymph node (Figure 34: a), and those of the tarsal joint (Figures 34: 3, 4 and 37: d, d') drain to both lymph node groups (Figures 34: a; 37: g). If a deep inguinal lymph node (Figure 37: f) is present, some of the lymph vessels from the hip, stifle, and tarsal joints that would otherwise drain directly to the medial iliac lymph node in the absence of a deep inguinal lymph node, then drain into it. Likewise, if a medial femoral lymph node (Figure 37: e) is present, some of the lymph vessels of the stifle and tarsal joints drain to it. Nonetheless, even if this lymph node is present, the lymph vessels may not drain to it.

2.7 LYMPH VESSELS OF THE DIAPHRAGM, PLEURA, AND PERITONEUM

GENERAL

The lymph vessels of the diaphragm, the pleura, and the mediastinum will be described before those of the digestive and respiratory organs, because they are variably connected.

LYMPH VESSELS OF THE DIAPHRAGM

The lymph vessels of the diaphragm ([Figures 17; 18; 27](#)) drain to the middle tracheobronchial, sternal, cranial lumbar aortic, left hepatic, splenic and gastric lymph nodes and showed the following behaviour:

A. LYMPH VESSELS OF THE PARS COSTALIS AND PARS STERNALIS

Most lymph vessels of the *pars costalis* and *pars sternalis* drain to the sternal lymph node, as well as to a lesser extent to lymph nodes located at the stomach (left hepatic, splenic, and gastric lymph nodes), to the middle tracheobronchial lymph node, and to the cranial lumbar aortic lymph nodes. When the muscle layer of the *pars costalis* and *pars sternalis* of the diaphragm is injected by puncture ([Figures 17:7; 18: w](#)), the lymph vessels that fill initially form very coarsely meshed networks under the pleura of these parts of the diaphragm, as shown in [Figures 17 and 18](#).

The lymph vessels arising from these networks travel in 3 different patterns:

Pattern 1

The lymph vessels arise on each side, underneath the pleura, to the point of attachment of the *pars costalis* on the ribs, and merge to form 1 to 2 larger lymph vessels, or trunks, which run ventrally under the pleura at the attachment of the *pars costalis* to the sternum. From there, they then travel under the *M. transversus thoracis*, and, now on the inner surface of the sternum, covered by the *M. transversus thoracis* and accompanied by the *A. and V. mammaria interna*, run on each side of the neck up to the sternal lymph node ([Figures 17: c; 18: 6](#)). Because the 1 to 2 lymph trunks often divide and reunite with their sub-branches, networks with very coarse meshes are created, and in many locations, it appears that 3 to 4 lymph vessels lie next to each other. The subpleural networks also fill up with dye when either the peritoneum of the diaphragm or the subperitoneal portion of the muscles are injected by puncture. It is also interesting to note that lymph vessels can drain to both sternal lymph nodes when only one-half of the diaphragm is injected. For example, in one case, the lymph vessels ran from the left *pars costalis* of the diaphragm together with the left mammary artery and vein to the 4th intercartilage space. From there, only some of the vessels traveled to the left sternal lymph node, while the remainder passed over the median plane and drained into the right sternal lymph node.

Pattern 2

From the aforementioned subpleural network, several subpleural lymph vessels continue on each side near the diaphragmatic pillars. One to 2 of these lymph vessels run towards the heart in the postcardial mediastinum, usually near the *truncus esophagus ventralis* of the vagus nerves, and drain to the middle tracheobronchial lymph node as shown in [Figures 17](#) and [18](#), while 2 to 3 of these lymph vessels ([Figures 17: e,f; 18: 7](#)) enter the abdominal cavity, either with the esophagus or directly through the diaphragmatic muscle near the diaphragmatic tendon, and subsequently to lymph nodes that are located in the abdominal cavity by the stomach, specifically the left hepatic lymph node ([Figure 28: 1](#)), the splenic lymph nodes ([Figure 28: 8](#)), and the gastric lymph node. These lymph vessels demonstrate the same behaviour as those of the end of the esophagus (see lymph vessels of the esophagus), however, individual lymph vessels may also ascend subperitoneally on the diaphragm ([Figure 27: 13](#)) and drain into the cranial lumbar aortic lymph node. For the sake of completeness, it should be emphasized that no lymph vessels drained to the right hepatic lymph nodes, not even those from the right *pars costalis* of the diaphragm. Of course, these lymph vessels and networks do not all fill with each injection.

Pattern 3

Finally, some of the lymph vessels of the *pars costalis* of the diaphragm drain to the cranial lumbar aortic lymph node. These lymph vessels originate from the dorsal aspect of the *pars costalis*, and in contrast to the aforementioned lymph vessels, only some of them run subpleural ([Figures 17: d'; 18:8](#)), and others run subperitoneal ([Figure 27: 12, 13](#)). Both groups curve towards the aortic hiatus. The subpleural lymph vessels either enter the abdominal cavity through the aortic hiatus, or penetrate the muscles close to the aortic hiatus and join the subperitoneal lymph vessels. Finally, all the lymph vessels merge to form 2 to 3 vessels on each side, which drain to the cranial lumbar aortic lymph node.

B. LYMPH VESSELS OF THE PARS LUMBALIS

Most of the lymph vessels of the *pars lumbalis* of the diaphragm ([Figures 17: 7²; 18: w¹; 27: a²](#)) are part of the group described in Pattern 3 above ([Figures 17: d; 18: 8; 27: 13](#)) for the *pars costalis*, while a smaller number are part of the group described in Pattern 2 above, and drain together with the lymph vessels in these groups to the middle tracheobronchial lymph node, the cranial lumbar aortic lymph node, the splenic lymph nodes, and the gastric lymph node. Some of the lymph vessels leading to the three latter groups of lymph nodes can, however, also extend subperitoneally.

C. LYMPH VESSELS OF THE DIAPHRAGMATIC TENDON

The lymph vessels of the diaphragmatic tendon ([Figures 17: 7¹; 18: w²](#)) form extremely rich and fine networks, again subpleural. The lymph vessels arising from these networks merge with the lymph vessels of the muscular part (*pars costalis* and *pars lumbalis*) of the diaphragm and consequently also drain to the same lymph nodes as them.

When the pleura covering the diaphragm is punctured and injected, the same subpleural networks and the lymph vessels developing from them fill as described above under A, B, and C. When the peritoneum covering the diaphragm is punctured and injected, subperitoneal lymph networks fill up on the diaphragmatic muscle, but they do not stand out as clearly as the subpleural networks, which fill at the same time from the subperitoneal networks. There are evidently still intermuscular networks between the subperitoneal and subpleural networks, as described in the cow, although they cannot be recognized macroscopically with absolute certainty in the dog, given the small size of this species. Macroscopic subperitoneal networks could not be detected on the diaphragmatic tendon with certainty even when the peritoneum was punctured, in contrast to the cow (see Baum [\[6\]](#) page 115). The above findings demonstrate that lymph flow must occur from the abdominal cavity to the thoracic cavity side of the diaphragm, which has been previously demonstrated in the cow. Lymph vessels of the peritoneum are connected to the diaphragmatic lymph vessels (see lymph vessels of the peritoneum).

The lymph vessels of the diaphragm were almost all filled by puncture injection because this method is very easy and convenient, however, filling can also be achieved by introducing the coloured injection fluid into either the pleural or peritoneal cavity, or into both, and performing artificial respiration. Respiratory movements were usually performed for several hours. Nonetheless, the filling of the lymph vessels was not nearly as complete as that obtained by injection.

LYMPH VESSELS OF THE COSTAL PLEURA

The lymph vessels of the pleura were almost all filled by puncture injection, as this is the easiest and most convenient method, but they can also be injected by introducing coloured fluid into the pleural sacs and performing artificial respiration as described in *The Lymphatic System of Cattle* [\[6\]](#) on page 117.

The lymph vessels of the costal pleura (see [Figure 19](#)) drain to the sternal lymph node ([Figure 19: 2](#)), the cranial mediastinal lymph nodes (always the main cranial mediastinal lymph nodes in the examined cases) ([Figure 19: 1, 1, 1'](#)), the intercostal lymph node, and the cranial lumbar aortic lymph node. The behaviour of these vessels is very similar to the lymph vessels of the intercostal muscles.

Two to 4 lymph vessels arise from the pleurae of the 1st rib and the 1st intercostal space and drain into

the main cranial mediastinal lymph node, as shown in [Figure 19](#). One lymph vessel usually runs directly to the same lymph node from the middle of the intercostal space. Of the remaining lymph vessels, 1 to 2 curve sharply ventrally and 1 to 2 curve sharply dorsally. One of the lymph vessels arising from the pleurae of the 1st rib and the 1st intercostal space, however, may additionally drain to the sternal lymph node. The lymph vessels of the ventral half of the pleura from the 2nd to 10th ribs and the 2nd to 9th intercostal spaces (Figure 19: *d, d*) turn ventrally and run under the *M. transversus thoracis*, reaching the internal mammary artery and vein and moving with them to drain into the sternal lymph node (Figure 19: 2), while the lymph vessels of the dorsal half of this region (Figure 19: *a, a'*) turn dorsally up to the aorta, and then turn cranially (Figure 19: *b*) to run along the aorta and the *M. longus colli* and drain into the main cranial mediastinal lymph node (Figure 19: *l, l'*), usually merging along the way to form 2 to 3 vessels.

If an intercostal lymph node is present, some of these lymph vessels may drain to it (Figure 19: *ll*). The pleural lymph vessels from the 11th to 13th ribs and 10th to 12th intercostal spaces also turn dorsally up to the vicinity of the aorta, but then run caudally (Figure 19: *c*) and drain to the cranial lumbar aortic lymph node. Only the lymph vessels from a small region at the insertion of the diaphragm at the 10th, 11th, and 12th intercostal spaces (Figure 19: *d'*) turn ventrally and enter the diaphragm (Figure 19: 5) to either merge with diaphragmatic lymph vessels or to merge directly to form 1 to 2 vessels that run cranioventrally at the insertion of the diaphragm, passing under the *M. transversus thoracis* and draining into the sternal lymph node. The lymph vessels of the part of the pleura covering the *M. transversus thoracis* and the sternum penetrate the *M. transversus thoracis* and thus join the lymph vessels mentioned above, draining into the sternal lymph node. These lymph vessels are difficult to inject because the pleura is so thin that there is a risk of penetrating through it into the *M. transversus thoracis*.

As can be seen in Figure 19, puncture injection mainly fills finely meshed lymph networks in the pleura of the intercostal spaces but, although to a lesser extent, in the pleura adjacent to the ribs, as well. I mention the pleural lymph networks adjacent to the ribs specifically because Dybkowsky [16] states that for the pleural lymph vessels of the dog, he was only able to fill lymph networks in the intercostal spaces. This statement was inconsistent with my findings in the dog and in the cow (see Baum [6], page 117), both when the lymph vessels were filled by puncture injection and by artificial respiration. The lymph vessels arising from the lymph networks continue to run subpleurally. In each intercostal space and associated rib, there are usually 2 to 4 lymph vessels, of which 1 to 3 turn both ventrally and dorsally, as described above. Some of the lymph vessels run with the intercostal blood vessels, but some additionally run irregularly, i.e. not accompanied by blood vessels. It is difficult to say which of these two behaviours is more common. Occasionally, one of the lymph vessels of a specific intercostal space runs to its neighbouring intercostal space. I could not determine whether pleural lymph vessels, particularly those of the first intercostal spaces, pass through the intercostal musculature to drain to the axillary lymph node, which occurs in both the human and bovine species, even though I carefully examined 4 to 5 cases to look for this behaviour specifically.

LYMPH VESSELS OF THE MEDIASTINUM

The lymph vessels of the mediastinum (Figure 17: 4, 5, 6, 6¹, 6²) drain to the cranial mediastinal lymph nodes, the sternal lymph node, the middle tracheobronchial lymph node, the cranial lumbar aortic lymph node, the gastric lymph node, the splenic lymph nodes, and the left hepatic lymph node. Extensive, fine lymph vessel networks fill up at the puncture injection site.

The lymph vessel networks can be filled in the same way as those of the costal and diaphragmatic pleura; both by puncture injection and by introducing the injection fluid into the pleural cavity and mimicking respiratory movements.

A. THE LYMPH VESSELS OF THE PRECARDIAL MEDIASTINUM

The lymph vessels of the precardial mediastinum (Figure 17: 4) drain to the cranial mediastinal lymph nodes (Figure 17: a, a¹) and the sternal lymph node (Figure 17: c), as shown in Figure 17. The lymph vessels draining into the cranial mediastinal lymph nodes usually accompany the largest of the *Aa. (Vv.) mediastinales craniales*.

B. THE LYMPH VESSELS FROM THE CARDIAC PART OF THE MEDIASTINUM

The lymph vessels from the cardiac part of the mediastinum (Figure 17: 5) cannot be clearly separated from those of the pericardium.

i. Ventral Half of the Pericardium

Some of the lymph vessels from the ventral half of both the pericardium and the cardiac mediastinum run ventrally towards the sternum, then turn towards the thoracic inlet, accompany the internal mammary artery and vein, and drain to the sternal lymph node (Figure 17: c) while some of these lymph vessels preferentially run with larger cranial mediastinal arteries and veins, and join the lymph vessels of the precardial mediastinum to drain to the cranial mediastinal lymph nodes (Figure 17: a¹, a²). A second group of lymph vessels run dorsally and reach the phrenic nerve, or its vicinity, running with the nerve cranially and draining to the cranial mediastinal lymph nodes (Figure 17: a¹). From many puncture injection sites, the lymph vessels filled in both dorsal and ventral directions.

ii. Dorsal Half of the Pericardium

Most of the lymph vessels from the dorsal half of the pericardium and the cardiac mediastinum join the second group of lymph vessels mentioned above, though some may additionally join the lymph vessels of the postcardiac mediastinum, which pass through the diaphragm, to drain to either the cranial lumbar aortic lymph node or to the gastric, splenic, or left hepatic lymph nodes (see below).

Two to 3 lymph vessels arise from the caudodorsal part of the left pericardial wall and ascend directly in the mediastinum to the middle tracheobronchial lymph node (Figure 17: b').

C. THE LYMPH VESSELS FROM THE POSTCARDIAL PART OF THE MEDIASTINUM

The lymph vessels from the postcardial part of the mediastinum ([Figure 17: 6, 6¹, 6²](#)) drain to the sternal lymph node, the middle tracheobronchial lymph node, and the cranial lumbar aortic lymph node. Some of the lymph vessels from the dorsal part of the postcardial mediastinum, the part extending caudally from the aortic arch, between the thoracic aorta and the esophagus ([Figure 17: 6²](#)), run cranially to the middle tracheobronchial lymph node ([Figure 17: b¹](#)), while others run caudally. Of the lymph vessels running caudally, some join the lymph vessels of the *pars lumbalis* of the diaphragm (see lymph vessels of the diaphragm) and pass with them, through the aortic hiatus, into the abdominal cavity to drain to the cranial lumbar aortic lymph node ([Figure 17: d](#)), while others ([Figure 17: f](#)) join the lymph vessels of the esophagus and enter with them, through the esophageal hiatus, into the abdominal cavity ([Figure 28: 7, 7'](#)) to drain to the gastric, splenic, or left hepatic lymph nodes ([Figure 28: 1, 8](#)).

Most of the lymph vessels from the part of the mediastinum situated directly ventral to the esophagus, between the esophagus and the left phrenic nerve ([Figure 17: 6¹](#)), drain to the middle tracheobronchial lymph node ([Figure 17: b¹](#)). These lymph vessels usually turn towards the *truncusoesophageus ventralis* of the vagus nerves and accompany it to the middle tracheobronchial lymph node, merging into 2 to 3 vessels. A small number of these lymph vessels also join the lymph vessels that penetrate the diaphragm ([Figure 17: e](#)), which are described below.

Lymph vessels from the ventral part of the postcardial mediastinum (the part ventral to the left phrenic nerve) merge to form 3 to 4 vessels, 1 to 2 of which enter the diaphragm near the phrenic nerve, penetrating it at or near the central tendon ([Figure 17: e](#)), and passing under the peritoneum to the esophageal hiatus. From there, the lymph vessels will either drain into the cranial lumbar aortic lymph node or into the gastric, left hepatic, or splenic lymph nodes. Additionally, 1 of these lymph vessels may also join the lymph vessels draining into the middle tracheobronchial lymph node ([Figure 17: b¹](#)). The other 1 to 2 lymph vessels from the ventral part of the postcardial mediastinum either run ventrally or run directly to the diaphragm, travel under the *M. transversus thoracis* with the lymph vessels of the diaphragm, and drain to the sternal lymph node ([Figure 17: c](#)).

The lymph vessels of the *plica vena cava* show the same behaviour as the lymph vessels of the ventral part of the postcardial mediastinum.

LYMPH VESSELS OF THE PERITONEUM

The lymph vessels of the peritoneum drain to the cranial lumbar aortic lymph nodes, the medial iliac lymph nodes, the deep inguinal lymph nodes, the sternal lymph nodes, the left hepatic lymph node, and the gastric lymph node. The lymph vessels from most of the caudal half of the peritoneum run on each side towards the medial iliac lymph node, gradually merging into 2 to 3 vessels, which then turn towards the deep circumflex iliac artery and vein, accompanying them to the aforementioned lymph node. Only the lymph vessels of the peritoneum on the caudal half of the ventral abdominal wall join the caudal epigastric artery and vein as they run towards the inguinal canal, where they join with the external iliac artery and vein to run to the medial iliac lymph node. If a deep inguinal lymph node is present, some of these lymph vessels drain to it.

Most of the lymph vessels from the cranial half of the peritoneum turn in a dorsal direction towards the *A. and V. lumboabdominalis*, accompanying these vessels to drain into the cranial lumbar aortic lymph node. Only the lymph vessels from the part of the cranial half located on the ventral abdominal wall and on the ventral part of the lateral abdominal wall drain to the sternal lymph node; these lymph vessels enter the thoracic cavity at the attachment of the diaphragm to the xiphoid cartilage and accompany the internal mammary artery and vein to the aforementioned lymph node. Some of the lymph vessels from the peritoneum of the part of the lateral and ventral abdominal walls adjoining the diaphragm run to the diaphragm and join the diaphragmatic lymph vessels, flowing with them not only to the cranial lumbar aortic lymph node and sternal lymph node, but also the middle tracheobronchial lymph node, the gastric lymph node, the left hepatic, and even to the splenic lymph nodes.

The following peritoneal lymph vessel behaviours have been directly observed: lymph vessels that either run subperitoneally on the diaphragm to drain to the cranial lumbar aortic lymph node or drain to the sternal lymph node; lymph vessels that pass through the diaphragm, run subpleurally on it and drain to the cranial lumbar aortic and sternal lymph nodes; and lymph vessels that join those of the diaphragm and drain to the left hepatic and gastric lymph nodes. Peritoneal lymph vessels that join the diaphragmatic lymph vessels and drain to the splenic and middle tracheobronchial lymph nodes could not be directly demonstrated, but there is no doubt that such lymph vessels are present. Sometimes they simply may not fill with the injected solution, and often the injection takes too long to perform.

LYMPH VESSELS OF THE OMENTUM

The lymph vessels of the right half of the omentum ([Figures 25: f; 26: 15](#)) are usually accompanied by the blood vessels (veins) as they travel to the omental lymph node ([Figure 25: l](#)) and the duodenal lymph node ([Figures 25: 2; 26: a](#)). In the absence of the omental lymph node, all the lymph vessels drain directly to the duodenal lymph node. The lymph vessels of the left half of the omentum drain to the splenic lymph nodes ([Figures 25: 4; 26: d, d'](#)). The lymph vessels of the ventral and dorsal walls of the omental bursa behave in the same way, except the lymph vessels of the right half of the ventral wall ([Figure 26](#)) drain only to the duodenal lymph node, not to the omental lymph node.

The larger trunks of lymph vessels most likely all run in the strips of fat on the omentum. In one case, a lymph vessel in the dorsal wall of the omental bursa travelled over the pancreas directly to the left hepatic lymph node (Figure 26: *c*).

2.8 LYMPH VESSELS OF THE DIGESTIVE ORGANS

GENERAL

Lymph vessels were found for all the digestive organs.

LYMPH VESSELS OF THE UPPER AND LOWER LIPS

The lymph vessels of the upper lip (see [Figure 13](#)) all drain to both groups of the mandibular lymph nodes. Most of the lymph vessels lie between the skin and the skin muscle, though a smaller number may also penetrate the skin muscle to the inner surface of the muscle. Some lymph vessels run in large, caudodorsally convex arcs along the *M. masseter*, while others run in the intermandibular region (the region between the left and right sides of the body of the mandible).

Interestingly, some of the lymph vessels in the intermandibular region cross the median plane, resulting in the lymph vessels from the left half of the upper lip draining to the right mandibular lymph nodes, and vice versa. The lymph vessels of the lower lip also drain to the mandibular lymph nodes; these lymph vessels join those from the skin of the intermandibular region (see [Figure 13](#)), and some cross the median plane, so that they drain to the lymph nodes on the contralateral side. These behaviours apply to the lymph vessels of all the structures of the lips (skin, musculature, and mucosa). The lymph vessels of the mucosa of the upper lip tend to emerge between the end of the *M. zygomaticus* and the *M. levator nasolabialis*, while those of the mucosa of the lower lip emerge at the ventral edge of the cheek muscle, near the corner of the lip, and then proceed to join the other lymph vessels.

The lymph vessels of both lips were injected 11 times, and in no case did any of the lymph vessels drain to the parotid lymph node, not even from the upper lip. I mention this negative finding because, in the cow, the lymph vessels of both lips drain to the mandibular lymph nodes as well as the parotid lymph node, and even occasionally to the lateral retropharyngeal lymph node. As already mentioned, the lymph vessels of the lips frequently cross the median plane, and I was able to confirm this in smaller dogs with injections made 1 cm lateral to the median plane in one of the lips.

LYMPH VESSELS OF THE TONGUE

A small number of the tongue's lymph vessels drain to the mandibular lymph nodes, but most of the lymph vessels drain to the medial retropharyngeal lymph node. The lymph vessels of the tip of the tongue drain to both groups of lymph nodes, while those of the body and base of the tongue drain only to the medial retropharyngeal lymph node.

A. LYMPH VESSELS OF THE TIP OF THE TONGUE

The lymph vessels of the tip of the tongue (Figure 14: 6, 6', 6'') are divided into two groups: superficial lymph vessels and deep lymph vessels. Some drain to the mandibular lymph nodes (Figure 14: *t*, *t'*), and some drain to the medial retropharyngeal lymph node (Figure 14: *u*). The superficial lymph vessels emerge from under the mucosa on the ventral aspect of the tip of the tongue. Some (Figure 14: 6) run on the outer side of the *M. mylohyoideus* into the mandibular lymph nodes, while others (Figure 14: 6', 6'') curve around either the rostral or the ventral border of the *M. genioglossus* to its medial side and join the deep lymph vessels. The deep lymph vessels emerge between the lingual muscles and run deeply on the lateral and medial sides of the *M. genioglossus*, and then some of the lymph vessels emerge on the ventral border of the *M. styloglossus*, some through the *M. hyoglossus*, and turn over the pharyngeal muscles to drain into the medial retropharyngeal lymph node. At the tip of the tongue, the lymph vessels are always found to cross the median plane, so that when the left half of the tongue is punctured and injected, the lymph vessels also go to the lymph node on the right side, and vice versa.

B. LYMPH VESSELS OF THE BODY OF THE TONGUE

The lymph vessels of the body of the tongue (Figure 14: 5, 7, 7', 8) drain to the medial retropharyngeal lymph node. A small number of vessels run superficially (Figure 14: 7), under the mucous membrane of the lateral surface of the tongue, but most run deeply (Figure 14: 7', 8), under the *M. styloglossus*, though some may run through the *M. hyoglossus* instead (Figure 14: 5), and drain together with the lymph vessels of the tip of the tongue over the pharyngeal muscles into the medial retropharyngeal lymph node.

C. LYMPH VESSELS OF THE BASE OF THE TONGUE

The lymph vessels of the base of the tongue all drain to the medial retropharyngeal lymph node. Some emerge through the *M. hyoglossus* (Figure 14: 5, 5), while others emerge at its caudodorsal border (Figure 14: 4') and continue to travel as 2 to 3 vessels over the pharyngeal muscles to the aforementioned lymph node. Other lymph vessels of the base of the tongue also initially run from the base of the tongue, under the mucous membrane of the pharynx, and penetrate the pharynx muscles: these lymph vessels either emerge through the *M. keratopharyngeus* (Figure 14: 4''), or between it and the *M. thyropharyngeus* (Figure 14: 4), and then run directly to the retropha-

ryngeal lymph node. In most cases, 2 to 3 of the lymph vessels of the base of the tongue demonstrate this behaviour.

D. LYMPH VESSELS OF THE INDIVIDUAL MUSCLES OF THE TONGUE AND HYOID BONE

The lymph vessels of the muscles of the tongue and hyoid bone (*M. mylohyoideus*, *M. geniohyoideus*, *M. genioglossus*, *M. styloglossus*, *M. hyoglossus*, *M. jugulohyoideus*, *M. stylohyoideus* and *M. hyothyroideus*) drain to the medial retropharyngeal lymph node. Additionally, some of the lymph vessels of *M. mylohyoideus* drain to the mandibular lymph nodes (see [Figures 14 and 15](#)).

The lymph vessels of *M. mylohyoideus* (Figures 14, 15: *a*) drain into the mandibular and the medial retropharyngeal lymph nodes. These are tiny lymph vessels that emerge on the outer side of the muscle and then either drain directly to a ventral mandibular lymph node (usually 2 lymph vessels) or run along the *M. hyothyroideus* and the pharyngeal muscles to drain into the medial retropharyngeal lymph node (usually 1 lymph vessel).

The lymph vessels of the *M. geniohyoideus* (Figure 14: *b*) drain to the medial retropharyngeal lymph node (Figure 14: *u*). They emerge either at the dorsal edge of the muscle or in its vicinity. Some of the vessels run over the lateral side of the *M. hyoglossus*, and some run over its medial side, and from there over the pharyngeal muscles to drain into the medial retropharyngeal lymph node.

The lymph vessels of the *M. genioglossus* (Figure 14: *c*) drain to the medial retropharyngeal lymph node (Figure 14: *u*). They emerge from both the cranial aspect and middle one-third of the muscle on its lateral side and run between it and the *M. hyoglossus* aborally, where they merge to form 1 to 3 large, network-forming lymph vessels that run over the pharyngeal muscles into the aforementioned lymph node.

Three to 4 lymph vessels emerge from the *M. styloglossus* (Figure 14: *e*), which drain to the medial retropharyngeal lymph node (Figure 14: *u*). Some may emerge on the medial side of the muscle, some on the ventral border, and occasionally some on the lateral side of the muscle near its ventral border, travelling from the rear (aboral) half of *M. styloglossus* over the pharyngeal muscles, directly to the medial retropharyngeal lymph node. The lymph vessels emerging from the front (oral) half of the muscle usually cross the medial side of the *M. hyoglossus*, often forming large, orally turned loops.

The lymph vessels of the *M. jugulohyoideus* and *M. stylohyoideus* run as 1 to 2 vessels directly on the pharyngeal musculature into the medial retropharyngeal lymph node.

The lymph vessels of the *M. hyoglossus* (Figure 14: *d*) emerge on both of its surfaces and usually merge to form 1 small lymph vessel, which runs over the pharyngeal musculature to drain into the medial retropharyngeal lymph node (Figure 14: *u*).

Three to 4 small lymph vessels emerge from both surfaces of the *M. hyothyroideus* (Figure 14: *p*), and run directly dorsally to the medial retropharyngeal lymph node ([Figure 14: u](#)).

LYMPH VESSELS OF THE MUCOUS MEMBRANE OF THE FREE FLOOR OF THE ORAL CAVITY

Some of the lymph vessels of the mucous membrane of the free floor of the oral cavity drain to the mandibular lymph nodes, whereas others drain into the medial retropharyngeal lymph node. The lymph vessels that drain to the mandibular lymph nodes (1 to 2 small vessels) penetrate the *M. mylohyoideus*, reaching its outer surface, and from there travel directly into the mandibular lymph nodes. The lymph vessels that drain to the medial retropharyngeal lymph node (also 1 to 2 small vessels) join those of the tip of the tongue and pass between the *M. geniohyoideus* and *M. genioglossus* towards the medial side of the *M. mylohyoideus*, running along it to the medial retropharyngeal lymph node.

LYMPH VESSELS OF THE GINGIVAE

The lymph vessels of the gingivae have already been carefully examined by Schweitzer [26]. Nevertheless, I injected them several times and was able to confirm almost all of Schweitzer's findings. The results were as follows: most of the lymph vessels of the gingivae drain into the mandibular lymph nodes, though a smaller number drain into the medial retropharyngeal lymph node. The lymph vessels from the buccal, labial, and lingual sides of the upper and lower teeth (incisors and molars) all drain into the mandibular lymph nodes. Additionally, those from the lingual side of the teeth (incisors and molars) drain into the medial retropharyngeal lymph node. The lymph vessels from the gingivae on the lingual side of the upper teeth join the lymph vessels of the hard palate (see section D below).

A. LYMPH VESSELS OF THE LABIAL SIDE OF THE MAXILLARY INCISORS, MOLARS, AND PREMOLARS

The lymph vessels of the gingivae on the labial side of the intermaxillary incisors and on the buccal side of the maxillary premolars and molars form an extremely dense, finely meshed lymphatic network in and under the mucous membrane, from which a large number of small lymph vessels emerge. These lymph vessels combine to form several (5 to 7) trunks, which initially run a distance quite deep in the lip and cheek mucosa, then penetrate through the cheek muscles at various points (Figure 13: 6), travelling with the lymph vessels of the upper lip and cheek mucosa to the oral border of the *M. masseter*. Almost all the lymph vessels then run over the lateral surface of the *M. masseter* to drain into the mandibular lymph nodes (Figure 13: 2, 2', 2''), most frequently to the dorsal group.

Occasionally, 1 to 2 of these lymph vessels drain into one of the ventral mandibular lymph nodes. This behaviour may not be as rare as described by Schweitzer: in 6 cases, I observed the behaviour twice. When the gingiva of the upper incisors in the median plane was punctured and injected, lymph vessels drained into the mandibular lymph nodes on both the left and right sides. However, lymph vessels additionally drained to both sides when puncture injection was done at the border of the 1st and 2nd upper incisors of only one side.

B. LYMPH VESSELS OF THE LABIAL SIDE OF THE MANDIBULAR INCISORS AND BUCCAL SIDE OF THE MANDIBULAR PREMOLARS AND MOLARS

The lymph vessels of the gingivae on the labial side of the mandibular incisors and on the buccal side of the mandibular premolars and molars form the same network in and under the mucous membranes mentioned above, and these lymph vessels will eventually merge together to form 5 to 7 trunks. Some of these trunks pass through the ventral portion of the *M. buccalis*, while others emerge at its ventral margin (Figure 13: 7) and travel more or less to the *incisura vasorum*, running a fairly long distance in the intermandibular region. From the *incisura vasorum*, the lymph vessels then drain into the ventral mandibular lymph nodes (Figure 13: 2', 2''), and only rarely to the dorsal mandibular lymph node. If there are 2 ventral mandibular lymph nodes beside one another, the lymph vessels from the incisor region mostly flow into the aboral lymph node, and those from the molar region into the oral lymph node.

C. LYMPH VESSELS OF THE LINGUAL SIDE OF THE MANDIBULAR MOLARS, PREMOLARS, AND INCISORS

The lymph vessels of the gingivae on the lingual side of the mandibular molars, the mandibular premolars, and the mandibular incisors show three different patterns of drainage to the ventral mandibular lymph nodes and the medial retropharyngeal lymph node:

- i. Some of the lymph vessels pass on the molar margin between 2 teeth to the lateral side, joining the lymph vessels from the gingivae on the lateral side of the molars (Figure 13: 7) and running with them to the ventral mandibular lymph nodes (Figure 13: 2', 2''). Rarely, one of these lymph vessels will also drain to a dorsal mandibular lymph node. This was observed for the gingivae of the molars.
- ii. Other lymph vessels penetrate the *M. mylohyoideus*, reach its outer surface, and run in a caudal direction to the ventral mandibular lymph nodes, and along the pharyngeal muscles to the retropharyngeal lymph node.
- iii. Finally, some of the lymph vessels run caudally on the medial side of the *M. mylohyoideus*. Of these vessels, some then run from the caudal border of this muscle along the pharyngeal muscles to drain into the retropharyngeal lymph node, and others descend along the medial side of the *M. digastricus* to drain into the ventral mandibular lymph nodes.

D. LYMPH VESSELS OF THE LINGUAL SIDE OF THE UPPER INCISORS, PREMOLARS, AND MOLARS

The lymph vessels of the gingivae on the lingual side of the upper incisors, premolars, and molars join those of the mucous membrane of the hard palate and accompany them to the mandibular lymph nodes and the medial retropharyngeal lymph node (see lymph vessels of the hard palate).

Occasionally, a lymph vessel from the gingivae of the incisors and premolars will cross the median plane and enter the corresponding lymph nodes on the other side. Schweitzer has stated that there are always 3 mandibular lymph nodes present, one dorsal and two ventral, and that the regional drainage of the individual lymph nodes is sharply delineated insofar as the lymph vessels of the gingivae of the maxillary teeth (with the exception of 1 case) all drained to the dorsal node, while those of the gingivae of the mandibular teeth drained to the 2 ventral lymph nodes. I could not confirm this statement, because the number of lymph nodes in this group ranges from 2 to 5 (see mandibular lymph nodes), and also because, even when there were 3 mandibular lymph nodes, I found many cases that were exceptions to Schweitzer's statement.

LYMPH VESSELS OF THE CHEEK

The lymph vessels of the cheek, including all associated structures (skin, muscles, mucous membrane, ventral cheek glands), drain to the mandibular lymph nodes (see [Figure 13](#)). The lymph vessels of the mucous membrane of the cheek penetrate the cheek muscles at various points and join the lymph vessels of the skin of the cheek. The dorsal cheek glands of the dog are in the orbit and are called zygomatic glands ([Figure 14: i](#)). These lymph vessels drain to the mandibular lymph nodes, emerging to a lesser extent on the lateral and mostly on the medial side of the gland ([Figure 14: I''](#)) and joining with the lymph vessels of the hard and soft palate, which run around the maxillary tuberosity (*tuber maxillae*) or the last molar to the medial side of the *M. masseter* ([Figure 14: I'](#)) and then to the mandibular lymph nodes. The lymph vessels of the zygomatic glands were examined in 4 dogs, and in 2 of the dogs on both sides: in none of these cases were lymph vessels draining to the medial retropharyngeal lymph node found.

LYMPH VESSELS OF THE HARD PALATE

This section includes the gingivae on the lingual side of the maxillary (incisor, premolar, and molar) teeth. The lymph vessels of the hard palate mostly drain to the mandibular lymph nodes, and only a small number of lymph vessels, those from the part of the hard palate adjacent to the soft palate, drain to the medial retropharyngeal lymph node.

The lymph vessels from the rostral and middle thirds of the hard palate (from the maxillary incisors to the 4th molar) pass outwards through the spaces between the teeth, joining the lymph vessels from the gingivae on the labial side of the maxillary incisors and the buccal side of the maxillary premolar and molar teeth (see lymph vessels of the gingivae), accompanying them to the mandibular lymph nodes. The lymph vessels form extensive networks in and under the mucosal membrane of the hard palate; one consequence of this is that the median plane is crossed very often, so that when one half of the hard palate is injected, the dye almost always drains to the lymph nodes on the contralateral side. The individual lymph vessels can run for long distances under the mucous membrane, resulting in them

passing through the cheek muscles at all points (up to the *M. masseter*) (Figure 13: 6, 7). In the more closely examined cases, the lymph vessels of the rostral third of the hard palate drained into the dorsal and ventral groups of the mandibular lymph nodes (Figure 13: 2, 2', 2''), whereas the lymph vessels of the middle third only drained to the dorsal mandibular lymph node (Figure 13: 2).

From the caudal third of the hard palate, some of the lymph vessels may also drain to the mandibular lymph nodes, though most drain to the medial retropharyngeal lymph node. The lymph vessels draining to the mandibular lymph node (Figure 14: 1') run laterally around the last molar, and, at this location, join the corresponding gingival lymph vessels (see lymph vessels of the gingivae), emerging with them from under the *M. masseter* and descending to the dorsal mandibular lymph node. The lymph vessels draining to the medial retropharyngeal lymph node (Figure 14: 1) originate from the caudal-most part of the hard palate (that is, the part of the hard palate adjacent to the soft palate): these vessels run over both surfaces of the *M. pterygoideus* and join the corresponding lymph vessels of the soft palate and tonsil (see lymph vessels of the soft palate and tonsil).

LYMPH VESSELS OF THE SOFT PALATE AND TONSIL

The lymph vessels from the rostral (oral) part of the soft palate, including the *arcus glossopalatinus* and the folds of the mucous membrane surrounding the tonsillar sinus, drain to both the dorsal mandibular and medial retropharyngeal lymph node groups, while those from the caudal (aboral) part of the soft palate drain only to the medial retropharyngeal lymph node.

The lymph vessels draining to the dorsal mandibular lymph node (Figure 14: 1', 2') run under the mucous membrane as far as the area of the last molar, joining with the corresponding lymph vessels from the back of the hard palate (see lymph vessels of the hard palate), and running with them under the *M. masseter* to drain to the dorsal mandibular lymph node. The small number of lymph vessels that drain to the ventral mandibular lymph nodes run along the medial side of the mandible, between the mucous membrane and the *M. mylohyoideus* ventrally and somewhat caudally, before penetrating the *M. mylohyoideus* and running to the ventral mandibular lymph nodes. The lymph vessels draining into the medial retropharyngeal lymph node (Figure 14: 1, 2) travel with the corresponding lymph vessels from the caudal part of the hard palate and those of the tonsil to the aforementioned lymph nodes (for details, see lymph vessels of the tonsils, below).

The lymph vessels of the tonsil drain to the medial retropharyngeal lymph node. Three to 5 lymph vessels leave the tonsil, emerging behind the palatoglossal arch (Figure 14: 3, 3), crossing the *M. styloglossus* medial to the *M. digastricus* by passing over either its lateral or medial surface, or passing through it, and then travelling along the pharyngeal muscles into the aforementioned lymph node. Some of the lymph vessels additionally run under the mucosal membrane of the lateral wall of the pharynx, proceeding to either penetrate the pharyngeal musculature, specifically (Figure 14) either the *M.*

hyoglossus or the *M. keratopharyngeus*, or passing between the *M. hyothyroideus* (Figure 14: *p*), *M. keratopharyngeus* (Figure 14: *m*), and *M. thyropharyngeus* (Figure 14: *n*), before emerging (Figure 14: *4*) and travelling along the pharyngeal muscles to drain to the medial retropharyngeal lymph node (Figure 14: *u*).

The lymph vessels of the mucosal fold surrounding the tonsillar sinus also drain to the medial retropharyngeal lymph node, however, a lymph vessel from just that portion of the fold facing away from the sinus may instead join with a corresponding soft palate lymph vessel to drain to the mandibular lymph nodes (Figure 14: *2*¹).

LYMPH VESSELS OF THE MAJOR SALIVARY GLANDS (SUBLINGUAL, SUBMAXILLARY, AND PAROTID GLAND)

A. SUBLINGUAL GLAND

The lymph vessels of the sublingual gland (Figure 15: *r, r'*) drain to the mandibular and medial retropharyngeal lymph nodes: those of the *glandula sublingualis parvicanalaris* drain to both groups of lymph nodes, while those from the *glandula sublingualis grandicanalaris* drain only to the medial retropharyngeal lymph node. Several lymph vessels arise from the *glandula sublingualis parvicanalaris* (Figure 15: *r'*) and proceed to merge into 2 to 3 smaller vessels. One to 2 of these vessels (Figure 15: *l*) will join with the lymph vessels of the gingivae of the lingual side of the mandibular molars (pattern ii), running rostrally between the mucosa on the medial side of the mandible and the *M. mylohyoideus* for a varying distance, before turning ventrally, penetrating the *M. mylohyoideus*, and draining to the ventral mandibular lymph nodes.

Most of the lymph vessels draining to the ventral mandibular lymph nodes originate from the cranial part of the *glandula sublingualis parvicanalaris*. In addition, another 1 to 2 lymph vessels drain to the medial retropharyngeal lymph node. These lymph vessels mainly originate from the caudal part of the *glandula sublingualis parvicanalaris*, as shown in Figure 15, and run under the *M. digastricus* to drain to the medial retropharyngeal lymph node. The lymph vessels arising from the *glandula sublingualis grandicanalaris* (Figure 15: *r*) also merge to form several (though most commonly 2) trunks, which wrap around the nasodorsal margin of the *M. digastricus* to its medial side, joining the lymph vessels of the caudal part of the *glandula sublingualis parvicanalaris*, and running with them to the medial retropharyngeal lymph node (Figure 15: *t*).

B. SUBMAXILLARY (MANDIBULAR) GLAND

The lymph vessels of the submaxillary gland (Figure 15: *q*) drained to the medial retropharyngeal lymph node (Figure 15: *t*) in 4 examined cases. Three to 5 lymph vessels emerge from the gland, most-

ly from its medial surface, though sometimes from its caudal border, and travel over both surfaces of the *M. digastricus* to drain to the medial retropharyngeal lymph node.

C. PAROTID GLAND

Some of the lymph vessels of the parotid gland (Figure 15: *p*) drain to the parotid lymph node (Figure 15: *s*), and some drain to the medial retropharyngeal lymph node (Figure 15: *t*). The lymph vessels draining to the parotid lymph node originate mainly from the oral half of the gland and emerge from its ventral surface, while those draining to the medial retropharyngeal lymph node originate mainly from the caudal half of the gland, and, after they have left the gland on its ventral surface, travel as 4 to 5 vessels, some over the lateral and some over the medial side of the *M. digastricus*, to drain to the medial retropharyngeal lymph node. Lymph vessels draining from the parotid gland to the mandibular lymph nodes could not be found in 6 carefully examined cases. This finding is significant because, in the cow, the lymph vessels of the parotid gland were always found to drain to the mandibular lymph nodes.

LYMPH VESSELS OF THE PHARYNX

The lymph vessels of the pharynx (Figure 14) drain to the medial retropharyngeal lymph nodes (Figure 14: *u*). The lymph vessels of the pharyngeal mucosa form abundant networks in and under the mucosa. The lymph vessels emerging from these networks travel for long distances between the mucosa and the pharyngeal musculature, and then on the muscle, directly to the medial retropharyngeal lymph nodes, merging on the way to form 2 to 4 vessels. When they pass through the pharyngeal musculature, they do so mainly in the angle between the *M. keratopharyngeus*, *M. thyropharyngeus*, and *M. hyothyroideus* (Figure 14: *4*, *4'*, *4''*), as well as between the *M. stylopharyngeus* and *M. keratopharyngeus*.

The lymph vessels of the pharyngeal muscles join those of the mucous membranes, draining with them to the medial retropharyngeal lymph nodes (see also the laryngeal muscles).

LYMPH VESSELS OF THE ESOPHAGUS

The lymph vessels of the esophagus can be injected from the muscular layer as well as from the mucosa of the esophagus, however, the lymph vessels from both tissues in any given section of the esophagus usually drain to the same lymph nodes. These lymph vessels form very coarse networks in the submucosa; the networks are primarily composed of the lymph vessels of the mucosa, though the lymph vessels of the muscular layer also contribute to the network formation. Occasionally, a fine network was visible through the epithelium after dye injection, apparently located inside the mucosa. The small lymph vessels arising from the submucosal networks often travel relatively long distances between the mucous

membrane and the muscles before penetrating the muscle and joining the lymph vessels of the muscles. Other lymph vessels of the mucous membrane penetrate the muscle layer directly and form coarse networks with the lymph vessels of the muscles in the adventitia, and in some cases in the muscles as well. The lymph vessels arising from the lymphatic networks drain to the medial retropharyngeal lymph node, the deep cervical lymph nodes, the cranial mediastinal lymph nodes, the tracheobronchial lymph nodes, the left hepatic lymph node, the splenic lymph nodes, and the gastric lymph node. A detailed description of their behaviour is as follows:

A. LYMPH VESSELS OF THE CERVICAL ESOPHAGUS

The lymph vessels of the cervical part of the esophagus ([Figure 23: b, b](#)) drain to the medialretropharyngeal lymph node ([Figure 23: 1](#)), the deep cervical lymph nodes ([Figure 23: 2, 3, 4](#)) and the cranial mediastinal lymph nodes ([Figure 23: 6, 6'](#)). From the initial part of the esophagus (approximately the cranial quarter of the cervical esophagus), the lymph vessels, usually 1 to 3, drain to the medial retropharyngeal lymph node ([Figure 23: 1](#)), and, if one is present, to the cranial cervical lymph node ([Figure 23: 2](#)). Drainage occurs to lymph nodes on both sides. Occasionally, one of the lymph vessels additionally drains to either the middle cervical ([Figure 23: 3](#)) or caudal cervical ([Figure 23: 4](#)) lymph nodes, or, in their absence, to a cranial mediastinal lymph node.

The path taken by the lymph vessels to the medial retropharyngeal lymph node is variable; either they run directly on the pharyngeal musculature to the lymph node ([Figure 23: 5](#)), or they initially run orally underneath the mucosa before passing through the pharyngeal musculature (usually at the angle between *M. hyothyroideus* and *M. keratopharyngeus*) ([Figure 23: 5'](#)), at times running along the medialside of the thyroid cartilage.

In 1 case, all the lymph vessels drained to a cervical lymph node located between the thyroid gland and the pharyngeal muscles, and none drained to the medial retropharyngeal lymph node, whereas in other cases, they drained into both lymph nodes. In 2 of 7 cases examined, 1 lymph vessel from the initial part of the esophagus drained to a middle cervical or caudal cervical lymph node, while in another case, a lymph vessel drained to a cranial mediastinal lymph node.

Most of the lymph vessels from the middle one-third of the cervical esophagus ([Figure 23](#)) drain to the caudal cervical lymph node ([Figure 23: 4](#)) (and middle cervical lymph node on occasion [[Figure 23: 3](#)]), though some accompany the lymph vessels of the caudal section of the esophagus to drain to the cranial mediastinal lymph nodes ([Figure 23: 6, 6'](#)) (see below). In the absence of the cervical lymphnodes, all the lymph vessels drain to the mediastinal lymph nodes ([Figure 23: 6, 6'](#)).

In 8 other closely examined cases, an unpaired caudal cervical lymph node was found 3 times. This lymph node drained 1 to 2 lymph vessels that originated from the middle third of the cervical esophagus – these vessels were formed by the confluence of 3 to 4 single lymph vessels and travelled to the lymph node along either the left or right side of the trachea. In 1 case, 3 caudal cervical lymph nodes were present, and all 3 received lymph vessels from the middle third of the esophagus. In 2 cases, a left middle cervical lymph node was found, which also drained lymph vessels from the middle third

of the cervical esophagus: in 1 of these cases, a right middle cervical lymph node was found as well, and it additionally drained lymph vessels from the esophagus. These latter vessels obviously crossed the median plane. In addition to all these lymph vessels, in 3 of the cases described above, an additional lymph vessel was found to emerge from the middle third of the cervical esophagus, joining the lymph vessels from the caudal part of the cervical esophagus and draining with them to the cranial mediastinal lymph nodes (Figure 23: 6). In the last 2 cases, the caudal cervical and middle cervical lymph nodes were absent, and all the lymph vessels drained to a mediastinal lymph node. They were always found to drain to a left mediastinal lymph node, either the left main mediastinal lymph node or to the mediastinal lymph node located on the left side of the cranial vena cava.

The lymph vessels of the caudal one-third of the cervical esophagus (Figure 23) drain to the cranial mediastinal lymph nodes (Figure 23: 6, 6'). A large number of tiny lymph vessels arise from this part of the esophagus and merge to form 1 to 2 larger vessels, which may also receive lymph vessels from the middle part of the cervical esophagus (see above), before entering the thoracic cavity along with the esophagus (on its two borders and two surfaces), through the thoracic inlet, and draining to a mediastinal lymph node. In the examined cases, the lymph vessels always drained to a left mediastinal lymph node, either the left main mediastinal lymph node (Figure 23: 6) or the lymph node located on the left side of the cranial vena cava (Figure 23: 6').

In one case with 2 lymph vessels draining the caudal one-third of the cervical esophagus, one lymph vessel traveled around the right border of the trachea at the level of the 2nd intercostal space and passed over the ventral edge of the trachea to drain to the lymph node located on the left side of the cranial vena cava. The other lymph vessel traveled a relatively long distance (to the entrance of the thoracic cavity), between the mucous membrane and the fascia, penetrated the fascia, and ran from the left side of the esophagus to drain to the left cranial mediastinal lymph node.

B. LYMPH VESSELS OF THE THORACIC ESOPHAGUS

The lymph vessels of the thoracic esophagus drain to the mediastinal lymph nodes, the tracheobronchial lymph nodes, the left hepatic lymph node, the splenic lymph nodes, and the gastric lymph node. The lymph vessels of the esophagus in the cranial half of the thoracic cavity drain mainly to the mediastinal lymph nodes, in almost all cases to the left mediastinal lymph nodes, but occasionally also cross over the right side of the trachea to drain to the right mediastinal lymph nodes. Some of the lymph vessels also join the lymph vessels of the esophagus in the caudal half of the thoracic cavity, which enter the abdominal cavity with the esophagus and drain to either the left hepatic lymph node, a splenic lymph node, or the gastric lymph node (see lymph vessels of the stomach). I observed this latter behaviour particularly in the lymph vessels of the esophageal mucosa, but also in isolated cases of those of the fascia and of all the thoracic esophagus up to the thoracic inlet, so from the cranial third of the thoracic esophagus as well. These lymph vessels usually travel a relatively long distance between the mucous membrane and the fascia towards the diaphragm, and, when injected, may be visible through the musculature. They usually only penetrate the outer surface of the fascia very close

to the diaphragm, and then join the lymph vessels of the caudal half of the thoracic esophagus (see below).

Some lymph vessels of the caudal half of the thoracic esophagus ([Figure 18: t](#)) drain into the tracheobronchial lymph nodes, specifically to the left and middle ([Figure 18: l](#)) lymph nodes. However, most of the lymph vessels join with the lymph vessels of the cranial half of the thoracic esophagus (see above) and enter the abdominal cavity, through the diaphragm, with the esophagus as 4 to 7 lymph vessels, forming many networks. The vessels then run from the cardia, between the serosa and muscularis of the stomach. Some of the lymph vessels run to the small curvature of the stomach and from there in the dorsal wall of the omentum, more or less accompanied by the left gastric vein until reaching the splenic vein ([Figure 28: 7](#)), and drain into the left hepatic lymph node ([Figure 28: l](#)). If a gastric lymph node is present at the small curvature of the stomach, some of these lymph vessels will first drain to it. The remainder of the lymph vessels run from the cardia, around its left side, to the gastrosplenic ligament ([Figure 28: 7'](#)), and travel in it to reach the splenic vein, draining to the splenic lymph nodes ([Figure 28: 8](#)).

The individual drainage areas of the thoracic esophagus are not sharply delineated from one another. Just as some of the lymph vessels from the cranial part of the thoracic esophagus drain to a left hepatic lymph node, it can happen that lymph vessels from the caudal part of the thoracic esophagus drain to a cranial mediastinal lymph node, or a lymph vessel from the cranial part of the thoracic esophagus drains to a tracheobronchial lymph node. It is also not uncommon for lymph vessels to pass from one part of the esophagus around either the dorsal or ventral borders of the esophagus to the other side: e.g. the lymph vessels labelled 5 in [Figure 18](#), which drain to the left tracheobronchial lymph node.

LYMPH VESSELS OF THE STOMACH

The lymph vessels of the stomach ([Figure 26: l](#)) of the dog all eventually drain to the hepatic lymph nodes, most of them to the left hepatic lymph node ([Figure 26: c](#)), and a small number to the right hepatic lymph nodes ([Figure 26: b](#)). Some of the lymph vessels that drain to the left hepatic lymph node drain through the splenic lymph nodes ([Figure 26: d, d'](#)) and the gastric lymph node ([Figure 26: o](#)), and some of the vessels that drain to the right hepatic lymph nodes drain through the duodenal lymph node ([Figure 26: a](#)). The detailed behaviours are described below.

A. LYMPH VESSELS OF THE STOMACH (EXCLUDING THE PYLORIC REGION)

The lymph vessels of the larger part of the stomach on the left side (excluding the pylorus) drain to the splenic lymph nodes, the left hepatic lymph node, and the duodenal lymph node, and, as shown in [Figure 26](#), take one of the 3 following paths:

i. The lymph vessels of the left part of the greater curvature and from the stomach walls on each side of this part of the greater curvature run towards the splenic vein by following the splenic vein

branches. From here, they run in either the gastrosplenic ligament or the omentum and then drain into the splenic lymph nodes (Figure 26: *d, d'*), which lie next to the splenic vein. Not all the lymph vessels drain into the splenic lymph nodes, however: some bypass these lymph nodes and join their efferent vessels, accompanying the gastrosplenic vein to drain to the left hepatic lymph node (Figure 26: *c*).

ii. The lymph vessels of the ventral part of the greater curvature and the adjacent parts of the lateral walls merge to form 2 to 3 vessels which run to the large curvature and from there towards the right in the omentum together with the gastroepiploic vein, and join the lymph vessels from the pylorus (see below) to drain to the duodenal lymph node (Figure 26: *a*).

iii. Lymph vessels of both lateral walls of the stomach adjacent to the lesser curvature and the lesser curvature itself travel, together with the cranial and caudal branches of the left gastric vein, towards the lesser curvature before accompanying the left gastric vein to the gastrosplenic vein, and then joining the lymph vessels accompanying the splenic vein (see above) to drain with them to the left hepatic lymph node (Figure 26: *c*). If a gastric lymph node (Figure 26: *o*) is present, then some of these lymph vessels, from both stomach walls, first drain to it. The efferent vessels of the gastric lymph node then join the other lymph vessels. Even if a gastric lymph node is present, not all lymph vessels drain to it – some bypass the lymph node entirely.

B. LYMPH VESSELS OF THE PYLORIC REGION OF THE STOMACH

The lymph vessels of the pyloric region of the stomach behave as follows:

i. The lymph vessels of the lateral walls and dorsal margin of the pylorus join the lymph vessels accompanying the left gastric vein from the lesser curvature and drain with them to the left hepatic lymph node (Figure 26: *c*). If a gastric lymph node is present (Figure 26: *o*), some of the vessels usually first drain to it.

ii. The lymph vessels of the lateral walls adjacent to the ventral border of the pylorus and from the ventral border itself, however, run towards the right gastroepiploic vein and travel with it along the pylorus and the initial part of the duodenum, towards the right, until they reach the duodenal lymph node (Figure 26: *a*), though they may also bypass this lymph node and drain to a right hepatic lymph node.

The lymph vessels of the areas between the above sections A and B, between A(i) and A(ii), and between B(i) and B(ii), usually drain in both directions.

The lymph vessels of the stomach wall form extensive submucosal and subserous networks, both of which are interconnected. The subserous networks often extend into the musculature, i.e. they are covered by the musculature when viewed from the outside the stomach (this has also been demonstrated by microscopic examination). The lymph vessels arising from the subserous networks usually travel for a short distance before entering the serosa and continuing in the serosa for long distances, again forming very coarse networks. This results in 3 interconnected networks: one serous, one subserous, and

one submucosal, all lying one above the other, though the serous and subserous networks often cannot be clearly separated from each other. The serous and subserous lymph vessels may also re-enter the muscles, or at least be covered by parts of the muscle layer. The terminal lymph vessels develop from the serous network. The lymph vessels arising from the submucosal networks frequently continue for a considerable distance in the submucosa before penetrating the musculature. The lymph vessels of the mucosa form the submucosal networks, from which the subserosal and serosal networks then fill. Some of the lymph vessels of the musculature open into the submucosal networks, some into the subserosal networks – the lymph vessels of the serosa open to a smaller extent smaller extent into the subserosal networks. More commonly, these lymph vessels directly form serosal networks.

LYMPH VESSELS OF THE INTESTINE

The following general behaviours of the intestinal lymph vessels were demonstrated:

Lymph vessels arise from all 3 layers of the intestinal wall. Those of the mucosa form either mucosal or submucosal networks: the lymph vessels arising from these networks usually run a variable distance between the mucous membrane and the fascia, before penetrating the fascia and joining its lymph vessels. The lymph vessels of the musculature and serosa form subserosal networks, though some of the networks also lie in the muscle layer (as has been demonstrated microscopically); the lymph vessels arising from these networks run between the serosa and musculature to the mesenteric border (see below) before entering the mesentery.

A. LYMPH VESSELS OF THE SMALL INTESTINE

A smaller number of the lymph vessels of the small intestine drain to the duodenal lymph node, the right hepatic lymph nodes, and the right colic lymph nodes, while most drain to the jejunal lymph nodes.

i. Lymph Vessels of the Duodenum (Figure 26: 2)

The lymph vessels from the initial part of the duodenum drain to the duodenal lymph node (Figure 26: a). Those of the middle part of the duodenum drain directly to the right hepatic lymph nodes (Figure 26: b), and those of the terminal part (as far as the *flexura tertia*) drain to the right jejunal lymph node (Figures 25: 9; 26: l). If there are several nodes in the group, they will drain to either the cranial lymph node or to the 2 cranial lymph nodes. The lymph vessels lie between the two sheets of the mesentery and usually accompany the corresponding veins, though they may, to a lesser extent, also run irregularly between these veins. Most of the lymph vessels draining to the right hepatic lymph nodes run over the ventral side of the pancreas, only occasionally over its dorsal surface (as shown in Figure 26), but some of the lymph vessels also enter the pancreas. Some of the lymph vessels, especially those that enter the pancreas, merge with the lymph vessels of the pancreas. Because the lymph vessels of the duodenum and the pancreas are connected in this way, the lymph vessels of the duodenum can also be filled from the pancreas (see lymph vessels of the pancreas).

ii. Lymph Vessels of the Jejunum

The lymph vessels of the jejunum (Figure 25: *b*, *b'*) drain to the jejunal lymph nodes (Figure 25: 6, 6¹, 6²). Specifically, the lymph vessels from the part of the jejunum immediately after the duodenum drain to the right jejunal lymph node, those from the much larger central part of the jejunum (Figure 25: *b*, *b*) drain to the left jejunal lymph node (Figure 25: 6¹, 6²), and those from the terminal part of the jejunum (Figure 25: *b'*, *b'*) drain to the right jejunal lymph node (Figure 25: 6).

iii. Lymph Vessels of the Ileum

Most of the lymph vessels of the ileum (Figures 25: *c*, 26: 5) drain to the right jejunal lymph node (Figure 25: 6), though a small number of them instead drain to the right colic lymph node (Figures 25: 5, 26: *e*). The lymph vessels draining to the right jejunal lymph node run from the ileum directly to the small intestinal mesentery, running within it to drain to the lymph node (as shown in Figure 25). Some of the lymph vessels draining to the right colic lymph node enter the mesocecum (mesentery between the ileum and cecum) and join the lymph vessels of the cecum (see lymph vessels of the cecum below) to drain with them into the right colic lymph node, while others merge to form 1 to 2 vessels which run along the opposite border of the ileum to the lymph node (as shown in Figure 26).

The lymph vessels of the jejunum and ileum lie between the sheets of the mesentery as they run from the intestine to the lymph nodes. Almost all of them run alongside the jejunal veins, but occasionally they lie between two jejunal veins. From the site of puncture injection, most of the lymph vessels initially form extensive, fine subserosal networks, from which small lymph vessels emerge; these vessels run, mostly subserosally, over both surfaces of the intestine to the mesenteric margin. At this location, and in the adjacent mesentery, they merge with neighbouring vessels and form anastomoses and coarse networks with numerous islands, then mostly run alongside mesenteric veins; only a small number runs between the mesenteric veins (Figure 25). A smaller number of the lymph vessels do not run directly towards the mesenteric margin, but instead, they run around the free border of the jejunum or ileum opposite to the mesenteric margin to the opposite surface of the intestinal loop and from there to the mesenteric margin. It is not uncommon for lymph vessels to fill from one puncture site towards both intestinal surfaces.

B. LYMPH VESSELS OF THE LARGE INTESTINE

Most lymph vessels of the large intestine drain to the colic lymph nodes; only those of the end of the descending colon, the transition of the colon into the rectum, and the rectum itself drain to the medial iliac lymph nodes and hypogastric lymph nodes.

i. Lymph Vessels of the Cecum

The lymph vessels of the cecum (Figure 26: 6) drain to the right colic lymph node (Figure 26: *e*). Specific cecal lymph nodes could not be found. The small lymph vessels arising from the subserosal

networks run over both surfaces of the cecum towards the mesocecum (the mesentery between the ileum and cecum) and run in the mesocecum together with the lymph vessels of the ileum (see above) towards the transition of the ileum to the colon. The lymph vessels cross both surfaces of this transition area, or the distal end of the ileum, and then run in the mesentery directly to the right colic lymph node.

ii. Lymph Vessels of the Colon

The lymph vessels of the colon (Figure 26: 7, 8 and 9) drain to all 3 groups of the colic lymph nodes (Figure 26: *e, f, g*), the medial iliac lymph nodes (Figure 26: *l*), and the hypogastric lymph nodes (Figure 26: *k*). The lymph vessels of the ascending colon (Figure 26: 7), found in the mesocolon, drain directly to the right colic lymph node (Figure 26: *e*), and the lymph vessels of the transverse colon (Figure 26: 8) run in the mesentery to the middle colic lymph node (Figure 26: *f*) and drain to it if the lymph node is present – if it is absent, the lymph vessels of the transverse colon drain directly to the right colic lymph node (Figure 26: *e*). However, even if a middle colic lymph node is present, not all the lymph vessels of the transverse colon drain to it: some bypass the lymph node and drain directly to the right colic lymph node.

The lymph vessels of the descending colon (Figure 26: 9) drain to the middle colic lymph node (Figure 26: *f, f*), the left colic lymph nodes (Figure 26: *g, g*), the medial iliac lymph nodes (Figure 26: *i*), and the hypogastric lymph nodes (Figure 26: *k*). The lymph vessels from the initial half of the descending colon drain to the middle colic lymph node (Figure 26: *f, f*), and the lymph vessels from the second half drain to the left colic lymph nodes (Figure 26: *g, g*). If the middle colic lymph node is absent, then the lymph vessels that would drain to it drain instead to the right colic lymph nodes (Figure 26: *e*).

The lymph vessels from the terminal part of the descending colon and the transition of the colon into the rectum drain to both the hypogastric lymph nodes (Figure 26: *k*) and the medial iliac lymph nodes (Figure 26: *i*). The lymph vessels drain to the lymph nodes on both sides. These lymph vessels run caudally along the rectum to the point where the peritoneum meets the pelvic wall, then outside of this part of the peritoneum and further subperitoneally along the lateral pelvic wall until they reach the aforementioned lymph nodes. Frequently, lymph vessels filled from a puncture site between two drainage areas run towards the lymph node groups of both areas.

Most of the lymph vessels arising from the intestinal subserosal networks, which tend to form elongated meshes (see [Figure 26](#)), run directly to the mesenteric border of the colon. However, some of the lymph vessels may also run towards the free border of the colon (i.e. the border opposite to the mesenteric border) to the opposite surface before travelling from this surface to the mesenteric border (also shown in Figure 26). At this border and in the adjacent mesentery, most of the lymph vessels form coarse networks with very large islands, from which, again, individual lymph vessels arise. In the terminal half of the descending colon, these lymph vessels run directly to the left colic lymph nodes, usually accompanied by the corresponding venous branches. In the initial part of the descending colon, these lymph vessels (or the islands formed by them) mostly accompany the left colic vein to the left colic lymph nodes, although a small number also run transversely through the mesentery towards these lymph nodes.

iii. Lymph Vessels of the Rectum

The lymph vessels of the rectum (Figure 26: *l*) drain to both the hypogastric lymph nodes (Figure 26: *k*) and the medial iliac lymph nodes (Figure 26: *i*). They merge into 4 to 5 vessels and drain to the lymph nodes on both sides, some of them running over the dorsal side of the rectum (Figure 26: *p, p*).

C. LYMPH VESSELS OF THE ANUS

The lymph vessels of the anus (Figure 26: *m*) join those of the rectum (see above) and drain with them to the hypogastric lymph nodes (Figure 26: *k*) and the medial iliac lymph nodes (Figure 26: *i*). The lymph vessels also drain to the lymph nodes on both sides.

LYMPH VESSELS OF THE LIVER AND GALLBLADDER

The lymph vessels of the liver can also be divided into superficial (subserosal) and deep (parenchymal) vessels. The superficial lymph vessels fill up particularly during puncture injections into the serosa and the most superficial parenchymal layers. These lymph vessels form fine serous or subserosal networks, as shown in several places in [Figure 28](#). Most of the lymph vessels arising from these networks continue only a short distance subserosally or in the serosa (Figure 28: *4, 4, 4*), before travelling more deeply and joining the deep lymph vessels. They often travel more deeply immediately (especially on the parietal or diaphragmatic surface of the liver), though a smaller number of subserosal lymph vessels can be followed over long distances, even up to the hepatic portal or to the point where the lymph vessels leave the liver, for example, to the coronary ligament or the lateral ligament (Figure 28: *5, 5, 9, 9'*). Less commonly, superficial lymph vessels fill after injections into the liver parenchyma, i.e. lymph vessels that emerge from the depth to the surface. Deep lymph vessels, of course, fill primarily when injections are made into the liver parenchyma, but may also fill when, as has been described above, superficial lymph vessels penetrate more deeply.

The lymph vessels of the liver, both superficial and deep, drain to the left hepatic lymph node, the right hepatic lymph nodes, the gastric lymph node, and the splenic lymph nodes. The superficial lymph vessels additionally drain to the cranial lumbar aortic lymph node.

A. THE DIAPHRAGMATIC SURFACE OF THE LIVER

The superficial (subserosal) lymph vessels of the parietal or diaphragmatic surface of the liver can be divided into 3 groups based on their behaviour: some of the lymph vessels run deeply and join the deep lymph vessels of the liver, some enter the lateral ligament and coronary ligament of the liver and run from there towards the diaphragm, and, finally, some can be followed subserosally to the hepatic lymph nodes. The first group includes subserosal lymph vessels from the entire parietal surface, but particularly from its ventral half.

The second group includes subserosal lymph vessels that originate from the dorsal half of the pa-

rietal surface, particularly from the part of the parietal surface that is adjacent to the dorsal part of the lateral margins of the liver. These lymph vessels approach the diaphragm as described above, but then, as was found in 8 closely examined cases, do not enter the thoracic cavity, instead running along the diaphragm under its peritoneum. Some drain to the cranial lumbar aortic lymph node (right and left) (Figure 28: 9, 9', 3, 3'), and some run towards the vena cava and the end of the esophagus, at this point joining the parenchymal lymph vessels emerging from a depth (see below), and then, together with the lymph vessels of the esophagus (Figure 28: *n*), drain to the splenic, gastric, and left hepatic lymph nodes (Figure 28: 7, 7', 1, 8). Some of these lymph vessels run from the cardia, between serosa and muscularis of the stomach, to the small curvature and from here in the dorsal wall of the omentum and accompany the left gastric vein to the splenic vein, draining to the left hepatic lymph node (Figure 28: 1). If a gastric lymph node is present at the small curvature of the stomach, some of these lymph vessels enter it. The remaining lymph vessels run from the cardia, around its left side, to the gastrosplenic ligament and run within it to the splenic vein and to the splenic lymph nodes (Figure 28: 8).

Some of the lymph vessels mentioned above may additionally bend around the dorsal edge of the liver onto its visceral surface, where they join the deep lymph vessels emerging from the hepatic portal, draining with them into the hepatic lymph nodes. This third group of subserosal lymph vessels arises from the parietal surface of the liver, especially on the parietal surfaces of the individual lobes of the liver that are covered by adjacent lobes.

The superficial lymph vessels of the visceral surface are, for the most part, situated deeply (Figure 28: 4, 4, 4) and join with the deep hepatic lymph vessels. Some lymph vessels run subserosally to the hepatic lymph nodes (Figure 28: 5, 5, 1, 2), while others, especially those from the parts of the lateral hepatic lobes adjacent to the dorsal part of the lateral margins, enter the lateral ligaments of the liver and join the corresponding lymph vessels from the parietal surface to drain to the cranial lumbar aortic lymph nodes (see above and Figure 28: 10, 10', 3, 3'). Finally, some lymph vessels from the dorsal part of the visceral surface join lymph vessels running to the vena cava and the end of the esophagus.

B. DEEP LYMPH VESSELS OF THE LIVER

The deep lymph vessels of the liver leave the liver in two places: 1) in the hepatic portal and 2) on the parietal surface of the liver, where the hepatic veins join with the vena cava.

i. Hepatic Portal

The deep lymph vessels (Figure 28: 6, 6) emerging in the hepatic portal arise from all the individual lobes, accompanied by the corresponding branch of the portal vein: several (4 to 12) lymph vessels arise from each lobe. Some of these lymph vessels merge in the hepatic portal and join the lymph vessels from the visceral surface of the liver (see above). Despite the union of the neighbouring

lymph vessels, at least 50 to 70 lymph vessels can be counted in the hepatic portal as they exit the liver. These vessels are accompanied by the portal vein (Figure 28: *e*) and drain to all the lymph nodes in both the right hepatic lymph node group (Figure 28: 2) and the left hepatic lymph node group (Figure 28: 1), as shown in Figure 28. As they travel to these lymph nodes, the number of lymph vessels decreases, as they unite with neighbouring lymph vessels.

ii. Parietal Surface

The deep lymph vessels arising from the parietal (diaphragmatic) surface of the liver emerge in close proximity either to the hepatic veins or where these veins join the vena cava, and behave as described in more detail above; they mainly originate from the dorsal part of the liver adjacent to the vena cava. The lymph vessels of the gallbladder (Figure 28: *b*) form extensive networks in the wall of the gallbladder. Two to 4 lymph vessels arise from these networks and accompany the common bile duct to drain into the right hepatic and left hepatic lymph nodes (Figure 28: 1, 2).

In humans, Franke [19] found that the lymph vessels of the gallbladder drained into a network of lymph vessels located on the dorsal aspect of the head of the pancreas – I have not observed the same or even similar findings in dogs. Additionally, the lymph vessels of the liver cannot be filled from the gallbladder, although, conversely, the lymph vessels of the parts of the liver adjacent to the gallbladder cross over to the gallbladder and merge with its lymph vessels.

LYMPH VESSELS OF THE PANCREAS

The lymph vessels of the pancreas (Figure 26: 3, 3') drain to the jejunal, right hepatic, left hepatic, duodenal, and splenic lymph nodes.

The lymph vessels from the right terminal part of the pancreas (Figure 26: 3) merge to form 1 to 2 trunks (Figure 26: *l'*), which run in the mesentery to the jejunal lymph nodes. From the remaining right half of the pancreas, most of the lymph vessels travel as several trunks to drain to the right hepatic lymph nodes (Figure 26: *b*), though some also open directly into the duodenal lymph node (Figure 26: *a*), which is located at the pancreas. The lymph vessels of the left half of the pancreas (Figure 26: 3') drain to the splenic lymph nodes (Figure 26: *d*) and the left hepatic lymph node (Figure 26: *c*).

The lymph vessels of the pancreas are all very small and are prominent on both surfaces of the pancreas: on the right half, most of the lymph vessels are located on the ventral surface, while on the left half, most of the lymph vessels are on the dorsal surface.

The lymph vessels of the pancreas connect with the lymph vessels of the duodenum in such a way that the lymph vessels of the duodenum merge or anastomose with those of the pancreas. Due to this connection, the lymph vessels of the duodenum can be injected from the pancreas, and apparently, microorganisms can also travel by this route. I have often succeeded in injections of this type, but I have not succeeded in

filling the smaller lymph vessels of the pancreas from the lymph vessels of the duodenum, which drain to the pancreas. The injection material penetrates, at most, from the lymph vessel of the duodenum over a short distance into the lymph vessel of the pancreas, evidently as far as the next valve.

In this respect, the results of my research agree exactly with those of Bartels [2], who was likely the first to study the lymphatic connections between the pancreas and duodenum carefully, first in dogs, but also in men and monkeys. Bartels explained the finding that the lymph vessels of the duodenum fill from pancreatic lymph vessels, but smaller lymph vessels of the pancreas do not fill from duodenal lymph vessels, as being due to the numerous valves present in the pancreatic lymph vessels preventing the reverse flow of lymph in these vessels – this is apparently the case. However, one then must assume, which Bartels does not point out, that the lymph vessels of the duodenum either do not have such valves, or at least have valves that do not completely close. This is evident from the fact that, when a main lymph vessel formed by the union of a duodenal lymph vessel with a pancreatic lymph vessel is injected, the injected fluid may be forced back in the duodenal lymph vessel up to its finer branches, but this is not seen in the pancreatic lymph vessel. Occasionally, the filling of 1 or 2 duodenal lymph vessels that form subperitoneal networks on the pancreas can be mistaken for more extensive filling of pancreatic lymphatics from the duodenal lymphatics.

Similar connections of the pancreatic lymph vessels with the lymph vessels of the stomach and the transverse colon could not be established, despite conducting a careful examination.

LYMPH VESSELS OF THE SPLEEN

Of the lymph vessels of the spleen ([Figure 26: 4](#)), only those of the spleen capsule are considered, as the splenic parenchyma has no lymph vessels – in this respect, the dog is the same as the cow (see Baum [4]).

I would like to point out that it is very easy to mistake the small veins that fill when injections are made into the splenic parenchyma for lymph vessels. Because of this, I have therefore only described a vessel as a lymph vessel when I have been able to trace it to the associated lymph node.

The spleen capsule has lymph vessels, but these are very difficult to inject, likely because the capsule is very thin. These lymph vessels can be filled more easily on the visceral surface than on the parietal surface of the spleen; as for the latter, it is extremely difficult to succeed. I have not been able to conclude anything definite about the formation of a network of these lymph vessels, despite very careful examination and observation. It must be assumed *a priori* that these lymph vessels form networks, but I have not been able to prove that they exist macroscopically. The lymph vessels run on the visceral surface of the spleen directly from the site of injection to either the hilus of the spleen or to the point of attachment of the omentum to the spleen, and then from the splenic hilus, accompanied by the splenic veins, to drain to the splenic lymph nodes ([Figure 26: d, d'](#)) and, if there are several lymph nodes, to all of them. The lymph vessels were not observed to bypass the lymph nodes.

2.9 LYMPH VESSELS OF THE RESPIRATORY ORGANS

GENERAL

The lymph vessels of all the respiratory organs were injected, including the thyroid and thymus glands. The lymph vessels of the pharyngeal cavity are described in the section on digestive organs (see lymph vessels of the pharynx).

LYMPH VESSELS OF THE NOSE

A. EXTERNAL NOSE

Most of the lymph vessels of the external nose ([Figure 13: 11](#)) drain to the mandibular lymph nodes ([Figure 13: 2, 2'](#)), while a small number drain to the parotid lymph node ([Figure 13: 1](#)). They merge to form 3 to 6 larger lymph vessels, most of which pass under the muscles located in the lateral nasal region, though a few may run over these muscles, and then under the *M. zygomaticus* to the oral side of the masseter. From here, either all the lymph vessels (1 case) or most of the lymph vessels (2 cases) drain to the mandibular lymph nodes. One to 2 of the lymph vessels may turn across the *M. masseter* to drain to the parotid lymph node instead.

B. NASAL CAVITY

The lymph vessels of the nasal cavity (nasal septum and turbinates) form beautiful, richly developed networks in the mucosa and submucosa, respectively. The lymph vessels arising from these networks in the rostral half of the nasal cavity merge to form several lymph vessels, which leave the nasal cavity through the osseous nasal aperture, travel around the nasal process of the incisive bone, and then run outward to join the lymph vessels of the external nose and drain to the mandibular lymph nodes. In 6 more closely examined cases, none of the lymph vessels drained into the parotid lymph node (in contrast to the cow).

The lymph vessels in the caudal half of the nasal cavity, on the other hand, drain into the medial retropharyngeal lymph node. They leave the nasal cavity on each side through their respective choana as 2 to 3 larger vessels and travel caudally at the base of the skull, covered only by the mucous membrane of the pharynx, to drain to the medial retropharyngeal lymph node.

Lymph vessels from the middle part of the nasal cavity usually drain both rostrally and caudally.

LYMPH VESSELS OF THE LARYNX

The lymph vessels of the larynx drain to both the medial retropharyngeal and the cranial cervical lymph nodes. The lymph vessels of the laryngeal mucosa, the cartilages of the larynx, and the internal laryngeal muscles merge to form several small vessels that leave the larynx by 3 different routes (groups A to C, below).

Group A

Two to 3 of the lymph vessels pass through the pharyngeal muscles, usually either between the *M. keratopharyngeus* and *M. thyropharyngeus*, or at the angle between these two muscles and the *M. hyothyroideus* (Figure 16: *k*), and then run on the pharyngeal muscles to the aforementioned lymph nodes.

Group B

One to 2 other lymph vessels emerge either between the thyroid cartilage and the cricoid cartilage at the ventral margin of the *M. cricothyroideus*, between it and the *M. hyothyroideus*, or through the *M. hyothyroideus* (Figures 14: 9; 16: *k'*), and run over both surfaces of the *M. sternothyroideus*, continuing on the pharyngeal muscles towards the medial retropharyngeal lymph node.

Group C

Lastly, 1 to 2 lymph vessels emerge at the caudal edge of the cricoid cartilage, near its plate, and drain to the aforementioned lymph nodes (Figure 16: *k''*). If a cranial cervical lymph node is present, then 1 to 2 vessels of this group will additionally drain to it (Figure 16: *k'''*).

The lymph vessels of the laryngeal mucosa form very fine networks in and under it. The lymph vessels arising from the networks initially run under the mucosa for varying distances. At the epiglottis, the lymph vessels form abundant networks under the mucosa of both its surfaces. One to 2 lymph vessels emerge from the network on each surface, merging in the aryepiglottic fold to form 1 to 2 vessels, which then pass between *M. keratopharyngeus* and *M. thyropharyngeus*, specifically in the gap between these two muscles and the *M. hyothyroideus*, to the other side (see group A, above).

The lymph vessels of the thyroid cartilage join groups A and B, those of the cricoid cartilage join group C, and those of the arytenoid cartilage join group A. The lymph vessels of both the vocal cord and vocal fold join group A.

The lymph vessels of the external laryngeal muscles (*M. hyothyroideus* [Figure 23: *g*] and *M. cricothyroideus*) as well as the pharyngeal constrictors located on the larynx (*M. keratopharyngeus*, *thyropharyngeus* and *cricopharyngeus*) (Figure 23: *f*, *h*) emerge from the surface of these muscles and drain directly to the medial retropharyngeal lymph node (Figure 23: *l*).

LYMPH VESSELS OF THE TRACHEA

The tracheal lymph vessels ([Figure 23: a, a](#)) drain to the medial retropharyngeal lymph node ([Figure 23: 1](#)), the deep cervical lymph nodes ([Figure 23: 2, 3, 4](#)), the cranial mediastinal lymph nodes ([Figure 23: 6, 6'](#)), and the bronchial lymph nodes. A description of the drainage from the separate sections of the trachea follows:

A. CERVICAL TRACHEA

The lymph vessels from the cranial third or fourth of the trachea (see [Figure 23](#)) drain to the medial retropharyngeal lymph node ([Figure 23: 1](#)). The small lymph vessels arising from both the lymphatic network of the mucous membrane and from the cartilage almost all emerge on the dorsal side, to a lesser extent on the lateral surface of the trachea, and continue on the trachea as 2 to 4 small vessels to drain to the medial retropharyngeal lymph node. If a cranial cervical lymph node ([Figure 23: 2](#)) is present, then some of the lymph vessels from the initial part of the trachea usually also drain to it (see [Figure 23](#)). However, I have also observed cases in which, despite the presence of a cranial cervical lymph node, no tracheal lymph vessels were observed entering it.

Small lymph vessels arise from the middle and caudal third of the cervical trachea, also emerging mainly on the dorsal, left, and right surfaces of the trachea and merging to form 1-2 larger vessels. These lymph vessels run caudally on the trachea (on the left side, also on the esophagus) and, when a caudal cervical lymph node ([Figure 23: 4](#)) is present, either some or all drain to this lymph node. A small number of the lymph vessels usually continue on to drain to a cranial mediastinal lymph node ([Figure 23: 6, 6'](#)): on the left side, usually into the cranial mediastinal lymph node located in the 1st intercostal space ([Figure 23: 6](#)) as well as the cranial mediastinal lymph node located on the left side of the cranial vena cava ([Figure 23: 6'](#)), and, on the right side, usually to the main cranial mediastinal lymph node ([Figure 18: 3](#)) that is located between the costocervical vein and the cranial vena cava. If the caudal cervical lymph node is absent, then all the lymph vessels drain directly into the cranial mediastinal lymph nodes. If (though rarely the case) a middle cervical lymph node ([Figure 23: 3](#)) is present, some of the lymph vessels of the cervical part of the trachea will additionally drain to it.

From the border area between the cranial and middle third of the cervical trachea, lymph vessels can drain in both directions; however, lymph vessels from the border between the cranial and middle third, and even those from the cranial quarter of the cervical trachea, may drain only to either the cranial mediastinal or caudal cervical lymph nodes. When lymph vessels are injected on one side of the trachea, they are frequently found to emerge on the other side of the trachea. It remains to be seen whether there is a true crossing of the median plane by the lymphatics, however, since there is always some degree of extravasation with the injection and this can reach the median plane.

B. THORACIC TRACHEA (WITHIN THE THORACIC CAVITY) (FIGURE 18: R)

The lymph vessels from the cranial part of the thoracic trachea drain to the cranial mediastinal lymph nodes ([Figure 18](#): 3, 3¹, 3², 3³) and may enter any lymph node of this group. The lymph vessels from the caudal or terminal part of the trachea, as well as from the part of the main bronchi outside the lungs, drain to all the lymph nodes in the tracheobronchial lymph node group ([Figure 18](#): 1, 2). Occasionally, a lymph vessel of the main bronchi may also drain to a pulmonary lymph node. The lymph vessels can emerge from all parts of the trachea between 2 tracheal rings.

Lymph vessels of the thoracic trachea were frequently observed to cross the median plane, so that, for example, the lymph vessels emerging on the left side of the trachea would drain to the cranial mediastinal lymph nodes located on the right side (contralateral drainage).

The lymph vessels of the tracheal mucosa form abundant networks of very tiny vessels. The lymph vessels emerging from these networks merge with the lymph vessels of the cartilage before they pass externally through the intercartilaginous spaces, so that lymph vessels of the mucosa and those of the cartilaginous rings cannot be clearly differentiated; the best differentiation is achieved when each group is injected separately. On the external aspect of the trachea, the lymph vessels form the usual large networks.

LYMPH VESSELS OF THE LUNGS

All the lymph vessels of the lungs ([Figure 20](#)) drain to the bronchial lymph nodes (tracheobronchial and pulmonary lymph nodes). They are remarkably difficult to inject in dogs, at least much more difficult than those from cattle (specifically, calves). It is also difficult to separate the lymph vessels of the pleura from the lymph vessels of the superficial parenchymal layer during the injection. Because of the thinness of the pleura, it is not possible to decide with certainty whether the needle is only in the pleura or whether it has penetrated into the superficial lung layer as well.

Nevertheless, it is possible to inject the more obvious serosal or subserosal networks, which are relatively coarsely meshed. Occasionally, the lymph vessels arising from the subserosal (superficial) networks can be traced further; in some cases, it was possible to follow a subserosal lymph vessel arising from such a network to the lymph node(s) into which the deep lymph vessels of the respective lung lobe drained (see below). Examples of these lymph vessels are designated as 6 and 6' in [Figure 20](#). In other cases, such subserosal lymph vessels could only be traced for a short distance, before they descended and traveled deeply (as shown in [Figure 20](#) in several places [e.g. at 7, 7, 7]). A subserosal lymph vessel from one area of the lung may additionally run around the border of the lung to another area of the lung, most commonly from the costal area to the diaphragmatic area, as in the case of the lymph vessel labeled as 5 in [Figure 20](#). In some of the cases in which the subserosal networks were filled by injection, it was not possible to identify lymph vessels arising from the networks and extending subserously, so it is assumed that the lymph vessels that arose from the networks immediately run deeply and join with the deep lymph vessels. On the other hand, the filling of a subserosal lymph vessel was often observed

(although not nearly as often as in the cow) when deep injections of the lung were made – this lymph vessel could usually only be followed for a few centimeters before it returned to the depth.

The above findings demonstrate that superficial (subserosal) and deep lymph vessels cannot be clearly differentiated. The deep lymph vessels merge within each individual lung lobe to form 2 to 4 trunks, which then leave the lobe of the lung accompanied by its bronchus and its blood vessel (a branch of the pulmonary artery and a pulmonary vein). Most of these lymph vessels are located on the dorsal wall of the bronchus and on its borders but occasionally are also present on its ventral side. The 1 deep lymph vessels of the left apical lobe (the cranial part of the left cranial lobe)¹ and left cardiac lobe (the caudal part of the left cranial lobe) emerge from each of the 2 lobes as 2 to 3 vessels, then merge to form 2 to 4 vessels, before draining into the left tracheobronchial lymph node. Most of the deep lymph vessels of the left diaphragmatic lobe (the left caudal lobe) drain to the middle tracheobronchial lymph node, and to a left pulmonary lymph node if present. However, 1 of these lymph vessels usually travels further, over either the ventral edge of the left main bronchus or the end of the trachea, to drain to the left tracheobronchial lymph node. The deep lymph vessels of the right diaphragmatic lobe (the right caudal lobe) drain to the middle and right tracheobronchial lymph nodes and to the right pulmonary lymph node if one is present. The deep lymph vessels of the right cardiac lobe (the right middle lobe) go either under the right main bronchus and drain to the middle tracheobronchial lymph node, or under the bronchus of the right apical lobe (the right cranial lobe), draining to the right tracheobronchial lymph node. The deep lymph vessels of the right apical lobe additionally drain to the right tracheobronchial lymph node, while those of the accessory lobe drain to the middle tracheobronchial lymph node. The lymph vessels of the bronchi join the deep lung lymph vessels.

LYMPH VESSELS OF THE THYMUS

The lymph vessels of the thymus merge to form 4 to 6 trunks on each side and drain to both the cranial mediastinal and sternal lymph nodes, with possible additional drainage to all the lymph nodes in the cranial mediastinal group. It could not be determined whether the lymph vessels from the small part of the thymus that extend through the thoracic inlet onto the neck in very young animals drain to the caudal cervical lymph node.

LYMPH VESSELS OF THE THYROID GLAND

The lymph vessels of the thyroid gland ([Figures 2, 6, 8, 16: 1](#)) drain to the medial retropharyngeal lymph node, the cranial, middle, and caudal cervical lymph nodes, and the cranial mediastinal lymph nodes, and additionally are frequently found to drain directly into either the tracheal duct or the internal jugular vein. The thyroid lymph vessels were injected in 17 dogs, most often on both sides.

The lymph vessels that drain to the medial retropharyngeal lymph node ([Figures 2, 6, 8, 16: a, a'](#)) and

¹ The current naming of the lung lobes from Miller's Anatomy of the Dog (5th edition) is included in parentheses.

to the cranial cervical lymph node (Figures 2, 6, 8 and 16: *b, b'*) arise near the cranial end of the thyroid gland, while the lymph vessels that drain to the caudal (and middle) cervical lymph node(s) (Figures 8, 16: *c, c'*) and the cranial mediastinal lymph nodes arise from both surfaces of the caudal half of the thyroid gland.

However, there are frequent exceptions to this rule: in Figure 8, for example, a lymph vessel originating from the caudal part of the thyroid gland was found to drain to a cranial cervical lymph node (*k'*). Occasionally, all lymph vessels arising from the caudal end of the thyroid gland may drain to both the medial retropharyngeal and cranial cervical lymph nodes (Figure 6). If there are two medial retropharyngeal lymph nodes, then the lymph vessels of the thyroid gland usually open into both of them (Figures 8, 16: *a, a'*).

During injection, rich, coarse lymphatic networks fill in the capsule, but soon coalesce. The lymph vessels draining to the medial retropharyngeal and cranial cervical lymph nodes usually merge to form 3 to 4 small vessels, after which either some or all drain to the cranial cervical lymph node when it is present, while the lymph vessels that do not enter the cranial cervical lymph node drain directly to the medial retropharyngeal lymph node. If the cranial cervical lymph node is absent, all lymph vessels drain directly to the medial retropharyngeal lymph node. In 1 case in which a cranial cervical lymph node was present, none of the cranial lymph vessels of the thyroid gland were observed to drain to it (Figure 2).

Likewise, the lymph vessels running along the trachea and esophagus and draining to the caudal cervical and cranial mediastinal lymph nodes merge to form 1 to 3 trunks. If a caudal (or middle) cervical lymph node (Figure 8, 16: *c'*) is present, then either all or some of these lymph vessels drain to it, while the rest (Figure 16: *l*) drain directly into a cranial mediastinal lymph node. If the caudal cervical lymph node is absent, all these lymph vessels drain directly to the cranial mediastinal lymph nodes, with a preference on the left side for the cranial mediastinal lymph node that lies on the left side of the cranial vena cava.

The thyroid lymph vessels frequently cross the median plane, even in those cases where an isthmus is not present. If there is an isthmus between both thyroid glands, then the injected fluid passes from one thyroid gland through the isthmus into the other thyroid gland, and the lymph vessels on both sides fill up even though only one side was injected.

An interesting example of a pronounced median crossing of thyroid lymph vessels was seen in one of the cases mentioned above, in which lymph vessels draining caudally from the left thyroid gland to the caudal cervical and cranial mediastinal lymph nodes could not be injected. In this case, close examination revealed that some of the lymph vessels passed directly over the ventral aspect of the trachea to the right side then ran down the right side of the trachea and drained to a caudal cervical lymph node located on the ventral aspect of the trachea. The thyroid lymph vessels also have a strong tendency to form networks.

It is evident from the above description that, while one can generally consider there to be both cranial and caudal drainage areas of the lymph vessels of the thyroid gland, these two areas cannot be clearly

demarcated, and the division into lateral and medial drainage areas is even less evident.

It is striking how often lymph vessels of the thyroid gland open directly, i.e. without having passed a lymph node, into either the tracheal duct or into the venous system ([Figure 2: k](#)). I was able to demonstrate this finding in approximately one-third to one-half of all 17 dogs examined. In all cases, it was the caudal lymph vessels of the thyroid gland that merged to form a small trunk which, near the thoracic inlet, opened either into the tracheal duct (right or left) or into the internal jugular vein, even though a caudal or middle cervical lymph node was present in some of these cases. For more details see Baum [8]. It is also remarkable that the blue injection fluid often appeared in the internal jugular vein during injections into the thyroid gland, similarly to the transfer of injection fluid into veins that can be observed during the injection of bone lymph vessels.

2.10 LYMPH VESSELS OF THE URINARY ORGANS

GENERAL

The lymph vessels of the urinary organs (kidneys, adrenal glands, ureters, bladder, and female urethra) drain to the lumbar aortic lymph nodes, the medial iliac lymph nodes, and the hypogastric lymph nodes.

LYMPH VESSELS OF THE KIDNEYS

The lymph vessels of the kidneys ([Figure 27: f, f'](#)) are divided into two groups: those of the renal capsule and those of the renal parenchyma.

A. LYMPH VESSELS OF THE RENAL CAPSULE

The lymph vessels of the renal capsule form extensive networks within the capsule. The lymph vessels arising from the capsular networks drain to the lumbar aortic lymph nodes, including the cranial lumbar aortic lymph node, and can drain to all lymph nodes in this group, even the most caudal ones. The lymph vessels from the cranial part of the renal capsule usually drain to the cranial lumbar aortic lymph node ([Figure 27: 1, 1'](#)) and to the lumbar aortic lymph node located at the renal artery and vein ([Figure 27: 2](#)). The lymph vessels from the caudal part of the renal capsule usually drain to the lumbar aortic lymph node located at the renal artery and vein, as well as the lumbar aortic lymph nodes caudal to it ([Figure 27: 3](#)). The lymph vessels emerge from all parts of the capsule, first running between the fibrous renal capsule and either the adipose capsule or serosa (the peritoneum) to the medial, cranial, or caudal margin of the kidney, and, from there, run subperitoneally to the lymph nodes mentioned above. Frequently, individual lymph vessels form large arcs that extend in a caudal direction.

A connection between the capsular and the parenchymal lymph vessels could be established. When puncturing and injecting the parenchyma, particularly its superficial layer, capsular lymph vessels were almost always filled. But it is difficult to determine whether capsular lymph vessels enter the parenchyma and join or merge with its lymph vessels. In several cases, I was able to demonstrate that the injected capsular lymph vessels did not run into the kidney but instead went directly to the lymph nodes. In other cases, in addition to the lymph vessels draining directly to the lymph nodes, parenchymal lymph vessels were also filled. However, it was never clear in such cases whether this filling was truly from the capsule or, more specifically, from the capsular lymph vessels. Due to the thinness of the fibrous capsule, it was rare to fill only capsular lymph vessels – the capsule itself will always be punctured, and the lymph vessels of the renal surface will be filled. This can then be mistaken for capsular lymph vessels connecting to the parenchymal lymph vessels.

I was also able to demonstrate that lymph vessels in the fibrous capsule were present in all cases. Therefore, I could not confirm the statement by Kumita [22] that the fibrous capsule of the kidney lacks lymph vessels in some cases, and that capsular lymph vessels penetrate the parenchyma. I will address these areas in a detailed paper. The lymph vessels of the adipose capsule join those of the fibrous capsule.

B. LYMPH VESSELS OF THE RENAL PARENCHYMA

The lymph vessels of the renal parenchyma leave the kidney through its hilus in the form of 5 to 8 lymph vessels of varying sizes, which travel with the renal blood vessels to drain to the closest lumbar aortic lymph nodes. Lymph vessels from these lymph nodes then usually run to the more caudally located lumbar aortic lymph nodes and then to the medial iliac lymph node, and also in the cranial direction to the cranial lumbar aortic lymph node. Parenchymal lymph vessels may also drain directly to the cranial lumbar aortic lymph node. Additionally, since the lymph vessels of the capsule almost always fill during the injection of dye into the parenchymal lymphatics (see above), and the capsular lymph vessels drain to the cranial lumbar aortic lymph node and the more caudally located lumbar aortic lymph nodes, these lymph nodes will also fill with dye during injection of parenchymal lymph vessels.

Lymph vessels of the kidney and the renal capsule could not be traced directly to the medial iliac lymph node, but relatively often (6 times in 12 examined dogs, or in half of all cases), I observed that the lymph vessels of both the kidney and the renal capsule opened directly into the *cisterna chyli* (for details see Baum [8]). Additionally, the lymph vessels of the renal capsule are often connected with the testicular lymph vessels (see lymph vessels of the testis).

LYMPH VESSELS OF THE URETER

The lymph vessels of the cranial part of the ureter drain to the lumbar aortic lymph nodes, those of the middle part drain to the medial iliac lymph node, and those of the caudal part drain to the hypogastric lymph nodes. The lymph vessels of the caudal part of the ureter merge into 1 to 2 vessels which accompany the ureter until it nears the urinary bladder before running in the lateral ligament of the urinary bladder and entering the hypogastric lymph nodes.

LYMPH VESSELS OF THE URINARY BLADDER

Most of the lymph vessels of the urinary bladder (Figure 32: *i*) drain to the medial iliac lymph nodes (Figure 32: *l*), while a small number drain to the hypogastric lymph nodes (Figure 32: *3*). These lymph vessels form very coarse, subserosal networks; the lymph vessels emerging from these networks run somewhat longitudinally in the dorsal wall of the urinary bladder.

The lymph vessels from the apex (vertex) and the body of the urinary bladder run in the form of several vessels into the lateral ligament of the urinary bladder ([Figure 32: m](#)), where they form coarse networks and merge into 1 to 2 vessels, which then either accompany the external iliac artery and vein, or run near them, to drain to the medial iliac lymph node ([Figure 32: l](#)). Some of the lymph vessels of the apex and body of the bladder merge with the lymph vessels of the caudal part of the bladder and the neck of the bladder, as well as with the lymph vessels of the prostate gland in males (see lymph vessels of the prostate) and of the urethra in females (see lymph vessels of the female urethra) to drain with these to the hypogastric lymph nodes ([Figure 32: 3](#)).

Rarely, the lymph vessels of the urinary bladder were observed crossing the median plane. These were always lymph vessels originating from the part of the urinary bladder located between the lateral ligament, the pubovesical ligament, and the median umbilical (*vesicoumbilicale*) ligament, which then pass around the ventral border of the urinary bladder to the other side and drain to the contralateral lymph nodes ([Figure 32: 8](#)).

LYMPH VESSELS OF THE FEMALE URETHRA

The lymph vessels of the female urethra ([Figure 29: i](#)) join those of the vagina and the uterine body, draining with them to the hypogastric lymph nodes ([Figure 29: 4](#)), in some cases directly to the medial iliac lymph nodes ([Figure 29: l](#)), or to the lateral sacral lymph node ([Figure 29: 7](#)).

For the lymph vessels of the male urethra, see the section on male genital organs (lymph vessels of the male urethra).

LYMPH VESSELS OF THE ADRENAL GLANDS

The lymph vessels arising from each adrenal gland ([Figure 28: d, d'](#)) merge to form 2 to 3 small trunks, which drain on each side to the cranial lumbar aortic lymph node ([Figure 28: 3, 3'](#)).

2.11 LYMPH VESSELS OF THE MALE GENITAL ORGANS

GENERAL

The lymph vessels of the male genital organs drain to the superficial inguinal, medial iliac, lumbar aortic, hypogastric, and lateral sacral lymph nodes.

LYMPH VESSELS OF THE SCROTUM

All the lymph vessels of the scrotum ([Figure 31: v'](#)) drain to the superficial inguinal lymph nodes ([Figure 31: 4](#)), forming coarse networks through anastomosis. Some of these lymph vessels cross both surfaces of the spermatic cord.

LYMPH VESSELS OF THE TESTIS

The lymph vessels of the testis ([Figure 38](#)) and epididymis run in the spermatic cord into the abdominal cavity, and, from here, drain to the medial iliac and lumbar aortic lymph nodes, and, in rare cases, to the hypogastric lymph nodes as well.

The lymph vessels of the testis ([Figure 31: w](#)) form extremely numerous and extremely fine networks in the *tunica albuginea* (capsule). These lymph vessels fully penetrate the entire *tunica albuginea* and continue into the *tunica albuginea* lining the epididymis pouch and into the *tunica albuginea* of the epididymis ([Figure 31: x](#)). Due to this vascular structure, the lymphatic networks in the *tunica albuginea* of the epididymis pouch and the epididymis receive lymph from the networks in the *tunica albuginea* of the testis.

Numerous lymph vessels of varying sizes emerge from these lymphatic networks at the epididymis, particularly at its dorsal border and *caput epididymis* (head), and mostly accompany the blood vessels of the spermatic cord, forming rich, coarse networks, especially in the half of the spermatic cord facing the testis (see [Figure 31](#)). A smaller number of lymph vessels of the testis and epididymis either run in the mesorchium or accompany the *ductus deferens* ([Figure 31: y'](#)). All these lymph vessels are in proximity to each other at the inner inguinal ring, and at this location, there are 3 to 4 vessels.

From the inner inguinal ring, some of the lymph vessels run in the *plica vasculosa* in a craniodorsal direction towards the medial iliac lymph node ([Figure 31: 1](#)) and the lumbar aortic lymph nodes ([Figure 31: 2, 2'](#)). These lymph vessels usually drain to the caudal lumbar aortic lymph nodes ([Figure 31: 2](#)), though sometimes they also drain to the more cranially located lymph nodes ([Figure 31: 2'](#)), and, at times, even to those located at the renal artery and vein. Usually, the lymph vessels open into both the medial iliac and lumbar aortic groups of lymph nodes, less often only into the lumbar aortic lymph nodes.

Other lymph vessels (1 to 2 vessels) from this group accompany the *ductus deferens* (*vas deferens*) from the inner inguinal ring to the neck of the urinary bladder before turning to drain into the medial iliac lymph node (Figure 31: 1). More frequently, one of these lymph vessels will also drain into the hypogastric lymph nodes (Figure 31: 3), as shown in Figure 31.

Frequently, some of the lymph vessels draining from the testis to the lumbar aortic lymph nodes may fill with dye up to the renal capsule, where they connect with the lymph vessels of the renal capsule (Figure 31: 8). Furthermore, the lymph vessels of the testis were frequently observed (in about two-thirds of all examined dogs) to open directly, i.e. without having passed a lymph node, into the *cisterna chyli*. Usually, this behaviour was shown by 1 lymph vessel, while the other lymph vessels of the testis drained into the aforementioned lymph nodes. In other cases, the lymph vessels of the testis merged to a single vessel in the abdominal cavity, from which branches drained to the lymph nodes, but the vessel itself could be followed to the *cisterna chyli* (for details see Baum [8]).

Additionally, in 1 case, I observed 1 of the lymph vessels of the testis pierce the *tunica vaginalis communis* and, near the external inguinal ring, run towards the femoral canal to join its lymph vessels.

LYMPH VESSELS OF THE *DUCTUS DEFERENS*

The lymph vessels of the *ductus deferens* merge with those of the testis and epididymis.

LYMPH VESSELS OF THE *M. CREMASTER* AND THE *TUNICA VAGINALIS COMMUNIS*

The lymph vessels of the *M. cremaster* and the *tunica vaginalis communis* accompany the *M. cremaster* in the form of 1 to 2 vessels and, at the internal inguinal ring, join the lymph vessels of the testis that drain to the medial iliac and lumbar aortic lymph nodes and run in the *plica vasculosa* (see lymph vessels of the testis).

LYMPH VESSELS OF THE PROSTATE

The lymph vessels of the prostate (Figure 32: k) drain to the medial iliac, hypogastric, and lateral sacral lymph nodes. They form a coarse network on the surface of the prostate, from which 3 to 5 lymph vessels emerge on each side: these run either in the lateral ligament of the urinary bladder, or under the peritoneum attached to the lateral pelvic wall, continuing to form coarse networks by dividing and merging, to drain to the medial iliac lymph node (Figure 32: 1) and the hypogastric lymph nodes (Figure 32: 3). If a lateral sacral lymph node (Figures 32: 5) is present, one of these lymph vessels will usually also enter this lymph node.

Some of the lymph vessels of the pelvic part of the urethra may be filled from the prostate, but these

lymph vessels usually then drain to the same lymph nodes as mentioned above. Lymph vessels of the neck of the urinary bladder may also be filled from the prostate, but I cannot be sure if this involves communications between the prostate and urinary bladder lymph vessels. Gerota (*Archiv für Anatomie und Physiologie*, Volume 5/6, 1897) assumes that this is the case, as he has stated: “In man, the lymph vessels of the fundus of the bladder communicate with those of the prostate and seminal vesicles”. Walker [28] describes the lymph vessels of the prostate of the dog in detail, though it is difficult to determine which lymph nodes are involved from his description. According to his illustrations, lymph vessels of the prostate also drain into the deep inguinal lymph node and to lymph nodes located on the rectum, but I have not observed drainage from the prostate to either of these groups of lymph nodes.

LYMPH VESSELS OF THE PREPUCE

The lymph vessels of the prepuce (Figures 31, 32: v) drain to the superficial inguinal lymph nodes (Figures 31: 4; 32: 4, 6, 6'). The lymph vessels of the integumentary layer (Figure 32: 6, 6') form coarse networks in the subcutis, while those of the parietal layer (Figure 31) form extraordinarily rich and fine networks in the parietal layer and the submucosa; these networks are, of course, not clearly separated. The lymph vessels emerging from these networks run between both layers to the base of the preputial sac. From here, some of the lymph vessels (Figure 32: 6) join the lymph vessels of the penis, which are closely attached to the penis, particularly on its dorsum, and run to the superficial inguinal lymph nodes (Figure 32: 4). Other preputial lymph vessels (Figures 31: 5, 6; 32: 6'), however, run from the base of the preputial sac more in the fat between the penis and the ventral abdominal wall, in the caudal direction, to drain to the superficial inguinal lymph nodes (Figures 31, 32: 4), often curving quite far laterally from the penis or forming large lateral loops, as shown in Figure 31.

For lymph vessels of the visceral layer of the prepuce, see the lymph vessels of the penis.

LYMPH VESSELS OF THE PENIS AND THE GLANS

Most of the lymph vessels of the penis (including the *M. ischiocavernosus* and *M. bulbocavernosus*) and the glans (including the visceral layer of the prepuce) drain to the superficial inguinal lymph nodes, while a smaller number drain to the lateral sacral and hypogastric lymph nodes. A description of their detailed behaviour follows:

The lymph vessels of the glans, including the visceral layer of the prepuce (Figure 32: t), form extraordinarily fine networks in the visceral layer of the prepuce covering the glans. The lymph vessels which develop from these networks run either in the visceral layer or just under it to the base of the preputial sac, which lies immediately caudal to the *bulbus glandis*. Here, the lymph vessels emerge from under the visceral layer and continue to run caudally close to the penis, usually on its dorsum, though some may also run on its lateral surfaces, to drain to the superficial inguinal lymph nodes (Figure 32: 4). Before

reaching the lymph nodes, most of the lymph vessels run caudally past them, often as far as the vicinity of the ischial arch, before turning again in a cranial direction towards the lymph nodes; due to this pattern, they form large, caudally extended loops, which are shown in Figure 32.

The lymph vessels of the penis (Figure 32: *s*) join with the lymph vessels of the glans and drain with them to the superficial inguinal lymph nodes. The lymph vessels of the *crus penis*, including the *M. ischiocavernosus* (Figure 32: *r*) and the *M. bulbocavernosus* (Figure 32: *q*), take one of two paths: some of these lymph vessels join with the lymph vessels of the penis, as shown in Figure 32, and drain with them to the superficial inguinal lymph nodes (Figure 32: 4), while others (1 to 2 vessels) enter the pelvic cavity and run subperitoneally along the lateral pelvic cavity wall to drain to the hypogastric lymph nodes (Figure 32: 3). If a lateral sacral lymph node (Figure 32: 5) is present, one of these lymph vessels will usually enter this node first.

Direct drainage of the lymph vessels to the medial iliac lymph nodes was not observed in 4 more closely examined cases. The lymph vessels of the penis form extensive networks in the *tunica albuginea* of the penis.

LYMPH VESSELS OF THE MALE URETHRA

The lymph vessels of the male urethra (Figure 32) drain to the superficial inguinal, hypogastric, medial iliac, and lateral sacral lymph nodes. From the initial part of the pelvic urethra (Figure 32: *l*), the lymph vessels join those of the prostate and drain with them to the medial iliac lymph nodes (Figure 32: *l*) and the hypogastric lymph nodes (Figure 32: 3). If a lateral sacral lymph node (Figure 32: 5) is present, then usually one of these lymph vessels will also drain to this lymph node. From the terminal part of the pelvic urethra, the lymph vessels join with those of the *crus penis*, the *M. ischiocavernosus* and *M. bulbocavernosus* (Figure 32: *q, r*) (see lymph vessels of the penis and the glans) and run with them either on the penis to drain to the superficial inguinal lymph nodes (Figure 32: 4), or subperitoneally in the pelvic cavity to drain to the hypogastric lymph nodes (Figure 32: 3). If a lateral sacral lymph node (Figure 32: 5) is present, one of these lymph vessels will usually (but not always) enter it.

The lymph vessels from the penile part of the urethra (Figure 32: 7) join with those of the penis and drain with them to the superficial inguinal lymph nodes (Figure 32: 4).

For the lymph vessels of the female urethra, see the section on lymph vessels of the urinary system (lymph vessels of the female urethra).

2.12 LYMPH VESSELS OF THE FEMALE GENITAL ORGANS

GENERAL

The lymph vessels of the female genital organs (ovary, uterus, vagina, vaginal vestibule, vulva, and clitoris) drain to the lumbar aortic, medial iliac, hypogastric, lateral sacral, and superficial inguinal lymph nodes.

LYMPH VESSELS OF THE OVARY

The lymph vessels of the ovary ([Figure 29: b](#)) drain to the lumbar aortic lymph nodes ([Figure 29: 2,3](#)). They form extensive, coarsely meshed networks in the fat that envelops the ovary, as well as in the suspensory ligament of the ovary ([Figure 29: k](#)), particularly in the ventromedial portion. Usually, 3 to 4 lymph vessels emerge from these networks and drain into the lumbar aortic lymph nodes, most commonly to the lumbar aortic lymph nodes located at the renal artery and vein.

No lymph vessels could be traced from the ovary to the medial iliac lymph nodes in 4 cases examined in more detail.

LYMPH VESSELS OF THE UTERUS

The lymph vessels of the uterus ([Figure 29: c, d](#)) drain to the lumbar aortic lymph nodes ([Figure 29: 2, 3](#)), the medial iliac lymph nodes ([Figure 29: 1](#)), the hypogastric lymph nodes ([Figure 29: 4](#)), and the lateral sacral lymph nodes ([Figure 29: 7](#)). From the cranial half of the uterine horn, lymph vessels drain to 1 to 2 lumbar aortic lymph nodes, with a preference for the lymph nodes that are located on the renal artery and vein ([Figure 29: 2, 3](#)), as well as to the medial iliac lymph node ([Figure 29: 1](#)).

Lymph vessels of the caudal half of the uterine horn drain to the medial iliac lymph node ([Figure 29: 1](#)) and to the hypogastric lymph nodes ([Figure 29: 4](#)), and those from the uterine body drain to the hypogastric lymph nodes, and into the lateral sacral lymph node ([Figure 29: 7](#)), if one is present.

The lymph vessels of the uterus form rich, coarsely meshed networks under the serosa and adjacent to the uterus in the uterine broad ligaments. The lymph vessels emerging from these networks usually initially run in the broad ligament of the uterus, proximate and parallel to the uterus and uterine horn. They then curve quite sharply away from the uterus and uterine horn and run in the broad ligament of the uterus to drain to the lymph nodes mentioned above.

Macroscopically, I have not been able to make any definite conclusions about the relationship between the lymph vessels of the individual layers of the uterine wall (mucous membrane, muscular layer) (see Baum [6], page 155). Occasionally, one of the lymph vessels may curve from one surface of the uterus and uterine horn towards the opposite surface ([Figure 29: 8](#)), travelling around the side opposite to the insertion of the broad ligament.

LYMPH VESSELS OF THE VAGINA

Some of the lymph vessels of the vagina ([Figure 29: e](#)) join those of the body of the uterus and drain with them to the hypogastric lymph nodes ([Figure 29: 4](#)), and, if a lateral sacral lymph node ([Figure 29: 7](#)) is present, also to it. Other lymph vessels join those of the vaginal vestibule and drain to the same lymph nodes.

LYMPH VESSELS OF THE VAGINAL VESTIBULE

Some of the lymph vessels of the vaginal vestibule ([Figure 29: f](#)) drain with those of the vagina to the hypogastric lymph nodes ([Figure 29: 4](#)) and to the lateral sacral lymph nodes ([Figure 29: 7](#)), though others also drain to the superficial inguinal lymph nodes ([Figure 29: 5](#)), as demonstrated in [Figure 29](#). Occasionally, a lymph vessel of either the vagina or the vaginal vestibule bypasses the hypogastric lymph nodes and will either flow directly into the medial iliac lymph node ([Figure 29: 1](#)), or into the lateral sacral lymph node ([Figure 29: 7](#)).

LYMPH VESSELS OF THE VULVA AND CLITORIS

Some of the lymph vessels of the vulva, including the clitoris ([Figure 29: g](#)), which again form coarse networks, run as 2 to 4 vessels subcutaneously over the medial side of the thigh near the pelvic symphysis, forward to the superficial inguinal lymph nodes ([Figure 29: 5](#)). Other lymph vessels of the vulva enter the pelvic cavity in the form of 1 to 2 vessels, running subperitoneally to drain to the hypogastric lymph nodes ([Figure 29: 4](#)). If a lateral sacral lymph node ([Figure 29: 7](#)) is present, 1 of these vessels will usually also open into it; 1 of the lymph vessels may also drain directly to the medial iliac lymph node ([Figure 29: 1](#)).

LYMPH VESSELS OF THE MAMMARY GLANDS (APPENDED SECTION)

The lymph vessels of the mammary glands ([Figure 30](#)) drain to the superficial inguinal, axillary, and sternal lymph nodes.¹ The lymph vessels from the caudal half of the mammary chain, including the 3 caudal of the 5 teats, drain to the superficial inguinal lymph nodes ([Figure 30: 1, 1'](#)). The lymph vessels from the cranial half of the mammary chain, including the 3 cranial of the 5 teats, drain to the axillary lymph node. If an accessory axillary lymph node ([Figure 30: 2](#)) is present, some vessels will also drain to it, with the remainder draining to the sternal lymph node. The lymph vessels from the middle part of the mammary chain, corresponding to the 3rd teat, drain to all lymph node groups.

The lymph vessels of the teats and the skin of the mammary glands form subcutaneous, coarsely meshed networks ([Figure 30](#)), from which the lymph vessels that lead to the aforementioned lymph nodes emerge. Most of these lymph vessels run subcutaneously to the lateral edge of the mammary chain and, as shown in [Figure 30](#), then run either cranial to drain to the axillary lymph node ([Figure 30: 2](#)), or caudal to the superficial inguinal lymph nodes ([Figure 30: 1, 1'](#)). However, some of the lymph vessels ([Figure 30: c, c](#)) also enter the mammary gland parenchyma, passing through it to run between the mammary glands and the ventral abdominal and thoracic walls to drain to the aforementioned lymph nodes, most gradually curving towards the lateral edge of the mammary chain and joining the lymph vessels described above. Additionally, some of the lymph vessels passing through the mammary parenchyma drain to the sternal lymph node, joining with the corresponding lymph vessels of the mammary parenchyma (see below). This behaviour was demonstrated only by the lymph vessels originating from the cranial 2 or 3 teats, or their skin, though not by the lymph vessels from the skin between these teats.

All these lymph vessels, including the lymph vessels that form the networks, are remarkable because of their considerable strength (thickness).

Some of the lymph vessels of the mammary parenchyma emerge subcutaneously in various places along the surface of the mammary parenchyma ([Figure 30: a, a](#)), joining with the lymph vessels or networks of the skin. Other lymph vessels merge with the cutaneous lymph vessels that penetrate the mammary parenchyma, running between the mammary glands and the ventral abdominal and thoracic walls to drain to the aforementioned lymph nodes (superficial inguinal and axillary lymphnodes) ([Figure 30: b, b](#)), most also curving toward the lateral margin of the mammary chain (see above).

1 Additional references for the lymphatic drainage of the healthy and neoplastic mammary glands of the dog include: (1) Patsikas MN, Dessiris A. The lymph drainage of the mammary glands in the bitch: a lymphographic study. Part I: The 1st, 2nd, 4th and 5th mammary glands. *Anat Histol Embryol.* 1996 Jun;25 (2):131-8., (2) Patsikas MN, Dessiris A. The lymph drainage of the mammary glands in the Bitch: a lymphographic study. Part II: The 3rd mammary gland. *Anat Histol Embryol.* 1996 Jun;25(2):139-43., and (3) Patsikas MN, Karayannopoulou M, Kaldrymidoy E, Papazoglou LG, Papadopoulou PL, Tzegas SI, Tziris NE, Kaitzis DG, Dimitriadis AS, Dessiris AK. The lymph drainage of the neoplastic mammary glands in the bitch: a lymphographic study. *Anat Histol Embryol.* 2006 Aug;35(4):228-34.

However, some of the lymph vessels running deep to the mammary parenchyma also drain to the sternal lymph node; 1 to 2 lymph vessels ([Figure 30: e](#)) from the middle part of the mammary chain, corresponding approximately to the 3rd teat, travel deeply between the xiphoid cartilage and the last true costal cartilage, accompanied by the cranial epigastric artery and vein, before running under the diaphragmatic attachment into the thoracic cavity and then to the sternal lymph node. Furthermore, several lymph vessels ([Figure 30: e', e''](#)) from the cranial part of the mammary chain, corresponding to the 1st and 2nd teats, enter the thoracic cavity through the *M. pectoralis profundus* and then through the intercartilaginous spaces (usually 1 lymph vessel passing through each of the 4th, 5th, and 6th intercartilaginous spaces), joining the aforementioned lymph vessels and draining with them to the sternal lymph node.

It should be emphasized that I have injected such lymph vessels not only from the mammary parenchyma, but also from the 1st, 2nd, and 3rd teats, although the injection was certainly not successful every time.

The lymph vessels of the mammary parenchyma have not been observed crossing the median plane to the contralateral side, although this region has frequently been injected and examined. However, lymph vessels of the skin of the mammary glands adjacent to the median line may cross to the other side.

2.13 LYMPH VESSELS OF THE PERICARDIUM, HEART, AND AORTA

LYMPH VESSELS OF THE PERICARDIUM, HEART, AND AORTA

A. LYMPH VESSELS OF THE PERICARDIUM AND MEDIASTINUM

The lymph vessels of the pericardium cannot be separated from those of the cardiac part of the mediastinum. Therefore, the description of the lymph vessels of the cardiac part of the mediastinum also applies to the lymph vessels of the pericardium (see lymph vessels of the mediastinum).

B. LYMPH VESSELS OF THE HEART

Most of the lymph vessels of the heart drain to all 3 lymph nodes in the tracheobronchial group, while the rest drain to the cranial mediastinal lymph nodes.

i. Lateral Wall of the Left Ventricle

The lymph vessels of the lateral wall of the left ventricle ([Figures 18: a; 21: b](#)) drain to the left tracheobronchial lymph node (Figure 21: *l*), the middle tracheobronchial lymph node (Figures 18: *l*; 21: *k*), and the cranial mediastinal lymph nodes (Figures 18: *3*; 21: *m*). Some of the lymph vessels run from the puncture sites to the left longitudinal groove, while others run to the right longitudinal groove, and the rest run upwards to the coronary groove. In general, the lymph vessels of the left part of the left ventricular wall (Figure 21) run towards the left longitudinal groove (Figure 21: *o*), the lymph vessels of the caudal part of the left ventricular wall (Figure 21) rise towards the coronary groove (Figure 21: *n, n'*), and the lymph vessels of the right part of the left ventricular wall (Figure 18) run towards the right longitudinal groove (Figure 18: *e*). However, these individual areas are by no means sharply demarcated from each other; these lymph vessels fill towards both sides from most sites of injection (e.g. towards the left longitudinal groove and the coronary groove, or towards the right longitudinal groove and the coronary groove). From some sites of injection near the cardiac apex, the lymph vessels even filled in all 3 directions upon injection. Lymph vessels also pass from the right side of the cardiac apex to the left side, and from the left side to the right side, as shown in Figure 21.

The lymph vessels running to the right longitudinal groove merge within it to form 2 to 3 small vessels, some of which rise above the left atrium to drain to the middle tracheobronchial lymph node (Figure 18: *l*), while others join those in the coronary groove and curve with them to the left (see below and Figure 18). In rare cases, all the lymph vessels of the right longitudinal groove curve to the coronary groove. The lymph vessels entering the coronary groove also merge, forming 1 to 3 vessels, which then run in the left part of the coronary groove ([Figure 21: n'](#)), more or less hidden by

the left atrial appendage (auricle), to the pulmonary artery where they either join or merge with the 2 to 3 vessels ascending in the left longitudinal groove (Figure 21: *o*). The resulting lymph vessels pass between the left atrial appendage and the pulmonary artery, running over the right side of the pulmonary artery to drain to either the left tracheobronchial lymph node (Figure 21: *l*) or one of the cranial mediastinal lymph nodes (Figure 21: *m*), or to both groups of lymph nodes. The lymph vessels usually drain to the cranial mediastinal lymph node that lies on the cranial vena cava.

ii. Lateral Wall of the Right Ventricle

The lymph vessels of the lateral wall of the right ventricle (Figures 18: *b*; 21: *a*) behave similarly to the lymph vessels of the left ventricular wall, draining to the left and middle tracheobronchial lymph nodes and to the cranial mediastinal lymph nodes. From the left part of the right ventricular wall, the lymph vessels usually run towards the left longitudinal groove (Figure 21: *o*), and, from the cranial part of the right ventricular wall, they run directly upwards to the coronary groove (Figures 18: *d'*; 21: *n*). From the right part of the right ventricular wall, they run towards the right longitudinal groove (Figure 18: *e*), either joining the corresponding lymph vessels from the right part of the left ventricular wall and running with them via the left atrium upwards to drain to the middle tracheobronchial lymph node (Figure 18: *l*), or turning caudally in the coronary groove and joining the lymph vessels of the left ventricular wall.

The lymph vessels entering the coronary sulcus run in the left part of the sulcus to the caudal border of the pulmonary artery (see Figure 21), merging here with the lymph vessels ascending in the longitudinal sinus (Figure 21: *o*) (see above) and with the lymph vessels coming from the left ventricular wall (see above), before travelling deeply between the pulmonary artery and the left atrial appendage, as described above, and draining to the left tracheobronchial lymph node (Figure 21: *l*) and the cranial mediastinal lymph nodes (Figure 21: *m*).

The following deviations from this behaviour have been observed:

1. The lymph vessels that meet in the coronary groove do not merge with the ascending lymph vessels in the left longitudinal groove, rather forming a small trunk that extends over the left side of the pulmonary artery and aorta to drain to one of the cranial mediastinal lymph nodes (this type of lymph vessel is also drawn in Figure 18).
2. The lymph vessels usually running from the right part of the right ventricular wall to drain to the middle tracheobronchial lymph node do not drain to this lymph node, but instead join the lymph vessels running in the coronary groove, as described for the lymph vessels of the left ventricular wall. In this case, all the lymph vessels of the two ventricular walls eventually merge to form 2 to 3 larger vessels, which run deeply between the pulmonary artery and the left atrial appendage.

The individual drainage areas of the right ventricular wall are not sharply demarcated as described for the left ventricular wall.

iii. Lymph Vessels of the Left Atrium

Some of the lymph vessels of the left atrium (Figure 21: *d*), specifically those from the atrial appendage and the part of the atrium adjacent to it, run over both surfaces of the atrium towards the coronary groove where they join with the lymph vessels of the left ventricular wall running in the coronary groove, draining with them to the left tracheobronchial lymph node (Figure 21: *l*) and usually into a cranial mediastinal lymph node (Figure 21: *m*) as well; other lymph vessels of this area of the left atrium run over the dorsal surface of the left atrium and drain into the same lymph nodes (see Figure 21). The lymph vessels from the posterior (caudal) and from the right (adjacent to the right atrium) parts of the left atrium drain to the middle tracheobronchial lymph node (Figure 21: *k*). Most pass directly upwards over the left atrium to drain to the lymph node (as shown in Figure 21), while some merge with the lymph vessels of the left ventricular wall, which rise upwards from the right longitudinal groove over the left atrium to drain to the middle tracheobronchial lymph node (Figure 18). If the lymph vessels of the left ventricular wall do not take this path, and instead join the lymph vessels which run to the left side in the coronary groove as described previously, then the lymph vessels of the left atrium that join them also take the same path.

iv. Lymph Vessels of the Right Atrium

Some of the lymph vessels of the right atrium (Figure 18: *c*) drain to both the middle (Figure 18: *l*) and right (Figure 18: *2*) tracheobronchial lymph nodes, while others drain to the cranial mediastinal lymph nodes (Figure 18: *3*). The lymph vessels of the part of the right atrium adjacent to the left atrium join with the lymph vessels from the right part of the left atrium, running upwards with them to drain to the middle tracheobronchial lymph node (Figure 18: *l*). Rarely, these lymph vessels may also run caudally in the coronary groove and merge with the lymph vessels of the left ventricular wall (see above). From the remaining part of the right wall of the right atrium, some of the lymph vessels ascend to drain to the right tracheobronchial lymph node (Figure 18: *2*), some merge to form a lymph vessel that runs cranially along the cranial vena cava to drain to one of the cranial mediastinal lymph nodes (Figure 18: *3*), and some run to the coronary groove (Figure 18: *d'*) where they join with the lymph vessels of the right ventricular wall (see above). The lymph vessels of the left wall of the right atrium drain to the middle tracheobronchial lymph node as well as into the right tracheobronchial lymph node, occasionally. The lymph vessels of the left atrial appendage (Figure 21: *c*) and the part of the right atrium adjacent to it run over both surfaces of the right atrium to the coronary groove, where they merge with the lymph vessels of the right ventricle and drain with them to the left tracheobronchial lymph node (Figure 21: *l*) and possibly to one of the cranial mediastinal lymph nodes (see above and Figure 21: *m*).

v. Lymph Vessels of the Ventricular Septum

The lymph vessels of the ventricular septum emerge in both longitudinal grooves and join the lymph vessels of the ventricular wall.

vi. Lymph Vessels of the Papillary Muscles

The lymph vessels of the 2 papillary muscles of the left ventricle behave as follows: the lymph vessels of the papillary muscle adjacent to the left longitudinal groove pass from the base of this papillary muscle through the left part of the ventricular wall, joining with the lymph vessels ascending in the left longitudinal groove ([Figure 21: o](#)), and those of the papillary muscle adjacent to the right longitudinal groove join with the lymph vessels in the right longitudinal groove ([Figure 18: e](#)) in the same manner. The 2 to 3 papillary muscles of the right ventricle behave as follows: the lymph vessels of the posterior right papillary muscle near the right longitudinal groove pass through the ventral part of the lateral wall of the right ventricle, then enter the right longitudinal groove ([Figure 18: e](#)), joining with the other lymph vessels of the groove. The lymph vessels of the left anterior or 2 left anterior papillary muscles pass through the ventral part of the lateral wall of the right ventricle near the left longitudinal groove, joining with the lymph vessels rising in the left longitudinal groove ([Figure 21: o](#)). The lymph vessels emerge from the base of the papillary muscles and run to the lateral wall, at least some running on the transverse muscles.

The lymph vessels of each papillary muscle merge to form 2 to 4 larger lymph vessels. An extremely rich, fine network of lymph vessels fills with dye under the endocardium of the papillary muscles.

vii. Lymph Vessels of the Endocardium and Epicardium

The lymph vessels of the endocardium and the epicardium behave exactly as they do in the cow (pages 148 and 149 of *The Lymphatic System of Cattle* [6]): the endocardial lymph vessels form abundant networks under the endocardium, which may be multilayered at thick endocardial sites, such as at the tip of the papillary muscles. The lymph vessels that emerge from the endocardium will enter the myocardium and gradually penetrate obliquely, joining with the lymph vessels of the myocardium. The lymphatics of the epicardium cannot be clearly demarcated from the subepicardial lymphatics of the myocardium.

C. LYMPH VESSELS OF THE AORTA

The lymph vessels of the aorta can be injected in dogs with a high degree of certainty. The lymph vessels from the aortic arch and the adjacent part of the thoracic aorta were injected ([Figure 17: 3](#)) and were observed to be very small lymph vessels that drained into a cranial mediastinal lymph node (specifically, into the lymph node located on the left side of the cranial vena cava near the aortic arch) (Figure 17: *a*¹).

From the middle part (Figure 17: 3¹) of the thoracic aorta, some of the lymph vessels drain to the cranial mediastinal lymph nodes (Figure 17: *a*¹), and some drain to the middle tracheobronchial lymph node (Figure 17: *b*¹). If an intercostal lymph node is present, some of the lymph vessels draining to the cranial mediastinal lymph nodes will also drain to it.

The lymph vessels of the caudal part of the thoracic aorta (Figure 17: 3²) merge to form 1, 2, or 3 larger vessels and drain to the 2 cranial lumbar aortic lymph nodes, while the lymph vessels of the abdominal aorta drain to both the lumbar aortic and medial iliac lymph nodes.

2.14 LYMPH VESSELS OF THE EYE

LYMPH VESSELS OF THE EYE

Of the lymph vessels of the eye, it was possible to inject those of the eyelids, lacrimal caruncle, lacrimal gland, and zygomatic gland. The lymph vessels of the zygomatic gland will not be described here, as this gland can be considered a dorsal cheek gland that has moved into the orbit, and its drainage will be described instead in the section on the lymph vessels of the digestive organs (see lymph vessels of the cheek). The lymph vessels from the parts of the eye listed above drain to the parotid and mandibular lymph nodes.

A. LYMPH VESSELS OF THE EYELIDS

The lymph vessels of the eyelids ([Figure 13: *u, v*](#)), as well as all of its layers (including the conjunctiva and the lacrimal caruncle), drain either to the parotid lymph node ([Figure 13: *l*](#)) or to the mandibular lymph nodes ([Figure 13: *2, 2'*](#)). The lymph vessels were injected from the upper, lower, and third eyelids, as well as from the lacrimal caruncle, and were observed to run from each of the aforementioned structures to both groups of lymph nodes, joining with the corresponding lymph vessels of the skin.

B. LYMPH VESSELS OF THE LACRIMAL GLAND

The lymph vessels of the lacrimal gland also drain to the parotid and mandibular lymph nodes. The lymph vessels that drain to the parotid lymph node join with the corresponding lymph vessels of the upper eyelid, while the lymph vessels that drain to the mandibular lymph nodes emerge near the lacrimal caruncle and join with the lymph vessels of the caruncle and the lower eyelid, which then descend at the anterior border of the masseter to drain to the mandibular lymph nodes.

C. LYMPH VESSELS OF THE EYE MUSCLES

Despite multiple attempts, I did not succeed in injecting the lymph vessels of the eye muscles and the globe.

2.15 LYMPH VESSELS OF THE EAR

LYMPH VESSELS OF THE EAR

Only the lymph vessels of the external ear were examined. These were found to drain to the parotid, retropharyngeal, and superficial cervical lymph nodes.

A. LYMPH VESSELS OF THE EAR MUSCLES

The lymph vessels of the ear muscles drain either to the parotid lymph node or to the retropharyngeal lymph nodes. The lymph vessels of the *M. scutularis* and the pinna adductors merge into 2 to 3 larger vessels and drain to the parotid lymph node. Additionally, 2 lymph vessels were always observed to emerge from the pinna abductors and to drain to the medial retropharyngeal lymph node, and, if a lateral retropharyngeal lymph node was present, also to it. The lymph vessels of the *M. depressor auris* usually merge to form 2 trunks, which then drain to the lateral and medial retropharyngeal lymph nodes. For the lymph vessels of the *M. stylohyoideus*, see lymph vessels of the individual muscles of the tongue and hyoid bone.

B. LYMPH VESSELS OF THE PINNA

Most of the lymph vessels of the pinna (Figures 13, 14) drain to the superficial cervical lymph nodes (Figure 13: 3), while a smaller number drain to the lateral retropharyngeal (Figure 14: s") and medial retropharyngeal lymph nodes (Figure 13: 12), as well as to the parotid lymph node (Figure 13: 1). The lymph vessels of the conchal cartilage and those of the skin on the inner and outer sides of the conchal cartilage join with each other so that they can be described collectively. More specifically, the lymphvessels of the skin on the inner side of the conchal cartilage form coarse subcutaneous networks; thelymph vessels emerging from these networks pass through the conchal cartilage, merging with the lymph vessels of the conchal cartilage, and then joining the lymph vessels of the skin on the outer side of the pinna. The latter lymph vessels form coarse subcutaneous networks, which are distributed over the entire dorsum of the pinna, then merge with those of the skin of the parietal region, from which alarger number of lymph vessels emerge. Most of these lymph vessels join with the lymph vessels of the skin of the back of the neck (nuchal region) (see lymph vessels of the skin of the neck) and drain with them to the superficial cervical lymph nodes (Figure 13: 3). Three to 5 lymph vessels from the part of the pinna adjacent to the lateral rim of the pinna run down either the caudal side of the cartilaginous auditory canal or just caudal to it to drain to the lateral and medial retropharyngeal lymph nodes (Figures 13: 12; 14: s", u). Finally, 2 to 3 lymph vessels originating from the part of the pinna adjacentto its medial edge descend directly in front of the pinna to drain to the parotid lymph node (Figure13: 1), crossing both the inner and outer surfaces of the pinna adductors.

2.16 LYMPH VESSELS OF THE NERVOUS SYSTEM

LYMPH VESSELS OF THE NERVOUS SYSTEM

The lymph vessels and lymph pathways of the nervous system (the ventricular system of the brain and spinal cord, their sheaths, and the cerebrospinal nerves) behave in the dog exactly as I described for the cow in *The Lymph Vessels of the Nervous System of Cattle* [5]. I have briefly summarized my results in this area in the cow, and have provided an excerpt below:

“I found that with careful injection of fluid (dye) into the subarachnoid space:

1. the subdural space does not fill;
2. the injected fluid passes from the subarachnoid space into the venous system;
3. the lymph vessels of the nasal cavity fill from the subarachnoid space;
4. the injected fluid continues from the subarachnoid space into the (subarachnoid) lymphatic clefts of all the cerebrospinal nerves, although the (subarachnoid) lymphatic clefts of all cerebrospinal nerves did not always fill in individual cases.

I was repeatedly able to trace the dye into the terminal branches of both the cerebral and spinal nerves after injections. For example, I was able to trace the hypoglossal nerve into the tongue, the infraorbital nerve into the upper lip, the cervical and intercostal nerves down to their cutaneous branches, the intercostal nerves along the entire ribs down to the sternum, and the sciatic nerve down to the stifle region. It is interesting to note that even the lymphatic clefts of the branches connecting the spinal nerves to the sympathetic nerve filled with dye, and the dye also continued into the sympathetic ganglia. Furthermore, I was also able to fill lymph vessels from the subarachnoid space, which, to my knowledge, has not been previously demonstrated. These lymph vessels, accompanied by the cerebrospinal nerves, leave the cranial cavity and the spinal canal and enter the corresponding lymph nodes (*Ln./Lnn. retropharyngei, pterygoidea, mandibularis, cervicales profundae, cervicales superficiales, axillares primae costae, intercostales, mediastinales craniales and dorsales, lumbales aorticae and hypogastricae*). However, the lymph vessels do not fill with dye directly from the subarachnoid space, but either from the lymphatic clefts of the cerebrospinal nerves, shortly after the nerves exit from the brain and spinal cord, or from the intervertebral foramen.”

In general, my observations in the dog were in complete agreement with these findings from the nervous system of the cow, with obvious differences resulting from the different behaviours of the lymph nodes. The lymph vessels of the cranial cavity in the dog drained only into the medial retropharyngeal lymph node, those of the cervical spinal canal drained to the mediastinal lymph nodes, those of the subarachnoid space of the thoracic spine drained to the mediastinal, intercostal, and cranial lumbar aortic lymph nodes, and those of the lumbar and sacral canal drained to the lumbar aortic, medial iliac,

and hypogastric lymph nodes. As in the cow, I found that the subdural space is separated from the ventricular system, from the subarachnoid space, and from the cerebrospinal fluid pathways of the brain, and only connects with them peripherally; the injected dye passes from the subdural space into the venous system in the same way that it does from the subarachnoid space (for more details, see my article mentioned above [5]). In the dog, again as in the cow, I observed that the dye injected into the subdural space fills the (subdural) lymphatic clefts of all cerebrospinal nerves and that lymph vessels fill from these lymphatic clefts.

This is the same behaviour as described in detail above for the lymph vessels arising from the nerves after dye injection into the subarachnoid space. This behaviour is explained by the fact that the subdural and subarachnoid lymphatic clefts in the nerves are not separated, and instead communicate with each other, forming one lymphatic cleft system. Due to this, the lymphatic cleft system of a nerve has efferent lymph vessels.

The technique I used to inject the lymphatic spaces and lymph vessels of the nervous system in dogs was the same as that given in detail for cattle in the above referenced article [5]. It should be emphasized that, with the small size of the dog, it is hardly possible to insert the cannula into the subdural space of the spinal cord and tie it in place without destroying the arachnoid. As a result, the injection fluid will probably always penetrate not only into the subdural space, but also into the subarachnoid space. If you wish to inject each of the two spaces separately, the only way to achieve this is to carefully insert the cannula into the subdural space when the front half of a dog is hung upside down, or the rear half of a dog is hung upside down (with the tail downwards), and to not tie in the cannula, but instead loosely attach it to the surrounding tissues, attach a glass funnel, and pour the injection liquid into the funnel. Because much lighter pressure is applied, the injection takes much longer. I also found that the injection fluid in the dog transferred into the venous system from both the subdural and the subarachnoid space much more easily and in relatively larger quantities than is the case with the cow – when such injections are done, large parts of the venous system easily fill, up to the finest capillaries.

FIGURES

FIGURE 1: LYMPH VESSELS OF THE KIDNEY

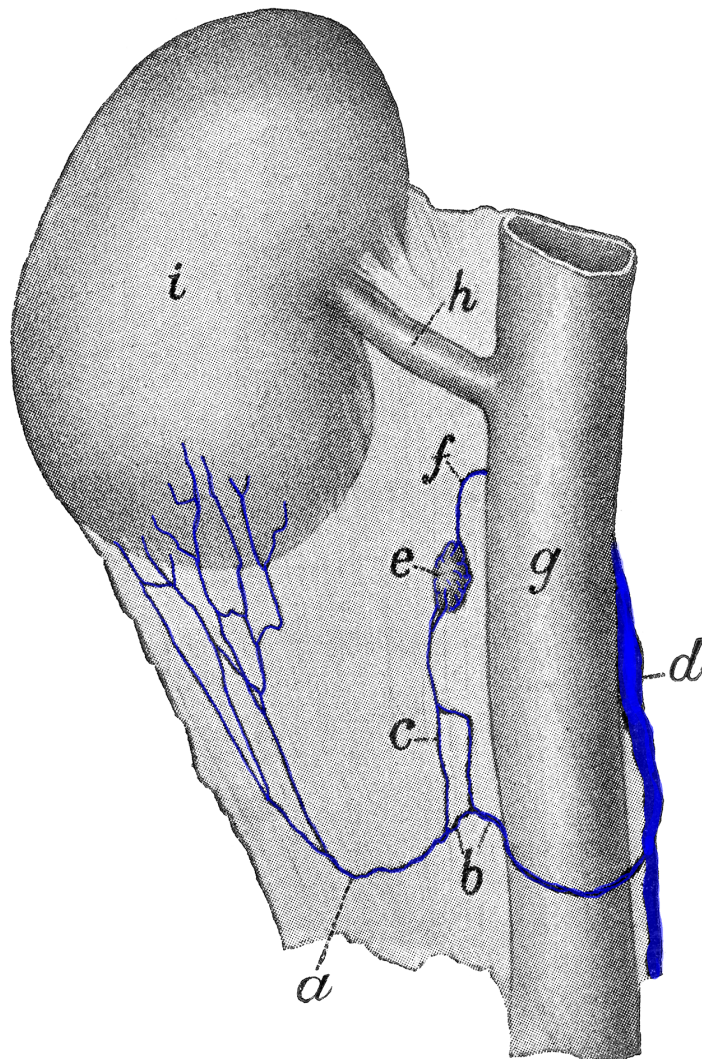
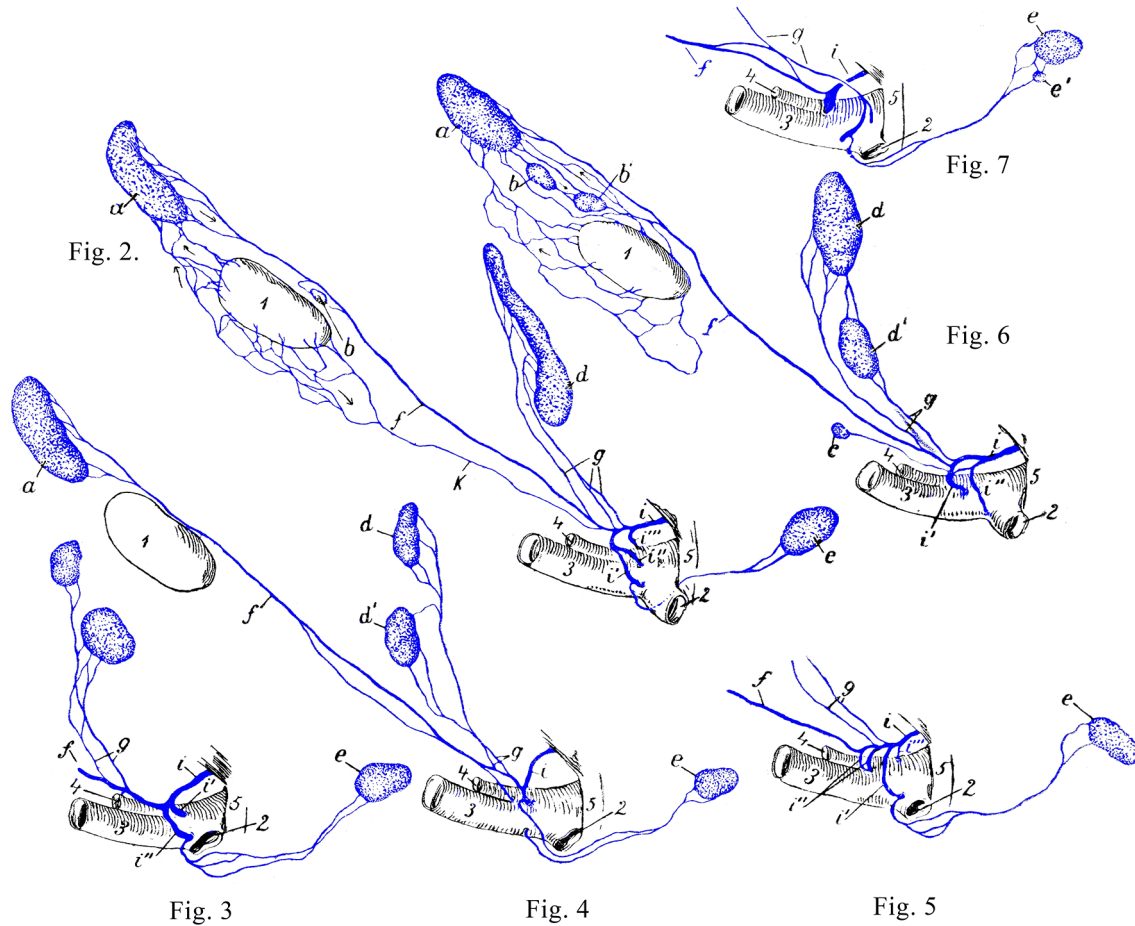


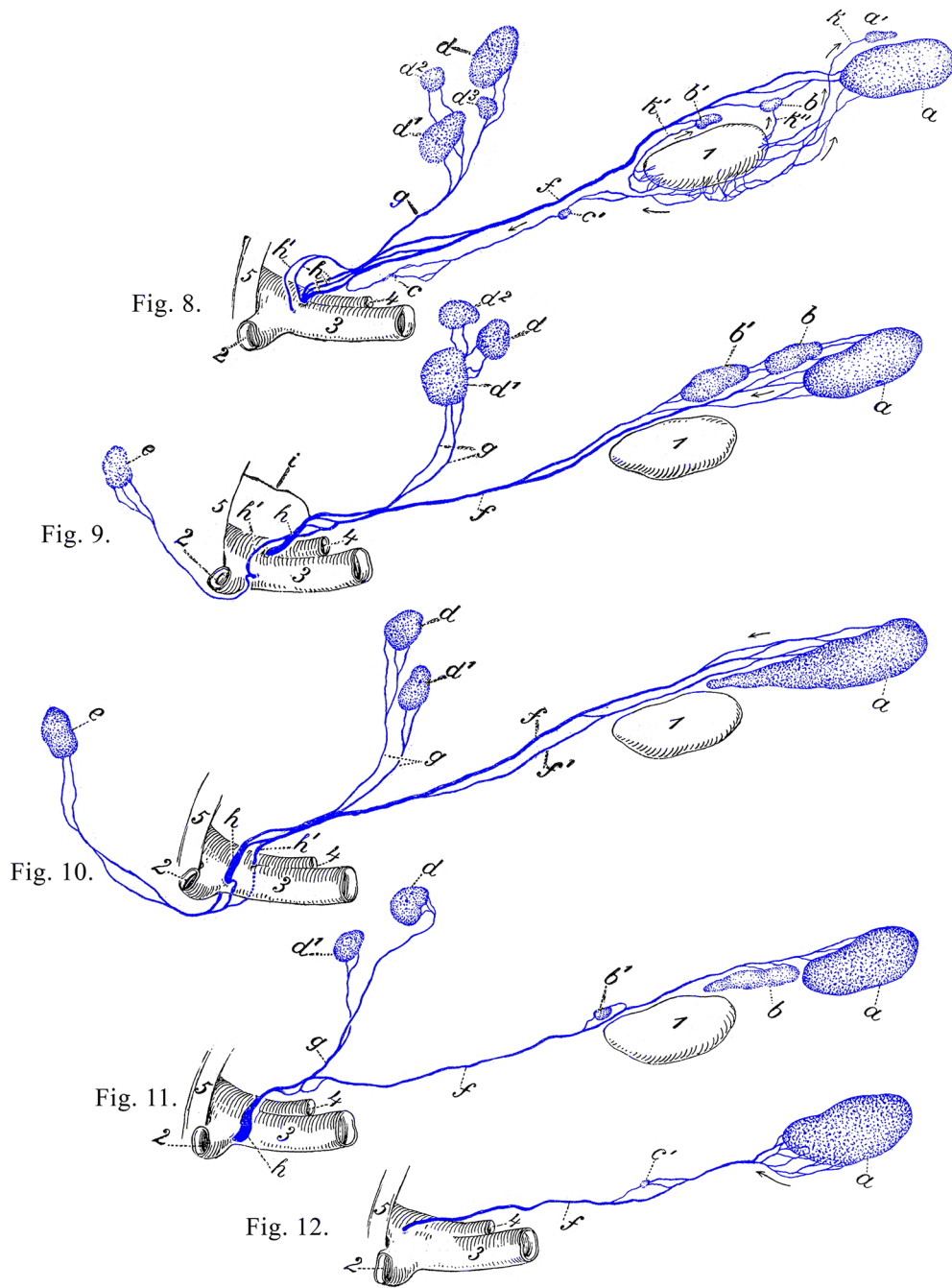
Figure 1. Illustration of a lymph vessel (*a*) of the right kidney (*i*) that at (*b*) opens directly into the *cisterna chyli* (*d*), after a branch (*c*) flows to a lumbar aortic lymph node (*e*). The efferent vessel (*f*) from the lymph node leads directly to the caudal vena cava (*g*). The renal vein is shown (*h*). Source: Dr. Hermann Baum (1918). (This work is in the public domain).

FIGURES 2-7: SCHEMATA OF THE LEFT TRACHEAL DUCT



Figures 2-7: *a* medial retropharyngeal lymph node; *b, b'* cranial cervical lymphnodes; *c* caudal cervical lymph node; *d, d'* superficial cervical lymph nodes; *e, e'* axillary lymph nodes; *f* left tracheal duct; *g* efferent vessels or efferent vessel from the superficial cervical lymph node; *i, i', i'', i'''* thoracic duct with its end branches; *k* lymph vessel from the thyroid *l*, that opens into the left tracheal duct *f*. *l* thyroid gland; *2* axillary vein; *3* external jugular vein; *4* internal jugular vein; *5* 1st rib. Source: Dr. Hermann Baum (1918). (This work is in the publicdomain).

FIGURES 8-12: SCHEMATA OF THE RIGHT TRACHEAL DUCT AND RIGHT LYMPHATIC DUCT



Figures 8-12: *a, a'* medial retropharyngeal lymph nodes; *b, b'* cranial cervical lymph nodes; *c* caudal cervical lymph node; *c'* middle cervical lymph node; *d, d¹, d², d³* superficial cervical lymph nodes; *e* axillary lymph node; *f, f'* right tracheal duct; *g* efferent vessels or efferent vessel from the superficial cervical lymph node; *h, h'* the end of the right tracheal duct or the right lymphatic duct, *i* efferent vessel of a cranial mediastinal lymph node; *k, k', k''* lymph vessels from the thyroid gland; *l* thyroid gland; *2* axillary vein; *3* external jugular vein; *4* internal jugular vein; *5* 1st rib. Source: Dr. Hermann Baum (1918). (This work is in the public domain).

FIGURE 13: LYMPH VESSELS OF THE SKIN OF DOGS

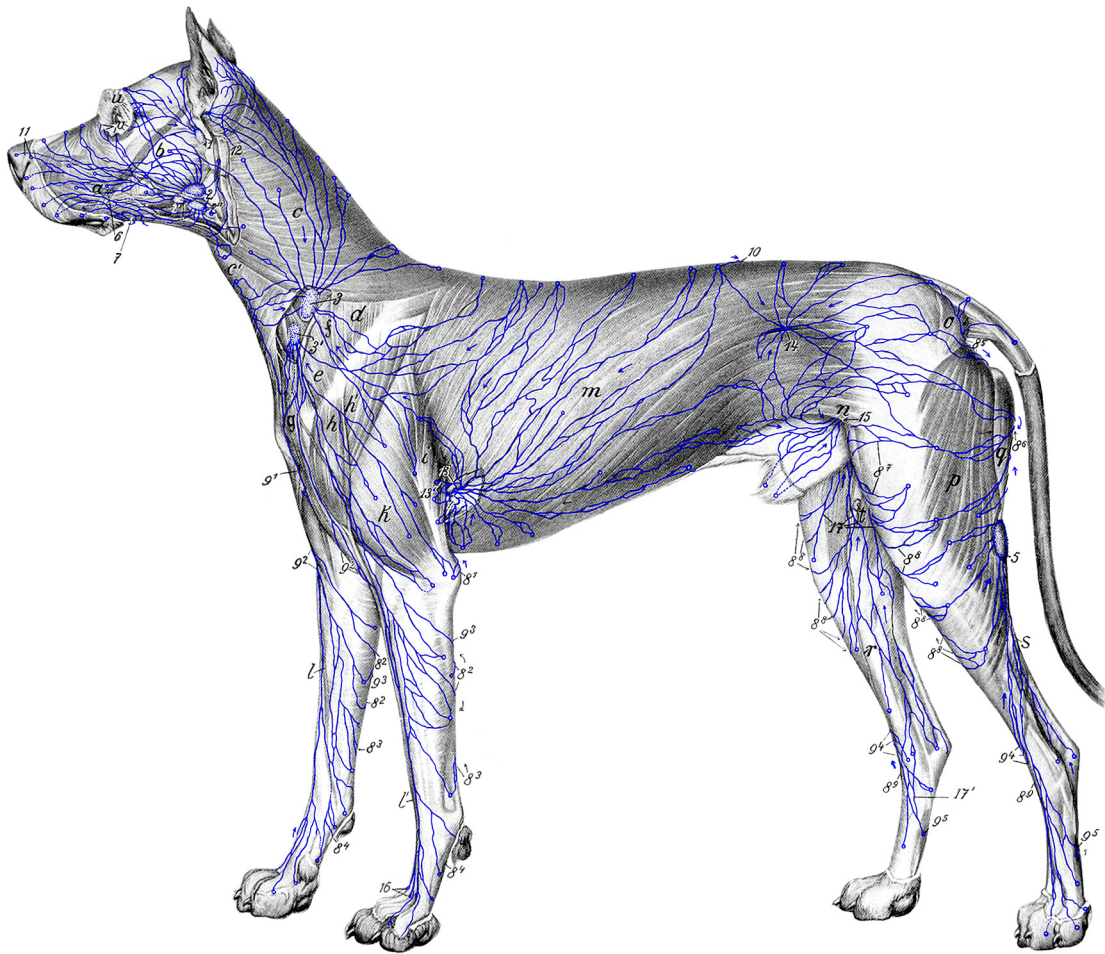


Figure 13: 1 parotid lymph node; 2, 2', 2'' mandibular lymph nodes; 3, 3' superficial cervical lymph nodes; 4 accessory axillary lymph node; 5 popliteal lymph node; 6 lymph vessels from the buccal gingiva of the maxillary teeth; 7 lymph vessels from the buccal gingiva of the mandibular teeth; 8¹-8⁹ lymph vessels that go to the medial side of the leg (8⁵-8⁸ are lymph vessels that run to the superficial inguinal lymph nodes; 8² and 8², 8³ and 8³, 8⁴ and 8⁴ are the same lymph vessels); 9¹ lymph vessels from the skin of the ventral chest; 9²-9⁵ lymph vessels that go to the lateral side of the leg; 9² and 9², 9³ and 9³, 9⁴ and 9⁴, 9⁵ and 9⁵ are the same lymph vessels; 10 lymph vessel that crosses the median plane; 11 lymph vessels of the external nose; 12 lymph vessel that runs deep to the medial retropharyngeal lymph node; 13, 13' lymph vessels running to the axillary lymph node; 14 lymph vessels running to the medial iliac lymph node; 15 lymph vessels opening into the superficial inguinal lymph nodes; 16 lymph vessels passing from the palmar to the dorsal side; 17, 17' lymph vessels running to the superficial inguinal lymph nodes. *a* muscles of the cheek; *b* *M. masseter*; *c, c'* cervical skin muscle; *d* *M. trapezius*; *e* *M. omotransversarius*; *f* *M. supraspinatus*; *g* *M. brachiocephalicus*; *h, h'* *M. deltoideus*; *i* *Caput logum* and *k* *Caput laterale* of the *M. triceps brachii*; *l* antebrachial cephalic vein; *l'* accessory cephalic vein; *m* abdominal skin muscle; *n* stifle fold; *o* *M. gluteus superficialis*; *p* *M. biceps femoris*; *q* *M. semitendinosus*; *r* great saphenous vein; *s* small saphenous vein; *t* medial femoral lymph node; *u* upper and *v* lower eyelid. Source: Dr. Hermann Baum (1918). (This work is in the public domain)

FIGURE 14: LYMPH VESSELS OF THE TONGUE, TONGUE MUSCLES, SOFT PALATE, AND LARYNX OF THE DOG

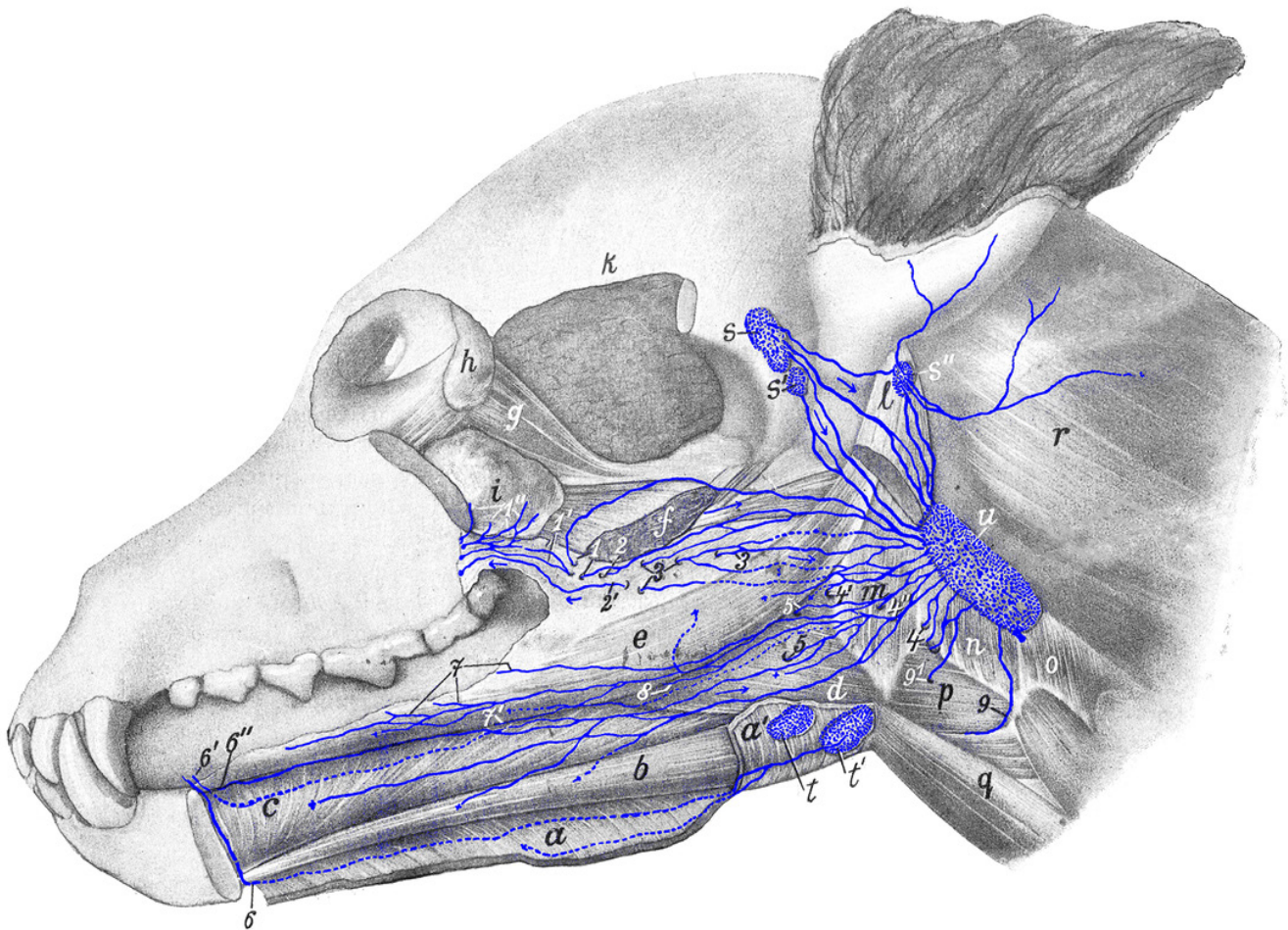


Figure 14: *a, a'* *M. mylohyoideus* (largely retracted); *b* *M. geniohyoideus*; *c* *M. genioglossus*; *d* *M. hyoglossus*; *e* *M. styloglossus*; *f* *M. pterygoideus*; *g* eye muscles; *h* lacrimal gland; *i* zygomatic gland; *k* temporal muscles; *l* aboral end of the *M. digastricus*; *m* *M. keratopharyngeus*; *n* *M. thyropharyngeus*; *o* *M. cricopharyngeus*; *p* *M. hyothyroideus*; *q* *M. sternohyoideus*; *r* *M. splenius*; *s, s'* parotid lymph nodes; *s''* lateral retropharyngeal lymph node; *t, t'* mandibular lymph nodes; *u* medial retropharyngeal lymph node. *1, 1'* lymph vessels from hard palate and soft palate; *1''* lymph vessels of the zygomatic gland, joining *1'* labeled lymph vessels; *2, 2'* lymph vessels from the soft palate or *2'* lymph vessel from the fold surrounding the tonsillar sinus; *3, 3* lymph vessels from the tonsil; *4, 4', 4''* lymph vessels from the soft palate, the tonsil, the base of the tongue and from the mucous membrane of the cavity of the pharynx, which initially run between the mucous membrane and the musculature; *5, 5* lymph vessels from the tongue, which perforate the *M. hyoglossus*; *6, 6', 6''* lymph vessels of the tip of the tongue; *7, 7'* and *8* lymph vessels of the body of the tongue; *9, 9'* lymph vessels from the larynx. Source: Dr. Hermann Baum (1918). (This work is in the public domain).

FIGURE 15: LYMPH VESSELS OF THE SALIVARY GLANDS OF THE DOG

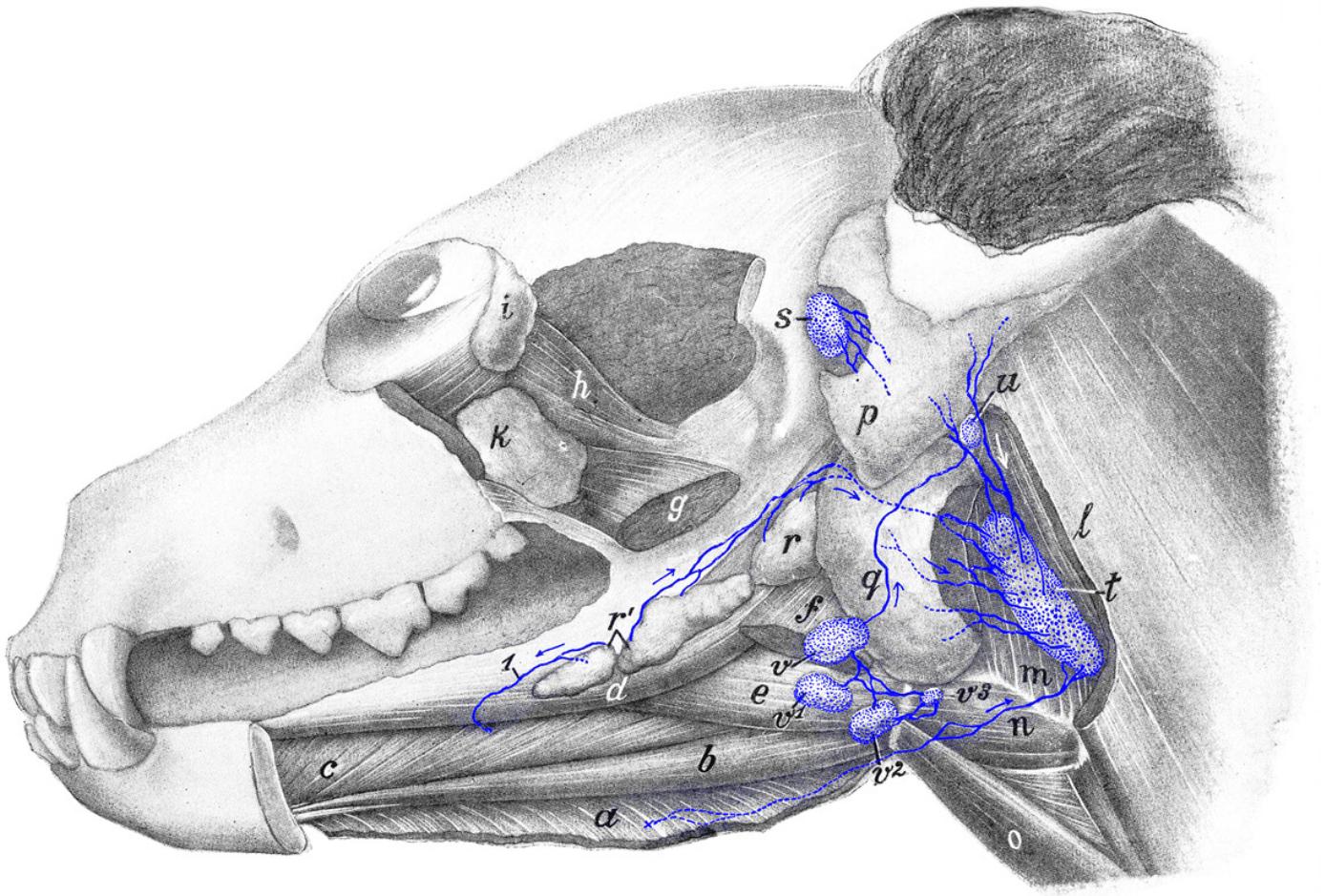


Figure 15: *a* *M. mylohyoideus* (retracted); *b* *M. geniohyoideus*; *c* *M. genioglossus*; *d* *M. styloglossus*; *e* *M. hyoglossus*; *f* aboral part of *M. digastricus* (cut off); *g* *M. pterygoideus*; *h* eye muscles; *i* lacrimal gland; *k* zygomatic gland; *l* *M. sternomastoideus* and *cleidomastoideus* (a piece cut out of both to allow the medial retropharyngeal lymph node [*t*] to be exposed); *m* pharyngeal muscles; *n* *M. hyothyroideus*; *o* *M. sternohyoideus*; *p* parotid gland and *q* submaxillary (mandibular) gland (a piece cut out of both glands); *r* caudal part of sublingual gland (*glandula sublingualis grandicanalaris*) and *r'* rostral part of sublingual gland (*glandula sublingualis parvicanalaris*); *s* parotid lymph node; *t* medial retropharyngeal lymph node; *u* lateral retropharyngeal lymph node; *v*, *v*¹, *v*², *v*³ mandibular lymph nodes. *l* lymph vessel of the sublingual gland (*glandula sublingualis parvicanalaris*) running to a mandibular lymph node (cut off). Source: Dr. Hermann Baum (1918). (This work is in the public domain).

FIGURE 16: MEDIAL RETROPHARYNGEAL LYMPH NODES AND CERVICAL LYMPH NODES OF THE DOG

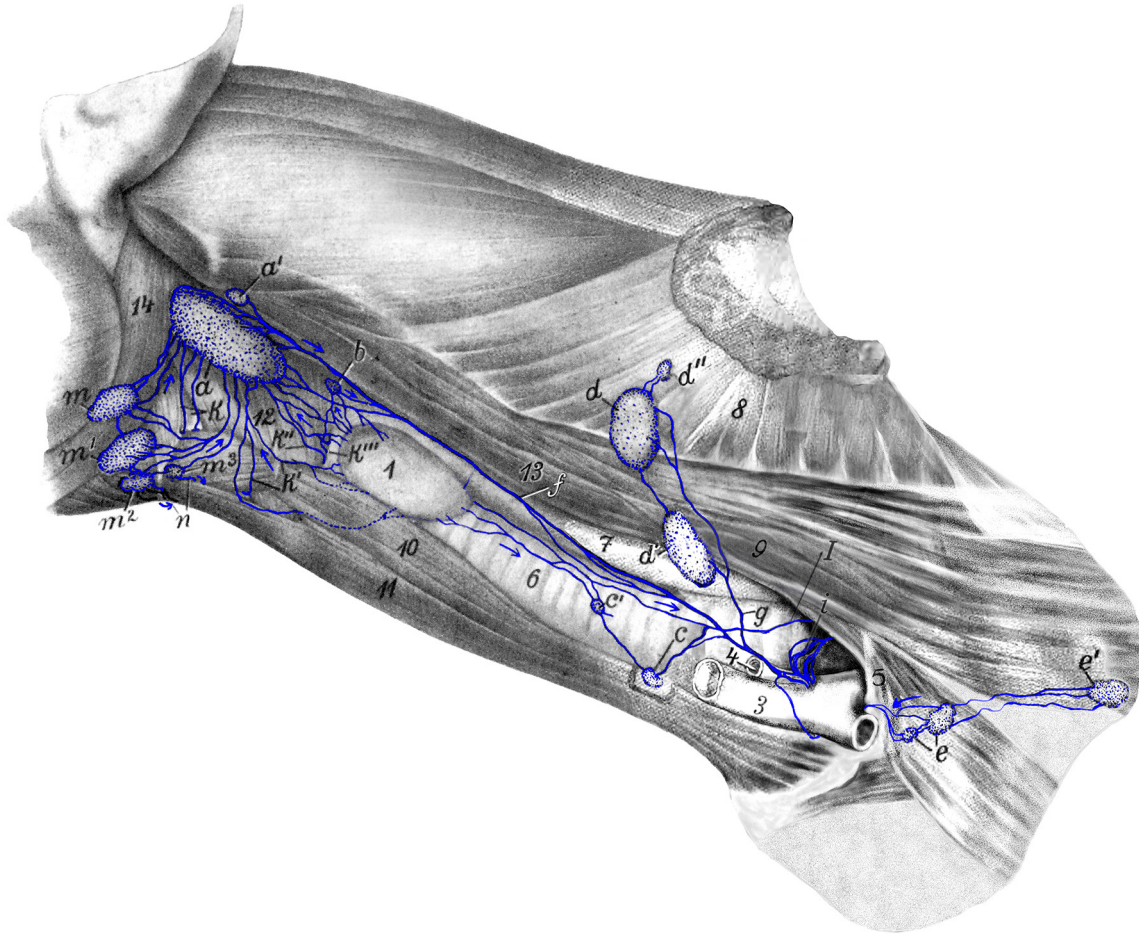


Figure 16: *a, a'* medial retropharyngeal lymph nodes; *b* cranial cervical lymph node; *c, c'* caudal cervical lymph nodes; *d, d', d''* superficial cervical lymph nodes; *e* axillary lymph node; *e'* accessory axillary lymph node; *f* left tracheal duct; *g* efferent vessel of superficial cervical lymph nodes; *i* thoracic duct with its terminal branches; *k, k', k'', k'''* lymph vessels from the larynx; *l* lymph vessel opening into a cranial mediastinal lymph node; *m, m', m'', m'''* mandibular lymph nodes; *n* efferent vessels of mandibular lymph nodes draining to medial retropharyngeal lymph node(s) of the other side. *I* thyroid gland; *2* axillary vein; *3* external jugular vein; *4* internal jugular vein; *5* 1st rib; *6* trachea; *7* esophagus; *8* *M. serratus ventralis*; *9* *M. scalenus*; *10* *M. sternothyroideus*; *11* *M. sternohyoideus*; *12* pharyngeal muscles; *13* *M. longus capitis*; *14* *M. digastricus*. Source: Dr. Hermann Baum (1918). (This work is in the public domain).

**FIGURE 17: LYMPH VESSELS OF THE MEDIASTINUM, PERICARDIUM, DIA-
PHRAGM, AORTA, AND ESOPHAGUS IN THE DOG**

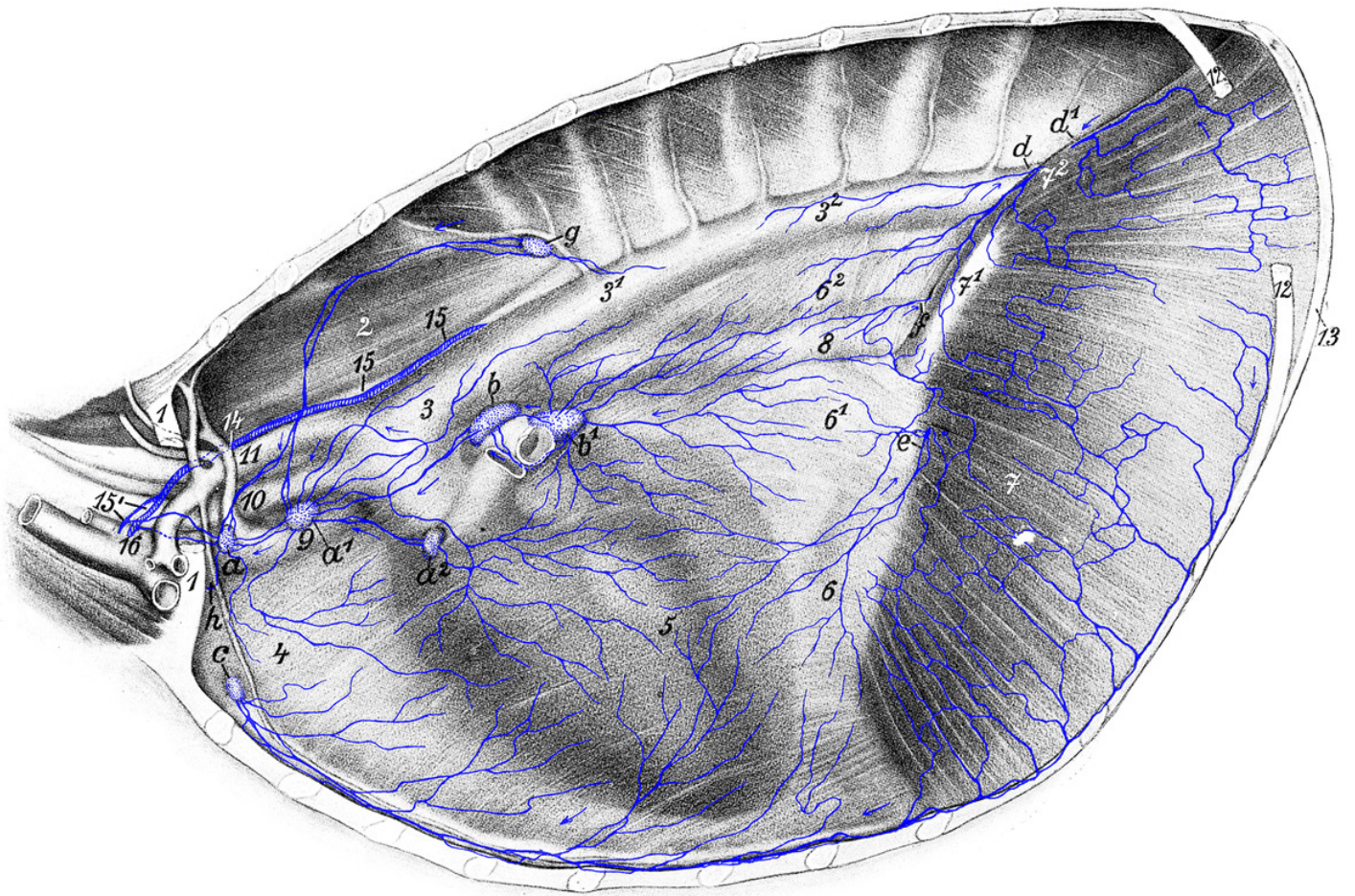


Figure 17: The entire left lung and almost the entire left thoracic wall with the *M. transversus thoracis* removed. 1, 1st rib from which a piece is excised; 2 *M. longus colli*; 3, 3¹, 3² aorta; 4 precardiac mediastinum; 5 pericardium and cardiac mediastinum; 6, 6¹, 6² postcardiac mediastinum; 7, 7¹, 7² diaphragm; 8 esophagus; 9 cranial vena cava; 10 brachiocephalic artery; 11 left subclavian artery; 12, 12th rib from which a piece is excised; 13 13th rib; 14 costocervical vein; 15 thoracic duct; 16 division point of subclavian vein into axillary vein and jugular vein. *a*, *a*¹, *a*² cranial mediastinal lymph nodes; *b* left tracheobronchial lymph node; *b*' middle tracheobronchial lymph node; *c* sternal lymph node; *d*, *d*¹ lymph vessels that run to the cranial lumbar aortic lymph node; *e* lymph vessels that enter the abdominal cavity through the diaphragm and open into splenic lymph nodes, gastric lymph node, left hepatic lymph node or the cranial lumbar aortic lymph node; *f* lymph vessel entering the abdominal cavity with the esophagus; *g* intercostal lymph node; *h* one efferent vessel running to the right side and appearing in Figure 18 (10). Source: Dr. Hermann Baum (1918). (This work is in the public domain).

FIGURE 18: RIGHT SIDE OF THE THORACIC CAVITY OF THE DOG

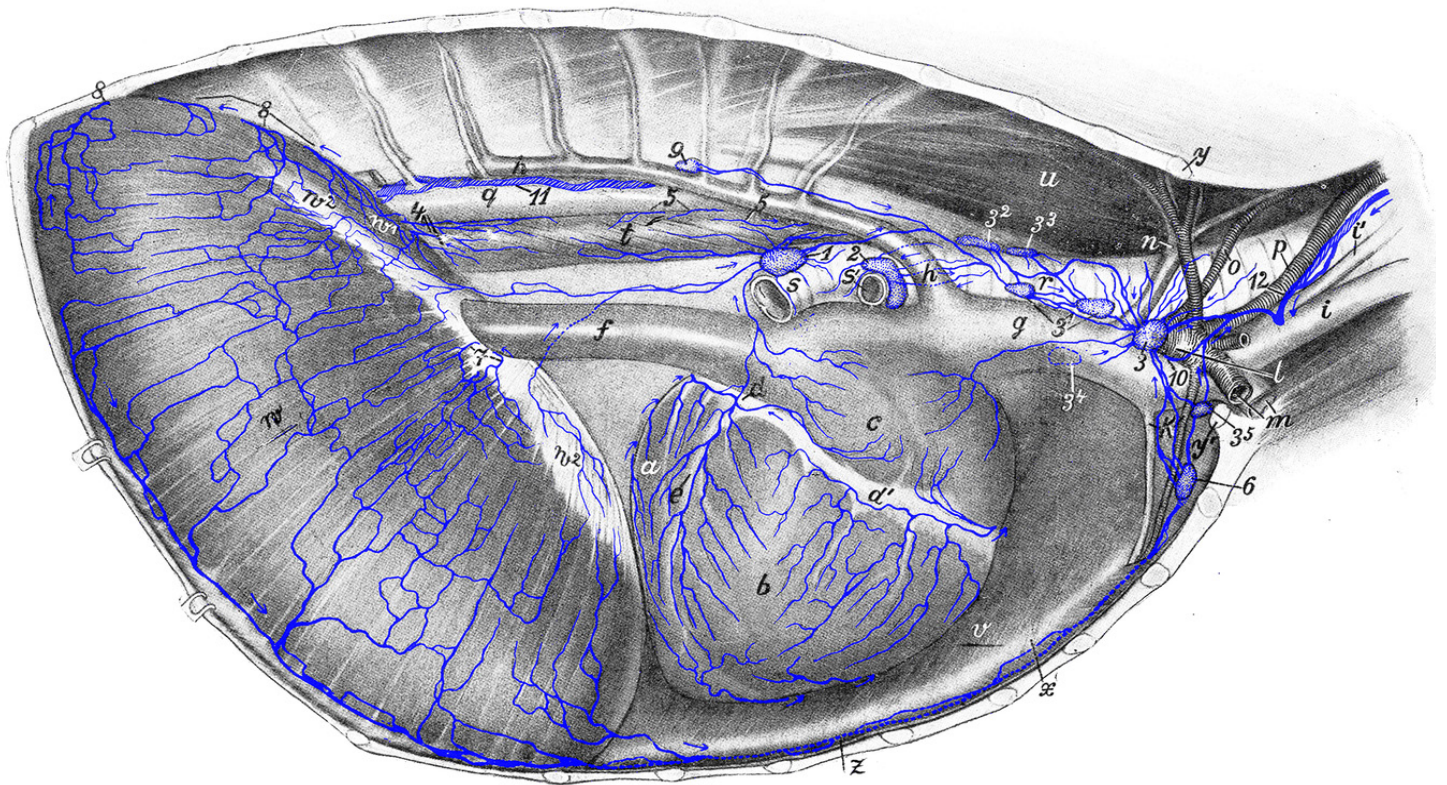


Figure 18: After removal of right costal wall and right lung. *a* left ventricle; *b* right ventricle; *c* right atrium; *d, d'* coronary sulcus; *e* right longitudinal sulcus; *f* caudal vena cava; *g* cranial vena cava; *h* azygos vein; *i* external jugular vein; *i'* internal jugular vein; *k* internal mammary artery and vein; *l* right subclavian artery; *m* right axillary artery and vein; *n* right costocervical vein; *o* right vertebral artery; *p* right common carotid artery; *q* aorta; *r* trachea; *s* right main bronchus; *s'* right eparterial bronchus; *t* esophagus; *u* *M. longus colli*; *v* left *M. transversus thoracis*; *w* costal part, *w*¹ lumbar part, and *w*² central tendon of diaphragm; *x* sternum; *y, y'* dorsal and ventral piece of 1st rib; *z* right *M. transversus thoracis* (cut off). *1* middle tracheobronchial lymph node; *2* right tracheobronchial lymph node; *3, 3*¹, *3*², *3*³, *3*⁴, *3*⁵ cranial mediastinal lymph nodes; *4* lymph vessels of the esophagus entering the abdominal cavity; *5, 5* lymph vessels of the esophagus turning towards its dorsal edge and then to the left and entering the left tracheobronchial lymph node; *6* sternal lymph node; *7* lymph vessels opening into the gastric lymph node, splenic lymph node, hepatic lymph node or cranial lumbar aortic lymph node; *8, 8* lymph vessels running to cranial lumbar aortic lymph node; *9* intercostal lymph node; *10* efferent vessel of a left cranial mediastinal lymph node; *11* thoracic duct; *12* right tracheal duct. Source: Dr. Hermann Baum (1918). (This work is in the public domain).

FIGURE 19: LYMPH VESSELS OF THE PLEURA OF THE DOG

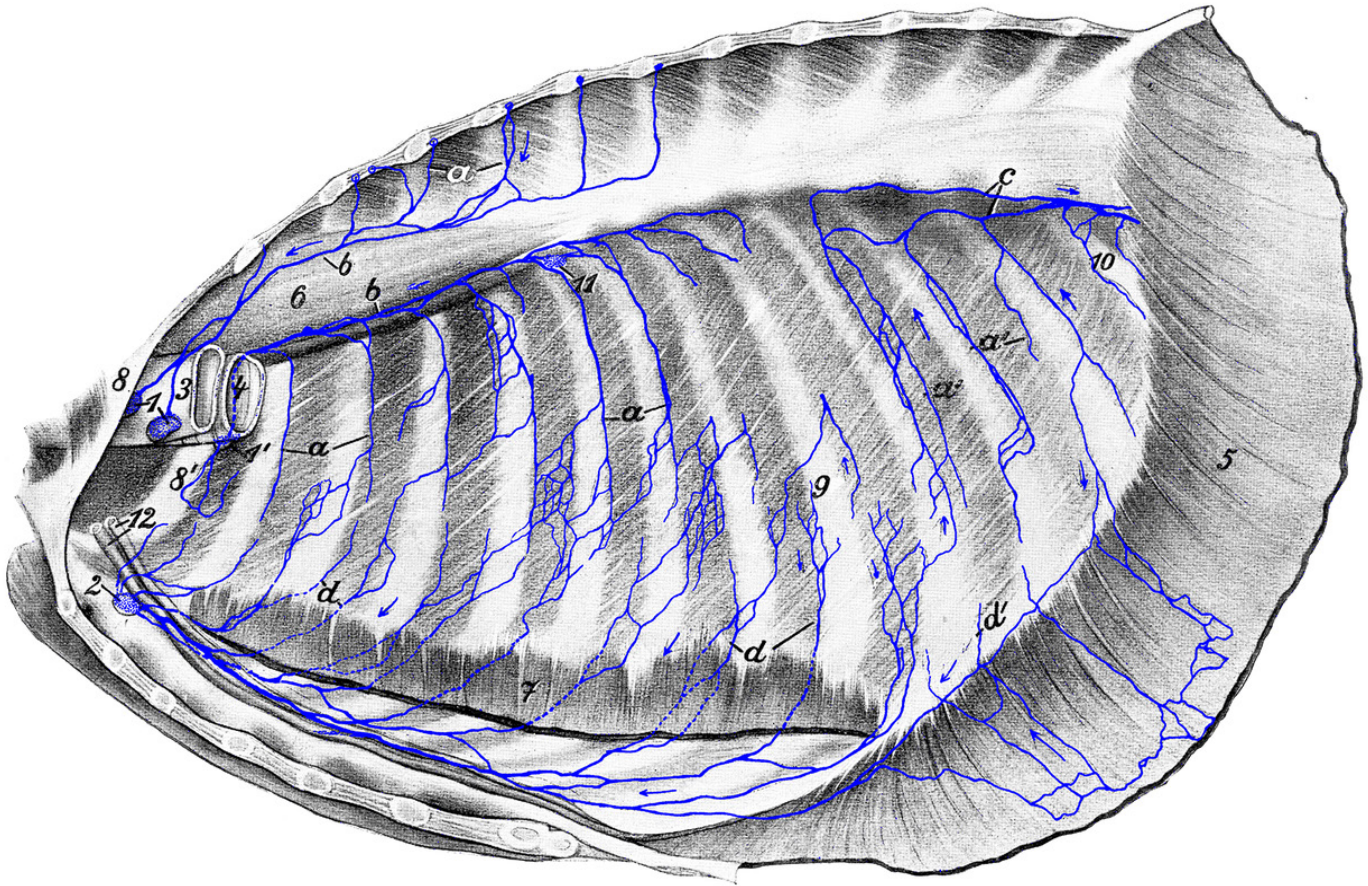


Figure 19: Left thoracic wall and organs of the thorax removed. *a, a'* dorsal running lymph vessels; they merge to form larger vessels, which run partly (*b*) cranial to the cranial mediastinal lymph nodes (*1, 1'*) and partly (*c*) caudal to the cranial lumbar aortic lymph node. *d, d'* ventral running lymph vessels, which open into the sternal lymph node (*2*). Some of them (*d'*) first run over the diaphragm. *1, 1'* cranial mediastinal lymph nodes; *2* sternal lymph node; *3* esophagus (cut off); *4* trachea (cut off); *5* diaphragm (cut off and retracted); *6* *M. longus colli*; *7* *M. transversus thoracis* (cut off); *8* left and *8'* right 1st rib; *9* 9th rib; *10* 13th rib; *11* intercostal lymph node; *12* internal mammary artery and vein. Source: Dr. Hermann Baum (1918). (This work is in the public domain).

FIGURE 20: LYMPH VESSELS OF THE LUNGS AND TRACHEOBRONCHIAL LYMPH NODES OF THE DOG

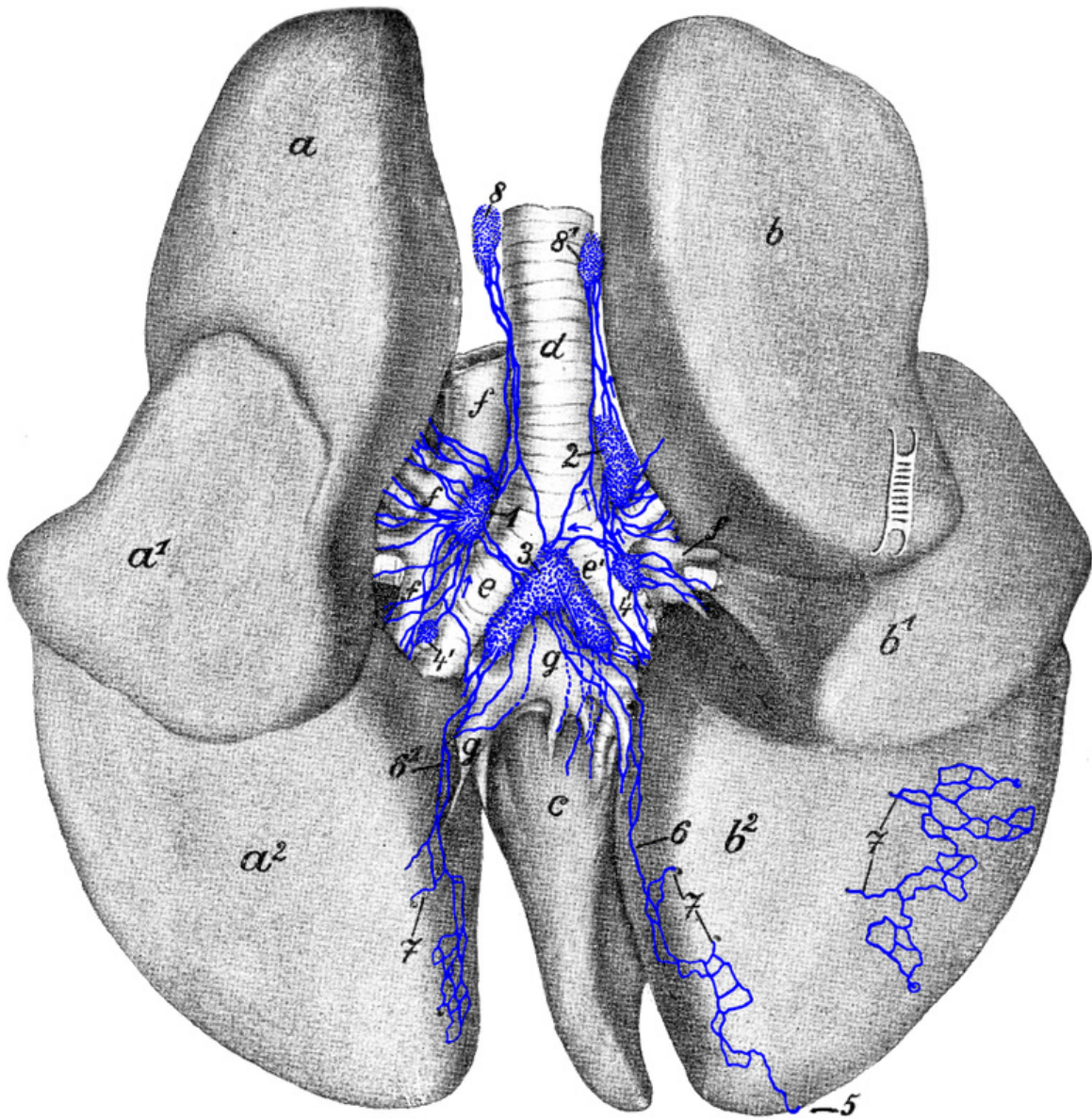


Figure 20: Dorsal side of the lungs; slightly pulled apart. *a*, *a*¹, *a*² left apex, cardiac and base lobes (now known as left cranial [divided into a cranial and caudal part] and caudal lobes); *b*, *b*¹, *b*² right apex, cardiac and base lobes (now known as right cranial, middle and caudal lobes); *c* *Lobus intermedius* (accessory lobe); *d* end of trachea; *e* left and *e*' right main bronchus; *f*, *f* pulmonary artery and its branches; *g*, *g* pulmonary vein. *1* left tracheobronchial lymph node; *2* right tracheobronchial lymph node; *3* middle tracheobronchial lymph node; *4*, *4*' pulmonary lymph nodes; *5* subserous lymph vessel passing around the *Margo acutus* onto the diaphragmatic surface where it runs deeper; *6*, *6*¹ subserous lymph vessels running in the first part of the pulmonary ligament; *7*, *7*, *7* subserous lymph vessels, which start to run deep at this location; *8* left and *8*¹ right mediastinal lymph node. Source: Dr. Hermann Baum (1918). (This work is in the public domain).

FIGURE 21: LEFT SIDE OF THE DOG'S HEART WITH INJECTED LYMPH VESSELS

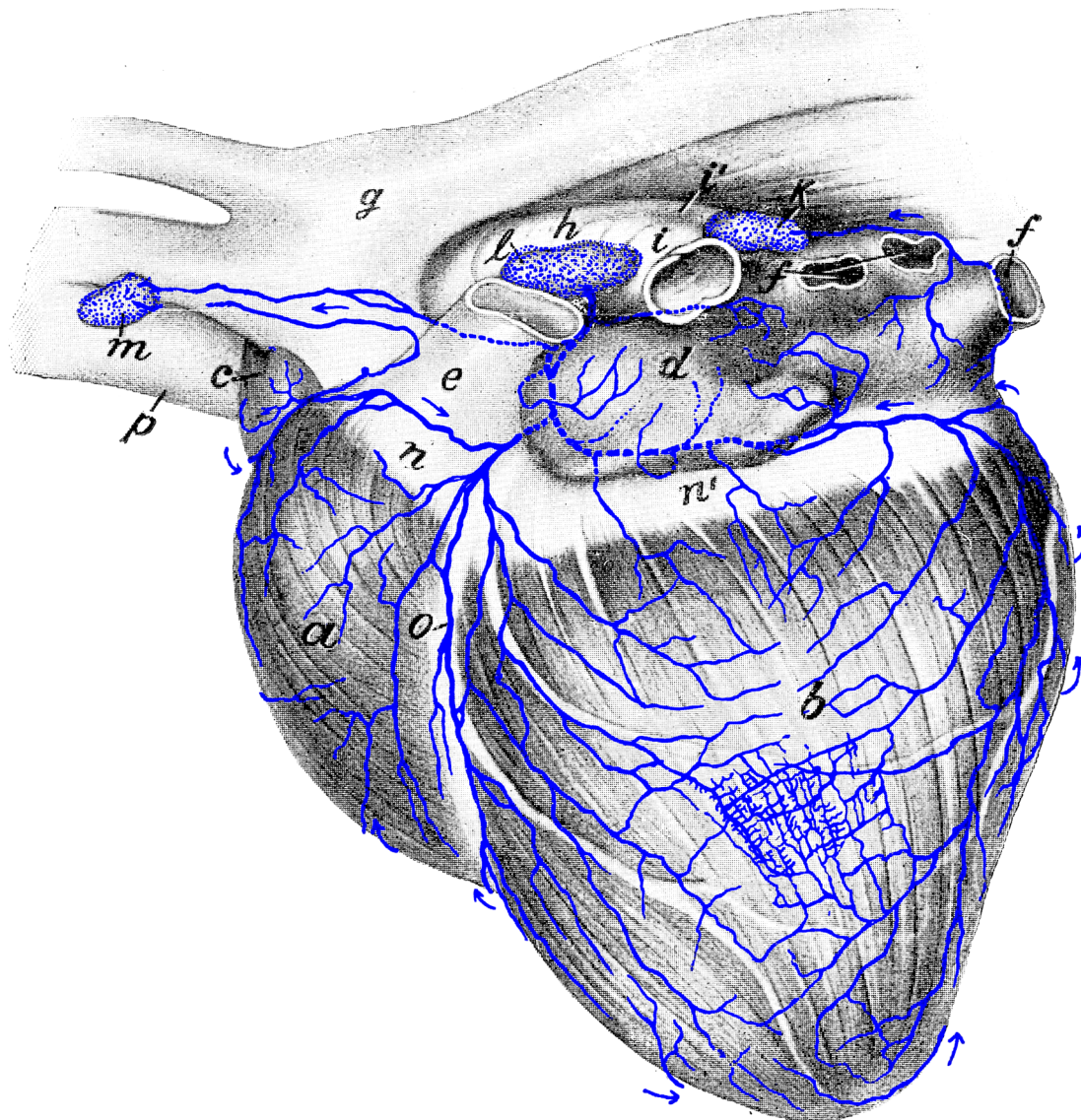


Figure 21: *a* right ventricle; *b* left ventricle; *c* right atrium (auricle); *d* left atrium; *e* pulmonary artery (cut off); *f* pulmonary veins (cut off); *g* aorta; *h* end of the trachea; *i* left and *i'* right main bronchus; *k* middle tracheobronchial lymph node; *l* left tracheobronchial lymph node; *m* cranial mediastinal lymph node; *n*, *n'* coronary sulcus; *o* left longitudinal sulcus; *p* cranial vena cava. Source: Dr. Hermann Baum (1918). (This work is in the public domain).

FIGURE 22: BRONCHIAL LYMPH CENTER OF THE DOG

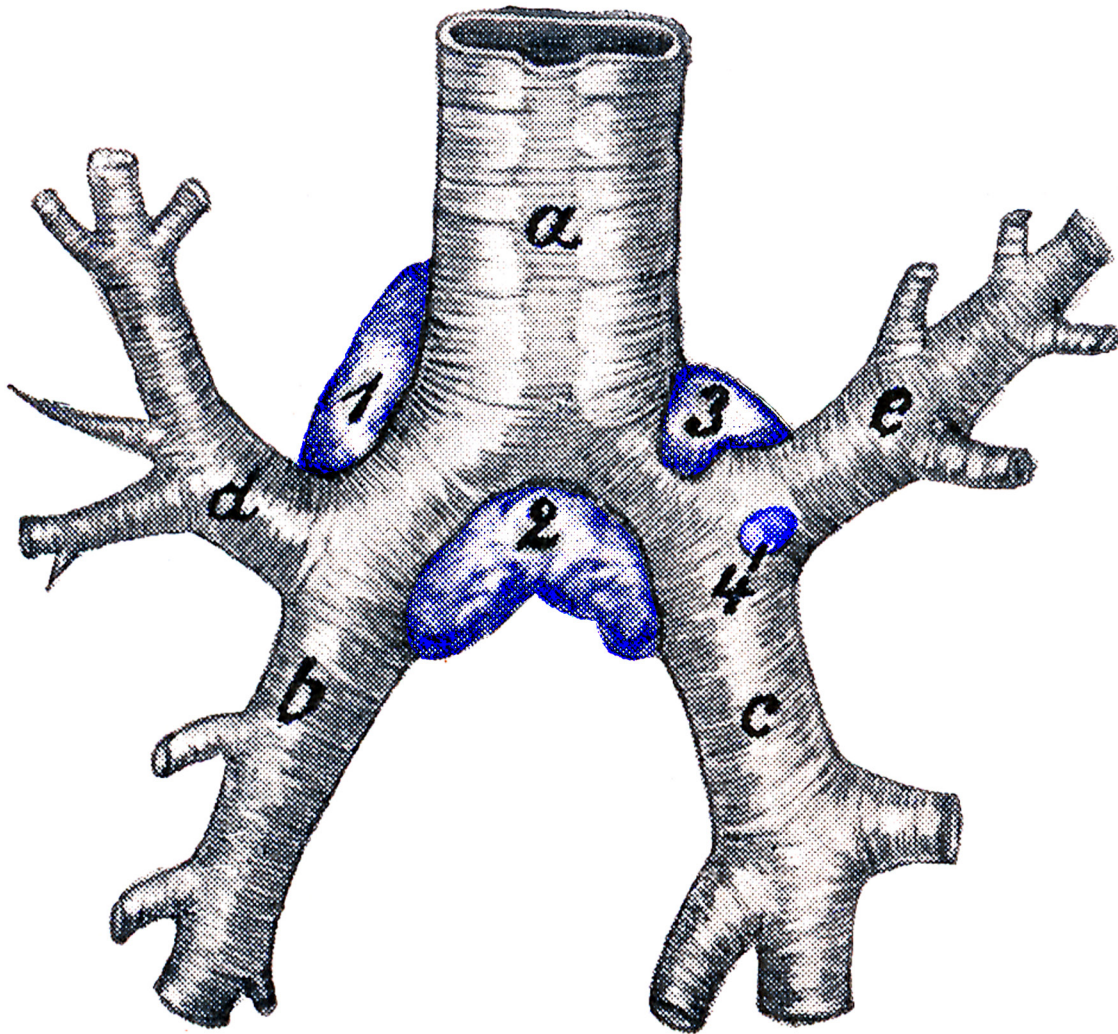


Figure 22: *a* end of the trachea; *b* left and *c* right main bronchus; *d* left and *e* right cranial bronchus. *1* left tracheobronchial lymph node; *2* middle tracheobronchial lymph node; *3* right tracheobronchial lymph node; *4* pulmonary lymph node. Source: Dr. Hermann Baum (1918). (This work is in the publicdomain).

FIGURE 23: LYMPH VESSELS OF THE CERVICAL PART OF THE TRACHEA AND ESOPHAGUS OF THE DOG

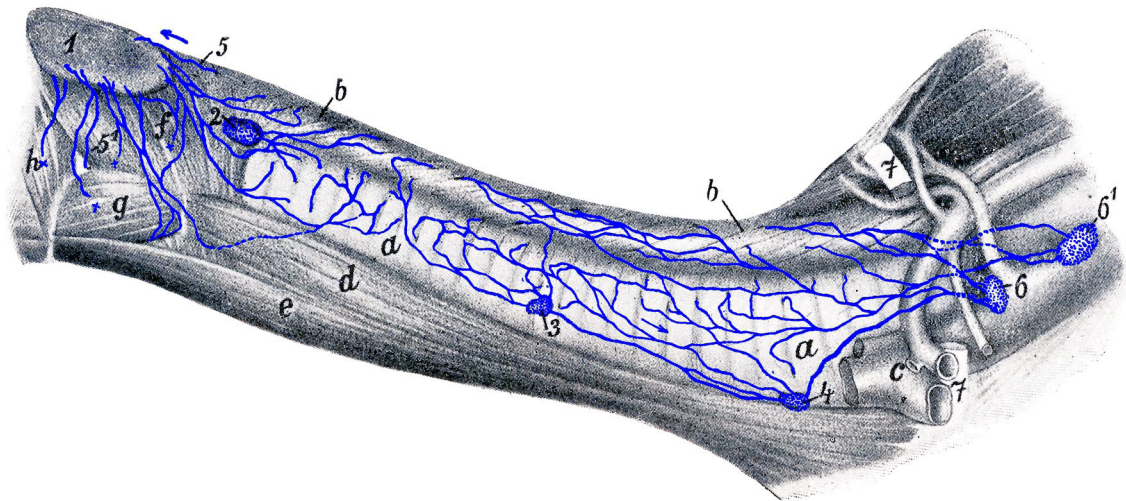


Figure 23: Parts located in the thoracic cavity are shown in Figure 17. *a*, *a* cervical part of the trachea; *b*, *b* cervical part of the esophagus; *c* veins (axillary vein, external and internal jugular veins); *d* *M. sternothyroideus*; *e* *M. sternohyoideus*; *f* *M. thyropharyngeus* and *cricopharyngeus*; *g* *M. hypothyroideus*; *h* *M. keratopharyngeus*. 1 medial retropharyngeal lymph node; 2 cranial cervical lymph node; 3 middle cervical lymph node; 4 caudal cervical lymph node; 5 lymph vessels from the initial part of the esophagus; 6, 6' cranial mediastinal lymph nodes; 7, 7st rib from which a piece is excised. Source: Dr. Hermann Baum (1918). (This work is in the public domain).

FIGURE 24: LYMPH VESSELS AND LYMPH NODES OF THE ABDOMINAL CAVITY OF THE DOG

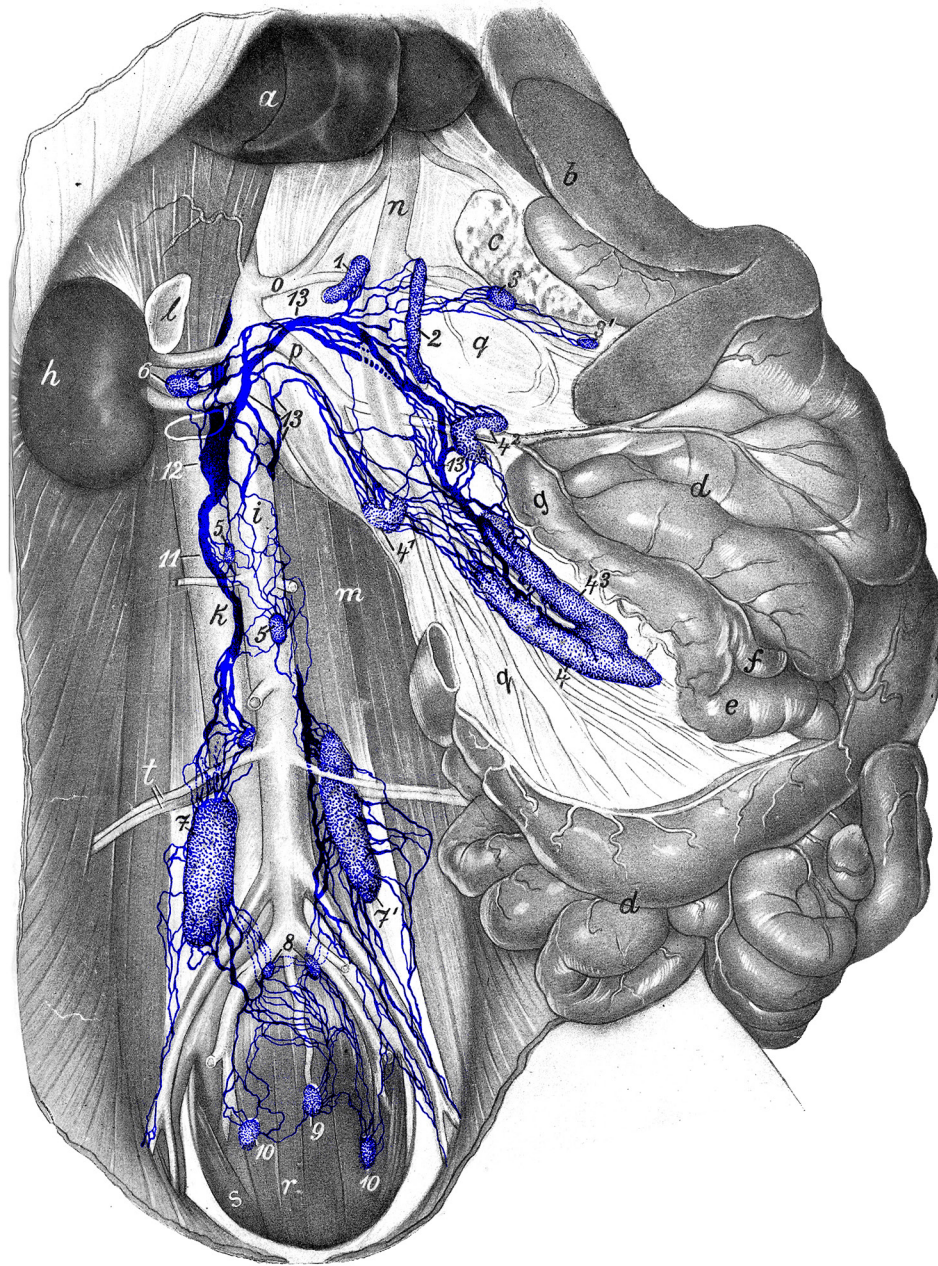


Figure 24: The animal is lying on its back, the abdominal cavity is open, and most of the abdominal organs are laid to the side or pulled out. *a* liver; *b* spleen; *c* pancreas; *d* jejunum; *e* ileum; *f* cecum; *g* colon; *h* right kidney; *i* aorta; *k* vena cava; *l* right adrenal gland; *m* lumbar musculature; *n* portal vein; *o* celiac artery; *p* cranial mesenteric artery; *q* mesentery with blood vessels; *r* depressor and *s* curvator muscles of tail; *t* deep circumflex iliac artery and vein. *1* right hepatic lymph node; *2* left hepatic lymph node; *3*, *3*¹ splenic lymph nodes; *4*, *4*¹, *4*², *4*³ jejunal lymph nodes; *5* lumbar aortic lymph nodes; *6* right cranial lumbar aortic lymph node; *7*, *7*¹ medial iliac lymph nodes; *8* hypogastric lymph nodes; *9* medial sacral lymph node; *10* lateral sacral lymph node; *11* lumbar trunk; *12* *cisterna chyli*; *13*, *13*, *13* lymphatic trunks from the viscera. Source: Dr. Hermann Baum (1918). (This work is in the public domain).

FIGURE 25: LYMPH VESSELS OF THE SMALL INTESTINE AND THE OMENTUM

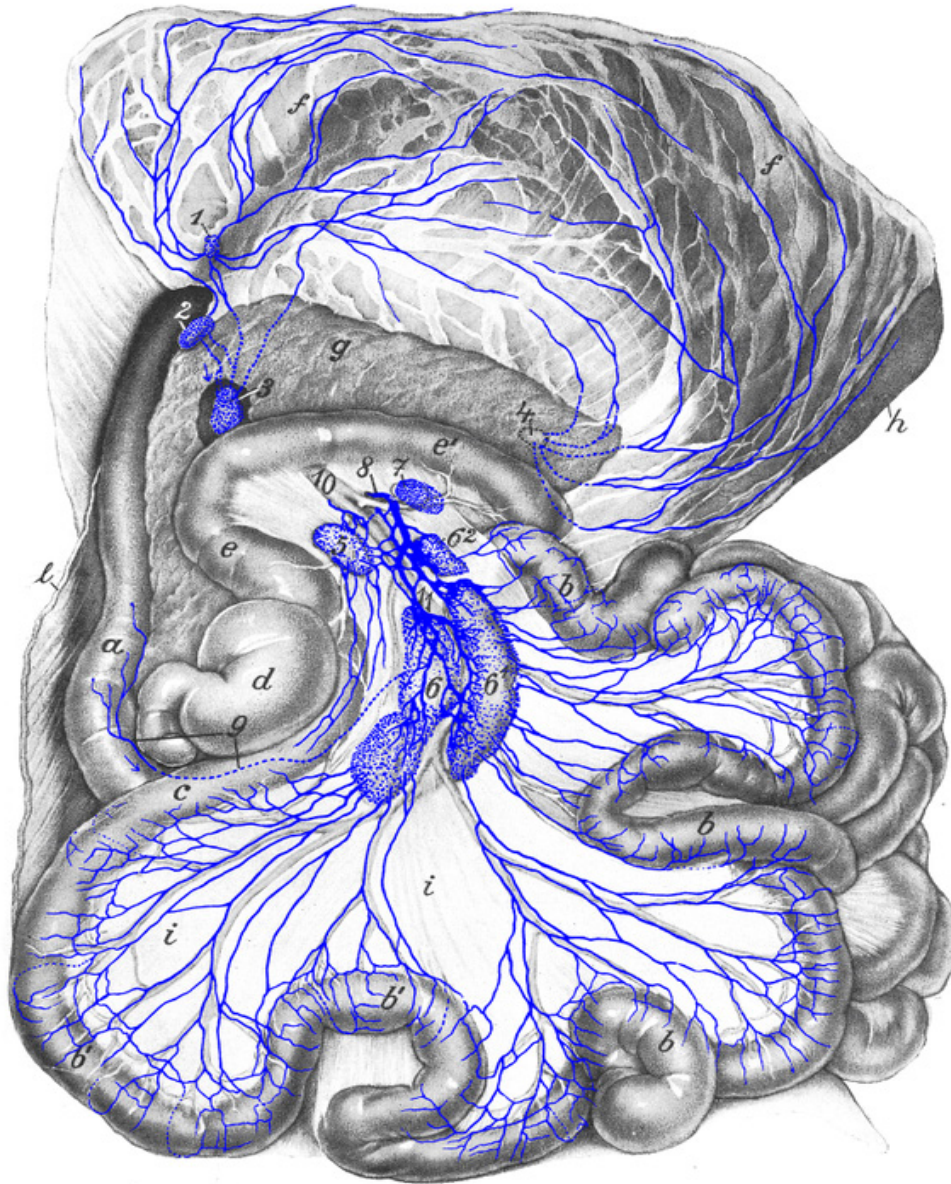


Figure 25: Dog is lying on its back. *a* duodenum; *b*, *b'* jejunum; *c* ileum; *d* cecum; *e*, *e'* colon; *f*, *f* omentum (dorsal wall); the stomach shimmers through it; *g* pancreas; *h* spleen (largely covered by the omentum); *i* intestinal mesentery; *l* cut-open abdominal wall. *1* omental lymph node; *2* duodenal lymph node; *3* right hepatic lymph node; *4* splenic lymph node; *5* right colic lymph node; *6*, *6'*, *6''* jejunal lymph nodes; *7* middle colic lymph node; *8* intestinal trunk; *9* lymph vessel of duodenum going into right jejunal lymph node *6*; *10* cranial mesenteric artery; *11* jejunal trunk. Source: Dr. Hermann Baum (1918). (This work is in the public domain).

FIGURE 26: LYMPH VESSELS AND LYMPH NODES FROM THE STOMACH, SPLEEN, PANCREAS, DUODENUM, AND LARGE INTESTINE OF THE DOG

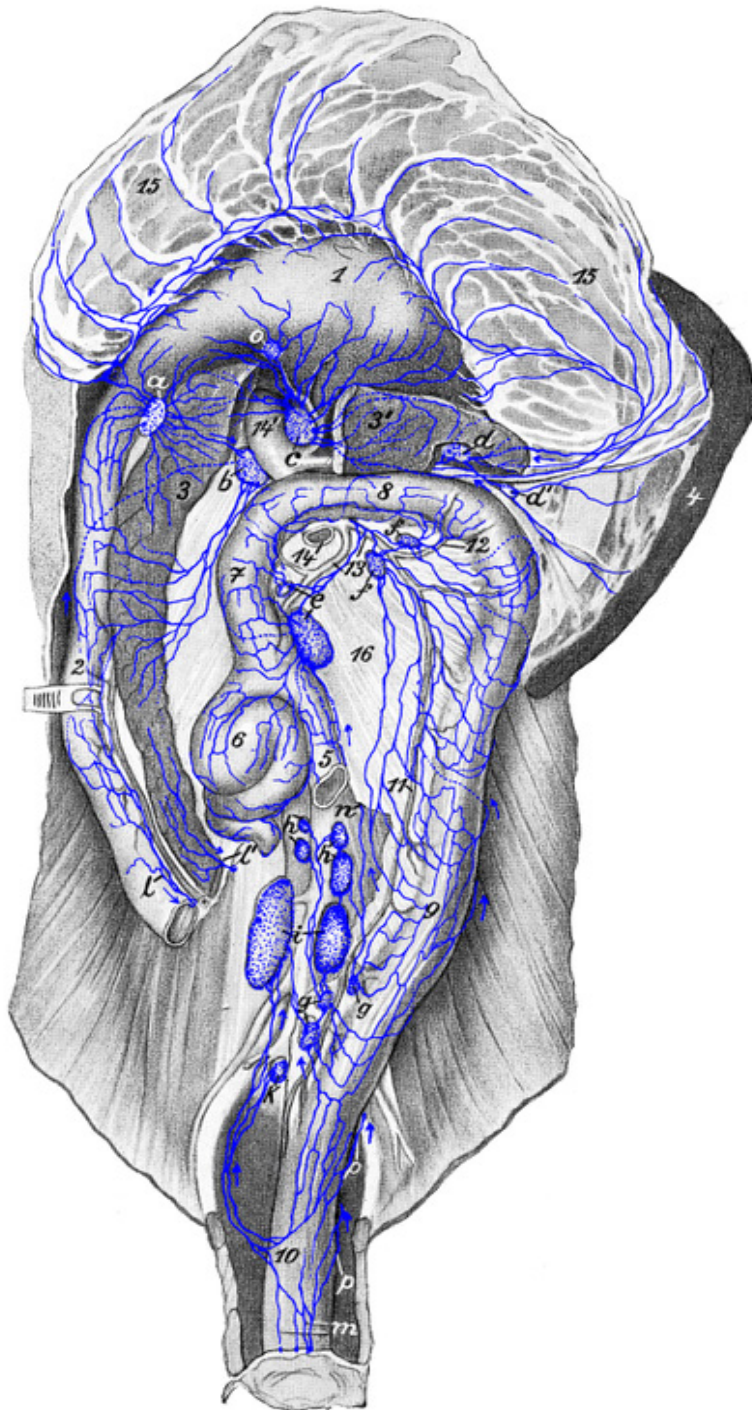


Figure 26: The animal is lying on its back, and the small intestine is removed except for the first part of the duodenum and the end of the ileum. *a* duodenal lymph node; *b* right hepatic lymph node; *c* left hepatic lymph node; *d*, *d'* splenic lymph nodes (a part of the pancreas is cut out so that [*c*] and [*e*] became visible); *e* right colic lymph node; *f*, *f'* middle colic lymph nodes; *g*, *g'* left colic lymph nodes; *h*, *h'* lumbar aortic lymph nodes; *i* medial iliac lymph nodes (a part of the mesocolon is cut out so that the groups [*h*] and [*i*] became visible); *k* hypogastric lymph node; *l* lymph vessel of the duodenum and *l'* lymph vessel of the pancreas running to the jejunal lymph nodes and therefore cut off; *m* lymph vessels of the anus and rectum; *n* lymph vessel running directly to the *cisterna chyli*; *o* gastric lymph node; *p*, *p* lymph vessels of the rectum passing over the dorsal side of the rectum to the hypogastric and medial iliac lymph nodes. *1* stomach; *2* duodenum (cut off); *3*, *3'* pancreas; *4* spleen (with splenic veins laid aside); *5* ileum (cut off); *6* cecum; *7*, *8*, and *9* colon; *10* rectum; *11* left colic vein; *12* middle colic vein; *13* ileocolic vein (*V. ileocaecocolica*); *14*, *14'* portal vein; *15*, *15* ventral wall of the omental bursa, folded back; *16* mesentery of the colon. Source: Dr. Hermann Baum (1918). (This work is in the public domain).

FIGURE 27: LYMPH VESSELS OF THE KIDNEYS AND LYMPH NODES ALONG THE ABDOMINAL AORTA AND ITS TERMINAL BRANCHES

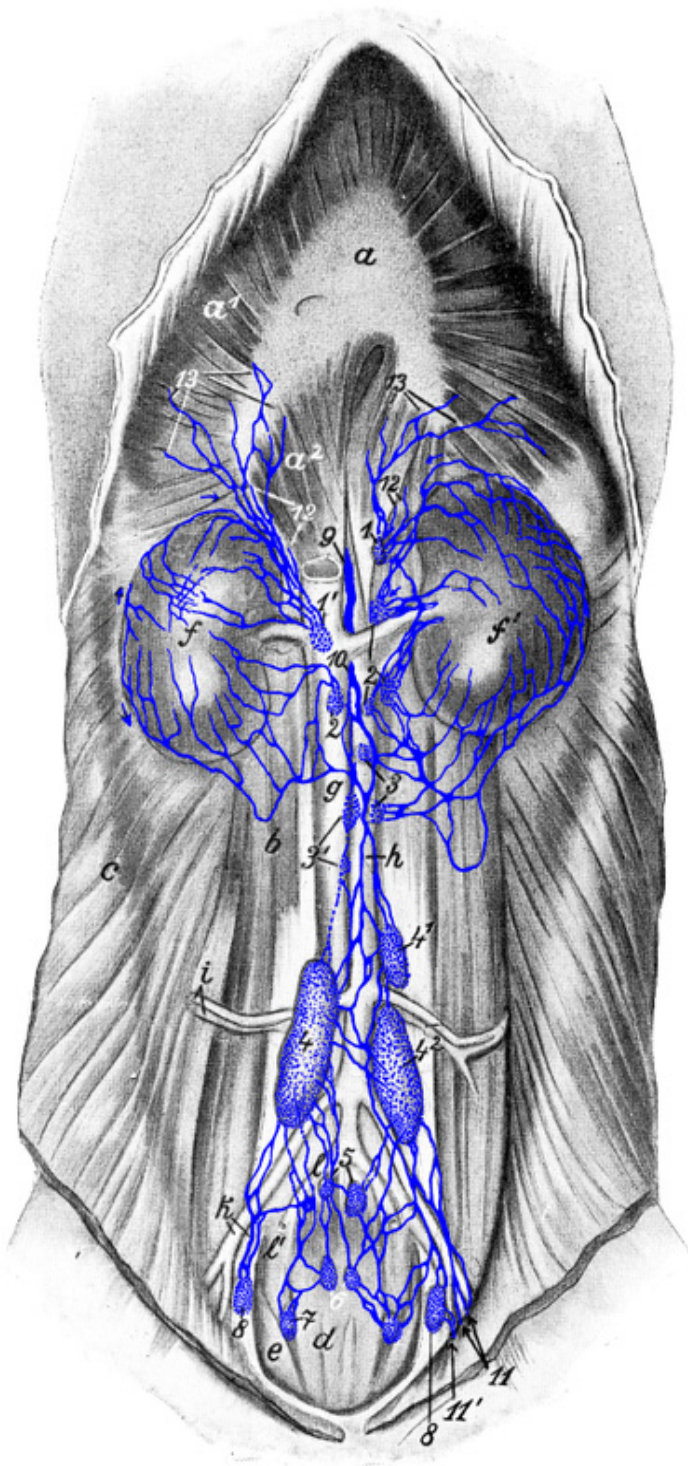


Figure 27: The dog lies on its back, the ventral abdominal wall and the abdominal organs (except for the kidneys) are removed. The kidneys are not drawn in the correct position; the right kidney (*f*) is pushed back pelvically, so that certain lymph vessels could be drawn into the figure. *a, a¹, a²* diaphragm; *b* lumbar musculature; *c* lateral abdominal wall; *d* depressor muscles of the tail (muscles that lower the tail) and *e* lateral flexors of tail; *f, f'* kidneys; *g* caudal vena cava; *h* abdominal aorta; *i* right deep circumflex iliac artery and vein; *k* right external iliac artery and vein; *l* right hypogastric artery and vein. *1* left and *1'* right cranial lumbar aortic lymph nodes (the latter is covered by the caudal vena cava); *2* lumbar aortic lymph nodes located near the renal artery and vein; *3, 3'* lumbar aortic lymph nodes (those marked [*3'*] are covered by the caudal vena cava); *4, 4¹, 4²* medial iliac lymph nodes; *5* hypogastric lymph nodes; *6* medial sacral lymph nodes; *7* lateral sacral lymph node; *8, 8'* deep inguinal lymph node; *9* *cisterna chyli*; *10* pelvic lymphatic trunk; *11* efferent vessels of the superficial inguinal lymph nodes and medial femoral lymph node (some of them [*11'*] enter the deep inguinal lymph node [*8*]); *12* lymph vessels which travel with the sympathetic nerve and greater splanchnic nerve from the thoracic cavity into the abdominal cavity; *13* lymph vessels of the diaphragm. Source: Dr. Hermann Baum (1918). (This work is in the public domain).

FIGURE 28: LYMPH VESSELS OF THE LIVER OF THE DOG

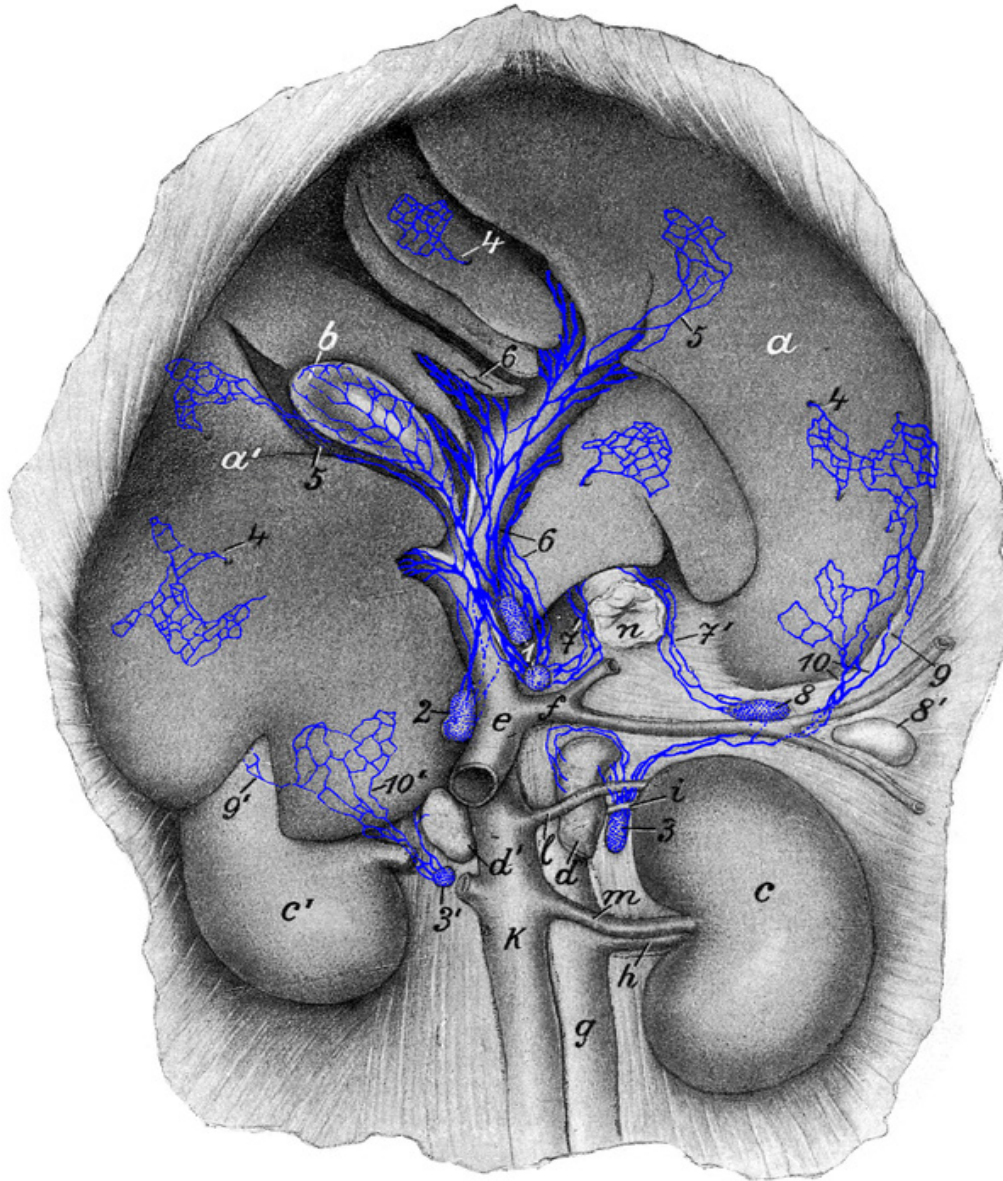


Figure 28: The animal is lying on its back; the visceral surface of the liver is shown. 1 left hepatic lymph nodes; 2 right hepatic lymph node; 3, 3' cranial lumbar aortic lymph nodes; 4, 4, 4 subserosal lymph vessels starting to run deep; 5, 5 subserosal lymph vessels running subserosally to the hepatic lymph nodes; 6, 6 deep lymph vessels of the liver; 7, 7' lymph vessels running with the terminal part of the esophagus; 8, 8' splenic lymph nodes; 9, 9' subserosal lymph vessels arising from the parietal surface of the liver; 10, 10' subserosal lymph vessels from the visceral surface of the liver running to cranial lumbar aortic lymph nodes (3, 3'). a, a' liver; b gallbladder; c left and c' right kidney; d, d' adrenal glands; e portal vein; f gastrosplenic vein; g aorta; h renal artery; i *A. lumboabdominalis*; k caudal vena cava; l *V. lumboabdominalis*; m renal vein; n esophagus (cut-off). Source: Dr. Hermann Baum (1918). (This work is in the public domain).

FIGURE 29: LYMPH VESSELS OF REPRODUCTIVE ORGANS OF THE FEMALE DOG

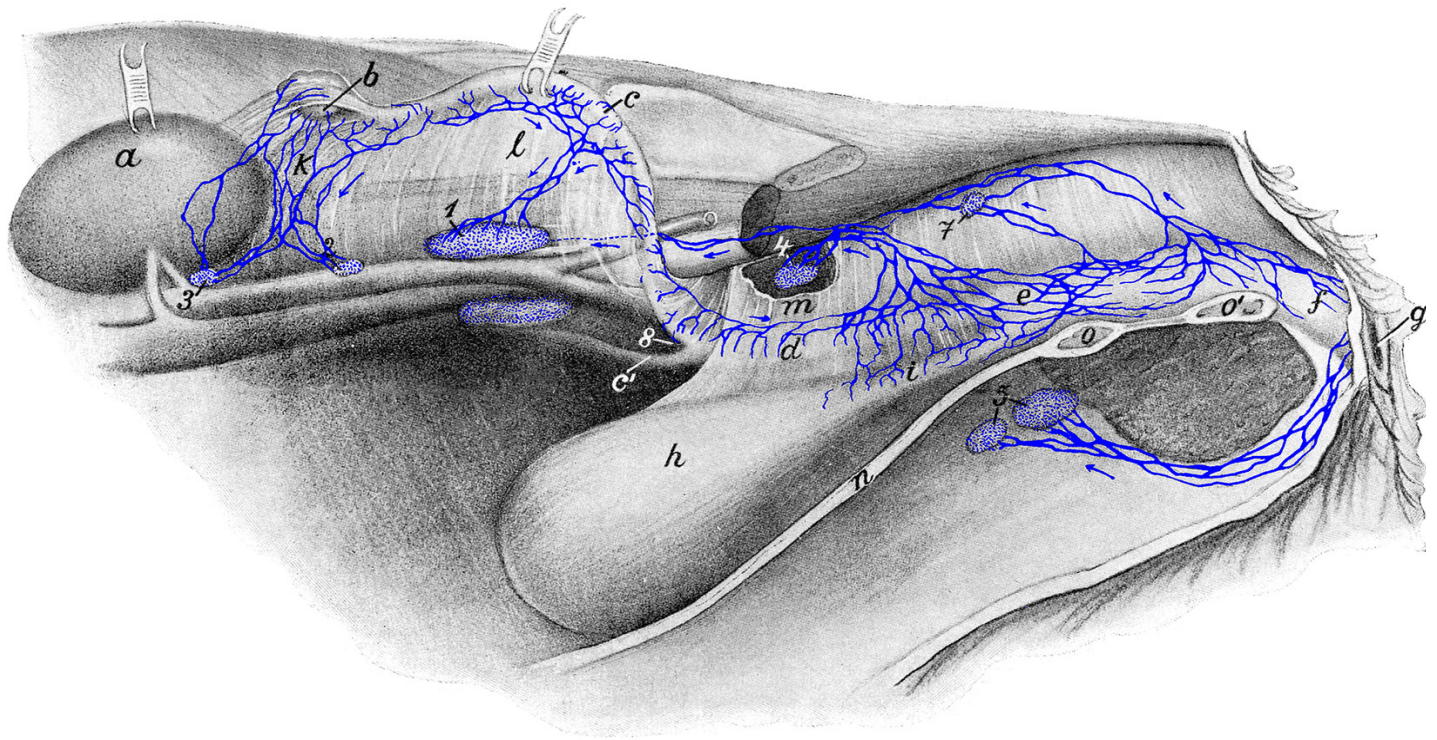


Figure 29: 1 medial iliac lymph node; 2 and 3 lumbar aortic lymph nodes; 4 hypogastric lymph node; 5 superficial inguinal lymph nodes; 7 lateral sacral lymph node; 8 lymph vessel bending over to the other surface of the uterine horn. *a* left kidney (folded back); *b* left ovary embedded in fat (folded back); *c* left uterine horn (folded back); *c'* right uterine horn; *d* uterine body; *e* vagina; *f* vaginal vestibule; *g* vulva; *h* urinary bladder; *i* urethra; *k* suspensory ligament of the ovary (*ligamentum suspensorium ovarii*) including the ovary-kidney ligament; *l* broad ligament of uterus (*ligamentum latum uteri*); *m* lateral bladder ligament; *n* ventral abdominal wall (cut lateral to the linea alba); *o*, *o'* ventral pelvic wall (cut left of the median plane). Source: Dr. Hermann Baum (1918). (This work is in the public domain).

FIGURE 30: LYMPH VESSELS OF THE MAMMARY GLAND OF THE DOG

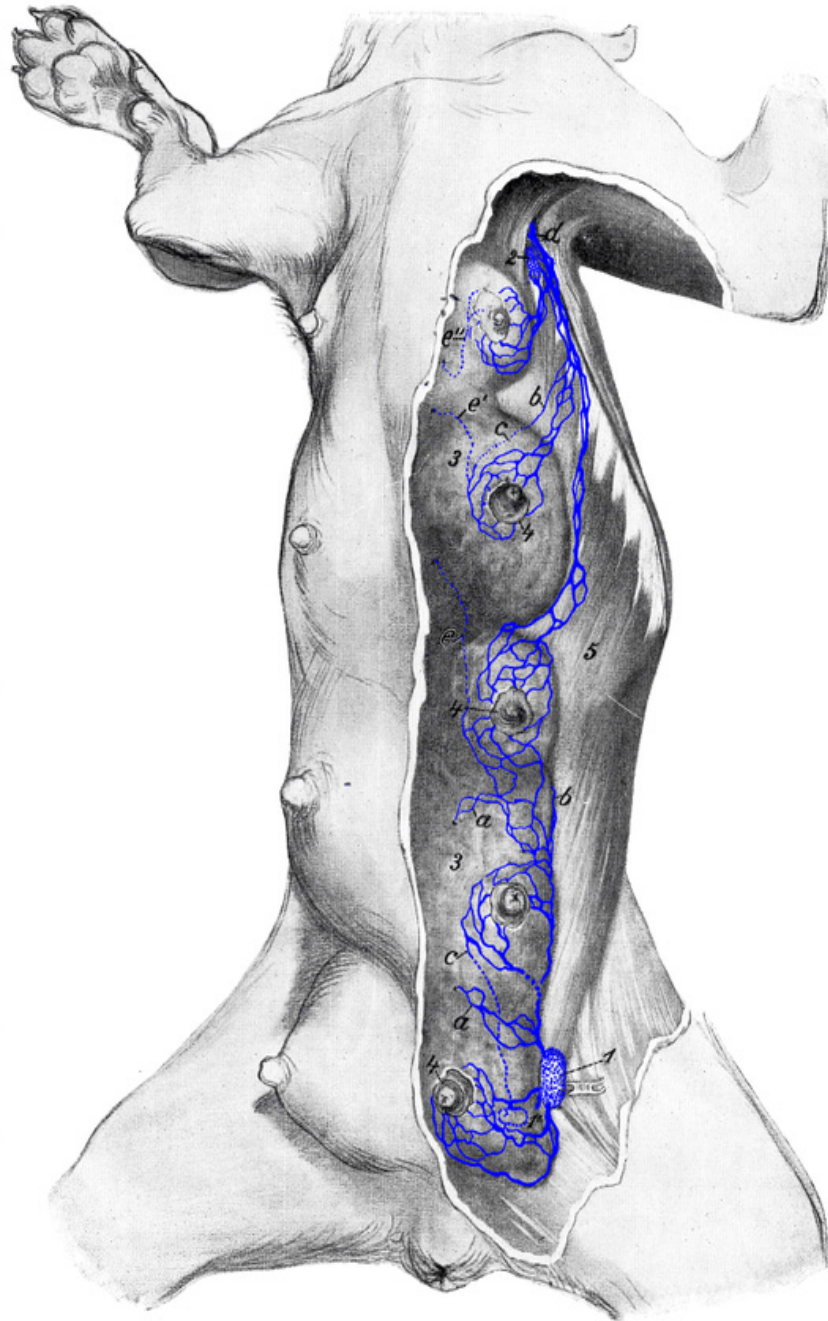


Figure 30: The skin is removed from the left half of the mammary glands. *a, a* lymph vessels of the parenchyma emerging on the surface; *b, b* lymph vessels emerging from under the mammary gland; *c, c* lymph vessels of the skin running deep (the remaining lymph vessels are from the skin and teat); *d* lymph vessels running to the axillary lymph node; *e, e', e''* lymph vessels running deep to the sternal lymph node. *1* superficial inguinal lymph node (slightly pulled out from under the mammary gland); a second superficial inguinal lymph node (*1'*) is covered by the mammary gland; *2* accessory axillary lymph node; *3, 3* mammary gland; *4, 4* teats; *5* *M. obliquus abdominis externus*. Source: Dr. Hermann Baum (1918). (This work is in the public domain).

FIGURE 31: LYMPH VESSELS OF THE URINARY AND REPRODUCTIVE ORGANS OF THE MALE DOG

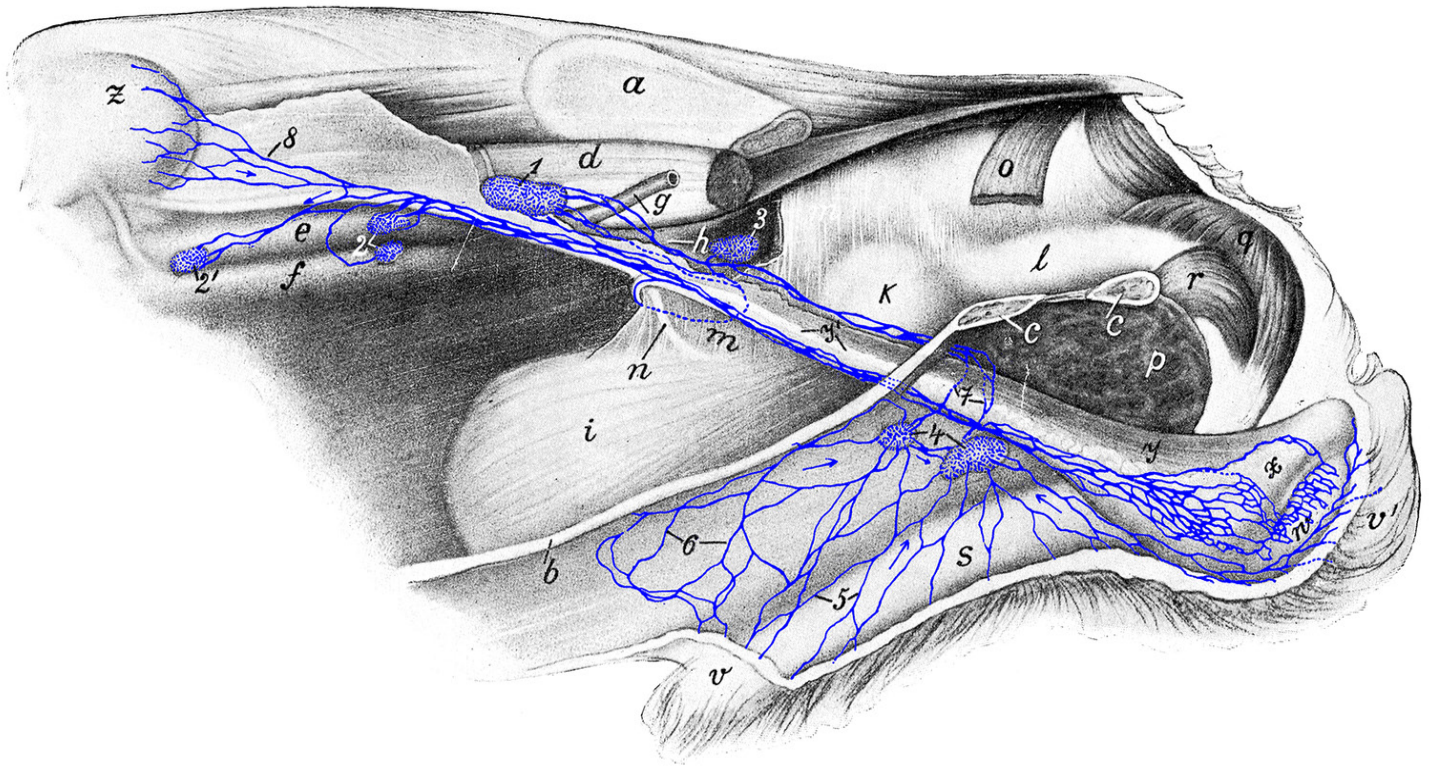


Figure 31: The left abdominal and pelvic wall and the intestine are removed. The penis is slightly detached from the ventral abdominal wall. 1 medial iliac lymph node; 2, 2' lumbar aortic lymph nodes; 3 hypogastric lymph node; 4 superficial inguinal lymph nodes; 5 and 6 lymph vessels of the integument of the prepuce; 7 efferent vessels of superficial inguinal lymph nodes; 8 lymph vessels of the testis, that can be traced to the renal capsule. a ilium (sawn off); b ventral abdominal wall (cut left of the linea alba); c, c ventral pelvic wall (cut left of the median plane); d lumbar musculature; e aorta; f venacava; g left external iliac artery; h right hypogastric artery; i urinary bladder; k prostate; l urethra; m lateral ligament of urinary bladder; n ureter; o *M. coccygeus* (cut off); p cut surface of *M. adductor*; q *M. bulbocavernosus*; r *M. ischiocavernosus*; s penis; v prepuce (cut off); v' outer skin of scrotum; w testis; x epididymis; y spermatic cord with ductus deferens y'; z left kidney. Source: Dr. Hermann Baum (1918). (This work is in the public domain).

FIGURE 32: LYMPH VESSELS OF THE URINARY AND REPRODUCTIVE ORGANS OF THE MALE DOG

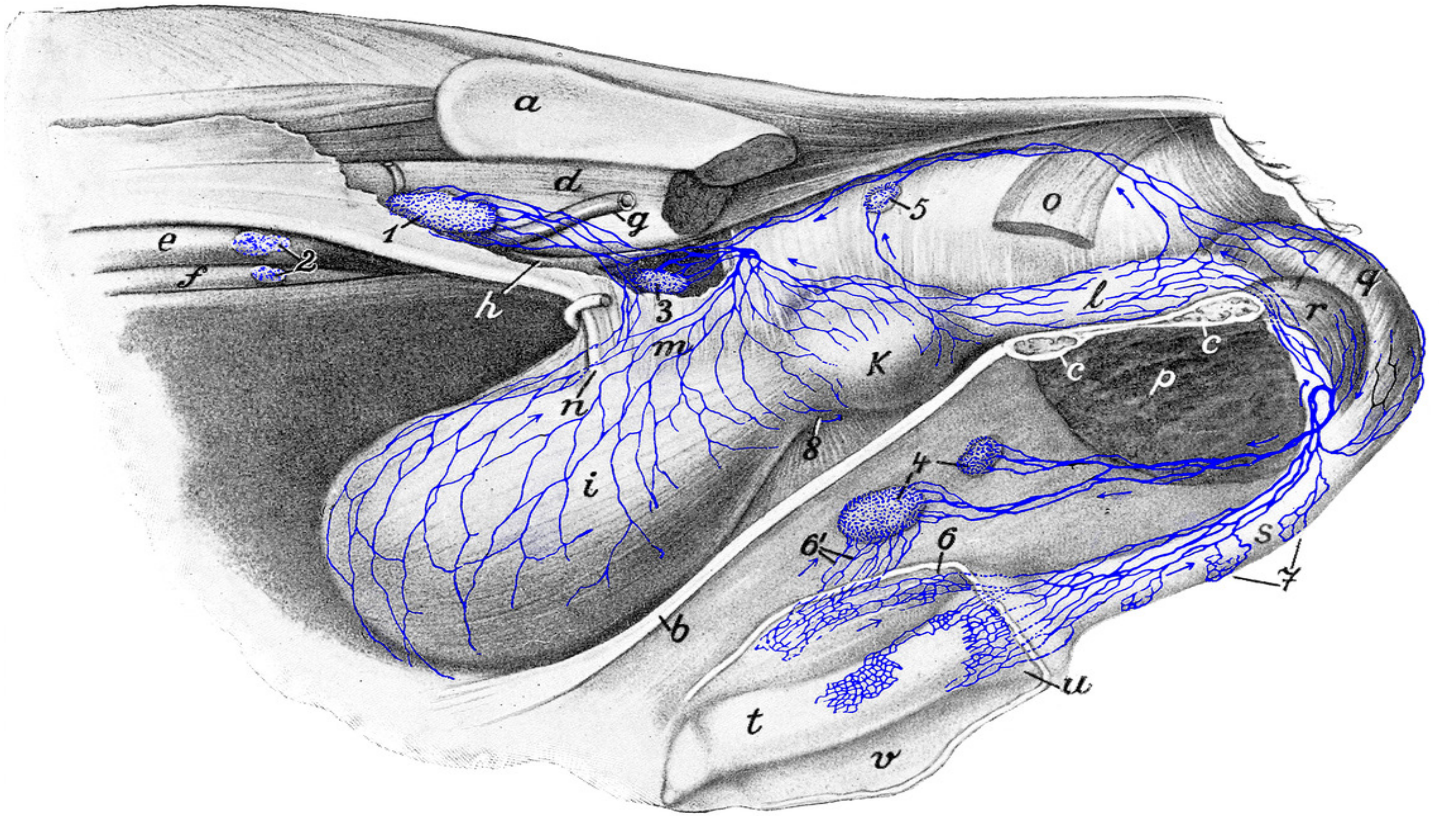


Figure 32: The left abdominal and pelvic wall and the intestine are removed; the penis is slightly detached from the ventral abdominal wall. 1 medial iliac lymph node; 2 lumbar aortic lymph nodes; 3 hypogastric lymph node; 4 superficial inguinal lymph nodes; 5 lateral sacral lymph node; 6, 6' lymph vessels of the integument of the prepuce; 7 lymph vessels of the urethra; 8 lymph vessel of the urinary bladder, which bends to the other side. a ilium (sawn-off); b ventral abdominal wall (cut left of the *linea alba*); c, c ventral pelvic wall (cut left of the median plane); d lumbar musculature; e aorta; f vena cava; g left external iliac artery; h left hypogastric artery; i urinary bladder; k prostate; l urethra; m lateral ligament of the urinary bladder; n ureter; o *M. coccygeus* (cut off); p cut surface from *M. adductor*; q *M. bulbocavernosus*; r *M. ischiocavernosus*; s penis; t glans; u cavernous node; r prepuce (opened and retracted). Source: Dr. Hermann Baum (1918). (This work is in the public domain).

FIGURE 33: LYMPH VESSELS OF THE JOINTS OF THE TOES OF THE FORELIMB

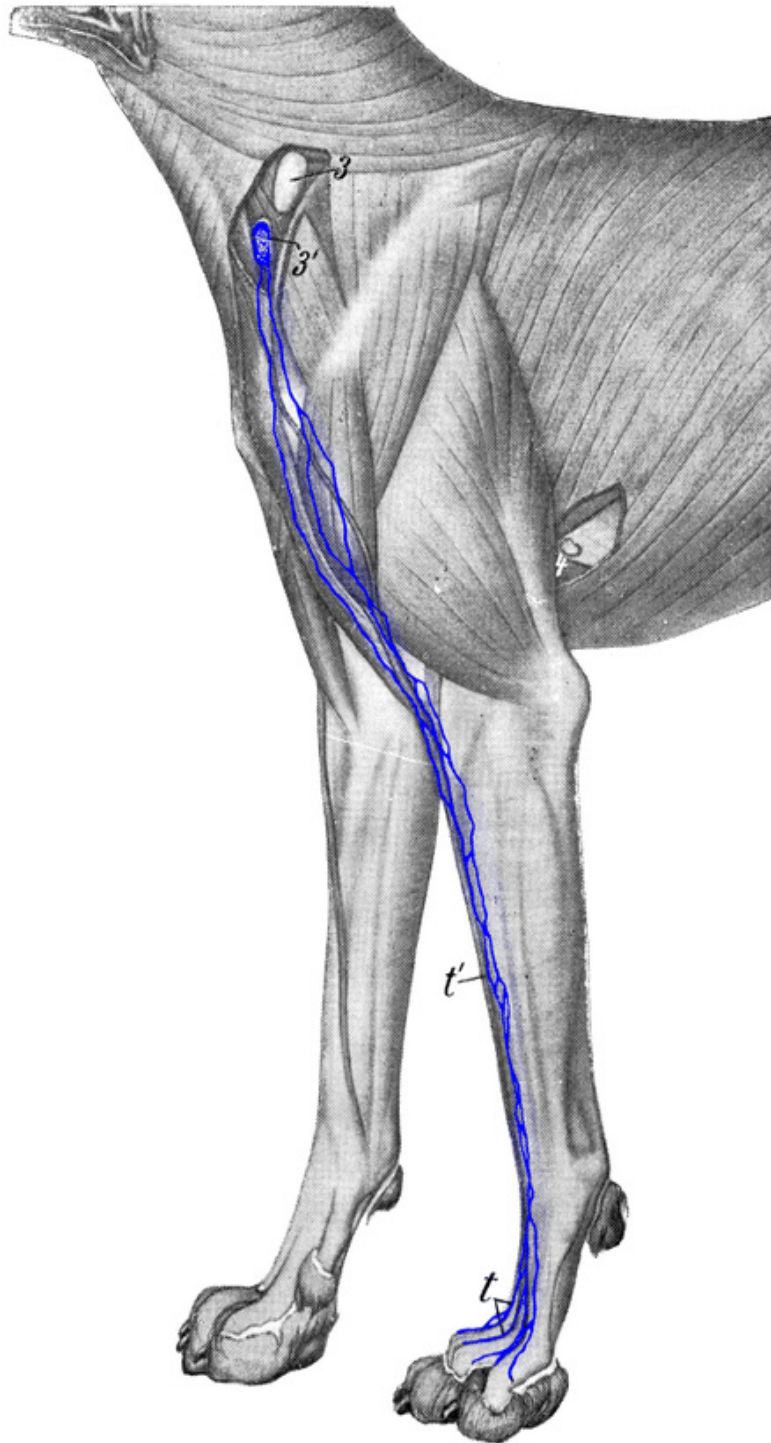


FIGURE 34: LYMPH VESSELS OF THE STIFLE, TARSAL, AND TOE JOINTS OF THE HINDLIMB

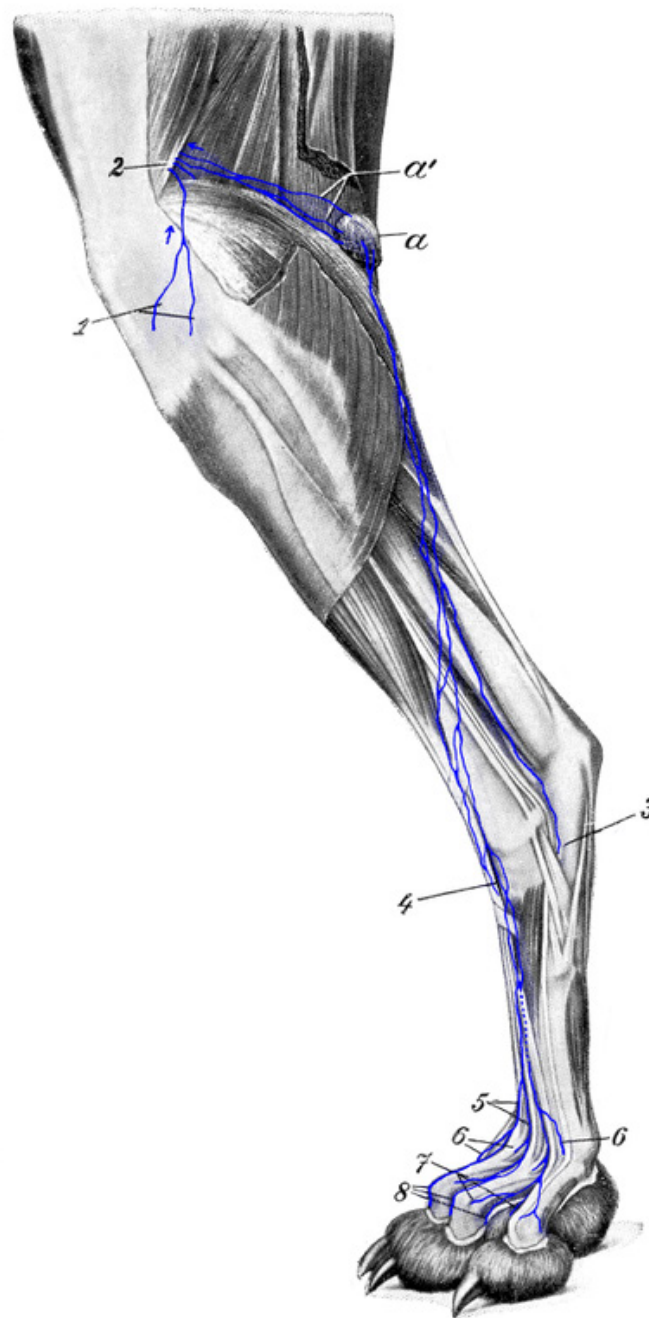


Figure 34: 1 lymph vessels of the stifle joint emerging on its lateral side; 2 lymph vessels of the stifle joint emerging on its flexor side; 3 and 4 lymph vessels of the tarsal joint emerging on its lateral side (3) and the lateral part of its flexor side (4); 5 to 8 lymph vessels of the toe joints, specifically: 6 lymph vessels from the metatarsophalangeal joints; 7 lymph vessels from the proximal interphalangeal joints; 8 lymph vessels from the distal interphalangeal joints. *a* popliteal lymph node; *a'* the efferent vessels leaving the popliteal lymph node. Source: Dr. Hermann Baum (1918). (This work is in the public domain).

FIGURE 35: LYMPH VESSELS OF THE CARPAL JOINT AND TOE JOINTS OF THE DOG'S FORELIMB

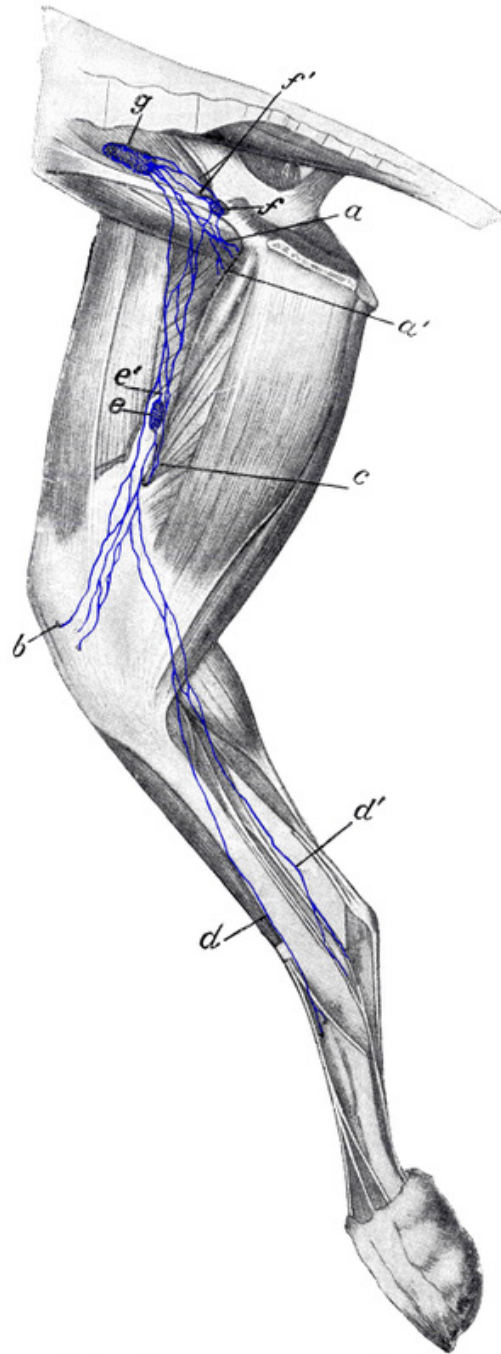


Figure 35: *1, 1* lymph vessels of carpal joint running to the superficial cervical lymph nodes; *1', 1'* lymph vessels of the carpal joint running deep, i.e. in the space between the radius and ulna; *2* lymph vessel joining the cephalic vein and ascending to a superficial cervical lymph node, which is further shown in Figure 33. *3* lymph vessels of a metacarpophalangeal joint, *4* lymph vessels of a proximal interphalangeal joint; *5* lymph vessels of a distal interphalangeal joint; *6* lymph vessel from the joint between metacarpus 1 and the corresponding toe. Source: Dr. Hermann Baum (1918). (This work is in the public domain).

FIGURE 36: LYMPH VESSELS OF THE JOINTS OF THE FORELIMB OF THE DOG (MEDIAL SIDE)

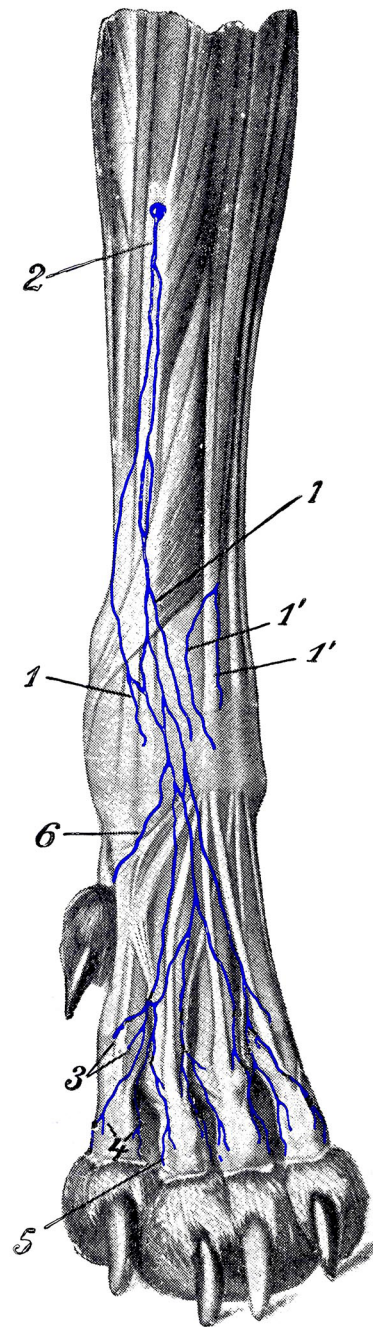


Figure 36: *a* lymph vessels from the elbow joint; *b*, *b'*, *b''* lymph vessels from the carpal joint (*b''* emerges from under the *M. pronator quadratus*); *c*, *c'* lymph vessels of the shoulder joint (the one labeled *c'* comes from the lateral side of the shoulder joint); *d* axillary lymph node. *1* *M. subscapularis*; *2* *M. teres major*; *3* *M. coracobrachialis*; *4* *M. biceps*; *5* *M. extensor carpi radialis*; *6* *M. pronator quadratus*; *7*, *7'* *M. flexor carpi radialis* (a piece is cut out); *8* *M. flexor digitalis sublimis*. Source: Dr. Hermann Baum (1918). (This work is in the public domain).

FIGURE 37: LYMPH VESSELS OF THE HIP, STIFLE, AND TARSAL JOINTS OF THE DOG

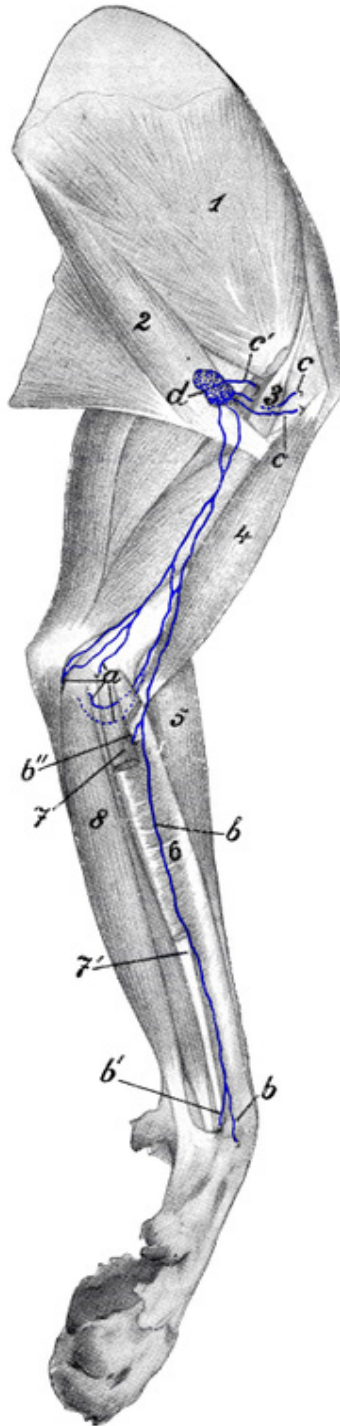


Figure 37: *a, a'* lymph vessels from the hip joint; *b* lymph vessels of stifle joint emerging from its medial side; *c* lymph vessels from lateral and caudal sides of stifle joint and efferent vessels of popliteal lymph node; *d, d'* lymph vessels of the tarsal joint emerging from its medial side; *e* medial femoral lymph node; *e'* its efferent vessel; *f* deep inguinal lymph node; *f'* its efferent vessels; *g* medial iliac lymph node. Source: Dr. Hermann Baum (1918). (This work is in the public domain).

FIGURE 38: LYMPH VESSELS OF THE TESTIS

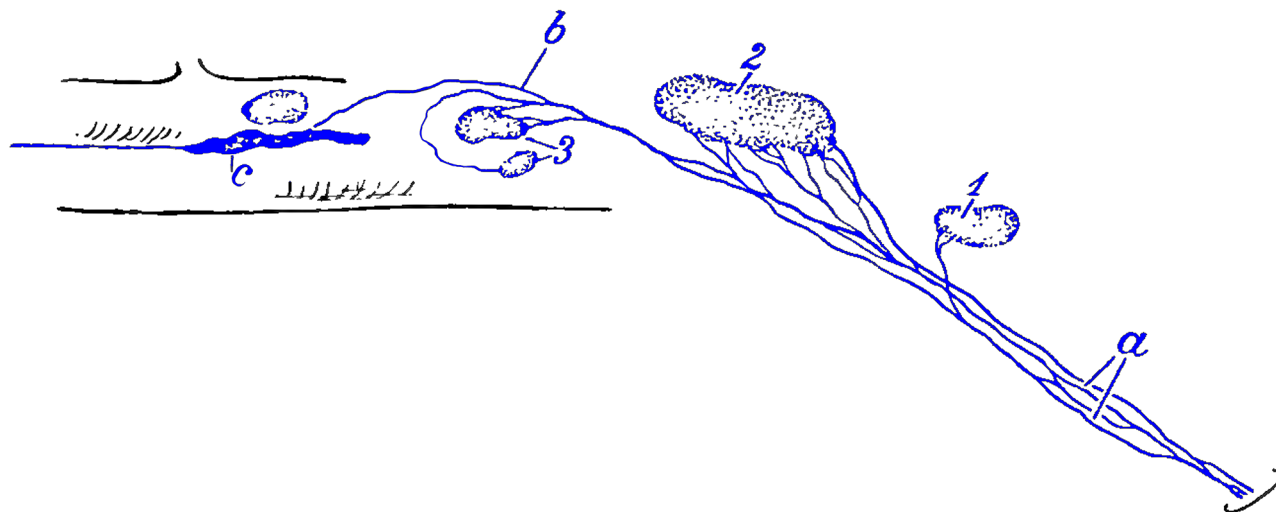


Figure 38: *a* lymph vessels of the testis emerging from the inguinal canal; *b* lymph vessels of the testis opening directly into the *cisterna chyli* *c*; *1* hypogastric lymph node; *2* medial iliac lymph node; *3* lumbar aortic lymph nodes. Source: Baum, Hermann, Können Lymphgefäße direkt in das Venensystem einmünden? *Anat Anzeiger*. 49. Bd. No 15. 1916. S. 407—414. (This work is in the public domain).

BIBLIOGRAPHY

1. Bartels, Das Lymphgefäßsystem (des Menschen), im Handb. d. Anat. d. Menschen von Bardeleben. Jena 1909. III. Bd. 4. Abt.
2. Bartels, Ueber die Lymphgefäße des Pancreas. Arch. f. Anat. u. Physiol. 1904. Anat. Abt. S. 229, und ebenda 1906. S. 250.
3. Baum, Die Lymphgefäße der Muskeln und Sehnenscheiden der Schultergliedmasse des Rindes. Anat. Hefte. 1911. Heft 134. (44 Bd.)
4. Baum. Die Lymphgefäße der Milz des Rindes. Ztschr. f. Infektionskrankheiten, parasit. Krankh. u. Hyg. d. Haustiere. 1911. 10. Bd. 6. Heft.
5. Baum, Die Lymphgefäße des Nervensystems des Rindes. Ztschr. f. Infektionskrankheiten, parasit. Krankh. u. Hyg. d. Haustiere. 1912. 12. Bd. 5. Heft.
6. Baum, Das Lymphgefäßsystem des Rindes. Berlin 1912.
7. Baum, Die Lymphgefäße der Leber des Hundes. Ztschr. f. Fleisch- u. Milchhyg. 1916. 26. Jahrg. Heft 15.
8. Baum, Können Lymphgefäße direkt in das Venensystem einmünden? Anat. Anzeiger. 1916. 49. Bd.
9. Baum, Die Lymphgefäße der Gelenke der Schulter und Beckengliedmasse des Hundes. Anat. Anz. 1916. 49. Bd.
10. Baum, Die Lymphgefäße der Haut des Hundes. Anat. Anzeiger. 1917. 50. Bd.
11. Baum, Die Lymphgefäße der Skelettmuskeln des Hundes, ihrer Sehnen und Sehnenscheiden. Bericht über d. Königl. Tierärztl. Hochschule in Dresden f. d. Jahr 1917.
12. Baum, Die im injizierten Zustande makroskopisch erkennbaren Lymphgefäße der Skelettknochen des Hundes. Anat. Anzeiger. 1918. Bd. 50.
13. Baum, Lassen sich aus dem anatomischen Verhalten des Lymphgefäßsystems einer Tierart Schlüsse auf dasjenige anderer Tierarten ziehen? Unterschiede im Lymphgefäßsystem zwischen Rind und Hund. Anat. Anzeiger. 1918. 51. Bd.
14. Bucher, Topographische Anatomie der Brusthöhlenorgane des Hundes mit besonderer Berücksichtigung der tierärztlichen Praxis. Diss. Dresden 1909.
15. Chauveau-Arloing, Traité d'Anatomie Comparée des Animaux Domestiques. 5. Aufl. von Lesbre. Paris 1903.
16. Dybkowsky, Ueber Anfsaugung und Absonderung der Pleurawand. Berichte d. Sächs. Gesellschaft d. Wissensch. 1866.
17. Ellenberger und Baum, Handbuch der Vergleich. Anat. d. Haustiere. Berlin 1915. 14. Aufl.
18. Dieselben, Anatomie des Hundes. Berlin 1891.
19. Franke, Ueber die Beziehung der Gallenblasenlymphgefäße zum Pankreas. Deutsche Zeitschr. f. Chirurgie. 1911. III. Bd.
20. Gurlt, Anatomische Abbildungen der Haussäugetiere. 1829.

21. Huber, Der Ductus thoracicus vom Pferd, Rind, Hund und Schwein. Dissertation. Dresden 1909.
22. Kumita, Lymphgefäße der Nieren- und Nebennierenkapsel. Arch. f. Anat. und Entwicklungsgeschichte. Anat. Abt. 1909.
23. Martin. Lehrbuch der Anatomie der Haustiere. Stuttgart 1912-1915.
24. Merzdorf, Untersuchungen über das makroskopisch-anatomische Verhalten der Lymphknoten des Hundes und über den Einfluss des Lebensalters auf das relative Gewicht der Lymphknoten. Dissertation. Leipzig 1911.
25. Sappey, Traité d'anatomie descriptive. Available online. Last accessed November 15, 2021.
26. Schweitzer. Lymphgefäße des Zahnfleisches und der Zähne. Arch. für mikroskop. Anat. und Entwicklungsgeschichte. 1909. Bd. 74.
27. Stahr, Bemerkungen über die Verbindungen der Lymphgefäße der Prostata mit denen der Blase. 1899. Anat. Anzeiger. Bd. 16.
28. Walker, Ueber die Lymphgefäße der Prostata beim Hunde. Arch. f. Anat. u. Entwicklungsgeschichte. 1899. Anat. Abt.