

UC Irvine

Clinical Practice and Cases in Emergency Medicine

Title

CPC-EM Full-Text Issue

Permalink

<https://escholarship.org/uc/item/40q2h3r0>

Journal

Clinical Practice and Cases in Emergency Medicine, 2(1)

ISSN

2474-252X

Author

Hernandez, Nancy G.

Publication Date

2018

License

<https://creativecommons.org/licenses/by/4.0/> 4.0

Peer reviewed

CPC Emergency Medicine

Volume II, Number 1, February 2018

Open Access at www.cpcem.org

ISSN: 2474-252X

Clinical Practice and Cases in Emergency Medicine

In Collaboration with the *Western Journal of Emergency Medicine*

Clinicopathological Cases from the University of Maryland

- 1 **54-Year-Old Female with a Syncopal Episode**
N Camino-Fiallos, WW Chang, LJ Bontempo, Z DW Dezman

Case Reports

- 7 **Submassive Central Saddle and Extensive Bilateral Pulmonary Embolism Presenting as Syncope Treated with Catheter-directed Therapy**
J Andrusaitis, M Helmy, CE McCoy, W Hoonpongsimanont, B Chakravarthy, S Lotfipour
- 12 **Double Trouble: Massive Unruptured Aortic Aneurysms**
ML Gagne, R Malhotra, J Zito, A Schwartz, S Sattler
- 16 **Endophthalmitis and Mycotic Aneurysm: The Only Clues to Underlying Endocarditis**
G Carmelli, T Surlles, A Brown
- 21 **The “Black-and-White Cookie” Sign – A Case Series of a Novel Ultrasonographic Sign in Gastric Outlet Obstruction**
A Cohen, M Foster, B Stankard, M Owusu, M Nelson
- 26 **Asymptomatic Hypotension in a Patient with Catheter-related Right Atrial Thrombus**
HE Davis, M Lu, SJ Cameron, R Bodkin
- 31 **Adhesive Closed-loop Small Bowel Obstruction**
MK Edwards, CS Kuppler, CA Croft, HM Easton-Bates
- 35 **Gastric Outlet Obstruction Caused by Foley Catheter: A Complication when Substituting for Commercial Gastrostomy Tubes**
S Vu, AB Lewis, B Moore
- 39 **Novel Use of Ophthalmic pH Paper to Diagnose Malicious Caustic Ingestion in a Pediatric Patient**
NP Johnson, EC Bruno

Contents continued on page iii



UC Irvine Health



— ACOEP's —
SPRING
SEMINAR

2018



ACOEP's Spring Seminar
Heads West!

April 3- April 7, 2018

Loews Coronado Bay • San Diego, CA

Visit acoep.org/spring for more information and to register.



CALL FOR SECTION EDITORS!



- Behavioral Emergencies
- Cardiac Care
- Injury Prevention
- Pediatric Emergencies
- Public Health

Send your CV and letter of interest
to editor@westjem.org

Clinical Practice and Cases in Emergency Medicine

In Collaboration with the *Western Journal of Emergency Medicine*

Rick A. McPheeters, DO, Editor-in-Chief
Kern Medical

Manish Amin, DO, Associate Editor
Kern Medical

Mark I. Langdorf, MD, MHPE, Associate Editor
University of California, Irvine School of Medicine

Shadi Lahham, MD, MS, Associate Editor
University of California, Irvine School of Medicine

Shahram Lotfipour, MD, MPH, Managing Associate Editor
University of California, Irvine School of Medicine

Editorial Board

Erik D. Barton, MD, MBA
Icahn School of Medicine, Mount Sinai, New York

Peter A. Bell, DO, MBA
*Liberty University
College of Osteopathic Medicine*

Barry E. Brenner, MD, MPH
Case Western Reserve University

David F.M. Brown, MD
*Massachusetts General Hospital/
Harvard Medical School*

Francis Counselman, MD
Eastern Virginia Medical School

Robert W. Derlet, MD
University of California, Davis

Daniel J. Dire, MD
*University of Texas Health Sciences
Center San Antonio*

Steven Gabaeff, MD
Clinical Forensic Medicine

Brent King, MD, MMM
University of Texas, Houston

Edward Michelson, MD
Texas Tech University

Linda S. Murphy, MLIS
*University of California, Irvine School
of Medicine Librarian*

Jonathan Olshaker, MD
Boston University

Edward Panacek, MD, MPH
University of South Alabama

Niels K. Rathlev, MD
Tufts University School of Medicine

Robert M. Rodriguez, MD
*University of California, San
Francisco*

Scott Rudkin, MD, MBA
University of California, Irvine

Peter Sokolove, MD
*University of California, San
Francisco*

Samuel J. Stratton, MD, MPH
Orange County, CA, EMS Agency

Robert Suter, DO, MHA
UT Southwestern Medical Center

Scott Zeller, MD
University of California, Riverside

Leslie Zun, MD, MBA
Chicago Medical School

Advisory Board

Peter A. Bell, DO, MBA
*American College of Osteopathic
Emergency Physicians
Liberty University
College of Osteopathic Medicine*

John B. Christensen, MD
California Chapter Division of AAEM

Amal Khalil, MBA
UC Irvine Health SOM

Mark I. Langdorf, MD, MHPE
UC Irvine Health SOM

Elena Lopez-Gusman
*California ACEP
American College of Emergency
Physicians*

Shahram Lotfipour, MD, MPH
UC Irvine Health SOM

Trevor Mills, MD, MPH
*California Chapter Division of AAEM
LSU Medical Center*

Aimee Moulin, MD
*California ACEP
American College of Emergency
Physicians
University of California, Davis*

Nicholas T. Sawyer, MD, MBA
*California ACEP
American College of Emergency
Physicians
University of California, Davis*

Robert Suter, DO, MHA
*American College of Osteopathic
Emergency Physicians
UT Southwestern Medical Center*

Janice Wachtler, BAE, CBA
*American College of Osteopathic
Emergency Physicians*

International Editorial Board

Pablo Aguilera Fuenzalida, MD
*Pontificia Universidad Catolica de
Chile, Región Metropolitana, Chile*

Anwar Al-Awadhi, MD
*Mubarak Al-Kabeer Hospital,
Jabriya, Kuwait*

Arif A. Cevik, MD
*United Arab Emirates University
College of Medicine and Health
Sciences, Al Ain, United Arab Emirates*

Francesco Dellacorte, MD
*Azienda Ospedaliera Universitaria
"Maggiore della Carità," Novara,
Italy*

Abhinandan A. Desai, MD
*University of Bombay Grant Medical
College, Bombay, India*

Gayle Galleta, MD
*Sorlandet Sykehus HF, Akershus
Universitetssykehus, Lorenskog,
Norway*

Vijay Gautam, MBBS
University of London, London, England

Wirachin Hoonpongsimanont, MD,
MSBATS
*Siriraj Hospital, Mahidol University,
Bangkok, Thailand*

Rosidah Ibrahim, MD
*Hospital Serdang, Selangor,
Malaysia*

Katsuhiko Kanemaru, MD
*University of Miyazaki Hospital,
Miyazaki, Japan*

Amin A. Kazzi, MD, MAAEM
*The American University of Beirut,
Beirut, Lebanon*

Terry Mulligan, DO, MPH, FIFEM
*ACEP Ambassador to the
Netherlands Society of Emergency
Physicians*

Steven H. Lim, MD
*Changi General Hospital, Simei,
Singapore*

Khrongwong Musikatavorn, MD
*King Chulalongkorn Memorial
Hospital, Chulalongkorn University,
Bangkok, Thailand*

Bandr Mzahim, MD
*King Fahad Medical City, Riyadh,
Saudi Arabia*

Jacob (Kobi) Peleg, PhD, MPH
Tel-Aviv University, Tel-Aviv, Israel

Nadeem Qureshi, MD
*St. Louis University, USA
Emirates Society of Emergency
Medicine, United Arab Emirates*

Editorial Staff

Ahdilah Haswary, BS
Editorial Director

Jimmy To, BS
Associate Editorial Director

Tushank Chadha, BS
Marketing Director

Nancy G. Hernandez, BA
Publishing Director

Tracy Nguyen, BS
Associate Publishing Director

June Casey, BA
Copy Editor

Alissa Fiorentino, BA
WestJEM Staff Liaison

Clinical Practice and Cases in Emergency Medicine

In Collaboration with the *Western Journal of Emergency Medicine*

This open access publication would not be possible without the generous and continual financial support of our society sponsors, department and chapter subscribers.

Professional Society Sponsors

AMERICAN COLLEGE OF OSTEOPATHIC EMERGENCY PHYSICIANS

CALIFORNIA ACEP

CALIFORNIA CHAPTER DIVISION OF

AMERICAN ACADEMY OF EMERGENCY MEDICINE

Academic Department of Emergency Medicine Subscriber

Albany Medical College Albany, NY	Kaweah Delta Health Care District Visalia, CA	Rush University Medical Center Chicago, IL	University of Illinois at Chicago Chicago, IL
American University of Beirut Beirut, Lebanon	Kennedy University Hospitals Turnersville, NJ	Southern Illinois University Carbondale, IL	University of Illinois College of Medicine, Peoria Peoria, IL
Arrowhead Regional Medical Center Colton, CA	Kern Medical Bakersfield, CA	St. Luke's University Health Network Bethlehem, PA	University of Iowa Iowa City, IA
Augusta University, Augusta GA	Lakeland HealthCare St. Joseph, MI	Stanford/Kaiser Emergency Medicine Residency Program Stanford, CA	University of Louisville Louisville, KY
Baystate Medical Center Springfield, MA	Lehigh Valley Hospital and Health Network Allentown, PA	Staten Island University Hospital, Staten Island, NY	University of Maryland Baltimore, MD
Beaumont Hospital Royal Oak, MI	Loma Linda University Medical Center Loma Linda, CA	SUNY Upstate Medical University, Syracuse, NY	University of Michigan Ann Arbor, MI
Beth Israel Deaconess Medical Center Boston, MA	Louisiana State University Health Sciences Center New Orleans, LA	Temple University Philadelphia, PA	University of Missouri, Columbia Columbia, MO
Boston Medical Center Boston, MA	Madigan Army Medical Center Tacoma, WA	Texas Tech University Health Sciences Center El Paso El Paso, TX	University of Nebraska Medical Center Omaha, NE
Brigham and Women's Hospital Boston, MA	Maimonides Medical Center Brooklyn, NY	University of Alabama, Birmingham Birmingham, AL	University of South Alabama Mobile, AL
Brown University Providence, RI	Maricopa Medical Center Phoenix, AZ	University of Arkansas for Medical Sciences Little Rock, AR	University of Southern California/Keck School of Medicine Los Angeles, CA
Carl R. Darnall Army Medical Center Fort Hood, TX	Massachusetts General Hospital Boston, MA	University of California, Davis Medical Center Sacramento, CA	University of Tennessee, Memphis Memphis, TN
Conemaugh Memorial Medical Center Johnstown, PA	Mayo Clinic College of Medicine Rochester, MN	University of California Irvine Orange, CA	University of Texas, Houston Houston, TX
Desert Regional Medical Center Palm Springs, CA	Mt. Sinai Medical Center Miami Beach, FL	University of California, Los Angeles Los Angeles, CA	University of Texas Health San Antonio, TX
Doctors Hospital/Ohio Health Columbus, OH	North Shore University Hospital Manhasset, NY	University of California, San Diego La Jolla, CA	University of Warwick Library Coventry, United Kingdom
Eastern Virginia Medical School Norfolk, VA	Northwestern Medical Group Chicago, IL	University of California, San Francisco San Francisco, CA	University of Washington Seattle, WA
Einstein Healthcare Network Philadelphia, PA	Ohio State University Medical Center Columbus, OH	UCSF Fresno Center Fresno, CA	University of Wisconsin Hospitals and Clinics Madison, WI
Emory University Atlanta, GA	Ohio Valley Medical Center Wheeling, WV	University of Chicago, Chicago, IL	Wake Forest University Winston-Salem, NC
Hartford Hospital Hartford, CT	Oregon Health and Science University Portland, OR	University of Colorado, Denver Denver, CO	Wright State University Dayton, OH
Hennepin County Medical Center Minneapolis, MN	Penn State Milton S. Hershey Medical Center Hershey, PA	University of Florida Gainesville, FL	
Henry Ford Hospital Detroit, MI	Presence Resurrection Medical Center Chicago, IL	University of Florida, Jacksonville Jacksonville, FL	
INTEGRIS Health Oklahoma City, OK	Robert Wood Johnson University Hospital New Brunswick, NJ		

State Chapter Subscriber

ARIZONA CHAPTER DIVISION OF THE
AMERICAN ACADEMY OF EMERGENCY MEDICINE

CALIFORNIA CHAPTER DIVISION OF THE
AMERICAN ACADEMY OF EMERGENCY MEDICINE

FLORIDA CHAPTER DIVISION OF THE
AMERICAN ACADEMY OF EMERGENCY MEDICINE

GREAT LAKES CHAPTER DIVISION OF THE
AMERICAN ACADEMY OF EMERGENCY MEDICINE

TENNESSEE CHAPTER DIVISION OF THE
AMERICAN ACADEMY OF EMERGENCY MEDICINE

UNIFORMED SERVICES CHAPTER DIVISION OF THE
AMERICAN ACADEMY OF EMERGENCY MEDICINE

VIRGINIA CHAPTER DIVISION OF THE
AMERICAN ACADEMY OF EMERGENCY MEDICINE

International Society Partners

SOCIEDAD ARGENTINA DE EMERGENCIAS
SOCIEDAD CHILENO MEDICINA URGENCIA
MEDITERRANEAN SOCIETY OF EMERGENCY MEDICINE

THAI ASSOCIATION FOR EMERGENCY MEDICINE
EMERGENCY MEDICINE ASSOCIATION OF TURKEY

NORWEGIAN SOCIETY FOR EMERGENCY MEDICINE
LEBANESE ACADEMY OF EMERGENCY MEDICINE

To become a *WestJEM* departmental sponsor, waive article processing fee, receive print and copies for all faculty and electronic for faculty/residents, and free CME and faculty/fellow position advertisement space, please go to <http://westjem.com/subscribe> or contact:

Alissa Fiorentino
WestJEM Staff Liaison
Phone: 1-800-884-2236
Email: sales@westjem.org

Clinical Practice and Cases in Emergency Medicine

In Collaboration with the *Western Journal of Emergency Medicine*

JOURNAL FOCUS

Clinical Practice and Cases in Emergency Medicine (CPC-EM) is an internationally recognized journal affiliated with the MEDLINE-indexed *Western Journal of Emergency Medicine* (WestJEM). It will offer the latest in patient care case reports, images in the field of emergency medicine and state of the art clinicopathological cases. CPC-EM is fully open-access, peer reviewed, well indexed and available anywhere with an internet connection. CPC-EM encourages submissions from junior authors, established faculty, and residents of established and developing emergency medicine programs throughout the world.

Table of Contents *continued*

- 43 **Isolated Dissection of the Superior Mesenteric Artery**
S Barnes, B Kushner
- 47 **Sodium-glucose Cotransporter-2 Induced Diabetic Ketoacidosis with Minimal Hyperglycemia**
DT Gammons, FL Counselman
- 51 **Consumption Junction: A Case of Peritoneal Tuberculosis-induced Small Bowel Obstruction**
M Poppe, K Peng, D Arnold
- 55 **Urinary Catheterization in Infants: When It's Knot so Simple**
DC Sheridan, B Burns, M Mickley
- 58 **Exaggerated Arthropod Bite: A Case Report and Review of the Mimics**
S Ahmed, E Bromberek, J Borhart
- 61 **A Walk in the Park: A Case of Babesiosis in the South Bronx**
C Hajicharalambous, M Rattu, S Leuchten
- 64 **Traumatic Fetal Intracranial Hemorrhage Suggested by Point-of-Care Ultrasound**
NC Mooney, L Wu, ME Vrablik
- 67 **Central Venous Catheter-directed Tissue Plasminogen Activator in Massive Pulmonary Embolism**
V Gulati, J Brazg
- 71 **Intraosseous Vascular Access Device as a Transarticular K-wire Alternative in Mallet Finger Laceration**
SB Crawford
- 75 **A New Diagnosis of a Genetic Disorder in a Patient Presenting with Bilateral Upper Extremity Neuropathy**
TM Ruttenberg, AD Miller
- 78 **Lemierre Syndrome as a Complication of Laryngeal Carcinoma**
C Colbert, M McCormack, W Eilbert, L Bull
- 82 **What's the Mass? The Gist of Point-of-care Ultrasound in Gastrointestinal Stromal Tumors**
KP Chan

Policies for peer review, author instructions, conflicts of interest and human and animal subjects protections can be found online at www.cpcem.org.

Clinical Practice and Cases in Emergency Medicine

In Collaboration with the *Western Journal of Emergency Medicine*

Table of Contents *continued*

Images in Emergency Medicine

- 86 **Adult Male with Leg Swelling after a Fall Two Weeks Prior**
W Hoonpongimanont, AS A Akeel, PK Sahota, S Lahham, MA Helmy, S Lottipour
- 89 **A Cloudy Conical Cornea**
K Biggs, S Stuart
- 91 **Recurrent Cellulitis in a Patient with Papillomatosis Cutis Lymphostatica**
S Pak, JP Markovic, Y Yatsynovich, E Tope, D Valencia
- 93 **Oculomotor Nerve Palsy Secondary to Cavernous Internal Carotid Aneurysm**
G Lai, MI Rodriguez, AJ Scumpia
- 95 **Pseudo-Subarachnoid Hemorrhage after Cardiac Arrest**
KE Schreyer, K Surapaneni, M Sammon
- 97 **Child with Testicular Pain**
N Otts, RL Webb, J Greenstein, B Hahn
- 99 **Point-of-care Ultrasound for the Diagnosis of a “Ping Pong” Skull Fracture**
AS Bloom, J Auten, JM Schofer
- 101 **Acute Cardiac Air Embolism**
LA Bilello, BQ Gacioch, JP Phillips

VITAL STATISTICS

Clinical Practice and Cases in Emergency Medicine (CPC-EM) is an internationally recognized journal affiliated with the MEDLINE-indexed *Western Journal of Emergency Medicine* (WestJEM). CPC-EM is distributed electronically to 23,278 emergency medicine scholars. This includes our sponsors: California ACEP, the American College of Osteopathic Emergency Physicians, California Chapter of AAEM, and over 81 academic department of emergency medicine subscribers as well as eight AAEM State Chapters.

Official Journal of the California Chapter of the American College of Emergency Physicians, the America College of Osteopathic Emergency Physicians, and the California Chapter of the American Academy of Emergency Medicine



Available in Google Scholar.

Editorial and Publishing Office: CPCEM/Department of Emergency Medicine, UC Irvine Health, 333 City Blvd, West, Rt 128-01, Orange, CA 92868, USA

Office: 1-714-456-6389; Email: Editor@cpcem.org

54-Year-Old Female with a Syncopal Episode

Nicole Cimino-Fiallos, MD*

*University of Maryland Medical Center, Baltimore, Maryland

Wan-Tsu W. Chang, MD†

†University of Maryland School of Medicine, Department of Medicine, Baltimore, Maryland

Laura J. Bontempo, MD, MEd†

Zachary D.W. Dezman, MD, MS, MS†

Section Editor: Rick A. McPheeters, DO

Submission history: Submitted November 20, 2017; Revision received December 19, 2018; Accepted January 19, 2018

Electronically published January 29, 2018

Full text available through open access at http://escholarship.org/uc/uciem_cpccem

DOI: 10.5811/cpccem.2018.1.37086

[Clin Pract Cases Emerg Med. 2018;2(1):1–6.]

Case Presentation (Dr. X)

A 54-year-old woman presented to the emergency department (ED) with a complaint of syncope. The patient was unable to offer any history, so all information was obtained from her friend, paramedics, and past records. Her friend, who accompanied the patient to the ED, reported that the patient had been “feeling unwell,” vomited twice, and then went to bed earlier that day. A few hours later, the friend heard a loud thud and subsequently found the patient unresponsive on the floor. When paramedics arrived at the scene, the patient was unresponsive. They gave her 50 gm of dextrose intravenously because her capillary blood glucose was 17 mg/dL. She regained consciousness, but continued to be altered during her transport to the ED.

Her past medical and surgical histories included hypothyroidism, anemia and a Cesarean section 17-years prior, complicated by postpartum hemorrhage. Her friend was adamant that the patient has no history of diabetes mellitus (DM). Her only known medication was levothyroxine (dose unknown). She had no known drug allergies and her last known menstrual period was before the birth of her son.

The patient works as a custodian and lives with her son, a recent high school graduate. The patient’s friend stated that the patient does not smoke, drink alcohol, or use recreational drugs. The friend stated that the patient had not had any recent injuries, headaches, illnesses, or sick contacts. A complete review of systems could not be obtained due to the patient’s altered mental status.

Physical examination revealed a well-developed, thin woman resting on a stretcher. She had a temperature of 98.5° Fahrenheit with a heart rate of 60 beats per minute, and a blood pressure of 146/82 mmHg. She was breathing 16 breaths per minute with an oxygen saturation of 100% on room air. Her body mass index was 18.5kg per meter squared. Examination of the head, eyes, ears, nose and throat showed that the patient was normocephalic and atraumatic, without evidence of intraoral or external

trauma. Pupils were three mm, equal, round and reactive to light. Lungs were clear to auscultation with equal breath sounds bilaterally. Cardiac exam revealed a regular rate and rhythm, without murmurs, rubs, or gallops. The patient’s abdomen was soft with normal bowel sounds and without distention, tenderness, rebound, guarding, or organomegaly. The extremities did not have any edema or evidence of trauma. There were 2+ pulses throughout all the extremities and all were warm, well perfused and without evidence of tenderness to palpation. Neurological exam revealed an awake patient oriented only to self and able to follow simple commands. The patient was unable to participate in detailed cranial nerve testing. Genital exam showed normal female genitals with pubic alopecia. Her skin was warm and dry. Cranial hair was thin.

Laboratory results are shown in table. Her electrocardiogram (ECG) is shown in Image 1. A chest radiograph (Image 2) and computed tomography (CT) of her head were obtained. Representative images of the CT are shown in Image 3.

Approximately an hour after arrival to the ED, the patient became unconscious and could not be aroused. Capillary blood glucose was 32 mg/dL. The patient was treated with dextrose 50g intravenously and regained consciousness.

A diagnostic test was then done, which confirmed the patient’s diagnosis.

Case Discussion (Dr. Y)

This is a 54-year-old female who was found unresponsive and hypoglycemic with altered mental status. Patient has a past medical history significant for hypothyroidism, anemia, and prior Cesarean-section with hemorrhage. She does not have a known history of DM thus the cause of her presenting hypoglycemia is unclear at this time. On exam, the patient is alert, able to follow commands, though oriented to person only. She has dry, thin hair consistent with her known history of hypothyroidism.

Table 1. Initial laboratory results of patient presenting with syncope.

Complete blood cell count	Values
White blood cell count	13.1 K/mcl
Hemoglobin	9.7 g/dL
Hematocrit	29.8%
Platelets	196 K/mcl
Complete metabolic panel	
Sodium	128 mmol/L
Potassium	3.8 mmol/L
Chloride	104 mmol/L
Bicarbonate	28 mmol/L
Blood urea nitrogen	14 mg/dL
Creatinine	0.9 mg/dL
Glucose	122 mg/dL
Alanine aminotransferase	32 u/L
Aspartate aminotransferase	8 u/L
Alkaline phosphatase	80 u/L
Total bilirubin	0.7 mg/dL
Total protein	7.6 g/dL
Albumin	4.1 g/dL
Calcium	8.9 mg/dL
Additional laboratory tests	
Free thyroxine	1.18 ng/dL
Thyroid stimulating hormone	0.054 mIU/L
Troponin	<0.02 ng/mL
Urinalysis	
Color	Straw
Ketones	1+
Nitrite	Negative
Glucose	1+
Protein	Negative
Blood	Negative
Leukocyte esterase	Negative
Human chorionic gonadotropin	Negative
Urine drug screen	Negative
Acetaminophen level	<10 mcg/mL
Salicylate level	<3 mg/dL

In reviewing this case, one thing that stood out is the patient's presenting hypoglycemia without a known diagnosis of DM. The patient did not present with any neurogenic symptoms of hypoglycemia such as sweating, shakiness, tachycardia, anxiety, or sensation of hunger. However, she did present with neuroglycopenic symptoms of hypoglycemia such as confusion and unresponsiveness.

The differential diagnosis of hypoglycemia can be categorized into exogenous drugs, increased glucose utilization, decreased glucose delivery, decreased glucose production, increased insulin production, and decreased insulin clearance. In patients with a history of DM, common causes of hypoglycemia are exogenous drugs such as sulfonylureas and insulin, and decreased glucose delivery such as with fasting. It is important to remember that sepsis can increase glucose utilization while renal failure can decrease insulin clearance, both leading to hypoglycemia. Thus, one should consider the full differential diagnosis of hypoglycemia even when dealing with a patient with known DM.

In patients without a history of DM, the etiology of hypoglycemia is more complex. Exogenous drugs including alcohol, beta-blockers, valproic acid, and salicylates can all cause hypoglycemia. Malaria can increase glucose utilization. One needs to consider decreased glucose production in patients with liver disease, Addison's disease, or pituitary insufficiency. There may be increased production of insulin from insulinomas or islet cell hyperplasia. And finally, we also have to be sure that we are not dealing with pseudohypoglycemia in the setting of leukocytosis, thrombocytosis, or erythrocytosis.

This patient's history does not suggest any exogenous drugs as the cause of her hypoglycemia, though we cannot be certain that she does not take salicylates as an over-the-counter analgesic. Her clinical presentation does not suggest sepsis or malaria. She also does not have any stigmata of liver disease on her physical exam. At this time, we are still left with a wide differential.

Her laboratory studies are notable for an anemia consistent with her history. However, she has a low thyroid stimulating hormone (TSH) and free thyroxine level, which is not suggestive of primary hypothyroidism. She also has a hyponatremia of unclear etiology. The remainder of her diagnostic studies including ECG, chest radiograph, and noncontrast head CT are unremarkable.

When we summarize the facts, we have a 54-year-old female with no history of DM, who has persistent hypoglycemia associated with hyponatremia. While she has a history of hypothyroidism her thyroid function studies are not consistent with a primary hypothyroidism, but rather, secondary or central hypothyroidism. When we review the case for any additional clues, we find that her last menstrual period was in 1996, approximately 19 years ago, similar to the age of her son. She has not had a total hysterectomy since the birth of her son, though she did have a Cesarean-section with hemorrhage. Could she have had a postpartum hemorrhage with pituitary infarction leading to amenorrhea?

Supporting evidence for diagnosis of hypopituitarism are the patient's central hypothyroidism, amenorrhea due to inadequate gonadotropin production, and secondary adrenal insufficiency due to inadequate adrenocorticotropic

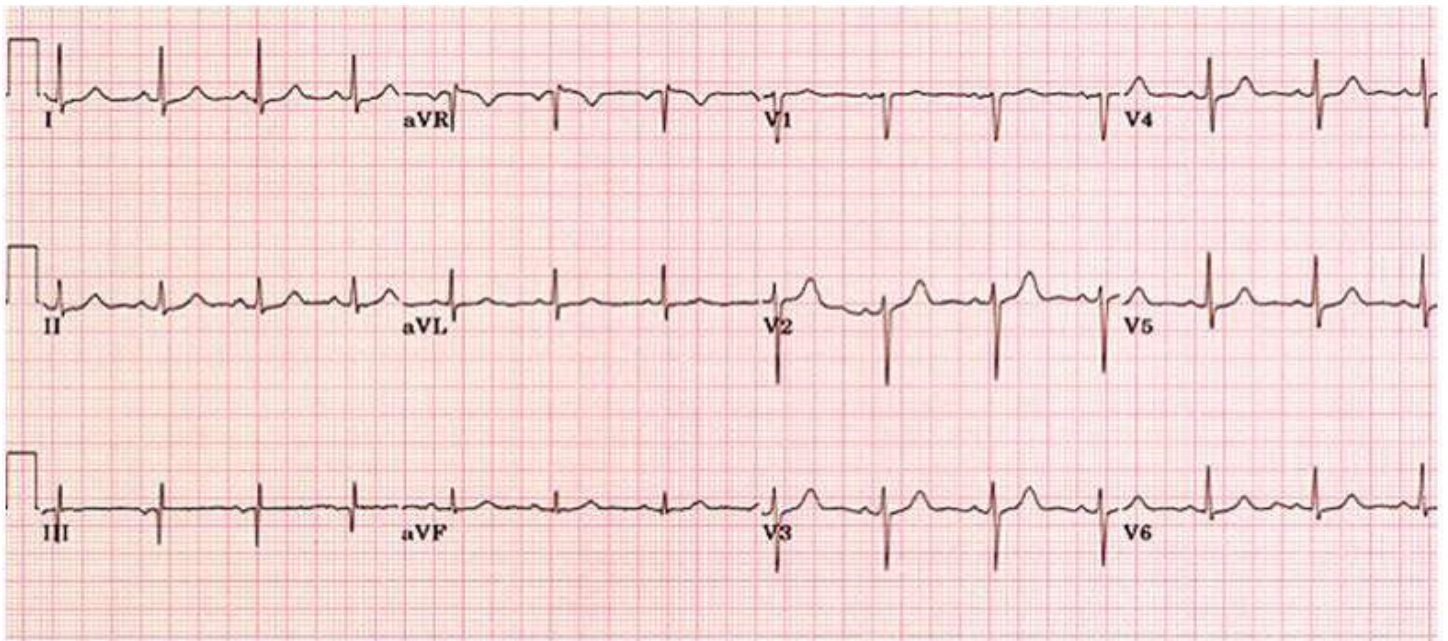


Image 1. Patient's initial electrocardiogram showing a normal sinus rhythm. Obtained while in the emergency department.

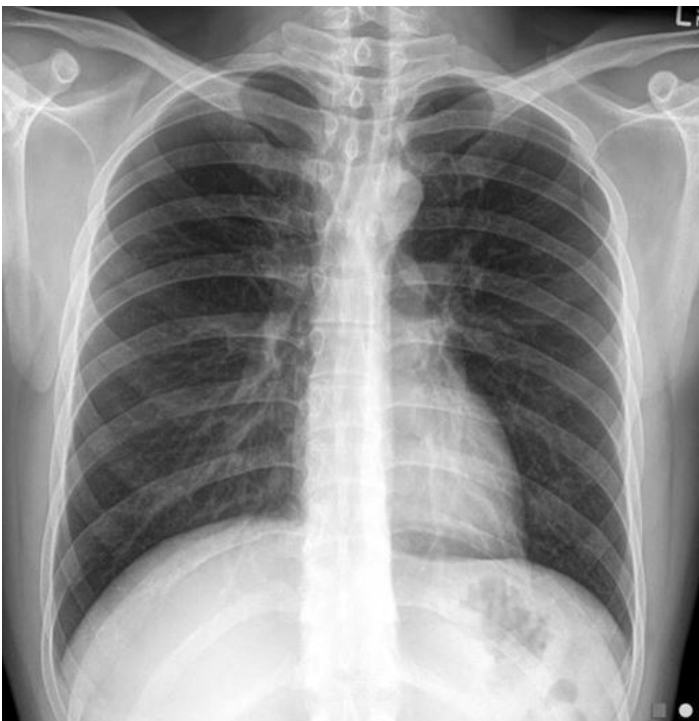

Image 2. Radiograph of the patient's chest while in the emergency department showing no acute disease (posterior-anterior view).

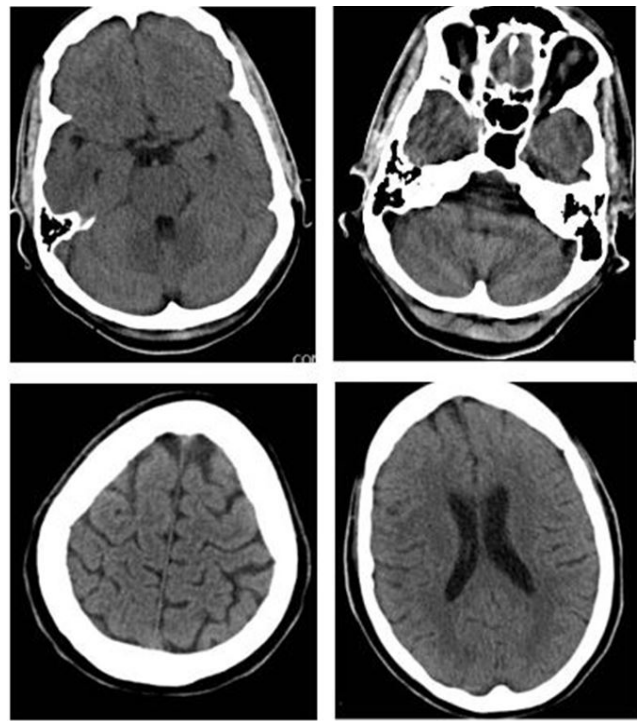


Image 3. Representative images from the patient's computed tomography of the head, showing no acute disease.

hormone production. It is important to note that the patient does not have any hypotension or hyperkalemia, thus suggesting that she has intact mineralocorticoid function. Her glucocorticoid function, however, is affected as evidenced by her hypoglycemia. Her hyponatremia is caused by an inappropriate secretion of antidiuretic hormone due to the lack of negative feedback from cortisol.

The study of choice to make the diagnosis of hypopituitarism relating to pituitary infarction would be magnetic resonance imaging (MRI) of the brain to demonstrate an empty sella. If the patient were to have developed symptoms of hypopituitarism early after her postpartum hemorrhage, an MRI can demonstrate an enlarged pituitary with peripheral enhancement. Work-up of her endocrinopathies are important to evaluate the extent of her hypopituitarism and to direct treatment.

Case Outcome (Dr. X)

A brain MRI was performed, which revealed an empty sella turcica (Image 4). The patient was diagnosed with Sheehan's syndrome (postpartum hypopituitarism) and was admitted to the hospital for further evaluation and treatment. She was treated with steroids due to her adrenal insufficiency and her levothyroxine dosage was adjusted. She was discharged from the hospital with endocrinology follow-up and was back at work within two weeks.

After a massive postpartum hemorrhage, the pituitary gland can infarct resulting in complete or partial hypopituitarism and subsequent endocrinopathies. The size of the infarction directly correlates to the extent of the syndrome, which was identified by Dr. Harold Sheehan in 1937. There are several theories as to why

the syndrome occurs.¹ The pituitary grows in response to constant high levels of estrogen during pregnancy (lactotroph hyperplasia). Because the pituitary resides in an enclosed space, this growth causes increased intrasellar pressure. The location of the pituitary gland's blood supply also makes the gland vulnerable to ischemia. Another possible explanation is that the gland undergoes a massive thrombosis from either the hypercoagulability of pregnancy or arterial vasospasm from bleeding during delivery.² Some patients may form anti-pituitary autoantibodies.³

Epidemiology

This syndrome mostly occurs in developing countries. Patients in those countries have less access to obstetrical care and are more likely to have massive hemorrhage during delivery.² Similarly, the group of patients in the United States who most often have Sheehan's syndrome are those who deliver outside of a medical setting. As a part of their prenatal care, obstetricians are able to anticipate which patients are at high risk for bleeding based on placental location, past history, coagulation status, etc. Obstetricians can also help to limit the amount of bleeding that occurs during delivery while aggressively transfusing the patient when bleeding occurs.⁴

Presentation

The most common presenting symptom of Sheehan's syndrome is the failure to menstruate or lactate after delivery. Other symptoms of this syndrome include axillary and pubic hair loss, fatigue, cold intolerance, weakness, breast atrophy, decreased libido, adrenal insufficiency, diabetes insipidus and possibly osteoporosis.⁵ A patient's symptoms can vary

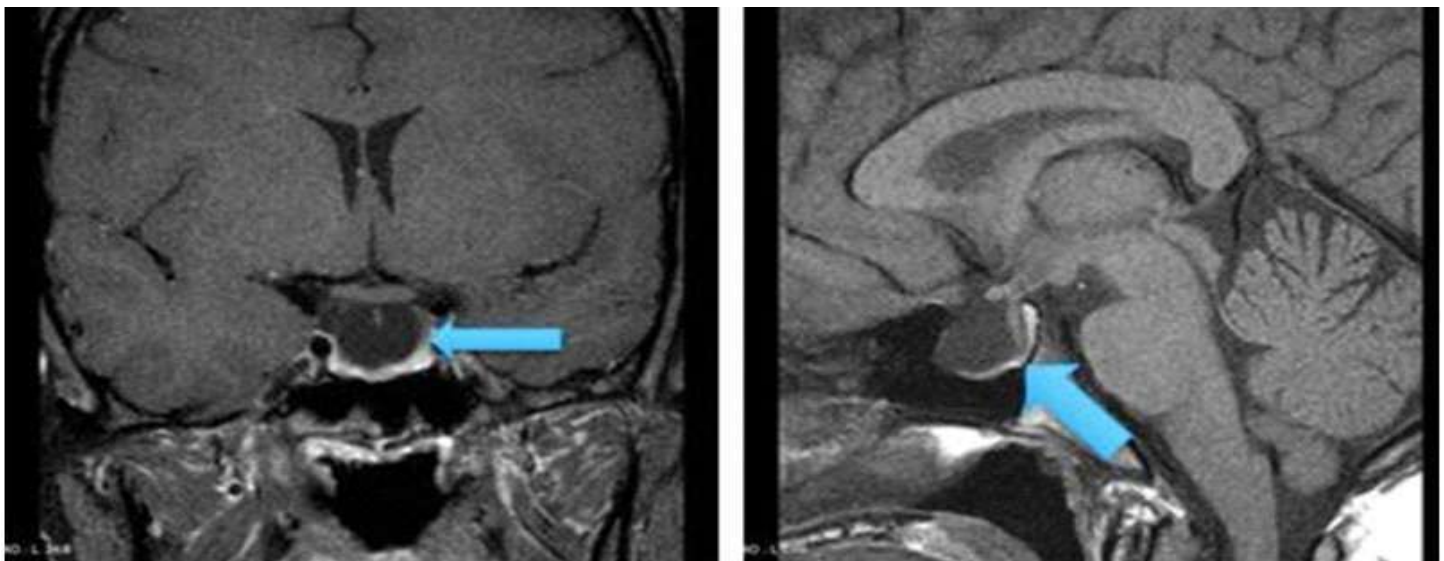


Image 4. Magnetic resonance imaging of the patient's brain, showing an empty sella turcica (blue arrows) in coronal (left) and sagittal views (right).

due to the extent of pituitary necrosis and the specific areas of the pituitary that are necrosed^{6,7}. There are case reports of patients not being diagnosed until several decades after the birth of their last child^{6,7}. Many women can be asymptomatic until a stressor precipitates an endocrinological crisis such as myxedema coma or adrenal insufficiency. The continued production of aldosterone by the adrenal gland can also mask some symptoms of Sheehan's syndrome. Other causes of hypopituitarism include pituitary adenomas, autoimmune or lymphocytic hypophysitis, and congenital causes. The patient in this case had several clues to suggest the diagnosis: her last menstrual period was before the birth of her son, she had a history of hypothyroidism and postpartum hemorrhage, and her exam was suggestive of hypothyroidism. Her testing revealed a low TSH level, hypoglycemia and hyponatremia in the presence of normokalemia, suggesting a glucocorticoid deficiency without a disturbance in the mineralocorticoid pathway.

Adrenal insufficiency is a common presentation of Sheehan's syndrome. The patient will present with recurrent hypoglycemia.^{8,9} As the need for energy increases, the adrenals will not release cortisol as in a normal person. Without cortisol, the liver will not convert glycogen to glucose and the patient will present with hypoglycemia. In addition to hypoglycemia, the patient can also present with hypotension, orthostasis, fatigue, hypopigmentation and sometimes sudden death. The differential diagnosis for causes of adrenal insufficiency should include Addison's disease, pituitary adenoma, Sheehan's syndrome, and infection.

Diagnostic Testing

The patient's thyroid function tests, including serum triiodothyronine, free thyroxine, TSH and cortisol should be checked in the ED. The patient's endocrinologist may choose to test the patient's cortisol, adrenocorticotrophic hormone, follicle stimulating hormone, luteinizing hormone, estradiol and prolactin levels. MRI of the brain is the definitive test. In early disease, the MRI will show an enlarged non-hemorrhagic pituitary gland. In chronic disease, the MRI will show an empty sella turcica, due to gland necrosis and atrophy.

Treatment

The presentation of Sheehan's syndrome is a result of the constellation of endocrinopathies that occur when the pituitary gland is non-functional. The treatment for this disease is to replace the missing hormones. If the patient has adrenal insufficiency, the patient will need steroids, specifically hydrocortisone. There is no need to replace mineralocorticoids as the renin-angiotensin system should be unaffected. If the patient is having recurrent hypoglycemia, she should be started on dextrose containing intravenous fluids. If the patient is awake enough, she

should eat a meal of complex carbohydrates. If the patient presents to the hospital in myxedema coma, she should first be given glucocorticoids to prevent an adrenal crisis and then be treated with levothyroxine.² The patient's primary care doctor may choose to treat with estrogen to prevent osteoporosis. Growth hormone replacement is very expensive and has not been shown to improve outcomes.

Final Diagnosis

Sheehan's syndrome resulting in adrenal crisis.

Take-home Points

- Recurrent hypoglycemic episodes, especially in the context of hyponatremia, should prompt the clinician to consider adrenal insufficiency.
- Immigrants from countries without access to obstetrical care may present with symptoms of Sheehan's syndrome.
- Patients with Sheehan's syndrome can present with emergencies such as adrenal crisis or myxedema coma.
- MRI is the diagnostic test of choice for Sheehan's syndrome and the images in early disease will look different from late disease.
- While Sheehan's syndrome has no cure, the goal is to treat the resulting endocrinopathies.

Address for Correspondence: Zachary D.W. Dezman, MD, MS, University of Maryland, Department of Emergency Medicine, 110 S Paca Street, 6th Floor, Suite 200, Baltimore, MD 21201. Email: zdezman@em.umaryland.edu.

Conflicts of Interest: By the CPC-EM article submission agreement, all authors are required to disclose all affiliations, funding sources and financial or management relationships that could be perceived as potential sources of bias. The authors disclosed none.

Copyright: © 2018 Cimino-Fiallos et al. This is an open access article distributed in accordance with the terms of the Creative Commons Attribution (CC BY 4.0) License. See: <http://creativecommons.org/licenses/by/4.0/>

REFERENCES

1. Schragger S, Sabo L. Sheehan syndrome: a rare complication of postpartum hemorrhage. *J Am Board Fam Pract.* 2001;14(5):389-91.
2. Kilicli F, Dokmetas HS, Acibucu F. Sheehan's syndrome. *Gynecol Endocrinol.* 2013;29(4):292-5.
3. Takasu N, Nakayama Y. A patient with postpartum hypopituitarism (Sheehan's Syndrome) developed postpartum autoimmune thyroiditis (transient thyrotoxicosis and hypothyroidism): a case report and

- review of the literature. *J Thyroid Res.* 2011.
4. Feinberg EC, Molitch ME, Endres LK, et al. The incidence of Sheehan's syndrome after obstetric hemorrhage. *Fertil Steril.* 2005;84(4):975-9.
 5. Dosi RV, Bhatt NR, Patell RD, et al. Recurrent hypoglycemia...: A less well-known presentation of Sheehan's syndrome. *J Postgrad Med.* 2013;59(4):318.
 6. Matsuwaki T, Khan KN, Inoue T, et al.. Evaluation of obstetrical factors related to Sheehan syndrome. *J Obstet Gynaecol Res.* 2014;40(1):46-52.
 7. Kristjansdottir HL, Bodvarsdottir SP, Sigurjonsdottir HA. Sheehan's syndrome in modern times: a nationwide retrospective study in Iceland. *Eur J Endocrinol.* 2011;164(3):349-54.
 8. Bunch TJ, Dunn WF, Basu A, et al. (2002). Hyponatremia and hypoglycemia in acute Sheehan's syndrome. *Gynecol Endocrinol.* 2002;16(5):419-23.
 9. Pahadiya HR, Lakhota M, Gandhi R, et al. Fasting intolerance and recurrent hypoglycemia: Ponder for Sheehan's. *Indian J Endocrinol Metab.* 2016;20(5):739.

Submassive Central Saddle and Extensive Bilateral Pulmonary Embolism Presenting as Syncope Treated with Catheter-directed Therapy

Jessica Andrusaitis, MS*
Mohammad Helmy, MD†
Christopher E. McCoy, MD, MPH‡
Wirachin Hoonpongsimanont, MD, MS‡
Bharath Chakravarthy, MD, MPH‡
Shahram Lotfipour, MD, MPH‡

*University of California, Irvine, School of Medicine, Irvine, California
†University of California, Irvine, Department of Radiological Sciences, Orange, California
‡University of California, Irvine, Department of Emergency Medicine, Orange, California

Section Editor: Rick A. McPheeters, DO
Submission history: Submitted September 15, 2017; Accepted December 13, 2017
Electronically published January 18, 2018
Full text available through open access at http://escholarship.org/uc/uciem_cpccm
DOI: 10.5811/cpcem.2017.12.36410

Massive and submassive pulmonary emboli (PE) are rare but potentially life-threatening medical conditions that necessitate immediate recognition and appropriate treatment. We report a 52-year-old man who was found to have a submassive central saddle and extensive bilateral PEs after experiencing a syncopal event and who had evidence of right heart strain and pulmonary hypertension. He was subsequently treated with catheter-assisted thrombectomy and pulmonary artery tissue plasminogen activator administration. This case report presents an outcome in a patient who received an innovative therapy that has not been well established in this subset of patients. [Clin Pract Cases Emerg Med. 2018;2(1):7–11.]

INTRODUCTION

Pulmonary embolism (PE) remains a common cause of morbidity and mortality with estimates of up to 200,000 deaths annually.¹ The two severe forms of this disease are massive and submassive PE. A massive PE is defined by the presence of hemodynamic compromise with a systolic blood pressure <90 millimeters of mercury (mmHg) or a drop in systolic BP \geq 40 mmHg from baseline for >15 minutes or hypotension requiring vasopressors not explained by other causes.² Submassive PE is defined by evidence of right ventricular dysfunction with hemodynamic stability.² Although massive PEs are rare and comprise only about 2-5% of all PEs,³⁻⁵ they are crucially important because they carry a 52.4% 90-day mortality rate.³ Despite being a rather infamously feared entity, the submassive PE lacks consensus on the optimal evidence-based therapy. This disease is an important entity for physicians to promptly identify and appropriately treat because of the high potential for negative outcomes.

CASE REPORT

A 52-year-old morbidly obese male presented to the Emergency Department (ED) with a chief complaint of syncope. The morning of presentation he reported feeling lightheaded with shortness of breath and blurry vision upon standing. He next remembered waking up on the floor. He reported worsening shortness of breath over the prior three days. Additionally, he reported experiencing a dull, constant, pressure-like sensation over the left side of his chest that had begun the night before. Initially, the patient denied any medical conditions other than morbid obesity; however, several hours into his stay we learned that he had a history of a deep vein thrombosis (DVT) with a PE after a knee arthroscopy two years earlier.

His temperature was 36.5 degrees Celsius, heart rate of 114 beats per minute, blood pressure of 137/91 mmHg, respiratory rate of 18 breaths per minute, and pulse oximetry of 94% on room air. His weight was 181 kilograms (body mass index of 59). The patient was awake, alert, conversing appropriately,

and in no apparent distress. He was noted to be tachycardic but was well perfused, with no signs of cyanosis and a capillary refill less than two seconds. His lungs were clear to auscultation bilaterally without an increase in work of breathing. Other than venous stasis changes, his lower extremities appeared normal.

His electrocardiogram showed sinus tachycardia at 103 beats per minute with a S-wave in lead I, Q-wave in lead III, and small ST-elevations in V1-V3. His initial troponin was above the normal limit at 0.17 ng/mL [0.00-0.03 ng/mL]. The patient's metabolic panel was notable only for an elevated glucose of 206 mg/dL [85-125mg/dL]. His complete blood count was normal except for an elevated white blood cell count of 12.3 thous/MCL [4-10.5 thous/MCL]. D-dimer was >1000ng/ml [<500 ng/ml]. A computed tomography pulmonary angiogram was ordered to rule out PE (Images 1 and 2). It demonstrated a central saddle embolism and multiple occlusive and nonocclusive lobar, segmental, and subsegmental pulmonary arterial emboli bilaterally. Right heart strain and pulmonary hypertension were evidenced by enlargement of the main pulmonary artery and straightening to leftward bowing of the interventricular septum, indicating significant clot burden.

Pulmonary critical care and interventional radiology teams were consulted and after evaluating the patient, the decision was made to not start heparin and instead immediately take the patient for thrombectomy. The patient underwent clot aspiration and catheter-directed intra-procedural tissue plasminogen activator (tPA) administration into each pulmonary artery. Post-thrombectomy angiogram demonstrated significant improvement, but showed persistent areas of clots. Following the procedure, the patient became hypotensive and hypoxemic requiring vasopressors and continued intubation.

The following day the patient had bilateral pulmonary artery EKOS™ catheters (EkoSonic® Endovascular System designed for the treatment of PE) placed for continuous tPA administration.

On hospital day three, his pulmonary artery angiogram demonstrated no visible thrombus and the EKOS™ catheters were removed. The patient remained in the intensive care unit (ICU) intubated, sedated, and receiving anticoagulants. On hospital day 4, he had sustained hypoxia and then suffered a cardiac arrest but had return of spontaneous circulation after cardiopulmonary resuscitation. This event was thought to be due to a recurrent PE, and thus an inferior vena cava filter was placed the following day.

On hospital day 14, he was extubated and transferred out of the ICU. The patient returned to his baseline mental status without any breathing difficulties or chest pain. On hospital day 20, he was transferred to a skilled nursing facility for rehabilitation. At time of discharge, he was neurologically intact and required minimal assistance with activities of daily living.

DISCUSSION

PE is a form of venous thromboembolism that is estimated to affect 600,000 patients per year in the United States.⁶ The

CPC-EM Capsule

What do we already know about this clinical entity?

The etiology, presentation, and risk factors of pulmonary emboli (PE) are well known. There remains a lack of consensus on the recommended treatment for submassive PE.

What makes this presentation of disease reportable?

The presentation of this disease was unique in that the chief complaint was syncope, and shortness of breath was not a prominent finding.

What is the major learning point?

Catheter-directed therapies are increasingly being used for the treatment of submassive PE.

How might this improve emergency medicine practice?

Early recognition of submassive pulmonary embolism and prompt treatment with selected therapy should lead to better outcomes for individuals with PE.

well-known predisposing factors include recent surgery or trauma, hormone replacement, oral contraceptives, pregnancy, immobility, chemotherapy, and malignancy.⁷⁻⁸ This patient's previous PE occurred after a known predisposing factor of arthroscopic knee surgery and resulting immobility. However, his current episode of PE seemed to have no predisposing factors other than obesity and sedentary lifestyle. About 20% of patients with PEs have no identifiable predisposing factors.⁹ PEs typically present with dyspnea (80%), pleuritic chest pain (52%), substernal chest pain (12%), cough (20%), syncope (19%), tachypnea (70%), and tachycardia (26%).⁷ This patient exhibited dyspnea, substernal chest pain, syncope, and tachycardia.

The sequence of pathophysiological events that occur with a PE can be deadly. Initially, an embolus that arises from elsewhere in the body, typically from a DVT in an extremity, lodges in the pulmonary arterial system. Depending on the size of the emboli and the size and abruptness of the resulting occlusion, symptoms can vary dramatically from totally asymptomatic to instant death. It is estimated that more than 30-50% of the arterial bed must be affected before the patient becomes symptomatic.⁷ Once the embolus occludes the vessel, the pulmonary vascular resistance is abruptly increased and

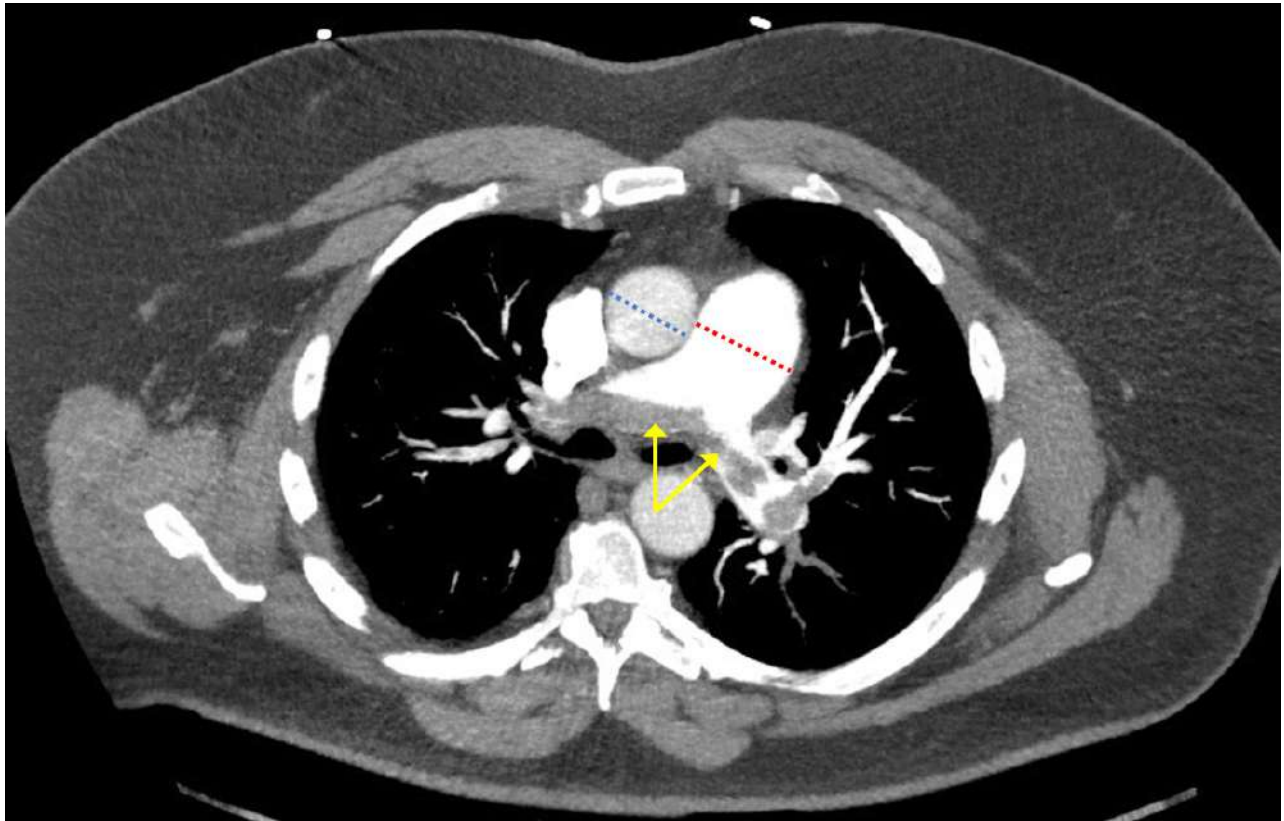


Image 1. Computed tomography pulmonary angiogram demonstrating a saddle embolism at the main pulmonary artery bifurcation extending into right and left pulmonary arteries (yellow arrows). Also visible is an enlarged main pulmonary artery diameter (red dashed line) relative to the ascending aorta (blue dashed line) indicating right-sided heart strain with pulmonary hypertension.

the ability of the right ventricle to match this increase in pressure determines if the patient will survive.⁷ If the right ventricle cannot keep up with the increase in pressure, then right ventricular failure will ensue leading to shock and death.

This case is significant for the decision-making that occurred after the diagnosis was made. As it currently stands, there is a lack of consensus in the literature regarding the optimal treatment for the different types of PEs. And indeed, in the case above, there was a brief time of uncertainty in deciding which treatment method was best for this particular patient. Ultimately, he was successfully treated with an innovative approach that has yet to be well established in patients with submassive PEs.

The treatment options for PEs are systemic thrombolytics, anticoagulation, open thrombectomy, and catheter-assisted techniques, including fragmentation and local thrombolytic delivery. In 2004 the American College of Chest Physicians (ACCP) published their evidence-based guidelines for treating venous thromboembolic diseases.¹⁰ At that time, the recommendation was that patients with massive PEs should receive systemic thrombolytics, and it was “unsettled” whether patients with submassive PEs should receive

thrombolytics or anticoagulants. Mechanical approaches and pulmonary embolectomies were recommended only when 1) thrombolytics were contraindicated or failed, and 2) the patient was in critical status.

In the decade or so since those guidelines were published, catheter-directed therapies (CDT) have made small but important strides towards becoming more accepted. This reluctance to embrace CDT has been attributed to the lack of large-scale high-quality trials, lack of an established protocol, requirement for trained personnel and specialized equipment, and a delay in obtaining Food and Drug Administration approval for these techniques and for an intrapulmonary thrombolytic drug.¹¹ Some studies have emerged from interventional radiology and vascular publications documenting the success of CDT as treatment for submassive and massive PEs.^{3,11,12} These studies have documented about an 86% success rate with a 7% rate of complication,¹¹⁻¹² compared to the old standard of systemic thrombolytics that has about a 77% success rate but comes with a 20% risk of serious hemorrhage.¹¹

In 2016 the ACCP published updated guidelines for the treatment of venous thromboembolism.¹³ These guidelines

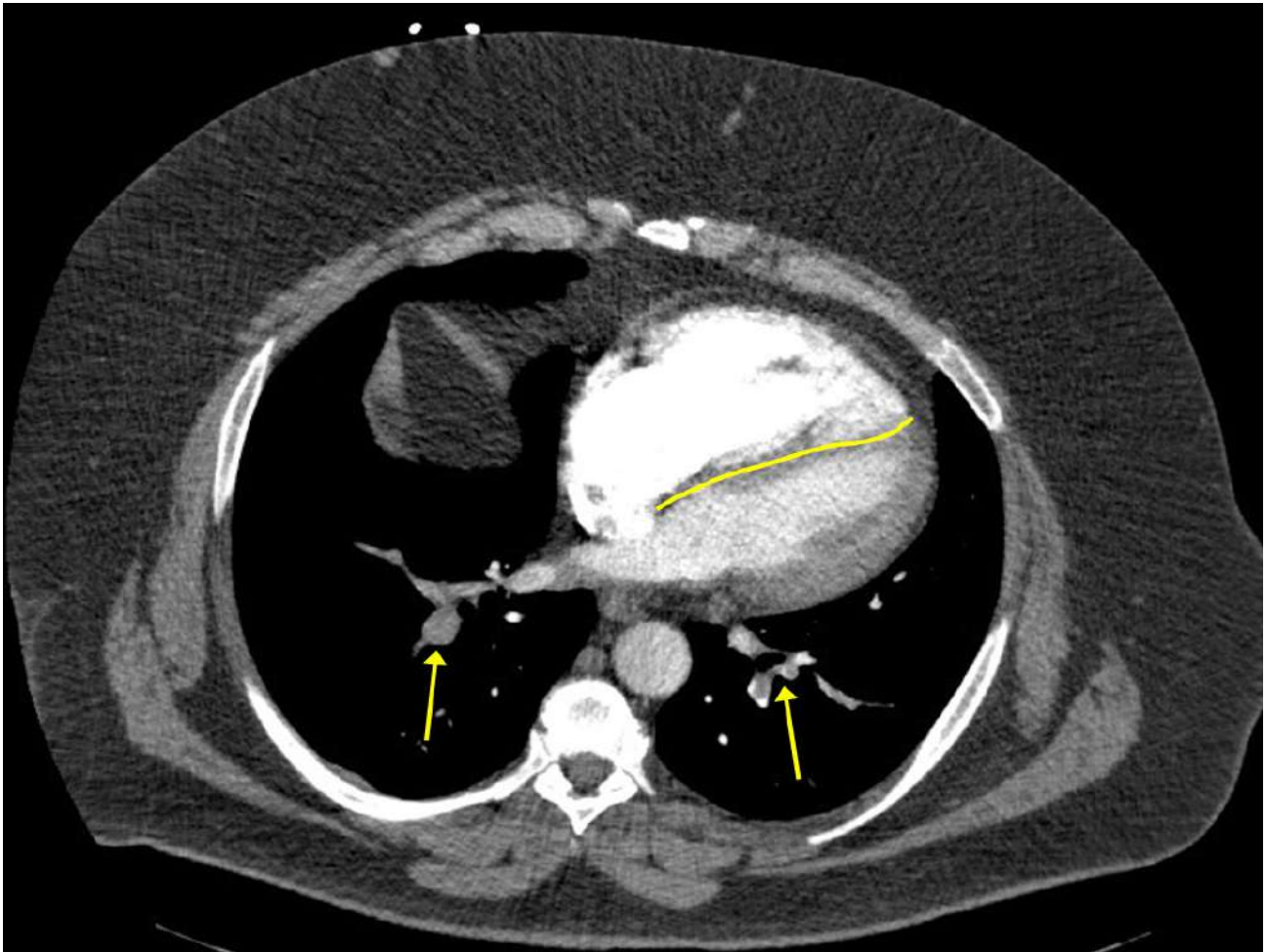


Image 2. Additional view of the computed tomography pulmonary angiogram demonstrating occlusive and nonocclusive lower lobe pulmonary artery emboli bilaterally (yellow arrows). Straightening and leftward bowing (yellow line) of the interventricular septum indicating right-sided heart strain is also visible.

reiterated the 2004 recommendation that massive PEs should receive systemic thrombolytics, and concluded that submassive PEs should not receive systemic thrombolytics but may warrant aggressive anticoagulation. Lastly, the committee recommended against the use of CDT over systemic thrombolytics and also against catheter fragmentation for massive and submassive PEs, citing low quality of evidence and lack of trials as their rationale for this recommendation. CDT was only recommended in cases in which the patient was hypotensive, thrombolytics could not be given, and appropriate expertise and resources were available.¹³

CONCLUSION

The value of this case is that it demonstrates how our patient was successfully treated with an innovative approach that has yet to be well established in patients with submassive PEs. The intention of this report was to provide a small data point in an area awaiting higher quality evidence and large trials. While

awaiting those results, it is the responsibility of the treating physician to select a therapy option that is best suited to the clinical status of the individual PE patient.

Address for Correspondence: Shahram Lotfipour, MD, MPH, University of California, Irvine, Department of Emergency Medicine, 333 The City Blvd. West, Rt 128-01, Suite 640, Orange, CA 92868. Email: shl@uci.edu.

Conflicts of Interest: By the *CPC-EM* article submission agreement, all authors are required to disclose all affiliations, funding sources and financial or management relationships that could be perceived as potential sources of bias. The authors disclosed none.

Copyright: © 2018 Andrusaitis et al. This is an open access article distributed in accordance with the terms of the Creative Commons Attribution ([CC BY 4.0](http://creativecommons.org/licenses/by/4.0/)) License. See: <http://creativecommons.org/licenses/by/4.0/>

REFERENCES

1. Fesmire FM, Brown MD, Espinosa JA, et al. Critical issues in the evaluation and management of adult patients presenting to the emergency department with suspected pulmonary embolism. *Ann Emerg Med.* 2011;57(6):628-652.e75.
2. Torbicki A, Van Beek EJR, Charbonnier B, et al. Guidelines on diagnosis and management of acute pulmonary embolism. *Eur Heart J.* 2000;21(16):1301-36.
3. Kucher N, Rossi E, De Rosa M, et al. Massive pulmonary embolism. *Circulation.* 2006;113(4):577-82.
4. Goldhaber SZ. Integration of catheter thrombectomy into our armamentarium to treat acute pulmonary embolism. *Chest.* 1998;114(5):1237-8.
5. Ryu JH, Pellikka PA, Froehling DA, et al. Saddle pulmonary embolism diagnosed by CT angiography: frequency, clinical features and outcome. *Respir Med.* 2007;101(7):1537-42.
6. Dalen JE, Alpert JS. Natural history of pulmonary embolism. *Prog Cardiovasc Dis.* 1975;17(4):259-70.
7. Torbicki A, Perrier A, Konstantinides S, et al. Guidelines on the diagnosis and management of acute pulmonary embolism. *Eur Heart J.* 2008;29:2276-2315.
8. Uflacker R. Interventional therapy for pulmonary embolism. *JVIR.* 2001;12:147-164.
9. Goldhaber SZ, Visani L, Rosa M De. Acute pulmonary embolism: clinical outcomes in the International Cooperative Pulmonary Embolism Registry (ICOPER). *Lancet.* 1999;353(2182):1386-9.
10. Buller HR, Agnelli G, Hull R, et al. Antithrombotic Therapy for Venous Thromboembolic Disease: The Seventh ACCP Conference on Antithrombotic and Thrombolytic Therapy. *Chest J.* 2004;126(3):401S-28S.
11. Kuo WT, Gould MK, Louie JD, et al. Catheter-directed therapy for the treatment of massive pulmonary embolism : systematic review and meta-analysis of modern techniques. *JVIR.* 2009;20(11):1431-40.
12. Kuo WT, Banerjee A, Kim PS, et al. Pulmonary Embolism Response to Fragmentation, Embolectomy, and Catheter Thrombolysis (PERFECT): initial results from a prospective multicenter registry. *Chest J.* 2015;148(3):667-73.
13. Kearon C, Akl EA, Ornelas J, et al. Antithrombotic therapy for VTE disease: CHEST guideline and expert panel report. *Chest.* 2016;149(2):315-52.

Double Trouble: Massive Unruptured Aortic Aneurysms

Martin L. Gagne, DO
Radhika Malhotra, MD
Joseph Zito, MD
Adam Schwartz, DO
Steven Sattler, DO

Good Samaritan Hospital Medical Center, Department of Emergency Medicine, West Islip, New York

Section Editor: Rick A. McPheeters, DO

Submission history: Submitted February 1, 2017; Revision received June 28, 2017; Accepted July 11, 2017

Electronically published January 9, 2018

Full text available through open access at http://escholarship.org/uc/uciem_cpccem

DOI: 10.5811/cpcem.2017.7.33820

We describe a patient who presented to the emergency department complaining of generalized weakness, dark stools, and urinary retention who was found to have two large abdominal aortic aneurysms (AAA) compressing his bilateral ureters with associated hydronephrosis and renal insufficiency. In elderly male patients presenting with signs of obstructive uropathy, AAA should be considered as a potential cause. [Clin Pract Cases Emerg Med.2018;2(1):12-15.]

INTRODUCTION

Abdominal aortic aneurysms (AAA) can be classified as inflammatory or non-inflammatory. Non-inflammatory AAAs are characterized by asymptomatic presentation, lack of aneurysmal wall thickening, lack of perianeurysmal fibrosis, and normal erythrocyte sedimentation rate. It is known that inflammatory AAAs can result in obstructive uropathy secondary to retroperitoneal/perianeurysmal fibrosis; however, the incidence of non-inflammatory AAAs resulting in bilateral mechanical compression of the ureters is extremely rare. We present a case report of a patient presenting to the emergency department (ED) for generalized weakness, dark stools, and urinary retention who was found to have two large non-inflammatory AAAs causing ureteral compression with bilateral hydronephrosis.

CASE REPORT

A 77-year-old Caucasian male presented to the ED complaining of generalized weakness, fatigue, lightheadedness, and shortness of breath. His symptoms began gradually three days prior and progressively worsened. His lightheadedness was provoked by moving from a seated to standing position; and at the time he presented, he was unable to stand up. Review of systems (ROS) was positive for decreased urination for one month, as well as dark, maroon-colored stools. ROS was negative for fever, chest pain, nausea, vomiting, and bright red blood per rectum.

His medical history included anemia, blood transfusions, jejunal angiodysplasia, and a cerebrovascular accident. His

surgical history was significant for endoscopy, colonoscopy, capsule endoscopy, and deep enteroscopy. Home medications included allopurinol, esomeprazole, ezetimibe-simvastatin, levothyroxine, mometasone, montelukast, and sertraline. In addition, the patient was a former smoker (20 pack-year history) and consumed alcohol occasionally.

Upon presentation to the ED, the patient was afebrile with a heart rate of 80 beats per minute, blood pressure of 104/68 mm Hg, respiratory rate of 24 breaths per minute, and oxygen saturation of 97% on room air. He appeared weak and in mild distress. His body habitus was normal. Mucous membranes were dry. The abdomen was mildly distended, but there was no tenderness, rebound, guarding, organomegaly, or appreciable masses. His rectal exam demonstrated a small amount of dark stool that was guaiac positive. The patient's skin was pale but warm and dry with good turgor. The remainder of the physical exam was unremarkable.

An electrocardiogram demonstrated a normal sinus rhythm at 79 beats per minute with no acute ischemic changes. Laboratory results were obtained. The patient was found to be severely anemic with a hemoglobin of 5.1 g/dL. His carbon dioxide level was 16 mmol/L, blood urea nitrogen was 104 mg/dL, and creatinine was 3.4 mg/dL. The etiology of the patient's renal insufficiency was likely due to post-renal obstructive uropathy, as well as pre-renal azotemia related to gastrointestinal bleeding. Two units of packed red blood cells were given. A non-contrast computed tomography (CT) of his abdomen and pelvis was obtained (Images 1-3) to screen for a wide variety of

significant intra-abdominal pathologies given the patient's age, comorbidities, presenting symptoms, and findings suggestive of gastrointestinal bleeding, anemia, and renal insufficiency. The CT revealed two large aneurysms: a 9.0 x 9.0 cm infrarenal abdominal aortic aneurysm and a 10.0 x 9.0 right common iliac artery aneurysm. Both aneurysms were increased in size in comparison to a prior study from 2006. There was no evidence of extravasation; however, this study was performed without intravenous contrast due to the patient's renal failure. Additionally, there was bilateral ureteral compression from the abdominal aneurysms resulting in

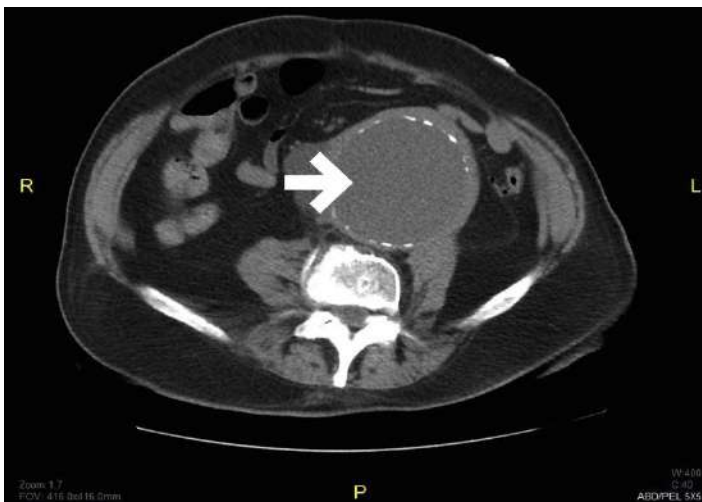


Image 1. Computed tomography without contrast of the abdomen and pelvis in axial view with an arrow demonstrating a 9 x 9 cm infrarenal aortic aneurysm.

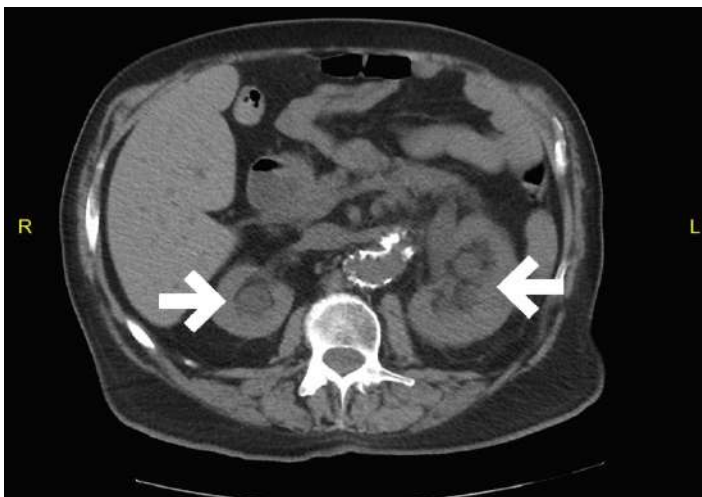


Image 2. Computed tomography of the abdomen and pelvis in axial view with arrows demonstrating bilateral hydronephrosis

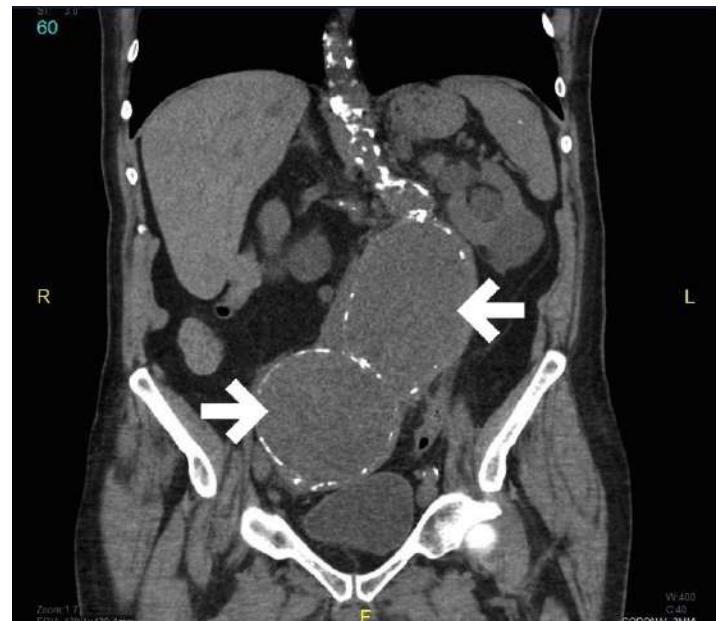


Image 3. Computed tomography of the abdomen and pelvis in coronal view demonstrates a 9 x 9 cm aortic aneurysm (large arrow) and a 10 x 9 cm right common iliac aneurysm (small arrow)

CPC-EM Capsule

What do we already know about this clinical entity?

Aortic aneurysms are the 14th leading cause of death in the U.S. Common complaints include back, flank, and abdominal pain.

What makes this presentation of disease reportable?

This patient was found to have two massive aneurysms causing mechanical ureteral compression with bilateral hydronephrosis, which is extraordinarily rare.

What is the major learning point?

In elderly male patients presenting with signs of obstructive uropathy, aortic aneurysms should be considered as a potential cause.

How might this improve emergency medicine practice?

Emergency physicians must continue to consider a wide range of differential diagnoses in elderly patients presenting with generalized or atypical abdominal complaints.

moderate bilateral hydroureter and hydronephrosis. There was no evidence of an aortoenteric fistula, perianeurysmal fibrosis, or an acute inflammatory process.

The patient was stabilized and transferred to a tertiary care center for deep enteroscopy, bilateral nephrostomy tube placement, and aneurysmal repair. The patient was later discharged to a rehabilitation center, but soon re-admitted for a recurrence of gastrointestinal bleeding.

DISCUSSION

Aortic aneurysms were identified as the primary cause of 10,597 deaths in the United States in 2009.¹ It is the 14th leading cause of death in the U.S.² AAAs are described as a focal dilation, 3 cm or greater, of the abdominal aorta with respect to the original artery. Most AAAs occur distal to the renal arteries.² AAA risk factors include age of 60 years and greater, smoking history (defined as lifetime use greater than 100 cigarettes), hypertension, male gender, and Caucasian ethnicity.³ The majority of unruptured aneurysms are asymptomatic and discovered incidentally. The prevalence of symptoms in patients with unruptured AAAs is unknown, but common complaints include back, flank, and abdominal pain. The most common physical exam finding is a pulsatile abdominal mass.

For screening or diagnostic purposes, abdominal ultrasound is the imaging modality of choice (sensitivity of 95% and specificity of 99%); however, CT angiography provides a more detailed assessment of the abdomen preferable for serial monitoring or surgical planning.² CT angiography also has the advantage of being able to identify a ruptured AAA. Surgical management is recommended for patients who have AAAs that are symptomatic or greater than 5.5 cm in diameter. In the hemodynamically stable but symptomatic patient with a large unruptured aneurysm, surgical repair can be delayed for medical optimization with the patient monitored in the intensive care unit setting. Traditionally, AAAs were repaired using an open laparotomy approach; however, technological advances now facilitate an endovascular technique, which is associated with better outcomes.²

Between 3%-10% percent of AAAs are characterized as inflammatory AAAs (IAAA), which are a distinct entity distinguished by symptomatic presentation, aneurysmal wall thickening, perianeurysmal fibrosis, adherence to surrounding structures, and an elevated erythrocyte sedimentation rate. IAAs have a 20-40% incidence of ureteral compromise⁴ and are well documented as causing bilateral obstructive uropathy.⁵⁻⁹ On the other hand, *non-inflammatory* AAAs have a 0.2% incidence of ureteral involvement⁴ and reports of compressive uropathy related to aneurysmal size are exceedingly rare. Upon review of the literature, we found only two previous case reports of non-inflammatory AAAs causing mechanical ureteral obstruction.^{10,11}

CONCLUSION

This case is unique because our patient presented with urinary retention and was found to have renal insufficiency, hydronephrosis, and bilateral ureteral compression from two large aneurysms without preoperative evidence of an inflammatory reaction or fibrotic obstruction. Cases of non-inflammatory AAAs causing mechanical ureteral compression and urinary retention are extraordinarily rare. In elderly male patients presenting with this constellation of symptoms, AAA should be included in the differential diagnosis.

Address for Correspondence: Martin Gagne, DO, Good Samaritan Hospital Medical Center, 1000 Montauk Highway, West Islip, NY, 11795. Email: mgagne@nyit.edu.

Conflicts of Interest: By the *CPC-EM* article submission agreement, all authors are required to disclose all affiliations, funding sources and financial or management relationships that could be perceived as potential sources of bias. The authors disclosed none.

Copyright: © 2018 Gagne et al. This is an open access article distributed in accordance with the terms of the Creative Commons Attribution (CC BY 4.0) License. See: <http://creativecommons.org/licenses/by/4.0/>

REFERENCES

1. Kochanek KD, Xu J, Murphy SL, et al. Deaths: final data for 2009. *Natl Vital Stat Rep*. 2011;60(3):1-116.
2. Aggarwal S, Qamar A, Sharma V, et al. Abdominal aortic aneurysms: A comprehensive review. *Exp Clin Cardiol*. 2011;16(1):11-5.
3. Kent KC, Zwolak RM, Egorova NN, et al. Analysis of risk factors for abdominal aortic aneurysm in a cohort of more than 3 million individuals. *J Vasc Surg*. 2010;52(3):539-48.
4. Branchereau A, Jacobs M. *Unexpected challenges in vascular surgery*. Malden, MA: Wiley-Blackwell; 2005.
5. Korzets Z, Witz M, Goldberg E, et al. The patient with asymptomatic advanced renal failure--obstructive uropathy caused by inflammatory abdominal aortic aneurysm. *Nephrol Dial Transplant*. 1998;13(7):1835-7.
6. Kujubu D, Agarwal J, Gandhi N, et al. A case of aneurysm induced obstructive nephropathy masked by polyuria. *Internet J Nephrol*. 2005;3(1).
7. Turo A, Torres L, Peiro M, et al. [Obstructive uropathy caused by retroperitoneal fibrosis secondary to aneurysm of the abdominal aorta]. *Actas Urol Esp*. 2000;24(9):764-6.
8. McGentee GP, Smith JM, Corrigan TP. Renal failure from obstructive

- uropathy secondary to aortic aneurysm. *Urology*. 1982; 20(3):294-5.
9. Sánchez R, Arroya A, Gesto R, et al. Obstructive ARF caused by inflammatory abdominal aortic aneurysm. *Am J Kidney Dis*. 2003;41(3):E9.
10. Babić S, Radak D, Matic P, et al. [Non-inflammatory aortoiliac aneurysm with ureteral obstruction and consequent hydronephrosis: case report]. *Srp Arh Celok Lek*. 2012;140(1-2):91-3.
11. Korn S, Feller AM, Huth C, et al. [Bilateral obstruction of the ureters as a complication of iliac aneurysms]. *Thorac Cardiovasc Surg*. 1987;35(1):61-4.

Endophthalmitis and Mycotic Aneurysm: The Only Clues to Underlying Endocarditis

Guy Carmelli, MD*
Taylor Surles, MD*
Alisha Brown, MD‡

*King's County Hospital Center, Department of Emergency Medicine, Brooklyn, New York
†SUNY Downstate University Hospital of Brooklyn, Department of Emergency Medicine, Brooklyn, New York
‡University of Washington, Department of Emergency Medicine, Seattle, Washington

Section Editor: Rick A. McPheeters, DO

Submission history: Submitted April 30, 2017; Revision received August 6, 2017; Accepted August 10, 2017

Electronically published January 9, 2018

Full text available through open access at http://escholarship.org/uc/uciem_cpem

DOI: 10.5811/cpcem.2017.8.34723

Infective endocarditis is a deadly disease that can present as a myriad of symptoms and thus its diagnosis can be missed. We present a case of infective endocarditis presenting as endogenous endophthalmitis and a ruptured mycotic aneurysm. This case illustrates both the complexity of infective endocarditis as a disease process and the more subtle diagnostic criteria as outlined by the Modified Duke Criteria. [Clin Pract Cases Emerg Med.2018;2(1):16-20.]

INTRODUCTION

Infective endocarditis (IE) remains a deadly disease, despite advances in modern medicine. The 30-day in-hospital mortality for IE is typically 15-20%¹⁻² and as high as 40% in the event that the patient is admitted to the intensive care unit.³ Proper, prompt diagnosis and management is imperative to minimize mortality. Furthermore, the wide range of presenting symptoms for this disease creates a diagnostic challenge. We present a unique case of a woman with IE who presented with both endogenous bacterial endophthalmitis and an intracerebral mycotic aneurysm that ruptured, causing a hemorrhagic stroke. Her presentation not only highlights the often diagnostically challenging nature of endocarditis, but also illustrates the underlying pathophysiology of this disease process.

CASE REPORT

A 69-year-old female presented to the emergency department (ED) with a chief complaint of left-eye blurriness and discharge for two days. She described the discharge as yellowish, starting as a thin exudate that progressively became heavier over two days. She had associated malaise, fever, and multiple episodes of non-bilious, non-bloody emesis for one day. By the time she presented to the ED, she had lost vision in the affected eye. She denied contact lens use, eye pain with extraocular movements, or recent trauma to the eye.

Her past medical history was significant for hypertension and hyperlipidemia. She had no surgical history, no allergies, and no reported drug use. Her medications included amlodipine, hydrochlorothiazide, pantoprazole, and simvastatin, for which she reported compliance. On review of systems, she denied diarrhea, sick contacts, recent travel, fever, cough, sneezing, runny nose, headache/neck pain, chest pain/shortness of breath or abdominal pain.

Her triage vitals were as follows: blood pressure 125/71 mmHg, pulse 105 beats per minute, temperature 99.3 F (orally), respiratory rate 18 breaths per minute, and oxygen saturation of 95% on room air. Her initial ED exam showed an injected conjunctiva of the left eye with profuse mucopurulent drainage, normal pupillary response without an afferent pupillary defect, no photophobia, no proptosis and no pain with eye movements (Image 1). Her visual acuity was measured as no light perception. Her right eye had a normal exam. She had a normal cardiopulmonary exam, without any appreciable murmur. Her abdomen was soft and non-distended, but she had some minimal right upper quadrant pain. The rest of her exam, including an extremity, skin, and neurological exam, was within normal limits.

Labs were significant for a lactate of 1.7 mmol/L, a troponin I of 0.134 ng/ml (reference range normal \leq 0.10), and a white blood cell count of 3.09 K/uL with a predominance of immature neutrophils. Her electrolytes,

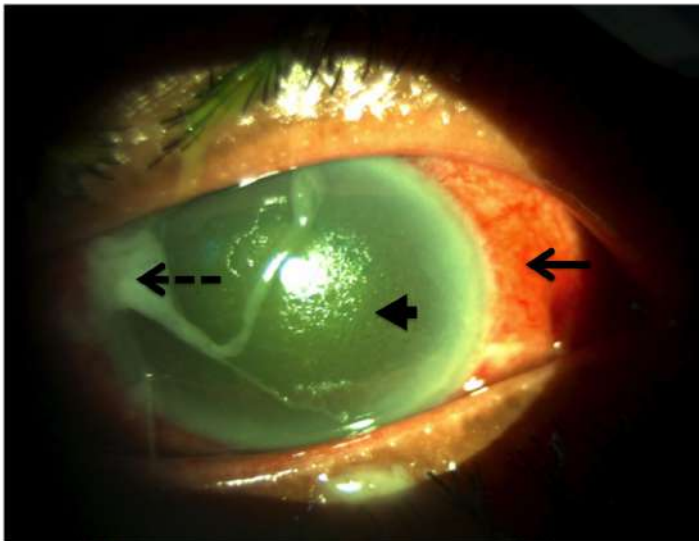


Image 1. Image of patient's left eye, taken by ophthalmology, demonstrating diffuse conjunctival injection without limbic sparing (solid arrow), mucopurulent drainage (dashed arrow) and a cloudy anterior chamber (arrow head).

renal function, liver function and lipase were normal. Her electrocardiogram (ECG) demonstrated sinus tachycardia with a few atrial ectopic beats, but no ischemic findings. An abdominal sonogram was performed by the radiologist to evaluate her right upper quadrant pain, and it showed no acute pathology. The patient was given an aspirin for her elevated troponin and Maalox for her abdominal pain. She was admitted to medicine for vomiting, fever without a source, possible non-ST-segment elevation myocardial infarction, and ophthalmologic evaluation.

While in the ED awaiting admission, ophthalmology evaluated the patient. On fundoscopic exam, the patient was found to have white fibrinous material with cell and flare in the anterior chamber, evidence of vitritis in the posterior segment and punctate intraretinal hemorrhages with central whitening thought to be Roth's spots. Ophthalmology's findings were consistent with endophthalmitis. They obtained vitreous cultures and recommended a broad workup for an endogenous cause.

Blood cultures and serial troponins were obtained. While awaiting a transthoracic echocardiogram (TTE) in the ED, the patient developed new right upper extremity weakness and a stroke code was called. Computed tomography (CT) of the brain showed a left frontal lobe parenchymal hemorrhage with mild surrounding vasogenic edema and subarachnoid hemorrhage. CT angiography showed a mycotic aneurysm as the culprit lesion (Image 2), and the subsequent transesophageal echocardiogram (TEE) confirmed a valvular mass. The patient was treated for endocarditis with vancomycin and ceftriaxone intravenously. She was ultimately sent to physical rehabilitation for post-stroke care. The patient is now doing well and is awaiting valve replacement.

CPC-EM Capsule

What do we already know about this clinical entity?

Infective endocarditis (IE) is a deadly infection of the endocardial surface, most commonly the heart valves. Clinical manifestations can be extremely variable.

What makes this presentation of disease reportable?

Typical symptoms are pathognomonic for IE, such as Osler Nodules. However, our patient presented with endophthalmitis and intracranial hemorrhage, two relatively rare symptoms.

What is the major learning point?

Due to hematologic seeding, symptoms can arise in multiple organ systems at once. The Modified Duke Criteria provides a framework to stratify patients with possible endocarditis.

How might this improve emergency medicine practice?

When unusual symptoms present in multiple organ systems within a single patient, bacterial endocarditis must be on the differential.

DISCUSSION

Our case report is unique in that this is a rare presentation of a classic disease. Our patient first presented with endophthalmitis and then had a hemorrhagic stroke from a mycotic aneurysm. Endogenous endophthalmitis is rare in the United States. One retrospective study by Okada et al. showed that in a large acute-care hospital over a 10-year period there were only 28 reported cases.⁴ Intracerebral mycotic aneurysms are almost as rare. In a retrospective review of 27 studies over 59 years, Ducruet et al. found only 287 cases.⁵ Therefore, the presence of both phenomena together in our patient is truly exceptional. It is important to first review both of these disease processes separately and then understand how they link to endocarditis.

Endogenous endophthalmitis is an embolic event

Endophthalmitis is an infective process involving the anterior and posterior chambers of the eye and can be bacterial or fungal. It is further subdivided into exogenous or endogenous sources. Exogenous endophthalmitis is

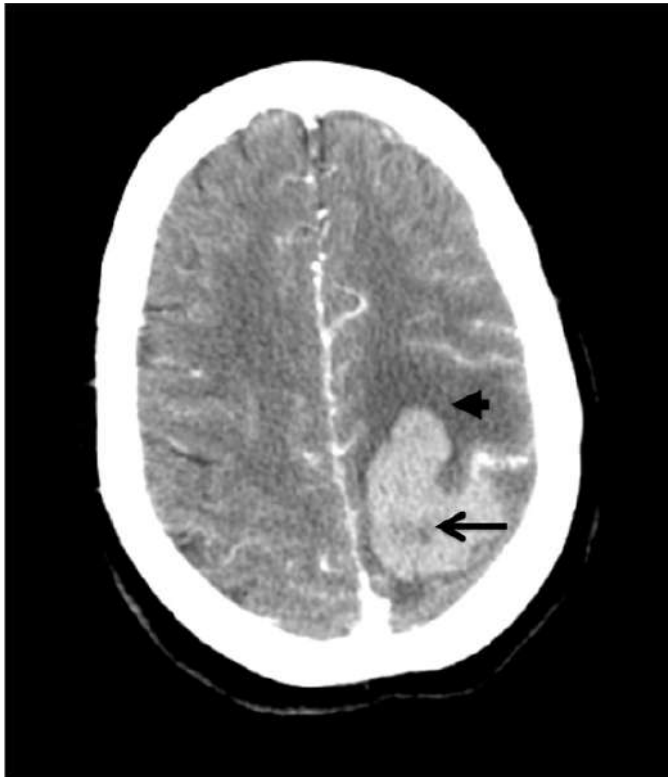


Image 2. Computed tomographic angiography of the patient's brain demonstrating left middle cerebral artery mycotic aneurysm with intracerebral hemorrhage (black arrow) and surrounding vasogenic edema (arrow head).

most common, typically resulting from a surgical procedure or direct ocular trauma.⁶ Endogenous endophthalmitis occurs in otherwise-healthy eyes, but infection is spread hematogenously from another infectious source in the body. Endogenous endophthalmitis accounts for 2-8% of all cases of endophthalmitis,⁷ with up to 40% resulting from IE.⁴

The diagnosis is largely clinical since the disease can rapidly progress and lead to permanent visual loss if treatment is not started before culture results are available. Key presenting symptoms are decreased vision (93%), conjunctival injection (81%), pain (75%) and lid swelling (33%). There typically is no fever or leukocytosis for endophthalmitis alone, and its presence should prompt an investigation for an endogenous source of infection.⁶ The hallmark of endophthalmitis is involvement in both the anterior chamber and posterior segments of the eye. Slit lamp examination may reveal cell and flare with or without a hypopyon in the anterior chamber. Vitreous inflammation and exudates may obscure the retina and hide the red reflex.^{6,8} Our patient came in with rapidly deteriorating vision secondary to infectious endophthalmitis. Given there was no history suggestive of an exogenous etiology, a broad search for an endogenous source was necessary.

Mycotic Aneurysms are also embolic events

A mycotic aneurysm is an abnormal dilatation of an artery from bacterial involvement. This can be caused by inoculation of a previously weakened vessel wall, or by direct infection of a previously normal arterial wall from septic emboli, as is the case in IE. Studies show that up to 40% of patients with IE will have central nervous system involvement, with up to 3-10% of patients developing an intracerebral mycotic aneurysm (IMA).^{9,10} However, these numbers may be inaccurate because there are a number of silent IMAs that are only found on autopsy.⁵

The dilatation makes the arterial wall fragile and friable and therefore more prone to rupture. Clinical symptoms typically only present after the aneurysm has ruptured, causing a hemorrhagic stroke. Diagnosis is done primarily through neurovascular imaging and is typically only done after there is evidence of a stroke. Some may present first with fever (28%), headache (20%), hemiparesis (15%), or vomiting (9%).⁵ About 65% of people with IMA presented initially with IE. Therefore, most experts agree that anyone with IE who develops neurologic symptoms should undergo neuroimaging to rule out IMA.⁵

With regard to our patient, the next clue to underlying endocarditis came when she had an intracranial hemorrhage (ICH). While there is a broad differential diagnosis for ICH (including but not limited to hypertension, vascular malformation, or brain tumor), when presenting in the setting of simultaneous infectious endophthalmitis, septic emboli from an unknown source was at the top of the differential.

Endocarditis is a syndrome- A review of the Modified Duke Criteria

IE is a challenging diagnosis to make because it can present as multiple, non-specific symptoms, and "textbook" presentations are rare.¹¹ It was initially described by Sir William Osler in the late 1800s in his *Gulstonian Lectures*.¹²⁻¹⁴ It was not until 1994 that the Duke criteria were proposed as a means to diagnose IE. The criteria were later modified in 2000 (Table 1).^{15,16} These criteria are purposefully very broad because the pathophysiology of IE can produce symptoms in almost any organ system. In a study by Murdoch et al., the diagnosis of Roth's spots, splinter hemorrhages, Janeway lesions, or Osler nodes occurred in 2%-8% of all patients.¹⁷ Rather, the most common presenting symptom was fever (96%) and either an elevated erythrocyte sedimentation rate (61%) or C-reactive protein level (62%),¹⁷ all of which are non-specific and could be related to a number of disease processes. However, one feature that differentiates IE from other systemic inflammatory responses is the presence of septic emboli. Vascular embolic events account for 17%- 23% of complications from IE.¹⁷

At this point our patient met diagnostic criteria by Modified Duke Criteria for endocarditis. She had three minor

Table. Modified Duke criteria. Remade from Li et al.¹⁶

Major criteria	Minor criteria
Positive blood culture with typical IE organism from 2 different blood cultures or persistently positive > 12 hours apart Viridians- group <i>Streptococcus</i> <i>Streptococcus bovis</i> HACEK group* <i>Staphylococcus aureus</i> Community-acquired Enterococci	Predisposing factor: known cardiac lesion or recreational intravenous drug use Microbiologic evidence: positive blood culture (not meeting major criterion) or serologic evidence of infection with organism consistent with IE but not satisfying major criterion
Evidence of endocardial involvement with positive echocardiogram defined as Oscillating intracardiac mass on valve/supporting structures Abscess New valvular regurgitation Dehiscence of prosthetic valve	Vascular phenomena: arterial emboli, pulmonary infarcts, intracranial hemorrhage, Janeway lesions, conjunctival hemorrhage, or mycotic aneurysm Fever of \geq to 38.0 C (100.4 F)
Single positive blood culture for <i>Coxiella burnetii</i> or anti-phase 1 IgG antibody titer >1:800 Definite infective endocarditis (IE): 2 Major, 1 major/3 minor, or 5 minor Possible IE: 1 major/1 minor, or 3 minor criteria	Immunological phenomena: Osler's nodes, glomerulonephritis, rheumatoid factor, or Roth's spots

*HACEK group: Haemophilus species, Aggregatibacter species, Cardiobacterium species, Eikenella species, Kingella species.
IE, Infective Endocarditis; C, Celsius; F, Fahrenheit; IgG, Immunoglobulin G.

criteria: a fever, an immunologic phenomenon (Roth's spots on fundoscopy), and a vascular phenomenon (ICH). The TEE confirmed a valvular vegetation, fulfilling one major criteria, thus diagnosing endocarditis.

CONCLUSION

We present a rare case of endocarditis that presented as rapidly progressing vision loss and hemorrhagic stroke from a mycotic aneurysm. The patient was aggressively treated with both intravenous and intravitreal antibiotics to reduce any further complications. She is alive and doing well to this day, awaiting definitive valvular replacement.

Address for Correspondence: Guy Carmelli, MD, SUNY Downstate Medical Center, 450 Clarkson Avenue, Box 1228, Brooklyn, NY 11203-2098. Email: guy.carmelli@downstate.edu.

Conflicts of Interest: By the CPC-EM article submission agreement, all authors are required to disclose all affiliations, funding sources and financial or management relationships that could be perceived as potential sources of bias. The authors disclosed none.

Copyright: © 2018 Carmelli et al. This is an open access article distributed in accordance with the terms of the Creative Commons Attribution (CC BY 4.0) License. See: <http://creativecommons.org/licenses/by/4.0/>

REFERENCES

1. Cabell CH, Jollis JG, Peterson GE, et al. Changing patient characteristics and the effect on mortality in endocarditis. *Arch Intern Med.* 2002;162(1):90-4.
2. Hoen B, Alla F, Selton-Suty C, et al. Changing profile of infective endocarditis: results of a 1-year survey in France. *JAMA.* 2002;288(1):75-81.
3. Leroy O, Georges H, Devos P, et al. Infective endocarditis requiring ICU admission: epidemiology and prognosis. *Ann Intensive Care.* 2015;5(1).
4. Okada AA, Johnson RP, Liles WC, et al. Endogenous bacterial endophthalmitis: report of a ten-year retrospective study. *Ophthalmology.* 1994;101(5):832-8.
5. Ducruet A, Hickman Z, Zacharia B, et al. Intracranial infectious aneurysms: a comprehensive review. *Neurosurg Rev.* 2010;33(1):37-46.
6. Yanoff M, Duker J. *Ophthalmology.* 4th ed. Pittsburgh: Elsevier/Saunders; 2014:723-38.
7. Shrader SK, Band JD, Lauter CB, et al. The clinical spectrum of endophthalmitis: incidence, predisposing factors, and features influencing outcome. *J Infect Dis.* 1990;162(1):115-20.
8. Sadiq MA, Hassan M, Agarwal A, et al. Endogenous endophthalmitis: diagnosis, management, and prognosis. *J Ophthalmic Inflamm Infect.* 2015;5(1):32.
9. Sonnevile R, Mourvillier B, Bouadma L, et al. Management of neurological complications of infective endocarditis in ICU patients. *Ann Intensive Care.* 2011;1(1):10.
10. Silverman ME, Upshaw CB Jr. Extracardiac Manifestations of

- Infective endocarditis and their historical descriptions. *Am J Cardiol.* 2007;100(12):1802-7.
11. Baddour LM, Wilson WR, Bayer AS, et al. Infective endocarditis in adults: diagnosis, antimicrobial therapy, and management of complications. *Circulation.* 2015;132(15):1435-86.
 12. Osler W. The Gulstonian Lectures, on Malignant Endocarditis. *Br Med J.* 1885;1(1262):467-70.
 13. Osler W. The Gulstonian Lectures, on Malignant Endocarditis. *Br Med J.* 1885;1(1263):522-6.
 14. Osler W. The Gulstonian Lectures, on Malignant Endocarditis. *Br Med J.* 1885;1(1264):577-9.
 15. Durack DT, Lukes AS, Bright DK, Duke Endocarditis Service. New criteria for diagnosis of infective endocarditis: utilization of specific echocardiographic findings. *The Am Journal Med.* 1994;96(3):200-9.
 16. Li JS, Sexton DJ, Mick N, et al. Proposed modifications to the Duke criteria for the diagnosis of infective endocarditis. *Clin Infect Dis.* 2000;30(4):633-8.
 17. Murdoch DR, Corey GR, Hoen B, et al. Clinical presentation, etiology, and outcome of infective endocarditis in the 21st century. *Arch Intern Med.* 2009;169(5):463-73.

The “Black-and-White Cookie” Sign – A Case Series of a Novel Ultrasonographic Sign in Gastric Outlet Obstruction

Allison Cohen, MD
Mark Foster, MD
Brendon Stankard, PA-C
Maxine Owusu, MD
Mathew Nelson, DO

North Shore University Hospital, Department of Emergency Medicine, Manhasset, New York

Section Editor: Rick A. McPheeters, DO

Submission history: Submitted August 8, 2017; Revision received October 17, 2017; Accepted November 8, 2017

Electronically published January 9, 2018

Full text available through open access at http://escholarship.org/uc/uciem_cpccm

DOI: 10.5811/cpcem.2017.11.35890

Gastric outlet obstruction (GOO) is a rare condition occurring as a consequence of numerous processes that prevent gastric emptying. Presenting symptoms of GOO are non-specific and include nausea, vomiting, epigastric discomfort and decreased appetite. The diagnosis of GOO is often challenging. Emergency physicians must have a heightened awareness of GOO to ensure proper diagnosis and rapid treatment. Although the gold standard for diagnoses of GOO is endoscopy, many patients are identified by computerized tomography imaging. Point-of-care ultrasound (POCUS) is a rapid and non-invasive technique for evaluating patients in the emergency department. Previous literature has validated the use of ultrasound in diagnosing various intra-abdominal pathologies including bowel obstructions and appendicitis; however, there is limited research on evaluating gastric disease.¹ We report three cases of GOO diagnosed with the “black-and-white cookie” sign on POCUS. [Clin Pract Cases Emerg Med. 2018;2(1):21–25.]

INTRODUCTION

Gastric outlet obstruction (GOO) is a clinical entity occurring as a consequence of numerous processes that prevent gastric emptying. Previously it was hypothesized that GOO was most commonly caused by benign conditions like peptic ulcer disease; however, malignancy is now known to be responsible for most new cases.² GOO is a known complication of metastatic disease, most often of the upper gastrointestinal tract. The most common causes are pancreatic and gastric malignancies. However, lymphomas, ampullary carcinomas, and biliary tract disease also play a significant role.³

Presenting symptoms of GOO are nausea and vomiting, but it can present with epigastric discomfort and decreased appetite. Endoscopy is the gold standard for diagnoses of GOO, but many patients are identified by computerized tomography(CT) imaging, which provides information about the underlying cause.⁴ Proposed treatments for obstruction include both surgical and nonsurgical options depending on the underlying cause and goals of care. Proposed treatment options include gastrojejunostomy with laparotomy or a laparoscopic approach and endoscopic stenting.⁵ We report three cases of malignant

GOO diagnosed with point-of-care ultrasound (POCUS) in the emergency department (ED).

CASE REPORT

Case 1

A 72-year-old-female with a past medical history of hypertension, pulmonary embolism, and ovarian carcinoma presented to the ED with hypotension, vomiting and two syncopal episodes. Over the prior three weeks the patient reported diminished appetite and poor oral intake secondary to persistent nausea and vomiting. She denied any abdominal pain and reportedly was having normal bowel movements and flatus. Upon arrival to the ED, she had a blood pressure of 94/72mm Hg and a heart rate of 112 beats per minute. On physical exam, the patient was ill appearing and frail. Her abdomen was distended without peritoneal signs. In the ED, the patient remained hypotensive and therefore a POCUS was performed using the Rapid Ultrasound in Shock and Hypotension (RUSH) protocol.⁶ The ultrasound showed no evidence of cardiogenic shock, a flat inferior vena cava, and free intraperitoneal fluid. While attempting to visualize the splenorenal fossa, a distended

stomach was visualized. (Image 1b)

The gastric contents layered in a meniscal fashion, appearing like a black-and-white cookie. (Image 1a) There was no evidence of dilated bowel or bidirectional peristalsis to suggest a bowel obstruction. With concern for a distended stomach and abdominal free fluid without further evidence of bowel obstruction, a CT was ordered to further evaluate for gastric obstruction. The CT showed a dilated, fluid-filled distal esophagus and stomach consistent with GOO. The obstruction was secondary to loculated ascites and peritoneal carcinomatosis from the patient's metastatic ovarian cancer. A nasogastric tube was placed, draining more than two liters of stomach contents. The patient was admitted to the hospital for further evaluation. The gastroenterology, oncology and surgical services were consulted. After a family meeting the patient went home with hospice services.

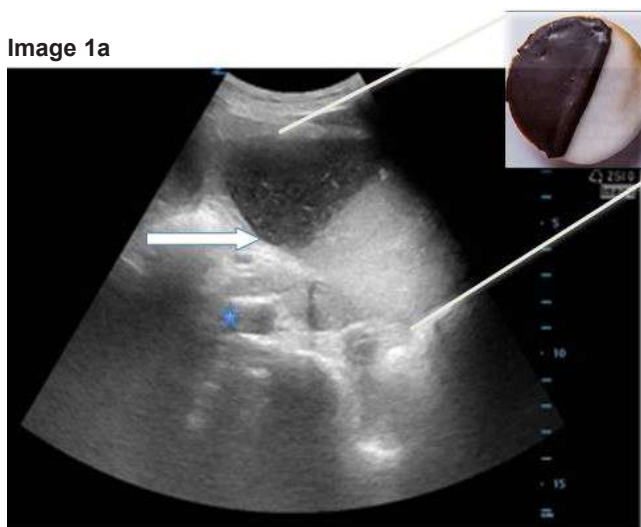


Image 1a

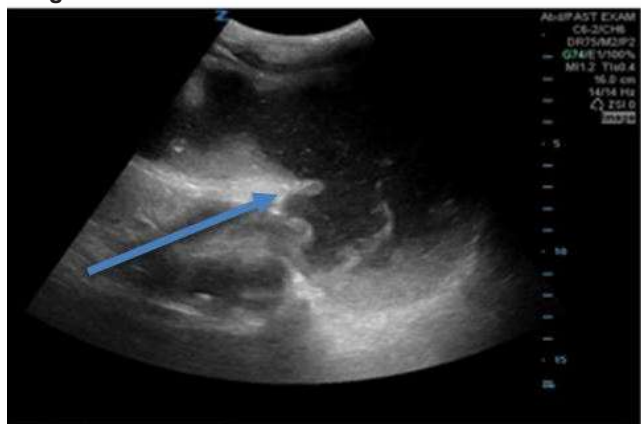


Image 1ab. a) Sagittal orientation point-of-care ultrasound (POCUS) with “black-and-white cookie” sign seen by white arrow with division of stomach contents. Inferior vena cava (blue star) seen distal to the stomach; b) POCUS of dilated, fluid-filled stomach with thickened stomach wall (blue arrow).

CPC-EM Capsule

What we already know about this clinical entity?

Gastric outlet obstruction (GOO) is a rare clinical condition occurring as a consequence of numerous processes that prevent gastric emptying.

What makes this presentation of disease reportable?

In this case series, we describe how point-of-care ultrasound (POCUS) was used to demonstrate common findings in three separate patients presenting with GOO.

What is the major learning point?

In all three patients, the stomach had a very distinct appearance on POCUS resembling a black-and-white cookie. This appearance was caused by a division of solid particles and gastric secretions within the stomach cavity.

How might this improve emergency medicine practice?

With improved availability, POCUS is often being used as a key tool for evaluation of bowel pathology. Emergency providers need to have a heightened awareness of GOO to ensure proper diagnosis and treatment. Although computerized tomography remains the standard diagnostic modality, the use of POCUS could represent a promising imaging alternative.

Case 2

A 71-year-old-male with a past medical history of coronary artery disease, hypertension, and newly diagnosed liver tumors presented to the ED with increased weakness, lower extremity edema, diminished appetite, nausea and vomiting. He denied any fever, abdominal pain or diarrhea. Upon arrival, the patient was found to be hypotensive with a blood pressure of 52/37mmHg, a heart rate of 80 beats per minute and oxygen saturating 100% on room air. On physical exam, the patient was ill appearing and with signs of acute distress and shock. The patient had dry mucous membranes, icteric sclera, clear lungs, lower extremity edema and a distended but soft abdomen. He was started on broad-spectrum antibiotics and given aggressive intravenous hydration. A POCUS demonstrated free intraperitoneal fluid (Image 2a), no evidence of interstitial pulmonary edema, and again a large, dilated stomach with a black-and-white cookie appearance (Image 2b), without evidence of small bowel

obstruction. Although the patient denied any abdominal pain, the ultrasound results prompted the emergency physician (EP) to order a CT of the abdomen. The CT showed GOO with a dilated stomach with extrinsic compression of the duodenum due to mass effect from hepatomegaly and ascites. The patient was admitted to the medical intensive care unit (MICU) for blood pressure support, palliative care consult and further care. In the MICU a family meeting took place and the patient was made hospice care only. The patient expired four days later.

Case 3

A 69-year-old-woman with a history of hypertension, breast cancer and cholangiocarcinoma with an indwelling percutaneous biliary drain presented to the ED after an episode of coffee ground emesis associated with acid reflux symptoms. The patient

complained of constipation, decreased appetite and weight loss. She denied any hematochezia and reported a normal last bowel movement. In the ED, the patient was frail appearing with a blood pressure of 100/60 mm Hg and a heart rate of 105 beats per minutes. On physical examination, the patient was jaundiced with scleral icterus. The abdomen was not tender but distended and firm with hyperactive bowel sounds. A biliary drain was also present without surrounding erythema or visible signs of infection. A rectal exam was negative for blood or presence of melena. A POCUS was performed showing a dilated stomach (Image 3a) without further evidence of bowel obstruction. Again, the stomach had the black-and-white cookie appearance on POCUS (Image 3b).

A CT scan of the abdomen displayed a dilated stomach with abrupt caliber change secondary to a porta hepatis mass

Image 2a

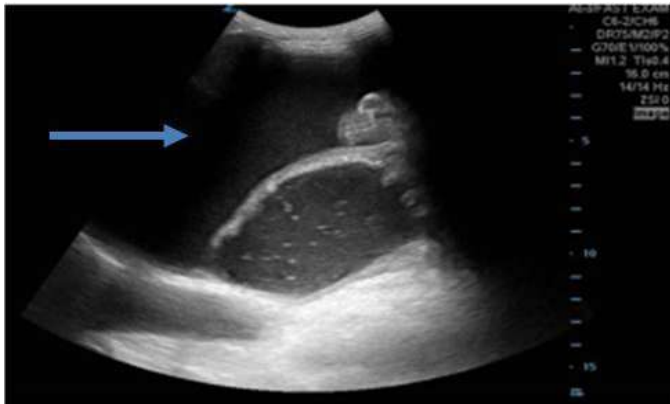

Image 2b

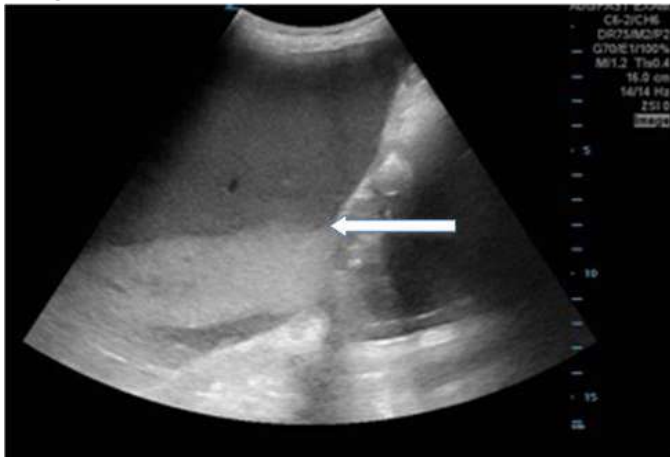


Image 2ab. a) Point-of-care ultrasound (POCUS) with dilated stomach and surrounding intraperitoneal free fluid (blue arrow); b) POCUS with "black-and-white cookie" sign seen by white arrow with division of stomach contents.

Image 3a

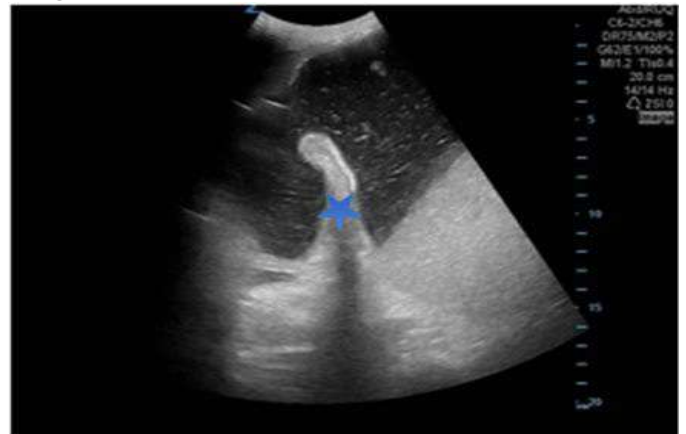

Image 3b

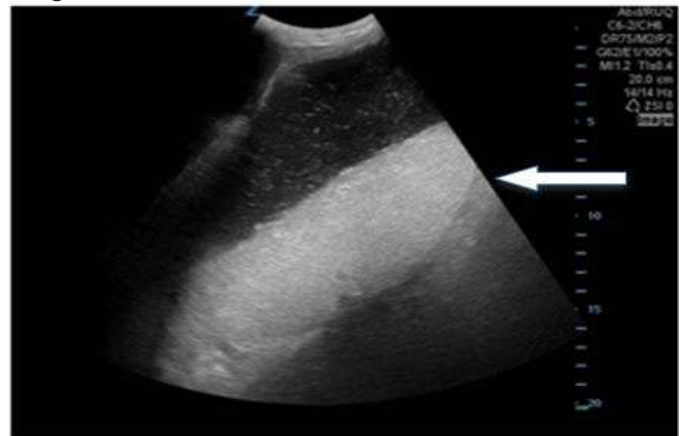


Image 3. a) Point-of-care ultrasound (POCUS) with dilated stomach with visible stomach fold (blue star) and bidirectional flow of stomach contents; b) POCUS with "black-and-white cookie" sign seen by white arrow with division of stomach contents.

extending to the pancreas causing a GOO. A nasogastric tube was placed in the ED draining approximately 1,500ml of gastric contents. The patient was admitted to the surgical service for further management and gastroenterology consult. During her hospital stay the patient had a metal stent placed to treat the GOO. The patient improved and was discharged home with gastroenterology and oncology follow-up.

DISCUSSION

POCUS is an invaluable tool to enhance decision-making in all patients and especially those that are critically ill. The incorporation of POCUS for patients with undifferentiated shock and hypotension is a well-validated tool to improve diagnostic accuracy and guide goal-directed treatments.⁷ Implementing protocols for goal-directed ultrasound with undifferentiated hypotension has been shown to increase physician accuracy and improve time to diagnosis.⁸ All three patients in this series received a RUSH protocol ultrasound.

While performing the Focused Assessment of Sonography in Trauma component of the exam and evaluating the splenorenal interface, a prominent, fluid-filled structure was visualized anterior to the spleen with bidirectional flow of internal contents, and was identified as the stomach. The ultrasound was performed while the patient was in the supine position, using a low frequency Zonare curvilinear probe. The transducer was placed on the patient's left flank to obtain a coronal view of the splenorenal fossa. Once the left kidney was identified, the probe was fanned anteriorly to visualize a thin-walled, dilated, fluid-filled structure not containing plicae circularis or haustra, which was identified as the stomach. As the gastric antrum is the most easily visualized portion of the stomach and is commonly found anterior to the left lobe of the liver and posterior to the pancreas, it can be viewed by placing the transducer in the epigastric region in a sagittal orientation.⁹

As a dilated stomach cavity is often present with both GOO and small bowel obstructions, it is critical that the remaining bowel be evaluated in order to differentiate the two entities. In all three patients, the stomach had a very distinct appearance on POCUS resembling a black-and-white cookie. This appearance was caused by a hyperechoic meniscal layer of gastric contents that contained an internal division of anechoic as well as hyperechoic areas. This division is secondary to solid particles and gastric secretions moving towards the more dependent portions of the stomach, while less dense materials and gas separate and move anteriorly.¹⁰ Sonographic findings that should prompt further evaluation for possible GOO include a dilated and enlarged gastric cavity in a patient without further evidence of a bowel obstruction.

Currently there is minimal literature on ED diagnoses of GOO using POCUS in adults. Stomach size is variable and dependent on many factors including timing of last

meal. There is a paucity of research focusing on the use of POCUS in diagnosing and evaluating it for this pathology. A recent case report demonstrated the novel use of POCUS for identifying GOO; however, corroborating literature is limited.¹¹ Anesthesia as well as gastroenterology studies have focused on the use of ultrasound for evaluating the stomach volume and wall thickness to evaluate for aspiration risk during intubation, gastric malignancies and gastric emptying disorders. Prior studies have also focused on the predictive value of gastric fluid volume for identifying various pathologies. One study hypothesized that patients with increased gastric fluid, with an area greater than 10cm², had a greater likelihood of having either a gastric obstruction or duodenal ulcer.¹² All three patients evaluated in this case series had distended-appearing, large-volume stomachs without any evidence of bowel obstruction on POCUS.

GOO can be a challenging diagnosis to make in the ED. Its presenting symptoms of nausea, vomiting and cachexia are nonspecific and mimic many other illnesses. It is expected that the incidence of GOO will increase, as malignancy is now the most common etiology of new diagnoses. EPs need to have a heightened awareness of GOO to ensure proper diagnosis and treatment. Although the CT still remains the standard diagnostic modality for GOO, the use of POCUS could represent a promising imaging alternative. EPs should have an elevated suspicion for GOO in patients with a history of nausea, vomiting, known malignancy with a distended stomach on POCUS without further evidence of bowel distention or obstruction. As the use of POCUS has continued to advance, its application to bowel pathology has become more recognized and validated. The use of POCUS for diagnosing GOO is a novel technique that requires further study, but it has the potential to allow for more rapid diagnosis and management of this cohort of patients.

Address for Correspondence: Mathew Nelson, DO, North Shore University Hospital, Department of Emergency Medicine, 300 Community Dr, Manhasset, NY 11030. Email:XXX@xxx.com. Mnelson9@optonline.net.

Conflicts of Interest: By the CPC-EM article submission agreement, all authors are required to disclose all affiliations, funding sources and financial or management relationships that could be perceived as potential sources of bias. The authors disclosed none.

Copyright: © 2018 Cohen et al. This is an open access article distributed in accordance with the terms of the Creative Commons Attribution (CC BY 4.0) License. See: <http://creativecommons.org/licenses/by/4.0/>

REFERENCES

1. Taylor M., Lalani N. Adult small bowel obstruction. *Acad Emerg Med.* 2013;20(6):528-44.
2. Appasani S, Kochhar S, Nagi B, et al. Benign gastric outlet obstruction—spectrum and management. *Trop Gastroenterology.* 2011;32(4):259–66.
3. Nagaraja V, Eslick G, Cox M. Endoscopic stenting versus operative gastrojejunostomy for malignant gastric outlet obstruction—a systematic review and meta analysis of randomized and non-randomized trials. *J Gastrointest Oncol.* 2014;5(2):92-8.
4. Appasani S, Kochhar S, Nagi B, et al. Benign gastric outlet obstruction-spectrum and management. *Trop Gastroenterol.* 2011;32(4):259-66.
5. Miyazaki Y, Takiguchi S, Takahashi T, et al. Treatment of gastric outlet obstruction that results from unresectable gastric cancer: Current Evidence. *World J Gastrointest Endosc.* 2016;10:165-172.
6. Perera P, Mailhot T, Riley D, et al. The RUSH exam: rapid ultrasound in shock in the evaluation of the critically ill. *Emerg Med Clin North Am.* 2010;28(1):29–56.
7. Seif D, Perera P, Mailhot T, et al. Bedside ultrasound in resuscitation and the rapid ultrasound in shock protocol. *Crit Care Res Pract.* 2012;2012:503254.
8. Jones AE, Tayal VS, Sullivan D, et al. Randomized, controlled trial of immediate versus delayed goal-directed ultrasound to identify the cause of nontraumatic hypotension in emergency department patients. *Crit Care Med.* 2004;32(8):1703-8.
9. Putte P, Perlas A. Ultrasound assessment of gastric content and volume. *Brit J Anaesth.* 2014;113(1):12-22.
10. Perlas A, Chan V, Lupu C, et al. Ultrasound assessment of gastric content and volume. *Anesthesiology.* 2009;111(1): 82-89.
11. Gottlieb M, Nakitende D. Identification of gastric outlet obstruction using point-of-care ultrasound. *Am J Emerg Med.* 2017; 35:1207e1-1207e2.
12. Smiths R, Orth J. Gastric fluid detected by sonography in fasting patients: relation to duodenal ulcer disease and gastric-outlet obstruction. *AJR.* 1989;153:731-33.

Asymptomatic Hypotension in a Patient with Catheter-related Right Atrial Thrombus

Hillary E. Davis, MD, PhD*

Michael Lu, MD*

Scott J. Cameron, MD, PhD†

Ryan Bodkin, MD*

*University of Rochester Medical Center, Department of Emergency Medicine, Rochester, New York

†University of Rochester Medical Center, Department of Cardiology, Rochester, New York

Section Editor: Rick A. McPheeters, DO

Submission history: Submitted July 6, 2017; Revision received September 24, 2017; Accepted October 2, 2017

Electronically published January 9, 2018

Full text available through open access at http://escholarship.org/uc/uciem_cpem

DOI: 10.5811/cpem.2017.10.35608

Atrial thrombi can be a complication in patients with indwelling central-line catheters, and failure to diagnose can potentially be lethal. This condition is generally associated with profound hypoperfused states. Here we present a case of a 77-year-old female who arrived to our emergency department for evaluation of a leg laceration and was incidentally found to have a catheter-related right atrial thrombus using point-of-care ultrasound. [Clin Pract Cases Emerg Med.2018;2(1):26-30.]

INTRODUCTION

Long-term central venous catheters are often necessary for patients with chronic illnesses, providing repeated access for hemodialysis, blood tests, parenteral nutrition or delivery of intravenous medications. Thrombosis is a relatively common complication of central-venous indwelling catheters secondary to the turbulence their geometry invokes on the typical laminar adjacent flow.¹ Without intervention, thrombi can lead to vascular compromise by either growing substantial enough to occlude its native vessel or embolizing to another. Treatment either by anticoagulation therapy or systemic thrombolysis, or surgical thrombectomy is necessary to prevent acute decline. Patients typically present to the emergency department (ED) with overt signs of end-organ hypoperfusion. Here we present a rare case of an incidentally found catheter-related right atrial thrombus (CRAT).

CASE REPORT

A 77-year-old female presented to our ED from her assisted living center for evaluation of a right lower leg laceration. One hour prior to arrival, she struck her leg against her walker when attempting to use the toilet and sustained a laceration to the skin overlying her anterior tibia. She was brought immediately to the ED for evaluation. She had been in her usual state of health prior

to this episode. Her comorbidities included end stage renal disease (ESRD) on dialysis, hypertension, hypothyroidism, pulmonary embolism and pulmonary hypertension. She required two liters (L) of oxygen via nasal cannula at baseline, and her warfarin dosing had not changed for over six months. She had received her full course of dialysis the day prior through her 14-month-old right subclavian catheter without any incidents.

Upon emergency physician (EP) evaluation, she endorsed minimal pain at the wound. There was no active bleeding observed. She was afebrile (37.5 degrees Celsius) with a heart rate of 90 beats/minute, respiratory rate of 18 breaths/minute, blood pressure of 77/59 millimeters of mercury (mmHg), and an oxygen saturation of 93% on her home two L of oxygen. She denied any shortness of breath, palpitations, lightheadedness or chest pain. She continued to deny such even during periods of exertion such as ambulating, and she required no further increase in her oxygen level. Per prior documentation, her baseline systolic blood pressure ranged between 90 to 100 mmHg. Subsequent blood pressures over the following two hours included systolic blood pressures in the 50s mmHg; she continued to remain asymptomatic.

The patient's wound was closed without incident. She was given a 500 milliliter bolus of normal saline and five milligrams of midodrine without any noticeable effect

on her blood pressure. Subsequently ordered diagnostic studies were notable for an international normalized ratio (INR) of 2.9, a hematocrit of 31%, white blood count $14.8 \times 10^9/L$, lactate 1.7 millimoles/L and an anion gap of 13 milliequivalents/L. Electrolytes were grossly normal. The EP performed a point-of-care ultrasound (POCUS) echocardiogram to evaluate for a uremic pericardial effusion. A mass was observed in the right atrium on multiple views (Image 1).

Subsequently, a computed tomography angiogram chest demonstrated a catheter-associated right atrial thrombus along with a right lower lung pulmonary embolism (Image 2). Cardiology was called to evaluate the patient and suggested that her hypotension might be secondary to the reduced inflow into the right ventricle resulting in left ventricle underfilling. A complete echocardiogram demonstrated a reduced left ventricular end diastolic volume with normal ejection fraction between 55-75%, a stroke volume of 29.36 liters per square meters and a cardiac output of 4.27 liters per minute (L/M) (normal 5-7 L/M). The right ventricle ejection fraction was moderately reduced with right ventricular enlargement and septal flattening: "a positive D-sign." A tissue density mass measuring 4.0 x 3.7 centimeters attached to the right atrial free wall was also seen. An agitated saline study was negative for a right-to-left intracardiac shunt. Compared to a prior echocardiogram performed eight months earlier, there was an interval increase in estimated pulmonary artery pressures (from 60 to greater than 92 mmHg) and a new right atrial mass. Upon further investigation, the EP learned that the patient had recently changed her diet and she'd had one subtherapeutic INR one month prior.

The atrial thrombus was deemed too large for percutaneous suction thrombectomy. Patient declined surgical thrombectomy after a cardiac surgeon explained that her risk of mortality was extremely elevated. She was medically managed in the cardiac intensive care unit with a heparin drip and phenylephrine. Her pressor support was weaned and her blood pressure was 119/49 mmHg at the time of discharge. She returned to her assisted living center on midodrine and without any changes in her warfarin on hospital day 14.

DISCUSSION

We present a case of CRAT that was discovered incidentally by an EP while investigating the patient's asymptomatic hypotension. By detecting this pathology, the patient's course of care was significantly altered from what she might otherwise have experienced if she had been solely evaluated for her chief complaint.

The incidence of CRATs is not inconsequential. One prospective autopsy study demonstrated that mural thrombi were present in 29% of central lines.² Catheters placed

CPC-EM Capsule

What do we already know about this clinical entity?

Patients with central venous catheters are at risk for catheter-related right atrial thrombus (CRAT) and their associated complications such as pulmonary embolism, arrhythmias, and septic emboli.

What makes this presentation of disease reportable?

This case of CRAT was discovered secondary to the patient's asymptomatic hypotension leading to the finding of the patient being in cardiogenic shock.

What is the major learning point?

Always be suspicious of CRAT in patients with central venous catheters and do not ignore vital sign abnormalities.

How might this improve emergency medicine practice?

Emergency physicians might consider using point-of-care ultrasound echocardiograms more frequently for potential visualization of right atrial thrombi in patients with central venous catheters.

in the right atrium are particularly sensitive to thrombus formation and patients may not present with symptoms.³ This is particularly concerning as mortality from CRAT is high, ranging from 18% to 47%, and can be secondary to pulmonary embolism, arrhythmias, septic emboli, or even therapeutic interventions.^{4,5} CRATs are considered type B thrombi, meaning that they originate in the atrium itself and are usually secured to the atrial wall. This contrasts with their type A counterparts, which originate in the deep peripheral veins and mobilize, typically resulting in systemic emboli. Albeit pulmonary emboli are less likely to occur with type B thrombi, the simultaneous presence of a pulmonary embolism with an atrial thrombus is often a worse prognostic sign.⁶ Fourteen percent of hemodialysis-related CRATs will also have concomitant pulmonary emboli.⁷ However, a single pulmonary embolism in the right lower lobe, as in this case, would not likely be

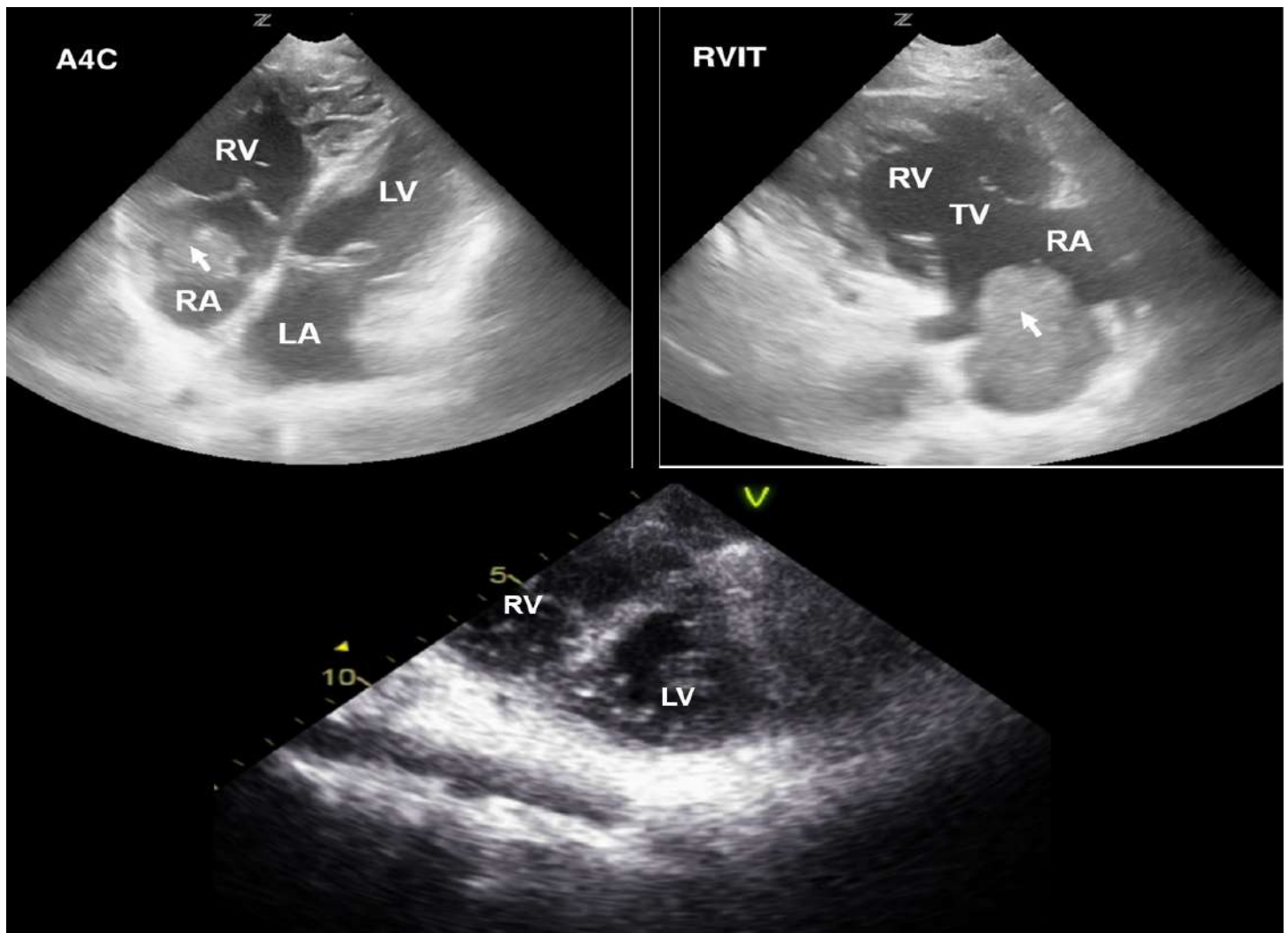


Image 1. Top: Point-of-care ultrasound echocardiogram. (left: apical 4-chamber view; right: right ventricle inflow tract view); right atrial mass is noted by the arrowhead. Bottom: Formal transthoracic echocardiogram, parasternal short-axis view, enlarged right ventricle with intraventricular septum flattening in diastole consistent with pressure overload. LA, left atrium; RA, right atrium; LV, left ventricle; RV, right ventricle; TV, tricuspid valve.

responsible for significantly decreasing left ventricle preload leading to the patient's profound hypotension.

Our patient experienced altered preload from right atrial obstruction consequent to the CRAT's substantial size. She was likely asymptomatic secondary to the slow accumulation of thrombus burden, providing time for the right heart to adapt. Further, her history of pulmonary hypertension would lead to a baseline of right heart strain and would likely mask new symptoms resulting from CRAT growth. A similar case of "compensated shock" secondary to type A right heart thrombi has been reported previously in which a 50-year-old male was evaluated for bilateral leg pain and, due to his asymptomatic tachycardia, a POCUS echocardiogram was performed leading to the ultimate diagnosis.⁸

The right atrium is not typically the focus of POCUS echocardiography, and is usually only partially visualized on the subxyphoid, apical-4-chamber (A4C), or high parasternal short views. Our patient's right atrial thrombus was identified on the right ventricle inflow tract (RVIT) view, which provides a more dedicated assessment of the right heart chambers and tricuspid valve. This view is obtained by placing the ultrasound probe in the parasternal long-axis position and tilting the beam anteriorly toward the chest wall (Image 3). Note the dilated, enlarged appearance of our patient's right ventricle in comparison to a normal RVIT appearance. Another important thing to point out is the appearance of the ventricles in the A4C view, as a dilated hypertrophied right ventricle may be mistaken for the left ventricle, especially

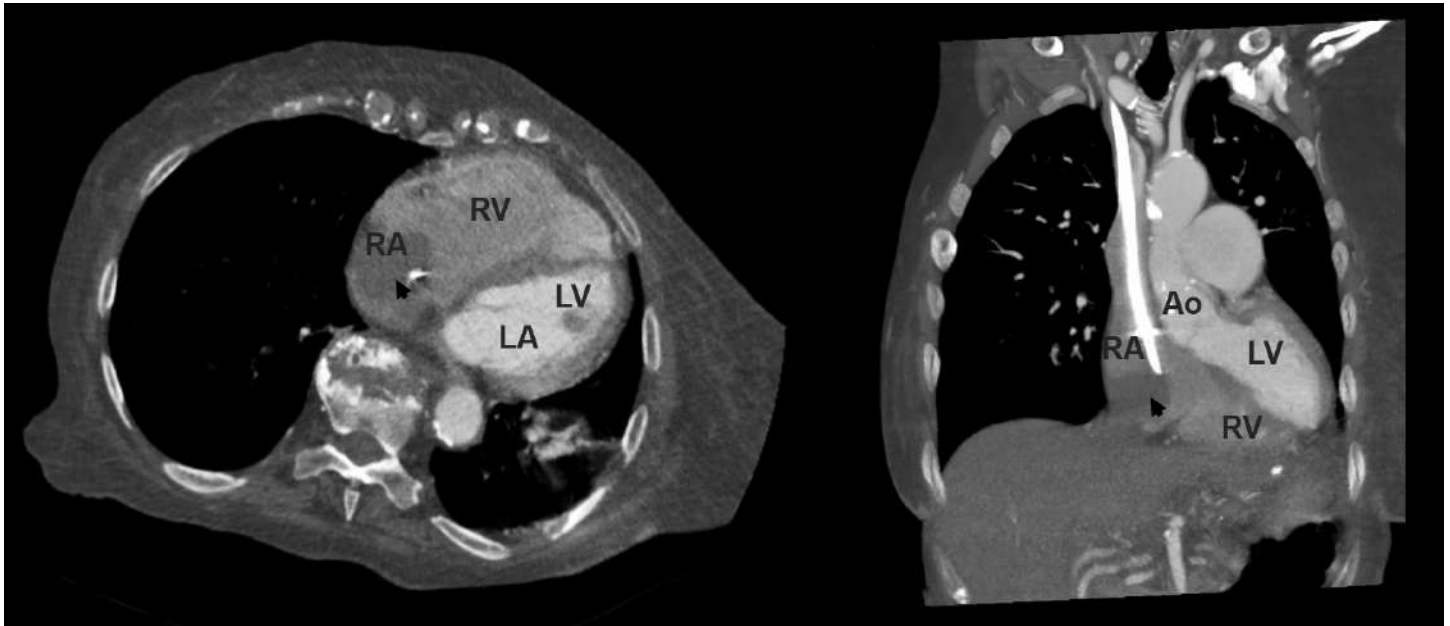


Image 2. Computed tomography angiogram of the chest. Left (cross section) Right (coronal section). Right atrial mass is noted by the arrowhead. Dialysis catheter tip noted as a bright white artifact within the thrombus. LA, left atrium; RA, right atrium; LV, left ventricle; RV, right ventricle; Ao, aorta.

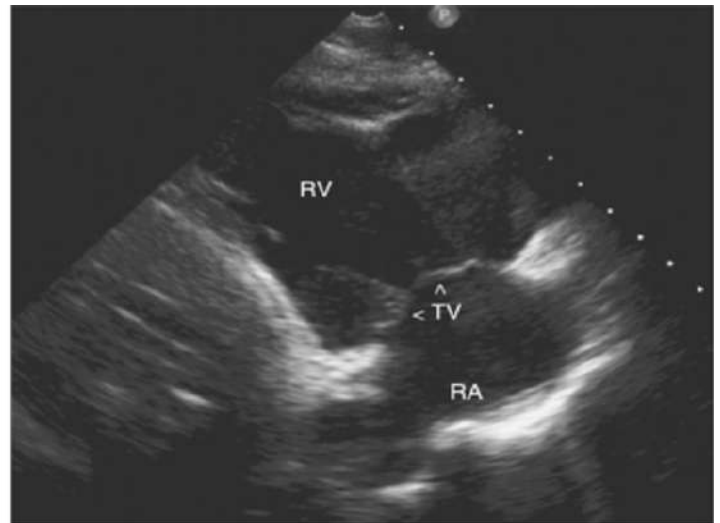
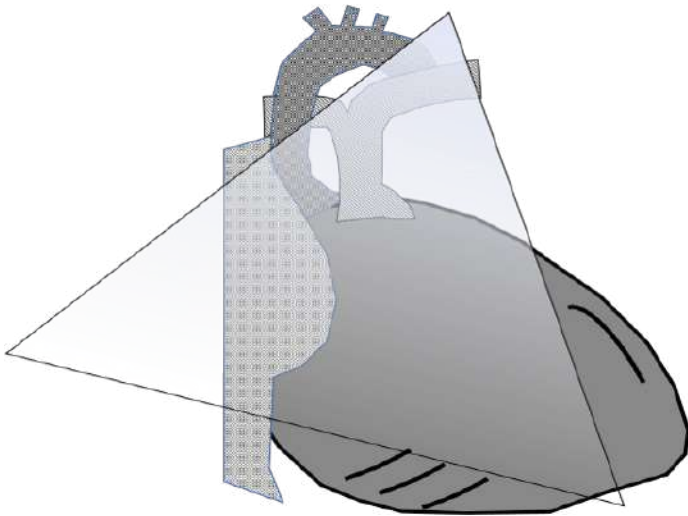


Image 3. Right ventricle inflow tract view. Left: Graphical representation. Right: Point-of-care ultrasound with normal anatomy. RA, right atrium; RV, right ventricle; TV, tricuspid valve.

if the probe is flipped. In addition to double-checking the machine settings and probe marker position, identifying the left ventricular outflow tract on the image and paying attention to which side it originates can help the POCUS provider differentiate between the right and left cardiac chambers.

Although the patient in this case was asymptomatic, it can be rationalized that she was in cardiogenic shock.

By strict definition, cardiogenic shock is defined as a low systolic blood pressure (<90 mmHg) in combination with a reduced cardiac output and adequate or elevated pulmonary wedge filling pressures.⁹ Per the patient's complete echocardiogram, her cardiac index would not meet the criteria to be considered for cardiogenic shock. However, a right heart catheter using the thermodilution method is

the most accurate method to discern cardiac index, as two-dimensional echocardiograms have been found to be a less reliable substitute.¹⁰

The Shock Index (SI = heart rate/systolic blood pressure) has been employed successfully as a means to predict mortality in patients with cardiogenic shock and in a general ED patient population.¹¹⁻¹³ Values for a SI ranging from 0.5-0.7 beats/minute/mmHg are considered normal, while values above 1.2 beats/minute/mmHg are associated with increased mortality. Our patient presented with a SI of 1.2 beats/minute/mmHg, which increased to 1.8 beats/minute/mmHg during her ED evaluation. Perhaps in the absence of pulmonary capillary wedge pressures, the SI can be employed in the ED to determine patients at risk for cardiogenic shock; however, further prospective trials are necessary for validation.

CONCLUSION

This is not the first case reported in literature using POCUS echocardiograms for visualization of right atrial thrombi; when used previously, the patients were in obvious states of end-organ hypoperfusion.^{8,14} Here we present an unusual presentation of CRAT in an asymptomatic patient that highlights the importance of noting abnormalities in vital signs. Given CRAT's high potential for morbidity and the relatively low risk and ease of obtaining a POCUS echocardiogram, we advocate that patients with a right heart catheter and vital sign abnormalities not attributed to another pathological state be evaluated in the ED for CRAT with a screening POCUS.

Address for Correspondence: Hillary E. Davis, MD, PhD, University of Rochester Medical Center, Strong Memorial Hospital, Department of Emergency Medicine, 601 Elmwood Ave, Box 655, Rochester, NY 14642. Email: hillary_davis@urmc.rochester.edu.

Conflicts of Interest: By the CPC-EM article submission agreement, all authors are required to disclose all affiliations, funding sources and financial or management relationships that could be perceived as potential sources of bias. The authors disclosed none.

Copyright: © 2018 Davis et al. This is an open access article distributed in accordance with the terms of the Creative Commons Attribution (CC BY 4.0) License. See: <http://creativecommons.org/licenses/by/4.0/>

REFERENCES

1. Baskin JL, Pui C-H, Reiss U, et al. Management of occlusion and thrombosis associated with long-term indwelling central venous catheters. *The Lancet*. 374(9684):159-69.
2. Ducatman BS, McMichan JC, Edwards WD. Catheter-induced lesions of the right side of the heart: A one-year prospective study of 141 autopsies. *JAMA*. 1985;253(6):791-5.
3. Gilon D, Schechter D, Rein AJJT, et al. Right atrial thrombi are related to indwelling central venous catheter position: Insights into time course and possible mechanism of formation. *Am Heart J*. 1998;135(3):457-62.
4. Asmarats L, Fernández-Palomeque C, Martínez-Riutort JM, et al. Right atrial thrombosis associated with hemodialysis catheter: first description of recurrence in a poorly understood problem. *J Thromb Thrombolysis*. 2015;39(2):254-7.
5. Kinney EL, Wright RJ. Efficacy of treatment of patients with echocardiographically detected right-sided heart thrombi: A meta-analysis. *Am Heart J*. 1989;118(3):569-73.
6. Burns KE, McLaren A. Catheter-related right atrial thrombus and pulmonary embolism: a case report and systematic review of the literature. *Can Respir J*. 2009;16(5).
7. Stavroulopoulos A, Aresti V, Zounis C. Right atrial thrombi complicating haemodialysis catheters. A meta-analysis of reported cases and a proposal of a management algorithm. *Nephrol Dial Transplant*. 2012;27(7):2936-44.
8. Jammal M, Milano P, Cardenas R, et al. The diagnosis of right heart thrombus by focused cardiac ultrasound in a critically ill patient in compensated shock. *Crit Ultrasound J*. 2015;7:6.
9. Califf RM, Bengtson JR. Cardiogenic Shock. *N Engl J Med*. 1994;330(24):1724-30.
10. Maeder MT, Karapanagiotidis S, Dewar EM, et al. Accuracy of echocardiographic cardiac index assessment in subjects with preserved left ventricular ejection fraction. *Echocardiography*. 2015;32(11):1628-1638.
11. Hemradj VV, Ottervanger JP, de Boer MJ, et al. Shock Index more sensitive than cardiogenic shock in ST-elevation myocardial infarction treated by primary percutaneous coronary intervention. *Circulation*. 2017;81(2):199-205.
12. Balhara KS, Hsieh Y-H, Hamade B, et al. Clinical metrics in emergency medicine: the shock index and the probability of hospital admission and inpatient mortality. *Emerg Med J*. 2017;34(2):89.
13. Awad HH, Anderson FA, Gore JM, et al. Cardiogenic shock complicating acute coronary syndromes: Insights from the Global Registry of Acute Coronary Events. *Am Heart J*. 2012;163(6):963-971.
14. Nelson EL, Greenwood-Ericksen M, Frasure SE. Point-of-care ultrasound diagnosis of a catheter-associated atrial thrombus. *J Emerg Med*. 2016;50(2):e75-e77.

Adhesive Closed-loop Small Bowel Obstruction

Matthew K. Edwards, MS
Christopher S. Kuppler, MD
Chasen A. Croft, MD
Hannah M. Eason-Bates, MD

University of Florida Health, Department of Emergency Medicine, Gainesville, Florida

Section Editor: Rick A. McPheeters, DO

Submission history: Submitted August 11, 2017; Revision received October 4, 2017; Accepted October 16, 2017

Electronically published January 9, 2018

Full text available through open access at http://escholarship.org/uc/uciem_cpccem

DOI: 10.5811/cpcem.2017.10.35927

Complete small bowel obstruction (SBO) is a common surgical emergency often resulting from adhesive bands that form following iatrogenic peritoneal injury. Rarely, adhesive SBO may arise without previous intra-abdominal surgery through other modes of peritoneal trauma. We present the case of a male evaluated in the emergency department for a closed-loop small bowel obstruction due to an adhesive band that likely formed after blunt abdominal trauma over two decades earlier. We review the epidemiology, pathophysiology, and treatment options for similar cases of adhesive SBO. [Clin Pract Cases Emerg Med. 2018;2(1):31-34.]

INTRODUCTION

Small bowel obstruction (SBO) is a common clinical entity in emergency medicine and globally remains an important source of morbidity and mortality. Approximately 65-75% of SBOs are due to peritoneal adhesions, aberrant fibrous bands within the abdominal cavity that constrict the intestine and disrupt its luminal flow.¹⁻² Peritoneal adhesions represent a considerable burden to patients and healthcare systems, annually causing more than 350,000 hospital admissions leading to over 960,000 days of inpatient care and \$2.3 billion in medical expenditures in the United States.³ Injury sustained during intra-abdominal surgery accounts for the majority of adhesions causing SBO, with the remainder often attributed to peritonitis or congenital formation.⁴ Rarely, however, adhesive SBO may occur without prior abdominal surgery through other modes of peritoneal injury. We examine the unusual case of a patient with a closed-loop SBO secondary to an omental band adhesion likely associated with a remote history of blunt abdominal trauma.

CASE REPORT

A 37-year-old male was evaluated in our emergency department for a 16-hour history of constant, cramping epigastric abdominal pain and nausea. His past medical history was significant for a pelvic fracture, suffered

during a motor vehicle collision (MVC) more than 20 years earlier, which required open reduction and internal fixation at the pubic symphysis. The patient reported no previous abdominal surgeries, recent abdominal injury, or history of acute or chronic intra-abdominal inflammation other than that likely associated with his remote abdominal trauma. He was otherwise in good health and did not use any regular medications.

The patient's vital signs were stable upon presentation, including heart rate of 75 beats per minute, oxygen saturation of 95%, respiratory rate of 14 breaths per minute, and temperature of 36.4 degrees Celsius. His physical examination was notable for dry mucous membranes, active bowel sounds, and tenderness in the epigastrium without abdominal guarding, distention, or palpable mass. During this evaluation, the patient experienced paroxysms of worsened abdominal pain that at times caused him to retch. The quality and location of his pain, along with his arrival to the hospital near midnight, raised our suspicion for an intestinal obstruction. The laboratory testing showed an elevated white blood count ($12.1 \times 10^9/\text{liter}$, normal $4.0\text{-}10.0 \times 10^9/\text{liter}$) and neutrophil fraction (81.8%, normal 40-80%). An abdomino-pelvic computed tomography (CT) with intravenous (IV) contrast revealed a distended stomach and several dilated loops of small bowel in the mid-abdomen, with multiple air-fluid levels and gradual decompression proximally and distally (Image).

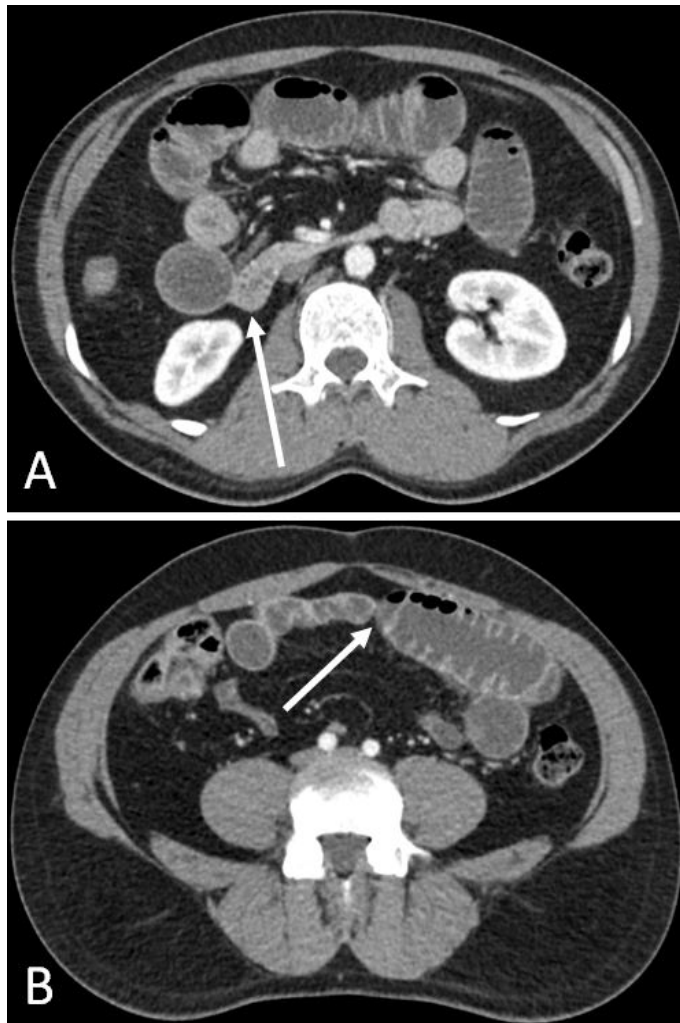


Image. Axial view of abdominal computed tomography images showing the proximal (A) and distal (B) transition points (arrows) of a small bowel obstruction.

There was no evidence of ischemia, but several bowel loops had inflammatory stranding and surrounding free fluid. The patient received IV isotonic fluid resuscitation and, following admission to the hospital, subsequently developed peritoneal signs. Due to concern for acute SBO with peritonitis, the patient underwent exploratory laparotomy later that day. He was found to have a fibrous band extending from the greater omentum to the jejunum, through which a 20 centimeter segment of decompressed bowel formed a closed-loop obstruction around which the jejunum was wrapped. After the entire length of the intestine was inspected and its viability was confirmed, the omental adhesion was divided and the bowel was released.

The patient's post-operative course was complicated by mild colonic ileus and a cellulitic incisional infection that resolved following a course of cephalexin. At follow-up on post-operative day 12, he was asymptomatic and had a normal physical examination.

CPC-EM Capsule

What do we already know about this clinical entity?

Complete small bowel obstruction (SBO) is a common surgical emergency often caused by adhesive bands that form after abdominal surgery or inflammatory disease.

What makes this presentation of disease reportable?

Our patient had no such history, and therefore the adhesive SBO likely resulted from blunt abdominal trauma sustained several decades prior.

What is the major learning point?

It is critical to obtain a thorough history of abdominal trauma from patients presenting with symptoms of obstruction yet lacking these common risk factors.

How might this improve emergency medicine practice?

Delaying surgery for complicated SBO increases its mortality; thus, recognizing unusual causes of obstruction may expedite intervention and improve patient outcomes.

DISCUSSION

Adhesions are the most common cause of SBO and thus create a substantial burden for patients and healthcare systems.¹⁻⁴ Adhesions may be congenital or acquired, arising either from inflammatory conditions including appendicitis, diverticulitis, or pelvic inflammatory disease, intraperitoneal infection, or abdominal trauma.⁵ The true proportions of each etiology vary among studies, though there is consensus that a majority of adhesions are due to abdominopelvic surgery.⁴⁻⁵ Greater than 93% of patients who have undergone transperitoneal surgery develop intra-abdominal adhesions.⁴ During surgery, damage to the peritoneum and its microvasculature causes a release of serosanguinous exudate that forms a fibrinous band connecting adjacent organs or injured serous membranes.⁴ Though adhesions ordinarily disintegrate within 72 hours, injury-induced ischemia may diminish fibrinolysis and allow the band to persist.⁴

Our patient's omental band adhesion was not likely the result of his prior pelvic surgery. The reduction and internal fixation of his pubic symphysis was entirely extraperitoneal and there was no evidence of screws transecting the peritoneum. Instead, we attribute his adhesive SBO to blunt abdominal trauma sustained during a remote MVC. Approximately 3-5% of patients treated for blunt abdominal trauma, commonly related to seatbelt use during MVCs, receive hollow viscus and mesenteric injuries.⁶⁻⁷ These injuries are inflicted either through deceleration and shearing of attachment points, particularly in fixed sections of the bowel like the proximal jejunum, or through compression against the vertebral column.⁷⁻⁸ Without uncontrolled bleeding or peritonitis, patients sustaining blunt abdominal trauma are managed conservatively, yet infrequently may develop adhesive SBO later.^{7,9}

Adhesions that are not broken down will mature within 10-14 days.⁵ Greater than 20% of adhesive obstructions occur within one month of injury, approximately 50% develop within 1-2 years, and occasionally obstructions may occur more than 10 years after trauma.^{5,10} The pathophysiology for the delay of obstructions following blunt abdominal trauma is not currently understood.

Adhesive SBO often presents similarly to other acute abdominal diseases, with symptoms including colicky abdominal pain, nausea, vomiting, abdominal distension, and obstipation.¹¹ On examination, the patient may appear dehydrated and have active, high-pitched bowel sounds, though abdominal auscultation generally has poor sensitivity and specificity for bowel obstruction.¹² Abdominal radiographs can help to identify SBO in 50-60% of cases and is often performed as the initial imaging tool because of its relatively low expense and radiation exposure.¹¹

However, CT of the abdomen is more useful for determining the location and etiology of a SBO, and therefore may be used instead of radiographs when this diagnosis is strongly suspected.¹³ Despite the inability of CT imaging to visualize most fibrous bands, it has a positive predictive value of 71% for adhesive SBO owing to the appearance of the transition zone made by the adhesion.¹³ Signs of compromised perfusion of the small bowel include tachycardia, focal abdominal tenderness, fever, and leukocytosis, though CT imaging remains the only reliable indicator of strangulation or ischemia.¹¹ Because clinical presentation, physical examination, and laboratory tests cannot accurately detect complications that require rapid surgery, CT imaging is also critical for guiding treatment course.¹⁴

Historically, patients suspected of having SBO secondary to adhesions underwent surgery immediately due to the uncertainty of strangulation.¹⁵ More recently, conservative therapy with administration of IV fluids, electrolyte supplementation, and nasogastric tube

decompression of the stomach has become the preferred initial management of adhesive SBO.¹¹ Non-operative treatment was shown to be successful in up to 80% of cases of uncomplicated partial SBO due to adhesions.⁵ Additionally, operative interventions are associated with significant risks including enterotomy, prolonged ileus, and recurrence of adhesions resulting from iatrogenic peritoneal injury.¹⁶ However, although guidelines exist, there is a lack of consensus within the literature and a paucity of evidence-supported criteria dictating which patients may be safely managed conservatively.¹⁵ Because delay in surgery for complicated SBO increases risk of mortality, many institutions still use early laparotomy, especially in patients without a history of intra-abdominal surgery.¹⁶

Early identification and treatment is particularly important in the case of a closed-loop obstruction, which can quickly progress to strangulation, ischemia, and necrosis.¹⁷ A closed-loop SBO forms when the lumen is blocked at two contiguous points, forming a segment of intestine with no outlet proximally or distally. Abdominal distension, the most common physical examination finding in patients with SBO, is minimal with closed-loop obstructions.¹ Furthermore, CT imaging lacks the specificity to distinguish closed loops.¹³ Many cases of closed-loop SBO therefore require exploratory surgery to make a diagnosis.

Our patient's clinical presentation was consistent with a SBO, including symptoms of nausea, abdominal tenderness, and dehydration, yet his medical history contained no commonly identified risk factors for adhesions. We followed our institution's standardized protocol by performing volume resuscitation and open surgery immediately after obtaining CT imaging findings consistent with obstruction and with the development of peritoneal signs consistent with bowel compromise.¹⁶ During the exploratory laparotomy, the patient was noted to have a single fibrous band forming a closed-loop SBO that threatened bowel strangulation, prompting lysis. Our protocol was successful in expediting surgical intervention for a case of complete bowel obstruction, abiding by current recommendations for operative management within 72 hours.¹⁶

CONCLUSION

Complete adhesive SBO is a common surgical emergency that requires rapid diagnosis to minimize complications. Patients presenting with adhesive SBO may rarely have no history of abdominal surgery or inflammatory disease, and thus may pose diagnostic uncertainty. Blunt trauma can create intra-abdominal adhesions, yet when old or trivial, may not be recognized as the cause. It is therefore imperative to take a thorough history of abdominal trauma from patients who present with symptoms consistent with obstruction.

Address for Correspondence: Matthew K. Edwards, MS, University of Florida Health, Department of Emergency Medicine, 1600 SW Archer Rd, Room H-2, Gainesville, Florida, 32610. Email: mkedwards@ufl.edu.

Conflicts of Interest: By the CPC-EM article submission agreement, all authors are required to disclose all affiliations, funding sources and financial or management relationships that could be perceived as potential sources of bias. Publication of this article was funded in part by the University of Florida Open Access Publishing Fund.

Copyright: © 2018 Edwards et al. This is an open access article distributed in accordance with the terms of the Creative Commons Attribution (CC BY 4.0) License. See: <http://creativecommons.org/licenses/by/4.0/>

REFERENCES

1. Markogiannakis H, Messaris E, Dardamanis D, et al. Acute mechanical bowel obstruction: clinical presentation, etiology, management and outcome. *World J Gastroenterol.* 2007;13(3):432-7.
2. Miller G, Boman J, Shrier I, et al. Etiology of small bowel obstruction. *Am J Surg.* 2000;180(1):33-6.
3. Sikirica V, Bapat B, Candrilli SD, et al. The inpatient burden of abdominal and gynecological adhesiolysis in the US. *BMC Surg.* 2011;11:13.
4. Attard JP, MacLean AR. Adhesive small bowel obstruction: epidemiology, biology and prevention. *Can J Surg.* 2007;50(4):291-300.
5. Liakakos T, Thomakos N, Fine PM, et al. Peritoneal adhesions: etiology, pathophysiology, and clinical significance. *Dig Surg.* 2001;18(4):260-73.
6. Bège T, Brunet C, Berdah SV. Hollow viscus injury due to blunt trauma: a review. *J Visc Surg.* 2016;153(4 Suppl):61-8.
7. Law CHL, Brennenan FD, Rizoli SB, et al. Post-traumatic small-bowel stricture: a case report. *Can J Surg.* 1996;39(1):57-8.
8. Harrison JR, Blackstone MO, Vargish T, et al. Chronic intermittent intestinal obstruction from a seat belt injury. *South Med J.* 2001;94(5):499-501.
9. Maharaj D, Perry A, Ramdass M, et al. Late small bowel obstruction after blunt abdominal trauma. *Postgrad Med J.* 2003;79:57-8.
10. Dijkstra FR, Nieuwenhuijzen M, Reijnen MMPJ, et al. Recent clinical developments in pathophysiology, epidemiology, diagnosis and treatment of intra-abdominal adhesions. *Scan J Gastroenterol.* 2000;35(Suppl 232):52-9.
11. Kulaylat MN, Doerr RJ. Small bowel obstruction. In: Holzheimer RG, Mannick JA, eds. *Surgical Treatment: Evidence and Problem-Oriented.* Munich: Zuckschwerdt. 2001.
12. Breum BM, Rud B, Kirkegaard T, et al. Accuracy of abdominal auscultation for bowel obstruction. *World J Gastroenterol.* 2015;21(34):10018-10024.
13. Petrovic B, Nikolaidis P, Hammond NA, et al. Identification of adhesions on CT in small-bowel obstruction. *Emerg Radiol.* 2006;12:88-93.
14. Kim JH, Ha HK, Kim JK, et al. Usefulness of known computed tomography and clinical criteria for diagnosing strangulation in small-bowel obstruction: analysis of true and false interpretation groups in computed tomography. *World J Surg.* 2004;28(1):63-8.
15. Baur J, Keeley B, Krieger B, et al. Adhesive small bowel obstruction: early operative versus observational management. *Am Surg.* 2015;81(6):614-20.
16. Loftus T, Moore F, VanZant E, et al. A protocol for the management of adhesive small bowel obstruction. *J Trauma Acute Care Surg.* 2015;78(1):13-21.
17. Beardsley C, Furtado R, Mosse C, et al. Small bowel obstruction in the virgin abdomen: the need for a mandatory laparotomy explored. *Am J Surg.* 2014;208(2):243-248.

Gastric Outlet Obstruction Caused by Foley Catheter: A Complication when Substituting for Commercial Gastrostomy Tubes

Sawlar Vu, MD*

Amanda B. Lewis, BS, PA-S†

Brooks Moore, MD**

*Emory University, Department of Emergency Medicine, Atlanta, Georgia

†Emory University, School of Medicine, Atlanta, Georgia

**Grady Memorial Hospital, Emergency Care Center, Atlanta, Georgia

Section Editor: Rick A. McPheeters, DO

Submission history: Submitted August 11, 2017; Revision received September 18, 2017; Accepted October 2, 2017

Electronically published January 9, 2018

Full text available through open access at http://escholarship.org/uc/uciem_cpem

DOI: 10.5811/cpem.2017.10.35930

The technique of using percutaneous endoscopic gastrostomy (PEG) for long-term enteral feeding is well established and commonly used. While the technique is relatively safe and simple, the gastrostomy tube itself may deteriorate or malfunction, requiring a replacement tube. We present a case of a 58-year-old woman who was found to have gastric outlet obstruction from the inflated balloon of a Foley catheter being used as a replacement for her PEG tube. This case illustrates a potential complication of using a Foley catheter in place of commercially available gastrostomy tubes. [Clin Pract Cases Emerg Med. 2018;2(1):35-38.]

INTRODUCTION

The technique of using percutaneous endoscopic gastrostomy (PEG) for long-term enteral feeding is well established and commonly used. While the technique is relatively safe and simple, the gastrostomy tube itself may deteriorate or malfunction, requiring a replacement tube. The emergency physician is often the first provider to encounter a patient after PEG tube malfunction. A common practice, appearing in the literature as early as 1992, has been to temporarily replace the malfunctioning or displaced PEG tube with a Foley catheter to avoid stoma closure or narrowing.¹ Foley catheters may be used if a commercial gastrostomy tube is not available or if a cheaper, temporary alternative is desired.^{2,3} While a recent large pediatric trial showed their successful utilization without severe complications, multiple case reports suggest the procedure is not without risk.⁴ This case report presents a patient who was initially identified as having an upper gastrointestinal bleed and was later found to have gastric outlet obstruction as a result of a migrating Foley catheter serving as a PEG replacement.

CASE REPORT

A 58-year-old African-American female with a history of traumatic brain injury presented to the emergency department (ED) from her nursing home after experiencing several episodes

of coffee-ground emesis that started on the day of presentation. She was noted to have three additional episodes of coffee-ground emesis mixed with maroon-colored clots in the ED but did not appear to be in distress. Past surgical history included the placement of a 25 French (Fr) PEG tube approximately one year prior. The PEG had been replaced by a Foley catheter at some point, but there was no available associated documentation.

On physical examination, she was normotensive (133/83 millimeters of mercury), tachycardic (109 beats per minute), and tachypneic with mildly increased work of breathing. She was afebrile and her oxygen saturation was greater than 95%. Her abdomen was distended, firm, and tender to palpation throughout. She demonstrated some guarding with no rebound. Normal bowel sounds were present and no hepatosplenomegaly was noted. Rectal exam revealed brown stool that was guaiac negative. The feeding tube site was clean and without erythema, with a Foley catheter entering the site secured by fenestrated gauze.

The patient was resuscitated following institutional treatment guidelines for sepsis. Laboratory data were within normal parameters except for a lactic acid of 4.2 mmol/L. In addition, there was some concern the patient may have had gastrointestinal obstruction or perforation. The patient was taken for computed tomography (CT) of the abdomen and pelvis with intravenous (IV) contrast. Imaging revealed

the Foley catheter traveling through the PEG tract with the balloon resting in the gastric antrum. The stomach was filled with fluid, the small bowel was unremarkable, and the colon was diffusely distended with air-fluid levels and no transition zone (Image 1 and 2).

The Foley balloon was deflated, pulled back, and re-inflated. Following retraction of the Foley catheter, the patient did not experience any further episodes of emesis. The patient was admitted to the inpatient medicine service for urgent endoscopy and observation. The next day the patient underwent endoscopy during which the Foley catheter was replaced with a 20 Fr PEG tube. The lactic acidosis resolved with IV hydration, and no source of bleeding was identified.

DISCUSSION

PEG is a widely performed procedure and remains the procedure of choice for providing enteral access for nutritional support for adults. There are several risks and complications that should be considered before tube placement. In published meta-analyses and case series, PEG tube placement is associated with notable patient morbidity (9% - 17%) and mortality (0.53%).⁵ Major complications after tube placement occur in 1-3% of cases and include aspiration pneumonitis, peritonitis, hemorrhage, tube migration, fistula, wound infection and necrotizing fasciitis, tube leakage, tube blockage, and inadvertent removal of PEG.⁵

Many professional organizations have guidelines for the use of PEG tubes, but almost none address the use of replacement Foley catheters. In 2008 the Canadian Agency for Drugs and Technologies in Health and their Health Technology Inquiry Service conducted a review of the

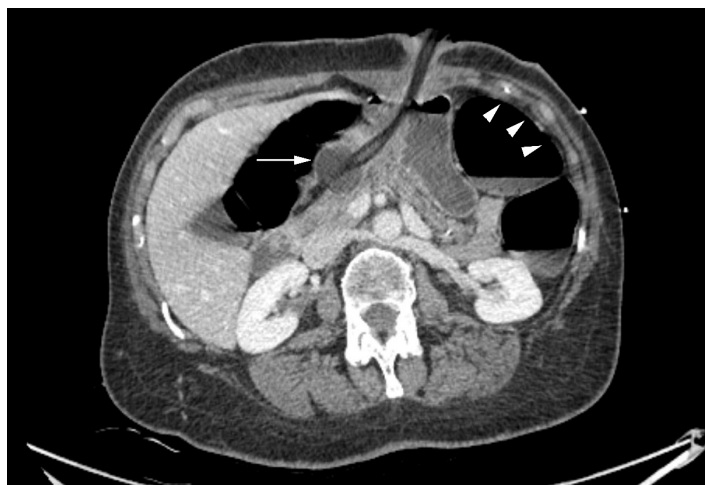


Image 1. Computed tomography of the abdomen and pelvis, axial view, demonstrating the Foley catheter with balloon in the gastric antrum (arrow), with resulting gastric outlet obstruction and colonic distension (arrowheads).

CPC-EM Capsule

What do we already know about this clinical entity?

Foley catheters are frequently used by emergency medicine providers as placeholders or temporary replacements for damaged or displaced percutaneous endoscopic gastrostomy (PEG) tubes

What makes this presentation of disease reportable?

This is a unique complication of replacement Foley catheter use, presenting as a gastrointestinal bleed secondary to gastric outlet obstruction.

What is the major learning point?

While “cheap” and widely available, Foley catheters used in lieu of commercial PEG tubes can be associated with varied complications. Consider using a replacement with a bolster.

How might this improve emergency medicine practice?

Foley catheter complication should be considered in evaluation of the appropriate patient who presents with signs of bowel obstruction and GI bleed.

guidelines and clinical evidence for using Foley catheters for gastrostomy or jejunostomy feeding tubes. They concluded that “no relevant health technology assessments, systematic reviews, meta-analyses, or randomized controlled trials were identified examining clinical effectiveness or potential risk or harms of using Foley catheters versus conventional gastrostomy or jejunostomy feeding tubes in adult inpatients requiring enteral feeding.”⁶ Other leading organizations, including the American Society for Parenteral and Enteral Nutrition, the American Society for Gastrointestinal Endoscopy, and the American Gastroenterological Association, fail to address the specific use of Foley catheters as replacement tubing.⁶ The Wound, Ostomy and Continence Nurses Society™ is the only organization that clearly discourages the use of Foley catheters in enteral feeding and highlights that the Foley catheter is associated with higher complication rates than standard commercially available tubing.⁶

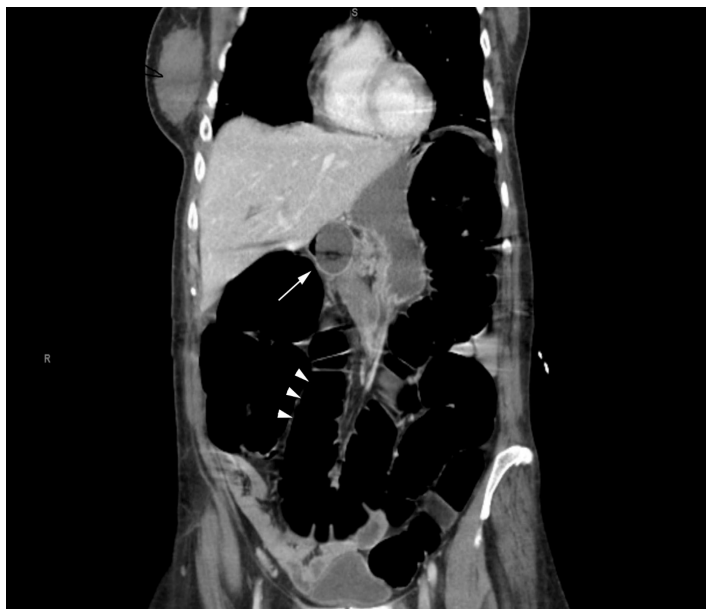

Image 2. Computed tomography of the abdomen and pelvis, coronal view, demonstrating the Foley catheter with balloon in the gastric antrum (arrow), with resulting gastric outlet obstruction and colonic distension (arrowheads).

There are several other reviews and reports that indicate complications associated with the specific use of Foley catheters in enteral feeding. In a study comparing three different types of feeding tube replacements, the Foley catheter was associated with increased incidence of breakage, leakage, and migration.⁷ There are also multiple case reports of pancreatitis and intussusception from Foley catheters used as feeding tubes, often caused by catheter migration.⁸⁻¹⁰ Peristalsis-induced migration has also been implicated in other cases of gastric outlet obstruction, often involving the duodenum and other small bowel.¹¹⁻¹⁸

Some researchers have indicated that complications may be minimized if specific precautions are taken to secure Foley catheters. One prospective randomized trial that compared the Foley catheter as a replacement for commercial gastrostomy tubes in 46 patients found the Foley to function well and showed a low incidence of balloon rupture and no cases of bowel obstruction in the Foley group.³ Study personnel specifically secured the tubes with self-made retention rings. Other studies suggest that user error, not the catheter itself, is accountable for complications.¹⁹

CONCLUSION

Emergency physicians should be aware of the multiple complications of Foley catheters being used as replacements for PEG tubes. We hope that this case study contributes to the growing body of evidence of Foley balloon-associated

gastrointestinal obstruction in PEG-dependent patients. Awareness of this complication enables the emergency physician to potentially treat this condition completely and immediately and avoid serious subsequent complications.

Address for Correspondence: Sawlar Vu, MD, Emory University, Department of Emergency Medicine, 49 Jesse Hill Jr. Drive SE, Atlanta, GA 30303. Email: svu@emory.edu.

Conflicts of Interest: By the CPC-EM article submission agreement, all authors are required to disclose all affiliations, funding sources and financial or management relationships that could be perceived as potential sources of bias. The authors disclosed none.

Copyright: © 2018 Vu et al. This is an open access article distributed in accordance with the terms of the Creative Commons Attribution (CC BY 4.0) License. See: <http://creativecommons.org/licenses/by/4.0/>

REFERENCES

1. Kadakia SC, Cassaday M, Shaffer RT. Prospective evaluation of Foley catheter as a replacement gastrostomy tube. *Am J Gastroenterol.* 1992;87(11):1594-7.
2. Shah AM, Shah N, Depasquale JR. Replacement gastrostomy tube causing acute pancreatitis: case series with review of literature. *JOP.* 2012;13(1):54-7.
3. Kadakia SC, Cassaday M, Shaffer RT. Comparison of Foley catheter as a replacement gastrostomy tube with commercial replacement gastrostomy tube: a prospective randomized trial. *Gastrointest Endosc.* 1994;40(2 Pt 1):188-93.
4. Kiatipunsodsai S. Gastrostomy tube replacement using Foley's catheters in children. *J Med Assoc Thai.* 2015;98 Suppl 3:S41-5.
5. Potack JZ, Chokhavatia S. Complications of and controversies associated with percutaneous endoscopic gastrostomy: report of a case and literature review. *Medscape J Med.* 2008;10(6):142.
6. Polisena J, Severn M. Foley Catheters For Gastrostomy Or Jejunostomy Feeding Tubes: A Review Of The Guidelines And Clinical Evidence. Health Technology Inquiry Service. 2008.
7. Hicks ME, Surratt RS, Picus D, et al. Fluoroscopically guided percutaneous gastrostomy and gastroenterostomy: analysis of 158 consecutive cases. *AJR Am J Roentgenol.* 1990;154(4):725-8.
8. Bui HD, Dang CV. Acute pancreatitis: a complication of Foley catheter gastrostomy. *J Natl Med Assoc.* 1986;78(8):779-81.
9. Ibegbu E, Relan M, Vega KJ. Retrograde jejuno-duodenogastric intussusception due to a replacement percutaneous gastrostomy tube presenting as upper gastrointestinal bleeding. *World J Gastroenterol.*

- 2007;13(39):5282-4.
10. Shah AM, Shah N, Depasquale JR. Replacement gastrostomy tube causing acute pancreatitis: case series with review of literature. *JOP*. 2012;13(1):54-7.
 11. Barosa R, Santos C, Fonseca J. Gastric outlet obstruction: an unusual adverse event of percutaneous endoscopic gastrostomy. *Rev Esp Enferm Dig*. 2016;108(1):53-4.
 12. Date RS, Das N, Bateson PG. Unusual complications of ballooned feeding tubes. *Ir Med J*. 2002;95(6):181-2.
 13. Gowen GF. The management of complications of Foley feeding gastrostomies. *Am Surg*. 1988;54(9):582-5.
 14. MCGovern R, Barkin JS, Goldberg RI, et al. Duodenal obstruction: a complication of percutaneous endoscopic gastrostomy tube migration. *Am J Gastroenterol*. 1990;85(8):1037-8..
 15. O'keefe KP, Dula DJ, Varano V. Duodenal obstruction by a nondeflating Foley catheter gastrostomy tube. *Ann Emerg Med*. 1990;19(12):1454-7.
 16. Netz U, Perry ZH, Mizrahi S. The lost foley catheter. *Am Surg*. 2012;78(9):E407-8.

Novel Use of Ophthalmic pH Paper to Diagnose Malicious Caustic Ingestion in a Pediatric Patient

Neal P. Johnson, MD
Eric C. Bruno, MD

University of Tennessee College of Medicine, Saint Thomas Rutherford Hospital,
Department of Emergency Medicine, Murfreesboro, Tennessee

Section Editor: Rick A. McPheeters, DO

Submission history: Submitted September 11, 2017; Revision received November 28, 2017; Accepted November 29, 2017

Electronically published January 9, 2018

Full text available through open access at http://escholarship.org/uc/uciem_cpccem

DOI: 10.5811/cpcem.2017.11.36367

Occult caustic ingestion in the pediatric population is a challenging diagnosis to make in the emergency department. Failure to suspect and diagnose a caustic ingestion can lead to potentially life-changing comorbidities. Historically, the diagnosis of caustic ingestion has been clinical without any suitable diagnostic tools to aid in the suspicion of occult cases. In this case, we describe a novel use of ophthalmic pH paper to diagnose caustic ingestion in a three-year-old. [Clin Pract Cases Emerg Med. 2018;2(1):39-42.]

INTRODUCTION

According to the National Poison Data System, in 2015 there were 2.2 million potentially toxic exposures reported to United States poison centers; of those, about half were among children less than five years of age.¹ The clinical gestalt of the emergency physician may be the only hope a child has in the setting of a malicious ingestion. Recognition and intervention are critical to preventing acute and chronic life-changing morbidities. We present an innovative way of using ophthalmic pH paper to identify caustic ingestion in a three-year-old boy.

CASE REPORT

A three-year-old male with a significant past medical history of speech delay presented to an urban emergency department (ED) via ambulance with symptoms of facial edema and erythema. Before the patient's arrival, the emergency medical services (EMS) providers relayed through the medical communications center that the patient was en route and symptoms were consistent with an acute allergic reaction, likely due to first exposure to Chinese food and dark chocolate that day.

Upon arrival, the patient had right facial erythema with lingual edema and erythema. There was mild pharyngeal erythema without pharyngeal edema or stridor. Initial vital signs were heart rate 142 beats per minute, temperature 36.2 degrees Celsius, respirations 26 per minute, and oxygen saturation 100% on room air. A blood pressure was not

recorded. Prior to the onset of symptoms, the patient was not taking any routine medications, nor had he been exposed to new medications. Based on exam and history provided by the mother, maternal grandmother, and EMS, intravenous (IV) access was obtained, and weight-based dosing of diphenhydramine was administered.

During the observational period in the ED the patient remained inconsolable, most likely secondary to pain. He continued to keep his mouth in an open position with occasional episodes of gagging and drooling. The patient was witnessed vomiting colorless emesis, with occasional blood-streaked emesis. He subsequently had a significant increase in the amount of drooling. Upon a more thorough inspection of the oropharyngeal cavity, the patient was noted to have erythema and ecchymosis on the inside of the right upper and lower lip regions.

Due to suspicions about the provisional diagnosis, the attending physician decided to perform a pH test of the emesis, using a pH strip ordinarily used for ophthalmological pH testing. The pH strip indicated a pH of 9. The focus of the patient's care plan immediately shifted to the evaluation of a patient with a caustic ingestion. After consultation with the pediatric intensive care unit (PICU), a presumptive plan for nil per os (NPO) and endoscopy were discussed. The patient was transferred to an affiliated tertiary care facility.

The admitting PICU team considered the initial diagnosis of allergic reaction more likely and therefore proceeded with treatment for an allergic reaction, which did provide some

improvement in the patient's oral labial edema. Approximately two days after the patient's initial presentation to the ED, he underwent an upper endoscopy because he continued to refuse to eat or drink. Endoscopy revealed grade 2b findings (see Table) in the esophagus and gastric cardia. Based on the endoscopic findings the diagnosis was changed to a caustic ingestion. The patient remained hospitalized, was placed on NPO and received a peripherally inserted central catheter for total parenteral nutrition; he was given IV fluids, placed on a proton pump inhibitor, sucralfate, and ranitidine. Antibiotic prophylaxis was given with ampicillin/sulbactam and steroids were started. Over his hospital course, his diet was slowly advanced. He was eventually discharged home after one week when tolerating a soft diet. Although the family initially denied potential ingestion, it was later discovered that the patient was a victim of non-accidental trauma, where one of the family members forced him to ingest an industrial bleach compound in an attempt to stop the child's crying.

DISCUSSION

In the Western world, alkaline material accounts for most caustic ingestions injuries.¹ Esophageal injury can begin within minutes and may continue for hours. These burns can lead to chronic complications such as esophageal strictures, reported between 2%-63% of cases, and increased incidence of esophageal cancer, reported in 18%-46% of cases.³⁻⁷

Acids and alkalis create tissue damage differently. Acids usually cause coagulation necrosis leading to eschar formation and limited deep tissue penetration. Alkalis tend to cause liquefactive necrosis and thrombosis in blood vessels leading to the destruction of deeper tissues. Both acids and alkalis can penetrate the esophageal wall rapidly and can cause full-thickness damage. The degree of severity of gastrointestinal injury due to caustic ingestion is associated with several factors including the pH of the agent, physical state (solid, liquid, or powder), tissue exposure time, and quantity or concentration of the substance. The pH of standard liquid industrial bleaches, detergents, and phosphates ranges from 9 to 11. Gastrointestinal injury of caustic origin is linked to high rates of morbidity and mortality.⁸

Table. Endoscopic grading of esophageal injuries (reproduced from Zargar et al,²)

Grade	Features
Grade 0	Normal mucosa
Grade 1	Superficial mucosal edema and hyperemia
Grade 2A	Superficial erosions, exudates and ulcerations
Grade 2B	Deep discrete or circumferential ulcerations
Grade 3A	Small scattered areas of focal necrosis
Grade 3B	Extensive necrosis

CPC-EM Capsule

What do we already know about this clinical entity?

The use of pH paper has been validated measuring intragastric pH, but little is known about its usefulness in measuring the pH of emesis, especially in suspected ingestion.

What makes this presentation of disease reportable?

This is the first report of ophthalmic pH paper being used to diagnose an occult caustic ingestion.

What is the major learning point?

Early diagnosis of caustic ingestion and esophageal injury helps to initiate appropriate therapy, anticipate airway intervention, and decrease overall morbidity.

How might this improve emergency medicine practice?

pH paper should be stocked in every ED and is a quick, simple, and inexpensive test that can lead to a rapid diagnosis and faster implementation of treatment.

The pH of gastric acid in the stomach of children is typically less than 4.0.⁹ One study measured regional postprandial differences in pH within the stomach and gastroesophageal junction on various types of foods. After 27 hours of monitoring the highest pH at any region was 5.4.¹⁰ Emesis should yield a moderately acidic result. If this emesis is tested with a pH paper, it should indicate an acidic state (pH <7). However, when high quantities or concentrations of basic substances are exposed to gastric acid, it is proposed that the pH should be buffered (pH ~7) or basic (greater than 7) (Image). pH-tested emesis with a neutral or basic pH should raise concern for possible alkaline ingestion; however, an acidic pH does not rule out an alkaline ingestion. Litmus paper has been shown to be sensitive and specific for measuring intragastric pH when compared to gastric samples taken from a nasogastric pH probe.¹¹ Although easy to use, clinicians should be aware that pH measurement errors can occur from excessive wetting of the paper, small sample sizes, allowing drying of the paper, and using expired litmus paper. Some reports advocate the use of a control when doing any litmus test; however, this would be difficult to do with emesis.¹²

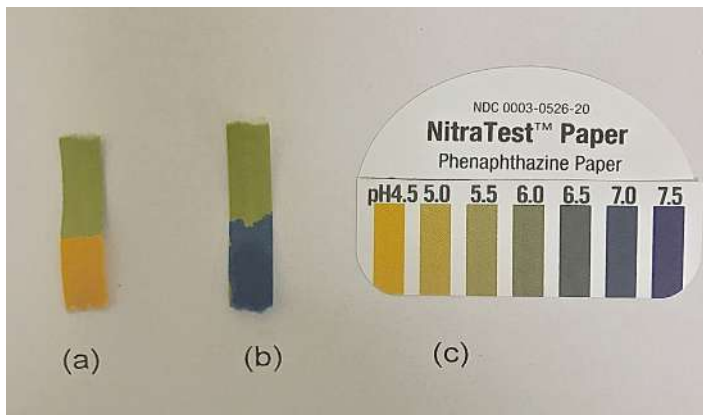


Image. NitraTest™ Paper tested on emesis of a pediatric patient (a), emesis of the same pediatric patient mixed with industrial drain cleaner comprised of 90% emesis and 10% drain cleaner (b), and control strip (c).

Pediatric patients who are unable to give a reliable history and present with emesis and oral burns from an unknown ingestion or from a substance known to cause esophageal or gastric injury, should have an esophagogastroduodenoscopy (EGD) performed early. In this case, as well as other caustic ingestions, early EGD is considered crucial and recommended within the first 12-48 hours.¹³ Endoscopic classification is important in determining prognosis and management. A grading system has been adopted based on visualization during endoscopy and helps to predict clinical outcomes (*Table*).¹⁴ Huang et al. reported that all patients with grade two and three injuries developed esophageal strictures.¹⁵ Early esophageal dilatation is recommended to improve the outcome of esophageal injury and reduce the number of patients developing esophageal stricture.¹⁶

Early ED management is important not only for acute intervention but also for helping establish a treatment course that can ultimately lead to fewer long-term complications. Early management includes airway assessment and hemodynamic stabilization. For patients with persistent vomiting and severe oropharyngeal injury, airway protection is vital, and early intubation should be considered. Fiberoptic laryngoscopy can allow direct visualization versus a “blind” intubation, which increases the risk of additional injuries. Blind placement of nasogastric tubes is not recommended due to the risk of perforation or additional injury.

Late ED management is primarily conservative. Gastric lavage, inducing emesis and pH neutralization are contraindicated. Use of corticosteroids and antibiotics remains controversial.¹⁷ Literature analysis dating back to 1956 has not found any benefit for steroids preventing

stricture formation.¹⁸ One small study in 2014 showed a large difference in stricture development in patients with grade 2b burns, between a control group receiving ceftriaxone and ranitidine and treatment group receiving methylprednisolone, ceftriaxone and ranitidine, with stricture development in 30% vs. 10.8% of patients, respectively.¹⁹ A small prospective study showed IV omeprazole might effectively be used in the acute phase treatment of caustic esophageal injuries.²⁰

The most common complication after caustic ingestions includes gastric outlet obstruction, esophageal stricture formation and an increased risk of esophageal carcinoma. It is estimated that strictures will form in 3- 57% of patients who ingest caustic substances and in nearly 100% who develop circumferential burns.^{3,7,21} Esophageal neoplasms (squamous cell carcinoma and adenocarcinoma) may develop later in life at a rate 1,000-3,000 times higher than the general population.²² These life-changing comorbidities make early diagnosis and intervention critical to the improved quality of life post-ingestion for these patients.

CONCLUSION

Caustic ingestion is a race against time. Early diagnosis of caustic ingestion and esophageal injury is imperative in initiating appropriate therapy and decreasing overall morbidity. There is limited literature regarding pH testing of unknown ingested substances and its diagnostic value. There has been even less discussion on testing the pH of emesis in the setting of suspected ingestion. The use of pH paper on emesis is a practical way to help the confirm suspicion of caustic ingestion. It is not practical in cases of suspected acidic ingestion but can be beneficial if concerned about alkaline agents. These pH paper strips should be stocked in every ED. They offer a quick, simple, and inexpensive test that should be added to our armamentarium as emergency physicians.

Address for Correspondence: Neal P. Johnson, MD, University of Tennessee College of Medicine, Saint Thomas Rutherford Hospital, Department of Emergency Medicine, 1840 Medical Center Parkway, Suite 403, Murfreesboro, TN 37129. Email: Njohns64@uthsc.edu.

Conflicts of Interest: By the CPC-EM article submission agreement, all authors are required to disclose all affiliations, funding sources and financial or management relationships that could be perceived as potential sources of bias. The authors disclosed none.

Copyright: © 2018 Johnson et al. This is an open access article distributed in accordance with the terms of the Creative Commons Attribution (CC BY 4.0) License. See: <http://creativecommons.org/licenses/by/4.0/>

REFERENCES

- Mowry JB, Spyker DA, Brooks DE, et al. 2015 Annual Report of the American Association of Poison Control Centers' National Poison Data System (NPDS): 33rd Annual Report. *Clin Toxicol (Phila)*. 2015;54(10):1058-7.
- Zargar SA, Kochhar R, Mehta S, et al. The role of fiber- optic endoscopy in the management of corrosive ingestion and modified endoscopic classification of burns. *Gastrointest Endosc*. 1991;37(2):165-9.
- Adam JS, Birck HG. Pediatric caustic ingestion. *Ann Otol Rhinol Laryngol*. 1982;91(6 Pt 1):656-8.
- Gupta SK, Croffie JM, Fitzgerald JF. Is esophagogastroduodenoscopy necessary in all caustic ingestions? *J Pediatr Gastroenterol Nutr*. 2001;32(1):50-3.
- Lamireau T, Rebouissoux L, Denis D, et al. Accidental caustic ingestion in children: is endoscopy always mandatory? *J Pediatr Gastroenterol Nutr*. 2001;33:81-4.
- de Jong AL, Macdonald R, Ein S, et al. Corrosive esophagitis in children: a 30-year review. *Int J Pediatr Otorhinolaryngol*. 2001;57(3):203-11.
- Anderson KD, Rouse TM, Randolph JG. A controlled trial of corticosteroids in children with corrosive injury of the esophagus. *N Engl J Med*. 1990;323(10):637-40.
- Hawkins DB, Demeter MJ, Barnett TE. Caustic ingestion: controversies in management. A review of 214 cases. *Laryngoscope*. 1980;90(1):98-109.
- Flavia I, Riezzo G, Raimondi F, et al. "Regurgitation in Healthy and Non Healthy Infants." *Italian Journal of Pediatrics*. 2009;35:39
- Simonian HP, Vo L, Doma S, et al. "Regional Postprandial Differences in PH Within the Stomach and Gastroesophageal Junction." *Dig Dis Sci*. 2005;50:2276-85.
- Levine RL, Fromm Jr. RE, Mojtahedzadeh M, et al. "Equivalence of litmus paper and Intra-gastric pH probes for intra-gastric pH monitoring in the intensive care unit." *Crit Care Med*. 1994;22(6):945-8.
- Connor AJ, Severn P. "Use of a control test to aid pH assessment of chemical eye injuries." *Emerg Med J*. 2009;26(11):811-2.
- Poley JW, Steyerberg EW, Kuipers EJ, et al. Ingestion of acid and alkaline agents: outcome and prognostic value of early upper endoscopy. *Gastrointest Endosc*. 2004;60(3):372-7.
- Betalli P, Rossi A, Bini M, et al. Update on management of caustic and foreign body ingestion in children. *Diagn Ther Endosc*. 2009;969868.
- Huang YC, Ni YH, Lai HS, et al. Corrosive esophagitis in children. *Pediatr Surg Int*. 2004;20:207-10.
- Temiz A, Oguzkurt P, Ezer SS, et al. "Predictability of outcome of caustic ingestion by esophagogastroduodenoscopy in children." *World J of Gastroenterol*. 2012;18:1098-103.
- Contini S, Scarpignato C. Caustic injury of the upper gastrointestinal tract: a comprehensive review. *World J Gastroenterol*. 2013;19(25):3918-30.
- Fulton JA, Hoffman RS. Steroids in second degree caustic burns of the esophagus: a systematic pooled analysis of fifty years of human data: 1956-2006. *Clin Toxicol (Phila)*. 2007;45(4):402-8.
- Usta M, Erkan T, Cokugras FC, et al. High doses of methylprednisolone in the management of caustic esophageal burns. *Pediatrics*. 2014;133(6):E1518.
- Cakal B, Akbal E, Köklü S, et al. Acute therapy with intravenous omeprazole on caustic esophageal injury: a prospective case series. *Dis Esophagus*. 2013;26:22-26
- Gaudreault P, Parent M, McGuigan MA, et al. Predictability of esophageal injury from signs and symptoms: a study of caustic ingestion in 378 children. *Pediatrics*. 1983;71:767.
- Kiviranta NK. Corrosive carcinoma of the esophagus. *Acta Otolaryngol*. 1952;102:1-9.

Isolated Dissection of the Superior Mesenteric Artery

Stacey Barnes, DO
Beth Kushner, DO

St. Joseph's Regional Medical Center, Department of Emergency Medicine, Paterson, New Jersey

Section Editor: Rick A. McPheeters, DO

Submission history: Submitted March 15, 2017; Revision received June 28, 2017; Accepted July 11, 2017

Electronically published January 9, 2018

Full text available through open access at http://escholarship.org/uc/uciem_cpccem

DOI: 10.5811/cpcem.2017.7.34224

Isolated dissection of the superior mesenteric artery is a novel disease often presenting with vague signs and symptoms. Although the disease entity is rare, the potential for morbidity and mortality is high. This is a case report of a healthy 58-year-old male presenting with diffuse persistent abdominal pain. Diagnosed on computed tomography, this patient's condition was managed conservatively with anticoagulants. [Clin Pract Cases Emerg Med.2018;2(1):43-46.]

INTRODUCTION

Spontaneous isolated dissection of the superior mesenteric artery (SIDSMA) is an extremely rare condition and a difficult diagnosis to make from the emergency department (ED). SIDSMA is associated with a wide range of clinical presentations, ranging from asymptomatic incidental finding to acute catastrophic bowel ischemia or aneurysmal SMA rupture.¹ While certain factors such as hypertension, connective tissue disorders, vasculitis, atherosclerosis and trauma to the aorta may predispose patients to this condition, in the majority of cases no risk factors can be found.^{2,3} Depending on the extent of the dissection and the patient's symptoms, treatment options vary from conservative treatment with anticoagulation to endovascular stenting, or even surgery.^{1,4} SIDSMA is a novel disease that requires immediate treatment and cannot be missed as a potentially life-threatening diagnosis in the ED.

CASE REPORT

A 58-year-old male with a past medical history of migraine headaches, nephrolithiasis, and appendectomy presented to the ED with non-radiating left upper quadrant abdominal pain for one week. The pain was constant with no aggravating or relieving factors. The patient denied fever, urinary symptoms, vomiting, or change in appetite. He reported having more bowel movements than usual but stated they were of normal consistency. The patient denied rectal bleeding, and denied use of tobacco. He had a normal outpatient colonoscopy five months prior.

On physical examination, the patient's vital signs were blood pressure of 117/87 milliliters of mercury, pulse 73

beats per minute, respiratory rate 16 breaths per minute, temperature 97.3 degrees Fahrenheit, and pulse oximetry 99% on room air. On physical examination, the abdomen was soft and had moderate left upper quadrant tenderness without guarding or rebound. Skin was without ecchymosis, petechiae, or purpura. Musculoskeletal exam revealed no deformities or swelling of joints. The rest of the physical exam was unremarkable.

Laboratory testing was ordered including a complete blood count, complete metabolic panel, lactic acid, and urinalysis that showed no acute abnormalities. The patient was initially treated with intravenous (IV) fluids and ketoralac during his ED stay. Computed tomography (CT) of the abdomen and pelvis was then completed with intravenous contrast. Results revealed aneurysm of the SMA with a four-centimeter dissection longitudinally along the course of the vessel (Images 1 and 2). Complicating the dissection was a 70-80% thrombosed lumen of a dissection flap that created a false lumen.

Vascular surgery was emergently consulted. As the patient was hemodynamically stable and the dissection with thrombosis did not reveal evidence of bowel ischemia, the patient was managed conservatively with IV heparin drip. During his hospital stay and repeat imaging, the patient did not show evidence of propagation of the dissection and the thrombus remained stable. He was converted to oral anticoagulation and discharged home with close follow-up.

DISCUSSION

Isolated dissection of the SMA is a rare diagnosis made in the ED, but it is of critical clinical significance. Post-mortem

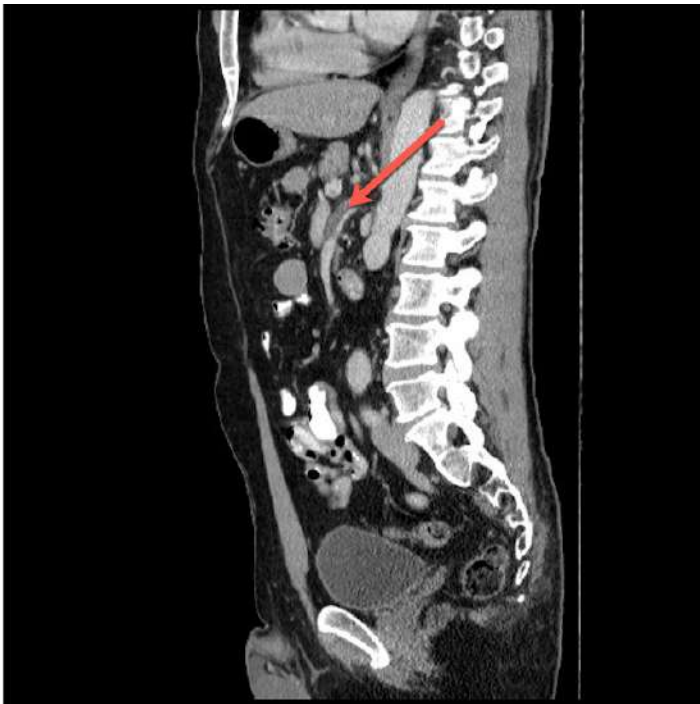


Image 1. Sagittal computed tomography with intravenous contrast demonstrating thrombus (arrow) in the false lumen of the superior mesenteric artery dissection.

findings of isolated SMA dissection suggest that if left undiagnosed and untreated, catastrophic compromise of intestinal blood supply can occur resulting in bowel ischemia and death.⁵ Spontaneous dissection of peripheral arteries is rare; however, after the carotid artery, the second most common peripheral artery to be affected is the SMA.¹ The increase in reported incidence over the past several decades is likely secondary to the expanding use and higher-quality imaging capabilities of CT for undifferentiated abdominal pain.^{2,3} Unfortunately for the emergency physician, the three most common symptoms of SMA dissection are acute abdominal pain, abdominal pain with vomiting, and subacute intestinal obstruction. Interestingly, the fourth most common presentation for SMA dissection is an asymptomatic patient, with dissection found incidentally on CT.⁴ Acute abdominal pain is often reported as left upper quadrant and more rarely as postprandial pain, which is likely a sign of intestinal angina.⁵

Just as patient presentations are varied, so are the risk factors associated with SMA dissection. The majority of the cases reported are found in men 39-82 years old, with a mean age of 54. Smoking and hypertension appear to be a common factor in patients with SIDSMA. Unlike other forms of dissection, however, atherosclerosis is not a common risk factor. Other conditions such as previous abdominal surgery, diabetes or trauma have been reported with SMA dissection, but they have not been found to have a consistent correlation.⁴

CPC-EM Capsule

What do we already know about this clinical entity?

Spontaneous isolated dissection of the superior mesenteric artery is a rare condition and a difficult diagnosis to make from the Emergency Department as it has a variety of presenting symptoms.

What makes this presentation of disease reportable?

The presentation of this disease is reportable as it will increase awareness of emergency physicians to this rarity of this type of dissection, symptoms, and treatment.

What is the major learning point?

While nonspecific abdominal pain is common in the emergency department, it is vital for the physician to have a wide differential including this disease due to the high morbidity and mortality.

How might this improve emergency medicine practice?

By understanding the etiology and presentation of this fatal disease, the emergency physician will be more readily able to diagnose and treat superior mesenteric artery dissections.

Despite the variety of patients affected, the majority of the dissections begin in the retropancreatic portion of the SMA, which is most often in a fixed position.⁶ From this nidus, increased shearing forces lead to a tear in the intima or primary hemorrhage in the media itself. The mechanism is similar to an aortic transection at the ligamentum arteriosum seen in rapid deceleration injuries.⁷ Blood accumulates between the medial and adventitial layers or within the medial laminae leading to propagation of the dissection throughout the artery.⁴

As with other forms of dissection, CT performed with IV contrast in combination with advancement of multi-slice CT imaging techniques improves the accuracy in diagnosing both the dissection itself and the length of the dissection. In various other case reports, a seemingly otherwise normal CT only had increased fat attenuation around the SMA, which helped indicate

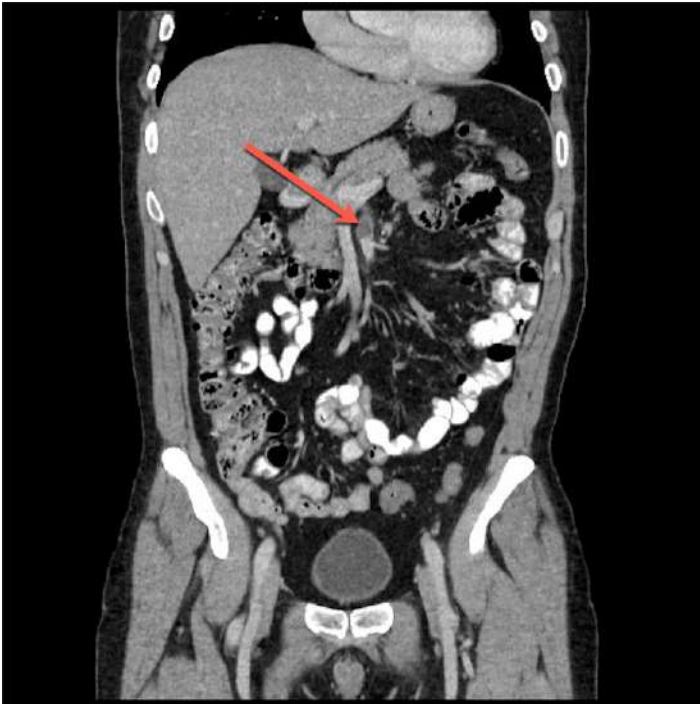


Image 2. Coronal computed tomography with intravenous contrast demonstrating thrombus (arrow) in the false lumen of the superior mesenteric artery dissection.

to the practitioner that further investigation with angiography was necessary.⁴ Visualization of the intimal flap is considered a pathognomonic sign of isolated dissection; however, a mural thrombus is sometimes the only indication of a dissection.⁸

As indicated by the rarity of SMA, no standard therapeutic approach has been established. In decreasing frequency, treatment is separated into surgical, conservative, and endovascular approaches. The decision for route of management is directed by the symptoms the patient is experiencing. For patients such as the one described in this case, there were no signs of bowel ischemia or rupture of any of the branches from the SMA.⁵ In cases such as this, conservative management is often employed. Patients are started on a heparin drip and reimaged to ensure no further dissection has occurred.⁷ If repeat imaging is found to be stable, patients are then switched to oral anticoagulation and discharged home with close follow-up with vascular surgery.

A variation to conservative management includes the addition of an antiplatelet agent, which has been described in several case reports.⁵ Due to lack of clinical trials, there are great discrepancies for length of follow-up and optimal intervals for reimaging. Additional considerations in treatment involve whether or not a thrombus is present in the false lumen. With a thrombus present, patients are at increased risk of potential bowel ischemia and for this reason warfarin is continued on an outpatient basis. It should be emphasized that in previous case reports it has been noted that although

conservative therapy does prevent new thrombus formation, progression of disease has occurred, resulting in the need for urgent endovascular or surgical intervention.⁹

For patients who have signs or symptoms of intestinal ischemia or impending aneurysm rupture, endovascular or surgical technique is preferred. Endovascular treatment includes stent placement, intralesional thrombolytic therapy, and balloon angioplasty.^{6,9} Surgical treatment includes aortomesenteric bypass, direct transposition of the SMA to the infrarenal aorta, or even patch angioplasty. Due to the invasive nature of surgery, operative intervention is often reserved for patients with bowel necrosis or increasing size of aneurysm despite medical management. Although endovascular treatment has been advocated recently and performed successfully several times per the case literature, there is still no consensus about which treatment modality is the gold standard for isolated SMA dissection.⁹

CONCLUSION

Our case demonstrates that patients with persistent abdominal pain, even without standard risk factors for dissection of the carotid or aortic arteries, are still prime candidates for superior mesenteric artery dissection. With technological advances in CT, the practitioner is able to diagnose and halt the propagation of a potentially lethal disease. Patients whose symptoms are manageable and who are without signs of bowel ischemia or injury to vessels distal to the dissection can be treated conservatively with a heparin drip and converted to oral anticoagulants with close follow-up as an outpatient. Case reports of SMA dissection have been reported in surgical and gastroenterology literature, but are novel to emergency medicine. Detection and treatment of this challenging disease will increase and is something every emergency physician should be familiar with. While isolated dissection of the SMA is a rare disease, the potential for morbidity and mortality is high. Therefore, this is a critical diagnosis to make in the ED.

Address for Correspondence: Stacey Barnes, DO, FACEP, FACOEP, St. Joseph's Regional Medical Center, 703 Main Street Paterson, NJ 07503. Email: barnes223@hotmail.com.

Conflicts of Interest: By the CPC-EM article submission agreement, all authors are required to disclose all affiliations, funding sources and financial or management relationships that could be perceived as potential sources of bias. The authors disclosed none.

Copyright: © 2018 Barnes et al. This is an open access article distributed in accordance with the terms of the Creative Commons Attribution (CC BY 4.0) License. See: <http://creativecommons.org/licenses/by/4.0/>

REFERENCES

1. Min SI, Yoon KC, Min SK, et al. Current strategy for the treatment of symptomatic spontaneous isolated dissection of superior mesenteric artery. *J Vasc Surg*. 2011;54(2):461-6.
2. Wilson SK, Hutchins GM. Aortic dissecting aneurysms: causative factors in 204 subjects. *Arch Pathol Lab Med*. 1982;106(4):175-80.
3. Watring NJ, Smith CM, Stokes GK, et al. Spontaneous superior mesenteric artery (SMA) dissection: an unusual cause of abdominal pain. *J Emerg Med*. 2010;39(5):576-8.
4. Akuzawa N, Seki H, Oku Y, et al. Three cases of spontaneous isolated dissection of the superior mesenteric artery. *Journal Emer Med*. 2015;48(5):e111-6.
5. Wu XM, Wang TD, Chen MF. Percutaneous endovascular treatment for isolated spontaneous superior mesenteric artery dissection: Report of two cases and literature review. *Catheter Cardiovasc Interv*. 2009;73(2):145-51.
6. Sparks SR, Vasquez JC, Bergan JJ, et al. Failure of nonoperative management of isolated superior mesenteric artery dissection. *Ann Vasc Surg*. 2000;14(2):105-9.
7. Stanely S, Chang J, Garg S, et al. Successful nonoperative management of isolated superior mesenteric artery dissection. *Vasc Dis Manag*. 2015;12(11):e221-4.
8. Zeina AR, Nachtigal A, Mahamid A, et al. Isolated spontaneous dissection of a visceral artery: a rare cause of epigastric pain. *Emerg Radiol*. 2015;22(3):215-20.
9. Froment P, Alerci M, Vandoni RE, et al. Stenting of a spontaneous dissection of the superior mesenteric artery: a new therapeutic approach? *CVIR Cardiovasc Intervent Radiol*. 2004;27(5):529-32.

Sodium-glucose Cotransporter-2 Induced Diabetic Ketoacidosis with Minimal Hyperglycemia

D. Taylor Gammons, MD*
Francis L. Counselman, MD*†

*Eastern Virginia Medical School, Department of Emergency Medicine, Norfolk, Virginia
†Emergency Physicians of Tidewater, Norfolk, Virginia

Section Editor: Rick A. McPheeters, DO

Submission history: Submitted August 25, 2017; Revision received December 4, 2017; Accepted December 4, 2017

Electronically published January 11, 2018

Full text available through open access at http://escholarship.org/uc/uciem_cpchem

DOI: 10.5811/cpchem.2017.12.36213

The case of a 56-year-old man with a history of type 2 diabetes mellitus who presented to the emergency department in diabetic ketoacidosis (DKA) with only mild hyperglycemia is presented. The patient was taking empagliflozin (Jardiance®), a sodium-glucose cotransporter -2 inhibitor, which has now been recognized as causing this unusual presentation of DKA. Emergency physicians need to be aware of this complication, as the euglycemia/mild hyperglycemia and a history of type 2 diabetes mellitus can make the correct diagnosis of DKA a challenge. [Clin Pract Cases Emerg Med. 2018;2(1):47-50.]

INTRODUCTION

We present the case of a 56-year-old man with a history of type 2 diabetes mellitus who presented to the emergency department in diabetic ketoacidosis (DKA) with only a slightly elevated serum glucose. The patient was taking empagliflozin (Jardiance®), a sodium-glucose cotransporter-2 inhibitor. There are increasing reports of this unusual complication in patients taking this class of medication. Emergency physicians need to be aware of this complication, as the euglycemia and history of type 2 diabetes mellitus can make the correct diagnosis of DKA challenging.

CASE PRESENTATION

A 56-year-old man presented to the emergency department (ED) with a five-day history of left upper quadrant abdominal pain and low-grade fever. The patient described the pain as achy, constant and worse with eating. The patient denied nausea, vomiting or diarrhea. There was no history of trauma or similar symptoms in the past. The past medical history was significant for coronary artery disease (requiring two stents), type 2 diabetes mellitus, hypertension and hypertriglyceridemia. The patient stated he was compliant with his medications, including losartan-hydrochlorothiazide 100/12.5 mg, metoprolol 50 mg, glipizide XL 10 mg, empagliflozin (Jardiance®) 25 mg, sitagliptin-metformin 500/1000 mg, prasugrel 10 mg, rosuvastatin 10 mg, and aspirin 81mg. He denied smoking cigarettes, but admitted to

several drinks at “happy hour.” He denied any alcohol use in the previous five days.

The vital signs were heart rate 97 beats per minute; respiratory rate 18 breaths per minute; blood pressure 196/96 mm Hg; temperature of 99.2 °F (37.3 °C); and 94% oxygen saturation on room air. The patient appeared in no distress. The head, eyes, ears, nose and throat exam was normal, as were the heart and lung exams. The abdomen was soft, with mild tenderness in the epigastrium and left upper quadrant, without guarding or rebound. The remainder of the physical exam, including the extremities and neurologic, were normal.

The emergency physician (EP) ordered an electrocardiogram (ECG), complete blood count (CBC), basic metabolic profile (BMP), lipase, urinalysis and troponin T. The CBC was normal, as was the lipase. The BMP was remarkable for a glucose of 142 mg/dL, sodium of 128 mmol/L, chloride of 87 mmol and a bicarbonate of 19 mmol/L. The blood urea nitrogen, creatinine and potassium were normal. The urinalysis was remarkable for 80 mg/dL of ketones and greater than 500 mg/dL of glucose. The ECG revealed only non-specific ST and T-wave changes in the lateral leads. The patient’s anion gap was markedly elevated at 21.7. After reviewing the laboratory results, the EP was concerned about the large anion gap metabolic acidosis. Additional studies ordered included a serum acetone, beta-hydroxybutyrate and a lactic acid.

The EP ordered one liter of normal saline intravenous (IV) bolus and morphine 4 mg and ondansetron 4 mg IV for

the abdominal pain. The EP went back and specifically asked the patient about possible causes of the anion gap metabolic acidosis, including ethylene glycol, propylene glycol or methanol ingestion, alcohol abuse, iron or isoniazid use, excessive salicylate use, and dieting (starvation). The patient denied all of these. The serum acetone was reported as “moderate,” the beta-hydroxybutyrate was elevated at 47.6 mg/dL (normal range 0.2 – 2.8 mg/dL) and a serum lactate of 1 mmol/L (normal range 0.5 – 2.2 mmol/L). A repeat BMP revealed the bicarbonate had decreased to 17 mmol/L.

The EP thought the patient was in diabetic ketoacidosis (DKA), but was confused by the only slightly elevated blood glucose and the fact that the patient was a type 2 diabetic. The EP performed a quick literature search and found that diabetic patients on sodium-glucose cotransporter-2 (SGLT2) inhibitors were at risk for DKA with euglycemia. This patient was on just such a medication (empagliflozin) and had been so for the preceding three years. The patient was admitted to the medicine service and started on an IV insulin drip with concomitant IV dextrose 5% in normal saline drip at 125 cc/hr.

A computed tomography (CT) scan of the abdomen/pelvis with IV contrast was ordered to further evaluate the cause of the left upper quadrant abdominal pain. The CT demonstrated “findings of acute pancreatitis with confluent infiltrative phlegmon around the tail and left side of the pancreatic body, extending to lower portion of the spleen and to left anterior and lateral pararenal space. There was no definable pancreatic mass.” Gastroenterology (GI) was consulted and thought the patient had acute chemical pancreatitis secondary to the DKA and his underlying hypertriglyceridemia. Endocrinology was consulted; they felt the DKA was most likely due to the empagliflozin and that the patient needed to avoid this medication in the future. After four days on an insulin drip, the anion gap decreased to 14, there was no definable serum acetone, and the beta-hydroxybutyrate level returned to normal. The patient could then be weaned off the insulin drip and started on medications by mouth. The patient was discharged home on day five. The patient was instructed to stop taking the empagliflozin and to avoid all such similar medications in the future. His abdominal pain was much improved and he was eating a full diet. The patient was scheduled to follow up with GI and endocrinology in one week.

DISCUSSION

Diabetic ketoacidosis is a life-threatening complication of diabetes mellitus. It usually occurs in type 1 diabetics, but may occur in type 2 patients under moderate to severe physiologic stress. According to the American Diabetes Association, the diagnostic criteria for DKA includes a plasma glucose greater than 250 mg/dL, positive serum or urinary ketones, an arterial pH of less than 7.3, serum bicarbonate less than 18 mEq/L and a high anion gap. The key diagnostic feature is the elevated circulating total blood ketone concentration.¹

Euglycemic diabetic ketoacidosis is now defined as diabetic

CPC-EM Capsule

What do we already know about this clinical entity?

Diabetic ketoacidosis (DKA) is a life-threatening complication of diabetes mellitus. It usually occurs in patients with type 1 diabetes, and is associated with a blood glucose level of greater than 250mg/dL, a serum bicarbonate level less than 15 mEQ/dL, and a pH less than 7.3.

What makes this presentation of disease reportable?

With the introduction of sodium-glucose cotransporter-2 inhibitor medications for the treatment of type 2 diabetes mellitus, this classic presentation of DKA no longer holds true.

What is the major learning point?

These medications can cause DKA in a type 2 diabetic patient with euglycemia or only mild hyperglycemia.

How might this improve emergency medicine practice?

Emergency physicians must be aware of this atypical presentation of DKA to ensure making the correct diagnosis.

ketoacidosis with a blood glucose concentration of less than 200 mg/dL, and occurring primarily in patients with type 1 diabetes.² Euglycemic DKA has been described in the past but is considered rare.^{3,4} Munro et al. described the first case series of euglycemic DKA in 1973, consisting of 37 episodes in 17 patients.⁵ They suggested that in type 1 diabetics who were unable to maintain sufficient carbohydrate intake, but maintained hydration status and continued their normal insulin intake, could develop severe ketoacidosis without pronounced hyperglycemia.⁵ Thawabi et al. presented two cases of euglycemic DKA in type 1 diabetic patients that were consistent with Munro’s physiologic explanation.¹ One case was precipitated by an underlying infection; the other by acute pancreatitis.¹

More recently, there have been several reports of euglycemic DKA attributed to the use of SGLT2 inhibitors.^{6,7} Roach et al. described the first case of euglycemic DKA associated with the use of empagliflozin, the same medication as in our patient.⁶ The case involved a 64-year-old woman with type 2 diabetes who developed DKA following five days of empagliflozin use.⁶ The

other SGLT2 inhibitors – canagliflozin and dapagliflozin -- have all been associated with euglycemic DKA.^{3,7,8} In fact, in May 2015 the U.S. Food and Drug Administration (FDA) issued a warning that the “SGLT2 inhibitors can cause too much acid in the blood,” and that patients should stop taking their SGLT2 inhibitor and seek medical attention immediately if they develop symptoms of ketoacidosis.⁹ This warning was based in part because of the FDA identifying 73 cases of ketoacidosis requiring hospitalization in patients on SGLT2 inhibitors between March 2013 and June 2015.^{3,9} The median time to onset of symptoms was 43 days, with a range of 1 to 365 days.^{3,9}

The SGLT2 inhibitors are one of the newest class of oral hypoglycemic medications used to treat diabetes mellitus. These drugs are FDA approved for use in adults with type 2 diabetes. Canagliflozin was the first to be introduced, followed by dapagliflozin and empagliflozin.³ These medications are available as single-ingredient products, or in combination, usually with metformin. These drugs have a novel mechanism of action by inhibiting the enzyme SGLT located in the proximal renal tubules. This enzyme is responsible for reabsorbing approximately 90% of glucose found in the filtrate within the kidney.¹⁰ By blocking this enzyme, the blood glucose is decreased because of an increase in renal glucose excretion. These drugs have a relatively pronounced blood glucose lowering effect, with a low risk for hypoglycemia when administered as monotherapy.² Given that these drugs promote excretion of glucose (an energy source) into the urine, treatment with these drugs also reduces body weight and have pleiotropic effects attributable to weight loss, including amelioration of insulin resistance, dyslipidemia, and nonalcoholic fatty liver disease.² In addition, empagliflozin was shown to reduce cardiovascular and all-cause mortality, and reduce hospitalization for heart failure, compared to placebo in over 7,000 adult patients with type 2 diabetes mellitus.¹¹

These drugs, however, are not without adverse effects. In addition to ketoacidosis, they are associated with urinary tract infections (in some cases, leading to urosepsis) and vaginal candidiasis. However, it is the ketoacidosis, and specifically the euglycemic ketoacidosis, that is the most concerning. There are several proposed theories to explain the link between SGLT2 inhibitors and ketoacidosis. One possible mechanism involves a decreased secretion of insulin from pancreatic cells in response to the lowering of blood glucose via urinary excretion.⁴ This results in decreased circulating insulin and its antilipolytic activity, leading to increased free fatty acid production.⁴ One animal study suggests that SGLT2 inhibitors stimulate the secretion of the counterregulating hormone glucagon, which in turn contributes to the overproduction of ketone bodies.^{3,8,12} Finally, another animal study suggests that SGLT inhibitors might decrease the renal clearance of ketone bodies.^{3,4} The net result is a stimulation of the ketogenesis pathway and an increase in serum ketones, which predispose the body to ketoacidosis. This effect is compounded in the presence of physiologic stressors, such as starvation or dehydration.³

CONCLUSION

Although the reason behind SGLT2 inhibitors causing ketoacidosis, often euglycemic ketoacidosis, might not be fully understood, the association definitely exists. Emergency physicians must recognize that diabetic ketoacidosis can develop in type 2 diabetic patients with normal or only slightly elevated blood glucose levels in patients taking SGLT2 inhibitors.

Address for Correspondence: Francis L. Counselman, MD, Eastern Virginia Medical School, Department of Emergency Medicine, 600 Gresham Drive, Room 304, Raleigh Building, Norfolk, VA 23507. Email: counself@evms.edu.

Conflicts of Interest: By the CPC-EM article submission agreement, all authors are required to disclose all affiliations, funding sources and financial or management relationships that could be perceived as potential sources of bias. The authors disclosed none.

Copyright: © 2018 Gammons et al. This is an open access article distributed in accordance with the terms of the Creative Commons Attribution (CC BY 4.0) License. See: <http://creativecommons.org/licenses/by/4.0/>

REFERENCES

1. Thawabi M, Studyvin S. Euglycemic diabetic ketoacidosis, a misleading presentation of diabetic ketoacidosis. *N Am J Med Sci*. 2015;7(6):291-4.
2. Ogawa W, Sakaguci K. Euglycemic diabetic ketoacidosis induced by SGLT2 inhibitors: possible mechanism and contributing factors. *J Diabetes Invest*. 2016;7(2):135-8.
3. Jazi M, Porfiris G. Euglycemic diabetic ketoacidosis in type 2 diabetes treated with a sodium-glucose cotransporter-2 inhibitor. *Can Fam Physician*. 2016; 62(9):722-4.
4. Simeon IT, Blau JE, Kristina IR. SGLT2 inhibitors may predispose to ketoacidosis. *J Clin Endocrinol Metab*. 2015;100(8):2849-52.
5. Munro JF, Campbell IW, McCuish AC, et al. Euglycaemic diabetic ketoacidosis. *Br Med J*. 1973;2:578-80.
6. Roach P, Skierczynski P. Euglycemic diabetic ketoacidosis in a patient with type 2 diabetes after treatment with empagliflozin. *Diabetes Care*. 2016; 39(1):e3-e3.
7. Fralick M, Schneeweiss S, Paterno E. Risk of diabetic ketoacidosis after initiation of an SGLT2 inhibitor. *N Engl J Med*. 2017;376(23):2300-2.
8. Hayami T, Kato Y, Kamiya H, et al. Case of ketoacidosis by a sodium-glucose cotransporter 2 inhibitor in a diabetic patient with a low-carbohydrate diet. *J Diabetes Invest*. 2015;6(5):587-90.
9. US Food and Drug Administration (website). FDA Drug Safety Communication: FDA revises labels of SGLT2 inhibitors for diabetes to include warning about too much acid in the blood and serious urinary tract infections. Silver Spring, MD: US Food and Drug Administration; May 2015. Available at: www.fda.gov/Drugs/

- DrugSafety/ucm475487.htm. Accessed 2017 Aug 23.
10. Kim GW, Chung SH. Clinical implication of SGLT2 inhibitors in type 2 diabetes. *Arch Pharm Res*. 2014;37(8):957-66.
 11. Zinman B, Wanner C, Lachin JM, et al. Empagliflozin, cardiovascular outcomes, and morbidity in type 2 diabetes mellitus. *N Engl J Med*. 2015;373(22):2117-28.
 12. Kibbey RG. SGLT-2 inhibition and glucagon: cause for alarm? *Trends Endocrinol Metab*. 2015;26(7):337-8.

Consumption Junction: A Case of Peritoneal Tuberculosis-induced Small Bowel Obstruction

Michael Poppe, MD
Kelly Peng, DO
Dylan Arnold, DO

Naval Medical Center San Diego, Department of Emergency Medicine, San Diego, California

Section Editor: Rick A. McPheeters, DO

Submission history: Submitted September 2, 2017; Revision received November 3, 2017; Accepted November 28, 2017

Electronically published January 11, 2018

Full text available through open access at http://escholarship.org/uc/uciem_cpceem

DOI: 10.5811/cpcem.2017.11.36310

The rapid diagnosis and treatment of tuberculosis (TB) is necessary to prevent the spread of infection to others and reduce morbidity and mortality. Atypical presentations are not often considered in the differential. This patient presented with fever and abdominal pain. Computed tomography of the abdomen and pelvis showed small bowel obstruction, initially attributed to the patient's Crohn's disease. Chest radiograph showed diffuse interstitial lung disease, consistent with his diagnosis of sarcoidosis. He had multiple recent negative tuberculin skin tests documented. After being admitted to the surgical service and started on antibiotics, the diagnosis of abdominal TB was discovered following surgical exploration and tissue sampling. [Clin Pract Cases Emerg Med. 2018;2(1):51-54.]

INTRODUCTION

Tuberculosis remains a worldwide problem, with one third of the earth's population currently infected.¹ The incidence of pulmonary tuberculosis (PTB) in the United States has largely diminished over the past century, which has led to fewer U.S. physicians caring for tuberculosis patients. While it may often remain a consideration in the emergency department (ED) for patients presenting with cough and fever or a suspect travel history, it is important to remember that TB can affect any part of the body.

Unlike PTB, the incidence of extrapulmonary tuberculosis (EPTB) has remained relatively constant over the last 15 years, and the proportion of EPTB relative to PTB has increased.^{2,3} In EPTB cases, the abdomen can be involved in up to 11% of patients. Bowel obstruction, most commonly secondary to hyperplastic mural thickening, stricture formation or adhesions, is a known potential complication. We present a patient with this complication in the setting of previously diagnosed Crohn's disease and sarcoidosis.

CASE REPORT

The patient was a 34-year-old male with a history of Crohn's disease and sarcoidosis who presented to the ED with two weeks of intermittent fevers, night sweats, and two days of nausea and vomiting. He had intermittent fevers for the prior

year. Since beginning his current medication regimen, he had not experienced symptoms from his Crohn's disease and had baseline mild shortness of breath from sarcoidosis with a dry cough without hemoptysis. He endorsed a five-pound weight loss over the prior month. He stated that he typically had a non-bloody bowel movement daily, but his last bowel movement was two days prior. Review of systems was otherwise negative.

The patient stated that he had taken azathioprine and adalimumab for his Crohn's disease for the preceding two years, and prednisone and trimethoprim/sulfamethoxazole for his sarcoidosis for the prior six months without any recent dosing changes. His only surgery was a terminal ileum abscess removal and appendectomy three years prior in the Philippines, after which he received his diagnosis of Crohn's disease. He denied any drug allergies and took no other medications. His only recent travel had been to the Philippines three months prior to visit family. He was up to date on vaccinations and had a negative purified protein derivative (PPD) in the past year.

The only vital sign abnormality was a fever to 101.3 degrees Fahrenheit. Pertinent physical exam findings included anterior cervical chain lymphadenopathy, diffuse mild inspiratory crackles, significant abdominal guarding with rebound tenderness. Bowel sounds were present. Labs showed no significant leukocytosis, normal lactate, a mild microcytic anemia, and a mild acute kidney injury.

Erythrocyte sedimentation rate and C-reactive protein were 20 and 8.2 respectively.

Intravenous fluids, antibiotics, and antipyretics were started and a nasogastric tube was placed for what was initially presumed to be a gastrointestinal source of infection with possible obstruction. Abdominal computed tomography (CT) obtained showed signs of intraabdominal infection and obstruction, as seen in Image 1.

He was admitted to the surgical service. Upon further chart review, the patient was shown to have a positive QuantiFERON® test in 2014 while taking adalimumab and azathioprine, which was never addressed. A colonoscopy was performed to attempt biopsy of the affected tissue, but could not pass through the terminal ileum due to the high-grade obstruction. An exploratory laparotomy was subsequently performed to obtain a definitive diagnosis, as the differential was still broad and included abdominal sarcoidosis, TB, and coccidiomycosis.

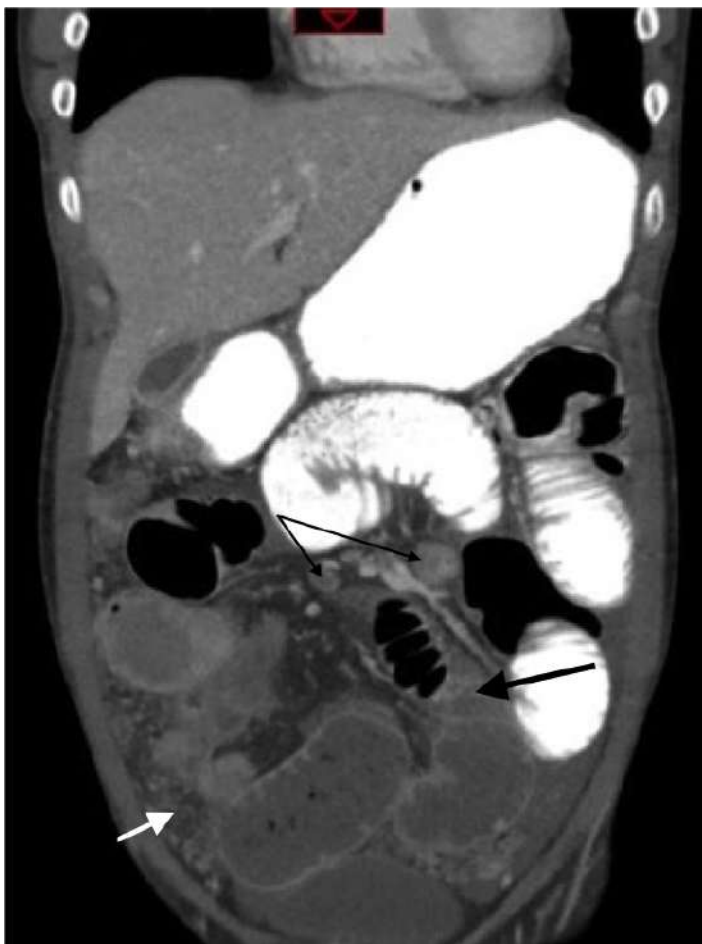


Image 1. Coronal computed tomography with oral contrast showing oral contrast not completing its path through the bowel (thick black arrow), indicating presence of high-grade obstruction. Also visualized are large mesenteric lymph nodes (thin black arrows), peritoneal studding, and omental caking (white arrow).

CPC-EM Capsule

What do we already know about this clinical entity?

Tuberculosis (TB) is a disease that most commonly affects the lungs, but it can seed nearly any other part of the body.

What makes this presentation of disease reportable?

This is a strong reminder that TB can occur outside of the lungs, can lead to bowel obstruction, and that certain medications increase risk of activation.

What is the major learning point?

TB is not only a disease of the lungs.

How might this improve emergency medicine practice?

Keeping TB in the differential can prevent significant patient and staff morbidity and mortality through early identification and isolation.

Histopathological staining was positive for acid-fast bacilli, and the patient was diagnosed and treated for TB. Sputum samples also grew out acid-fast bacilli, indicating concomitant pulmonary infection. Intra-operative photo (Image 2) depicts peritoneal studding, also demonstrated on CT.

Typically, EPTB can be treated with the same drug regimen as pulmonary TB.⁴ However, this patient's NPO status due to his bowel obstruction necessitated IV therapy. Infectious disease was consulted, and the patient was placed on streptomycin, rifampin, and moxifloxacin until his obstruction resolved. Five days into his hospital course, the obstruction had resolved and the patient was started on oral rifampin, isoniazid, pyrazinamide and ethambutol. His adalimumab and azathioprine were held on admission, and the decision was made to keep holding until his next outpatient visit. He responded well to the drug course, and after a nine-day hospital stay he was allowed to leave after two consecutive sputum cultures were negative.

Approximately three weeks after discharge, the patient had elevated liver enzymes and his pyrazinamide was changed to moxifloxacin. He remained on a four-drug regimen for 10 weeks with significant clinical improvement, and was then transitioned to two-drug therapy with rifampin and isoniazid. He remained on this regimen for eight months. After completing his course, the

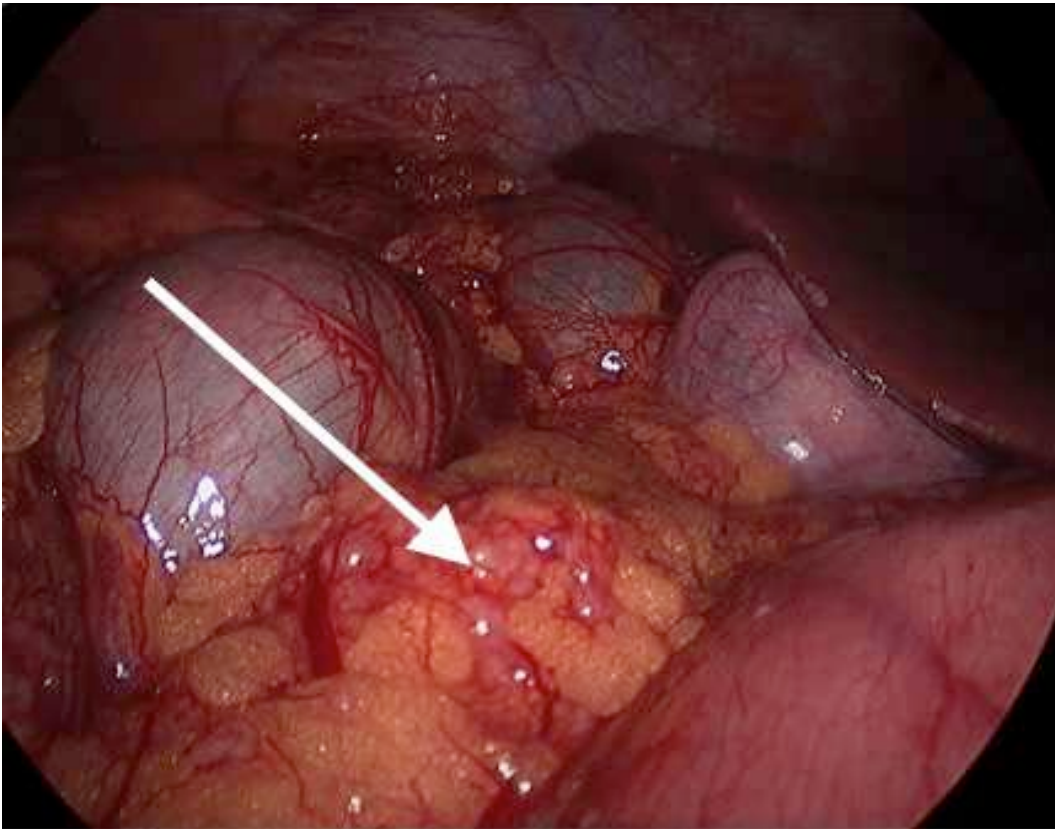


Image 2. Intra-operative photo showing extensive peritoneal studding (arrow). Histopathology was consistent with a diagnosis of abdominal tuberculosis.

only residual effect was a mild peripheral neuropathy. He was able to transition back onto adalimumab and azathioprine, and steroid treatment was tapered off successfully.

DISCUSSION

As demonstrated in this case, abdominal TB can present very similarly to Crohn's disease.⁵ It is difficult to determine at what point this patient contracted TB; his positive QuantiFERON® in 2014 indicates he had at least been exposed at that time. However, there were no changes made to his drug regimen. The patient remained on adalimumab as well as azathioprine and steroids, which can all decrease sensitivity of the tuberculin skin test, as well as increase risk of activation of latent TB.^{6,7,8}

The abdomen is the most common site for TB to occur after the lungs.⁹ Although uncommon in the U.S., bowel obstruction secondary to abdominal TB is a well-documented issue in countries with higher disease prevalence.¹⁰ Seeding of the abdomen can occur through hematogenous spread from primary lung foci, lymphatic spread from infected nodes, ingestion of the organism from infected sources (milk products, sputum, etc.), or spread from adjacent infected organ.¹¹ A clue on this patient's imaging was the presence

of peritoneal studding and omental caking, which are not typically seen with inflammatory bowel diseases, but can be caused by TB infection in this area.¹²

The patient had been diagnosed with sarcoidosis a few years prior after bronchoalveolar lavage (BAL) revealed non-caseating granulomatous disease without acid-fast bacilli present. On repeat BAL during his hospital stay he grew acid-fast bacilli, and sputum cultures were positive as well. It seems likely that the primary infection in this patient was the lungs, with subsequent spread to the abdominal cavity by one of the previously mentioned pathways.

CONCLUSION

Diagnosing abdominal TB can be challenging. The disease process is often sub-acute, and the patient presenting with abdominal pain and fever has a large differential. In particular, this condition presents very similarly to inflammatory bowel disease and often requires histological analysis to obtain a definitive diagnosis. Patients may, as in this case, already carry diagnoses that can complicate the picture. Care should be taken in the ED to consider TB in the setting of the patient's symptoms, comorbidities, immune-suppressing medications, recent travel and exposure history.

Address for Correspondence: Michael Poppe, MD, Naval Medical Center San Diego. 34800 Bob Wilson Drive, San Diego, CA 92134. Email: poppe1268@gmail.com.

Conflicts of Interest: By the CPC-EM article submission agreement, all authors are required to disclose all affiliations, funding sources and financial or management relationships that could be perceived as potential sources of bias. The authors disclosed none. The views expressed in this article represent those of authors and do not represent the views of the United States Navy.

Copyright: © 2018 Poppe et al. This is an open access article distributed in accordance with the terms of the Creative Commons Attribution (CC BY 4.0) License. See: <http://creativecommons.org/licenses/by/4.0/>

REFERENCES

- Centers for Disease Control and Prevention Division of Tuberculosis Elimination Tuberculosis Web Site. 2017. Available at: <http://www.cdc.gov/tb/statistics/default.htm>. Accessed on August 18, 2017.
- Sandgren A, Hollo V, van der Werf MJ. Extrapulmonary tuberculosis in the European Union and European Economic Area, 2002 to 2011. *Euro Surveill.* 2013;18(12). pii: 20431.
- Korea Centers for Disease Control and Prevention. Annual report on the notified tuberculosis in Korea. Cheongwon: Korea Centers for Disease Control and Prevention. 2014; p. 2013.
- Treatment of Tuberculosis: Guidelines.* 4th edition. Geneva: World Health Organization. 2010. 8, Treatment of extrapulmonary TB and of TB in special situations.
- Akbar HO. Intestinal tuberculosis and Crohn's disease: the dilemma of similarities and misdiagnosis. *BMJ Case Reports.* 2009;2009. Pii:bcr04.2009.1729.
- Keane J, Gershon S, Wise RP, et al. Tuberculosis associated with infliximab, a tumor necrosis factor α -neutralizing agent. *N Engl J Med.* 2001;345(15):1098–104.
- Vassilopoulos D, Stamoulis N, Hadziyannis E, et al. Usefulness of enzyme-linked immunospot assay (Elispot) compared to tuberculin skin testing for latent tuberculosis screening in rheumatic patients scheduled for anti-tumor necrosis factor treatment. *J Rheumatol.* 2008;35(7):1464.
- Bélard E, Semb S, Ruhwald M, et al. Prednisolone treatment affects the performance of the QuantiFERON gold in-tube test and the tuberculin skin test in patients with autoimmune disorders screened for latent tuberculosis infection. *Inflamm Bowel Dis.* 2011;17(11):2340-9.
- Khan MR, Khan IR, Pal KN: Diagnostic issues in abdominal tuberculosis. *J Pak Med Assoc.* 2001;51(4):138-42.
- Phillipo LC, Mabula DM, Stephen EM, et al. Tuberculous bowel obstruction at a university teaching hospital in Northwestern Tanzania: a surgical experience with 118 cases. *World J Emerg Surg.* 2013;8:12.
- Rita S. Diagnosis of abdominal tuberculosis. Role of imaging. *J Ind Acad Clin Med.* 2001;2(3):103-4.
- Sharma MP. Abdominal tuberculosis. *Imaging Science Today.* 2009;146.

Urinary Catheterization in Infants: When It's Knot so Simple

David C. Sheridan, MD, MCR*† *Oregon Health & Science University, Department of Emergency Medicine, Portland, Oregon
Beech Burns, MD, MCR*† †Oregon Health & Science University, Department of Pediatrics, Portland, Oregon
Megan Mickley, MD*†

Section Editor: Manish Amin, DO

Submission history: Submitted September 18, 2017; Revision received November 14, 2017; Accepted November 28, 2017

Electronically published January 11, 2018

Full text available through open access at http://escholarship.org/uc/uciem_cpchem

DOI: 10.5811/cpchem.2017.11.36438

Pediatric fever is one of the most common presenting complaints to emergency departments (ED). While often due to a viral illness, in young children without a source the most common bacterial infection is pyelonephritis. For this reason, when no focal source can be identified a urinary specimen is recommended. In young children who are unable to urinate on demand, a straight catheter is required to obtain a sterile specimen. This is generally a benign procedure and is performed frequently in EDs. We report a case of a young girl who underwent straight bladder catheterization and was subsequently found to have a retained catheter that had become knotted in the bladder. This case report highlights a rare complication of this common procedure and describes the technique required to remove the catheter. An understanding of these issues may avoid the need for transfer to a pediatric facility or for subspecialty consultation. [Clin Pract Cases Emerg Med.2018;2(1):55-57.]

INTRODUCTION

Children visit emergency departments (ED) often, with over 23 million encounters annually in the United States.¹ Fever is one of the most common chief complaints for such visits in young children. In the modern era of widespread immunization, occult bacteremia is virtually nonexistent in the well-appearing child; pyelonephritis, however, remains common, accounting for 3-8% of febrile children.^{2,3} The American Academy of Pediatrics recommends straight catheter urine samples in young children with risk factors, including female sex, persistent fever above 102° Fahrenheit, and absence of an alternative etiology on exam.⁴ This results in a large number of straight catheterization procedures being performed in EDs across the country, as missing this infection can cause chronic problems from renal scarring.

Pediatric straight catheterization is a relatively fast procedure with a low complication rate of infection or pain and high parental acceptance.⁵ There are few descriptions in the literature regarding complications of this common procedure. This case report describes one potential complication, and the procedure providers can use to correct it.

CASE REPORT

A six-month-old previously healthy female presented to our tertiary care pediatric ED with fever and vomiting. Her parents noted that she had recently had mild cough and

congestion but otherwise no significant preceding symptoms. Over the prior 48 hours, however, she had developed persistent fever with a maximum temperature of 39° Celsius and had been vomiting for the preceding 24 hours. The patient was up to date on vaccines, the product of an uncomplicated full-term pregnancy, and had no significant past medical or family history. Her initial vital signs were remarkable for a heart rate of 185 beats per minute, temperature of 38.7°C, and normal oxygen saturation. She was evaluated by a board-certified pediatric emergency physician. The exam was notable only for minimal oropharyngeal erythema and a very mild diaper rash without skin desquamation. Due to the constellation of symptoms, physical exam and duration of high fever, a straight catheter urine sample was ordered to evaluate for pyelonephritis.

The attending physician was later called to the room by the ED nurse due to difficulty removing the catheter from the urethra following urine sample collection with a 5F straight catheter. The experienced nurse reported no resistance or difficulty with insertion and immediate drainage of urine. The physician evaluated the patient and noted the catheter to be appropriately exiting the urethral orifice. There was no external evidence of trauma or genitourinary abnormality. Using sterile technique, the catheter was easily advanced forward but, with gentle traction, could not be withdrawn from the urethra.

A single view abdominal radiograph was then obtained that demonstrated a urinary catheter with the distal tip knotted on itself (Image). Pediatric urology consult recommended repeat gentle traction to remove the catheter; this was re-attempted and again was unsuccessful. Pediatric urology subsequently evaluated the patient in the pediatric ED. Their team was also unsuccessful in removing the catheter with traction only. A range of guidewires was available at the bedside for the urology team to attempt to relieve the knot. They inserted a 0.025-inch diameter guidewire into the catheter and advanced it with minimal resistance. This simple procedure was done without any imaging guidance. The guidewire and catheter were then easily removed without a persistent knot. The patient tolerated the procedure well and was able to feed comfortably within 10 minutes. The urine studies returned and were negative for any sign of infection. After tolerating oral feeds and returning to her baseline level of comfort, the patient was discharged with a short course of cephalexin due to the straight catheter manipulation of the sterile GU system. To our knowledge the patient did well and did not require further interventions following discharge.

DISCUSSION

Few reports in the literature document urethral catheter knotting in the pediatric population. Given that straight catheterization is an extremely common procedure in children, provider knowledge regarding this complication and its potential solutions is critical. Increased awareness may prevent unnecessary subspecialty consultation if the physician feels comfortable advancing a guidewire or may, minimally, allow prompt recognition and urgent transfer to higher levels of care if

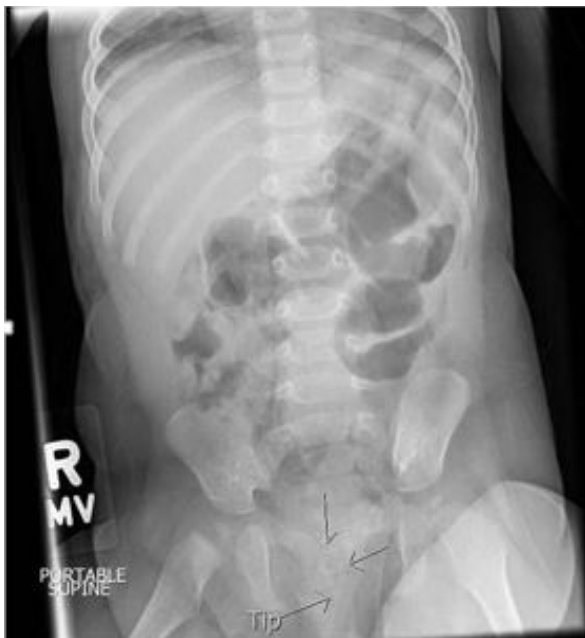

Image. Anteroposterior abdominal radiograph (arrows delineate the catheter location with knot)

CPC-EM Capsule

What do we already know about this clinical entity?
Straight catheters in the pediatric population are common in the emergency department setting, with urinary tract infections being one of the most common bacterial infections.

What makes this presentation of disease reportable?
With the straight catheter procedure so common, complications may arise. Feeling comfortable to deal with this complication is of utmost importance.

What is the major learning point?
If a straight catheter cannot be retracted, one must suspect a knot. Gentle traction is generally successful, but if it isn't successful then passing a guidewire can untie the knot and allow retraction.

How might this improve emergency medicine practice?
This procedure allows treatment at the bedside directly, eliminating unnecessary transfers or prolonged pain for patients.

the knotting occurs in a setting where circumstances do not permit procedural intervention.

There is one previous report of a pediatric emergency patient who experienced a urethral catheter knot that required only gentle traction for removal.⁶ In the case we describe, both the emergency physician and the urologist were unsuccessful in their attempts using that method. The novel feature of our report was the addition of a bedside guidewire procedure to facilitate catheter removal. By using a guidewire that is more firm than the floppy catheter it provides a skeleton to straighten the catheter. By advancing the guidewire slowly, it has the ability to unwind the knot at the end of the catheter. Of note, the procedure required trialing several guidewires of different sizes to assess which could thread easily through the catheter; thus, having a range of guidewire diameters available is essential. As support for this approach, we note that this technique has been used successfully in the radiology suite under fluoroscopic guidance in voiding cystourethrograms.⁷

Though we used radiography to better define this complication, there is one study demonstrating that ultrasound can be used to identify catheter knotting.⁸ Another study used simulation to evaluate risk factors for catheter knotting.⁹ The authors found that catheter size less than 10F – often the size used in pediatric patients such as the one in this report – was a risk

factor. Finally, knotting has also been described with indwelling Foley catheters. However, this may be due to the presence of the retention balloon, a component not present in the straight catheters used for urinary sampling.⁸

CONCLUSION

Urinary straight-catheter sampling complicated by knotting is an infrequent complication and should not deter the provider from appropriate collection of urine in the right clinical scenario. However, knowledge of the different methods used for catheter removal in the setting of this complication is important for any physician treating children. Based on this case report, we recommend gentle traction as first-line therapy and simple guidewire insertion to un-knot the catheter as a second-line procedure. An understanding of these issues may avoid the need for transfer to a pediatric facility or for subspecialty consultation. In addition, it provides a solution to a complication from a common procedure.

Address for Correspondence: David C. Sheridan, MD, Oregon Health & Science University, Department of Emergency Medicine, 707 SW Gaines Rd mail code CDRC-W, Portland, OR 97239. Email: sheridda@ohsu.edu.

Conflicts of Interest: By the CPC-EM article submission agreement, all authors are required to disclose all affiliations, funding sources and financial or management relationships that could be perceived as potential sources of bias. The authors disclosed none.

Copyright: © 2018 Sheridan et al. This is an open access article distributed in accordance with the terms of the Creative Commons Attribution (CC BY 4.0) License. See: <http://creativecommons.org/licenses/by/4.0/>

REFERENCES

- Centers for Disease Control and Prevention (CDC). 2013 National Hospital Ambulatory Medical Care Survey Summary Tables. Available at: https://www.cdc.gov/nchs/data/ahcd/nhamcs_emergency/2013_ed_web_tables.pdf. Accessed May 22, 2017.
- Wilkinson M, Bulloch B, Smith M. Prevalence of occult bacteremia in children aged 3 to 36 months presenting to the emergency department with fever in the postpneumococcal conjugate vaccine era. *Acad Emerg Med*. 2009;16(3):220-5.
- Sood A, Penna FJ, Eleswarapu S, et al. Incidence, admission rates, and economic burden of pediatric emergency department visits for urinary tract infection: data from the nationwide emergency department sample, 2006 to 2011. *J Pediatr Urol*. 2015;11(5):246.e1-8.
- Subcommittee on Urinary Tract Infection. Reaffirmation of AAP Clinical Practice Guideline: The diagnosis and management of the initial urinary tract infection in febrile infants and young children 2-24 months of age. *Pediatrics*. 2016;138(6). doi:10.1542/peds.2016-3026.
- Selekman RE, Sanford MT, Ko LN, Allen IE, Copp HL. Does perception of catheterization limit its use in pediatric UTI? *J Pediatr Urol*. 2017;13(1):48.e1-48.e6.
- Terentiev V, Khentsinsky O, Dickman E, et al. A knotted urethral catheter in the emergency department. *Pediatr Emerg Care*. 2017;33(3):190-1.
- Sambrook AJ, Todd A. Untangling of knotted urethral catheters. *Pediatr Radiol*. 2007;37(4):380-3.
- Bagheri MH, Nabavizadeh SA, Shirazi M, et al. Foley catheter entrapment resulting from the formation of a true knot in a female infant: sonographic findings. *J Clin Ultrasound*. 2009;37(6):360-2.
- Raveenthiran V. Spontaneous knotting of urinary catheters: clinical and experimental observations. *Urol Int*. 2006;77(4):317-21.

Exaggerated Arthropod Bite: A Case Report and Review of the Mimics

Sagah Ahmed, BA*
Elaine Bromberek, MD†
Joelle Borhart, MD†

*George Washington University School of Medicine and Health Sciences, Washington, District of Columbia

†MedStar Georgetown University Hospital, Department of Emergency Medicine, Washington, District of Columbia

Section Editor: Rick A. McPheeters, DO

Submission history: Submitted November 13, 2017; Revision received December 8, 2017; Accepted December 13, 2017

Electronically published January 11, 2018

Full text available through open access at http://escholarship.org/uc/uciem_cpem

DOI: 10.5811/cpsem.2017.12.37034

Exaggerated arthropod bite reactions causing hemorrhagic or necrotic bullous lesions can mimic other serious conditions such as cutaneous anthrax, brown recluse spider bite, and tularemia. A 55-year-old, healthy woman presented to the emergency department with a 3.5-centimeter painless, collapsed hemorrhagic bulla at the left costal margin. She was afebrile and had no systemic symptoms. Laboratory evaluation was unremarkable. She was prescribed silver sulfadiazine cream and mupirocin ointment. The area denuded two days later and the lesion completely healed. This case illustrates the broad differential to be considered when evaluating patients with hemorrhagic bullous lesions. [Clin Pract Cases Emerg Med. 2018;2(1):58-60.]

INTRODUCTION

Dermatologic complaints make up to 5-8% of emergency department (ED) visits in the United States every year.¹ Patients frequently present to the ED for evaluation of a “bug bite,” particularly if their reaction is atypical or dramatic. Although arthropod bites usually result in mild and self-limited symptoms, exaggerated arthropod bite reactions causing hemorrhagic or necrotic bullous lesions can mimic other serious conditions such as cutaneous anthrax, brown recluse spider bite, or tularemia. The following case illustrates the wide differential that should be considered for a patient who presents to the ED with a necrotic bullous lesion.

CASE REPORT

A 55-year-old, otherwise-healthy woman presented to the ED with complaint of a “possible bug bite.” Four days prior, she noticed a small, painless red lesion on her left abdomen. A day later, she noticed that the area had become increasingly red. Over the next 72 hours, the redness expanded and the center of the lesion became dark black in color. She also noticed redness surrounding the darkened area over the prior three days. She did not remember being

bit by a spider or insect, but she is an avid gardener. She lives in Maine, had no significant recent travel, no sick contacts, no contact with non-domesticated animals, and denied systemic symptoms. She reported mild pruritus at the site but no pain.

On physical exam, the patient was afebrile and well appearing with normal vital signs. On her left abdomen at the costal margin there was a 3.5-centimeter (cm), collapsed hemorrhagic bulla and surrounding indurated, non-tender erythema up to two cm from the central bulla. Immediately adjacent to the large bulla, a two-millimeter (mm), clear vesicle was present. A linear erythematous streak extended cranially from the superior aspect of the large bulla (Image 1).

Laboratory studies revealed a white blood cell count of 8,900/mm³ with 81% neutrophils and 10% lymphocytes and an otherwise-normal differential. Electrolytes, liver function tests and coagulation panel were normal. Gram stain showed moderate white blood cells, rare epithelial cells, and no organisms seen. A wound culture showed no growth at three days. Blood cultures were also obtained and were negative. Dermatology was consulted and determined that the patient most likely had an exaggerated arthropod

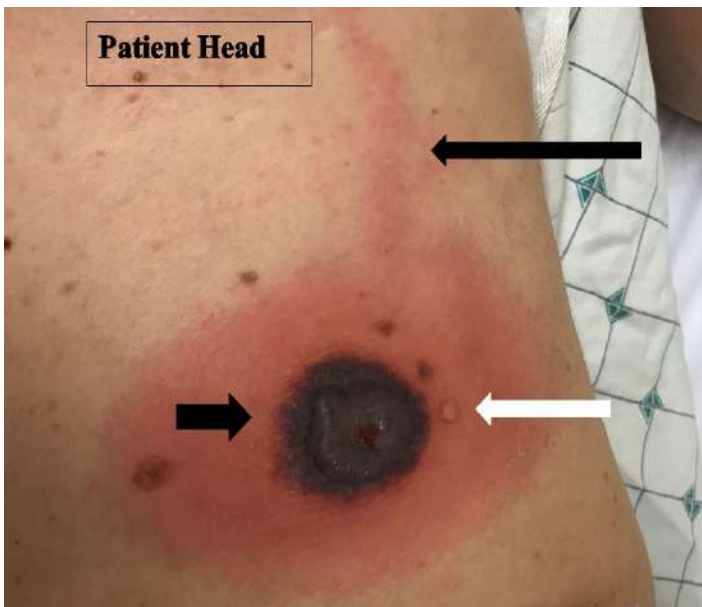


Image 1. Patient lesion. Approximately three-to-four centimeter, collapsed hemorrhagic bulla with two-centimeter, surrounding indurated, non-tender erythema (short black arrow). Immediately adjacent to the large bulla, a two-millimeter, clear vesicle is present (white arrow). A linear erythematous patch extended cranially from the superior aspect of the large bulla and surrounding erythema (long black arrow).

bite reaction. She was prescribed silver sulfadiazine cream to the open area of the wound and mupirocin ointment. The area denuded two days later and the lesion completely healed.

DISCUSSION

Typical arthropod bites cause minor, self-limited symptoms such as pruritic, pink papules only a few millimeters in size. Rarely, bites cause large immunologic reactions known as exaggerated arthropod bites. These can be large, erythematous, pruritic, edematous and sometimes hemorrhagic or necrotic. On histologic examination, they show a high number of eosinophils and a predominance of T- and B-cell lymphocytes.²

Most cases of exaggerated arthropod bites have been described in patients with chronic lymphocytic leukemia and other lymphoproliferative disorders, but patients with known allergies as well as healthy patients have developed similar reactions.² In the absence of a lymphoproliferative disorder, the pathophysiology is related to sensitization of T cells throughout the patient's life. Increased immunoglobulin E production in patients with exaggerated arthropod reactions may also be related. Care is primarily supportive, although topical antibiotics can be used to prevent superinfection.³

Exaggerated arthropod bites can mimic serious conditions such as cutaneous anthrax, brown recluse spider bite, and tularemia. Cutaneous anthrax lesions usually begin as a small, painless, and often pruritic papule that rapidly enlarges and

CPC-EM Capsule

What do we already know about this clinical entity?

Exaggerated arthropod bite reactions tend to occur in patients with lymphoproliferative disorders and can mimic serious conditions such as cutaneous anthrax.

What makes this presentation of disease reportable?

This is a case of a healthy, immune-competent patient with an exaggerated arthropod bite reaction presenting with a hemorrhagic bullous lesion.

What is the major learning point?

Arthropod bite reactions can be atypical or dramatic, even in immune-competent patients.

How might this improve emergency medicine practice?

This case illustrates the wide differential that should be considered for a patient who presents to the emergency department for evaluation of a "bug bite."

develops a central vesicle or bulla in 24-36 hours; the vesicle then becomes necrotic and dried, leaving a characteristic painless black eschar surrounded by extensive edema in the neighboring tissues (Image 2).

Brown recluse spiders are endemic in regions of the Central, South, and Midwestern United States. The initial bite is usually painless and begins as a red plaque that often develops central pallor with occasional surrounding vesiculation (Image 3A).

The lesion becomes increasingly painful over the next two to eight hours. In most cases, the wound is self-limited and resolves without further complications. In less than 10% of cases, however, necrosis will occur within 48-72 hours and the lesion subsequently breaks down into an ulcerating eschar.⁴ Tularemia is a zoonotic infection caused by the aerobic gram-negative coccobacillus, *Francisella tularensis*. Patients usually present with fever and a single erythematous ulcerative lesion with a central eschar at the site of a bite; however, more than one skin lesion may be present (Image 3B).

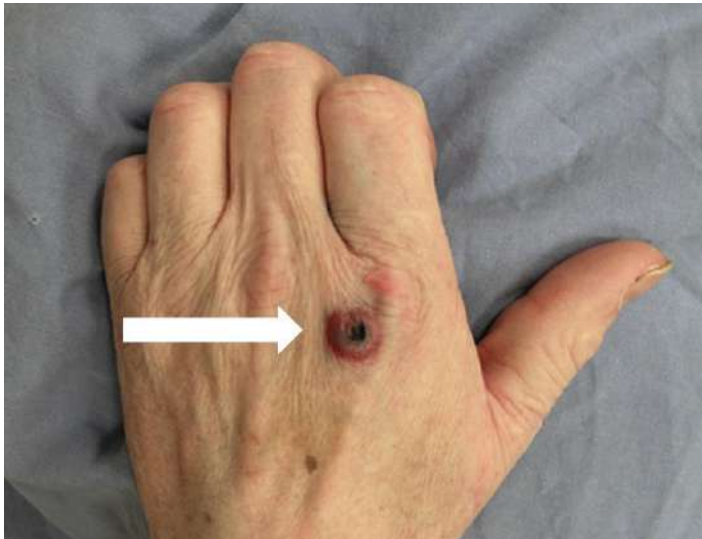


Image 2. Necrotic wound with a hemorrhagic rim on the left hand of a patient with cutaneous anthrax (white arrow). From: Cinquetti G, Banal F, Dupuy A-L, et al. Three related cases of cutaneous anthrax in France. *Medicine* 2009;88:371. (With permission)

CONCLUSION

Patients frequently present to the ED with “bug bites.” Exaggerated arthropod bite reactions are worrisome as they can mimic serious conditions. Emergency physicians must be prepared to use a combination of history, physical exam, geographic location, epidemiologic history, and laboratory results to make a timely and accurate diagnosis.

Address for Correspondence: Joelle Borhart, MD, Georgetown University School of Medicine, 3800 Reservoir Road NW, Washington, DC 20007. Email: joelle.borhart@gmail.com.

Conflicts of Interest: By the *CPC-EM* article submission agreement, all authors are required to disclose all affiliations, funding sources and financial or management relationships that could be perceived as potential sources of bias. The authors disclosed none.

Copyright: © 2018 Ahmed et al. This is an open access article distributed in accordance with the terms of the Creative Commons Attribution ([CC BY 4.0](http://creativecommons.org/licenses/by/4.0/)) License. See: <http://creativecommons.org/licenses/by/4.0/>

REFERENCES

1. Trott AT. Rash. In: Hamilton GC, Sanders A, Strange GS, editors. *Emergency Medicine : An Approach to Clinical Problem-Solving*. Philadelphia, PA: Saunders; 2003:185-206.
2. Davis MD, Perniciaro C, Dahl PR, et al. Exaggerated arthropod-bite lesions in patients with chronic lymphocytic leukemia: A clinical, histopathologic and immunopathologic study eight patients. *J Am Acad Dermatol*. 1998; 39(1); 27-35.
3. Tatsuno K, Fujiyama T, Matsuoka H, et al. Clinical categories of exaggerated skin reactions to mosquito bites and their pathophysiology. *J Dermatol Sci*. 2016;82(3):145-52.
4. Isbister GK, Fan HW, Guatimosim C, et al. Spider bite. *Lancet*. 2011;378(9808):2039-47.

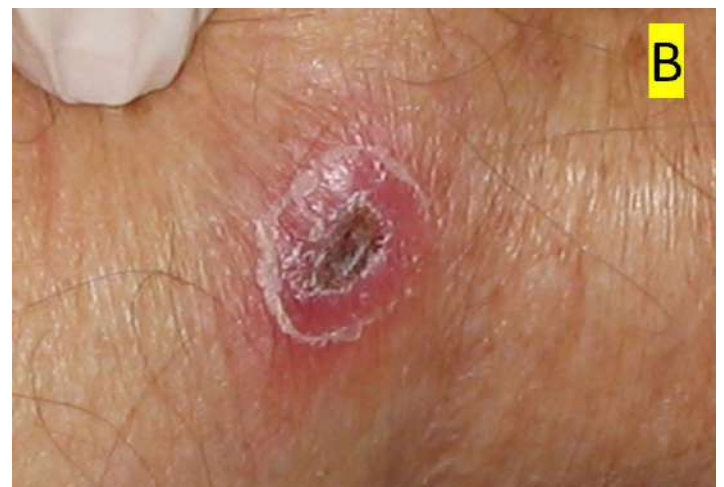
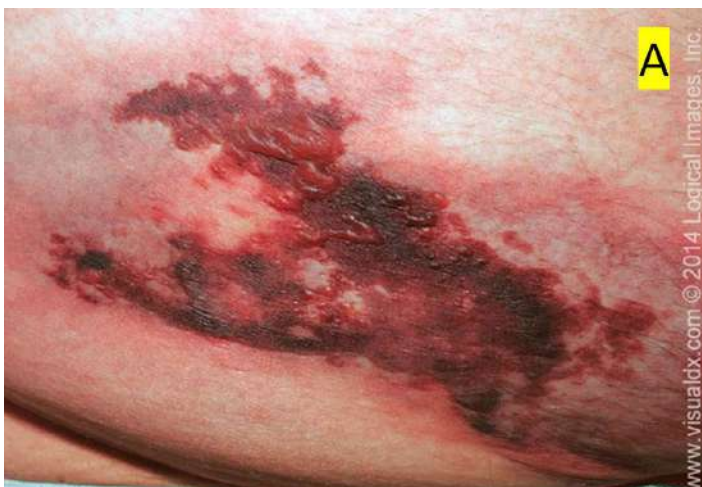
Image 3. A) Brown recluse spider bite. From: www.visualdx.com, Logical Images, Inc. Graphic 96174, with permission, B) and tularemia, courtesy of Todd M Pollack, MD.

A Walk in the Park: A Case of Babesiosis in the South Bronx

Christina Hajicharalambous, DO, MS*
Mohammad Rattu, DO†
Scott Leuchten, DO*

*Saint Barnabas Hospital Health System, Department of Emergency Medicine,
Bronx, New York
†Inspira Health Network, Department of Family Medicine, Vineland, New Jersey

Section Editor: Rick A. McPheeters, DO

Submission history: Submitted August 11, 2017; Revision received October 18, 2017; Accepted October 13, 2017

Electronically published January 11, 2018

Full text available through open access at http://escholarship.org/uc/uciem_cpccem

DOI: 10.5811/cpcem.2017.8.35924

Babesiosis, mainly endemic within the Northeastern and upper Midwestern regions of the United States, is a zoonotic disease that invades and lyses red blood cells, which can result in hemolytic anemia. Its decreased incidence in comparison to Lyme disease is often attributed to the greater asymptomatic infection proportion and insufficient physician awareness or suspicion of this disease. Here we describe a case of undifferentiated febrile illness with hemolytic anemia that yielded the diagnosis of babesiosis. [Clin Pract Cases Emerg Med. 2018;2(1):61-63.]

INTRODUCTION

Babesiosis is endemic within the Northeastern and upper Midwestern regions of the United States and is a reportable disease in 27 states.¹ *Babesia microti* is the predominant species and mimics the progression of Lyme disease due to having the same vector, the black-legged tick *Ixodes scapularis*. According to national reported disease cases, the infection prevalence rate of *Borrelia burgdorferi* is approximately 25 times greater than *B. microti*.² This discrepancy in rates is twofold. Younger individuals often have minimal symptoms and do not seek medical attention. In a cohort study by Krause et al.,³ asymptomatic *B. microti* infections were found in about 20% of adults and half of children in endemic Rhode Island. The lower reported incidence is also attributed to difficulty in diagnosis, lack of physician awareness and deficiency of concomitant testing for babesiosis when suspicious for Lyme disease.²

The parasite is spread from the young nymph stage, seeking blood during warm months. Humans are incidentally bitten by infected ticks during a blood meal, from which the tick will introduce sporozoites into the human host. Sporozoites will then reach the blood and invade erythrocytes and differentiate into trophozoites. Lysis of the infected red blood cells leads to the most common clinical manifestation of the disease, hemolytic anemia. Fragmented red blood cells can further cause renal failure. T cells that express the cluster of differentiation, four surface protein (CD4-positive T cells), are needed for adequate response and resolution of *B. microti* infection according to studies done on mice.⁴ As a result, the immunocompromised population, including those with human immunodeficiency

virus, malignancy, or on immunosuppressive treatments, is at higher risk for complications with mortality rates reported as high as 20%, compared to 5-9% of all hospitalized patients with the disease. Other risk factors for development of severe disease are those older than 50 years of age or patients with previous splenectomy.¹

CASE REPORT

A 66-year-old male with past medical history significant for hypertension, insulin-dependent diabetes, hyperlipidemia, and chronic kidney disease presented to the emergency department with progressive dyspnea and generalized weakness over the prior four days. He could previously walk up three flights of stairs without difficulty, but now could only walk up one flight before becoming dyspneic. He had associated tactile fever and weakness, which he described as decreased stamina. He also noted the chronic swelling of his bilateral lower extremities worsening over the same time period. He was not pale or icteric on skin examination. He denied associated orthopnea, cough, headache, abdominal pain, urinary complaints, sick contacts or recent travel.

On initial arrival, the patient was febrile to 38.2 degrees Celsius (°C), with a blood pressure of 131/71 millimeters of mercury (HHmg), heart rate of 80 beats per minute, respiratory rate of 18 per minute and saturating 96% on room air. He was a nontoxic-appearing obese male who was able to speak in full sentences. His heart was regular in rate and rhythm but had a grade two systolic ejection murmur. His lung sounds were clear with normal respiratory effort and symmetric chest expansion

and without abnormal breath sounds. His abdominal exam was unremarkable. He had plus two pitting edema bilaterally without calf tenderness and his skin was warm without skin eruptions.

His initial laboratory evaluation was remarkable for a mild anemia (hemoglobin and hematocrit [H and H] 10.3 grams per deciliter/ 29.2%), mild transaminitis (alanine aminotransferase [ALT] and aspartate aminotransferase [AST] of 56 international units per liter [IU/L] and 66 IU/L respectively) and thrombocytopenia at 88,000 per microliter (uL). The patient was admitted to the general medical floor for sepsis with unknown source and dyspnea. He was persistently febrile with a maximum temperature of up to 39.4°C despite treatment with broad spectrum antibiotics. On hospital day two, the patient's H and H precipitously dropped from 10.3 gm/dL /29.2% on admission to 6.0 gm/dL /16.9% with a concomitant increase in blood urea nitrogen (BUN)/creatinine (Cr) and ALT/AST that reached maximum levels of 94/10.4 milligrams per deciliter and 63/78IU/L respectively, and a thrombocytopenia that fell to 66,000/uL. It was determined that the patient was hemolyzing with reticulocytes of 2.7% and lactate dehydrogenase of 631 IU/L. Upon further questioning, the patient stated that three weeks prior he had been at a local state park for a day trip. He denied drinking water from any source and did not recall any tick or other insect bites.

Given his acute decompensation and hemolytic anemia, he was transferred to an intensive care unit step-down unit for close monitoring. Blood, urine and sputum cultures were all negative, and a repeat radiograph of the chest was also unremarkable. A peripheral blood smear (Image 1) was performed with the given clinical picture of fever, thrombocytopenia and hemolytic anemia, and the diagnosis of babesiosis was ultimately made. Atovaquone was added to the patient's medication regimen with improvement

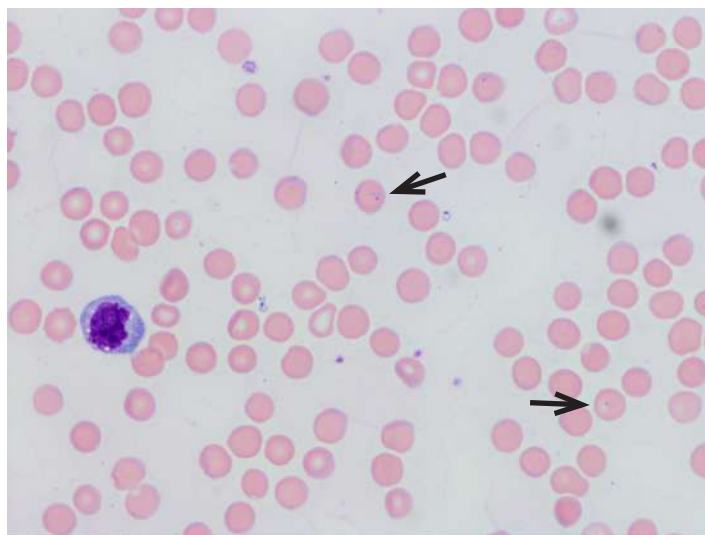


Image 1. Peripheral blood smear of patient, with arrows showing intraerythrocytic parasites seen in babesiosis

CPC-EM Capsule

What do we already know about this clinical entity?

Babesiosis is a parasitic disease that presents similarly to Lyme disease with fever, anemia and thrombocytopenia. It can cause severe illness in immunocompromised patients.

What makes this presentation of disease reportable?

Babesiosis is a reportable disease as it is endemic to the northeast and upper midwest regions of the United States.

What is the major learning point?

The threshold to ordering a peripheral smear should be low and considered as a concomitant test with Lyme titers.

How might this improve emergency medicine practice?

Diagnosis in the emergency department can facilitate initiation of correct treatment in hope to hasten the complications of severe parasite load.

in both clinical status and renal and hepatic function. On hospital day seven, he was discharged home in stable condition without sequelae from illness.

DISCUSSION

The most frequently reported presenting symptoms of babesiosis are fever (91%), fatigue, malaise, weakness (91%), and shaking chills (77%). When adding hemolytic anemia, this presentation still holds a broad differential including malaria, babesiosis, ehrlichiosis, relapsing fever, Chagas disease, thrombotic thrombocytopenic purpura, immune thrombocytopenic purpura, hemolytic uremic syndrome, and disseminated intravascular coagulation among other causes. This patient initially presented with vague symptoms associated with babesiosis, but did not show classic laboratory findings of disease until hospital day two. Early in the presentation, patients with babesiosis may have nonspecific findings similar to our patient. A peripheral smear performed early in the disease process may not be conclusive for babesiosis. For this reason, knowledge of babesiosis is important for emergency physicians in order to recognize this condition and prevent the downstream complications.

More severe complications from babesiosis include congestive heart failure, disseminated intravascular coagulation, myocardial infarction, renal failure and acute respiratory

distress syndrome.⁶ These are more commonly seen in the elderly and the immunocompromised patients and are associated with higher parasite loads.

The diagnosis of babesiosis can be made by Giemsa or Wright staining of peripheral smear through visualization of intraerythrocytic parasites. A distinct feature of the parasite is the formation of tetrads (Image 2) giving the characteristic appearance of a Maltese cross. Polymerase chain reaction (PCR) can also assist in the diagnosis and is indicated when clinical suspicion is high and multiple peripheral smears do not give the diagnosis. PCR has also been shown to be more sensitive and comparatively specific in the acute diagnosis of the disease.⁵

For the symptomatic patient, symptoms may develop as late as one to four weeks post exposure. Thus, it is important for emergency physicians to ask about recent travel, including in the prior four to six weeks, when obtaining a history. Treatment recommendations for moderate disease, as per the Centers for Disease Control and Prevention, include at least 7-10 days of two prescription medications, atovaquone plus azithromycin orally, or clindamycin plus quinine.⁷ Studies have shown that the treatment with the latter had increased rate of adverse effects, 15% vs. 72% respectively, with tinnitus being the most common.⁷ It did, however, show better promise in the treatment outcome for severely immunocompromised and decompensating patients.⁸ In immunosuppressed patients, treatment includes high-dose azithromycin plus atovaquone for six weeks and renal exchange transfusions if parasite load exceeds 10%.

CONCLUSION

The diagnosis of babesiosis is difficult to make in the ED particularly when the clinical presentation is early in the course of the disease and suspicion is low, even in endemic

areas. Keeping babesiosis in the differential when patients present with fever and anemia with thrombocytopenia is important, and a peripheral smear should be performed if suspicion exists. The threshold for ordering a peripheral smear should be low and considered as a concomitant test with Lyme titers. Although an urban setting is not typically associated with babesiosis, obtaining a travel history is critical and may serve as supporting evidence of infectious etiology. Even when suspicion is high and a peripheral smear is negative, PCR can be considered as it is a more sensitive method of detection.

Address for Correspondence: Christina Hajicharalambous, DO, MS, Saint Barnabas Hospital Health System, 4422 3rd Avenue, Bronx, NY, 10457. Email: CHajicharalambous@sbnhny.org.

Conflicts of Interest: By the CPC-EM article submission agreement, all authors are required to disclose all affiliations, funding sources and financial or management relationships that could be perceived as potential sources of bias. The authors disclosed none.

Copyright: © 2018 Hajicharalambous et al. This is an open access article distributed in accordance with the terms of the Creative Commons Attribution (CC BY 4.0) License. See: <http://creativecommons.org/licenses/by/4.0/>

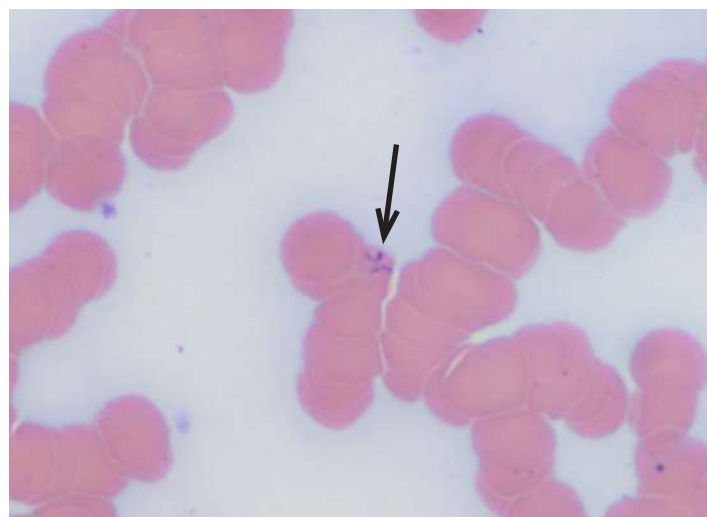


Image 2. Patient's blood smear with arrow showing intracellular formation of tetrads classically seen in babesiosis. This is also commonly described as a Maltese cross.

REFERENCES

1. Vannier EG, Diuk-Wasser MA, Ben Mamoun C, et al. Babesiosis. *Infect Dis Clin North Am.* 2015;29(2):357-70.
2. Diuk-Wasser M, Liu L, Steeves T, et al. Monitoring human babesiosis emergence through vector surveillance New England USA. *Emerg Infect Dis.* 2014; 20(2):225–31.
3. Krause PJ, McKay K, Gadbar J, et al. Increasing health burden of human babesiosis in endemic sites. *Am J Trop Med Hyg.* 2003;68(4):431–6.
4. Igarashi I, Waki S, Ito M, et al. Role of CD4+ T cells in the control of primary infection with *Babesia microti* in mice. *J Protozool Res.* 1194;4:164-71.
5. Krause PJ, Telford SR, Spielman A, et al. Comparison of PCR with blood smear and inoculation of small animals for diagnosis of *Babesia microti* parasitemia. *J Clin Microbiol.* 1996; 34:2791–4.
6. White DJ, Talarico J, Chang HG, et al. Human babesiosis in New York State: review of 139 hospitalized cases and analysis of prognostic factors. *Arch Intern Med.* 1998;158(19):2149-54.
7. Krause PJ, Lepore T, Sikand VJ, et al. Atovaquone and azithromycin for the treatment of human babesiosis. *N Engl J Med.* 2000;343(20):1454–8.
8. Vannier E, Gewurz BE, Krause PJ, et al. Human babesiosis. *Infect Dis Clin North Am.* 2008;22(3):469-ix.

Traumatic Fetal Intracranial Hemorrhage Suggested by Point-of-Care Ultrasound

Nicole Chicoine Mooney, JD, MD*
Lei Wu, MD†
Michael E. Vrablik, DO*

*University of Washington, Department of Emergency Medicine, Seattle, Washington

†University of Washington, Department of Radiology, Seattle, Washington

Section Editor: Shadi Lahham, MD, MS

Submission history: Submitted August 25, 2017; Revision received November 8, 2017; Accepted November 28, 2017

Electronically published January 18, 2018

Full text available through open access at http://escholarship.org/uc/uciem_cpem

DOI: 10.5811/cpcem.2017.11.36214

While the use of ultrasound to diagnose a fetal intracranial hemorrhage in utero is not a new concept, the emphasis of point-of-care ultrasound (POCUS) at the initial trauma presentation of the mother to evaluate for fetal injury is novel. A review of the literature failed to reveal a single case report wherein POCUS in the workup of a pregnant trauma patient led to the diagnosis of fetal intracranial hemorrhage. This is such a case. [Clin Pract Cases Emerg Med. 2018;2(1):64-66.]

INTRODUCTION

Prenatal detection of intracranial hemorrhage is extremely rare,¹ estimated as only one per 10,000 pregnancies.² Even rarer is the detection of fetal intracranial hemorrhage as a result of maternal trauma. While this report highlights a rare case of fetal intracranial hemorrhage due to maternal trauma, it is most noteworthy for the role that point-of-care ultrasound (POCUS) played in the initial evaluation of the mother, which ultimately led to the discovery that the fetus had suffered an intracranial hemorrhage. No similar report can be found in the literature that describes the use of POCUS to evaluate a pregnant trauma patient at the initial presentation in the emergency department (ED) and ultimate discovery of fetal intracranial injury. This case also demonstrates the extensive and unique coordination required of the emergency medicine (EM), obstetrics, neurosurgery, medicine, surgery, and radiology services to diagnose and manage the injuries of both the patient and her fetus.

CASE REPORT

The patient was a 46-year-old, gravida five, parity four (G5P4) at 24 weeks and five days (24w5d) gestation by last routine ultrasound, who presented to our Level 1 trauma ED after being a front-seat restrained (by a lap-shoulder belt) passenger in a high-speed rollover motor vehicle collision (MVC), with unknown loss of consciousness. The patient arrived hemodynamically stable but complaining of abdominal, pelvic, and back pain. She had no personal or family history of any coagulation disorder, was not being treated with any

anticoagulant, and denied any use of illicit drugs.

Initial examination revealed a gravid woman in a cervical spine collar, on a backboard, and moving all extremities. Vital signs were pulse of 98 beats per minute; blood pressure of 108/59 millimeters of mercury; respiration of 24 breaths per minute; and oxygen saturation of 99% on room air. The secondary survey revealed two facial lacerations, thoracic (T) and lumbar (L) spinal tenderness, a gravid uterus, tender abdomen, abdominal ecchymosis consistent with a seat-belt sign, and reduced strength in the right lower extremity, but otherwise neurologically intact. The initial pelvic radiograph revealed a left sacral fracture. Cardiotocographic monitoring revealed a fetal heart rate ranging from 130s-170s, with periodic decelerations.

POCUS was performed using a SonoSite Micomaxx (FUJIFILM SonoSite, Inc.), curvilinear transducer with abdominal and obstetric settings. An emergency extended focused assessment with sonography for trauma (eFAST) and POCUS, were performed by an EM resident and an ultrasound fellowship-trained EM attending, to evaluate for maternal injury and fetal viability, size, position, multiparity, age, and placental abruption. The eFAST was negative. The POCUS revealed a viable single fetus, a biparietal diameter of 6.58 centimeters (cm), consistent with a gestation of 26w4d. Based on the patient's stated gestational age, the fetal gestation should have been 24w5d. This discrepancy of almost two weeks was abnormal. The emergency physicians were concerned for fetal intracranial injury, prompting further fetal imaging and immediate consultation with obstetrics (Image 1).

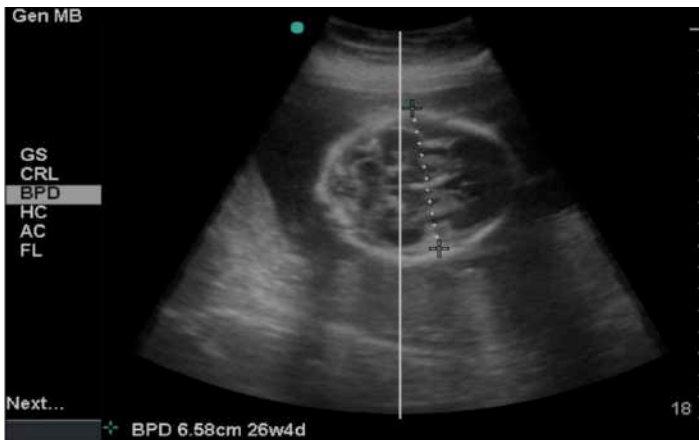

Image 1. Emergent point-of-care transabdominal ultrasound demonstrated a biparietal diameter of 6.58 centimeters - consistent with a fetal gestation of 26 weeks 4 days. Based on the patient's reported gestational age, the fetal gestation should have been 24 weeks 5 days. This discrepancy raised concern for fetal intracranial injury.

A formal obstetric ultrasound was subsequently performed, which revealed a biparietal diameter of 6.8 cm and head circumference of 24.5 cm, consistent with fetal gestation of 27w3d and 26w5d respectively, bilateral extra-axial fluid collections concerning for subdural hematomas, and no placental abruption. A subsequent ultrasound with color and Doppler of fetal middle cerebral artery was performed, which revealed normal bilateral Doppler.

Based upon the mechanism of injury and physical examination, the patient underwent a computed tomography (CT) of the head and full spine, with CT angiography (CTA) of the abdomen and pelvis. The CT head revealed a left mandibular and right nasal arch fractures. The CT full spine was notable for a three-column fracture of the T12 vertebral body, bilateral T12 and L1 transverse process fractures, and an oblique fracture of L1 vertebral body. The CTA revealed 10th and 11th left posterior rib fractures, fetal subdural hematomas, and fetal skull diastasis (Image 2).

Neurosurgery determined that the patient's spinal fractures were unstable, requiring full T&L spine precautions and surgical intervention for decompression and stabilization. A joint decision was made by the EM, obstetrics, neurosurgery, surgery, and medicine services to admit the patient to the medicine intensive care unit for observation and spinal precautions, a planned Cesarean section (C-section) at a later date, provided the fetus remained stable, and maternal spinal surgery immediately after delivery. Simultaneous delivery of the fetus and spinal surgery for the patient was determined to be too risky to both the patient and fetus.

The patient's spinal precautions included log roll procedures with turning and lying flat on an automatic tilting bed for the duration of her pregnancy. (The patient was unable to wear a

CPC-EM Capsule

What do we already know about this clinical entity?

Fetal intracranial hemorrhages are rare. No etiology is found in most cases. Fetal intracranial hemorrhages are usually detected at routine prenatal sonography.

What makes this presentation of disease reportable?

A point-of-care ultrasound (POCUS) used in evaluating a trauma patient led to the discovery that her fetus had suffered an intracranial bleed. No similar report can be found in the literature.

What is the major learning point?

Consider a POCUS in the evaluation of the gravid trauma patient. Any discrepancy in biparietal measurement with gestational age should raise concern for fetal intracranial injury.

How might this improve emergency medicine practice?

This case demonstrates the value in performing a POCUS when evaluating the gravid trauma patient. It can aid in the early detection of fetal intracranial injury, as well as maternal injury.

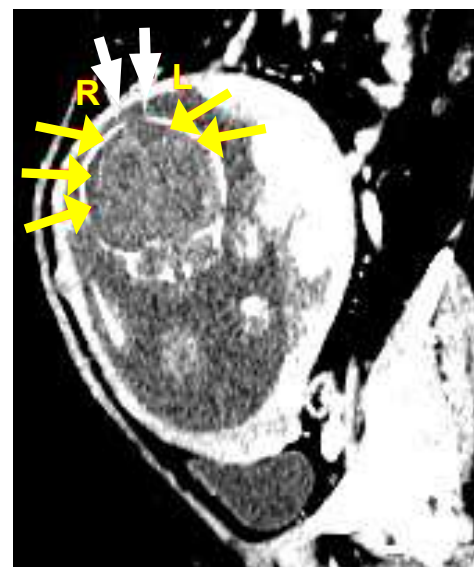

Image 2. Computed tomography angiography abdomen and pelvis sagittal view revealed bilateral subdural hematomas (yellow arrows) and fetal skull diastasis (white arrows).

thoracolumbosacral orthosis due to her gravid uterus.) At 33w6d, 64 days after the patient's accident, while on a backboard for spinal precautions, the patient underwent a C-section, delivering a viable male fetus with encephalomalacia and microcephaly likely due to the bilateral subdural hematomas. Immediately post-delivery, the patient underwent spinal imaging, which revealed stable spinal fractures that no longer required surgery. The patient was eventually moved to a rehabilitation facility for intensive physical therapy. At time of discharge, the patient's son suffered from encephalomalacia with microcephaly, mild extremity hypertonia, hyper-reflexia, and aspiration with feeding requiring a nasal-gastric tube.

DISCUSSION

Causes of extremely rare fetal intracranial hemorrhages include maternal trauma, maternal and fetal coagulation disorders, twin-to-twin transfusion syndrome, maternal use of warfarin or cocaine, and maternal infection.^{1,2,3} No etiology is found in most cases.^{1,2,3} Fetal intracranial hemorrhage in the circumstance of maternal trauma tends to be even rarer due to the fact that the cushion of the uterus and amniotic fluid are protective.⁴ When such fetal injuries exist, it is evidence of the magnitude of blunt force to the maternal abdomen.⁴

Fetal intracranial hemorrhage may be epidural, subdural, subarachnoid, intraventricular or intraparenchymal.³ Intraventricular hemorrhage is the most common type of perinatal and neonatal intracranial hemorrhage.⁴ Epidural and subdural hematomas are most often due to trauma.¹ Most intraventricular hemorrhages are the result of thrombocytopenia, fetal coagulation disorders or hypoxia.¹ The prognosis of fetal intracranial hemorrhages is poor, with approximately 40% of fetuses dying in utero or within the first month of life.^{2,3} Of those that survive, 50% have neurological dysfunction or delay.^{1,2,3} Subdural hematomas have the best prognosis.¹

Most fetal intracranial hemorrhages are detected at routine prenatal sonography. A 2003 case report describes a 20-year-old woman, at 28w gestation, involved in a MVC.⁴ An ED POCUS failed to show any fetal abnormalities.⁴ The patient was taken urgently to the operating room for diaphragmatic repair, wherein the fetus decompensated intraoperatively, a placental abruption was identified, and an emergency C-section was performed.⁴ A formal, postpartum ultrasound of the newborn's head revealed bilateral subdural hematomas, a left frontal and occipitotemporal intracranial hemorrhages, later confirmed by CT.⁴ The failure of the ED POCUS to identify any fetal intracranial hemorrhage was likely due to limited technology and image quality at the time.

Fetal intracranial hemorrhage can be challenging to identify.² Sonography is the diagnostic modality of choice.³ Magnetic resonance imaging (MRI) often follows to confirm the presence of an intracranial hemorrhage, as ultrasound has low sensitivity for small hemorrhages, and an MRI is helpful for estimation for time of and evolution of the bleeding.³ Sonographic evidence of a fetal intracranial hemorrhage depends upon the timing

of the ultrasound in relation to the insult.¹ If the bleed occurs within 24-48 hours of the ultrasound, the sonographer should see hyperechoic signals without posterior shadowing.^{1,2} After 48 hours, as blood reabsorption begins, the sonographer should see varying degrees of echo densities.¹ Ultimately, the area of the bleed will become anechoic and a cyst may form.^{1,2,3}

An MRI should be subsequently performed to confirm the extent and timing of the fetal intracranial hemorrhage and for further evaluation of the fetal brain. An MRI has higher sensitivity and specificity than sonography and carries no radiation risk. However, in the setting of significant maternal trauma, it is imperative that catastrophic injuries of the patient be identified emergently. CT imaging (as opposed to MRI) should be performed, despite the radiation risk, as it is readily available and offers better temporal and spatial resolution.

CONCLUSION

While this case is a very rare event of a fetal intracranial hemorrhage in the setting of maternal trauma, it is novel in that it demonstrates the value of POCUS in an attempt to identify early fetal injury. It also emphasizes the extensive coordination required to diagnose and manage both the traumatic injuries of both the patient and the fetus.

Address for Correspondence: Nicole Chicoine Mooney, JD, MD, University of Washington, Department of Emergency Medicine, 325 9th Avenue, Box 359702, Seattle, WA 98104. Email: nmc7@uw.edu.

Conflicts of Interest: By the CPC-EM article submission agreement, all authors are required to disclose all affiliations, funding sources and financial or management relationships that could be perceived as potential sources of bias. The authors disclosed none.

Copyright: © 2018 Mooney et al. This is an open access article distributed in accordance with the terms of the Creative Commons Attribution (CC BY 4.0) License. See: <http://creativecommons.org/licenses/by/4.0/>

REFERENCES

- Ghi T, Simonazzi G, Perolol A, et. al. Outcome of Antenatally Diagnosed Intracranial Hemorrhage. Case Series and Review of the Literature. *Ultrasound Obstet Gynecol* 2003;22:121-130.
- Muench M, Zheng, M, Bilica, P, Canterino, C. Prenatal Diagnosis of a Fetal Epidural Hematoma Using 2-and3-Dimensional Sonography and Magnetic Resonance Imaging. *J Ultrasound Med* 2008;27:1369-1373.
- Kutuk, M, Yikilmaz, A, Ozgyn, M, et. al. Prenatal Diagnosis and Postnatal Outcome of Fetal Intracranial Hemorrhage. *Childs Nerv Syst* (2014)30:411-418.
- Alley, J, Yahagi, Y, Moncure, M, Strickler, J. A Case of In Utero Fetal Brain Trauma after Motor Vehicle Collision. *J Trauma*. 2003;55:782-785.

Central Venous Catheter-directed Tissue Plasminogen Activator in Massive Pulmonary Embolism

Vishal Gulati, MD
Jared Brazg, MD

Maimonides Medical Center, Department of Emergency Medicine, Brooklyn, New York

Section Editor: Rick A. McPheeters, DO

Submission history: Submitted August 1, 2017; Revision received October 12, 2017; Accepted November 9, 2017

Electronically published January 18, 2018

Full text available through open access at http://escholarship.org/uc/uciem_cpem

DOI: 10.5811/cpcem.2017.11.35845

We present the case of an 88-year-old female who presented to the emergency department (ED) with suspected massive pulmonary embolism (PE) causing respiratory failure, right heart strain, and shock, who despite early and aggressive resuscitation with vasopressors and continuous peripheral infusion of tissue plasminogen activator (tPA), suffered a cardiac arrest in the ED. We describe the approach of a tPA bolus directed through a central venous catheter, resulting in return of spontaneous circulation and immediate improvement in physiologic parameters prior to confirmation of PE with computed tomography angiogram. We further hypothesize that in patients deemed too unstable to be transferred for embolectomy or catheter-directed thrombolysis, central venous catheter-directed bolus tPA may be more effective than peripheral infusion alone. [Clin Pract Cases Emerg Med. 2018;2(1):67-70.]

INTRODUCTION

Pulmonary embolism (PE) is a common life-threatening cardiovascular condition encountered by emergency physicians, with presentations ranging from incidental asymptomatic sub-segmental pulmonary embolus to massive saddle embolus and circulatory collapse. In general, thrombolysis and surgical thrombectomy are reserved for cases of massive PE, as defined by acute PE associated with persistent hypotension or shock. Thrombolytic regimens, however, vary among different studies with no clear recommendation on ideal dosage or route of administration. The American College of Emergency Physicians (ACEP) clinical policy on management of PE gives a level B recommendation to “administer thrombolytic therapy in hemodynamically unstable patients with confirmed PE for whom the benefits of treatment outweigh the risks of life-threatening bleeding complications,” and a level C recommendation to “consider thrombolytic therapy in hemodynamically unstable patients with a high clinical suspicion for PE for whom the diagnosis of PE cannot be confirmed in a timely manner.”¹ The following case demonstrates the successful administration of tissue plasminogen activator (tPA) through a central venous catheter (CVC) in an elderly female with massive PE.

CASE REPORT

The patient was an 88-year-old female with medical history significant for hypertension and hyperlipidemia who presented to the emergency department (ED) following a respiratory arrest. The patient was at home and had a syncopal episode while getting dressed. Paramedics arrived to find the patient hypoxic and in respiratory failure. She was intubated after receiving 10 milligrams of diazepam intravenously and transported to our ED. Her pre-hospital capillary glucose measurement was 230 milligrams per deciliter (mg/dL). Her presenting exam was notable for an obese elderly female, intubated and sedated with heart rate of 92 beats per minute (bpm), blood pressure 53/40 millimeters of mercury (mmHg), respiratory rate 21 breaths per minute by manual bag, end-tidal carbon dioxide (CO₂) 14, and oxygen saturation of 88% on 100% fraction of inspired oxygen (FiO₂). Her pupils were equal and reactive, and her heart, lung, and abdominal exam was unremarkable. She had cool extremities with peripheral cyanosis but palpable distal pulses. No spontaneous extremity movements were noted. A 12-lead electrocardiogram (ECG) showed a right bundle branch block without signs of acute myocardial infarction and no prior ECG for comparison (Image 1).

In addition to a fluid bolus, a peripheral norepinephrine infusion and 1 milligram per minute of 50 milligrams tPA was started as an intravenous (IV) piggy-back while a CVC was being prepared. A bedside echocardiogram showed significant dilation of the right ventricle (Image 2).

Given the sudden cardiac arrest with hypoxia, persistent hypotension, and the echocardiogram findings with no acute myocardial infarction on the ECG, the most likely diagnosis was thought to be massive PE. The patient did not have any significant response to the initial infusion of thrombolytics. A right internal jugular CVC was inserted under sterile conditions. Moments later, the patient became bradycardic and then pulseless. Cardiopulmonary resuscitation (CPR) was initiated and two minutes of chest compressions were performed to complete the first round. Subsequently, the decision was made to push a 50mg tPA bolus through the CVC. CPR continued for four additional minutes and the patient had a total of 1 milligram of epinephrine and 75 milliequivalents of bicarbonate given, after which return of spontaneous circulation (ROSC) was achieved. Almost immediately following ROSC, the patient's hemodynamics improved to a heart rate 87bpm, respiratory rate of 20, blood pressure 139/67mmHg, and oxygen saturation 99% on the ventilator. She was also following commands and moving all extremities. A computed tomography angiogram (CTA) of the chest showed extensive acute thromboembolic clot burden involving the right and left main, lobar, segmental, and subsegmental arteries (Image 3).

CPC-EM Capsule

What do we already know about this clinical entity?

Death from massive pulmonary embolism (PE) is due to hemodynamic collapse. The only emergency department intervention that likely improves survival rates in massive PE is thrombolysis.

What makes this presentation of disease reportable?

Not much is known about the ideal route and dose of tissue plasminogen activator for patients with massive PE who have hemodynamic collapse.

What is the major learning point?

We suggest a central catheter-directed thrombolytic bolus to improve drug efficacy in patients with cardiac arrest from massive PE.

How might this improve emergency medicine practice?

This specific treatment modality may reduce mortality rates in patients with massive PE.

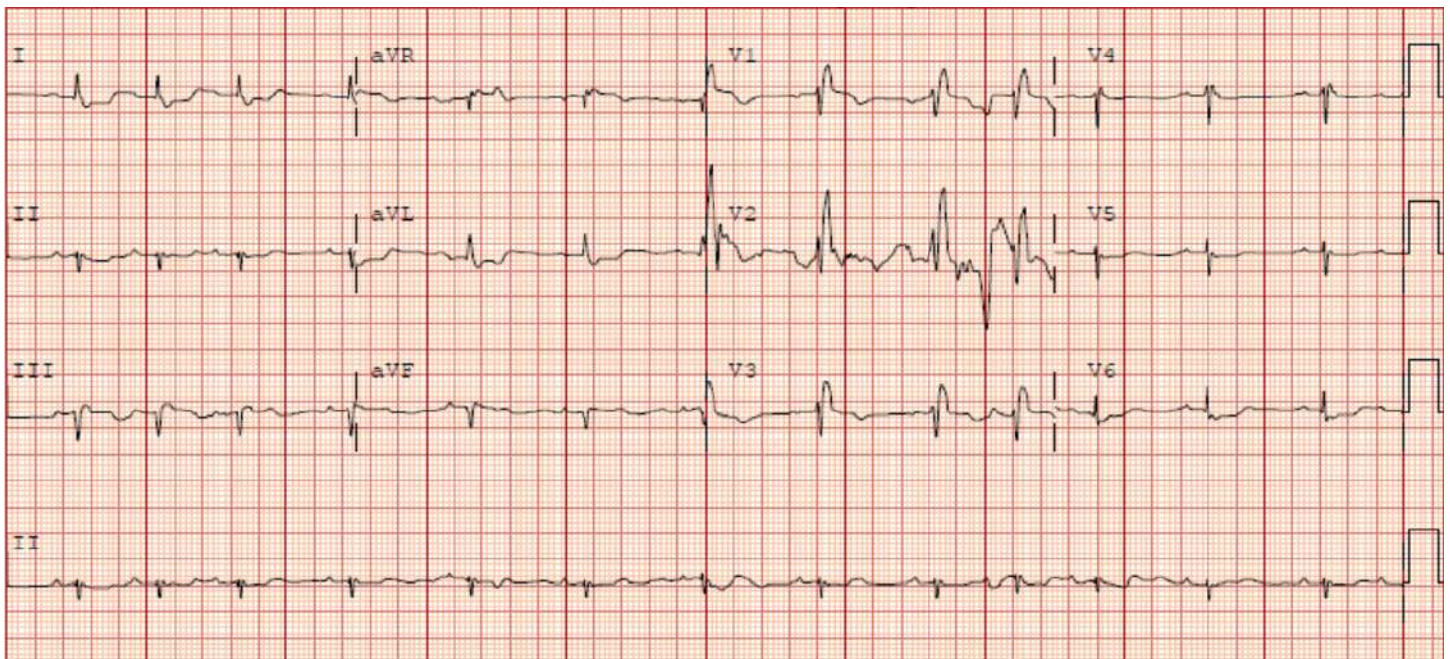


Image 1. Initial 12-lead electrocardiogram showing signs of right heart strain including right bundle branch block and right axis deviation in patient found to have large pulmonary embolism.

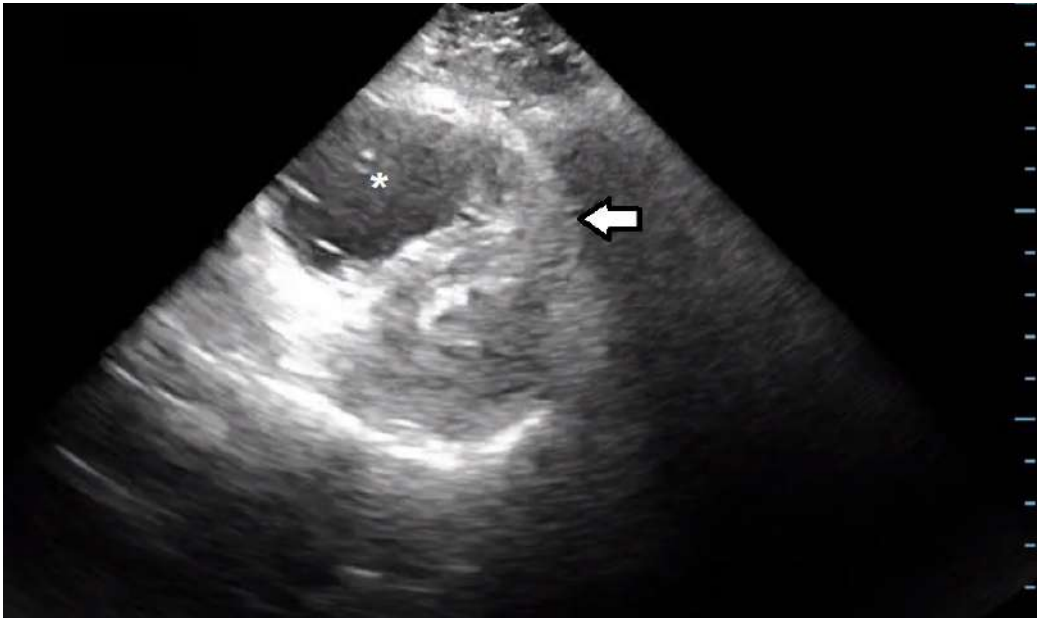


Image 2. Point-of-care cardiac ultrasound, short-axis view demonstrating right ventricular dilation (asterisk) and paradoxical septal position (arrow).

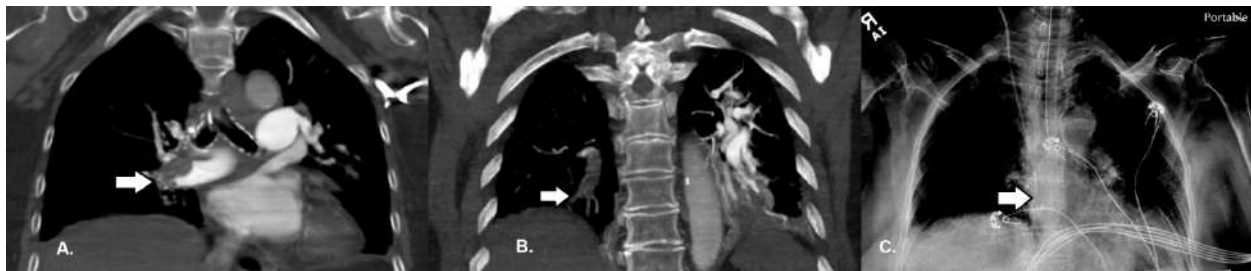

Image 3. Coronal computed tomographic angiography in coronal view with arrows demonstrating A) large right main pulmonary artery, and B) subsegmental pulmonary embolisms; and C) portable chest radiograph showing catheter tip position in the superior vena cava (arrow).

The patient was admitted to the medical intensive care unit for further management. She was discharged home on hospital day 13 at her baseline functional status on oral apixaban.

DISCUSSION

We present a case of massive PE that was strongly suspected based on history and physical exam and supported by the use of point-of-care ultrasound. The resulting hemodynamic collapse in this elderly female was thought to be successfully treated with CVC-directed tPA. The patient had return of cardiac function, resolution of hypoxia, and ultimately had a favorable outcome. It has been described that patients with massive PE and right ventricular dysfunction have a more rapid return of ventricular function and pulmonary perfusion with a thrombolytic bolus.² Guidelines from the American Heart Association support that fibrinolysis is reasonable in patients with suspected massive PE, and is associated with an acceptable risk of bleeding

complications.³ This strategy has also been endorsed by the American College of Chest Physicians and ACEP.^{1,4}

For patients with massive PE and hemodynamic instability, poor peripheral perfusion from right sided heart failure may limit tPA efficacy if administered through a peripheral intravenous line. Thus, the decision to bolus tPA through the CVC is hypothesized to increase concentration at the site of the thrombus. To date, there have been no randomized controlled trials that compare central to peripherally dosed thrombolytics. To our knowledge, there has been one published case report that describes CVC-directed thrombolytics, which also had a favorable outcome.⁵ Overall, the mortality from massive PE is approximately 15%, but increases to almost 65% when the patient has a cardiac arrest.⁶ In our case, immediate surgical or endovascular therapy was not feasible due to the patient's instability and the CVC-directed dose of thrombolytics in conjunction with cardiopulmonary resuscitation was associated with her survival.

CONCLUSION

Patients in cardiac arrest or peri-arrest in the setting of PE may benefit significantly from a bolus of tissue plasminogen activator through a central venous catheter. In the future, more evidence is needed to analyze CVC-directed tPA and its effect on morbidity and mortality.

Address for Correspondence: Jared Brazg, MD, Maimonides Medical Center, Department of Emergency Medicine, 4802 10th Avenue, Brooklyn, NY 11219. Email: Jaredbrazg@gmail.com.

Conflicts of Interest: By the CPC-EM article submission agreement, all authors are required to disclose all affiliations, funding sources and financial or management relationships that could be perceived as potential sources of bias. The authors disclosed none.

Copyright: © 2018 Gulati et al. This is an open access article distributed in accordance with the terms of the Creative Commons Attribution (CC BY 4.0) License. See: <http://creativecommons.org/licenses/by/4.0/>

REFERENCES

1. Fesmire FM, Brown MD, Espinosa JA, et al. Critical issues in the evaluation and management of adult patients presenting to the emergency department with suspected pulmonary embolism. *Ann Emerg Med.* 2011;57(6):628-52.e75.
2. Hao Q, Dong BR, Yue J, et al. Thrombolytic therapy for pulmonary embolism. *Cochrane Database Syst Rev.* 2015;(9):CD004437.
3. Jaff MR, McMurtry MS, Archer SL, et al. Management of massive and submassive pulmonary embolism, iliofemoral deep vein thrombosis, and chronic thromboembolic pulmonary hypertension: a scientific statement from the American Heart Association. *Circulation.* 2011;123(16):1788-830.
4. Kearon C, Akl EA, Omelas J, et al. Antithrombotic therapy for VTE disease: CHEST guideline and expert panel report. *Chest.* 2016;149(2):315-352.
5. Pillarisetti J, Gupta K. Massive pulmonary embolism with shock: role of thrombolysis using central venous access. *J Invasive Cardiol.* 2012;24(12):E321-4.
6. Chatterjee S, Chakraborty A, Weinberg I, et al. Thrombolysis for pulmonary embolism and risk of all-cause mortality, major bleeding, and intracranial hemorrhage: a meta-analysis. *JAMA.* 2014;311(23):2414-21.

Intraosseous Vascular Access Device as a Transarticular K-wire Alternative in Mallet Finger Laceration

Scott B. Crawford, MD

Texas Tech University Health Sciences Center El Paso, Department of Emergency Medicine, El Paso, Texas

Section Editor: Rick A. McPheeters, DO

Submission history: Submitted May 9, 2017; Revision received June 23, 2017; Accepted July 11, 2017

Electronically published January 18, 2018

Full text available through open access at http://escholarship.org/uc/uciem_cpchem

DOI: 10.5811/cpcem.2017.7.34811

Mallet finger is a common injury often treated without operative intervention. When there is concern for skin integrity or a large articular component is involved, simple operative repair may be needed. This has been performed with transarticular Kirschner wire (K-wire) placement. This case discusses the novel use of an intraosseous vascular access device (IOVAD) as a potential adjunct to stabilization and alternative to treatment with operative K-wire fixation. A 53-year-old man was successfully treated using the inner trocar of the EZ-IO® system for a mallet finger injury with laceration, shown in comparison with another standard manual pinning approach using an 18-gauge needle. An IOVAD can be used successfully as an alternative to K-wire placement in patients with mallet finger injuries. [Clin Pract Cases Emerg Med.2018;2(1):71-74.]

INTRODUCTION

Disruption of the extensor tendon at the distal interphalangeal joint (DIP) is common with lacerations due to the proximity of this structure to the skin surface. Two-thirds of extensor tendon lacerations are also associated with coincident damage to bone, skin or joint.¹ The disruption of this tendon is traditionally referred to as “mallet finger.” Stress through forced flexion of an extended DIP causes disruption of the extensor mechanism often due to sports or work-related injury, for example a ball striking the extending finger of a basketball player.² This injury pattern can cause deformity and disability if not treated appropriately. Most often it does not require surgical intervention. The severity of this injury and need for referral depends on the involved structures. There is debate as to the best technique, material and procedure to stabilize the injury to assure optimal healing, but initial splinting of the digit in extension for four to eight weeks is a clear consensus.³⁻⁵

Recommendations in the currently available literature regarding management of DIP extensor tendon injuries include use of basic aluminum and molded splint material, use of Kirschner wire (K-wire) and similar materials for stabilizing fracture fragments, bio-absorbable surgically implantable stabilization devices, screws and even arthrodesis.^{6,7} It has been recommended that use of pinning devices like the K-wire

be implemented to allow for full extension of the joint to best protect the repair and allow monitoring of the skin.^{1,8} Care is needed when placing an appropriate splint due to concern for skin breakdown and tissue ischemia in dorsally applied splints.⁴ In addition to keeping tension off the disrupted tendon, open tendon repairs can be achieved with tenodesis (the suturing of tendon to the skin during healing).³

Orthopedists have access to all manner of tools and materials in the operating room. Emergency departments and urgent care centers, however, are limited to a much smaller inventory to cover a wider number of potential ailments. Appropriate care must therefore be rendered with what is available at the time of patient presentation, with the knowledge that definitive follow-up can be achieved within the next hours to days after initial stabilization.

One product gaining popularity in many centers that care for critically ill patients, especially pediatric populations, is the intraosseous vascular access device (IOVAD). These devices are designed for the cannulation of the medullary cavity of various bone sites during resuscitation for fluid and medication administration when standard intravenous access is not quickly available. This paper discusses a novel use for the inner stylet of an IOVAD needle to aid in the treatment of mallet finger. The device used in this case was the EZ-IO® made by Vidacare®.

CASE REPORT

A 53-year-old Hispanic man presented with dorsal laceration to his third and fourth DIPs with bleeding and loss of mobility. The patient was right-hand dominant, and just prior to arrival he sustained a crush/laceration injury at work to this hand. His right hand had become trapped in the blades of an industrial vacuum machine. The patient's only complaint was pain to the third and fourth digits of his right hand. The patient had no past medical history, no prior surgeries and took only aspirin (81mg daily), folic acid, glucosamine and garlic tablets. His last tetanus shot was one year prior. The patient also denied tobacco use.

On physical examination; the patient was alert, ambulatory and talking, but in mild distress. He had a Glasgow coma scale score of 15. The only abnormal physical exam findings were as follows: Third digit of the right hand with a crush injury and avulsion of the nail bed. This was associated with complete extensor tendon deficit, with the tendon exposed on exam and a moderate amount of bleeding. The fourth digit was swollen and tender to palpation with a smaller skin defect over the dorsum of the finger with a puncture wound. There was no damage to the nail or nail bed of the fourth finger, but ecchymosis was noted to the finger pad.

A radiograph showed a mallet injury to the third finger on the right hand without associated fracture. The fourth finger demonstrated an open fracture of the distal phalanx with DIP extensor disruption (Image 1).

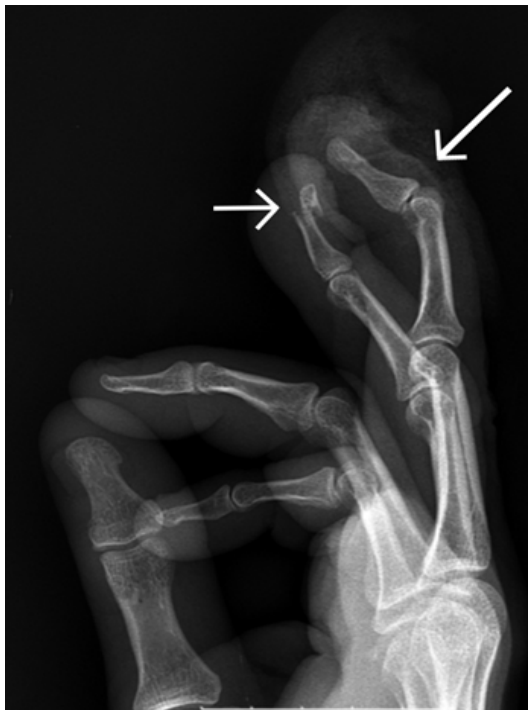

Image 1. Pre-repair radiograph demonstrating a fracture (short arrow) to the fourth digit and mallet injury (long arrow) to the third digit.

CPC-EM Capsule

What do we already know about this clinical entity?

Extensor tendon injury at the distal interphalangeal joint is treated with extension splinting. In cases of fracture, pinning of the digit or K-wire fixation may be required.

What makes this presentation of disease reportable?

Tissue loss overlying the extensor tendon defect prevented mechanical extension splinting. The inner trocar of an intra-osseous vascular access device was used to pin the finger in extension.

What is the major learning point?

Kirschner wire placement can be safely performed in the emergency department. The inner trocar of an EZ-IO® device was successfully used for pinning of a distal phalanx extensor tendon injury.

How might this improve emergency medicine practice?

This innovative pinning technique may allow patients to be treated in the emergency department without requiring an operating room or in a resource-limited environment.

The patient was given two grams of cefazolin intravenously. A digital block was performed with 1% lidocaine and a tourniquette applied to the base of both injured digits. Percutaneous fixation of the fourth finger was performed first to stabilize the distal fracture fragment using manual pressure and a standard 18-gauge needle. A similar procedure was then tried on the third finger to splint the digit in extension and allow for healing of the macerated tissue overlying the dorsum of the DIP, but the needle could not be advanced through the bony tissue with manual pressure. Verbal consent was obtained from the patient for use of an alternative fixation device. The needle driver for the EZ-IO® system was placed inside of a sterile glove by an assistant and was used to place the inner stylet of the IOVAD needle through the tip of the finger to achieve splint fixation in extension. Percutaneous needle fixation was recommended after phone consultation with the on-call orthopedic surgeon. Both needles were placed by the emergency physician caring for the patient, using simple tactile and visual guidance.

The patient was discharged home on cephalexin for 10 days and pain medicine with a bandage in place to protect the fingertips and exposed needles. Post-fixation films demonstrating alignment and needle comparison are shown in Image 2.

The patient followed up in the orthopedic clinic for needle removal and later physical therapy. He regained normal use of both digits.

DISCUSSION

This is a unique case discussing the use of an IOVAD as a substitute for K-wire stabilization of mallet finger. PubMed searches using “EZ-IO, EZIO, and EZ IO” were paired individually with “arthrodesis,” “mallet,” “DIP,” “finger,” “phalanx,” and “K-wire” for a total of 18 separate search strings that yielded no results.

Non-operative treatment is successful in most mallet injuries, but mallet injury with fracture should be regarded differently. Referral to an orthopedist is required for a bony mallet finger injury, especially one that is intra-articular with greater than 30% of the articular surface involved, or if there is subluxation of the DIP. Surgical fixation does not need to occur within hours of this injury to achieve adequate results. Surgery was delayed up to eight days with excellent treatment results in some studies comparing surgical treatment strategies,⁸ and chronic injuries were repaired years later in others.⁹ Still, emergency department (ED) placement of K-wires, rather than placement in an

operating room has been successfully performed without risk of osteomyelitis, even in the setting of open fractures.¹⁰

According to *Green's Operative Hand Surgery*, extensor tendon injuries are classified based on involved structures and on degree and type of associated fracture.⁵ One commonly used classification method is the Doyle Classification of Mallet Injuries (Table).

Type I injuries are the most common and are amenable to non-operative treatment. Type II and type III injuries require debridement and tendon suture, if possible. If the injury is more extensive it may require skin or tendon grafting. Type IV injuries are recommended for pinning and extension splinting. The injury in this case was a type III injury.⁵

A flexion deformity usually heals well on its own with splint placement. It may need an additional surgical procedure if there is a fracture involving more than 30% of the articular surface or if the patient cannot work with the external splint. In these cases, use of K-wire fixation is a frequently implemented.¹¹

The size of the K-wire used for repair is dependent upon the size of the bone and the intended use, but several authors recommend using 0.045 inch K-wire for this type of transarticular extension pinning.^{2,8,12} The 15-gauge needle and solid core stylet of the IOVAD used are similar to this size. The internal diameter of a 15-gauge needle, and therefore the outer diameter of the stylet, is reported to be 0.054 inches.¹³ Also noted in the literature, although less extensively, is the use of a standard injection needle for fixation across the joint.³ The external diameter of the 18-gauge needle in the fourth finger seen in Image 2 is 0.050 inches. Image 2 provides a side-by-side comparison of these two techniques/devices.

In the search for an alternative to the use of K-wires it has been found that using a regular needle attached to a drill, in much the same fashion as an IOVAD, provided similar ease of insertion instead of using a K-wire.¹⁴ However, an electric drill is not a tool frequently found in the emergency physician's toolkit.

The IOVAD stylet would seem to be an improvement over a standard needle because it has a solid core that seals the track, thereby reducing the risk of infection. In addition, the IOVAD comes with a drill designed to work with the included needles and may be found already in many EDs.

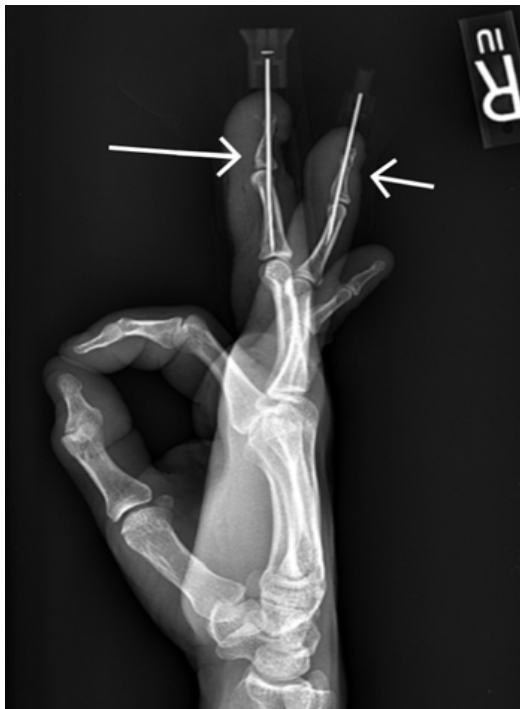

Image 2. Post-repair radiograph of 3rd and 4th digits: 4th digit fracture pinned with 18-gauge needle (short arrow); 3rd digit mallet injury pinned in extension with IOVAD needle trocar (long arrow).

Table. Doyle classification of mallet injuries.

Type I: Closed injury with or without small dorsal avulsion fracture
Type II: Open injury with laceration of tendon
Type III: Open injury with loss of skin and tendon substance
Type IV: Mallet fracture
A: Transepiphyseal plate fracture (in children)
B: Hyperflexion injury with 20-50% articular surface fracture
C: Hyperextension injury with fracture of >50% articular surface and subluxation of the distal phalanx

LIMITATIONS

The purpose of this discussion was to provide a general overview of the primary treatment options for DIP extensor tendon injury and to provide a new way of looking at IOVADs in the ED. Because only a single patient case is available to look at this technique, generalizing the use of this procedure is left to the individual practitioner in consultation with an orthopedic surgeon. Many care providers may feel uncomfortable performing this type of procedure without orthopedic training, but the concept is presented to show other possibilities based on available resources.

CONCLUSION

An IOVAD stylet and needle driver make a suitable and easily available alternative to formal surgical fixation with a K-wire for shallower depths, up to 45mm in length (the longest EZ-IO® needle manufactured). This method was appropriate in this particular case due to the macerated tissue, which prevented the use of a supportive dorsal brace on the third digit. The fact that a standard needle could not be inserted provided the motivation to seek a new method for placement of a stabilizing piece of metal. The favorable outcome of this case was supported by excellent orthopedic follow-up and physical therapy.

Address for Correspondence: Scott B. Crawford, MD, Texas Tech University Health Sciences Center El Paso, 4801 Alberta Ave. B3200, El Paso, TX 79005. Email: scott.crawford@ttuhsc.edu.

Conflicts of Interest: By the CPC-EM article submission agreement, all authors are required to disclose all affiliations, funding sources and financial or management relationships that could be perceived as potential sources of bias. The authors disclosed none.

Copyright: © 2018 Crawford. This is an open access article distributed in accordance with the terms of the Creative Commons Attribution (CC BY 4.0) License. See: <http://creativecommons.org/licenses/by/4.0/>

REFERENCES

1. Newport ML. Extensor Tendon injuries in the hand. *J Am Acad of Orthop Surg.* 1997;5(2):59-66.
2. Badia A, Riano F. A simple fixation method for unstable bony mallet finger. *J Hand Surg Am.* 2004;29(6):1051-5.
3. Jablecki J, Syrko M. Zone 1 extensor tendon lesions: current treatment methods and a review of literature. *Ortop Traumatol Rehabil.* 2007;9(1):52-62.
4. Oetgen ME, Dodds SD. Non-operative treatment of common finger injuries. *Curr Rev Musculoskelet Med.* 2008;1(2):97-102.
5. Strauch RJ. *Green's Operative Hand Surgery.* Vol 1. 6th ed. Philadelphia PA: Elsevier 2011.
6. Smit JM, Beets MR, Zeebregts CJ, et al. Treatment options for mallet finger: a review. *Plast Reconstr Surg.* 2010;126(5):1624-9.
7. Nelis R, Wouters D. Is the use of biodegradable devices in the operative treatment of avulsion fractures of fingers, the so-called mallet finger advantageous? a feasibility study with meniscus arrows. *Open Orthop J.* 2008;2:151-4.
8. Zhang X, Meng H, Shao X, et al. Pull-out wire fixation for acute mallet finger fractures with k-wire stabilization of the distal interphalangeal joint. *J Hand Surg Am.* 2010;35(11):1864-9.
9. Kardestuncer T, Bae DS, Waters PM. The results of tenodesis for severe chronic mallet finger deformity in children. *J Pediatr Orthop.* 2008;28(1):81-5.
10. Starker I, Eaton R. Kirschner wire placement in the emergency room: Is there a risk? *J Hand Surg Br.* 1995;20(4):535-8.
11. Bendre AA, Hartigan BJ, Kalainov DM. Mallet finger. *J Am Acad Orthop Surg.* 2005;13(5):336-44.
12. Tomaino MM. Distal interphalangeal joint arthrodesis with screw fixation: why and how. *Hand Clin.* 2006;22(2):207-10.
13. Sigma-Aldrich. Syringe Needle Gauge Chart. Available at: <http://www.sigmaaldrich.com/chemistry/stockroom-reagents/learning-center/technical-library/needle-gauge-chart.html>. Accessed December 22, 2016.
14. Imran D, Tripathi A, Eckersley R. Use of a hollow needle for drilling holes in small bones to guide intraosseous wires. *Hand Surg.* 2005;10(1):95-6.

A New Diagnosis of a Genetic Disorder in a Patient Presenting with Bilateral Upper Extremity Neuropathy

Todd M. Ruttenberg, DO
Alexander D. Miller, MD

Naval Medical Center San Diego, Department of Emergency Medicine, San Diego, California

Section Editor: Rick A. McPheeters, DO

Submission history: Submitted August 4, 2017; Revisions received October 16, 2017; Accepted November 8, 2017

Electronically published January 19, 2018

Full text available through open access at http://escholarship.org/uc/uciem_cpccem

DOI: 10.5811/cpcem.2017.11.35867

A 20-year-old male United States Marine Corps recruit was admitted to the emergency department with a two-week history of profound, bilateral upper-extremity weakness and numbness. Initially thought to be the result of his military training, the cause was ultimately determined to be genetic. This case represents a rare cause of a somewhat common presenting symptom: chronic symmetric polyneuropathy. [Clin Pract Cases Emerg Med. 2018;2(1):75-77.]

INTRODUCTION

Hereditary neuropathy with a liability to pressure palsies (HNPP) is a well-established, albeit rare, diagnosis with recurrent episodes of nerve demyelination. Affected patients typically present with isolated nerve palsies in areas frequently affected by compression or trauma, even of a trivial nature. HNPP is an autosomal dominant disorder most often associated with peripheral myelin protein 22 (PMP22) gene mutations, and may present de novo as well.^{1,2}

Although not a diagnosis requiring emergent intervention, HNPP may present with a dramatic and confusing constellation of symptoms and should be considered after other life-threatening processes are ruled out. HNPP carries with it a significant impact on the quality of the life for those whom it affects, therefore making its existence on our collective differential diagnosis of the utmost importance. The combination of peripheral neuropathy and upper extremity weakness carries a broad differential diagnosis, many of which have immediate treatment needs. Some may require hospitalization and further diagnostic evaluation to ensure a minimization of possible life threats and permanent neurologic deficits.

CASE REPORT

A 20-year-old male United States Marine Corps (USMC) recruit presented to the emergency department (ED) with a two-week history of stable yet profound bilateral, painless, upper extremity weakness, left greater than right, and a patchy, non-dermatomal sensory deficit, to the upper extremities. Three weeks

prior to presentation, the USMC recruit in training at the Marine Corps Recruit Depot first noticed a continuous numbness on the dorsal aspect of his left hand between the thumb and index finger. He thought little of the numbness as it did not impede him.

The following week, he noticed a sudden-onset, profound, right-hand grip strength weakness while in the prone position during rifle training as a right-handed shooter. He was seen in clinic, diagnosed with “backpack palsy” – a compressive neuropathy of the brachial plexus – and returned to rifle training. He then completed another day of rifle training in the prone position, this time as a left-handed shooter. Soon after, he developed weakness to the left upper extremity when in abduction and flexion. His training was halted to allow for time to assess if the presumed “backpack palsy” would improve. Ten days passed with no improvement, and he noticed that the weakness worsened with continued use. At this point the patient was having difficulties with activities of daily living, such as pulling up and fastening his pants. He was then sent to the ED for further evaluation and management.

Upon arrival to the ED, the patient was in no apparent distress and was pain free. He denied headache, neck pain, changes in vision, difficulty breathing, lower extremity weakness, sensory loss, or loss of bowel/bladder control. Vital signs were blood pressure 108/62 millimeters mercury, heart rate 56 beats per minute, respiratory rate 16 breaths per minute, oxygen saturation of 99% on room air, and temperature 97.7°Fahrenheit. His physical exam revealed a behaviorally appropriate patient with normal cranial nerves, normal gait, normal lower extremity

strength and sensation and patellar tendon reflexes, negative Romberg test, and painless extremities with less than two-second capillary refill globally. Physical exam pertinent positive findings included asymmetric upper extremity strength testing and sensory deficits to light touch with decreased triceps deep-tendon reflexes bilaterally for the upper extremities.

Given this patient's non-dermatomal presentation, atraumatic history, lack of associated symptoms, and relatively stable time course the need for hospitalization was considered less likely. Neurology was consulted and evaluated the patient at bedside, recommending an outpatient electromyogram (EMG) in clinic in one to three days for presumed multifocal lower motor neuron process. Prior to follow-up the patient developed sharp shooting pains localized to the left elbow without any known trigger, and he was directly admitted to the hospital from clinic to expedite testing.

Laboratories for autoimmune, musculoskeletal, infectious, and endocrine processes were unremarkable. Magnetic resonance imaging (MRI) of the cervical spine was essentially normal and did not demonstrate demyelinating lesions. EMG demonstrated bilateral compressive median neuropathy at the wrist, bilateral ulnar neuropathy at the elbow, and left upper brachial plexopathy with significant axonal features consistent with HNPP. Confirmatory genetic testing of the PMP22 gene via a diagnostics service was sent for verification and confirmed the diagnosis.

DISCUSSION

Patients presenting with HNPP and hereditary neuropathies present an intriguing challenge for the emergency physician. Patients with these conditions comprise only a small segment of the large number of patients presenting with peripheral neuropathy. In fact, chronic symmetric symptomatic polyneuropathy in patients is somewhat common and may occur in up to 8% of the general population. By contrast, hereditary motor sensory neuropathies like Charcot-Marie-Tooth disease and HNPP, which affect the peripheral nerves and anterior horn cells of the spinal cord, only have a variable prevalence from 0.008 - 0.11%.³ Thus, it affects an estimated 150,000 people in the U.S.⁴ HNPP itself is well documented in the literature, and has an estimated prevalence of at least 0.016% of the general population. Due to the insidious nature of HNPP, and the fact that many patients will present with subclinical symptoms, a mild or late onset, or varying levels of severity from an early age, the true prevalence is most likely underestimated.⁵

Peripheral neuropathy occurs in several common and rare disease states with diverse pathology and varying degrees of severity to the individual patient. This poses a significant challenge to physicians who are attempting to identify and treat these conditions. In our patient, we first considered all the potential emergent diagnoses. This ultimately led to the increased likelihood of first a multifocal lower motor neuron

CPC-EM Capsule

What do we already know about this clinical entity?

Hereditary neuropathy with a liability to pressure palsies (HNPP) is documented in the neurology literature. Patients present with nerve palsies in areas affected by compression or trauma, even of a trivial nature.

What makes this presentation of disease reportable?

Although a rare entity, this case provides a good, basic review of peripheral neuropathies.

What is the major learning point?

This case highlights the difficulty in identifying HNPP and provides a review of the patient with non-dermatomal peripheral neurologic complaints.

How might this improve emergency medicine practice?

Provides the practitioner with the knowledge base to identify HNPP and provide the patient with informed counsel.

process and finally to the ultimate diagnosis of HNPP through neurology follow-up, EMG studies and genetic testing.

In this case, central hemorrhagic and ischemic processes were initially considered and then excluded as the patient presented with a history and physical exam inconsistent with the dermatomal and progressive presentation consistent with these diagnoses. As well, a central venous thrombosis was also initially considered as it may present with a non-dermatomal deficit presentation; again, this was deemed highly unlikely secondary to the lack of historical relevance, lack of cranial nerve involvement or seizure activity, and lack of concurrent headache symptoms.

Syringomyelia was also carefully considered but as the patient presented without corresponding deficits to any particular nerve trunk or nerve root level this diagnosis was also unlikely. Guillain-Barré syndrome was also considered but was not consistent with history or physical exam findings. Toxic exposure and neuropathy was considered a possibility, but lack of exposure history made this implausible. Finally, the hypo-reflexia, down-going plantar reflex, and lack of a defined sensory level defect, lower extremity involvement, or

traumatic history, made a compressive cervical spine lesion also unlikely. This ultimately led to the consideration of a hereditary neuropathy as the most likely lower motor neuron process responsible for our patient presentation.

According to the National Institute of Neurological Disorders and Stroke, the classification of hereditary neuropathies is divided into four major subcategories: hereditary motor and sensory neuropathy; hereditary sensory neuropathy; hereditary motor neuropathy; and hereditary sensory and autonomic neuropathy. The most common type is Charcot-Marie-Tooth disease, one of the hereditary motor and sensory neuropathies. Symptoms of the hereditary neuropathies vary according to the type and may include sensory symptoms such as numbness, tingling and pain in the feet and hands; or motor symptoms such as weakness and loss of muscle bulk, particularly in the lower leg and feet muscles. Certain types of hereditary neuropathies can affect the autonomic nerves, resulting in impaired sweating, postural hypotension, or insensitivity to pain.

Some people may have foot deformities such as high arches and hammertoes, thin calf muscles (having the appearance of an inverted champagne bottle) or scoliosis (curvature of the spine). The symptoms of hereditary neuropathies may be apparent at birth or appear in middle or late life. They can vary among different family members, with some family members being more severely affected than others. Hereditary neuropathies can be diagnosed by blood tests for genetic testing, nerve conduction studies, and by nerve biopsies.^{6,7} Once the diagnosis is made, it is important to know that hereditary neuropathies like HNPP have no standard treatments. Treatment is mainly symptomatic and supportive. Medical treatment includes physical therapy and, if needed, pain medication.^{5,6,7}

CONCLUSION

This case demonstrates a challenge to the emergency physician as the relative rarity of hereditary neuropathy inhibits prompt recognition and affords only the most astute practitioners confidence in its likelihood. Lack of familiarity with hereditary neuropathies may lead to the performance of unnecessary testing, thus placing patients at undue risk and inhibiting our ability to provide competent and informed recommendations to patients facing an uncertain prognosis.

Address for Correspondence: LCDR Todd M Ruttenberg, DO, CLB-31, HSS PLT, Unit 38465, FPO AP 96385. Email: dr.ruttenberg@gmail.com, todd.m.ruttenberg.mil@mail.mil.

Conflicts of Interest: By the CPC-EM article submission agreement, all authors are required to disclose all affiliations, funding sources and financial or management relationships that could be perceived as potential sources of bias. The authors disclosed none. The views expressed in this article are those of the authors and do not necessarily reflect the official policy or position of the Department of the Navy, Department of Defense, or the U.S. Government.

Copyright: © 2018 Ruttenberg et al. This is an open access article distributed in accordance with the terms of the Creative Commons Attribution (CC BY 4.0) License. See: <http://creativecommons.org/licenses/by/4.0/>

REFERENCES

1. Mouton P, Tardieu S, Gouider R, et al. Spectrum of clinical and electrophysiologic features in HNPP patients with the 17p11.2 deletion. *Neurology*. 1999;52(7):1440-6.
2. Potulska-Chromik A, Sinkiewicz-Darol E, Ryniewicz B, et al. Clinical, electrophysiological, and molecular findings in early onset hereditary neuropathy with liability to pressure palsy. *Muscle Nerve*. 2014;50:914-8.
3. Martyn C N, Hughes R A, Epidemiology of peripheral neuropathy. *Neurol Neurosurg Psychiatry*. 1997;62(4):310-8.
4. Hereditary Motor Sensor Neuropathy: American Association of Neuromuscular & Electrodiagnostic Medicine Website: Available at: <http://www.aanem.org/Patients/Disorders/Hereditary-Motor-Sensory-Neuropathy>. Accessed June 2, 2017.
5. Meretoja P, Silander K, Kalimo H, et al, Epidemiology of hereditary neuropathy with liability to pressure palsies (HNPP) in south- western Finland. *Neuromuscul Disord*. 1997;7(8):529-32.
6. Hereditary Neuropathy information Page: National Institute of Neurological Disorders and Stroke website: Available at: http://www.ninds.nih.gov/disorders/neuropathy_hereditary/neuropathy_hereditary.htm. Accessed: June 2, 2017.
7. Hereditary Neuropathies: American Academy of Neurology – Practice Guidelines website: Available at: http://patients.aan.com/disorders/index.cfm?event=view&disorder_id=939. Accessed June 2, 2017.

Lemierre Syndrome as a Complication of Laryngeal Carcinoma

Christopher Colbert, DO*
 Molly McCormack, DO*
 Wesley Eilbert, MD*
 Lynea Bull, MS†

*University of Illinois at Chicago, College of Medicine, Department of Emergency
 Medicine, Chicago, Illinois
 †St. Louis University School of Medicine, St. Louis, Missouri

Section Editor: Shadi Lahham, MD, MS

Submission history: Submitted September 18, 2017; Accepted December 7, 2017

Electronically published January 24, 2018

Full text available through open access at http://escholarship.org/uc/uciem_cpem

DOI: 10.5811/cpcem.2017.12.36442

Lemierre syndrome is a rare condition characterized by a septic thrombophlebitis of the internal jugular vein with septicemia and metastatic foci of infection. It typically occurs as the result of an infection in the head and neck, most commonly pharyngitis. For reasons that are unclear, the incidence of Lemierre syndrome has been increasing over the past 15 years. Diagnosis of Lemierre syndrome is often delayed, and identification of internal jugular vein thrombosis is often the first indicator of its presence. We report a case of Lemierre syndrome associated with a laryngeal carcinoma. [Clin Pract Cases Emerg Med. 2018;2(1):78-81.]

INTRODUCTION

Lemierre syndrome is a rare condition characterized by a septic thrombophlebitis of the internal jugular (IJ) vein. This potentially fatal disorder results in bacteremia usually caused by *Fusobacterium necrophorum*, a gram-negative anaerobe that is a normal part of the oropharyngeal flora.¹ Most cases of Lemierre syndrome begin as an oropharyngeal infection, though primary infections in the chest, teeth, sinuses, and ears may also serve as sources.² Other rare causes include trauma and head and neck malignancies.³⁻⁷ We present a case of Lemierre syndrome associated with a laryngeal carcinoma.

CASE REPORT

A 41-year-old man with a past medical history of squamous cell carcinoma of the glottis treated with radiation therapy five years earlier presented to our emergency department (ED) complaining of one week of progressive right-sided neck pain and swelling with fever up to 38.9°Celsius (C) (102.1° Fahrenheit). His symptoms had been preceded by three months of throat pain, odynophagia, and right otalgia. A positron emission tomography performed at another institution one month before had revealed a lesion concerning for possible recurrence of the tumor. One week prior to presentation he had been prescribed a one-week course of cephalexin for

a “neck infection” at another ED. He was afebrile (37.0°C) on examination with a 3 cm fluctuant neck mass palpable in his right anterior neck. The remainder of his examination was unremarkable.

Laboratory analysis revealed a white blood cell count of 17,300/μl, and blood cultures were sent. A point-of-care ultrasound was performed, which showed echogenic material in a noncompressible right IJ vein (Image 1) – findings consistent with thrombophlebitis. A contrast-enhanced computed tomography (CT) of the neck later confirmed thrombosis of the right IJ vein extending to the subclavian vein, as well as a peripherally enhancing fluid collection in the right neck anterior and lateral to the trachea (Image 2). Needle aspiration of this fluid collection yielded purulent fluid that was sent for culture. Empiric antibiotic therapy was started with vancomycin and piperacillin/tazobactam, and the patient was started on enoxaparin for anticoagulation. A CT of the chest performed the next day revealed multiple bilateral, ground-glass opacities suspicious for infectious processes.

On hospital day three the patient underwent direct laryngoscopy, and biopsies of a glottic mass confirmed the diagnosis of squamous cell carcinoma. Blood cultures sent from the ED grew no organisms, though the fluid aspirated from the right neck fluid collection grew *Fusobacterium nucleatum* on hospital day six. At the recommendation

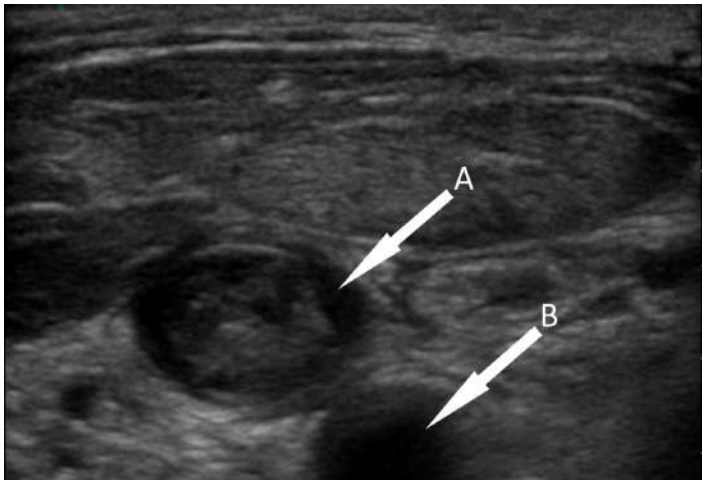


Image 1. Point-of-care ultrasound of the right internal jugular vein (A) showing echogenic material in the lumen adjacent to the common carotid artery (B).

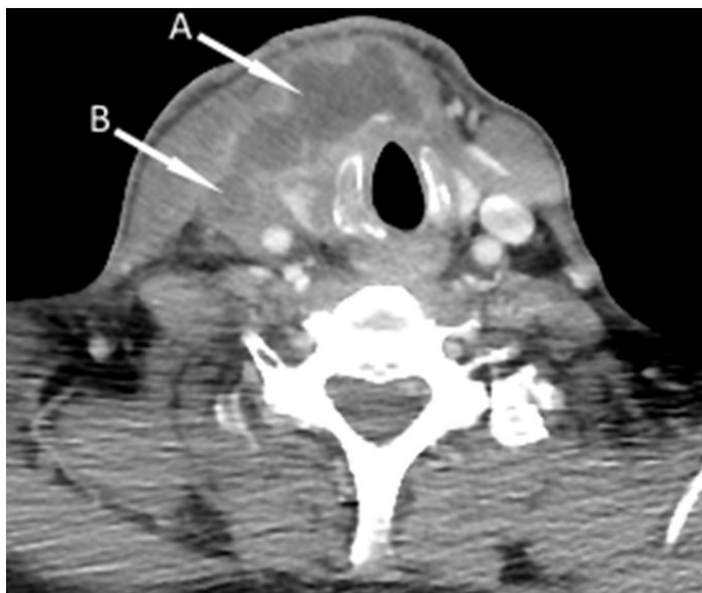


Image 2. Contrast-enhanced computed tomography of the neck showing a soft tissue fluid collection (A) anterior and lateral to the trachea, and thrombus in the right internal jugular vein (B)

of the infectious disease service, the patient's antibiotic regimen was changed to ampicillin/sulbactam. The patient was discharged on hospital day 11 to complete a six-week course of antibiotic therapy with ertapenem and anticoagulation with enoxaparin. A contrast-enhanced CT of the neck performed 20 days after the initial scan showed no significant change in the right IJ vein thrombus. Ultimately the patient underwent total laryngectomy for treatment of his malignancy.

CPC-EM Capsule

What do we already know about this clinical entity?

Lemierre syndrome, a septic thrombophlebitis of the internal jugular vein, is a rare condition. There is frequently a delay in making its diagnosis.

What makes this presentation of disease reportable?

Lemierre syndrome typically occurs as a result of an infection in the head and neck. This is only the fourth reported case occurring in conjunction with a primary head and neck tumor.

What is the major learning point?

Lemierre syndrome may occur in the setting of a primary head and neck malignancy. Point-of-care ultrasound can be used in the emergency department to expedite its diagnosis.

How might this improve emergency medicine practice?

A timely diagnosis of Lemierre syndrome can be assisted by recognizing an active head and neck malignancy as a risk factor for its presence and the use of point-of-care ultrasound.

DISCUSSION

Lemierre syndrome is classically characterized by the following: 1) primary infection in the oropharynx; 2) septicemia documented by at least one positive blood culture; 3) clinical or radiographic evidence of IJ vein thrombosis; and 4) at least one metastatic focus of infection (though several variations of this definition have been proposed).^{8,9} Lemierre syndrome is primarily a disease of young people, with the majority of cases occurring in the first three decades of life.² With the introduction of antibiotics for the treatment of streptococcal pharyngitis in the 1940s, the incidence of Lemierre syndrome fell dramatically. Since the start of the 21st century there has been a noted increase in the reporting of Lemierre syndrome.¹⁰⁻¹² While unclear, the cause of this increase may be due to increased recognition of the disease, more stringent use of antibiotics for oropharyngeal infections, and increasing antibiotic resistance.¹³

Fusobacterium necrophorum is the responsible pathogen in over 80% of cases of Lemierre syndrome.^{1,14} Other reported pathogens include other *Fusobacterium*

species, *Eikenella*, *Bacteroides*, *Streptococcus*, and *Staphylococcus* species.¹³ One review found blood cultures to be negative in 12.8% of cases, as with our case.¹⁴ The condition typically begins as a sore throat, followed days later by unilateral neck pain. Fever is the most common physical exam finding, present in 92% to 100% of cases, and approximately half of all patients will have a tender or swollen neck.^{14,16} The lungs are the most common site of metastatic infection, present in 80% to 97% of cases, followed by the joints.^{8,14}

The diagnosis of Lemierre syndrome is often delayed, probably due in part to its relative rarity. One review reported an average delay of five days from the time of admission until diagnosis was made.¹⁷ Identification of thrombophlebitis of the IJ vein is the first hard evidence to suggest Lemierre syndrome in many patients.¹⁷ Contrast-enhanced CT is considered the imaging study of choice for this purpose by several authors.^{8,17-21} As with our case, ultrasound offers a rapid, low-cost, noninvasive method of imaging the IJ vein. Ultrasound is limited by its ability to visualize recently formed, unorganized clot and incomplete evaluation of tissue adjacent to the mandible, clavicle, and skull base.¹⁸ As emergency physicians become more comfortable with the use of point-of-care ultrasound for various indications, its use in the future for rapid screening for Lemierre syndrome in the ED will likely increase.

Prolonged antibiotic therapy constitutes the mainstay of treatment of Lemierre syndrome. Since many *F. necrophorum* strains have beta-lactamase activity, most authorities recommend empiric treatment with clindamycin or a beta-lactamase resistant penicillin with good anaerobic coverage such as ticarcillin/clavulanate or ampicillin/sulbactam.^{15,16,21,22} The use of anticoagulation is controversial and no controlled studies exist, though more recent retrospective studies have advocated for its use.^{23,24}

The infection in our case most likely originated at the site of the malignancy where a loss of mucosal integrity allowed for entry of the pathogen. Thrombogenesis was further promoted by the presence of an active malignancy. To our knowledge, this is only the fourth reported case of Lemierre syndrome occurring in conjunction with a primary head and neck tumor.⁵⁻⁷

CONCLUSION

While it remains rare, Lemierre syndrome seems to be occurring with increasing frequency in this century. There is frequently a delay in making its diagnosis. The presence of an active malignancy in the head and neck may be a risk factor for its occurrence. Recognition of patient risk factors and typical history and physical examination findings are crucial to expedite its identification. The use of point-of-care ultrasound provides emergency physicians with a rapid and noninvasive means to help identify this condition.

Address for Correspondence: Wesley Eilbert, MD, University of Illinois at Chicago, College of Medicine, Department of Emergency Medicine, 1819 West Polk St., Room 469 COME, Chicago, Illinois 60612. Email: weilbert@uic.edu.

Conflicts of Interest: By the CPC-EM article submission agreement, all authors are required to disclose all affiliations, funding sources and financial or management relationships that could be perceived as potential sources of bias. The authors disclosed none.

Copyright: © 2018 Colbert et al. This is an open access article distributed in accordance with the terms of the Creative Commons Attribution (CC BY 4.0) License. See: <http://creativecommons.org/licenses/by/4.0/>

REFERENCES

- Moore BA, Dekle C, Werkhaven J. Bilateral Lemierre's syndrome: a case report and literature review. *Ear Nose Throat J.* 2002;81(4):234-6, 238-240, 242 passim.
- Karkos PD, Asrani S, Karkos CD, et al. Lemierre's syndrome: a systematic review. *Laryngoscope.* 2009;119(8):1552-9.
- Dellamonica P, Bernard E. 'Deep throat' cellulitis. *J Infect.* 1999;38(2):134.
- Takenouchi S, Kunieda T, Yamada R, et al. Lemierre syndrome caused by oral sex. *J Formos Med Assoc.* 2014;113(10):762-3.
- Winters R, Amedee R. Squamous cell carcinoma of the palate presenting as Lemierre syndrome. *J La State Med Soc.* 2010;162(6):343-4.
- Osman M, Hasan S, Bachuwa G. Oesophageal cancer presenting as Lemierre's syndrome caused by *Streptococcus anginosus*. *BMJ Case Rep.* 2017.
- Rahhal H, deCampos FP, Ferreira CR, et al. Lemierre's syndrome due to intratumoral abscess of the uvula. *Autops Case Rep.* 2015;5(3):11-20.
- Sinave CP, Hardy GJ, Fardy PW. The Lemierre syndrome: suppurative thrombophlebitis of the internal jugular vein secondary to oropharyngeal infection. *Medicine (Baltimore).* 1989;68(2):85-94.
- Riordan T. Human infection with *Fusobacterium necrophorum* (Necrobacillosis), with a focus on Lemierre's syndrome. *Clin Microbiol Rev.* 2007;20(4):622-59.
- Brazier JS, Hall V, Yusef E, et al. *Fusobacterium necrophorum* infections in England and Wales. *J Med Microbiol.* 2002;51(3):269-72.
- Ramirez S, Hild TG, Rudolph CN, et al. Increased diagnosis of Lemierre's syndrome and other *Fusobacterium necrophorum* infections at a children's hospital. *Pediatrics.* 2003;112(5):e380-5.
- Hagelskjaer Kristensen L, Prag J. Lemierre's syndrome and other disseminated *Fusobacterium necrophorum* infections in Denmark: a prospective epidemiological and clinical survey. *Eur J Clin Microbiol Infect Dis.* 2008;27(9):779-89.
- Chamseddin KH, Kirkwood ML. Lemierre's syndrome associated with mycotic aneurysm of the external carotid artery with primary internal

- carotid artery occlusion in a previously healthy 18-year-old female. *Ann Vasc Surg.* 2016;36:291.e11-291.e14.
14. Chirinos JA, Lichtstein DM, Garcia J, et al. The evolution of Lemierre syndrome. *Medicine (Baltimore).* 2002;81(6):458-65.
15. Wong AP, Duggins ML, Neil T. Internal jugular vein septic thrombophlebitis (Lemierre syndrome) as a complication of pharyngitis. *J Am Board Fam Med.* 2015;28(3):425-30.
16. Eilbert W, Singla N. Lemierre's syndrome. *Int J Emerg Med.* 2013;6(1):40.
17. Alvarez A, Schreiber JR. Lemierre's syndrome in adolescent children – anaerobic sepsis with internal jugular vein thrombophlebitis following pharyngitis. *Pediatrics.* 1995;96:354-9.
18. Wright WF, Shiner CN, Ribes JA. Lemierre syndrome. *South Med J.* 2012;105(5):283-8.
19. Lustig LR, Cusick BC, Cheung SW, et al. Lemierre's syndrome two cases of postanginal sepsis. *Otolaryngol Head Neck Surg.* 1995;112(6):767-72.
20. Kuppalli K, Livorsi D, Talati NJ, et al. Lemierre's syndrome due to *Fusobacterium necrophorum*. *Lancet Infect Dis.* 2012;12(10):808-15.
21. Davidoss N, Ha JF, Anderson JR, et al. Lemierre's syndrome – an unusual complication of otitis externa in a young, healthy female. *J Laryngol Otol.* 2015;129(suppl S1):S60-62.
22. Righini CA, Karkas A, Tourniaire R, et al. Lemierre syndrome: a study of 11 cases and literature review. *Head Neck.* 2014;36(7):1044-51.
23. Cupit-Link MC, Negeswara RA, Warad DM, et al. Lemierre syndrome: a retrospective study of the role of anticoagulation and thrombosis outcomes. *Acta Haematol.* 2017;137(2):59-65.
24. Schubert AD, Hotz MA, Caversaccio MD, et al. Septic thrombosis of the internal jugular vein: Lemierre's syndrome revisited. *Laryngoscope.* 2015;125(4):863-8.

What's the Mass? The Gist of Point-of-care Ultrasound in Gastrointestinal Stromal Tumors

Kim P. Chan, MBBS, MRCSEd (A&E), RDMS

Sengkang Health, Department of Emergency Medicine, Singapore

Section Editor: Shadi Laham, MD

Submission history: Submitted September 12, 2017; Revision received December 7, 2017; Accepted December 13, 2017

Electronically published January 24, 2018

Full text available through open access at http://escholarship.org/uc/uciem_cpccem

DOI: 10.5811/cpcem.2017.12.36375

Gastrointestinal stromal tumors (GISTs) are rare, and patients usually present with vague and non-specific abdominal symptoms. This report illustrates how point-of-care ultrasound performed in the emergency setting in the evaluation of such patients helped in management of two undiagnosed GIST patients. [Clin Pract Cases Emerg Med. 2018;2(1):82-85.]

INTRODUCTION

Gastrointestinal stromal tumors (GISTs) are rare gastrointestinal tumors though they are the most common mesenchymal neoplasms of the gastrointestinal tract. Patients may present with non-specific symptoms (abdominal fullness, pain or discomfort, malaise, or palpable abdominal mass) or may be asymptomatic. Computed tomography of the abdomen and pelvis (CTAP) are crucial in the diagnosis and staging of GISTs but are not universally available in all emergency settings worldwide. Point-of-care ultrasonography (POCUS) has the potential of being the first-line modality in the evaluation of acute patients with such non-specific symptoms. To date, there is no published article on the use of POCUS in the identification or management of GISTs. And presented here are two cases of GIST with different clinical presentations where POCUS had an impact on the management.

CASE REPORT (ONE)

A 64-year-old woman presented to the emergency department (ED) after three episodes of syncope. She also had an increasing abdominal girth with epigastric fullness and discomfort for the prior few months. Clinically her vital signs were blood pressure (BP) 146/97 millimeters of mercury (mmHg), pulse rate of 121 beats per minute (bpm), respiratory rate 18 breaths per minute (BPM), pulse oximetry of 96% on room air and temperature at 36.6 degrees Celsius (C). Her abdomen, though distended, was soft and non-tender. A point-of-care ultrasound (POCUS) was performed to evaluate for possible aortic pathology but revealed a large left hypochondrial mass of mixed echogenicity (Image 1); intra-abdominal free fluid was noted over the splenorenal and supra-pubic recesses.

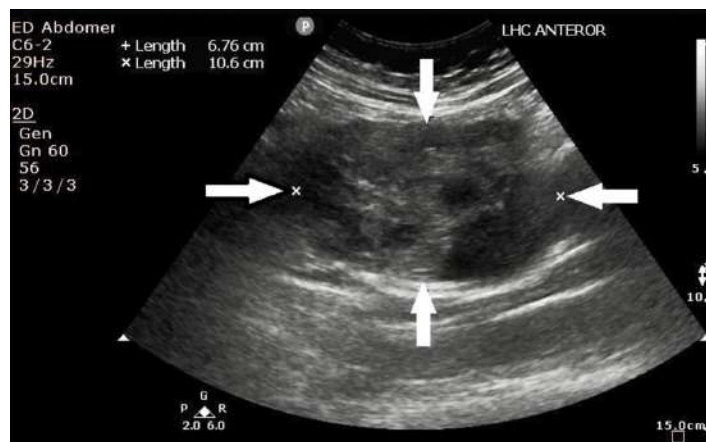


Image 1. Point-of-care ultrasound of the left hypochondrium showing a heterogeneous mass as outlined by the white arrows, later determined to be a gastrointestinal stromal tumor.

CTAP was performed, which showed a large heterogeneous exophytic mass (9.2 x 9.5 x 9 cm) arising from the greater curve of the stomach suspicious of GIST (Image 2), with hemorrhagic free fluid in the abdomen and pelvis (Image 3).

Intra-operative finding revealed a thin-walled stomach GIST with recent bleeding and intraperitoneal hematoma adjacent to the GIST. Histopathological report was that of GIST of intermediate to moderate risk of behavior.

CASE REPORT (TWO)

A 53-year-old man presented to the ED with a month of lower abdominal discomfort, which was more pronounced when the bladder was full. He had already undergone a

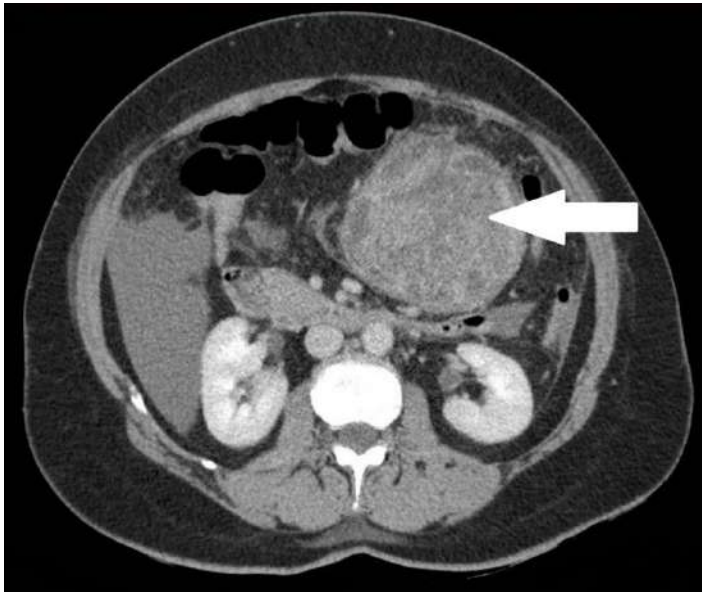


Image 2. Computed tomography of the abdomen and pelvis at level of renal hilum showing a large, heterogeneous exophytic mass of 9.2 x 9.5 x 9 cm as indicated by the white arrow, later determined to be a gastrointestinal stromal tumor.

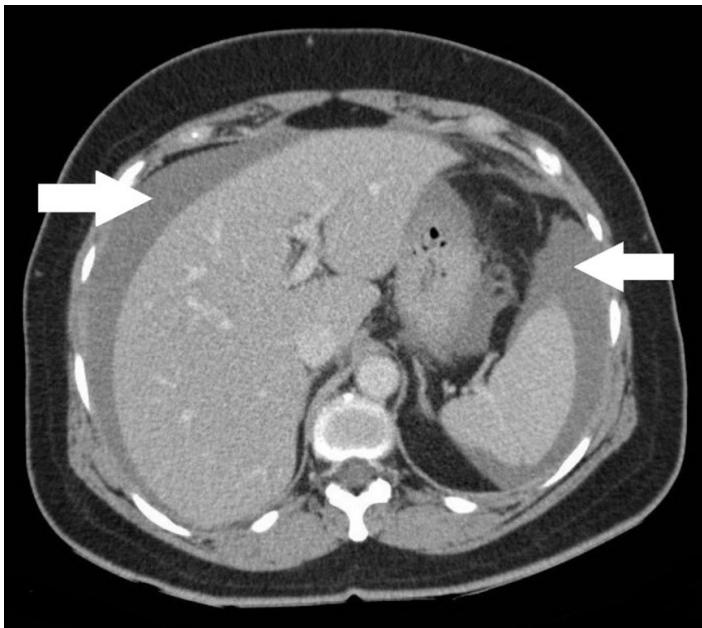


Image 3. Computed tomography of the abdomen and pelvis showing free intra-abdominal fluid as indicated by the white arrows, later determined to be a gastrointestinal stromal tumor.

cystoscopy and colonoscopy, which did not reveal any significant finding to account for his symptoms. At the ED, his vital signs were BP 122/71 mmHg, pulse rate of 92 bpm, respiratory rate 18 bpm, pulse oximetry of 99 % on room air and temperature at 36.2°C. Clinical examination of the

CPC-EM Capsule

What do we already know about this clinical entity? *Gastrointestinal stromal tumors (GISTs) are rare malignancies of the gastrointestinal tract, which are often incidental findings on computed tomography (CT). Symptomatic patients often present late and the diagnosis would usually involve CT and endoscopic ultrasonography.*

What makes this presentation of disease reportable?

Point-of-care ultrasound (POCUS) has never been previously described in the literature as a modality for the diagnosis of GIST. This case report illustrates the usefulness of POCUS in the evaluation of patients with non-specific abdominal symptoms and/or findings, leading to the diagnosis of GIST.

What is the major learning point?

POCUS may be a potential screening modality for patients with non-specific abdominal symptoms and/or findings, leading to the diagnosis of GIST.

How might this improve emergency medicine practice?

POCUS can help emergency physicians to expedite investigations and management plans for patients with non-specific abdominal symptoms and/or findings. This leads to an earlier diagnosis of GIST and the potential to improve the patient's prognosis.

abdomen revealed a left lower quadrant mass that was mildly tender on palpation. POCUS showed a suprapubic mass of mixed echogenicity with a marginal halo (Image 4).

He underwent a CTAP, which revealed a large centrally necrotic mass (9.3 x 11.6 x 9.3 cm) that was closely related to the pelvic small bowel loops (Image 5), highly suggestive of malignant GIST with peritoneal and liver metastases. A small amount of ascites was noted in the pelvis.

DISCUSSION

GISTs accounts for 90% of mesenchymal tumors in the gastrointestinal tract and 2-3% of all gastric malignancies.¹ It can arise anywhere in the gastrointestinal tract with the stomach being the most common site (up to 70%), as well as in extra-visceral locations such as mesentery, omentum or

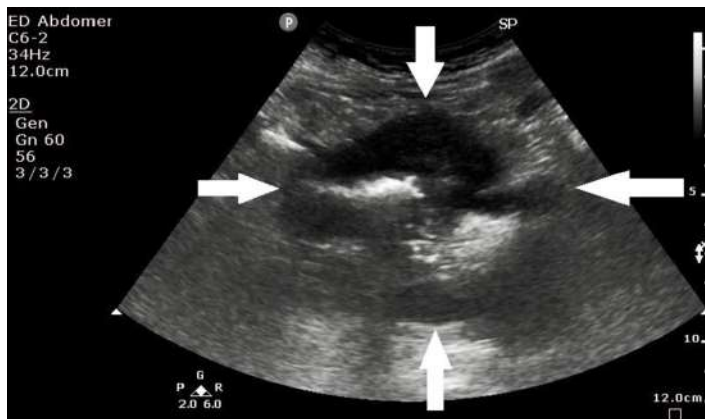


Image 4. Point-of-care ultrasound of the left lower quadrant showing a suprapubic mass of mixed echogenicity with marginal halo as outlined by the white arrows, later determined to be a gastrointestinal stromal tumor.

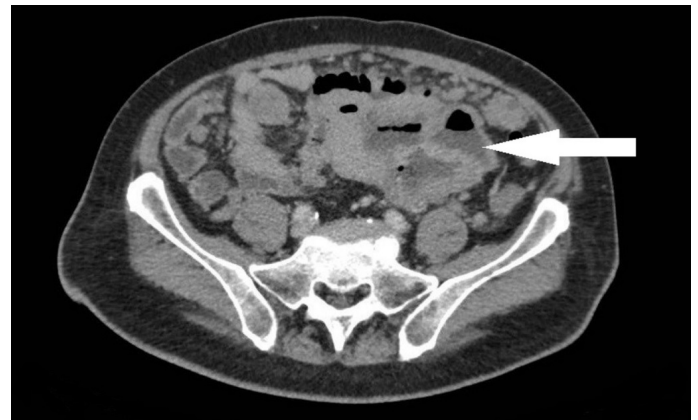

Image 5. Computed tomography of the abdomen and pelvis showing a centrally necrotic mass of 9.3 x 11.6 x 9.3 cm that was closely related to the small bowel loops as indicated by the white arrow, later determined to be a gastrointestinal stromal tumor.

retroperitoneum.² The global incidence of GISTs is reported to be between 10 to 15 cases per million population, with an age range between 10 to 100 years; the median age is reported in the mid-60s and there is equal male-to-female distribution.³ Clinical manifestations of GISTs are erratic and depend on their size and location.^{1, 4} The diagnosis of GIST is often delayed as small GISTs are often asymptomatic and patients generally present with non-specific symptoms such as early satiety, bloating, abdominal pain and fatigue from anemia.^{4, 5} And by the time of presentation, the tumor is often large and has spread to other organs.⁶

The most common symptom at presentation is bleeding,^{7, 8} as seen in our first patient who presented with syncope episodes secondary to intra-abdominal bleeding. These two cases illustrate the usefulness of point-of-care ultrasonography in evaluating patients with vague abdominal complaints or a clinically palpable mass in the acute setting. Although endoscopic ultrasonography has been described as a valuable tool that allows diagnosis and localization of GISTs and their characterization such as extra-mural involvement, with the possibility of performing real-time needle biopsy for confirmation,^{8, 9} such modality is often not readily available in the ED.

Trans-abdominal sonography can help to characterize the internal content of both the primary and metastatic GIST. It usually appears as a homogeneously hypoechoic mass in close relation to the gastrointestinal tract, but a variable degree of heterogeneity is seen in larger GISTs representing necrosis, cystic changes and hemorrhages. The site of origin is often hard to detect on US especially for a large tumor.⁸ Computed tomography (CT) is recommended as the primary imaging modality for the diagnosis of GISTs.⁹ CT can delineate the full extent of a large GIST and detect local invasion and distal metastases.¹⁰ It provides the basis for diagnosis and staging,

and when combined with positron emission tomography, it is the gold standard method for assessment of response to treatment.¹¹ However, such modalities are sophisticated and require time and expertise for the imaging and interpretation. In the acute emergency setting, POCUS has an important role as a first-line screening tool in such situations.

CONCLUSION

Although we are not able to confidently diagnose a GIST based on a point-of-care ultrasound, certain sonographic features, e.g., heterogeneity and marginal halo of an abdominal mass that is not within an intra-abdominal organ such as liver, spleen or kidneys, are suggestive of GIST and would prompt us to arrange for urgent definitive imaging modalities. Our two cases indicate that point-of-care ultrasound may be useful in screening for patients with vague abdominal pain.

Address for Correspondence: Kim Poh Chan, MBBS, MRCSEd (A&E), RDMS, Sengkang Health, Department of Emergency Medicine, 378, Alexandra Hospital, Singapore 159964. Email: chan.kim.poh@singhealth.com.sg.

Conflicts of Interest: By the CPC-EM article submission agreement, all authors are required to disclose all affiliations, funding sources and financial or management relationships that could be perceived as potential sources of bias. The authors disclosed none.

Copyright: © 2018 Chan. This is an open access article distributed in accordance with the terms of the Creative Commons Attribution (CC BY 4.0) License. See: <http://creativecommons.org/licenses/by/4.0/>

REFERENCES

1. HC Kang, CO Menias, AH Gaballah, et al. Beyond the GIST: Mesenchymal tumors of the stomach. *Radiographics*. 2013;33(6):1673-90.
2. B Sureka, MK Mittal, A Mittal, et al. Imaging spectrum of gastrointestinal stromal tumor. *Indian J Med Paediatr Oncol*. 2014;35(2):143-8.
3. K Søreide, OM Sandvik, JA Søreide, et al. Global epidemiology of gastrointestinal stromal tumours (GIST): a systematic review of population-based cohort studies. *Cancer Epidemiol*. 2016;40:39-46.
4. Michael Stamatakos, Emmanuel Douzinas, Charikleia Stefanaki, et al. Gastrointestinal stromal tumor. *World J Surg Oncol*. 2009;7:61.
5. Brian P Rubin, Michael C Heinrich, and Christopher L Corless. Gastrointestinal stromal tumour. *Lancet*. 2007;369:1731-41
6. S Patnaik, Y Jyotsnarani, S Rammurti. Radiological features of metastatic gastrointestinal stromal tumors. *J Clin Imaging Sci*. 2002;2:43.
7. H. Joensuu. Gastrointestinal stromal tumor (GIST). *Ann Oncol*. 2006;17(Supplement 10): x280-6.
8. F Vernuccio, A Taibbi, D Picone, et al. Imaging of gastrointestinal stromal tumours: from diagnosis to evaluation of therapeutic response. *Anticancer Res*. 2016;36(6):2639-48.
9. G Lanke, JH Lee. How best to manage gastrointestinal stromal tumor. *World J Clin Oncol*. 2017;8(2):135-44.
10. S Lau, KF Tam, CK Kam, et al. Imaging of gastrointestinal stromal tumour (GIST). *Clin Radiol*. 2004;59:487-49.
11. DM King. The radiology of gastrointestinal stromal tumours (GIST). *Cancer Imaging*. 2005;5:150-156.

Adult Male with Leg Swelling after a Fall Two Weeks Prior

Wirachin Hoonpongsimanont, MD, MS*

Amal S. A Keel, MD*

Preet K. Sahota, MS*

Shadi Lahham, MD, MS*

Mohammad A. Helmy, MD†

Shahram Lotfipour, MD, MPH*

*University of California, Irvine, Department of Emergency Medicine, Irvine, California

†University of California, Irvine, Department of Radiological Sciences, Irvine, California

Section Editor: Rick A. McPheeters, DO

Submission history: Submitted September 26, 2017; Revision received November 16, 2017; Accepted November 29, 2017

Electronically published January 18, 2018

Full text available through open access at http://escholarship.org/uc/uciem_cpccem

DOI: 10.5811/cpcem.2017.11.36544

[Clin Pract Cases Emerg Med.2018;2(1):86-88]

CASE PRESENTATION

A 49-year-old male presented to the emergency department (ED) with right knee pain and swelling for two days after falling from a two-story roof two weeks prior (Image 1). He visited the ED immediately after the fall; however, his radiographs showed no acute pathology. He was able to ambulate until significant swelling, bruising and pain ensued. His blood pressure was 111/71 millimeters of mercury, heart rate was 108 beats per minute, oxygen saturation was 97% at room air, and temperature was 37.4 degrees Celsius. His laboratory tests showed leukocytosis (white blood cell count: 35,500 cells per microliter), elevated c-reactive protein level (17 milligrams per deciliter (mg/dl)), lactate level (1.6 millimoles per liter (mmol/L)), sodium level (135 mmol/L), creatinine level (0.7 mg/dl), glucose level (143 mg/dl) and hemoglobin (14.9 grams per deciliter). A computed tomography (CT) of his right lower extremity was obtained (Image 2).

DIAGNOSIS

The patient was started on intravenous clindamycin and piperacillin/tazobactam. Surgery was consulted and requested a CT. The incision and drainage was performed four hours after his presentation to the ED. The surgeon found an abscess in the medial aspect of the leg at the level of the knee above the fascial plane with healthy-appearing muscle. The patient was discharged home in good condition after four-day admission.

Given the rapid progression of the infection, an operative finding of an abscess above the fascial plane, and a tissue culture that grew Group A *Streptococcus*, we concluded that the patient had early necrotizing fasciitis (NF). NF should be suspected even in immunocompetent hosts. Important clues are rapidly progressive violaceous lesions and a sudden onset of severe pain. A clinical staging of disease has been proposed based on cutaneous findings (Table 1).^{1,2}

The common pretest probability tool used is the Laboratory Risk Indicator for Necrotizing Fasciitis (LRINEC) score. Our patient had a LRINEC score of six, which is associated with longer intensive care unit stay and higher septic shock and mortality rate.³ CT and magnetic resonance imaging are the radiological tests of choice in diagnosing NF, but obtaining these images could delay the definitive treatment.^{4,5} Although dissecting air along the fascial plane is pathognomonic for NF, NF is a clinical diagnosis. Non-specific CT findings (i.e., dermal thickening, cellulitis mimics) can be found in early NF.⁶

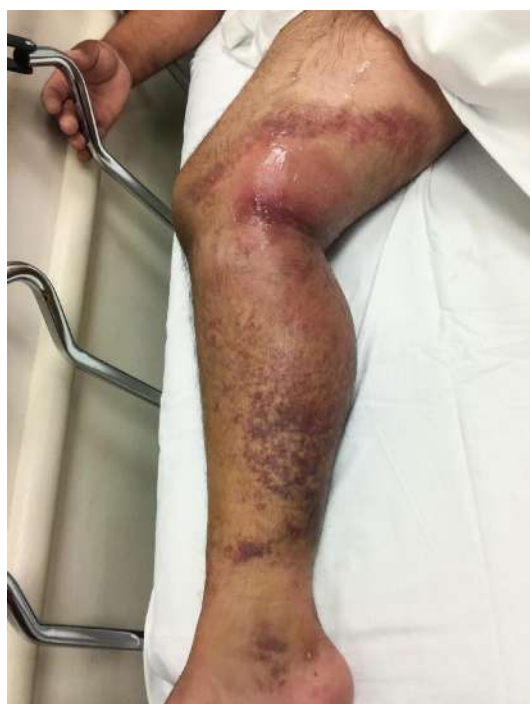

Image 1. Swelling at the right knee and leg in patient thought to have early necrotizing fasciitis.

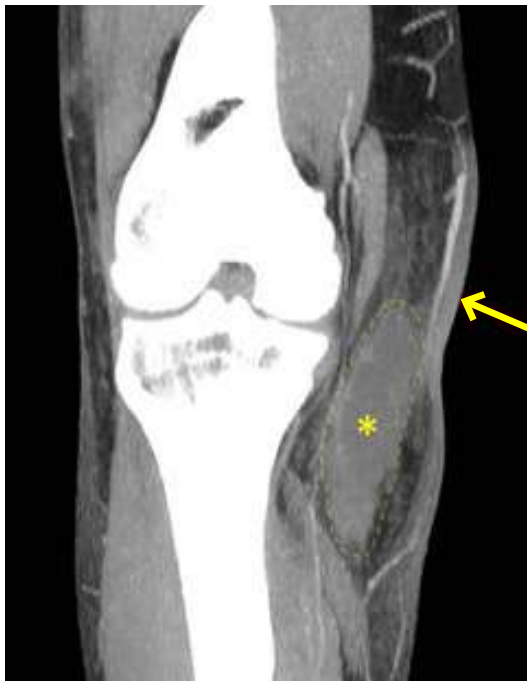

Image 2. Coronal computed tomography image at level of the knee joint demonstrates an abscess (dashed outline with asterisk) in the medial subcutaneous tissues superficial to the muscle planes. The overlying skin thickening (arrow) reflects cellulitis.

CPC-EM Capsule

What do we already know about this clinical entity?
Necrotizing fasciitis should be suspected even in immunocompetent hosts. Important clues are rapidly progressive violaceous lesions and sudden onset of severe pain.

What is the major impact of the image(s)?
Non-specific CT findings (i.e., dermal thickening, cellulitis mimics) can be found in early necrotizing fasciitis, within the appropriate clinical presentation.

How might this improve emergency medicine practice?
Ultimately, necrotizing fasciitis is a clinical diagnosis. The provider should not solely rely on the images to establish the diagnosis and treatment.

Table 1. Evolution of physical signs of necrotizing fasciitis, from early to late stages.²

Stage One (early)	Stage Two (intermediate)	Stage Three (late)
Warm to palpation	Blister or bullae formation (serous fluid)	Hemorrhagic bullae
Erythema	Skin fluctuance	Skin anesthesia
Tenderness to palpation (extending beyond the apparent areas of skin involvement)	Skin induration	Crepitus
Swelling		Skin necrosis with dusky discoloration progressing to frank gangrene

Address for Correspondence: Wirachin Hoonpongsimanont, MD, MS, University of California Irvine, Department of Emergency Medicine, 333 The City Drive Blvd. W, Suite 640 Orange, CA 92868. Email: whoonpon@uci.edu.

Conflicts of Interest: By the CPC-EM article submission agreement, all authors are required to disclose all affiliations, funding sources and financial or management relationships that could be perceived as potential sources of bias. The authors disclosed none.

Copyright: © 2018 Hoonpongsimanont et al. This is an open access article distributed in accordance with the terms of the Creative Commons Attribution (CC BY 4.0) License. See: <http://creativecommons.org/licenses/by/4.0/>

REFERENCES

1. CDC Features: Necrotizing Fasciitis. Centers for Disease Control and Prevention (CDC). 2017. Available at: <https://www.cdc.gov/features/necrotizingfasciitis/>. Accessed on August 13, 2016.
2. Wang YS, Wong CH, Tay YK. Staging of necrotizing fasciitis based on the evolving cutaneous features. *Int J Dermatol.* 2007;46(10):1036-41.
3. Edlich RF. Necrotizing fasciitis workup. Medscape. 2017. Available at: <http://emedicine.medscape.com/article/2051157-workup>. Accessed on August 13, 2016.
4. Zacharias N, Velmahos GC, Salama A, et al. Diagnosis of necrotizing soft tissue infections by computed tomography. *Arch Surg.*

- 2010;145(5):452-5.
5. Hosek WT, Laeger TC. Early diagnosis of necrotizing fasciitis with soft tissue ultrasound. *Acad Emerg Med*. 2009;16(10):1033.
 6. Chaudhry AA, Baker KS, Gould ES, et al. Necrotizing fasciitis and its mimics: what radiologists need to know. *AJR Am J Roentgenol*. 2015;204(1):128-39.

A Cloudy Conical Cornea

Katherine Biggs, DO
Sean Stuart, MD

Naval Medical Center Portsmouth, Department of Emergency Medicine, Portsmouth, Virginia

Section Editor: Rick A. McPheeters, DO

Submission history: Submitted June 15, 2017; Revision received August 20, 2017; Accepted September 6, 2017

Electronically published January 9, 2018

Full text available through open access at http://escholarship.org/uc/uciem_cpccem

DOI: 10.5811/cpcem.2017.9.35314

[Clin Pract Cases Emerg Med. 2018;2(1):89-90.]

CASE PRESENTATION

A 26-year-old Black male presented with right eye redness, discomfort and decreased vision over the preceding two weeks. There was no history of trauma or other precipitating event. Physical exam included acuity of 20/200 in the right eye, bilateral conjunctival injection, normal pupillary appearance and reactivity, and full, pain-free movement of bilateral orbits. An opacification was noted along the margin of the right iris extending into the visual field, without visualized defect of the outer cornea or fluorescence uptake on slit lamp examination.

DISCUSSION

In the lateral view (Image 1) there is a conical appearance of the normally round cornea. This is characteristic of keratoconus, a condition resulting in a thinning and resultant protrusion of the cornea. Distortion of the cornea results in impaired retinal focusing causing myopia and astigmatism. The etiology of the disease is uncertain. Treatment is based on the severity of the condition and ranges from use of rigid contact lenses and collagen cross-linking agents to corneal transplant.⁴

The opacification seen along the inferior aspect of the iris (Image 2) is characteristic of corneal hydrops – a collection of aqueous fluid within the cornea through a tear in Descemet's membrane, which leads to gaping of the posterior surface of the cornea. This allows the aqueous fluid to intrude into the cornea, producing an acute edematous response. Unlike corneal ulcerations, which also have an opacified appearance, in hydrops there is no defect in the outer surface of the cornea and therefore will not uptake fluorescein stain. Patients typically present with a rapid decrease in visual acuity, photophobia and pain. Corneal hydrops is a potential complication seen in patients with corneal ectatic disorders such as keratoconus and post-LASIK ectasia.^{1,2} Management includes topical hyperosmotic agents to decrease edema;

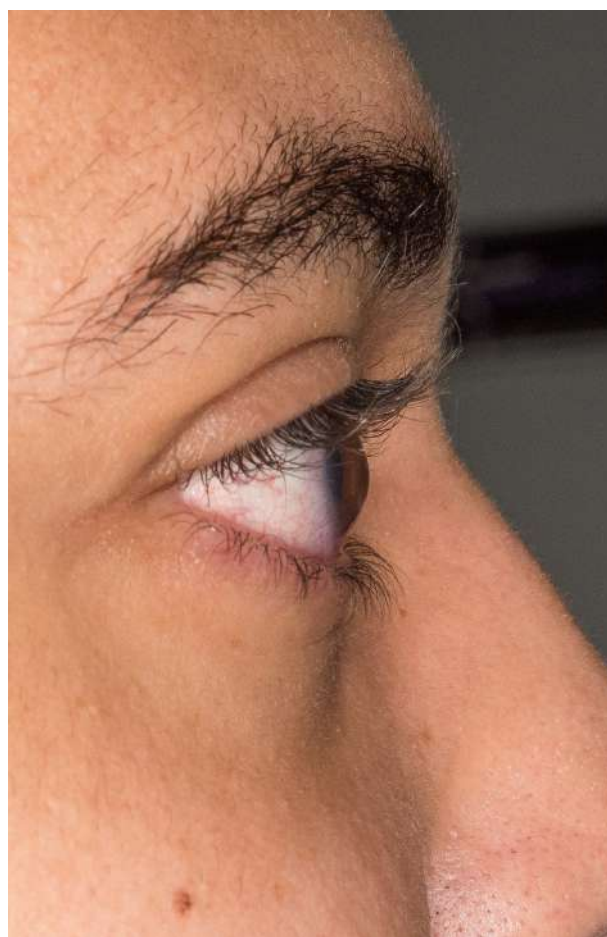

Image 1. Conical appearance of cornea, seen in keratoconus.

nonsteroidal anti-inflammatory drugs; corticosteroids and cycloplegics for pain and photophobia; and topical antihistamines if there is an allergic component.³

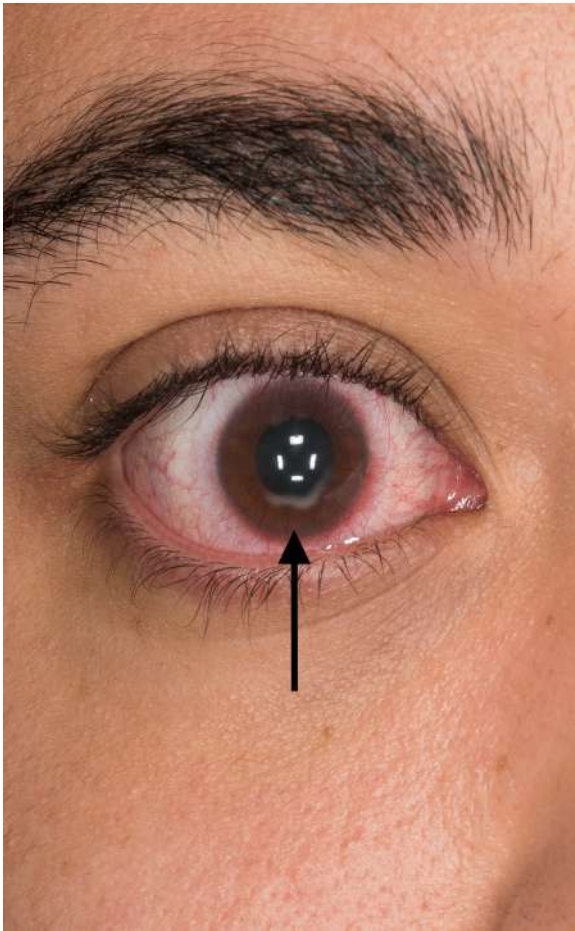


Image 2. Opacification along the inferior, inner aspect of the iris (arrow), characteristic of corneal hydrops.

CPC-EM Capsule

What do we already know about this clinical entity?

Change in vision, eye discomfort and red eyes are common complaints to the emergency department with multiple different etiologies. The images presented represent a rare cause of such complaints.

What is the major impact of the image(s)?

Keratoconus and corneal hydrops are both diagnoses that can be made in the ED. Diagnosis is made based on visual inspection, requiring no special tests or consultants. Recognizing either the conical cornea or opacification can lead to rapid treatment and outpatient follow-up.

How might this improve emergency medicine practice?

These images will broaden the differential diagnosis for patients with eye complaints. While follow up with ophthalmology provides definitive management, emergency physicians can employ multiple treatment options for symptomatic improvement.

Address for Correspondence: Katherine Biggs, DO, Naval Medical Center Portsmouth, 620 John Paul Jones Circle, Portsmouth, VA 23708. Email: katiebiggs11@gmail.com.

Conflicts of Interest: By the *CPC-EM* article submission agreement, all authors are required to disclose all affiliations, funding sources and financial or management relationships that could be perceived as potential sources of bias. Authors are military service members. This work was prepared as part of their official duties. Title 17 U.S.C. 105 provides that "Copyright protection under this title is not available for any work of the United States Government." Title 17 U.S.C. 101 defines a United States Government work as a work prepared by a military service member or employee of the United States Government as part of that person's official duties. The views expressed in this article are those of the author(s) and do not necessarily reflect the official policy or position of the Department of the Navy, Department of Defense, or the United States Government.

Copyright: © 2018 Biggs et al. This is an open access article distributed in accordance with the terms of the Creative Commons Attribution (CC BY 4.0) License. See: <http://creativecommons.org/licenses/by/4.0/>

REFERENCES

1. Biswell R. Cornea. In: Riordan-Eva P, Cunningham ET, Jr. eds. *Vaughan & Asbury's General Ophthalmology, 18e*. New York, NY: McGraw-Hill; 2011. Available at: <http://accessmedicine.mhmedical.com/content.aspx?bookid=387§ionid=40229323>. Accessed on: May 22, 2017.
2. Folberg R. The Eye. In: Kumar V, Abbas A, Aster J. eds. *Robbins and Cotran Pathologic Basis of Disease, 9e*. Philadelphia, PA: Elsevier; 2015: 1319-43.
3. Greenberg RD, Daniel KJ. Eye Emergencies. In: Stone C, Humphries RL. eds. *CURRENT Diagnosis & Treatment Emergency Medicine, 7e*. New York, NY: McGraw-Hill; 2011. Available at: <http://accessmedicine.mhmedical.com/content.aspx?bookid=385§ionid=40357247>. Accessed on: May 22, 2017.
4. Sugar J, Batta P. Keratoconus and other ectasias. In: Yanoff M. ed. *Ophthalmology, 4e*. Philadelphia, PA: Elsevier; 2014: 252-5.

Recurrent Cellulitis in a Patient with Papillomatosis Cutis Lymphostatica

Stella Pak, MD*

John-Phillip Markovic, MD*

Yan Yatsynovich, MD*

Ethan Tope, BS†

Damian Valencia, MD*

*Kettering Medical Center, Department of Medicine, Kettering, Ohio

†Wright State University, Boonshoft School of Medicine, Dayton, Ohio

Section Editor: Rick A. McPheeters, DO

Submission history: August 21, 2017; Revision received September 6, 2017; Accepted October 3, 2017

Electronically published January 9, 2018

Full text available through open access at http://escholarship.org/uc/uciem_cpem

DOI: 10.5811/cpcem.2017.10.36031

[Clin Pract Cases Emerg Med. 2018;2(1):91-92.]

CASE PRESENTATION

A 61-year-old female with a history significant for polycystic ovarian syndrome complicated by splenic cysts status-post splenectomy and chronic lymphedema presented to the hospital with cellulitis involving both lower extremities. In the prior eight months, she had six episodes of cellulitis caused by group B *Streptococcus* involving her lower extremities. She was hospitalized, and blood cultures grew out group B *Streptococcus*. She received treatment with intravenous levofloxacin and vancomycin

and demonstrated clinical improvement. However, careful inspection of the area of cellulitis on her lower extremities revealed papillary lesions consistent with a condition known as papillomatosis cutis lymphostatica (Image). For this condition, she was treated with compression stocking and amoxicillin 500 mg four times daily in the outpatient setting.

DIAGNOSIS

Papillomatosis cutis lymphostatica is a rare complication of primary or secondary lymphedema and

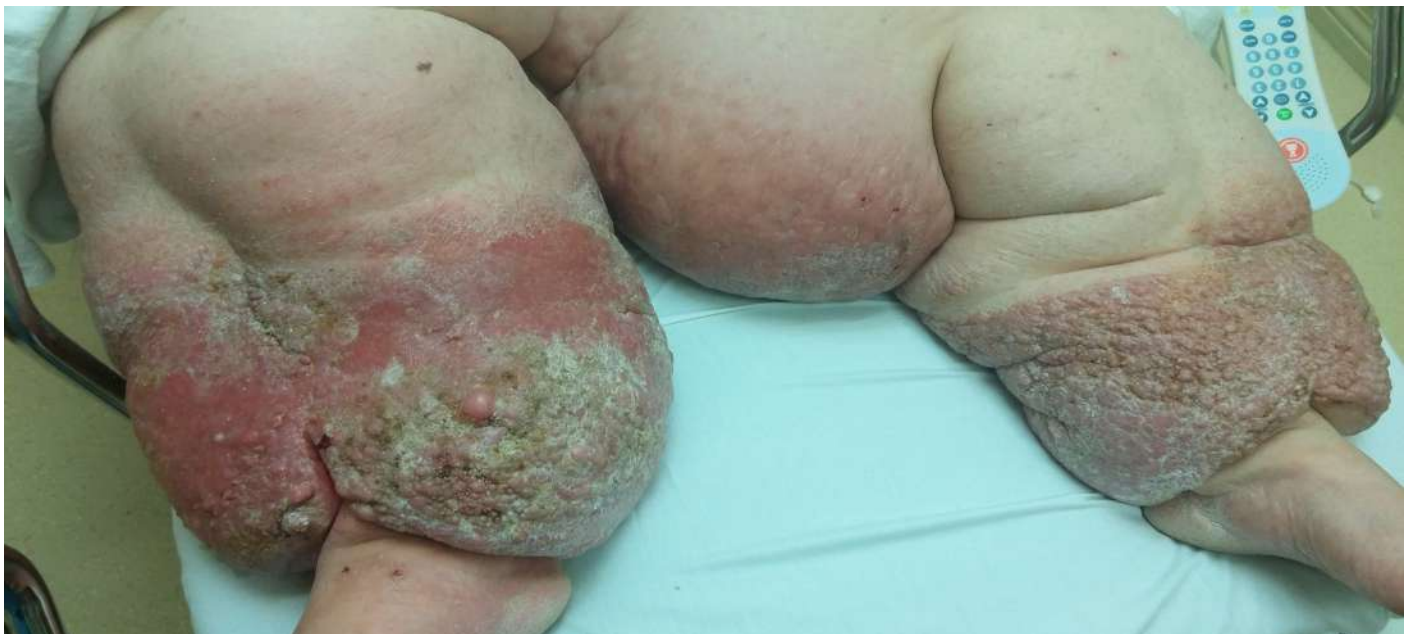

Image. Multiple papular lesions on both legs indicate papillomatosis cutis lymphostatica, a rare complication of lymphedema

has limited treatment options.¹ It increases the risk of infection by causing mechanical tearing of the papules and subsequent breakdown of the skin barrier, which provides a portal of entry for bacterial invasion. Use of compression stockings is the cornerstone of conservative management.¹ Vitamin A derivatives, such as acitretin, have shown therapeutic efficacy in several cases. The postulated therapeutic mechanism by which vitamin A derivatives work includes interference with epidermal proliferation and inflammation by causing increased cell turnover through alteration of gene expression.³ Topical ointments, including 5% salicylic acid, and surgical interventions are other potential treatment options.⁴ This patient was managed with conservative therapy since she was a poor surgical candidate. However, early recognition of papillomatosis cutis lymphostatica is crucial to preventing recurrent infections. To the best of our knowledge, this is the first case of papillomatosis cutis lymphostatica complicated with bacteremia.

CPC-EM Capsule

What do we already know about this clinical entity?

Papillomatosis cutis lymphostatica is a rare complication of chronic lymphedema associated with recurrent cellulitis.

What is the major impact of the image(s)?

This is the first case of papillomatosis cutis lymphostatica reported in the emergency medicine literature.

How might this improve emergency medicine practice?

This image will help clinicians recognize and treat papillomatosis cutis lymphostatica. In the ED, recognition of this rare complication would allow clinicians to have an appropriately high level of suspicion for cellulitis.

Address for Correspondence: Stella Pak, MD, Kettering Medical Center, Internal Medicine Department, 3535 Southern Blvd, Kettering, OH 45429. Email: Stella.Pak@ketteringhealth.org.

Conflicts of Interest: By the CPC-EM article submission agreement, all authors are required to disclose all affiliations, funding sources and financial or management relationships that could be perceived as potential sources of bias. The authors disclosed none.

Copyright: © 2018 Pak et al. This is an open access article distributed in accordance with the terms of the Creative Commons Attribution (CC BY 4.0) License. See: <http://creativecommons.org/licenses/by/4.0/>

REFERENCES

1. Aydin D, Heidenheim M. Papillomatosis cutis lymphostatica. *Clin Case Rep.* 2016;4(10):1012.
2. Kasper R, Nobbe S. Papillomatosis cutis lymphostatica. *N Engl J Med.* 2014;370(1):69.
3. Feind-Koopmans A, van der Kerkhof PC. Successful treatment of papillomatosis cutis lymphostatica with acitretin. *Acta Derm Venereol.* 1995;75(5):411.
4. Vozza A, Palla M, Aiello FS, et al. Papillomatosis cutis lymphostatica. *G Ital Dermatol Venereol.* 2009;144(2):211-2.

Oculomotor Nerve Palsy Secondary to Cavernous Internal Carotid Aneurysm

Gary Lai, DO*

Maria I. Rodriguez, RN†

Alexander J. Scumpia, DO, MSc†

*Broward Health, Coral Springs Hospital, Department of Emergency Medicine, Coral Springs, Florida

†Broward Health, Imperial Point Hospital, Department of Emergency Medicine, Fort Lauderdale, Florida

Section Editor: Rick A. McPheeters, DO

Submission history: Submitted June 26, 2017; Revision received September 28, 2017; Accepted October 13, 2017

Electronically published January 9, 2018

Full text available through open access at http://escholarship.org/uc/uciem_cpem

DOI: 10.5811/cpcem.2017.10.35510

[Clin Pract Cases Emerg Med. 2018;2(1):93-94.]

CASE PRESENTATION

A 68-year-old female presented to the emergency department with progressively worsening, atraumatic right-eye blurred vision, dull headache and mild nausea over the preceding two days. Her daughter also noticed that the patient's right eye was displaced inferolaterally or "down and out." The patient denied photophobia, neck stiffness, rash, myalgias, or changes in speech or gait. Vital signs and laboratory data were unremarkable. After a neurological examination raised the suspicion of intracranial pathology (Image 1) appropriate radiographic imaging was ordered. The lesion was confirmed via computed tomography angiography

with subsequent cerebral angiography (Image 2) demonstrating a 9 x 7.5 millimeter cavernous internal carotid aneurysm.

DISCUSSION

Oculomotor nerve palsy has been classically separated into pupil sparing and non-pupil sparing (i.e., pupils that react to light). Common causes for pupil-sparing pathologies are

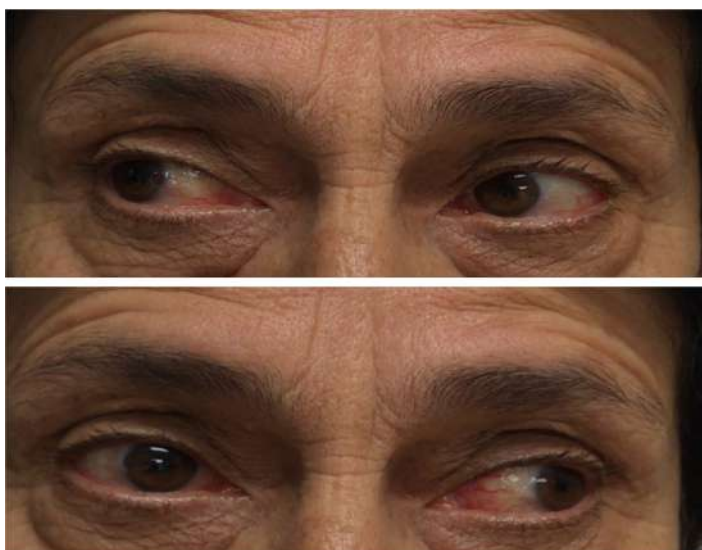

Image 1. Rightward gaze demonstrating normal ocular movements (top image). Leftward gaze demonstrating absent right ocular abduction, illustrating a third nerve palsy (bottom image)

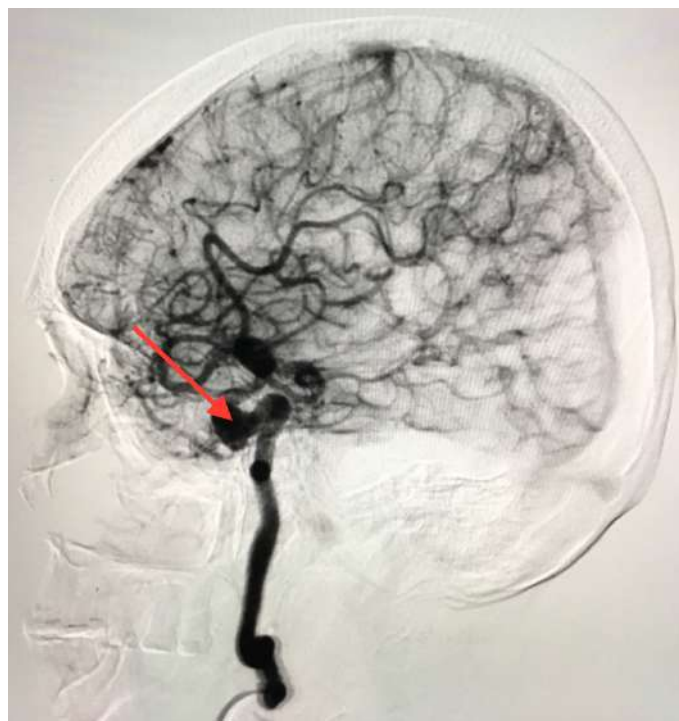

Image 2. Sagittal cerebral angiogram demonstrating the right fusiform, 9 x 7.5-millimeter cavernous internal carotid aneurysm (red arrow)

diabetic neuropathy, myasthenia gravis, atherosclerosis, chronic progressive ophthalmoplegia and vasculopathies (i.e., giant cell arteritis and temporal arteritis).¹ The accepted pathophysiological mechanism of this phenomenon is the formation of vascular lesions occluding the vaso-nervorum leading to ischemic infarction, sparing the parasympathetic fibers located peripherally of the third cranial nerve (62-83% of cases).¹ On the other hand, the most common causes of non-pupil sparing oculomotor palsy are tumor (i.e., chordomas, clival meningiomas), followed by vascular lesions (posterior communicating aneurysms,² and then distal basilar artery aneurysms). Even rarer presentations are uncal herniation and, least commonly (5%),¹ cavernous sinus lesions (including tumor, vascular pathologies).

Cavernous sinus syndrome from lesions can cause multiple nerve palsies due to the anatomical constituents of the oculomotor (III), trochlear (IV), trigeminal ophthalmic and maxillary divisions (V1 and V2) and abducens (VI).³ Third nerve palsy secondary to cavernous internal carotid aneurysms will not produce a dilated pupil, since sympathetic fibers that cause dilatation are also paralyzed.⁴ This was true to the case described herein where the patient's right pupil was not "blown." This case illustrates the complexity of the cavernous sinus and the utilization of computed tomography angiography to achieve appropriate clinical diagnosis. The patient ultimately underwent successful neuro-endovascular treatment and was subsequently discharged five days later.

CPC-EM Capsule

What do we know about this clinical entity?

Many previously reported intracranial pathologies can cause oculomotor nerve palsy, including endocrine, aneurysms, and tumors.

What is the major impact of the image(s)?
Cavernous sinus internal carotid aneurysms, although rare, can cause oculomotor nerve palsy. The images demonstrate the necessity for advanced imaging, which is essential for proper diagnosis.

How might this improve emergency medicine practice?

The neuroanatomical complexity of the cavernous sinus should raise the emergency physician's suspicion for intracranial lesions.

Address for Correspondence: Alexander J. Scumpia, DO, MSc, Broward Health, Imperial Point Hospital, 6401 N Federal Highway, Fort Lauderdale, FL 33308. Email: ascumpia@yahoo.com.

Conflicts of Interest: By the CPC-EM article submission agreement, all authors are required to disclose all affiliations, funding sources and financial or management relationships that could be perceived as potential sources of bias. The authors disclosed none.

Copyright: © 2018 Lai et al. This is an open access article distributed in accordance with the terms of the Creative Commons Attribution (CC BY 4.0) License. See: <http://creativecommons.org/licenses/by/4.0/>

REFERENCES

1. Trobe JD. Third nerve palsy and the pupil. Footnotes to the rule. *Arch Ophthalmol.* 1988;106(5):601-2.
2. Scumpia AJ, Serak J, Ritchie KL, et al. Posterior communicating artery aneurysm presenting in a 20-year-old female with Noonan's syndrome. *West J Emerg Med.* 2013;14(2):175-6.
3. Wilkins RH, Rengachary SS. *Neurosurgery.* McGraw-Hill, New York, 1985.
4. Breen LA, Hopf HC, Farris BK, et al. Pupil-sparing oculomotor nerve palsy due to midbrain infarction. *Arch Neurol.* 1991;48(1):105-6.

Pseudo-Subarachnoid Hemorrhage after Cardiac Arrest

Kraftin E. Schreyer, MD*
 Krishna Surapaneni, MD, MPH†
 Maura Sammon, MD*

*Lewis Katz School of Medicine at Temple University, Department of Emergency Medicine, Philadelphia, Pennsylvania

†Lewis Katz School of Medicine at Temple University, Department of Radiology, Philadelphia, Pennsylvania

Section Editor: Rick A. McPheeters, DO

Submission history: Submitted August 2, 2017; Revision received September 25, 2017; Accepted October 13, 2017

Electronically published January 9, 2018

Full text available through open access at http://escholarship.org/uc/uciem_cpccem

DOI: 10.5811/cpcem.2017.10.35856

[Clin Pract Cases Emerg Med. 2018;2(1):95-96.]

CASE PRESENTATION

A 24-year-old man presented after presumed atraumatic cardiac arrest. He had prolonged resuscitation that ultimately resulted in return of spontaneous circulation. A non-contrast computed tomography (CT) brain was immediately obtained. Comparison was made to the patient's prior head CT (Image).

DIAGNOSIS

Pseudo-subarachnoid hemorrhage (pseudo-SAH). The pseudo-SAH phenomenon can be seen with anoxic brain injury and many other causes of diffuse cerebral edema.² In anoxic brain injury, the hyperdense appearance results from a combination of loss of gray-white differentiation, narrowing and effacement of the subarachnoid spaces, and corresponding engorgement of superficial pial veins.^{3,4}

Although the CT mimics the appearance of SAH, as evidenced by apparent diffusely increased density of the basal

cisterns and subarachnoid spaces, this is perceptually artifactual, as the attenuation values are lower than expected for acute blood products. The Hounsfield units (HU) in pseudo-SAH are generally 30-45 vs. 60-70 in true SAH.¹ Additionally, true SAH will have higher attenuation values than that of the tentorium, a helpful differentiating feature. In this case, HU were 42 at the basal cisterns and 43 at the tentorium. Additional differentiating features are the diffuse loss of gray-white differentiation and effaced basal cisterns indicating diffuse cerebral edema.^{1,2}

The prognosis is worse in patients with pseudo-SAH vs. SAH, likely because of underlying disease processes and decreased cerebral perfusion in the setting of elevated intracranial pressure.¹ Pseudo-SAH must be included in the differential for a patient with this CT appearance, because it may facilitate end-of-life discussions regarding invasive procedures, transfers, and/or do-not-resuscitate status.

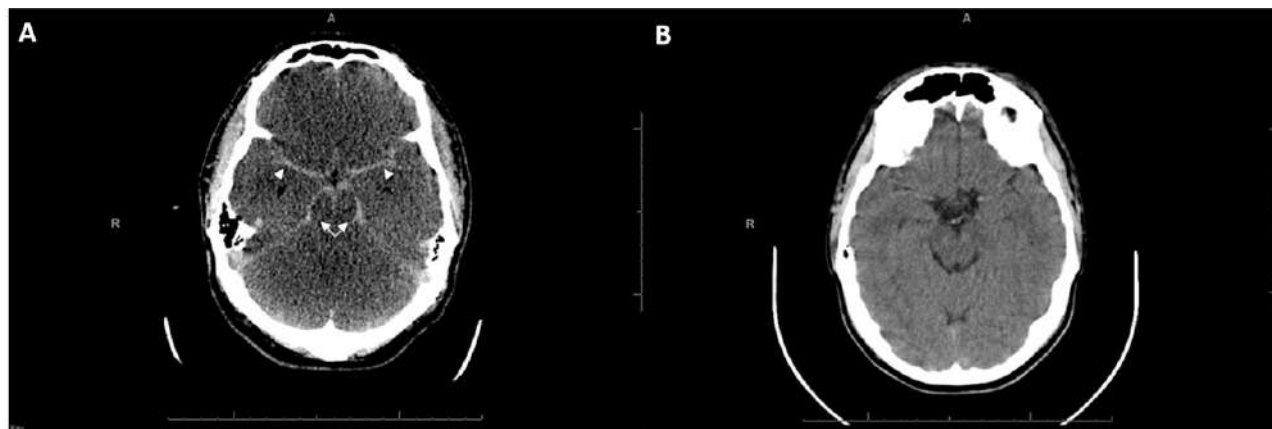


Image. A) Post-resuscitation axial computed tomography (CT) of the brain demonstrating diffusely increased density of the basal cisterns (arrows) and subarachnoid spaces (arrowheads); and B) normal axial CT of the brain obtained on prior visit.

Address for Correspondence: Kraftin E. Schreyer, MD, Lewis Katz School of Medicine at Temple University, 1316 W. Ontario Street, Jones Hall 1004, Philadelphia, PA 19140. Email: kraftin.schreyer@tuhs.temple.edu.

Conflicts of Interest: By the *CPC-EM* article submission agreement, all authors are required to disclose all affiliations, funding sources and financial or management relationships that could be perceived as potential sources of bias. The authors disclosed none.

Copyright: © 2018 Schreyer et al. This is an open access article distributed in accordance with the terms of the Creative Commons Attribution (CC BY 4.0) License. See: <http://creativecommons.org/licenses/by/4.0/>

REFERENCES

1. Yuzawa H, Higano S, Mugikura S, et al. Pseudo-subarachnoid hemorrhage found in patients with post resuscitation encephalopathy: characteristics of CT findings and clinical importance. *AJNR Am J Neuroradiol.* 2008;29(8):1544-9.
2. Given CA 2nd, Burdette JH, Elster AD, et al. Pseudo-subarachnoid hemorrhage: a potential imaging pitfall associated with diffuse cerebral edema. *AJNR Am J Neuroradiol.* 2003;24(2):254-6.
3. Thomas GL, Stachowski ER. Pseudosubarachnoid hemorrhage on CT brain scan: an unusual presentation of diffuse hypoxic brain injury. *Intensive Care Med.* 2007;33(11):2038-40.
4. Yu J, Park S. Pseudo-subarachnoid hemorrhage. *AJEM.* 2008;26:521-2.

CPC-EM Capsule

What do we already know about this clinical entity?

Pseudo-subarachnoid hemorrhage (pseudo-SAH) can be seen with many causes of diffuse cerebral edema, including anoxic brain injury.

What is the major impact of the image(s)?

This CT, seen after cardiac arrest, may indicate diffuse anoxic injury, rather than acute subarachnoid bleed.

How might this improve emergency medicine practice?

Including pseudo-SAH in the differential may facilitate end-of-life discussions regarding invasive procedures, transfers, or do-not-resuscitate status.

Child with Testicular Pain

Nicholas Otts, MD*
Ryan L. Webb, MD†
Josh Greenstein, MD*
Barry Hahn, MD*

*Staten Island University Hospital, Northwell Health, Department of Emergency Medicine, Staten Island, New York

†Staten Island University Hospital, Northwell Health, Department of Radiology, Staten Island, New York

Section Editor: Manish Amin, DO

Submission history: Submitted September 25, 2017; Revision received November 21, 2017; Accepted November 29, 2017

Electronically published January 11, 2018

Full text available through open access at http://escholarship.org/uc/uciem_cpccem

DOI: 10.5811/cpcem.2017.11.36530

[Clin Pract Cases Emerg Med.2018;2(1):97-98.]

CASE PRESENTATION

An 11-year-old boy presented to the emergency department (ED) with sudden onset severe atraumatic right testicular pain, associated with nausea and vomiting. On examination, the patient exhibited a slight horizontal lie of the right testicle as well as an absent cremasteric reflex on the right. Urology was emergently consulted. Though vascular flow was noted bilaterally on spectral Doppler (Images 2), the patient underwent surgical detorsion due to

the whirlpool sign seen on point-of-care ultrasound (POCUS) of spermatic cord (Image).

DIAGNOSIS

Testicular torsion with whirlpool sign: Testicular torsion occurs when twisting of the spermatic cord results in a subsequent loss of blood supply to the ipsilateral testicle. Testicular torsion is primarily a pediatric problem, with a bimodal age distribution of the first year of life and

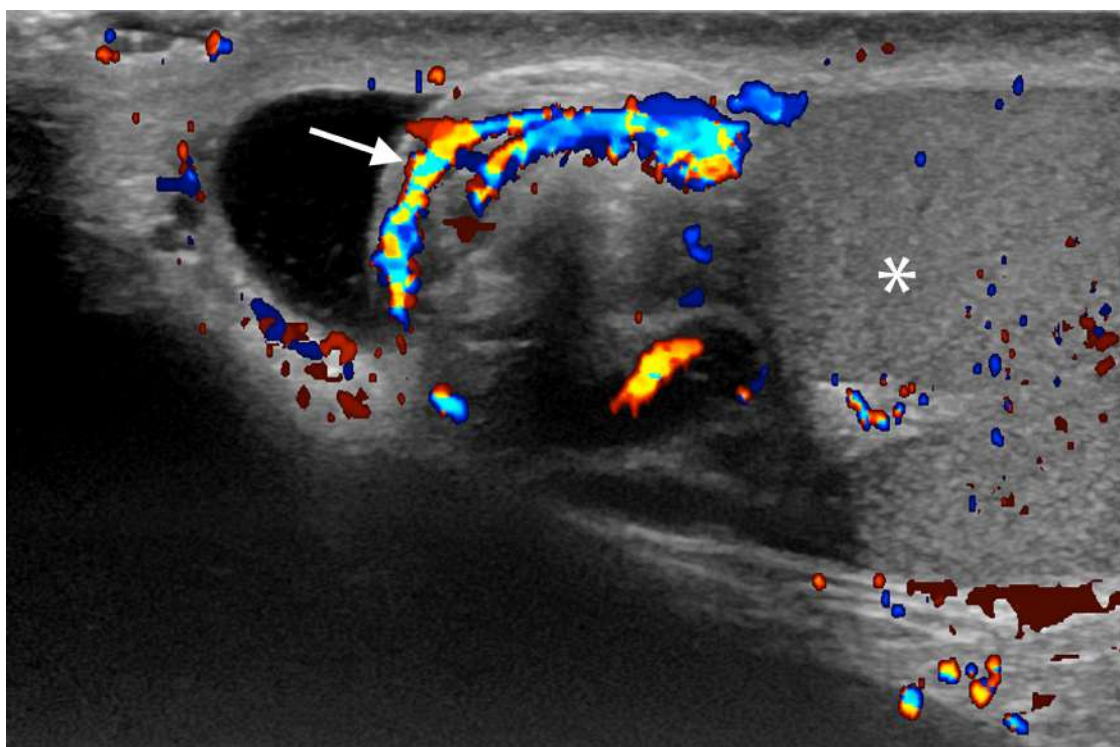


Image 1. Ultrasound of the spermatic cord demonstrates an edematous, heterogeneous extra testicular mass representing the twisted spermatic cord, with whorled color flow, the “whirlpool sign”(white arrow) around a central axis. Immediately adjacent is the testicle (white asterisk).

early adolescence. Evaluation of testicular flow by color and spectral Doppler is the primary method of diagnosis.¹ However, evaluation with Doppler can be non-diagnostic due to the presence of low-velocity blood flow. Direct visualization of the spermatic cord by POCUS may elicit the whirlpool sign or an echogenic mass twisted around a central axis. As demonstrated by this case, whirlpool sign is diagnostic of torsion and can help identify torsion when Doppler is non-diagnostic.^{2,3} Thus, the whirlpool sign, although not frequently mentioned in emergency medicine literature, can be critical to the diagnosis of torsion in the ED and should be an ultrasound finding known to all emergency physicians.

Address for Correspondence: Josh Greenstein, MD, Staten Island University Hospital, Department of Emergency Medicine, 475 Seaview Avenue, Staten Island, NY 10305. Email: JGreenstein1@northwell.edu.

Conflicts of Interest: By the CPC-EM article submission agreement, all authors are required to disclose all affiliations, funding sources and financial or management relationships that could be perceived as potential sources of bias. The authors disclosed none.

Copyright: © 2018 Otts et al. This is an open access article distributed in accordance with the terms of the Creative Commons Attribution (CC BY 4.0) License. See: <http://creativecommons.org/licenses/by/4.0/>

CPC-EM Capsule

What do we already know about this clinical entity?

The whirlpool sign is an important diagnostic marker in the evaluation of suspected testicular torsion by point-of-care ultrasound.

What is the major impact of the image(s)?

The whirlpool sign is a characteristic sonographic finding indicative of testicular torsion.

How might this improve emergency medicine practice?

Visualization of the whirlpool sign allows confident diagnosis of testicular torsion.

REFERENCES

1. Prando D. Torsion of the spermatic cord: the main gray-scale and Doppler sonographic signs. *Abdom Imaging*. 2009;34(5):648–61
2. Vijayaraghavan SB. Sonographic differential diagnosis of acute scrotum: real-time whirlpool sign, a key sign of torsion. *J Ultrasound Med* 2006;25(5):563–74
3. Baud C, Veyrac C, Couture C, et al. Spiral twist of the spermatic cord: a reliable sign of testicular torsion. *Pediatr Radiol*. 1998;28(12):950–4

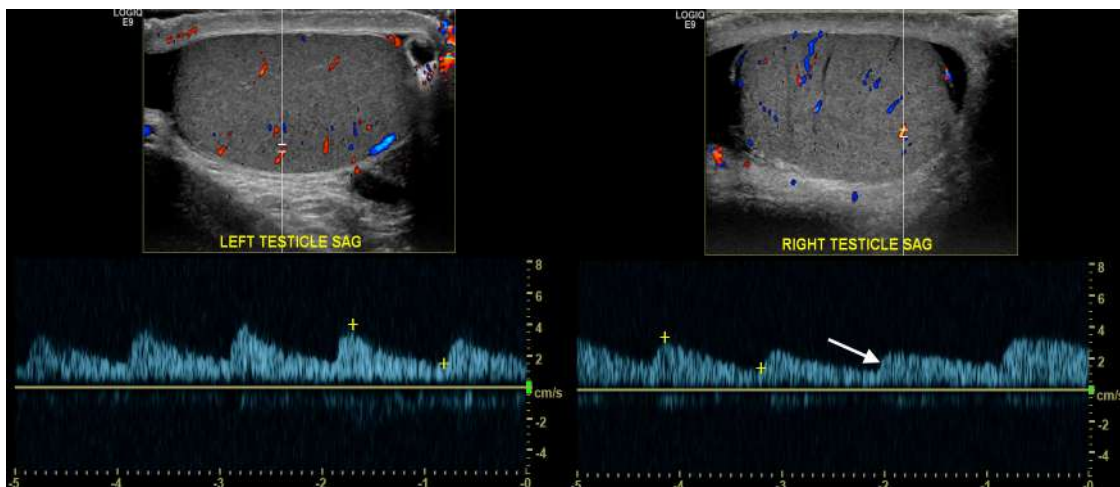


Image 2. Transverse ultrasound image of the left testicle obtained with a 15Mhz linear-array transducer using spectral Doppler demonstrates normal arterial wave form and flow (2A). Spectral Doppler of the right testicle (white arrow) demonstrates comparatively decreased systolic velocities with slowing of the upstroke (2B).

Point-of-care Ultrasound for the Diagnosis of a “Ping Pong” Skull Fracture

Adam S. Bloom, DO
Jonathan Auten, DO
Joel M. Schofer, MD

Naval Medical Center Portsmouth, Department of Emergency Medicine, Portsmouth, Virginia

Section Editor: Rick A. McPheeters, DO

Submission history: Submitted August 28, 2017; Revision received December 13, 2017; Accepted December 13, 2017

Electronically published January 11, 2018

Full text available through open access at http://escholarship.org/uc/uciem_cpce

DOI: 10.5811/cpcem.2017.12.36239

[Clin Pract Cases Emerg Med. 2018;2(1):99-100.]

CASE PRESENTATION

A four-month-old female presented to the emergency department after a witnessed fall from a high chair. She landed on her head but did not lose consciousness. She did not have any vomiting or altered mental status. There was a palpable defect in her right parietal skull. Point-of-care ultrasound (POCUS) demonstrated a large depression in her parietal skull consistent with a depressed skull fracture (Image 1). The fracture was confirmed by a non-contrast computed tomography (CT) of the head (Image 2). The CT was otherwise negative. The patient was admitted for observation but was discharged after an uncomplicated hospital course and was doing well at a follow-up visit.

DIAGNOSIS

Depressed skull fractures in neonates are typically different from those in adults. The soft bone tends to buckle rather than break. As such, they are often referred to as

CPC-EM Capsule

What do we already know about this clinical entity?

We know that ultrasound is a modality with excellent specificity for the diagnosis of skull fractures.

What is the major impact of the image(s)?

Ultrasound can also be used to diagnose depressed skull fractures in pediatric patients.

How might this improve emergency medicine practice?

Ultrasound may aid in the diagnosis of depressed skull fractures in pediatric patients.

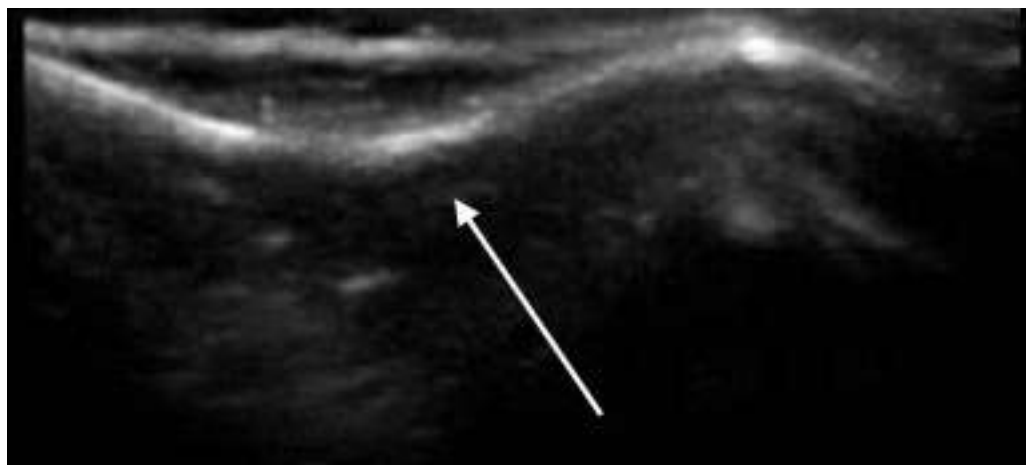


Image 1. Point-of-care ultrasound demonstrating “ping pong” skull fracture (Image obtained using a liner probe, 13-6 megahertz).

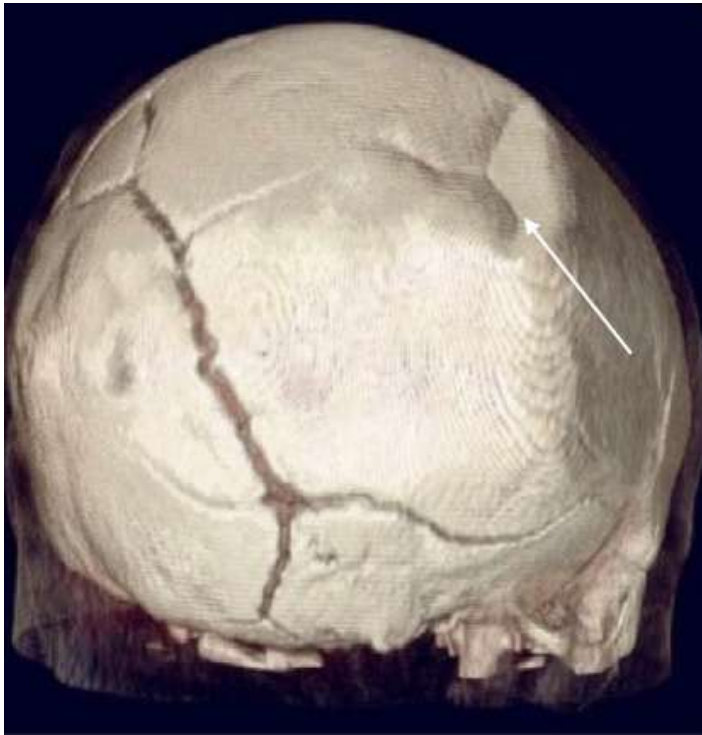


Image 2. Corresponding computed tomography with three-dimensional reconstruction demonstrating “ping pong” skull fracture.

“ping pong” fractures, a reference to the way a ping pong ball looks when it has been indented. They may occur as sequelae to trauma, birth, or normal uterine development.¹ POCUS is a convenient method to quickly and accurately detect skull fractures in pediatric patients with sensitivities ranging from 88-100% in two prospective trials.²⁻³ While most authors agree that a CT is indicated to rule out underlying pathology once a skull fracture is identified, a consensus does not exist on the role of POCUS to safely rule out skull fractures in neonates.⁴ We believe this is the first reported case of a “ping pong” skull fracture diagnosed using POCUS.

Address for Correspondence: Adam S. Bloom, DO, Naval Medical Center Portsmouth, Department of Emergency Medicine, 620 John Paul Jones Circle, Portsmouth, VA 23708. Email: adambloom34@gmail.com.

Conflicts of Interest: By the *CPC-EM* article submission agreement, all authors are required to disclose all affiliations, funding sources and financial or management relationships that could be perceived as potential sources of bias. The authors disclosed none. This work was prepared as part of authors' official duties. Title 17 U.S.C. 105 provides that 'Copyright protection under this title is not available for any work of the United States Government.' Title 17 U.S.C. 101 defines a United States Government work as a work prepared by a military service member or employee of the United States Government as part of that person's official duties. The views expressed in this article are those of the authors and do not necessarily reflect the official policy or position of the Department of the Navy, Department of Defense, or the United States Government.

Copyright: © 2018 Bloom et al. This is an open access article distributed in accordance with the terms of the Creative Commons Attribution ([CC BY 4.0](https://creativecommons.org/licenses/by/4.0/)) License. See: <http://creativecommons.org/licenses/by/4.0/>

REFERENCES

1. Zalatim, O, Ranasinghe M, Dias M, et al. Treatment of depressed skull fractures in neonates using percutaneous microscrew elevation. *J Neurosurg Pediatr.* 2012;9(6):676-9.
2. Parri N, Crosby B, Glass C, et al. Ability of emergency ultrasonography to detect pediatric skull fractures: a prospective, observation study. *J Emerg Med.* 2013;44(1):135-41.
3. Rabiner J, Friedman L, Khine H, et al. Accuracy of point-of-care ultrasound for the diagnosis of skull fractures in children. *Pediatrics.* 2013;131:1757-64.
4. Ramirez-Schrempp D, Vinci RJ, Liteplo A. Bedside ultrasound in the diagnosis of skull fractures in the pediatric emergency department. *Pediatr Emerg Care.* 2011;27(4):312-4.

Acute Cardiac Air Embolism

Leslie A. Bilello, MD*
Brian Q. Gacioch, MD, EMT-P†
James P. Phillips, MD‡

*Harvard Medical School, Beth Israel Deaconess Medical Center, Department of Emergency Medicine, Boston, Massachusetts
†Medical Corps, United States Air Force, Malcolm Grow Emergent Care Center, Joint Base Andrews, Maryland
‡George Washington University Hospital, Department of Emergency Medicine, Washington, District of Columbia

Section Editor: Shadi Lahham, MD

Submission history: Submitted September 18, 2017; Revision received December 8, 2017; Accepted December 13, 2017

Electronically published January 12, 2018

Full text available through open access at http://escholarship.org/uc/uciem_cpem

DOI: 10.5811/cpcem.2017.12.36422

[Clin Pract Cases Emerg Med. 2018;2(1):101-102.]

CASE PRESENTATION

An 84-year-old female status post-Mohs micrographic surgery (MMS) presented to the emergency department (ED) for evaluation after a syncopal episode. Surgical excision of a scalp basal cell carcinoma occurred immediately prior to arrival (Image 1). Hemostasis was achieved by both cauterization and direct pressure. Within one minute, patient experienced a 10-second syncopal episode and was hypoxic (64% on room air). The patient arrived via ambulance with blood pressure 108/56 mm Hg and 92% on 15 liters per minute via non-rebreather. Crepitus was appreciated during cardiac auscultation. We performed a focused cardiac ultrasound (Image 2).

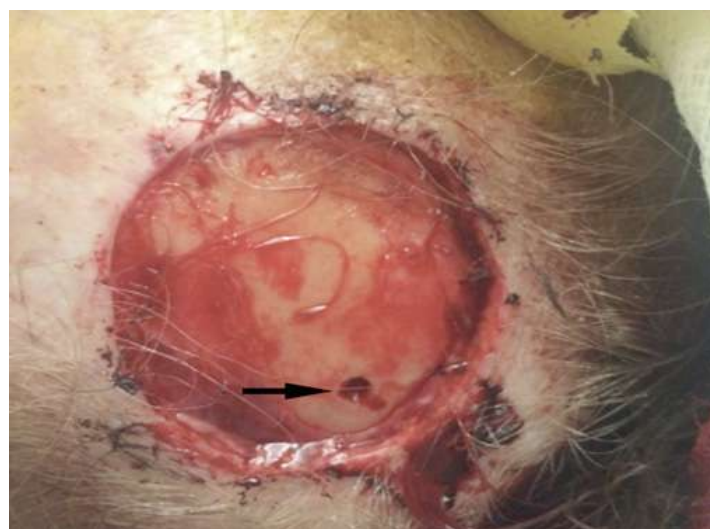


Image 1. Superficial basal cell carcinoma excision site on the parietal scalp. The procedure also required an area of deep bone curettage (black arrow).

DIAGNOSIS

Point-of-care cardiac ultrasound suggested acute air embolism with right heart strain as the cause of the patient's syncope. An air embolism is a rare but serious complication of any procedure that may involve venous or arterial vasculature. Air emboli in the setting of MMS has previously been cited in a dermatology case report.¹ It has also been recorded in head and neck surgery, dental surgery, and is a known complication of seated-position neurosurgical operations.²⁻⁵ Complications include, but are not limited to, coronary or cerebral infarct, complete cardiovascular collapse, and death.⁶

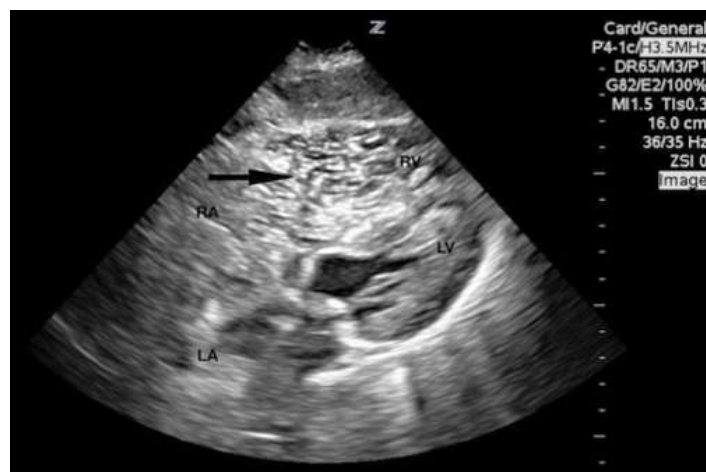

Image 2. A subcostal cardiac view demonstrated normal left ventricle (LV) contractility, decreased right ventricular (RV) contractility, and RV dilation greater than 1.5 times the LV diameter. Copious hyperechoic mobile bodies were noted within the right atrium (RA) and RV (black arrow). A parasternal short view, not pictured, revealed LV septal in-bowing during systole and diastole. LA, left atrium.

To our knowledge, this is the first case within the ED setting to capture acute air emboli causing hemodynamic compromise on point-of-care ultrasound (POCUS). We placed the patient in reverse Trendelenburg while providing supplemental oxygen which lead to real-time clinical improvement with echocardiographic evidence (Image 3). Computed tomography angiogram of the chest ruled out true pulmonary embolism. This case further demonstrates the value of POCUS as a diagnostic tool in the hemodynamically unstable patient. Although clinically significant air emboli are rare, the need to consider the diagnosis is critical. Recognition should prompt treatment with supine or reverse Trendelenburg positioning while providing supplemental oxygen and consideration of hyperbaric oxygen therapy.⁶

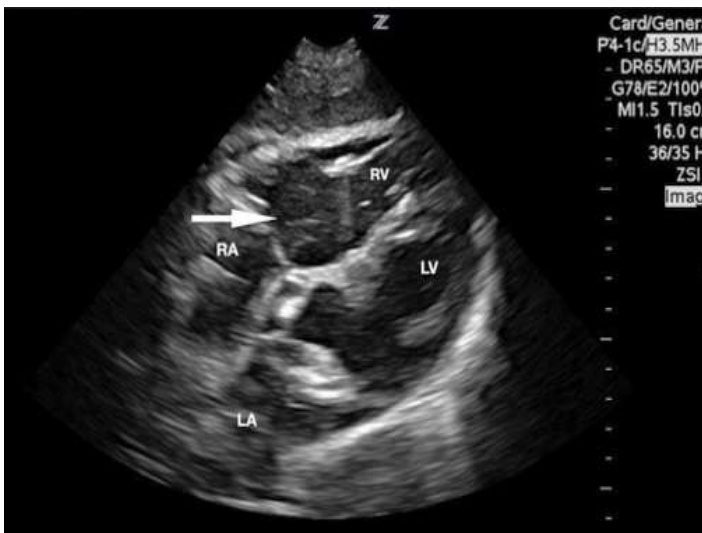


Image 3. Repeat subcostal view approximately 12 minutes later revealed improved, but not resolved, right ventricle (RV) dilatation, significantly decreased density of air bubbles in the RV (white arrow), trace air bubbles in the left ventricle (LV). At this time, the patient's vital signs had normalized and her oxygen requirement was significantly decreased. RA, right atrium; LA, left atrium.

REFERENCES

1. Goldman G, Altmayer S, Sambandan P, et al. Development of cerebral air emboli during Mohs micrographic surgery. *Dermatol Surg.* 2009;35(9):1414-21.
2. Davies JMK, Campbell LA. Fatal air embolism during dental implant surgery: a report of three cases. *Can J Anaesth.* 1990;37(1):112-21.
3. Phillips RJ, Mulliken JB. Venous air embolism during a craniofacial procedure. *Plast Reconstr Surg.* 1988;82(1):155-9.
4. Spence NZ, Faloba K, Sonabend AM, et al. Venous air embolus during scalp incision. *J Clin Neurosci.* 2016;28:170-1.
5. Turgut N, Ali A, Turkmen A, et al. Comparison of surgical approaches in neurosurgical patients experiencing venous air embolism in the sitting position. *West Indian Med J.* 2014;63(4):388.
6. Gordy S, Rowell S. Vascular air embolism. *Int J Crit Illn Inj Sci.* 2013;3(1):73-6.

CPC-EM Capsule

What do we already know about this clinical entity?

Acute air emboli may result in coronary or cerebral infarct, cardiovascular collapse and death without appropriate diagnosis and treatment.

What is the major impact of image(s)?

To our knowledge, these are the first ED ultrasound images to capture air emboli causing hemodynamic compromise as well as real-time clinical improvement with echocardiographic evidence.

How might this improve emergency medicine practice?

EM physicians must consider air embolus when approaching a hemodynamically unstable patient, particularly after procedures involving venous or arterial vasculature.

Address for Correspondence: Leslie A. Bilello, MD, Harvard Medical School, Beth Israel Deaconess Medical Center, One Deaconess Road, 2nd Floor, Boston, MA 02215. Email: lbilello@bidmc.harvard.edu.

Conflicts of Interest: By the CPC-EM article submission agreement, all authors are required to disclose all affiliations, funding sources and financial or management relationships that could be perceived as potential sources of bias. The authors disclosed none. The views expressed in this article are those of the authors and do not necessarily reflect the official policy or position of the Department of the Air Force, Department of Defense, or the U.S. Government.

Copyright: © 2018 Bilello et al. This is an open access article distributed in accordance with the terms of the Creative Commons Attribution (CC BY 4.0) License. See: <http://creativecommons.org/licenses/by/4.0/>

UC DAVIS

The University of California, Davis School of Medicine, Department of Emergency Medicine (EM) is conducting a faculty search for EM physicians in either a clinician/educator or clinician/researcher track. Candidates must be residency trained in EM with board certification/preparation and be eligible for licensure in California. At least one year of post-training clinical experience and/or fellowship training is preferred. Candidates are expected to enter at the Assistant/Associate level, commensurate with experience and credentials. EM faculty members at UC Davis who have preference for night shifts work fewer clinical shifts each month.

The University of California, Davis, Medical Center, one of the nation's "Top 50 Hospitals," is a 613 bed academic medical center with approximately 80,000 emergency department visits annually, including approximately 20,000 pediatric visits. The emergency services facility opened in 2010 and is state-of-the-art. Our program provides comprehensive emergency services to a large local urban and referral population as a level 1 trauma center, paramedic base station and training center. The department also serves as the primary teaching site for a fully accredited EM residency program and eight different EM fellowship programs. Our residency training program began more than twenty years ago and currently has 48 residents. The Department has a separate area for the care of children and is one of the leading centers in the Pediatric Emergency Care Applied Research Network (PECARN).

Salary and benefits are competitive and commensurate with training and experience. Sacramento is located near the northern end of California's Central Valley, close to Lake Tahoe, San Francisco, and the "wine country" of the Napa and Sonoma Valleys. Sports enthusiasts will find Sacramento's climate and opportunities ideal.

Interested candidates should submit a letter outlining interests and experience, and curriculum vitae to: recruit.ucdavis.edu/apply/JPF01809

Erik Laurin MD, Professor and Search Committee Chair (eglaurin@ucdavis.edu)
UC Davis Department of Emergency Medicine
2315 Stockton Blvd., PSSB 2100
Sacramento, CA 95817

The University of California is an affirmative action/equal opportunity employer.





Call for

- REVIEWERS -

Please send your CV and letter
of interest to
editor@westjem.org



Stay tuned

 @menatoxicology

 @MENATOX

 www.menatox.org



MUSCAT
MENATOX 2018
MARCH 21 - 24

CALL FOR SUBMISSIONS

Team Based Learning ■ Podcasts ■ Lectures ■ Small Group Learning and Workshops ■ Oral Boards ■ Simulation ■ Curricula ■ Innovations

CALL FOR REVIEWERS

JETem is an online, open access, peer-reviewed journal-repository for EM educators.

VISIT JETem.org to learn more about submissions or if you're interested in being a JETem reviewer.



Journal of Education & Teaching in Emergency Medicine
A Journal of **CORD**

Residency to the Real World: The Missing Curriculum

AAEM18



Track

Tuesday, April 10, 2018

Learn more by visiting: <http://www.aaem.org/aaem18/attendees/residents>

Fifth Annual Pills and Thrills that Kill!

Toxicology in Review

SAVE THE DATE
Thursday and Friday
April 12-13, 2018

LOCATION

TTUHSC El Paso Paul L. Foster School of Medicine
5001 El Paso Drive, El Paso, Texas 79905
Medical Education Building, Auditorium 1200

Fifth Annual Pills and Thrills that Kill!

Toxicology in Review

Look for our brochure coming soon. For further information or to be placed on the mailing list please contact Diane Huerta at (915) 215-4600 or at toxicology.elp@ttuhsc.edu.

This Activity has been approved for *AMA PRA Category 1 Credit™*.

University Medical Center of El Paso is an approved provider of continuing nursing education by the Texas Nurses Association, an accredited approver by the American Nurses Credentialing Center's Commission on Accreditation.

This activity is eligible for ACPE credit: see final CPE activity announcement for specific details.

Overview and Target Audience:

This program is reviewing new approaches to common toxicological problems, poisoning of high morbidity and mortality, and will point out changes in the general management of the poisoned patient. This educational activity is designed for emergency medicine physicians, internal medicine physicians, pediatric physicians, critical care providers, family medicine physicians, mid-level providers, registered nurses, and pharmacists, particularly those preparing to take the Certification as a Specialist in Poison Information (CSPI) examination.

Jointly Provided by Texas Tech University Health Sciences Center El Paso Paul L. Foster School of Medicine, University Medical Center of El Paso, the West Texas Regional Poison Center, and the Southwest Center for Pediatric Environmental Health.

Topics:

- Exposures in pregnancy
- Pesticides
- Drugs of abuse
- Psychiatric drugs
- Environmental exposures
- Cardiotoxic drugs
- Snakebites

2017 Review Comments:

- "This is my first attendance to this conference and it was extremely educational and applicable. Method of teaching was awesome."
- "Excellent presenters. Such a great conference. They have all been great, but this one tops them."
- "I enjoyed this year's conference. I felt that the topics and information was very informative and useful for the SPI exam."
- "All topics are fantastic. Excellent conference!"

For more information and registration, visit:
<http://elpaso.ttuhsc.edu/ecommerce/Conference/>

**JOIN
CAL/AAEM!**

*Championing
individual physician rights
and workplace fairness*

BENEFITS

- Western Journal of Emergency Medicine Subscription
- CAL/AAEM News Service email updates
- Discounted AAEM pre-conference fees
- And more!

CAL/AAEM NEWS SERVICE

- Healthcare industry news
- Public policy
- Government issues
- Legal cases and court decisions



In collaboration with our official journal

WestJEM Integrating Emergency Care
with Population Health



FACEBOOK.COM/CALAAEM



FOLLOW US @CALAAEM

[HTTP://WWW.CALAAEM.ORG](http://www.calaaem.org)



2018 LEGISLATIVE LEADERSHIP CONFERENCE

JOIN CALIFORNIA ACEP IN SACRAMENTO
TO ADVOCATE ON BEHALF OF YOUR
PATIENTS AND YOUR PRACTICE!

APRIL 17, 2018

WWW.
CALIFORNIA
ACEP.ORG