

UC Irvine

Clinical Practice and Cases in Emergency Medicine

Title

CPC-EM Full Text Issue

Permalink

<https://escholarship.org/uc/item/34s3h544>

Journal

Clinical Practice and Cases in Emergency Medicine, 2(3)

ISSN

2474-252X

Author

Soma, Shashank

Publication Date

2018

License

<https://creativecommons.org/licenses/by/4.0/> 4.0

Peer reviewed

CPC Emergency Medicine

Volume II, Number 3, August 2018

Open Access at www.cpcem.org

ISSN: 2474-252X

Clinical Practice and Cases in Emergency Medicine

In Collaboration with the *Western Journal of Emergency Medicine*

Clinicopathological Cases from the University of Maryland

181 65-year-old Female with Cardiac Arrest and Return of Spontaneous Circulation
Kirk M, Ablaihed L, ZDW Dezman, LJ Bontempo

187 An 18-Year-old Prisoner with Abdominal Pain
Windsor TA, Darby A

Medical Legal Case Reports

193 Patient with a Subarachnoid Headache
Montemayor ET, Long B, Pfaff JA, Moore GP

Case Reports

197 Compartment Syndrome with Rhabdomyolysis in a Marathon Runner
Brinley A, Chakravarthy B, Kiester D, Hoonpongsimanont W, McCoy CE, Lottipour S

200 Blunt Traumatic Cervical Vascular Injury Without any Modified Denver Criteria
Ritter JT, Chadd KK

203 Severe Intracranial Hemorrhage at Initial Presentation of Acute Myelogenous Leukemia
Balmages A, Dinglasan J, Osborn MB

207 Methemoglobinemia Induced By Ingesting Lava Lamp Contents
Funke ME, Fischetti CE, Rodino AM, Shaheen SP

211 Stump Appendicitis
Essenmacher AC, Nash E, Walker SK, Pitcher GJ, Buresh CT, Sato TS

215 Alteplase Causing Cardiac Tamponade in the Setting of Recent Cardiac Pacemaker Placement
Warf CJ, Huecker MR, O'Brien DJ, Bertolotti, DA

219 Fatal Influenza B Myocarditis in a 34-Year-Old Female
Dickey T, Schweir M, Hysell M

Contents continued on page iii



CALIFORNIA ACEP
AMERICAN COLLEGE OF EMERGENCY PHYSICIANS



UC Irvine Health



CALAAEM
CALIFORNIA CHAPTER DIVISION OF THE
AMERICAN ACADEMY OF EMERGENCY MEDICINE

A Peer-Reviewed, International Professional Journal



Are You Ready for the Launch of the FOEM Research Network?

Calling residents, students, researchers, program directors, and pharma reps!

The FOEM Research Network is launching this spring! This state-of-the-art, easy to use website connects researchers and research sites for easily accessible multicenter studies! Users can search by research topic, location, and more to help get their finger on the pulse of the most cutting-edge research in EM. Stay tuned for more information on this momentous achievement!



Find us at frn.foem.org

FOEM
FOUNDATION FOR OSTEOPATHIC
EMERGENCY • MEDICINE

Clinical Practice and Cases in Emergency Medicine

Indexed in PubMed and full text in PubMed Central

In Collaboration with the *Western Journal of Emergency Medicine*

Rick A. McPheeters, DO, Editor-in-Chief
Kern Medical

Manish Amin, DO, Associate Editor
Kern Medical

Mark I. Langdorf, MD, MHPE, Associate Editor
University of California, Irvine School of Medicine

Shadi Lahham, MD, MS, Associate Editor
University of California, Irvine College of Medicine

Shahram Lotfipour, MD, MPH, Managing Associate Editor
University of California, Irvine School of Medicine

Anna McFarlin, MD, Section Editor
Louisiana University Health Science Center- New Orleans

Christopher Sampson, MD, Section Editor
University of Missouri- Columbia

Joel Moll, MD, Section Editor
Virginia Commonwealth University School of Medicine

Scott Goldstein, DO, Section Editor
Sidney Kimmel College of Medicine

Steven Walsh, MD, Section Editor
Einstein Medical Center

Editorial Board

Amin A. Kazzi, MD, MAAEM
The American University of Beirut, Beirut, Lebanon

Anwar Al-Awadhi, MD
Mubarak Al-Kabeer Hospital, Jabriya, Kuwait

Arif A. Cevik, MD
*United Arab Emirates University
College of Medicine and Health Sciences, Al Ain, United Arab Emirates*

Abhinandan A. Desai, MD
University of Bombay Grant Medical College, Bombay, India

Bandr Mzahim, MD
King Fahad Medical City, Riyadh, Saudi Arabia

Barry E. Brenner, MD, MPH
Case Western Reserve University

Brent King, MD, MMM
University of Texas, Houston

Daniel J. Dire, MD
University of Texas Health Sciences Center San Antonio

David F.M. Brown, MD
Massachusetts General Hospital/Harvard Medical School

Edward Michelson, MD
Texas Tech University

Edward Panacek, MD, MPH
University of South Alabama

Erik D. Barton, MD, MBA
Icahn School of Medicine, Mount Sinai, New York

Francesco Dellacorte, MD
Azienda Ospedaliera Universitaria "Maggiore della Carità," Novara, Italy

Francis Counselman, MD
Eastern Virginia Medical School

Gayle Galleta, MD
*Sørlandet Sykehus HF, Akershus
Universitetssykehus, Lorenskog, Norway*

Hjalti Björnsson, MD
Icelandic Society of Emergency Medicine

Jacob (Kobi) Peleg, PhD, MPH
Tel-Aviv University, Tel-Aviv, Israel

Jonathan Olshaker, MD
Boston University

Katsuhiro Kanemaru, MD
University of Miyazaki Hospital, Miyazaki, Japan

Khrongwong Musikatavorn, MD
*King Chulalongkorn Memorial Hospital,
Chulalongkorn University, Bangkok, Thailand*

Leslie Zun, MD, MBA
Chicago Medical School

Linda S. Murphy, MLIS
*University of California, Irvine School of
Medicine Librarian*

Nadeem Qureshi, MD
*St. Louis University, USA
Emirates Society of Emergency Medicine,
United Arab Emirates*

Niels K. Rathlev, MD
Tufts University School of Medicine

Pablo Aguilera Fuenzalida, MD
*Pontificia Universidad Catolica de Chile,
Región Metropolitana, Chile*

Peter A. Bell, DO, MBA
*Liberty University
College of Osteopathic Medicine*

Peter Sokolove, MD
University of California, San Francisco

Robert M. Rodriguez, MD
University of California, San Francisco

Robert Suter, DO, MHA
UT Southwestern Medical Center

Robert W. Derlet, MD
University of California, Davis

Rosidah Ibrahim, MD
Hospital Serdang, Selangor, Malaysia

Samuel J. Stratton, MD, MPH
Orange County, CA, EMS Agency

Scott Rudkin, MD, MBA
University of California, Irvine

Scott Zeller, MD
University of California, Riverside

Steven Gabaeff, MD
Clinical Forensic Medicine

Steven H. Lim, MD
Changi General Hospital, Simei, Singapore

Terry Mulligan, DO, MPH, FIFEM
*ACEP Ambassador to the Netherlands Society of
Emergency Physicians*

Vijay Gautam, MBBS
University of London, London, England

Wirachin Hoonpongmanont, MD, MSBATS
*Siriraj Hospital, Mahidol University, Bangkok,
Thailand*

Advisory Board

Amal Khalil, MBA
UC Irvine Health SOM

Elena Lopez-Gusman
*California ACEP
American College of Emergency Physicians*

Janice Wachtler, BAE, CBA
*American College of Osteopathic Emergency
Physicians*

John B. Christensen, MD
California Chapter Division of AAEM

Lori Winston, MD
*California ACEP
American College of Emergency Physicians
Kaweah Delta Healthcare District*

Mark I. Langdorf, MD, MHPE
UC Irvine Health SOM

Nicholas T. Sawyer, MD, MBA
*California ACEP
American College of Emergency Physicians
University of California, Davis*

Peter A. Bell, DO, MBA
*American College of Osteopathic
Emergency Physicians
Liberty University, College of Osteopathic
Medicine*

Robert Suter, DO, MHA
*American College of Osteopathic
Emergency Physicians
UT Southwestern Medical Center*

Shahram Lotfipour, MD, MPH
UC Irvine Health SOM

Trevor Mills, MD, MPH
*California Chapter Division of AAEM
Northern California VA Health Care*

Jimmy To, BS
Editorial Director

Leila Danishgar, BS
Associate Editorial Director

Tushank Chadha, BS
Marketing Director

Nancy G. Hernandez, BA
Executive Publishing Director

Dana Le, BS
WestJEM Publishing Director

Shashank Somasundaram, BS
CPC-EM Publishing Director

Cassandra Saucedo, BS
Associate Publishing Director

June Casey, BA
Copy Editor

Alissa Fiorentino, BA
WestJEM Staff Liaison

Editorial Staff

Official Journal of the California Chapter of the American College of Emergency Physicians, the American College of Osteopathic Emergency Physicians, and the California Chapter of the American Academy of Emergency Medicine



Available in MEDLINE, PubMed, PubMed Central, Google Scholar, eScholarship, DOAJ, and OASPA.

Editorial and Publishing Office: *WestJEM*/Department of Emergency Medicine, UC Irvine Health, 333 City Blvd, West, Rt 128-01, Orange, CA 92866, USA

Office: 1-714-456-6389; Email: Editor@westjem.org

Clinical Practice and Cases in Emergency Medicine

Indexed in PubMed and full text in PubMed Central

In Collaboration with the *Western Journal of Emergency Medicine*

This open access publication would not be possible without the generous and continual financial support of our society sponsors, department and chapter subscribers.

Professional Society Sponsors

AMERICAN COLLEGE OF OSTEOPATHIC EMERGENCY PHYSICIANS
CALIFORNIA ACEP

CALIFORNIA CHAPTER DIVISION OF
AMERICAN ACADEMY OF EMERGENCY MEDICINE

Academic Department of Emergency Medicine Subscriber

Albany Medical College Albany, NY	INTEGRIS Health Oklahoma City, OK	Robert Wood Johnson University Hospital New Brunswick, NJ	University of Florida, Jacksonville Jacksonville, FL
American University of Beirut Beirut, Lebanon	Kaweah Delta Health Care District Visalia, CA	Rush University Medical Center Chicago, IL	University of Illinois at Chicago Chicago, IL
Arrowhead Regional Medical Center Colton, CA	Kennedy University Hospitals Turnersville, NJ	Southern Illinois University Carbondale, IL	University of Illinois College of Medicine Peoria, IL
Augusta University Augusta GA	Kern Medical Bakersfield, CA	St. Luke's University Health Network Bethlehem, PA	University of Iowa Iowa City, IA
Baystate Medical Center Springfield, MA	Lakeland HealthCare St. Joseph, MI	Stanford/Kaiser Emergency Medicine Residency Program Stanford, CA	University of Louisville Louisville, KY
Beaumont Hospital Royal Oak, MI	Lehigh Valley Hospital and Health Network Allentown, PA	Staten Island University Hospital Staten Island, NY	University of Maryland Baltimore, MD
Beth Israel Deaconess Medical Center Boston, MA	Loma Linda University Medical Center Loma Linda, CA	SUNY Upstate Medical University Syracuse, NY	University of Michigan Ann Arbor, MI
Boston Medical Center Boston, MA	Louisiana State University Health Sciences Center New Orleans, LA	Temple University Philadelphia, PA	University of Missouri, Columbia Columbia, MO
Brigham and Women's Hospital Boston, MA	Madigan Army Medical Center Tacoma, WA	Texas Tech University Health Sciences Center El Paso, TX	University of Nebraska Medical Center Omaha, NE
Brown University Providence, RI	Maimonides Medical Center Brooklyn, NY	University of Alabama, Birmingham Birmingham, AL	University of South Alabama Mobile, AL
Carl R. Darnall Army Medical Center Fort Hood, TX	Maricopa Medical Center Phoenix, AZ	University of Arkansas for Medical Sciences Little Rock, AR	University of Southern California/Keck School of Medicine Los Angeles, CA
Conemaugh Memorial Medical Center Johnstown, PA	Massachusetts General Hospital Boston, MA	University of California, Davis Medical Center Sacramento, CA	University of Tennessee, Memphis Memphis, TN
Desert Regional Medical Center Palm Springs, CA	Mayo Clinic College of Medicine Rochester, MN	University of California Irvine Orange, CA	University of Texas, Houston Houston, TX
Doctors Hospital/Ohio Health Columbus, OH	Mt. Sinai Medical Center Miami Beach, FL	University of California, Los Angeles Los Angeles, CA	University of Texas Health San Antonio, TX
Eastern Virginia Medical School Norfolk, VA	North Shore University Hospital Manhasset, NY	University of California, San Diego La Jolla, CA	University of Warwick Library Coventry, United Kingdom
Einstein Healthcare Network Philadelphia, PA	Northwestern Medical Group Chicago, IL	University of California, San Francisco San Francisco, CA	University of Washington Seattle, WA
Emory University Atlanta, GA	Ohio State University Medical Center Columbus, OH	UCSF Fresno Center Fresno, CA	University of Wisconsin Hospitals and Clinics Madison, WI
Genesys Regional Medical Center Grand Blanc, Michigan	Ohio Valley Medical Center Wheeling, WV	University of Chicago, Chicago, IL	Wake Forest University Winston-Salem, NC
Hartford Hospital Hartford, CT	Oregon Health and Science University Portland, OR	University of Colorado, Denver Denver, CO	Wright State University Dayton, OH
Hennepin County Medical Center Minneapolis, MN	Penn State Milton S. Hershey Medical Center Hershey, PA	University of Florida Gainesville, FL	
Henry Ford Hospital Detroit, MI	Presence Resurrection Medical Center Chicago, IL		

State Chapter Subscriber

ARIZONA CHAPTER DIVISION OF THE
AMERICAN ACADEMY OF EMERGENCY MEDICINE
CALIFORNIA CHAPTER DIVISION OF THE
AMERICAN ACADEMY OF EMERGENCY MEDICINE
FLORIDA CHAPTER DIVISION OF THE
AMERICAN ACADEMY OF EMERGENCY MEDICINE

GREAT LAKES CHAPTER DIVISION OF THE
AMERICAN ACADEMY OF EMERGENCY MEDICINE
TENNESSEE CHAPTER DIVISION OF THE
AMERICAN ACADEMY OF EMERGENCY MEDICINE

UNIFORMED SERVICES CHAPTER DIVISION OF THE
AMERICAN ACADEMY OF EMERGENCY MEDICINE
VIRGINIA CHAPTER DIVISION OF THE
AMERICAN ACADEMY OF EMERGENCY MEDICINE

International Society Partners

EMERGENCY MEDICINE ASSOCIATION OF TURKEY
LEBANESE ACADEMY OF EMERGENCY MEDICINE
MEDITERRANEAN SOCIETY OF EMERGENCY MEDICINE

NORWEGIAN SOCIETY FOR EMERGENCY MEDICINE
SOCIEDAD ARGENTINA DE EMERGENCIAS

SOCIEDAD CHILENO MEDICINA URGENCIA
THAI ASSOCIATION FOR EMERGENCY MEDICINE

To become a *WestJEM* departmental sponsor, waive article processing fee, receive print and copies for all faculty and electronic for faculty/residents, and free CME and faculty/fellow position advertisement space, please go to <http://westjem.com/subscribe> or contact:

Alissa Fiorentino
WestJEM Staff Liaison
Phone: 1-800-884-2236
Email: sales@westjem.org

Clinical Practice and Cases in Emergency Medicine

Indexed in PubMed and full text in PubMed Central

In Collaboration with the *Western Journal of Emergency Medicine*

JOURNAL FOCUS

Clinical Practice and Cases in Emergency Medicine (CPC-EM) is a MEDLINE-indexed internationally recognized journal affiliated with the *Western Journal of Emergency Medicine* (WestJEM). It will offer the latest in patient care case reports, images in the field of emergency medicine and state of the art clinicopathological and medicolegal cases. CPC-EM is fully open-access, peer reviewed, well indexed and available anywhere with an internet connection. CPC-EM encourages submissions from junior authors, established faculty, and residents of established and developing emergency medicine programs throughout the world.

Table of Contents *continued*

- 223 Fatality Following Intentional Ingestion of *Cerbera odollam* Seeds**
R Misek, G Allen, V LeComte, N Mazur
- 227 Cor Triatriatum: Case Report of Emergency Department Diagnosis**
C Halfman, A Thabet, R Blue, T Greenfield
- 231 Simultaneous Multiple Thromboembolic Events in a Postpartum Patient**
I Ghashimi, L Jafarah, A Bakhsh, A Azzazy, A Royashed, A Awad, A Ramadan, G Hashimi, R Alqahtani, A Bakhsh
- 235 Pyogenic Flexor Tenosynovitis by Point-of-care Ultrasound in the Emergency Department**
D Hubbard, S Joing, SW Smith
- 241 Pyometra, an Unusual Case of Acute Abdomen**
KE Nielsen, SA Medeck, DB Brillhart, KJ Mayclin
- 244 Spontaneous Diaphragmatic Hernia**
MD Darocki, A Medak
- 247 Anti-factor Xa Monitoring and Activated Charcoal for a Pediatric Patient With Rivaroxaban Overdose**
BM Carr, DJ Roy, SA Bangh, TR Hellmich, LE Walker
- 251 Nutritional Rickets Presenting as Chronic Episodic Extremity Pain in a 9-year-old with Autism**
N Tripathi, RK Shankar, A Baghdassarian
- 255 Esophageal Perforation After Failed Prehospital Intubation**
K Pomeranz, N Mohr

Images in Emergency Medicine

- 258 Invasive Fungal Sinusitis Minimally Evident by Physical Examination**
M Amin, VS Shankar, LC Castro, P Aguiñiga-Navarrete
- 260 Traumatic Acetabular Protrusion**
W Weber, J Moore, N Cheema
- 262 Accidental Hydrogen Peroxide Ingestion**
RB Sangal, J Bar, B Weiss, M Kelly, T Medina
- 264 Iliopsoas Abscess Due to Nephrolithiasis and Pyelonephritis**
D Frank, B Neal, A Jacobs
- 266 Open Globe: Corneal Laceration Injury with Negative Seidel Sign**
K Couperus, A Zabel, M Oguntoye

Policies for peer review, author instructions, conflicts of interest and human and animal subjects protections can be found online at www.cpcem.org.

Clinical Practice and Cases in Emergency Medicine

Indexed in PubMed and full text in PubMed Central

In Collaboration with the *Western Journal of Emergency Medicine*

Table of Contents *continued*

- 268 **Orbital Compartment Syndrome Following Mechanical Fall**
AE Schwitkis, TL Pollack, SS Torbati
- 270 **“Swirl Sign”: A Case of Abdominal Pain After Roux-en-Y Gastric Bypass Surgery**
C Corsino, H Harper, V Sieg
- 272 **Acute Respiratory Distress**
J Maloy, N Harrison, A Bahl
- 274 **Pre-Retinal Hemorrhage on Point-of-Care Ultrasound**
K Garcia, J Jakubowski, L Archer

Clinical Practice and Cases in Emergency Medicine (CPC-EM) is a open-access Medline-indexed internationally recognized journal affiliated with the *Western Journal of Emergency Medicine* (WestJEM). CPC-EM is distributed electronically to 19,000 emergency medicine scholars. This includes our sponsors California ACEP, the American College of Osteopathic Emergency Physicians, California Chapter of AAEM, and over 83 academic department of emergency medicine subscribers and 8 AAEM State Chapters.



CALL FOR SECTION EDITORS!



- Behavioral Emergencies
- Cardiac Care
- Injury Prevention
- Neuroscience
- Pediatric Emergencies
- Public Health
- Trauma Care

Send your CV and letter of interest
to editor@westjem.org

WestJEM Integrating Emergency Care
with Population Health

CPCEM Clinical
Practice
& Cases

Call for Reviewers!

Please send your CV and letter of interest to
editor@westjem.org

CPCEM Clinical
Practice
& Cases

CALL FOR SUBMISSIONS

- Patient Care Case Reports
- Images in Emergency Medicine
- Indexed in PubMed and PubMed Central

Fully open-access, peer reviewed: CPC-EM is available anywhere with an internet connection at **CPCEM.org**

Clinical Practice and Cases in Emergency Medicine is an internationally recognized companioned journal with the MEDLINE-indexed ***Western Journal of Emergency Medicine***

CPC-EM encourages submissions from junior authors and countries with developing emergency medicine programs

65-year-old Female with Cardiac Arrest and Return of Spontaneous Circulation

Megan Kirk, MD*

Leen Ablaihed, MBBS, MHA[†]

Zachary D.W. Dezman, MD, MS, MS[†]

Laura J. Bontempo, MD, MEd[†]

*University of Maryland Medical Center, Department of Emergency Medicine, Baltimore, Maryland

[†]University of Maryland School of Medicine, Department of Emergency Medicine, Baltimore, Maryland

Section Editor: Joel Moll, MD

Submission history: Submitted March 24, 2018; Revision received May 23, 2018; Accepted June 14, 2018

Electronically published July 18, 2018

Full text available through open access at http://escholarship.org/uc/uciem_cpem

DOI: 10.5811/cpcem.2018.6.38420

[Clin Pract Cases Emerg Med. 2018;2(3):181–186.]

CASE PRESENTATION

A 65-year-old female was transported to the emergency department (ED) at approximately 2:00 AM following a witnessed cardiac arrest. According to the patient's husband, she had been asleep in bed when she awoke suddenly, sat upright, and reached for her albuterol inhaler before "collapsing." He found her to be pulseless and initiated cardiopulmonary resuscitation (CPR) while placing a call to emergency medical services (EMS). On EMS arrival, the patient was unresponsive and continued to receive CPR. She was intubated in the field using a size 7.0 endotracheal tube. Her initial rhythm was pulseless electrical activity (PEA), but she converted to normal sinus rhythm after receiving 1mg of epinephrine intravenously and 15 total minutes of CPR. No further history was available.

Per her husband, her past medical history was notable for "thyroid problems." Her only medications were an albuterol inhaler, recently prescribed by her primary physician, and a multivitamin. She had no known drug allergies. On social history, the patient was not known to drink alcohol, smoke cigarettes, or use other substances. A family medical history and review of systems could not be obtained due to the acuity of her condition.

On examination, the patient was an obese female, intubated, and unresponsive. Her temperature was 37.1 degrees Celsius, blood pressure was 97/65 millimeters Hg, heart rate was 75 beats per minute (bpm). Her body mass index was estimated at 32. She was initially receiving assisted ventilation by EMS, but on examination in the ED she was found to have a spontaneous respiratory rate of 12 breaths per minute with an oxygen saturation of 98% on 40% fraction of inspired oxygen. Her head was atraumatic and normocephalic. Her pupillary exam showed mid-dilated symmetric pupils with sluggish reactivity to light. There was no hemotympanium or Battle's sign. She had no apparent facial droop. An oral endotracheal tube was in place, confirmed with radiography

and audible bilateral breath sounds. She had a full, supple neck without palpable masses, but additional exam was limited by body habitus. On cardiopulmonary exam, her lungs were clear to auscultation bilaterally and her heart had a regular rate and rhythm with no murmurs, gallops, or rubs. The patient's abdomen was soft and nondistended with normal bowel sounds. On neurologic exam, her Glasgow Coma Scale was 3T. She had diffusely decreased muscle tone, and 1+ patellar and brachioradialis deep tendon reflexes. Her musculoskeletal exam was unremarkable for deformity, erythema, or edema. Skin exam did not show any rashes, wounds or other lesions.

Initial electrocardiogram (ECG) (Image 1) showed normal sinus rhythm at a rate of 70 bpm, normal axis, normal intervals and no pathologic t-wave inversions or ST-segment changes. A complete blood count and complete metabolic panel were done (Table 1). Additional laboratory tests, including thyroid studies, were unremarkable except for an elevated lactic acid of 6.9 millimoles/liter (L) (Table 2). A point-of-care echocardiogram was performed, which demonstrated grossly normal heart chamber sizes and systolic function with no pericardial effusion (Image 2). A point-of-care ultrasound of the abdomen and thorax was negative for any intra-abdominal free fluid. There was bilateral lung sliding present and no B lines. An anterior to posterior chest radiograph (CXR) is shown in Image 3.

The etiology of the patient's cardiac arrest was unknown until a further diagnostic test was performed that revealed the diagnosis.

CASE DISCUSSION

The presentation is that of a 65-year-old female who awoke with sudden shortness of breath then went into cardiac arrest, presumably with an initial rhythm of PEA. Given the history provided, a few things stood out.

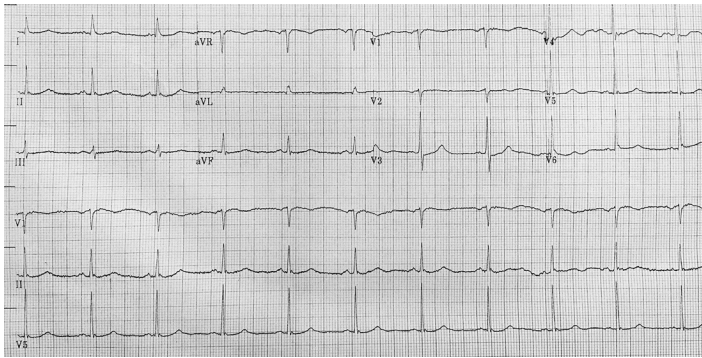


Image 1. Electrocardiogram taken on the patient's arrival to the emergency department.

Waking up with sudden dyspnea can be a symptom of many underlying diseases or conditions. Congestive heart failure is one of the more common causes of nocturnal dyspnea, but the patient had no symptoms or known diagnosis of previous heart failure. In fact she has a primary care doctor whom we know she had seen recently, had no complaints of limb swelling, and she did not have edema on exam when she presented to the ED. Her pro-brain natriuretic peptide was 96 picogram/milliliter and her CXR showed clear costal margins with no signs of pulmonary edema or effusions. Her point-of-care echocardiogram showed no B-lines, overt hypokinesis, or low ejection fraction. All of this points away from heart failure as the cause of her presentation.

Asthma, nocturnal asthma, and chronic obstructive pulmonary disease all cause nighttime wheezing and shortness of breath and respond to inhaled beta-agonists, such as the patient had at home. But this patient had no diagnosis of asthma, was not on chronic inhaled steroids, had no wheezing on exam, and no evidence of hyperinflation of her lungs on her CXR. Although her primary care physician recently prescribed her an albuterol metered-dose inhaler, adult onset asthma is rare and this patient has no known risk factors, except for obesity. Specifically, I am told that she never smoked and has no known allergies.

Pneumonia and upper respiratory infections (URI) with post-nasal drip can cause shortness of breath that might worsen at night. But this patient had no history of coughing or fever and the patient's husband states her health was good. Psychiatric disorders such as anxiety or panic attacks can cause shortness of breath but there is nothing in the history to suggest these conditions, and in the ED these are diagnoses of exclusion. People with large body habitus, obstructive sleep apnea (OSA) or upper airway obstruction often complain of nighttime shortness of breath or wake up feeling suffocated. Although OSA was not mentioned in her history, this obese patient may simply not be diagnosed and this entity should remain on our differential.

Initial presentation in PEA arrest: When emergency providers hear the words PEA arrest, we are trained to go

Table 1. Hematology and chemistry studies.

Hemoglobin	11.7 g/dL
Hematocrit	36.5%
Sodium	140 mmol/L
Chloride	100 mmol/L
Potassium	3.0 mmol/L
Bicarbonate	20 mmol/L
White blood count	7.1 K/mcL
Platelets	193 K/mcL
Blood urea nitrogen	14 mg/dL
Creatinine	1.0 mg/dL
Glucose	291 mg/dL

G, grams; dL, deciliter; mcL, microliter; mmol, millimoles; L, liter; mg, milligrams.

through all the "H's and T's" that cause PEA arrest. There was no history of bleeding, poor oral intake, or evidence to suggest hypovolemia on the patient's lab results. Additionally, her point-of-care cardiac and focused assessment in shock and trauma ultrasound examinations did not show evidence of volume loss. Her labs also showed no evidence of hypokalemia, hyperkalemia or hypoglycemia. She was not hypothermic (temperature of 37.1° C). Hydrogen ion (acidosis) is evident by her gap acidosis of 20, which is explained by an elevated lactate of 6.9 mmol/L. Her hyperlactemia, however, may be secondary to her cardiac arrest and not the primary cause of her illness. Her delta gap (calculated as actual anion gap - 12 + bicarbonate [HCO₃]) is 8. This is small and suggests an uncomplicated metabolic acidosis. Even after working through the MUDPILES mnemonic (Methanol, Uremia, Diabetic/alcoholic/starvation ketoacidosis, Paracetamol/phenformin/paraldehyde, Iron/isoniazid/inborn errors of metabolism, Lactic acidosis, Ethanol/ethylene glycol, salicylates), we return to lactic acidosis. Infection and sepsis are the common causes of hyperlactemia. She did not have any symptoms of infection prior to her arrest, and she doesn't have any signs of overwhelming infection on exam. Her white blood cell count and vital signs are normal, aside from a borderline low blood pressure, and are not consistent with a diagnosis of sepsis. The lactic acidosis is therefore probably entirely due to her cardiac arrest and not an underlying condition.

Hypoxia cannot be excluded because we do not know her oxygen saturation when EMS arrived or after her pulses returned. An arterial blood gas would be helpful, but this was not a part of the case as presented. There was nothing in the history that would concern us for toxic substances ingested (see MUDPILES above). Her exam was inconsistent with a drug toxidrome, and she had no evidence of illicit drug use on her exam such as track marks. The patient had no history or signs of trauma. Looking at the point-of-care cardiac ultrasound, I saw no fluid in the pericardial space

and therefore no pericardial tamponade. I also did not see any signs of right heart strain as the right ventricle was grossly normal in size and the intraventricular septum was not bowed, making a massive pulmonary embolism unlikely. Although it is difficult to see wall motion abnormalities on a point-of-care ultrasound, it was reported that the patient's ejection fraction was only minimally depressed. The patient's ECG showed no evidence of ST-segment elevation or depression, and her initial troponin was not elevated, thereby making an acute myocardial infarction (MI) as the primary cause of the patient's presentation unlikely. Thus, thrombus (both coronary and pulmonary) is unlikely to be the cause of this patient's arrest. Tension pneumothorax was excluded by looking at her CXR. After going through the list of "H's and T's," hypoxia and hydrogen ions remain on the differential of what might have caused her arrest.

The PEA arrest differential can also be divided into etiologies that cause a narrow complex vs. a wide complex rhythm.¹ I was not told if the patient's rhythm upon EMS arrival was narrow or wide. However, using the same logic applied to the "Hs and T's," the common causes of narrow complex PEA (cardiac tamponade, tension pneumothorax, mechanical hyperventilation, pulmonary embolism and acute MI) have already been eliminated. Wide complex etiologies such as hyperkalemia and acute MI have likewise been excluded. An additional cause of wide complex PEA, sodium channel blocker toxicity, has not been disproven but there is nothing in the history to suggest this as the cause. The patient's only reported medication is an albuterol inhaler and there is no known history of cocaine use.

She had return of spontaneous sinus rhythm after EMS intervened. Was the cause of her PEA arrest reversed by one of the interventions provided by EMS? PEA is generally due to a non-cardiac cause, and by addressing the underlying cause a patient can regain his/her pulse. EMS intubated the patient and gave her epinephrine. For the latter, epinephrine is a short-lived drug and its effects should have worn off by the time she reached the ED. For the former, the patient could have been in cardiac arrest due to respiratory failure, which was reversed once she was intubated. A third, and unlikely, possibility is that she was never in arrest at all but had difficult-to-palpate pulses and was in pseudo-PEA.

Given her potential causes of hypoxia, including OSA and upper airway obstruction, we turn to the CXR. There were no signs of pneumothorax or subcutaneous emphysema. There are no lobar infiltrates suggestive of a pneumonia or other intraparenchymal pathology, no signs of hyperinflation, no signs of pulmonary edema ("bat wings"), and no signs of pleural effusions. Looking at her trachea and the placement of the endotracheal tube, we can see it is clearly deviated to the right. There is a large soft-tissue mass in the left side of the neck that extends into the thoracic inlet causing the trachea to shift to the right. This finding made me very concerned for an upper airway mass that compressed her trachea. This could worsen when the patient is supine and sleeping and could have caused the patient's

Table 2. Additional laboratory values.

Total protein	6.3 g/dL
Albumin	3.6 g/dL
Direct bilirubin	<0.2 mg/dL
Total bilirubin	0.2 mg/dL
Aspartate aminotransferase	39 u/L
Alanine aminotransferase	25 u/L
Alkaline phosphatase	73 u/L
Lipase	46 u/L
Pro-brain natriuretic peptide	96 pg/mL
Thyroid stimulating hormone	1.18 u/mL
Troponin I	< 0.01 ng/mL
Lactate	6.9 mmol/L

G, grams; dL, deciliter; mg, milligrams; u, units; L, liter; pg, picograms; mL, milliliters; ng, nanograms; mmol, millimoles.

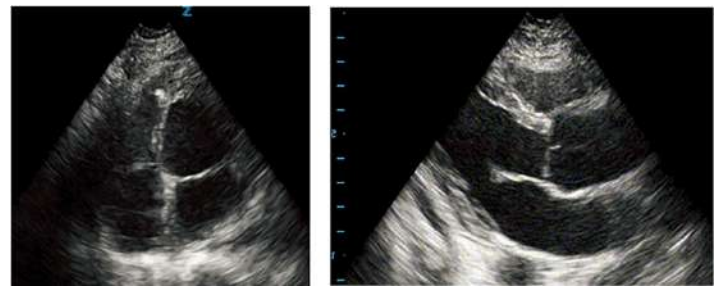


Image 2. Point-of-care echocardiogram with an apical four-chamber view (left) and a parasternal long-axis view (right).

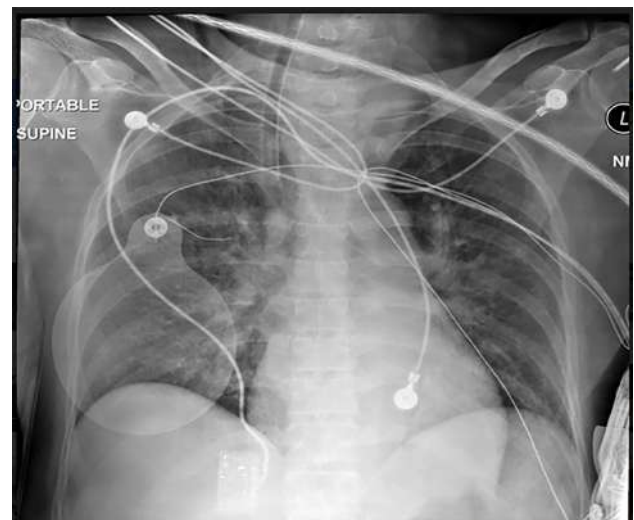


Image 3. Anterior-posterior bedside chest radiograph.

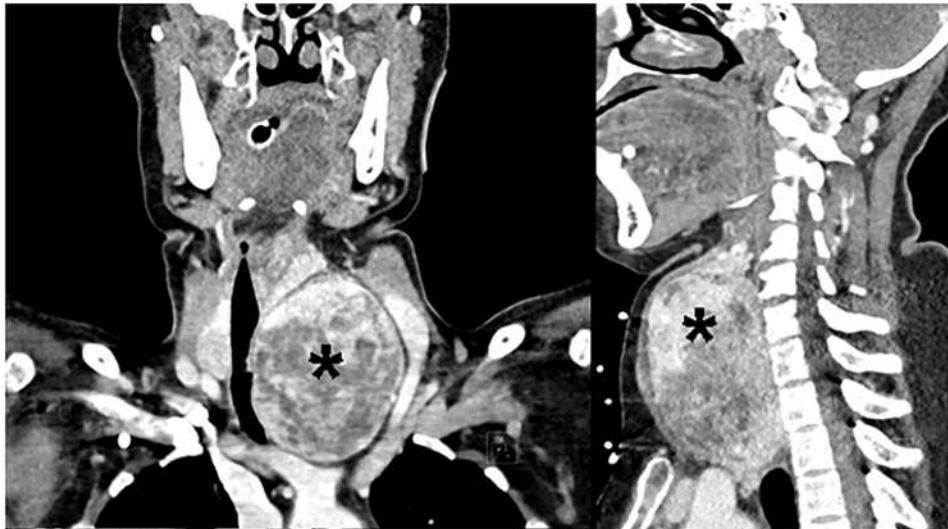


Image 4. Computed tomography of neck and soft tissues showing a large substernal goiter (*) with tracheal compression (frontal plane on left, sagittal plane on right).

cardiac arrest. This would be reversed by establishing an airway with a rigid endotracheal tube by EMS. Here's the question: What is the etiology of the mass causing this radiograph finding?

The differential diagnosis of tracheal deviation is divided into the following:

- Pulmonary causes:
 - Deviated towards the diseased side: atelectasis, agenesis of the lung, pneumonectomy, and pulmonary fibrosis
 - Deviated away from the diseased side: pneumothorax, lung mass, pleural effusion
 - All of these conditions are unlikely given the imaging provided.
- Other causes:
 - Retrosternal goiter, mediastinal masses, tracheal masses, thyroid cancer, and kyphoscoliosis.

Putting all the information together, we have an obese female who presented after a PEA arrest. The arrest appears to have been due to hypoxic respiratory failure and was reversed by intubation. Her history was notable for intermittent shortness of breath for months and a “thyroid problem.” Her medical history, exam, and ED workup did not support a cardiac or pulmonary condition as the primary cause of her presentation. She did have an elevated lactate, but the other information provided in the case does not support a diagnosis of sepsis. Her CXR reveals a neck mass with tracheal deviation. Neck masses generally originate from the thyroid, yet this patient had normal thyroid hormone levels. Some causes of euthyroid masses include thyroid cancer, uni- or multinodular goiter, diffuse goiter, autoimmune thyroiditis, de Quervain's thyroiditis, and Riedel's thyroiditis.

The question I now asked myself was this: Can a large goiter or thyroid mass have an initial presentation of hypoxia

and upper airway obstruction? The answer, after a quick review of the literature, was, “Yes!” There are many case reports in the literature that discuss similar presentations of patients presenting with sudden extreme upper airway obstruction requiring emergent intubation.²⁻⁸ Therefore, the test of choice would be a computed tomography (CT) of the neck and chest revealing what I expect would be a goiter causing tracheal deviation and obstruction.

CASE OUTCOME

The diagnostic test ordered was a CT of the soft tissues of the neck, which demonstrated a large substernal thyroid goiter with significant tracheal compression (Image 4). The patient had an overall unremarkable physical exam and laboratory findings due to EMS stenting open the obstructed trachea by placing an endotracheal tube in the field. The profound rightward tracheal deviation on CXR indicated a space-occupying lesion in the neck and chest, prompting further imaging of the neck. Ultimately, the patient was found to have a severe degree of hypoxic encephalopathy. She was removed from ventilatory support and expired on her fourth hospital day. Later chart review revealed she had been diagnosed with a multinodular thyroid goiter 10 years ago but had declined any workup and had been lost to follow-up. Her recent prescription of an albuterol inhaler suggests she had been experiencing shortness of breath but did not attribute it to her large goiter.

RESIDENT DISCUSSION

Thyroid goiter is a common problem worldwide, with iodine deficiency being responsible for the plurality of cases. Within the United States and other “iodine-replete” countries, multinodular goiter, chronic autoimmune thyroiditis

(Hashimoto's), and Grave's disease are the more likely etiologies.⁹ Multinodular goiter, the cause of our patient's pathology, is generally due to an unclear genetic predisposition and worsens with age. Chronic autoimmune thyroiditis is caused by excessive stimulation of the thyroid gland by thyroid-stimulating hormone (TSH). Grave's disease is attributed to over-activation of the TSH receptor by antibodies. Women are much more likely than men to develop a thyroid goiter.⁹⁻¹²

Approximately 10-20% of goiters are ultimately malignant in nature regardless of location.^{9,10} Few cause tracheal compression or obstruction. Large, rapidly growing, or posteriorly-positioned goiters are more likely to result in obstructive symptoms. Historical factors worrisome for progressive obstruction include longstanding goiter, cough, dysphagia, hoarse voice, or superior vena cava syndrome (SVCS).¹¹⁻¹³ Exertional dyspnea is frequently experienced when tracheal diameter is compressed to less than eight millimeters, and stridor manifests when the lumen is less than five millimeters.¹⁴ Positional changes, such as reaching forward, bending at the waist and lying supine, can provoke symptoms of obstruction.¹³

Compressive thyroid goiters are generally managed surgically on a non-emergent basis, although our case demonstrates they can cause complete airway loss.^{14,15} Partial airway obstruction can rapidly progress to complete obstruction if there is an additional insult, including even mild edema from an URI. Thyroid tissue is also especially vascular and nodules are prone to expansion if bleeding occurs within the gland, which can rapidly increase the size of a previously slow-growing goiter.¹⁴ Emergent airway management is the primary treatment in all of these scenarios. Passage of an orotracheal tube is ideal for such patients (as performed by EMS in our case), but generally a somewhat smaller caliber tube is required than what would be expected for an adult of a given size.^{14,16} Caution should be used when considering an emergency surgical airway (cricothyrotomy) as these patients are likely to have marked tracheal deviation and an overlying vascular mass complicating the procedure.

Complete tracheal compression resulting in a (likely hypoxic) PEA arrest is an uncommon presentation of a common illness (thyroid goiter), but demonstrates that compressive mediastinal masses can drastically impact a patient's health. Beyond the thyroid, other origins of compressive mediastinal mass to consider in such a patient are thymoma, teratoma, lymphoma, and the aorta.

FINAL DIAGNOSIS

Hypoxic cardiac arrest secondary to tracheal compression from substernal thyroid goiter.

KEY TEACHING POINTS

- Thyroid goiter is more common in women and in the U.S., it is most frequently attributed to multinodular goiter, Grave's disease, or chronic autoimmune thyroiditis.
- Laboratory testing is largely unhelpful in euthyroid goiter.

- When goiters develop substernally they can cause significant tracheal compression plus the following:
 - Dyspnea on exertion
 - Cough
 - Dysphagia
 - Dysphonia
 - Stridor
 - SVCS
 - Tracheal deviation/luminal narrowing
 - Respiratory arrest (rarely)
- Management is generally surgical excision.
- Endotracheal intubation instead of cricothyrotomy is the preferred means of airway management in these patients.

Documented patient informed consent and/or Institutional Review Board approval has been obtained and filed for publication of this case report.

Address for Correspondence: Zachary D.W. Dezman, MD,MS, MS, University of Maryland, Department of Emergency Medicine, 110 S Paca Street, 6th Floor, Suite 200, Baltimore, MD 21201. Email: zdezman@som.umaryland.edu.

Conflicts of Interest: By the CPC-EM article submission agreement, all authors are required to disclose all affiliations, funding sources and financial or management relationships that could be perceived as potential sources of bias. The authors disclosed none.

Copyright: © 2018 Kirk et al. This is an open access article distributed in accordance with the terms of the Creative Commons Attribution (CC BY 4.0) License. See: <http://creativecommons.org/licenses/by/4.0/>

REFERENCES

1. Littman L, Bustin DJ, Haley MW. A simplified and structured teaching tool for the evaluation and management of pulseless electrical activity. *Med Princ Pract.* 2014;23(1):1-6.
2. Ket S, Ozbudak O, Ozdemir T, et al. Acute respiratory failure and tracheal obstruction in patients with posterior giant mediastinal (intrathoracic) goiter. *Interact Cardiovasc Thorac Surg.* 2004;3(1):174-5.
3. Bayhan Z, Zeren S, Ucar BI, et al. Emergency thyroidectomy: due to acute respiratory failure. *Int J Surg Case Rep.* 2014;5(12):1251-3.
4. Altinsoy B, Altintas N, Ozyurt S. Unexpected etiology in elderly patient presenting with acute hypercapnic coma. *Hong Kong J Emerg Med.* 2013;20(4):251-3.
5. Lei WH, Shao CX, Xin J, et al. Multinodular goiter spontaneous hemorrhage in ESRD patients results in acute respiratory failure: a case report. *Medicine (Baltimore).* 2016;95(6):e2777.

6. Garingarao CJ, Afonuevo-Cruz C, Gasacao R. Acute respiratory failure in a rapidly enlarging benign cervical goitre. *BMJ Case Reports*. 2013;2013:bcr2013200027.
7. Ioannidis O, Dalampini E, Chatzopoulos S, et al. Acute respiratory failure caused by neglected giant substernal nontoxic goiter. *Arq Bras Endocrinol Metabol*. 2011;55(3):229-32.
8. Tunc M, Sazak H, Karlilar B, et al. Coexistence of obstructive sleep apnea and superior vena cava syndromes due to substernal goitre in a patient with respiratory failure: a case report. *Iran Red Crescent Med J*. 2015;17(5):e18342.
9. Moten AS, Thibault DP, Willis AW, et al. Demographics, disparities, and outcomes in substernal goiters in the United States. *Am J Surg*. 2016;211(4):703-9.
10. Sahbaz NA, Tatal F, Aksakal N, et al. Cancer frequency in retrosternal goiter. *Am Surg*. 2017;83(12):1390-3.
11. Benbakh M, Abou-elfadl M, Rouadi S, et al. Substernal goiter: Experience with 50 cases. *Eur Ann Otorhinolaryngol Head Neck Dis*. 2016;133(1):19-22.
12. Hernandez Q, Soria T, Rodriguez JM, et al. Substernal goiter: clinical experience of 72 cases. *Ann Otol Rhinol Laryngol*. 1999;108(5):501-4.
13. Banks CA, Ayers CM, Hornig JD, et al. Thyroid disease and compressive symptoms. *Laryngoscope*. 2012;122(1):13-6.
14. Sajid B, Rekha K. Airway management in patients with tracheal compression undergoing thyroidectomy: a retrospective analysis. *Anesth Essays Res*. 2017;11(1):110-6.
15. Raffaelli M, De Crea C, Ronti S, et al. Substernal goiters: incidence, surgical approach, and complications in a tertiary care referral center. *Head Neck*. 2011;33(10):1420-5.
16. Shaha AR. Substernal goiter: what is in a definition? *Surgery*. 2010;147(2):239-40.

An 18-Year-old Prisoner with Abdominal Pain

T. Andrew Windsor, MD*
Anna Darby, MD, MPH†

*University of Maryland School of Medicine, Department of Emergency Medicine,
Baltimore, Maryland

†Los Angeles County + USC Medical Center, Department of Emergency Medicine, Los Angeles, California

Section Editor: Rick A. McPheeters, DO

Submission history: Submitted January 1, 2018; Revision received March 22, 2018; Accepted March 28, 2018

Electronically published June 25, 2018

Full text available through open access at http://escholarship.org/uc/uciem_cpccem

DOI: 10.5811/cpcem.2018.3.37438

[Clin Pract Cases Emerg Med. 2018;2(3):187–192.]

CASE PRESENTATION (Anna Darby, MD, MPH)

An 18-year-old male presented to the emergency department (ED) with a complaint of severe abdominal pain for three days along with painful urination, vomiting, diarrhea and subjective fever and chills. The patient reported brief, severe, colicky episodes of mid and left upper quadrant (LUQ) abdominal pain that radiated to his testicles. He vomited several times because of the pain, which he stated began suddenly while he was lying down. Notably, the patient had recently got over a diarrheal illness a few days prior, followed by constipation, and had recurrence of one loose stool on the day of presentation. He denied any flank pain or back pain, and had never experienced anything like this current illness before.

The patient had no prior medical or surgical history, and had no known family history. His family lived in Honduras, but the patient was currently incarcerated. He was previously a one-pack-per-day smoker, drank alcohol one to two times per month, but denied drug use. Review of systems was negative for weight loss, headaches, chest pain, shortness of breath, melena, hematemesis, rashes, or joint swelling.

The vital signs were as follows: temperature 37.0°C orally, pulse 103 beats per minute, respiratory rate 11 breaths per minute (bpm), blood pressure 122/67 mmHg, and oxygen saturation 100% on room air. Physical examination revealed an alert young man intermittently doubled over in pain with spontaneous resolution. The heart was tachycardic and regular without murmurs, rubs or gallops. The lungs were clear bilaterally with normal work of breathing and no wheezes, rhonchi or rales. His abdomen was soft and non-distended with normoactive bowel sounds, but he demonstrated diffuse tenderness and guarding to palpation. He had no midline or costovertebral angle tenderness, and no ecchymoses were present on inspection of his back. His skin was warm, dry and without any obvious rashes. His neurological examination was grossly intact throughout. The patient was uncircumcised, and his right testicle was lying higher than his left, but neither was tender or swollen. No masses or inguinal hernias were appreciated in the groin.

Laboratory studies were ordered (Tables 1-3), and a point-of-care focused assessment with sonography for trauma (FAST) exam and gallbladder ultrasound were normal. The patient had a formal scrotal ultrasound performed. (Image 1).

The patient's pain was initially well controlled with hydrocodone/acetaminophen and non-steroidal anti-inflammatories; however, as more laboratory and imaging studies resulted, the patient continued to have intermittent pain episodes requiring morphine for analgesia. After two to three hours, the pain crises appeared more severe and the patient became more tachypneic to 18 bpm. It was at that point that an additional study was ordered, and the diagnosis was subsequently made.

CASE DISCUSSION (T. Andrew Windsor, MD)

Often, as we work through a differential we start broadly and narrow our way through our previously great ideas that have seemingly gone south as we blend the story together with our objective data. I'll walk you through my process. To start, let's go back and summarize the case: an 18-year-old male with three days of intermittent abdominal pain that radiated to the testicles. That gave me some initial confidence based on pattern recognition, until I kept reading and saw that the patient had no flank or back pain. That would make something simple and common like a kidney stone unlikely.

He did have a recent diarrheal illness, and on the day of presentation he had vomiting and diarrhea, although he

Table 1. Complete blood count results for patient presenting with severe abdominal pain.

White blood cells	18.1K/mL	Reference (Ref.) 4-10K/mL
Hemoglobin	14.8 g/dL	Ref. 13-17 g/dL
Hematocrit	43.10%	Ref. 40-52%
Platelets	232K/mL	Ref. 150-400K/mL

Table 2. Serum chemistry results

Sodium	139 mEq/L	Ref. 135-145 mEq/L
Potassium	4.3 mEq/L	Ref. 3.5-5 mEq/L
Chloride	99 mEq/L	Ref. 95-105 mEq/L
Bicarbonate	27 mEq/L	Ref. 23-29 mEq/L
Blood urea nitrogen	10 mg/dL	Ref. 8-21 mg/dL
Creatinine	0.64 mg/dL	Ref. 0.8-1.3 mg/dL
Glucose	119 mg/dL	Ref. 65-110 mg/dL
Total protein	7.6 g/dL	Ref. 6-8 g/dL
Albumin	4.6 g/dL	Ref. 3.5-5 g/dL
Alkaline phosphatase	68 IU/L	Ref. 50-100 IU/L
Alanine aminotransferase	27 IU/L	Ref. 5-30 IU/L
Aspartate aminotransferase	33 IU/L	Ref. 5-30 IU/L
Total bilirubin	0.4 mg/dL	Ref. 0.1-1.2 mg/dL
Direct bilirubin	0.1 mg/dL	Ref. 0.1-0.4 mg/dL
Magnesium	2.0 mEq/L	Ref. 1.5-2 mEq/L
Lactate	2.0 mmol/L	Ref. 0.5-1 mmol/L

Ref, reference.

Table 3. Urinalysis results

Color/clarity	Straw, clear	Ref. yellow, clear
Specific gravity	1.028	Ref. 1.005-1.025
pH 6.5	6.5	Ref. 4.5-8
Protein	Trace	Ref. Negative
Glucose	Negative	Ref. Negative
Ketones	Negative	Ref. Negative
Bilirubin	Negative	Ref. Negative
Urobilinogen	0.2 EU/dL	Ref. 0.1-1 EU/dL
Leukocytes	Negative	Ref. Negative
Nitrite	Negative	Ref. Negative
White blood cells	0-3/High powered field (HPF)	Ref. 0-3/HPF
Red blood cells	11-25/HPF	Ref. 0-3/HPF
Bacteria	None	Ref. None
Squamous epithelial cells	16-30/Low powered field (LPF)	Ref. 0-5/LPF
Hyaline casts	0-4/LPF	Ref. 0-4/LPF

Ref, reference.

had also apparently had constipation for about three days prior to this. He was an occasional drinker, but I doubt he had been drinking much in jail unless it was something like “toilet wine.” While I know he was in jail and originally from Honduras, I don’t know how long he had been incarcerated

or when he was last in his home country. Presuming this presentation was in the United States, I will assume he’d been in jail for less than a year since he was only 18. While it is not impossible that he had been previously or recently exposed to a disease such as tuberculosis, my feeling is that disseminated disease would be less likely based on his previously well state.

At the University of Maryland, one mnemonic that many of us teach to our students and interns for getting complete histories regarding pain is OLDCAAAR (Onset Location Duration Character Associated symptoms Aggravating factors Alleviating factors Radiation), and I think it’s good to go back to this to get an idea of his description of the abdominal pain. Its Onset occurred about three days ago, suddenly, at rest, after his diarrheal illness stopped and his constipation started. The Location was described in the LUQ and mid-abdomen. I don’t know if that means mid-upper abdomen as in the epigastrium, or mid-abdomen as in the periumbilical region. As you’ll see, those can mean very different things. The Duration was brief and the Character was severe and colicky but self-resolving. It was Associated with vomiting, diarrhea and dysuria (which is somewhat curious), fever and chills, as well as tachypnea. I don’t really know if anything in particular Aggravated the pain, as this information wasn’t included in the history, and it seemed to get better on its own without any particular Alleviating factors. The pain Radiated to the testicles.

His laboratory studies showed a normal chemistry, a complete blood count only remarkable for a leukocytosis, and a urine with some microscopic hematuria and a fair amount of squamous epithelial cells. I was informed that the patient was uncircumcised, which could possibly be the cause of the higher-than-expected number of squamous cells. There was trace urinary protein, but for now I think this is of uncertain significance.

On exam, we see that the patient is afebrile but mildly tachycardic, which is not surprising given the situation and his pain. He has diffuse abdominal tenderness with some guarding, but he does not seem particularly peritoneal. No back pain or costovertebral angle tenderness was noted, so it is less likely to be a renal or urologic problem. About 60% of men will have the left testicle lie lower than the right, so in the absence of tenderness or swelling that is a normal exam finding. Cremasteric reflex should, however, be verified.

The imaging studies presented, including his ultrasounds, were normal. I’m not 100% sure why he had a right upper quadrant ultrasound when his complaint was LUQ and mid-abdominal pain, but perhaps it was done for the sake of completeness. I saw no gallstones, gallbladder wall thickening, or pericholecystic fluid on the images I was provided. Both testicles have normal flow, so it is unlikely to be torsion. It is important to note that intermittent testicular torsion can have a normal flow when the testicles are not actively torsed, but given that his symptoms worsened prior to presentation, this diagnosis is unlikely.

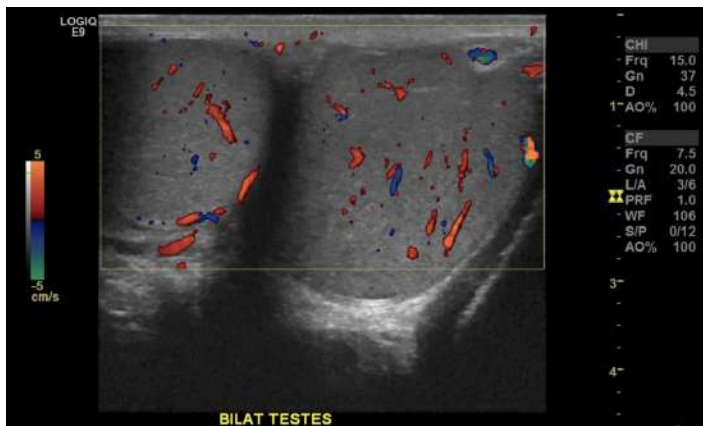


Image 1. The patient's normal scrotal ultrasound.

I'm still left with a few things I want to know. For instance, what is up with the dysuria? Does eating make the pain worse? Are his pulses normal, does he have any organomegaly, are there any other laboratory studies that were sent, and when did he go to jail? As it is in real-life emergency, we are not always provided with every bit of information we would like, but working with what we have we can start with a differential.

In general, with abdominal pain we usually think of quadrants (Image 2), and in this case we're also dealing with scrotal pain, which I'll consider a "fifth" quadrant, if you will. Based on location of the pain, we can form a basic differential diagnosis with which to start. Now, just from the nature of this being a clinicopathological case (CPC), there are a few things we can knock off the list, including simple stomach issues such as gastroenteritis. However, when considering a diagnosis, especially with abdominal pain, it's important to be sensitive to the fact that there are certain things that tend to be more common in different age groups. For example, it's very unlikely a child would have diverticulitis; on the other hand, you would very probably pause to consider aortic pathology before diagnosing grandpa with a first-time kidney stone.

Our patient falls between the child and adult age groups, so we'll have to keep that in mind. There are a few things that we can eliminate rapidly. His blood work points away from anything metabolic, and his urine is negative for infection. Although he has mid-abdominal pain, nothing points towards early appendicitis. There are no hernias on exam, and as before no flank pain for a renal stone, even though there is radiation to the scrotum. We already discussed that the testicular exam was normal with normal flow on ultrasound. It would be unlikely for the symptoms to be due to a psoas abscess, and he would be very young for diverticulitis. Although the patient has become more tachypneic, he has normal lung sounds. I think it is unlikely to be a primary lung source; instead, it could have been from pain or something pushing up on his diaphragm.

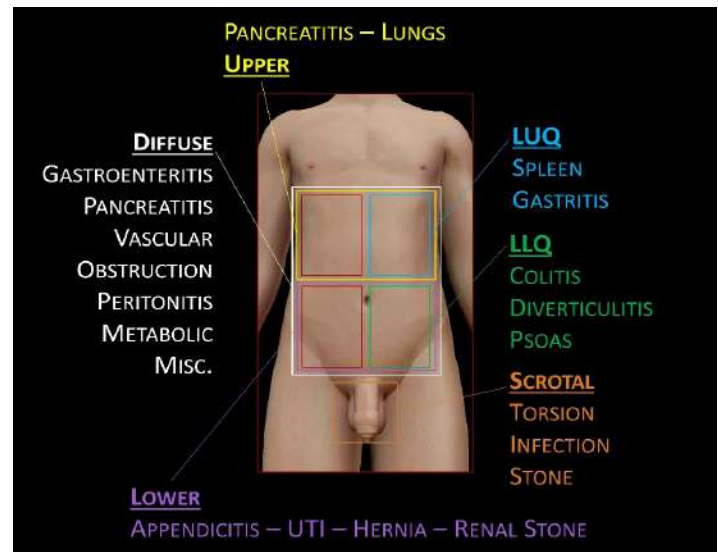


Image 2. Example differential diagnosis for abdominal pain based on location of the pain.¹

LUQ, left upper quadrant; LLQ, left lower quadrant; MISC, miscellaneous; UTI, urinary tract infection.

Since we've narrowed down a bit, let's focus in and look at individual features again. To recap, the patient has LUQ and mid-abdominal pain that radiates to the testicles and he has diffuse tenderness on exam. The way we feel pain in the abdomen is by several different mechanisms, including somatic pain, visceral pain and referred pain. The different areas involved probably reflect a bit of all three. Somatic pain is generally experienced from irritation of the parietal peritoneum. That pain is well localized – as in his LUQ pain, for example.

Visceral pain, on the other hand, is vague, deep and poorly localized, and is often felt in conjunction with or referred from an area of embryonic development. This is why you can have diffuse abdominal pain before localizing to the right lower quadrant in something like appendicitis. Referred pain is felt in a remote place from the source, for instance, renal colic causing pain in the groin; it often happens because nerves providing sensory information from different areas converge at their entry to the spinal cord. Our patient has pain that radiates to the testicles; so when we think about how the scrotum is innervated, we know there are both somatic and sympathetic nerves that do that job.

As opposed to the somatic nerves, which originate from the upper lumbar spine, the sympathetic nerves can be more visceral, cover a larger area and interact with other plexuses. Several organs have been associated with testicular pain, including the stomach, pancreas, kidneys/ureters and intestines. Considering the stomach, the patient does have nausea and vomiting, and it is in the right anatomic area for the pain; but unless the patient had perforated an ulcer, I don't see why he would have diffuse tenderness, and he is neither

febrile nor seemed peritoneal on exam. So, I'm taking that off my list. The pancreas is also in the right anatomical area, the symptomatology was reasonable, and he does drink. However, most case reports of pancreatic pain referred to the testicles is associated with scrotal edema,² the thought being that pancreatic fluid drains down through the retroperitoneal space, and his testicles were not tender. So that's off my list.

Earlier we established that there is unlikely to be direct involvement of the urinary system and there are no kidney issues, so those are gone as primary sources. All that's left is the intestines, and a lot of the patient's symptoms make sense for this. The way his pain is described makes it hard to localize, and he had the recent diarrheal illness followed by constipation, then nausea and vomiting. To me, this progression points to a possible obstructive process. While diffuse tenderness isn't diagnostic, it does fit. What I had a hard time wrapping my head around was the dysuria. Was this from ureteral or bladder irritation, or something else?

Going back to our basic list, I think I would be remiss to ignore the spleen for someone who presents with LUQ pain, even though the patient's symptoms don't really fit. There was no report of any trauma, and the colicky pain would be unusual for splenic pathology. I wasn't made aware of any organomegaly, but that would be important to check for. That being said, there is a rare condition called "wandering spleen" due to laxity in the suspensory ligaments. Other than possibly causing migrating pain, the pattern still doesn't fit this diagnosis. Furthermore, that condition does not present acutely.

What about vascular issues? The patient experiences intense waves of pain; so could this be some sort of ischemic process? Maybe there's an underlying structural abnormality or vasculitis? What points away from ischemic pain, within the limited data we have, is that the patient is young, he had a normal lactate, at least initially, and he had no pain out of proportion to exam. It would have to have been transient ischemia if at all. Based on the patient's pain, the most likely culprits would be upper vascular branches such as the celiac, superior mesenteric artery (SMA) or renal artery, and if involved at all, the symptoms would most likely be from spasm or compression. Two examples include median arcuate ligament syndrome (MALS),³ which is caused by compression of the celiac trunk by the median arcuate ligament, and nutcracker syndrome, which is caused by compression of the renal vein from the SMA.⁴ MALS tends to be more constant, have less of a sudden onset, worsen with food, etc. Nutcracker syndrome is more commonly associated with gross hematuria, and because the left gonadal vein comes off of the renal vein, I would expect the testicular exam to have shown a varicocele or altered flow on the ultrasound.

Given the patient's age, it would be extremely unlikely to be an abdominal aortic aneurysm or dissection. If we consider inherent vascular issues such as vasculitis, we'd be looking for one that could cause a constellation of symptoms consistent with the patient's presentation. There are a number of possible

small and large vessel vasculitides such as Takayasu's or lupus mesenteric vasculitis, but no syndrome fits nicely except for one in particular, Henoch-Schönlein purpura (HSP).

HSP, also known as IgA vasculitis, fits with some things from our patient's presentation, such as his colicky abdominal pain as well as a recent gastrointestinal (GI) illness, although we don't know the specific source. The patient had the expected microscopic hematuria and proteinuria, and congruent with HSP (and unlike other purpuric diseases), he had normal platelets. Unfortunately, the patient doesn't have other usual symptoms like arthritis or a rash. However, not everyone presents like this, and HSP may first have atypical symptoms before the typical ones such as rash manifest.⁵

Overall I'm not sure that we can completely exclude a vascular problem yet, so we'll move on to some miscellaneous causes because I'm beginning to feel confident that this was more directly related to the bowels than anything else. Because the patient is a prisoner, you'd have to at least consider an ingested or inserted foreign body, but nothing in his history suggests that. Could he have had a toxic bite or exposure to something? Possibly, but without geographical information available to me while looking at the case, it would be hard to pinpoint this. He did drink, and he was 18, so it would be remiss not to consider a toxic alcohol ingestion; however, his metabolic panel was normal and he doesn't really fit a toxidrome. He has no signs of trauma on exam, and I don't get any indication that he's malingering.

Since this is a CPC, we'll briefly address a couple of zebras. There have been case reports of pulmonary embolism presenting with abdominal pain,^{6,7} but he is not hypoxic, he has no leg swelling, and he does not have any risk factors. Furthermore, the pain shouldn't be colicky. I'd also expect that if he had upper quadrant pain from possible lung infarct-related irritation of the diaphragm, it would radiate to the shoulder rather than the testicles. The possibility of acute intermittent porphyria (AIP) was something that I entertained for a while because it fits the picture of having abdominal pain with dysuria; but he did not have any of the neurologic findings or psychiatric symptoms, and the attacks from AIP tend to result in more constant pain.⁸ Furthermore, the specific finding of AIP is rarely an ED diagnosis unless you could do an on-the-spot porphobilinogen test, which isn't available in our department. I suppose, though, you could take the urine sample to a windowsill and look for darkening after ultraviolet light exposure.

I think we have narrowed down the pain source to vascular or bowel pathology. With the diarrhea a presenting feature, an infectious cause is possible. However, the patient does not have any fevers, and has not had any bloody or mucous stool. His diarrhea had improved and there was no reported recent travel; so he does not fit any of the patterns of the well-known infectious diarrheas. What does fit, because of the severe waves of pain, is some sort of obstructive process. I like the way intussusception, although rare in an adult, more closely fits the

patient's presentation, more so than something like a volvulus or a functional problem. The patient experienced brief, severe episodes that self-resolved, which could be due to telescoping of bowel in and out. Although the most common location is usually ileocecal, and one might expect right lower quadrant pain, the pain from intussusception can occur anywhere, and as previously discussed the pain sensations we experience can be vague or poorly localized if visceral. Furthermore, an obstruction anywhere can cause pain upstream due to dilation. We typically think of "currant jelly stool" as part of the classic triad of intussusception, along with vomiting and abdominal pain. But keep in mind, "classic" in medicine often actually means "you probably won't see it." That triad is present in only around a third of patients, and bleeding is a late finding, less common in adults.

Does it fit? I think it does, especially the severe, brief nature, and the fact that it followed a diarrheal illness. What I'm still having a hard time fitting into the picture is the dysuria and hematuria. I suspect this would either have been reactive or from a more widespread condition like vasculitis. Intussusception usually has a lead point, so absent cancer or previous scar tissue, I went back to my list of vasculitides as a possible explanation, and HSP kept coming up with symptoms similar to our patient's. It is well known to cause intussusception in kids, and I found a number of reports⁹⁻¹⁰ of HSP presenting as intussusception in adults.

That being said, my test of choice is computed tomography (CT) of the abdomen and pelvis as there is no way to avoid scanning this patient based on his worsening presentation. I'm confident he has an obstructive bowel process. Any other diagnosis would be one of exclusion after making sure there isn't a mechanical cause. Some might suggest starting with an ultrasound and I like that idea; however, it would depend on his habitus, and if the ultrasound was inconclusive a CT would follow anyway. I only have enough information to diagnose intussusception, not HSP, but he should have close surveillance for HSP with a thorough skin exam, and a high index of suspicion. My final diagnosis is intussusception, with CT as the test of choice.

CASE OUTCOME (Anna Darby, MD, MPH)

In order to provide appropriate care for this patient, it became clear that more imaging would be required. At the time of presentation, his complaints seemed to be concerning for a genitourinary (GU) source: nephrolithiasis, testicular torsion or GU infection all seemed plausible. However, with a negative testicular ultrasound and worsening pain, a CT of the abdomen and pelvis was ordered and revealed the diagnosis of ileocolic intussusception. Once the CT resulted, an emergent surgery consult was placed. The patient was rushed to the operating room and underwent right hemicolectomy with part of the terminal ileum, ascending colon, and transverse colon removed. The pathology report showed ulceration

with extensive acute inflammation, and reactive lymphoid hyperplasia with acute lymphadenitis. Luckily, this patient did well after the operation and was discharged on postoperative day three without any complications.

RESIDENT DISCUSSION

Intussusception is classically described as a proximal segment of GI tract "telescoping" into a more distal portion of the bowel. This process is traditionally classified based on location and can lead to bowel obstruction proximally, gut ischemia, or perforation. Although intussusception is predominantly a pediatric diagnosis (the classic triad taught in most medical schools being intermittent abdominal pain, "red currant jelly" stool, and a palpable mass), adults account for about 5% of all cases of intussusception. The classic triad is much less likely to occur in adults than in children.¹¹

The majority of all adult cases are due to a "lead point" lesion, meaning some kind of physical abnormality that makes a portion of the bowel more likely to experience the telescoping. Among adults, tumors (~50%), adhesions, and lesions from inflammatory bowel disease are the most common lead points thought to trigger intussusception. These are most commonly enteroenteric in location, with the most likely presenting symptom being abdominal pain, followed by changes in bowel patterns, vomiting, rectal bleeding and/or melena.¹²

In this case, we are reminded why adult intussusception can be such a difficult diagnosis to make. Although our patient did exhibit abdominal pain as well as changes in bowel patterns and vomiting, he did not have the "classic" signs of pediatric intussusception and thus initially was somewhat of a medical mystery. Besides age, his leukocytosis, testicular pain, and hematuria led us down several erroneous diagnostic paths before we were able to make the correct diagnosis. In hindsight, our patient's pathology results of lymphoid hyperplasia were consistent with his recent GI infection, and in fact likely served as the lead point in this particular case.

Misdiagnosis is somewhat common in adult intussusception. Up to 20-30% of patients may be asymptomatic, and the aforementioned symptoms are somewhat nonspecific.¹³ Because delays in diagnosis of adult intussusception have proven to increase morbidity a high clinical suspicion is often key. As we saw in our case, CT is the gold standard for diagnosis and will typically reveal a "target"-like mass, which is due to the overlap of the inner and outer portions of the telescoped bowel (Image 3). Plain radiographs have neither the sensitivity nor specificity to reliably pinpoint the lesion but may show signs of obstruction and oral or enema contrast may identify the location of the intussusception. Ultrasound is used commonly for diagnosis in children, but may be limited due to bowel gas from an obstruction or body habitus in adults.

Unlike children, who are generally treated with either a barium or air enema, management of adult intussusception

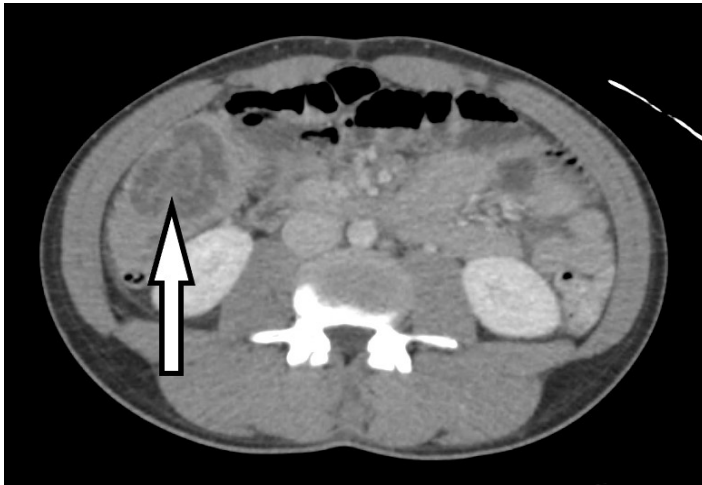

Image 3. Example of the “target” sign (arrow) of intussusception as seen on the patient’s computed tomography.

has traditionally been surgical because of the high proportion of pathologic lead points. Resection of the lead point and any ischemic area is the traditional surgical goal. There is, however, a more recent acknowledgment that with the development and increased use of better diagnostic imaging, more idiopathic or incidental intussusceptions are being diagnosed and that some adult patients may be treated non-surgically.¹⁴ If adult intussusception patients display obstructive symptoms, GI bleeding, or have a palpable mass, surgical exploration may still be the most appropriate option.¹⁵

FINAL DIAGNOSIS

Intussusception

KEY TEACHING POINTS

- Adult patients with intussusception can present with a wide variety of symptoms and do not abide by the classically taught, pediatric intussusception triad. Up to one third of adults with the disease may be asymptomatic.
- Delays in diagnosis of adult intussusception have proven to increase morbidity, so a high clinical suspicion is key with concerning symptoms.
- CT is the gold standard for diagnosis of intussusception in adults.
- While traditional treatment of adult intussusception was once strictly surgical, for patients with more mild disease there may now be a role for non-operative management. Any patient with obstructive symptoms, bleeding, or signs of a mass should still undergo surgical exploration.

Documented patient informed consent and/or Institutional Review Board approval has been obtained and filed for publication of this case report.

Address for Correspondence: T. Andrew Windsor, MD, University of Maryland School of Medicine, Department of Emergency Medicine, 110 South Poca St, Suite 200 – 6th floor, Baltimore, MD 2120. Email: awindsor@som.umaryland.edu.

Conflicts of Interest: By the CPC-EM article submission agreement, all authors are required to disclose all affiliations, funding sources and financial or management relationships that could be perceived as potential sources of bias. The authors disclosed none.

Copyright: © 2018 Windsor et al. This is an open access article distributed in accordance with the terms of the Creative Commons Attribution (CC BY 4.0) License. See: <http://creativecommons.org/licenses/by/4.0/>

REFERENCES

1. Windsor TA. “Great Ideas Gone Horribly Wrong”. CORD CPC Competition Finals. 10/29/17. Washington D.C.
2. Wilde C, Abdelrazeq A. Acute scrotal pain as sole presentation of acute pancreatitis. *Int J Surg Case Rep.* 2015;6:71-2.
3. Kim EN, Lamb K, Relles D, et al. Median arcuate ligament syndrome—review of this rare disease. *JAMA Surg.* 2016;151(5):471–7.
4. Kurklinsky AK, Rooke TW. Nutcracker phenomenon and nutcracker syndrome. *Mayo Clinic Proceedings.* 2010;85(6):552-9.
5. Roberts PF, Waller TA, Brinker TM, et al. Henoch-Schönlein purpura: A review article. *South Med J.* 2007;100:821–4.
6. Gantner J, Keffeler JE, Derr C. Pulmonary embolism: an abdominal pain masquerader. *J Emerg Trauma Shock.* 2013;6(4):280-2.
7. Rehman H, John E, Parikh P. Pulmonary embolism presenting as abdominal pain: an atypical presentation of a common diagnosis. *Case Rep Emerg Med.* 2016:7832895.
8. Besur S, Schmeltzer P, Bonkovsky HL. Acute porphyrias. *J Emerg Med.* 2015;49(3):305–12.
9. Krishnan M, Nahas J. Adult Onset Henoch-Schönlein purpura and intussusception: a rare presentation. *Case Rep Rheumatol.* 2016:13957605.
10. Kim KY. Henoch-Schönlein purpura presenting as intussusception. *Korean J Gastroenterol.* 2017;69(6):372-376.
11. Marinis A, Yiallourou A, Samanides L, et al. Intussusception of the bowel in adults: A review. *World J Gastroenterol.* 2009;15(4):407-11.
12. Lindor R, Bellolio M, Sadosty A, et al. Adult Intussusception: Presentation, management, and outcomes of 148 patients. *J Emerg Med.* 2012;43(1):1-6.
13. Onkendi E, Grotz T, Murray J, et al. Adult intussusception in the last 25 years of modern imaging: is surgery still indicated? *J Gastrointest Surg.* 2011;15(10):1699-705.
14. Amr MA, Polites SF, Alzghari M, et al. Intussusception in adults and the role of evolving computed tomography technology. *Am J Surg.* 2015;209(3):580-3.
15. Aydin N, Roth A, Misra S. Surgical versus conservative management of adult intussusception: case series and review. *Int J Surg Case Rep.* 2016;20:142-6.

Patient with a Subarachnoid Headache

Ethan T. Montemayor, MEd*
Brit Long, MD†
James A. Pfaff, MD‡
Gregory P. Moore, MD, JD‡

*Boston University School of Medicine, Boston, Massachusetts
†Brooke Army Medical Center, Department of Emergency Medicine, San Antonio, Texas
‡Madigan Army Medical Center, Department of Emergency Medicine, Tacoma, Washington

Section Editor: Rick A. McPheeters, DO

Submission history: Submitted March 24, 2018; Revision received May 8, 2018; Accepted May 9, 2018

Electronically published July 19, 2018

Full text available through open access at http://escholarship.org/uc/uciem_cpccem

DOI: 10.5811/cpcem.2018.5.38417

Subarachnoid hemorrhage (SAH) is a life-threatening cause of headache. The diagnostic approach to this entity continues to evolve with a recent questioning of the classic workup of computed tomography and lumbar puncture. We report a risk management case of a patient with a missed SAH resulting in a fatal outcome. When there are multiple diagnostic strategies, the patient may be involved with shared decision-making. Some of the medical and legal implications of the diagnosis of SAH will be discussed. [Clin Pract Cases Emerg Med. 2018;2(3):193–196.]

INTRODUCTION

Headaches are commonly seen in the emergency department (ED). Distinguishing a benign headache from a life-threatening one, such as subarachnoid hemorrhage (SAH), is a critical task for emergency physicians (EP). While the historical workup involves computed tomography (CT) followed by a lumbar puncture (LP), recent literature suggests that CT alone done within six hours obviates the need for this procedure. The following case will illustrate the significance in identifying the life-threatening diagnosis of SAH and the current state of the art in the diagnostic approach. We present a case, discuss the workup of SAH and the potential use of shared decision-making in this process.

CASE

A 53-year-old male with a history of migraine headaches and sleep apnea was brought in by emergency medical services with the chief complaint of headache. He stated the headache had woken him from sleep approximately two hours prior to arrival, was in the occipital area, and was described as persistent, throbbing, sharp, and severe. He reported nausea, dizziness, trouble walking, and tingling of his extremities. He did not lose consciousness but described near syncope. The pain also was exacerbated by movement. He had a history of migraines; however, he stated this headache was different.

The review of systems was unremarkable. Physical exam revealed a blood pressure 134/87 millimeters of mercury, heart rate of 75 beats per minute, respiratory rate of 16 breaths per minute, oral temperature of 98.2° Fahrenheit, and oxygen saturation of 100%. He appeared mildly anxious and described an

occipital headache, which was without meningismus and visual or neurological abnormalities. The remainder of the exam was unremarkable. The headache markedly improved with treatment. A noncontrast CT of the patient's head was performed and interpreted as negative for masses or bleeds. A LP was performed with difficulty and revealed a large number of red blood cells (TNTC) but an absence of xanthochromia. Given the time frame, the difficulty with the procedure and the lack of xanthochromia, the providers interpreted this to be a traumatic LP. The EP prescribed metaclopramide, acetaminophen, decadron, promethazine and hydromorphone with complete resolution of his symptoms. The patient was instructed to see his primary care physician for follow-up care.

The patient was seen in follow-up four days later in an outpatient setting. His labs were reviewed, and it was arranged for him to follow up with a neurologist. He was found dead at home the next day with a SAH secondary to a saccular aneurysm involving the anterior cerebral artery. In retrospect, the family stated that he had developed a headache the evening before his ED visit while weightlifting.

DISCUSSION

Montemayor

Headache accounts for approximately 2% of ED visits, with SAH occurring in 0.5% to 6%.¹ Approximately 15% of patients with SAH will die before they reach the hospital, 25% die within 24 hours, and 45% of patients die within 30 days.² Most patients with SAH experience abrupt headache, often thunderclap in nature, that reaches maximal intensity within one minute.³ Unfortunately, approximately 53% of cases are missed

on initial presentation.² Consequently, providers should have a low threshold of suspicion for SAH when patients present with key historical features. Such symptoms include sudden onset, difference in severity or quality compared to previous headaches and other symptoms, particularly neck stiffness, but also seizure, syncope, focal neurological deficit, and vomiting.² Clinicians should consider that thunderclap headache is not specific for SAH. (15% of thunderclap headaches are the result of SAH.)²

Sentinel headaches are similar to SAH headaches, which may occur days to weeks prior to aneurysm rupture. The incidence appears in 10%-43% of patients with subsequent aneurysmal SAH.⁴ While certain signs and symptoms may increase or decrease the likelihood of SAH, no single characteristic of the history or physical exam is sufficient to rule in or rule out SAH.⁵

Long

Noncontrast CT is done in the initial workup of a SAH. While older generation CT scanners had sensitivities approaching 92%, current generation machines demonstrate sensitivities approaching 100% if completed within six hours of headache onset.⁶ Several studies, both prospective and retrospective, have evaluated patients with sudden onset of headache, use of higher generation CT within six hours of onset, and CT interpreted by an experienced radiologist.^{7,8} The sensitivity and specificity approached 100%, though this is potentially limited in patients with anemia, smaller hemorrhage volume, poor CT quality, experience level of the interpreting radiologist, and imaging artifacts.² This has generated a great deal of discussion with some authorities recommending this approach without performing a LP.^{9,10}

Since many EPs are changing their practice based on these studies, it is imperative that the patient history is accurate. Despite little evidence for it, revisiting the history after the patient's pain improves or soliciting family member may improve the history's accuracy. In a patient with a sudden, severe headache with a normal neurologic examination, literature support exists for a negative noncontrast CT read by a qualified radiologist placing the patient at less than 1% risk for SAH.^{6,11}

Pfaff

While LP is classically used in the case of a negative CT and is a common procedure, it can result in a number of complications including post-spinal headache or back pain, infection, and spinal hematoma. Traumatic taps may occur in 15% of LPs, though the true frequency may be unknown and depends on how a traumatic tap is defined.¹² LP can also provide an alternative diagnosis such as meningitis 3% of the time,¹³ but may not be beneficial if the pretest probability for SAH is low.⁵

Although all values in the cerebral spinal fluid analysis should be evaluated, red blood cells and xanthochromia are most commonly used to diagnosis SAH. Clearing of blood from successive tubes is unreliable since it can also occur with

SAH.¹⁴ Classically, a decrease of red blood cells from the first to the fourth tubes has been used, but it is rare to completely clear. There is no clear cell count consensus with lower cutoffs anywhere from 100 X 10⁶ to 2,000 X 10⁶ cells per high power field or greater.^{15,16} Xanthochromia, a byproduct of hemoglobin breakdown, generally takes anywhere from 2-12 hours to develop. It may be measured by either spectrophotometry or visual inspections. Most laboratories use visual inspection performed by technicians. Studies have shown a wide variation in sensitivity of visual inspection.⁶ Xanthochromia in the setting of SAH greatly reduces the likelihood of a traumatic tap.² This may not be helpful if a tap was done in the first six hours since only 20% of patients getting an LP during that time frame will have positive xanthochromia.²

Pfaff/Moore

Failure to diagnose is the most common reason EPs are involved in litigation. Failing to accurately interpret a test or varying from accepted practice could put providers at risk for litigation. In the headache patient presenting within the first six hours, many EPs are using head CT results alone vs. the traditional practice of CT followed by LP and its potential complications. Since there is a low risk of missed SAH in patients with CT alone in the first six hours, these patients are good candidates for shared decision-making. Shared decision-making is the process of clinician and patient jointly participating in a healthcare decision after discussing the options, benefits, and harms, and considering the patient's values, preferences, and circumstances.^{17,18} Prior to the discussion, the patient must have the capacity to understand the risks; there should be clear documentation of the information provided, with the understanding that it is the patient's decision. Other factors include situations where there is more than one clinical option and equipoise, the patient has decision-making capability, and there is sufficient time for the physician and patient to make an informed decision.¹⁹ If adequate shared decision-making is done and adequately documented, the physician will likely have established a defense in the event the patient were to bring suit for malpractice.

Moore

This legal concept and defense is called assumption of risk. In this situation, the patient is made aware of the risk and danger but makes the choice anyway. The legal elements of the assumption-of-risk defense are as follows: 1) The risk is known; 2) the risk is appreciated; and 3) the risk is voluntarily ignored. An early example of this was in *Charrin v Methodist Hospital*, a case in which a patient pointed out a television cord running across a room and later tripped over it. Her lawsuit was unsuccessful since she was aware of the risk of the cord.²⁰ It is imperative that the risks are clearly spelled out. A classic legal case is *Schneider v Revici*; in this case a physician who practiced unorthodox treatment of breast cancer advised his patient to

evaluate conventional treatment and then had her sign a consent form for treatments not adopted by the medical community (i.e., not standard of care). She later sued, and the appeals court acknowledged the assumption-of-risk defense and allowed the physician to use it.²¹

CONCLUSION

While the approach to evaluation of the acute onset of headache evolves, it is imperative that the right patient population is chosen and that the history is accurate. When shared decision-making is used, the patient must have capacity, should understand the risk, and be informed that it is their decision. If this approach is used, the provider will very possibly have the availability of the assumption-of-risk defense in the event of adverse outcome.

TAKE HOME POINTS

1. Knowledge of the full spectrum of presentations of SAH is important, as patients do not always present with the classic thunderclap headache.
2. CT is the imaging modality of choice if SAH is suspected. Further evaluation for SAH should be based on consideration of other diseases, time of headache onset, and other factors.
3. Ensure there is an accurate history when deciding to use the CT as the sole diagnostic tool in patients who present within six hours of onset, if an LP is not performed.
4. It is important for shared decision-making to have clear documentation of the information provided, the patient's capacity, and the patient's decision.
5. If shared decision-making is done, then it is possible for a physician to use the assumption-of-risk defense.

Documented patient informed consent and/or Institutional Review Board approval has been obtained and filed for publication of this case report.

Address for Correspondence: James A. Pfaff, MD, Brooke Army Medical Center, Department of Emergency Medicine, 3851 Roger Brooke Drive, Ft. Sam Houston, TX 78234. Email: james.a.pfaff@mail.mil.

Conflicts of Interest: By the CPC-EM article submission agreement, all authors are required to disclose all affiliations, funding sources and financial or management relationships that could be perceived as potential sources of bias. The authors disclosed none. The view(s) expressed herein are those of the author(s) and do not reflect the official policy or position of Brooke Army Medical Center, the U.S. Army Medical Department, the U.S. Army Office of the Surgeon General, the Department of the Air Force, the Department of the Army or the Department of Defense or the U.S. Government.

Copyright: © 2018 Montemayor et al. This is an open access article distributed in accordance with the terms of the Creative Commons Attribution (CC BY 4.0) License. See: <http://creativecommons.org/licenses/by/4.0/>

REFERENCES

1. Bellolio MF, Hess EP, Gilani WI, et al. External validation of the Ottawa subarachnoid hemorrhage clinical decision rule in patients with acute headache. *Am J Emerg Med.* 2015;33(2):244-9.
2. Long B, Koyfman A, Runyon MS. Subarachnoid hemorrhage: updates in diagnosis and management. *Emerg Med Clin North Am.* 2017;35(4):803-24.
3. Ducros A, Bousser MG. Thunderclap headache. *BMJ.* 2013;346:e8557.
4. Polmear A. Sentinel headaches in aneurysmal subarachnoid haemorrhage: what is the true incidence? A systematic review. *Cephalalgia.* 2003;23(10):935-41.
5. Carpenter CR, Hussain AM, Ward MJ, et al: Spontaneous subarachnoid hemorrhage: a systematic review and meta-analysis describing the diagnostic accuracy of history, physical examination, imaging, and lumbar puncture with an exploration of test thresholds. *Acad Emerg Med.* 2016;23(9):963-1003.
6. Long B, Koyfman A. Controversies in the diagnosis of subarachnoid hemorrhage. *J Emerg Med.* 2016;50(6):839-47.
7. Perry JJ, Stiell IG, Sivilott ML, et al. Sensitivity of computed tomography performed within six hours of onset of headache for diagnosis of subarachnoid haemorrhage: a prospective cohort study. *BMJ.* 2011;243:d4277
8. Dubosh NM, Bellolio F, Rabinstein AA, et al. Sensitivity of early brain computed tomography to exclude aneurysmal subarachnoid hemorrhage: a systemic review and meta-analysis. *Stroke.* 2016;47(3):750-5.
9. Edlow JA, Fisher J. Diagnosis of subarachnoid hemorrhage: time to change the guidelines? *Stroke.* 2012;43(8):2031-2.
10. Edlow JA: Managing patients with nontraumatic, severe, rapid-onset headache. *Ann Emerg Med.* 2018;71(3):400-8.
11. Williams TS, Seupaul RA. Can noncontrast head computed tomography within 6 Hours of symptom onset exclude aneurysmal subarachnoid hemorrhage? *Ann Emerg Med.* 2016;68(3):352-3.
12. Shah KH, Richard KM, Nicholas S, et al. Incidence of traumatic lumbar puncture. *Acad Emerg Med.* 2003;10(2):151-4.
13. Brunell A, Ridefelt P, Zelano J. Differential diagnostic yield of lumbar puncture in investigation of suspected subarachnoid haemorrhage: a retrospective study. *J Neurol.* 2013;260(6):1631-6.
14. Heasley DC, Mohamed MA, Yousem DM. Clearing of red blood cells in lumbar puncture does not rule out ruptured aneurysm in patients with suspected subarachnoid hemorrhage but negative head CT findings. *AJNR Am J Neuroradiol.* 2005;26(4):820-4.
15. Czuczman AD, Thomas LE, Boulanger AB, et al. Interpreting red blood cells in lumbar puncture: distinguishing true subarachnoid from traumatic tap. *Acad Emerg Med.* 2013;20(3):247-56.
16. Perry JJ, Alyahya B, Sivilotti ML, et al. Differentiation between traumatic tap and aneurysmal subarachnoid hemorrhage: prospective cohort study. *BMJ.* 2015;350:h568.
17. Hoffman TC, Montori VM, Del Mar C. The connection between evidence-based medicine and shared decision making. *JAMA.* 2014;312(13):1295-6.

18. Elswyn G, Concran N, Pignone M. Shared decision making - the importance of diagnosing preferences. *JAMA Intern Med.* 2017;177(9):1239-40.
19. Probst MA, Kanzaria HK, Schoenfeld EM, et al. Shared decision-making in the emergency department: a guiding framework for clinicians. *Ann Emerg Med.* 2017;70(5):688-95.
20. *Charrin v Methodist Hospital*, 432 S.W.2d 572 (Tex. Civ.App.1968).
21. *Schneider v Revici* 817 F.2d 987 (2d Cir. 1987).

Compartment Syndrome with Rhabdomyolysis in a Marathon Runner

Alaina Brinley, MD, PhD*
Bharath Chakravarthy, MD, MPH*
Douglas Kiester, MD†
Wirachin Hoonpongsimanont, MD, MPH*
C. Eric McCoy, MD, MPH*
Shahram Lottipour, MD, MPH*

*University of California, Irvine, Department of Emergency Medicine, Orange, California

†University of California, Irvine, Department of Orthopedics, Orange, California

Section Editor: Manish Amin, DO

Submission history: Submitted February 15, 2018; Accepted April 19, 2018

Electronically published June 12, 2018

Full text available through open access at http://escholarship.org/uc/uciem_cpccem

DOI: 10.5811/cpcem.2018.4.37957

A 38-year-old female seasoned marathon runner presented to the emergency department (ED) with increasing right lower extremity pain after running two mid-distance races in one weekend. The patient had previously run many two-day races and longer distances, but recently had gained weight and had not been training. This case report details her presenting symptoms, evaluation, review of the literature, and treatment with attention to the factors that led to the development of her pathologies. [Clin Pract Cases Emerg Med. 2018;2(3):197-199]

INTRODUCTION

Acute compartment syndrome is a serious disease, which can result in severe morbidity and even mortality. Outcomes are progressively worse with delayed recognition of the diagnosis and the associated delayed treatment. The vast majority of compartment syndrome-associated injuries occur in relation to high-velocity trauma, fractures, and crush injuries. This article discusses the less-common cause: overuse and exercise. Many athletes are accustomed to significant muscle pain after training and events, which may delay the diagnosis. In addition, this patient used opiate painkillers after the races, which may have further delayed her presentation. To our knowledge, there is no previous report detailing a case of compartment syndrome after exercise, with concurrent use of opiate painkillers by the patient. This case report discusses a female recreational runner who presented to a tertiary care emergency department after two mid-distance running events in one weekend.

CASE REPORT

A 38-year-old female presented with right foot, ankle, and calf pain. Her past history was remarkable for a 55-pound weight gain in the prior six months due to being sedentary, and she had a history of meralgia paresthetica of her right lower extremity after a motor vehicle collision. The patient

stated that she had completed a 10K race (6.2 miles) two days prior to presentation and a half marathon (13.1 miles) one day prior to presentation when she noticed her right calf started “seizing up” during the second race. She then started to experience pain on the dorsal aspect of her right foot. The pain progressively worsened over the next 24 hours until she could no longer bear weight on the right lower extremity without severe pain. The pain was worse on the posterior/lateral leg and lateral ankle with associated foot numbness and burning in the sensory distribution of L2-S1. Her sensation was intact to light touch in the sensory distribution of L2-S1 and throughout her lower extremity, despite perceived numbness to the dorsal aspect of her foot and lateral calf. The pulses in her leg were 2+ in femoral, dorsalis pedis, and posterior tibial locations. She also cited intermittent pulling and tightness at rest and with active motion.

She had attempted her normal post-race remedies including ice, hot baths, ibuprofen and hydrocodone/paracetamol. Nothing improved her pain. Stepping on the leg, moving, or touching the leg was extremely painful. Physical exam showed normal vital signs and was significant for an uncomfortable appearing, overweight woman. She allowed a limited physical exam; however, she refused to move the extremity actively or passively.

A radiograph did not show a fracture and ultrasound did not show a deep venous thrombosis. Her creatinine kinase was 5533 (30 – 223 U/L). Intravenous fluid resuscitation was immediately initiated. Given that her pain seemed out of proportion to the exam, orthopedic surgery was consulted. Upon orthopedic evaluation, the patient was diagnosed with compartment syndrome based on the physical exam. She was taken to surgery for emergent lateral/anterior/superficial and deep posterior compartment (four-compartment) fasciotomy. Vacuum-assisted closure was placed on the fasciotomy wounds. A delayed primary closure of all of her wounds was done on postoperative day three. She was discharged the following day.

DISCUSSION

Compartment syndrome is a relatively rare condition. The vast majority of cases occur in individuals who have had fractures, high-velocity trauma, or crush injuries.¹ However, compartment syndrome has also been reported with exercise, overuse injuries and post operatively. Many of the postoperative cases are due to poor positioning on the operating table of an extremity that was not part of the surgery.

In this case, the patient was a trained marathoner who usually participated in multiple, long-distance running races per year. Her deconditioning coupled with significant weight gain were major factors rendering her more susceptible to muscle overuse injury, which subsequently led to the development of her compartment syndrome. Additionally, the patient's narcotic use likely contributed to delayed presentation. There is no previous literature describing the use of narcotics by endurance athletes for post-workout pain. This represents a unique presentation of compartment syndrome and is significant given the current national focus on the opioid epidemic and overuse of narcotic pain prescriptions. The patient presented in this case was using narcotics inappropriately, which provides another example of a risk for over-prescription of narcotics by providers.

Each muscular compartment is a tightly-closed anatomic container that has very little capacity to expand. After an injury, the muscle begins to swell due to increased blood flow to the injured area. In some cases, the swelling is extreme and leads to microvascular and venous dysfunction and collapse. This in turn leads to decreased venous outflow and further engorgement of the muscle, which then causes a continuous rise in compartment pressure. This can also lead to extravascular fluid collections and edema. When the compartment pressure rises to a level higher than the blood pressure, the muscle becomes ischemic and then necrotic, resulting in rhabdomyolysis, which then results in myoglobinemia. It is the myoglobinemia that interferes with kidneys and cardiac function and is the major cause of death in these cases. This process was already well underway in our patient at the time of presentation, which is why her

CPC-EM Capsule

What do we already know about this clinical entity?

Compartment syndrome is a well-characterized disease that usually occurs secondary to trauma, fracture, or overuse injury.

What makes this presentation of disease reportable?

This patient was a seasoned marathoner who had become deconditioned, ran two races in as many days, and then used narcotic pain medication to treat her post-run pain.

What is the major learning point?

Narcotic medication should not be used for post-exertional pain as it may mask injuries, such as compartment syndrome, and delay presentation.

How might this improve emergency medicine practice?

Emergency medicine practitioners should be cautious prescribing opiates as patients may use the medication for conditions other than the intended condition.

creatinine kinase was so high. Although compartment syndrome is a clinical diagnosis, a measured value of compartment pressure above 30 mm Hg above the diastolic blood pressure can also make the diagnosis. Modalities of treatment include conservative monitoring of compartment pressures and emergent fasciotomy.^{2,3}

The treatment for most acute compartment syndrome is emergent decompression of each involved compartment. This is managed surgically by making a longitudinal incision into the fascia. In a successful compartment syndrome fasciotomy, the pressurized muscle will decompress with an immediate color change noted from a dark purple to a bright red. If the compartment is not successfully treated, the muscle develops scar tissue, the nerves die, and circulation is permanently compromised. Permanent disability can result including extremity motor/sensory deficits, loss of all motion, even passive motion, and severe dysesthesias. Any of these conditions can lead to the extremity being amputated.⁴

Glass et al. completed a systematic review of

compartment syndrome, finding that delays in detection of compartment syndrome resulted in the most severe morbidity and mortality. The severe side effects of compartment syndrome (i.e., death and amputation) may be prevented by emergent fasciotomy performed by an orthopedic surgeon or qualified emergency physician; however, even after fasciotomy many patients still experience deficits such as foot drop, limb weakness, or sensory deficits. Some also progress to late amputations. Early diagnosis and treatment are the best predictors of good outcomes; however, there is no consensus in the literature regarding the best surgical method of treatment for compartment syndrome patients.³

Pain, or pain out of proportion to exam, is often the initial symptom indicating compartment syndrome pathology. Patients who are nonverbal as a result of their trauma, or pediatric patients, require close monitoring for physical signs of compartment syndrome as they may not be able to verbalize worsening pain.¹ Other reports suggest compartment syndrome in lower extremities after harvesting bypass grafts and urologic procedures.^{5,6} These patients may also be under heavy sedation and post-operative analgesia, further complicating early diagnosis. However, young athletes are usually able to determine when their pain progresses to abnormal levels and will seek medical aid. However, in the case we have presented, this patient's awareness of her condition may have been delayed by her use of narcotics for post-exercise pain.

Athletes may also develop chronic compartment syndrome where repetitive injury causes tissue and microvascular damage that leads to progressively elevated compartment pressures, rather than acute compartment pressures.² Chronic exertional compartment syndrome may be treated conservatively with physical therapy or gait retraining; it may also be treated operatively, most often arthroscopically. Campano et al. report good outcomes in 84% of operatively-managed chronic exertional compartment syndrome patients.^{7,8}

CONCLUSION

A high index of suspicion is an important consideration in patients presenting with calf discomfort without trauma but having pain out of proportion to exam. Our patient had previous experience in athletic competitions; however, significant recent weight gain added risk to this otherwise-seasoned athlete. Additionally, her use of narcotics likely delayed her presentation. It would have been easy to attribute her pain after two relatively short races to muscle fatigue, sprain and stress from the physical exertion. The risk of missing compartment syndrome has very serious morbidity and medical consequences, particularly for athletes, which makes consideration of this entity a critical diagnosis for emergency physicians.

Documented patient informed consent and/or Institutional Review Board approval has been obtained and filed for publication of this case report.

Address for Correspondence: Shahram Lottipour, MD, MPH, University of California, Irvine, Department of Emergency Medicine, 333 City Boulevard West, Suite 640, Route 128-01, Orange, CA 92868. Email: shl@uci.edu.

Conflicts of Interest: By the *CPC-EM* article submission agreement, all authors are required to disclose all affiliations, funding sources and financial or management relationships that could be perceived as potential sources of bias. The authors disclosed none.

Copyright: © 2018 Brinley et al. This is an open access article distributed in accordance with the terms of the Creative Commons Attribution ([CC BY 4.0](http://creativecommons.org/licenses/by/4.0/)) License. See: <http://creativecommons.org/licenses/by/4.0/>

REFERENCES

- Wallin K, Nguyen H, Russell L, et al. Acute traumatic compartment syndrome in pediatric foot: a systematic review and case report. *J Foot Ankle Surg.* 2016;55(4):817-20.
- McLaughlin N, Heard H, S Kelham. Acute and chronic compartment syndromes: know when to act fast. *JAAPA.* 2014;27(6):23-6.
- Von Keudell AG. Diagnosis and treatment of acute extremity compartment syndrome. *Lancet.* 2015;386(10000):1299-310.
- Glass GE et al. Managing missed lower extremity compartment syndrome in physiologically stable patient: a systematic review and lessons from a Level I trauma center. *J Trauma Acute Care Surg.* 2016; 81(2):380-7.
- Te Kolste HJ, Balm R, de Mol B. Acute compartment syndrome of the lower leg after coronary artery bypass grafting: a silent but dangerous complication. *Thorac Cardiovasc Surg.* 2015;63(4):300-6.
- Sukhu T, Krupski TL. Patient positioning and prevention of injuries in patients undergoing laparoscopic and robot-assisted urologic procedures. *Curr Urol Rep.* 2014;15(4):398.
- Agresta C, Brown. Gait retraining for injured and healthy runners using augmented feedback: a systematic literature review. *J Orthop Sports Phys Ther.* 2015;45(8):576-84.
- Campano D, Robaina JA, Kusnezov N, et al. Surgical management for chronic exertional compartment syndrome of the leg: a systematic review of the literature. *Arthroscopy.* 2016;32(7):1478-86.

Blunt Traumatic Cervical Vascular Injury Without any Modified Denver Criteria

Jed T. Ritter, MD

Chadd K. Kraus, DO, DrPH, MPH

Geisinger Health System, Department of Emergency Medicine, Danville, Pennsylvania

Section Editor: Rick A McPheeters, DO

Submission history: Submitted January 25, 2018; Revision received April 5, 2018; Accepted April 19, 2018

Electronically published June 26, 2018

Full text available through open access at http://escholarship.org/uc/uciem_cpchem

DOI: 10.5811/cpchem.2018.4.37719

Blunt traumatic cervical vascular injury (BCVI) is challenging to recognize, but it is a potentially devastating entity that warrants attention from emergency physicians. Injury to the vertebral or carotid artery can result in a delayed manifestation of neurologic injury that may be preventable if promptly recognized and treated. The modified Denver Criteria are frequently used to guide imaging decisions for BCVI; however, injuries can still be missed. We present a case of BCVI in a trauma patient whose initial presentation evaded standard screening criteria, illustrating the need for a high index of suspicion for BCVI in blunt trauma. [Clin Pract Cases Emerg Med. 2018;2(3):200-202.]

INTRODUCTION

Blunt traumatic cervical vascular injury (BVCI) is challenging to recognize and is a potentially devastating clinical entity that warrants special attention from emergency physicians. Injury to the vertebral or carotid artery can result in a delayed manifestation of neurologic injury that may be preventable if promptly recognized and treated. The modified Denver Criteria are frequently used to guide imaging decision for BCVI, however, injuries can still be missed even using these criteria. We present a case of BCVI in a trauma patient whose initial presentation evaded standard screening criteria, illustrating the need for a high index of suspicion for BCVI in blunt trauma.

CASE REPORT

A 26-year-old female presented to a Level I trauma center after a motorcycle crash in which she was the unhelmeted passenger thrown from the vehicle. The patient did lose consciousness and was noted to be briefly confused on scene. Her right shoulder had a palpable deformity and she had difficulty moving the right upper extremity, but she denied other symptoms and was transported to our facility via ground emergency medical services. Upon arrival, the patient was in no distress, alert and oriented, and reported only pain in the right shoulder.

Initial vital signs were temperature of 36.7° Celsius, heart rate 107 beats per minute, blood pressure 102/57 mmHg, respiratory rate 18 breaths per minute, and 100% oxygen

saturation on room air. She was evaluated by standard trauma protocol. Computed tomography (CT) imaging of the head, cervical spine, and chest/abdomen/pelvis were significant only for a right anterior shoulder dislocation. The patient was treated symptomatically and preparations were made to perform procedural sedation to reduce the shoulder dislocation. Prior to sedation, the patient developed an abrupt change in mental status. Her right pupil became fixed and dilated. She became aphasic, and her right side became flaccid. The patient was immediately intubated based on Glasgow Coma Scale (GCS) of 7 and rapid deterioration of her clinical status.

A repeat CT head was obtained and revealed a hyperdense left middle cerebral artery (MCA). Neurosurgery and neurology were both immediately consulted. CT angiography (CTA) of the head and neck revealed a left internal carotid dissection with tandem embolus to the proximal left MCA. A tandem occlusion is defined by injury that results in cervical carotid artery dissection, as well as embolic occlusion of a large intracranial artery. This type of vascular occlusion typically does not respond well to thrombolysis.¹ Given the confirmed presence of a tandem occlusion in our patient, a discussion regarding the utility of thrombolytics was held. Neurosurgery opted to perform endovascular mechanical thrombectomy and stenting of the internal carotid artery. Diagnostic cerebral angiogram revealed complete revascularization of the distal left MCA territory. The patient was subsequently admitted to

the intensive care unit. There, her course was uncomplicated, and by discharge on hospital day 18 the patient had regained a significant amount of independent function.

DISCUSSION

Blunt cervical vascular injury (BCVI) is a term used to include injuries to the carotid and vertebral arteries. Although BCVI is rare, it is an entity that can lead to devastating outcomes, including stroke and death.² Current estimates put the incidence of BCVI between 1-2% of all blunt trauma.³ If recognized promptly treatments exist for BCVI. Current treatment strategies for BCVI range from antiplatelet and anticoagulation therapy to endovascular stents and mechanical thrombectomy depending on the clinical scenario.

Screening for BCVI is heterogenous. Imaging modalities (e.g., CTA) have improved,⁴ but they are inadequate for screening⁵ and should not be relied upon exclusively for diagnosis.⁶ One commonly used screening tool, the modified Denver Criteria, suggests using CTA to evaluate for vascular injury in patients with any of the following: unexplained neurologic deficit; arterial hemorrhage, cervical bruit or thrill, infarct on head CT, basilar skull fracture on imaging, expanding neck hematoma; seatbelt abrasion on the neck; GCS less than or equal to 8 in association with blunt trauma; cervical spine fracture; Le Fort II or III facial fractures; or hanging with anoxic brain injury.^{7,8} In the case of our patient, she did not have any notable signs or symptoms to prompt early CTA screening for BCVI as suggested by the Denver Criteria. An abrupt onset of new symptoms prompted the imaging, which revealed a complete occlusion of the left internal carotid artery, as well as a tandem embolus to the proximal left MCA.

Treatment for BCVI is dependent upon the severity of the injury. The Blunt Carotid Arterial Injury Grading Scale is the most commonly used tool to stratify vascular injury. It uses a scale from I to V: I represents luminal irregularity or dissection with less than 25% narrowing; II represents greater than 25% narrowing, intraluminal thrombus, or raised flap; III represents pseudoaneurysm; IV represents occlusion; and V represents transection with active extravasation. Management for lower-grade injuries most often consists of antiplatelet or anticoagulation regimens. Multiple studies have shown no clear benefit between antiplatelet and anticoagulation therapy. Management and optimal treatment depends on the clinical scenario. For example, the Eastern Association for the Surgery of Trauma recommends that patients with grade III or greater vascular injuries be considered for operative intervention as they rarely respond to antithrombotic therapy.¹⁰

Multiple studies have been conducted comparing traditional vs. angio-interventional therapy, without clear superiority of one modality. In the case of our patient, CTA revealed a grade IV dissection with associated proximal MCA embolism. Recent case studies have shown promising results regarding the use of mechanical thrombectomy in association

CPC-EM Capsule

What do we already know about this clinical entity?

Injury to the vertebral or carotid artery can result in a delayed manifestation of neurologic injury that may be preventable if promptly recognized and treated.

What makes this presentation of disease reportable?

We present a case of Blunt cervical vascular injury (BCVI) in a trauma patient whose initial presentation evaded standard screening criteria, illustrating the need for a high index of suspicion for BCVI in blunt trauma.

What is the major learning point?

The Modified Denver Criteria are frequently used to guide imaging decisions for BCVI, however, injuries can still be missed.

How might this improve emergency medicine practice?

This case demonstrates the importance of considering BCVI in the setting of trauma, even in the absence of the Denver Criteria for computed tomography angiography.

with proximal stenting of the injured vessel.¹¹⁻¹⁷ Thrombolytics have a limited role in this situation. Endovascular therapy offers an alternative approach, which in the case of our patient provided complete revascularization and a favorable outcome.

CONCLUSION

BCVI has gained significant attention in the recent literature, and yet is frequently not recognized in a timely fashion. This case demonstrates the importance of considering BCVI in the setting of trauma, even in the absence of the Denver Criteria for CTA. Current screening criteria and imaging modalities can still miss injuries, delayed diagnosis and treatment leading to devastating sequelae, including death.

Documented patient informed consent and/or Institutional Review Board approval has been obtained and filed for publication of this case report.

Address for Correspondence: Chadd K. Kraus, DO, DrPH, Geisinger Health System, Department of Emergency Medicine, 100 North Academy Avenue Danville, PA 17822. Email: chaddkraus@gmail.com.

Conflicts of Interest: By the CPC-EM article submission agreement, all authors are required to disclose all affiliations, funding sources and financial or management relationships that could be perceived as potential sources of bias. The authors disclosed none.

Copyright: © 2018 Ritter et al. This is an open access article distributed in accordance with the terms of the Creative Commons Attribution (CC BY 4.0) License. See: <http://creativecommons.org/licenses/by/4.0/>

REFERENCES

1. Rangel-Castilla L, Rajah GB, Shakir HJ, et al. Management of acute ischemic stroke due to tandem occlusion: should endovascular recanalization of the extracranial or intracranial occlusive lesion be done first? *Neurosurg Focus*. 2017;42(4):E16.
2. Weber CD, Lefering R, Kobbe P, et al. Blunt cerebrovascular Artery injury and stroke in severely injured patients: an international multicenter analysis. *World J Surg*. 2017. In Press.
3. Bruns BR, Tesoriero R, Kufera J, et al. Blunt cerebrovascular injury screening guidelines: what are we willing to miss? *J Trauma Acute Care Surg*. 2014;76(3):691-5.
4. Paulus EM, Fabian TC, Savage SA, et al. Blunt cerebrovascular injury screening with 64-channel multidetector computed tomography: more slices finally cut it. *J Trauma Acute Care Surg*. 2014;76(2):279-83.
5. Miller PR, Fabian TC, Croce MA, et al. Prospective screening for blunt cerebrovascular injuries: analysis of diagnostic modalities and outcomes. *Ann Surg*. 2002;236(3):386-93.
6. Parks NA, Croce MA. Use of computed tomography in the emergency room to evaluate blunt cerebrovascular injury. *Adv Surg*. 2012;46:205-17.
7. Biffi WL, Moore EE, Offner PJ, et al. Optimizing screening for blunt cerebrovascular injuries. *Am J Surg*. 1999;178(6):517-22.
8. Cothren CC, Moore EE, Ray CE Jr, et al. Cervical spine fracture patterns mandating screening to rule out blunt cerebrovascular injury. *Surgery*. 2007;141(1):76-82.
9. Biffi WL, Moore EE, Offner PJ, et al. Blunt carotid and vertebral arterial injuries. *World J Surg*. 2001;25(8):1036-43.
10. Eastern Association for the Surgery of Trauma. Bromberg WJ, William J, Collier BC, et al. Blunt Cerebrovascular Injury - Practice Management Guideline. Available at: <http://www.east.org/education/practice-management-guidelines/blunt-cerebrovascular-injury>. Accessed on December 12, 2017.
11. Mpotsaris A, Kabbasch C, Borggrefe J, et al. Stenting of the cervical internal carotid artery in acute stroke management: The Karolinska experience. *Interv Neuroradiol*. 2017;23(2):159-65.
12. Cohen JE, Leker RR, Eichel R, et al. Emergency endovascular revascularization of tandem occlusions: Internal carotid artery dissection and intracranial large artery embolism. *J Clin Neurosci*. 2016;28:157-61.
13. Haussen DC, Jadhav A, Jovin T, et al. Endovascular management vs Intravenous thrombolysis for acute stroke secondary to carotid artery dissection: local experience and systematic review. *Neurosurgery*. 2016;78(5):709-16.
14. Kobata H. Diagnosis and Treatment of traumatic cerebrovascular Injury: Pitfalls in the management of neurotrauma. *Neurol Med Chir (Tokyo)*. 2017;57(8):410-7.
15. Marnat G, Mourand I, Eker O, et al. Endovascular management of tandem occlusion stroke related to internal carotid artery dissection using a distal to proximal approach: insight from the RECOAST study. *AJNR Am J Neuroradiol*. 2016;37(7):1281-8.
16. Rubiera M, Ribo M, Delgado-Mederos R, et al. Tandem internal carotid artery/middle cerebral artery occlusion: an independent predictor of poor outcome after systemic thrombolysis. *Stroke*. 2006;37(9):2301-5.
17. Wetter A, Shin M, Meila D, et al. Treatment of middle cerebral artery occlusion and internal carotid artery dissection with combined mechanical thrombectomy and stenting of the internal carotid artery: a case report. *Neuroradiol J*. 2013;26(1):84-8.

Severe Intracranial Hemorrhage at Initial Presentation of Acute Myelogenous Leukemia

Amanda Balmages*

Joseph Dinglasan, MD†

Megan Boysen Osborn, MD, MHPE‡

*Touro University California, Vallejo, California

†Mission Hospital, Department of Emergency Medicine, Mission Viejo, California

‡University of California Irvine Health, Department of Emergency Medicine, Orange, California

Section Editor: Manish Amin, DO

Submission history: Submitted February 7, 2018; Revision received April 2, 2018; Accepted April 19, 2018

Electronically published June 26, 2018

Full text available through open access at http://escholarship.org/uc/uciem_cpccem

DOI: 10.5811/cpcem.2018.4.37881

Intracranial hemorrhage (ICH) is the second leading cause of mortality among patients diagnosed with acute myelogenous leukemia (AML). The bone marrow failure associated with AML produces dysfunctional platelets, which significantly increases the risk of hemorrhagic complications within this population. In this report we discuss the case of a previously healthy female patient, newly diagnosed with AML, who rapidly developed fatal ICH. [Clin Pract Cases Emerg Med. 2018;2(3):203–206.]

INTRODUCTION

Intracranial hemorrhage (ICH) is the second leading cause of mortality in patients with acute myelogenous leukemia (AML).¹ AML-associated bone marrow failure produces marked thrombocytopenia with small, dysfunctional platelets, increasing risk of hemorrhage.² Emergency physicians (EP) should maintain a high degree of suspicion for hemorrhagic complications in patients presenting with new-onset AML. Bleeding-type disseminated intravascular coagulation (DIC) is a common finding in AML patients, especially those with the acute promyelocytic leukemia (APL) subtype, and further increases risk of death from hemorrhage.^{3,4}

DIC may be difficult to diagnose in the emergency department (ED) setting due to a lack of specific lab parameters and variable presentation, but a high degree of suspicion for DIC in AML patients is warranted. Administration of all-trans retinoic acid (ATRA) significantly improves outcomes of APL patients by preventing or rapidly reversing DIC.⁵ ATRA is a lifesaving intervention that EPs, in consultation with hematology-oncology, should consider in patients with laboratory values that suggest AML. Administration of platelet concentrate may also be useful.² AML carries a relatively favorable prognosis if the complications of the disease – such as infection or hemorrhage – can be avoided or effectively managed.⁶ In this report we

discuss a patient with newly diagnosed AML, who presented to the ED ambulating, alert, and oriented, and while en route to a higher level of care quickly deteriorated before further interventions could be implemented.

CASE REPORT

A previously healthy 55-year-old female was evaluated in urgent care for easy bruising for three weeks' duration. After she was found to have abnormal laboratory results, she was directed to a community ED for further treatment and care.

The patient presented to a community ED the following day. She denied trauma, fever, chills, headaches, or abdominal pain. Upon initial evaluation, the patient had a temperature of 98.5° F, pulse of 87/minute, respiratory rate of 18/minute, and blood pressure of 170/75 mm/Hg. Pulse oximetry showed 100% saturation on room air. Physical exam was unremarkable, except for ecchymosis to the upper and lower extremities bilaterally. Initial laboratory data was significant for a white blood cell (WBC) count of 51.7 x10⁹/L, with 89% monocytes and 5% segmented neutrophils, platelets of 16 x10⁹/L and hemoglobin of 11.3 g/dL. Prothrombin time (PT) was 17.3 seconds, and international normalized ratio (INR) was 1.6. Complete blood count was negative for blasts; however, Auer rods were present, and the specimen was sent for peripheral smear and flow cytometry. The EP consulted

oncology by phone for suspicion of acute leukemia, and the patient was scheduled for an outpatient follow-up two days later, with instructions to return if her symptoms worsened.

Early on the day of her scheduled oncology consultation, the patient returned to the ED complaining of bilateral lower extremity pain and multiple new bruises. She had pain in her lower extremities, from thighs to feet, and occasionally buttocks. She denied tingling, numbness, bladder or bowel incontinence, back pain, or headache. Review of systems was positive only for gross hematuria. Other than mild tachycardia, vital signs at triage were within normal limits. Similar to the prior visit, her physical exam showed ecchymosis over all four extremities, but was otherwise unremarkable. Neurologic examination was within normal limits.

Hematological studies showed significant dysfunction of multiple cell lines, including WBCs of $110.8 \times 10^9/L$, platelets of $60 \times 10^9/L$, hemoglobin of 10 g/dL, 0% neutrophils, and blasts now at 22%. Additional labs found a PT of 18.7 seconds, INR of 1.6, and a d-dimer of 27.9 mg/L FEU. Initial analysis of peripheral smear showed multiple blast forms with convoluted nuclei and monocytoid features. Flow cytometry results from the previous visit were consistent with AML, while a lack of cluster of differentiation antigen 34 (CD34) and human leukocyte antigen – antigen D related (HLA-DR) was suggestive of APL. After ruling out deep vein thrombosis by lower extremity ultrasound, the patient was transferred by ambulance to a tertiary care center. At the recommendation of the receiving oncologist, 30mg of ATRA was administered prior to transfer to prevent DIC.

While en route to the tertiary care facility, the patient became acutely altered and lost consciousness. Upon arrival, her pulse was 68/minute, blood pressure was 231/96, respiratory rate was 15/minute, and oxygen saturation was 99% on 15L by non-rebreather mask. The patient's Glasgow Coma Score was 1-1-1, her left pupil was fixed and dilated, and she was intubated for airway protection. She was given 50g mannitol. The right pupil became fixed and dilated shortly thereafter, and another 50g mannitol was administered.

Computed tomography (CT) demonstrated a 7.2 centimeter parenchymal hematoma with associated edema and a 10mm midline shift, causing leftward uncal herniation (Image). Trace subarachnoid hemorrhage was also noted. The patient was emergently evaluated by neurology and neurosurgery and was treated with 60ml (30ml x 2) 23.4% sodium chloride. Neurosurgery evaluated the patient's CT and reported that mortality associated with ICH of this size was 72%, and that full recovery, if she survived at all, would be unlikely. Although there was no advanced directive in place, the patient's family members agreed that the patient would not have wanted surgical intervention if her chances of significant recovery were unrealistic.

Over the next 24 hours, the patient's diagnostic studies demonstrated continued derangement across multiple parameters,

CPC-EM Capsule

What do we already know about this clinical entity?

Intracranial hemorrhage is a leading cause of death in patients with acute myelogenous leukemia (AML) and can occur as a result of disseminated intravascular coagulation or bone marrow failure.

What makes this presentation of disease reportable?

The patient's rapid progression makes this a valuable example of how critical a role the emergency physician can play in the care and management of patients with new-onset AML.

What is the major learning point?

This report highlights the importance of emergency physicians in gaining familiarity with medications uncommonly used in the emergency department.

How might this improve emergency medicine practice?

The authors' hope is that this will improve emergency medical practice by highlighting the emergent nature of the complications of AML.

with blast forms increasing to as high as 83%, fibrinogen dropping to 77 mg/dL, and platelets paradoxically oscillating from $60 \times 10^9/L$, to $13 \times 10^9/L$, to $88 \times 10^9/L$ in a matter of hours. Aspartate aminotransferase was measured at 64 units/L and alanine aminotransferase at 61 units/L, while creatinine increased from 0.9 mg/dL at initial presentation to 1.3 mg/dL, and troponin I was measured at 7.70 ng/mL at its peak. The patient died within 24 hours of arrival at the tertiary care center.

DISCUSSION

The incidence of AML in the United States is approximately 20,000 cases per year.⁷ While infection is still the leading cause of death in this population, approximately 10% of patients will die from DIC or bleeding diathesis at the time of initial presentation of AML, with ICH as the most common hemorrhagic complication.⁸⁻¹¹ Risk of death from ICH in this population is linked to extent of coagulopathy and leukocytosis; those patients found to have WBCs $>100 \times 10^9/L$ and INR >1.5 have significantly higher risk of death from ICH than those found with lower respective lab values,

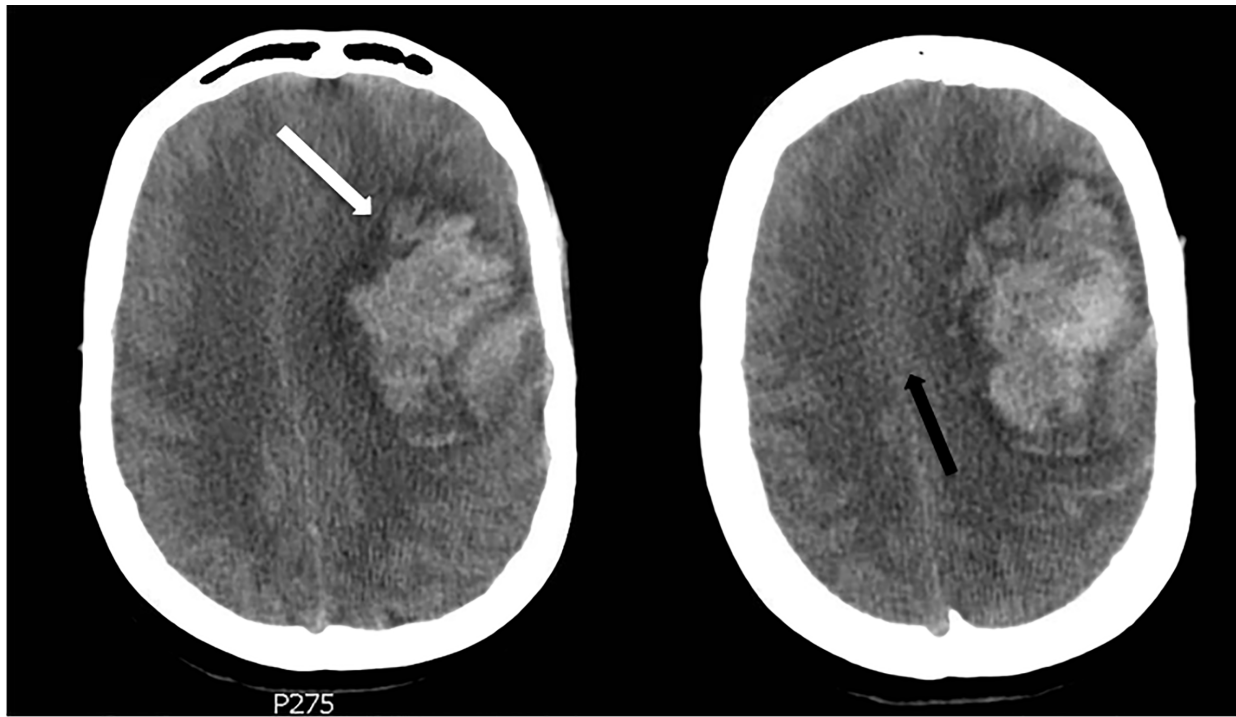


Image. Computed tomography of the brain, axial images, demonstrating 7.2 centimeter parenchymal hematoma (white arrow) with associated edema causing 10 millimeters of midline shift (black arrow).

while thrombocytopenia additionally increases risk.^{11,12} Female gender has also been associated with an increased risk of death from ICH.^{10,11} Therefore, it may be prudent for EPs to consider admission or observation for any patient meeting these high-risk criteria.

While prophylactic platelet transfusion has been well studied and widely used in AML patients undergoing chemotherapy,^{13,14} according to blood transfusion guidelines, prophylactic platelet transfusion is not routinely performed for patients newly presenting with evidence of AML whose platelet counts are greater than $10 \times 10^9/L$.^{2,15} In 2011, Psaila et al. conducted one of the first studies that looked specifically at platelet function in patients with AML as compared to platelet function in equally thrombocytopenic individuals with immune thrombocytopenic purpura (ITP) and determined that patients with AML have more dysfunctional platelets than those in patients with ITP.² This raises the question of whether it may be beneficial for EPs to consider prophylactic platelet transfusion at a higher platelet count in patients recently diagnosed with AML, who have not yet undergone any form of treatment.

DIC is especially common in patients with the APL subtype of acute leukemia; however, the risk of hemorrhage exists with all types.¹ Pathogenesis of DIC in patients with APL is mediated by increased blast cell production of tissue factor (TF) and cancer procoagulant (CP), and blast cell overexpression of the surface protein annexin II, which acts as a co-receptor

for plasmin and tissue plasminogen activator, leading to extensive fibrinolysis.¹⁶ Combined with thrombocytopenia and dysfunctional platelets, these factors can cause a patient to rapidly progress to overt DIC. Unfortunately, there is no single, specific test that is diagnostic of DIC, so a combination of studies must be obtained if DIC is suspected.³ According to a 2014 study published by Wada et al., the findings of PT prolongation, d-dimer elevation, fibrinogen reduction, and platelet count reduction, is the most reliable combination of test results readily attainable in the ED to indicate the bleeding type of DIC associated with hematologic malignancies.³

Administration of ATRA is effective in rapidly reversing DIC in these patients as it functions to stop aberrant production of TF and CP and simultaneously induce differentiation of leukemic promyelocytes.⁵ Current recommendations support starting ATRA as soon as a diagnosis of APL is suspected, as increased incidence of early death has been linked to delays in ATRA administration by as few as one to two days.¹⁷ Therefore, EPs may consider initiating ATRA treatment upon initial presentation of a patient with suspected APL. Prompt initiation of ATRA, followed by concomitant chemotherapy has significantly reduced morbidity and mortality in this population, and APL is now considered one of the most treatable subtypes of acute leukemia with long-term remission rates of up to 80% in those who survive the presentation period.^{6,18}

CONCLUSION

Patients with AML may access the ED for care throughout the course of their disease; they may be diagnosed in the ED, or they may present with infection, chemotherapy-induced nausea and vomiting, or hemorrhage. Maintaining a high degree of suspicion for ICH and DIC is important in improving outcomes of these patients throughout the course of their treatment. Emergency physicians may consider a variety of treatment strategies for managing the complications of AML. Gaining familiarity with medications uncommonly used by emergency physicians, such as ATRA, may be beneficial in preventing disastrous outcomes.

Documented patient informed consent and/or Institutional Review Board approval has been obtained and filed for publication of this case report.

Address for Correspondence: Amanda Balmages, c/o Megan Boysen Osborn, MD, MHPE, University of California Irvine Health, Department of Emergency Medicine, 333 City Boulevard West, Suite 640, Orange, CA 92868. Email: amanda.balmages@tu.edu.

Conflicts of Interest: By the CPC-EM article submission agreement, all authors are required to disclose all affiliations, funding sources and financial or management relationships that could be perceived as potential sources of bias. The authors disclosed none.

Copyright: © 2018 Balmages et al. This is an open access article distributed in accordance with the terms of the Creative Commons Attribution (CC BY 4.0) License. See: <http://creativecommons.org/licenses/by/4.0/>

REFERENCES

- Chen C-Y, Tai C-H, Tsay W, et al. Prediction of fatal intracranial hemorrhage in patients with acute myeloid leukemia. *Ann Oncol*. 2009;20(6):1100-4.
- Psaila B, Bussel JB, Frelinger AL, et al. Differences in platelet function in patients with acute myeloid leukaemia and myelodysplasia compared to equally thrombocytopenic patients with immune thrombocytopenia. *J Thromb Haemost*. 2011;9(11):2302-10.
- Wada H, Matsumoto T, Yamashita Y. Diagnosis and treatment of disseminated intravascular coagulation (DIC) according to four DIC guidelines. *J Intensive Care*. 2014;2(1):15.
- Miguel A, Sanz MA, Montesinos P. Open issues on bleeding and thrombosis in acute promyelocytic leukemia. *Thromb Res*. 2010;125(2):S51-4.
- Barbui T, Falanga A. Hemorrhage and thrombosis in acute leukemia. *Haematol Rep*. 2005;1(9):48-51.
- Testa U, Lo-Coco F. Prognostic factors in acute promyelocytic leukemia: strategies to define high-risk patients. *Ann Hematol*. 2016; 95(5):673-80.
- Cancer Stat Facts: Leukemia - Acute Myeloid Leukemia (AML). Surveillance, Epidemiology, and End Results Program. Available at: <https://seer.cancer.gov/statfacts/html/amyl.html>. Accessed on December 28, 2017.
- Hersh EM, Bodey GP, Nies BA, et al. Causes of death in acute leukemia: A ten-year study of 414 patients from 1954-1963. *J Am Med Assoc*. 1965;193(2):105-9.
- Chang HY, Rodriguez V, Narboni G, et al. Causes of death in adults with acute leukemia. *Medicine (Baltimore)*. 1976;55(3):259-68.
- Arbuthnot C, Wilde JT. Haemostatic problems in acute promyelocytic leukaemia. *Blood Rev*. 2006;20:289-97.
- Kim H, Lee JH, Choi SJ, et al. Risk score model for fatal intracranial hemorrhage in acute leukemia. *Leukemia*. 2006;20:770-6.
- Kim H, Lee JH, Choi SJ, et al. Analysis of fatal intracranial hemorrhage in 792 acute leukemia patients. *Haematologica*. 2004;89:622-4
- Rebulla P, Finazzi G, Marangoni F, et al. The threshold for prophylactic platelet transfusions in adults with acute myeloid leukemia. *N Engl J Med*. 1997;337:1870-5.
- Blajchman MA, Slichter SJ, Heddle NM, et al. New strategies for the optimal use of platelet transfusions. *Hematology*. 2008;198-204.
- Kaufman RM, Djulbegovic B, Gernsheimer T, et al. Platelet transfusion: a clinical practice guideline from the AABB. *Ann Int Med*. 2015;162:205-13.
- Ikezoe T. Pathogenesis of disseminated intravascular coagulation in patients with acute promyelocytic leukemia, and its treatment using recombinant human soluble thrombomodulin. *Int J Hematol*. 2014;100(1):27-37.
- Altman JK, Rademaker A, Cull E, et al. Administration of ATRA to newly diagnosed patients with acute promyelocytic leukemia is delayed contributing to early hemorrhagic death. *Leuk Res*. 2013;37(9):1004-9.
- Tamai H, Yamanaka S, Yamaguchi H, et al. Effective management of acute promyelocytic leukemia with high risk of fatal intracranial hemorrhage. *Biol Medicine*. 2015;8:262.

Methemoglobinemia Induced By Ingesting Lava Lamp Contents

Mary E. Funke, MD*
Chanel E. Fischetti, MD†
Anne M. Rodino, PharmD*‡
Stephen P. Shaheen, MD*

*Duke University, Department of Emergency Medicine, Durham, North Carolina
†UCI Medical Center, Department of Emergency Medicine, Orange, California
‡Duke University, Department of Medicine, Durham, North Carolina

Section Editor: Rick A. McPheeters, DO

Submission history: Submitted March 13, 2018; Revision received May 7, 2018; Accepted May 10, 2018

Electronically published July 16, 2018

Full text available through open access at http://escholarship.org/uc/uciem_cpchem

DOI: 10.5811/cpchem.2018.5.38261

A patient presented after ingesting the contents of a lava lamp that he believed to contain alcohol. It was later discovered that this product was comprised of 76% calcium nitrate, leading to his subsequent development of methemoglobinemia. This disease is a medical emergency secondary to poor transportation of oxygen and resultant tissue hypoxic effects. Therefore, having high suspicion for this disease process in patients with toxic ingestions, understanding the proper diagnosis, and promptly starting treatment are all critical actions for emergency physicians. [Clin Pract Cases Emerg Med. 2018;2(3):207–210.]

INTRODUCTION

Methemoglobinemia can be genetic or acquired following exposure to various toxins. It can be induced by substances containing nitrates. When nitrates are metabolized, they form inorganic nitrites that act as the oxidizing agent on iron in hemoglobin. Methemoglobinemia occurs when iron in hemoglobin is oxidized from the ferrous state (Fe^{2+}) to the ferric state (Fe^{3+}). This prevents hemoglobin from binding oxygen, causing varying degrees of hypoxia.¹

Acquired methemoglobinemia can be induced by ingestion of toxic substances such as paint thinner, which contain nitrobenzene, or it can be secondary to other less-common manifestations.⁴ For instance, in 1992 at a school in New Jersey, more than 40 children contracted methemoglobinemia after they ingested soup later found to contain high quantities of nitrite.² There have also been reports of methemoglobinemia in septic patients thought to be secondary to large amounts of nitric oxide.³ In addition, medications such as sodium nitrite used to treat cyanide poisoning have been shown to induce methemoglobinemia with toxic doses as low as 300mg.⁴

CASE REPORT

A 71-year-old, 86 kilogram male with a history of alcohol abuse, dementia, chronic kidney disease, and hypertension

presented to the emergency department (ED) after the ingestion of approximately half of a retail lava lamp's contents. On-scene vitals by emergency medical services (EMS) were notable for 90% oxygen saturation on room air. The patient was placed on two liters of oxygen by nasal cannula (NC), and the North Carolina Poison Control Center was called; they recommended supportive care, laboratory studies, and an electrocardiogram (ECG) with continuous cardiac monitoring. The risk of toxic ingestion was thought to be low because of the recent manufacture date, which theoretically minimized toxic contents previously found in similar products because of regulatory changes.

In the ED, EMS reported that the patient had consumed the lava lamp because he believed it to contain alcohol. The patient was unsure of the time of ingestion, though all history was limited by his chronic dementia. Initially, he remembered having nausea and vomiting at home, but was asymptomatic on evaluation. On physical exam, vital signs were notable for a blood pressure of 129/68mmHg, heart rate of 74 beats per minute (bpm), and oxygen saturation of 97% on two liters NC. Patient was tearful but in no distress. He had equal and reactive pupils, his heart rate was regular, breath sounds were clear, abdomen was soft, and he had a normal cranial nerve exam. Family in the room reported he was at his baseline mental status: delayed speech and

baseline dementia. They seemed unconcerned about any new or significant mental status changes.

Routine laboratory results were normal except for the following: white blood cell count 14.4×10^9 /liter, hemoglobin 10.0 g/dL, potassium 6.3 mmol/L, carbon dioxide 14 mmol/L, blood urea nitrogen 37 mg/dL, calcium 12.1 mg/dL, creatinine 2.3 mg/dL, and anion gap 23 mmol/L. Serum drug screen was negative for ethanol, acetaminophen, and salicylate. A 12-lead ECG showed normal sinus rate, with concern for peaked T-waves in the apical leads. A chest radiograph was read as persistent low lung volumes with bronchovascular crowding and bibasilar opacities, likely reflective of atelectasis.

The patient was treated for hyperkalemia with calcium gluconate, insulin, dextrose, and sodium bicarbonate; the Poison Control Center was updated on the findings and initial treatments. Within three hours, the potassium had corrected to 5.5 mg/dL and creatinine increased to 2.8 mg/dL. His mental status was unchanged. He continued to saturate in the low 90s, originally managed with two liters NC, but later requiring slight increases in his NC needs. Initially, it was thought that his lower saturations were attributed to a possible aspiration event, especially with reports of vomiting earlier in the morning.

About six hours into his ED visit, while pending admission, the nursing staff called providers to the room for an acute change in mental status with concomitant aspiration event. The patient's oxygen saturation acutely dropped to 85% on NC, and high-flow NC was initiated. The patient's saturation remained 85% on the Masimo SET™ pulse oximeter despite oxygen supplementation, and he was responsive to only painful stimulation. On auscultation, his lungs were clear bilaterally without wheezes or rales; his skin, especially distal, appeared gray and mottled. His blood pressure was 101/52 mmHg, and he became tachycardic to 101 bpm. A non-rebreather oxygen mask was applied at 15 liters and albuterol was administered with no change in respiratory status. Repeat radiograph was unchanged and it was thought this could be due to aspiration pneumonitis or acute respiratory distress syndrome. However, with the acute change, a venous blood gas was then also sent with the following notable results: pH of 7.22, methemoglobin of 45.6% and a lactate of 2.7 mmol/L.

Given this finding and the fact that his oxygen saturation remained the same on supplementation, the patient was diagnosed with methemoglobinemia. Subsequently, he was administered two doses of methylene blue (50 mg intravenously) 20 minutes apart. Over the next half-hour, his color and oxygen saturation improved, followed by a return of his mental status to baseline at initial presentation. A follow-up arterial blood gas at 45 minutes showed pH of 7.28 and methemoglobin of 9%. The patient was admitted to the intensive care unit.

The Poison Control Center was later updated. After research and testing, it was discovered that the components of the lava lamp ingested included 76% calcium nitrate, 23% water, and 1% potassium enol.

CPC-EM Capsule

What do we already know about this clinical entity?

Methemoglobinemia is a serious condition resulting in tissue hypoxia.

What makes this presentation of disease reportable?

There have been multiple case reports of ingestion of toxins leading to Methemoglobinemia, however, this is the first case report of a lava lamp being the inciting event.

What is the major learning point?

Keep Methemoglobinemia on your differential in any toxic ingestion, especially those who appear altered and have signs of hypoxia.

How might this improve emergency medicine practice?

Having this insight can help detect this disease earlier and allow patients to get proper treatment.

DISCUSSION

This patient survived after the ingestion of lava lamp contents later found to contain 76% calcium nitrate, which induced methemoglobinemia. It was originally presumed that the patient's change in respiratory status was secondary to aspiration, especially because he was only requiring two liters via NC for the majority of his ED visit. However, after his seemingly sudden decompensation, a venous blood gas ended up being a crucial test to help come to the correct diagnosis. We believe that the delay in his respiratory decompensation was likely secondary to delayed metabolism of calcium nitrates, producing levels significant enough to be clinically responsible for his methemoglobinemia symptoms.

The drug of choice in the treatment of severe methemoglobinemia is methylene blue.⁵ In the setting of drug- or toxin-induced methemoglobinemia, the actionable treatment level is generally considered to be 20% methemoglobin in symptomatic patients and 30% in asymptomatic patients.^{5,6,8} Normal methemoglobin levels are 1% - 3%.⁵ Methylene blue is available as a 1% solution (10 mg/ml).⁵ It is dosed at one to two mg/kg intravenous (IV) over three to five minutes. The time to peak concentration for IV methylene blue is 30 minutes, and the onset of action for

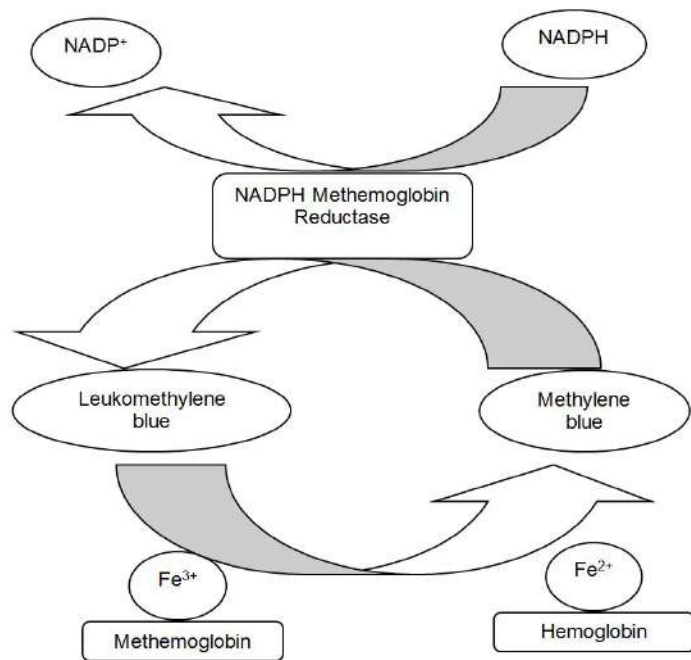


Figure. Methemoglobin process of metabolism. Fe^{2+} , ferrous state; Fe^{3+} , ferric state; $NADP^+$, nicotinamide adenine dinucleotide phosphate; $NADPH$, reduced state of nicotinamide adenine dinucleotide phosphate.

the reduction of methemoglobin is 30-60 minutes.⁶ Clinical response should be observed within one hour.⁸ The dose may be repeated at one mg/kg if methemoglobinemia does not resolve within 30 minutes to one hour, or if the patient's clinical status does not improve.⁶

At low concentrations, methylene blue enhances the reduction of methemoglobin to hemoglobin. It is converted to leukomethylene blue inside the red blood cell by erythrocyte methemoglobin reductase in the presence of nicotinamide adenine dinucleotide phosphate (NADPH). Leukomethylene blue is a reducing agent, and both compounds contribute to the reduction of methemoglobin in red blood cells.⁵ Methylene blue serves as a cofactor to accelerate NADPH-MetHemoglobin reductase. The ferric ion (Fe^{3+}) on methemoglobin is converted back to its oxygen-carrying state (Fe^{2+}), resulting in hemoglobin (see Figure).⁷

An alternative pharmacological option is high-dose ascorbic acid, colloquially known as Vitamin C. The mechanism of ascorbic acid in methemoglobinemia is purported to be due to an antioxidant effect, which is directly proportional to plasma concentrations. High doses (up to 10 grams) are required to rapidly achieve the necessary levels to achieve methemoglobin reduction. One notable concern for this treatment is that high doses increase urinary excretion of oxalate, which has been reported to cause oxalate nephropathy

in patients with renal impairment.⁹

In a case series reported from an institution where methylene blue was not available, five pediatric patients were successfully treated for methemoglobinemia with ascorbic acid. All patients required three or four doses of 1.5 to two grams intravenously, and their methemoglobin levels were reduced to non-toxic levels within 24 hours of treatment.¹⁰

No randomized controlled trials have been published to directly compare the two treatments, but methylene blue has traditionally been the agent of choice because of its rapid onset. Methylene blue has been shown to reduce methemoglobin to non-toxic levels within 10 to 60 minutes while ascorbic acid may require 24 hours to achieve the same effect. Additionally, ascorbic acid requires multiple doses much more frequently.^{9,10} Finally, in severe cases of methemoglobinemia, exchange transfusion and hyperbaric oxygen can also be used as adjunctive or monotherapy.^{11,12}

CONCLUSION

This case demonstrates the importance of considering methemoglobinemia in any patient with toxic ingestion of unknown contents, as well as those whose saturations do not improve with supplemental oxygen. It also demonstrates how precipitously patients with methemoglobinemia can desaturate over a short period of time. Methemoglobin should be considered in toxic ingestions, especially in substances that are not typically ingested with unknown contents. Lastly, if methemoglobinemia does present and if methylene blue is given, patients tend to respond to therapy within the hour and oxygen saturations can be expected to improve rapidly.

Documented patient informed consent and/or Institutional Review Board approval has been obtained and filed for publication of this case report.

Address for Correspondence: Chanel E. Fischetti, MD, University of California, Irvine Medical Center, Department of Emergency Medicine, 333 City Boulevard West, Suite 640, Orange, CA 92868. Email: cefischetti@gmail.com.

Conflicts of Interest: By the CPC-EM article submission agreement, all authors are required to disclose all affiliations, funding sources and financial or management relationships that could be perceived as potential sources of bias. The authors disclosed none.

Copyright: © 2018 Funke et al. This is an open access article distributed in accordance with the terms of the Creative Commons Attribution (CC BY 4.0) License. See: <http://creativecommons.org/licenses/by/4.0/>

REFERENCES

1. Rehman H. Methemoglobinemia. *West J Med.* 2001;175(3):193-6.
2. Askew GL, Finelli L, Genesa CA, et al. Boilerbaisse: an outbreak of methemoglobinemia in New Jersey in 1992. *Pediatrics.* 1994;94(3):381-4.
3. Ohashi K, Yukioka H, Hayashi M, et al. Elevated methemoglobin in patients with sepsis. *Acta Anaesthesiol Scand.* 1998;42(6):713-6.
4. Saxena H, Prakash, Saxena A. Acute methaemoglobinaemia due to ingestion of nitrobenzene (paint solvent). *Indian J Anaesth.* 2010;54(2):160-2.
5. Curry S. Methemoglobinemia. *Ann Emerg Med.* 1982;11(4):214-21.
6. Clifton J 2nd, Leikin JB. Methylene blue. *Am J Ther.* 2003;10(4):289-91.
7. Methylene blue [prescribing information]. Lake Forest, IL: Akorn Inc: July 2016.
8. Wright RO, Lewander WJ, Woolf AD. Methemoglobinemia: etiology, pharmacology, and clinical management. *Ann Emerg Med.* 1999;34(5):646-56.
9. Lee KW, Park SY. High-dose vitamin C as treatment of methemoglobinemia. *Am J Emerg Med.* 2014;32(8):936.
10. Rino PB, Scolnik D, Fustinana A, et al. Ascorbic acid for the treatment of methemoglobinemia: the experience of a large tertiary care pediatric hospital. *Am J Ther.* 2014;21(4):240-3.
11. Jansen T, Barnung S, Mortensen CR, et al. Isobutyl-nitrite induced methemoglobinemia; treatment with an exchange blood transfusion during hyperbaric oxygenation. *Acta Anesthesiol Scand.* 2003;47(10):1300-1.
12. Cho Y, Park SW, Han S, et al. A case of methemoglobinemia successfully treated with hyperbaric oxygenation therapy. *J Emerg Med.* 2017;53(5):685-7.

Stump Appendicitis

Alex C. Essenmacher, MD*

Emma Nash, MD †

Sarah K. Walker, MD‡

Graeme J. Pitcher, MB, BCh‡

Christopher T. Buresh, MD, MPH †

T. Shawn Sato, MD*

* University of Iowa Hospitals and Clinics, Department of Radiology, Iowa City, Iowa

† University of Iowa Hospitals and Clinics, Department of Emergency Medicine, Iowa City, Iowa

‡ University of Iowa Hospitals and Clinics, Department of Surgery, Division of Pediatric Surgery, Iowa City, Iowa

Section Editor: Rick A. McPheeters, DO

Submission history: Submitted January 26, 2018; Revision received March 26, 2018; Accepted March 28, 2018

Electronically published May 18, 2018

Full text available through open access at http://escholarship.org/uc/uciem_cpem

DOI: 10.5811/cpem.2018.3.37730

Abdominal pain is a frequent problem encountered in the emergency department, and acute appendicitis is a well-recognized diagnosis. Laparoscopic appendectomy has become one of the most common surgical procedures in the United States. Patients with a history of appendectomy may experience recurrent right lower quadrant abdominal pain from an infrequently encountered complication that may occur when the residual appendix becomes obstructed and inflamed. We describe two cases of stump appendicitis in pediatric patients with a review of clinical and imaging findings and surgical management. [Clin Pract Cases Emerg Med. 2018;2(3):211–214.]

INTRODUCTION

Abdominal pain is a common complaint in pediatric emergency visits, accounting for about 460,000 yearly visits for females under 15 years old and 314,000 for males under 15. Common entities such as appendicitis are diagnoses entertained early in the evaluation by emergency physicians; however, this diagnosis is often quickly ruled out in patients with a prior history of appendectomy. The provider must be familiar with complications of appendectomy such as retained stones and, as illustrated, stump appendicitis. Although rare, with a reported incidence of 1 in 50,000 appendectomies,¹ under-recognition can cause a significant delay in diagnosis and treatment, leading to severe complications. We review two cases of children presenting with abdominal pain after previous laparoscopic appendectomies. These cases highlight the importance of being familiar with this unusual entity as well as the value of serial abdominal examinations and utilization of imaging including ultrasound.

CASE REPORT

Case One

An 11-year-old male presented to the emergency department (ED) with abdominal pain of one night duration causing difficulty with sleeping and ambulation. Of note,

the patient denied loss of appetite, vomiting, and fever. Past surgical history was significant for appendectomy 19 months prior after presenting with similar symptoms and being diagnosed with appendicitis sonographically. There were no reported operative or postoperative complications.

Upon presentation the patient had not had a bowel movement in several days, and the initial leading differential diagnosis was constipation. Physical examination was significant for fever and localized peritonitis. Pertinent laboratory investigations at current presentation included leukocytosis of 13,300 per cubic millimeter (reference range 4,500-13,000), neutrophilia of 9,870 per cubic millimeter (reference range 1,700-7,500), and an elevated C-reactive peptide to 1.4 milligrams per deciliter (reference range <0.5). After antipyretics, repeat assessment showed a reduction in fever; however, the patient still had severe abdominal pain. A point-of-care ultrasound showed a normal-appearing gallbladder and no dilation of the common bile duct but demonstrated an aperistaltic mass in the right lower quadrant (RLQ).

After consulting with the pediatric surgery team, contrast-enhanced computed tomography of the abdomen and pelvis was performed and demonstrated surgical changes of appendectomy with staple lines at the blind end of the appendiceal stump. A high-density appendicolith

was obstructing the base of the appendiceal stump, which was surrounded by mesenteric fat stranding (Image 1). Thickening of the appendiceal wall and the peritoneal reflection of the RLQ were additional findings consistent with acute appendicitis. There was no pneumoperitoneum. The patient was admitted and taken for laparoscopic surgery the next day. Surgical exploration revealed an inflamed appendiceal stump with pus in the right paracolic gutter. The appendiceal wall was very friable, and the stump required piecemeal removal during which time two appendicoliths were discovered in the lumen. The base was stapled flush with the cecum ensuring that no residual appendicoliths were present. The patient was discharged on postoperative day 3 and reported good recovery at follow-up appointments.

Pathology confirmed that the stump was necrotic, in two 2 cm long portions, with one portion containing a large appendicolith.

Case Two

An 11-year-old female patient with a past medical history significant for appendicitis treated with laparoscopic appendectomy two months prior presented to a local ED with a one-day history of epigastric and right-sided abdominal pain, poor oral intake, and emesis. Prior to transfer to the university hospital, contrast-enhanced computed tomography of the abdomen and pelvis demonstrated a fluid collection in the right pericolic gutter at the site of surgical changes of appendectomy. The collection contained small stones (Image 2) and small foci of extraluminal air. There was also a small amount of frank pneumoperitoneum consistent with rupture of the appendiceal stump or dehiscence of the sutures.

Upon transfer, the patient was febrile and tachycardic. She was taken for laparoscopic appendectomy during which an inflamed, approximately 5 cm-long stump was encountered with an obvious appendicolith at its base adjacent to the cecum. The site of perforation was not readily evident, but there was evidence of recent peritoneal spillage and contamination. The previous staple line was readily apparent at the end of the stump. The appendectomy was completed by passing a stapling device proximal to the appendicolith and resecting the stump.

Pathology confirmed an inflamed, 5 cm appendix containing two large fecoliths. After gradual clinical improvement, she was discharged on postoperative day 4. Residual postoperative pain was well controlled with acetaminophen.

DISCUSSION

Stump appendicitis is an uncommon entity; consequently it is rarely entertained as a diagnosis in a patient who has previously undergone an appendectomy, which may lead to a delay in diagnosis. One case series found perforation at the appendiceal stump in 60% of cases.² Stump appendicitis may be significantly under-reported in the literature. Since 1945 there have only been about 60 cases reported in the

CPC-EM Capsule

What do we already know about this clinical entity?

Stump appendicitis has an estimated incidence of 1 in 50,000 and can occur after both open and laparoscopic surgeries, months to years after initial removal.

What makes this presentation of disease reportable?

Stump appendicitis is not well described in the emergency medicine literature. These patients had an evolving abdominal exam consistent with appendicitis despite their surgical history.

What is the major learning point?

These cases highlight the importance of being familiar with this unusual entity, as well as the value of serial abdominal examinations and use of imaging including ultrasound.

How might this improve emergency medicine practice?

Increased awareness of this disease process among emergency physicians could prevent delayed diagnosis and complications.

English medical literature.³⁻¹⁰ It has been reported following laparoscopic as well as open appendectomy, and can occur many years after the original operation.^{11,12} It is thought to be more common following laparoscopic appendectomy,² but a comparison to the open technique will become more difficult as that approach becomes less frequent. It is widely believed to be the result of a surgical illusion with respect to the actual location of the appendiceal base. This may be made more difficult by inflammatory changes and is probably more common after complicated appendicitis. Some authors suggest an appendiceal critical view¹³ similar to that described for cholecystectomy¹⁴ to avoid this problem.

The decision to use medical imaging in children can be difficult. While it is important to adequately rule out dangerous pathologies, it is also important to limit ionizing radiation doses in children. Ultrasound can be a screening tool to evaluate some etiologies of abdominal pain,¹⁵ but computed tomography with oral and intravenous contrast may be required for a definitive diagnosis in complicated and unusual cases such as these.

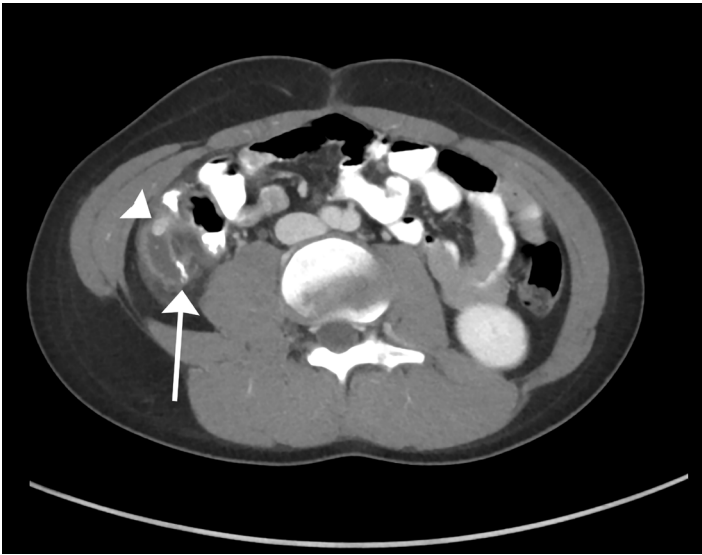

Image 1. Contrast-enhanced computed tomography of the abdomen and pelvis, oblique axial plane, demonstrating surgical changes of appendectomy with staple lines at the blind end of the appendiceal stump (arrow). A high-density appendicolith (arrowhead) was obstructing the base of the appendiceal stump, which was surrounded by inflammatory changes.

Pediatric patients presenting with abdominal pain often have an attributable, nonsurgical cause such as constipation or gastroenteritis. In the first case, the patient was initially afebrile, decreasing concern for a serious bacterial illness. However, he developed a fever throughout his ED course, and his abdominal exam became more concerning, illustrating the importance of observation and serial examination when the diagnosis is uncertain. Anchoring on a common diagnosis, such as constipation, and discharging the patient prior to the evolution of the fever could have devastating consequences.

CONCLUSION

Stump appendicitis is an uncommon complication after appendectomy. It is important for physicians to be aware of this entity to ensure timely diagnosis and treatment of this unusual condition. With the increased utilization of laparoscopy for appendix resection, there may be an increased incidence of stump appendicitis after appendectomy, and it is important not to exclude appendicitis from the differential diagnosis based on prior history of appendectomy.

Documented patient informed consent and/or Institutional Review Board approval has been obtained and filed for publication of this case report.

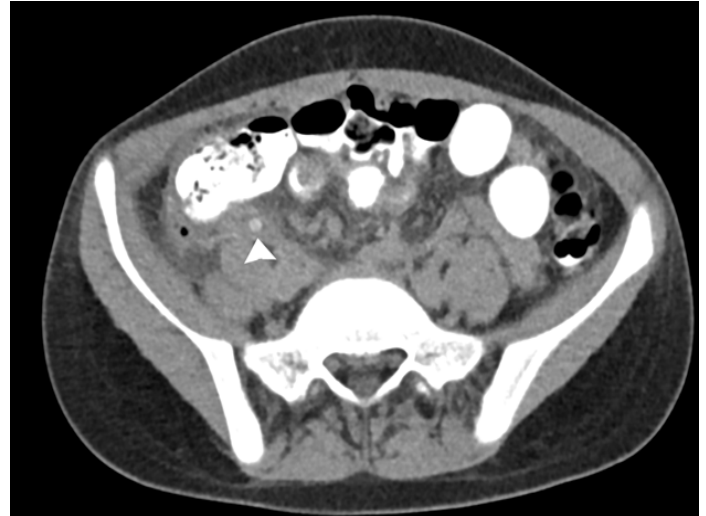

Image 2. Axial contrast-enhanced computed tomography of the abdomen and pelvis in delayed phase demonstrating inflammation and extraluminal air in the right lower quadrant at the appendectomy site with high-density appendicoliths (arrowhead).

Address for Correspondence: Alex C. Essenmacher, MD, University of Iowa Hospitals and Clinics, Department of Radiology, 200 Hawkins Drive, Iowa City, Iowa 52242-1077. Email: alex-essenmacher@uiowa.edu.

Conflicts of Interest: By the *CPC-EM* article submission agreement, all authors are required to disclose all affiliations, funding sources and financial or management relationships that could be perceived as potential sources of bias. The authors disclosed none.

Copyright: © 2018 Essenmacher et al. This is an open access article distributed in accordance with the terms of the Creative Commons Attribution ([CC BY 4.0](http://creativecommons.org/licenses/by/4.0/)) License. See: <http://creativecommons.org/licenses/by/4.0/>

REFERENCES

1. Hendahewa R, Shekhar A, Ratnayake S. The dilemma of stump appendicitis - a case report and literature review. *Int J Surg Case Rep.* 2015;14:101-3.
2. Roberts KE, Starker LF, Duffy AJ, et al. Stump appendicitis: a surgeon's dilemma. *JLS.* 2011;15(3):373-8.
3. Thomas SE, Denning DA, Cummings MH. Delayed pathology of the appendiceal stump: a case report of stump appendicitis and review. *Am Surg.* 1994;60(11):842-4.
4. Liang MK, Lo HG, Marks JL. Stump appendicitis: a comprehensive review of literature. *Am Surg.* 2006;72(2):162-6.
5. Johnston J, Myers DT, Williams TR. Stump appendicitis: surgical background, CT appearance, and imaging mimics. *Emerg Radiol.*

- 2015;22(1):13-8.
6. Rios RE, Villanueva KM, Stirparo JJ, et al. Recurrent (stump) appendicitis: a case series. *Am J Emerg Med.* 2015;33(3):480.e1-480.e2.
 7. Geraci G, Di Carlo G, Cudia B, et al. Stump appendicitis. A case report. *Int J Surg Case Rep.* 2016;20:21-3.
 8. Parthasarathi R, Jankar SV, Chittawadgi B, et al. Laparoscopic management of symptomatic residual appendicular tip: A rare case report. *J Min Access Surg.* 2017;13(2):154-6.
 9. Shah T, Gupta RK, Karkee RJ, et al. Recurrent pain abdomen following appendectomy: stump appendicitis, a surgeon's dilemma. *Clin Case Rep.* 2017;5(3):215-7.
 10. Giwa A, Reyes M. Three times a charm... a case of repeat appendicitis status post two prior appendectomies. *Am J Emerg Med.* 2018;36(3):528.e1-528.e2.
 11. Maurice AP, Ibrahim H, Franz R, et al. Stump appendicitis 5 years after laparoscopic appendectomy. *BMJ Case Rep.* 2016. In Press.
 12. Van Paesschen C, Haenen F, Bestman R, et al. Stump appendicitis 10 years after appendectomy, a rare but serious complication of appendectomy, a case report. *Acta Chir Belg.* 2017;117(1):49-51.
 13. Subramanian A, Liang MK. A 60-year literature review of stump appendicitis: the need for a critical view. *Am J Surg.* 2012;203(4):503-7.
 14. Strasberg SM, Hertl M, Soper NJ. An analysis of the problem of biliary injury during laparoscopic cholecystectomy. *J Am Coll Surg.* 1995;180(1):101-25.
 15. Kim C, Kang BS, Choi HJ, et al. Clinical application of real-time tele-ultrasonography in diagnosing pediatric acute appendicitis in the ED. *Am J Emerg Med.* 2015;33(10):1354-9.

Alteplase Causing Cardiac Tamponade after Recent Cardiac Pacemaker Placement

Corey J. Warf, MD
Martin R. Huecker, MD
Daniel J. O'Brien, MD
Don A. Bertolotti, MD

University of Louisville, Department of Emergency Medicine, Louisville, Kentucky

Section Editor: Manish Amin, DO

Submission history: Submitted February 1, 2018; Revision received April 5, 2018; Accepted April 19, 2018

Electronically published May 18, 2018

Full text available through open access at http://escholarship.org/uc/uciem_cpchem

DOI: 10.5811/cpchem.2018.4.37825

A 56-year-old female presented to the emergency department with evolving cardiac tamponade after receiving alteplase for acute ischemic stroke. This is the first case report of cardiac tamponade from thrombolytics in the setting of recent pacemaker placement. Point-of-care ultrasound was used to make the diagnosis quickly and expedite the patient to the operating room where a pericardial window was performed. [Clin Pract Cases Emerg Med. 2018;2(3):215–218.]

INTRODUCTION

The risks and benefits of thrombolysis for ischemic stroke are well established, with defined absolute and relative contraindications.¹ The alteplase package insert lists major surgery (e.g., coronary artery bypass graft, obstetrical delivery, and organ biopsy) as a warning but not an absolute contraindication, while the American Heart Association considers surgery a relative contraindication.² The European Stroke Organization does not list surgery as a contraindication.³ Following pacemaker implantation, systemic hemorrhage has occurred following thrombolytic administration,⁴ but there are no reports of pericardial effusion or tamponade.

A history of myocardial infarction (MI) within the prior three months is considered a relative contraindication to the administration of intravenous thrombolytics for acute stroke according to American Heart Association guidelines but not per the European guidelines.^{1,3} The risk of thrombolytics to this population includes risk of myocardial hemorrhage predisposing to myocardial wall rupture, pericarditis following MI that may progress to a hemorrhagic pericardial effusion, and embolization from possible ventricular aneurysm.⁵ There are several case reports of hemopericardium and cardiac rupture following thrombolytic therapy for acute stroke.⁶ Only one case had a confirmed prior MI within three months of receiving thrombolytic therapy. None of these cases reported a history of recent cardiac surgery or pacemaker placement.

Pericarditis is not an uncommon complication following pacemaker implantation, with a rate of 2% previously reported in a case series of 395 patients.⁷ Risk of bleeding in the setting of pericarditis is perceived as a potential risk, though this is not supported by the literature.^{8,9} There are prior examples of pericardial effusion in the setting of anticoagulation and pacemaker placement.¹⁰ However, we present a novel case with a combination of factors not previously reported: use of thrombolytics for ischemic stroke; very recent pacemaker placement (less than one week prior); and use of point-of-care ultrasound (POCUS) to quickly make the diagnosis and expedite the disposition of the patient.

CASE REPORT

We present the case of a 56-year-old female with history of syncope due to third degree atrioventricular heart block presenting initially with onset of stroke symptoms six days after pacemaker placement and two days after hospital discharge. At 5 PM she developed abrupt onset of left facial droop along with left upper and lower extremity weakness. The patient was initially treated at an outlying hospital and received alteplase at 6:35 PM for treatment of acute ischemic stroke.

A chest radiograph performed at the outlying hospital prior to alteplase administration demonstrated an enlarged cardiac silhouette when compared to prior radiographs showing only borderline cardiomegaly. Upon administration, the

patient reported mild chest pain and was given nitroglycerine and morphine. Her chest pain resolved and she was transferred to our comprehensive stroke center for admission. The patient presented to our emergency department at 10:10 PM with a heart rate of 122 beats per minute (bpm) and a blood pressure of 109/41 millimeters of mercury (mmHg).

At 11:20 PM the patient went for a computed tomography angiogram (CTA) after an initial assessment by the emergency physician in consultation with the stroke-team attending physician. After CTA at 10:28 PM, she was documented to have a blood pressure of 49/25 mmHg and heart rate of 109 bpm. She was returned to the resuscitation bay for re-evaluation. Cardiac tamponade was suspected due to the extreme hypotension in the setting of thrombolytic administration after recent pacemaker placement.

On reassessment, the patient had become confused with a Glasgow Coma Scale of 14. The emergency physician performed a POCUS, which demonstrated a pericardial effusion with features of cardiac tamponade including diastolic collapse of the right ventricle (Image). At that point the diagnosis of cardiac tamponade was made. The patient was alert and responsive, so an intravenous bolus of normal saline was given while a stat surgical consult was obtained. The surgical team evaluated the patient at the bedside within minutes and was able to review the POCUS findings. As the patient was conscious, they elected to take her immediately to the operating room rather than perform a bedside pericardiocentesis.

While in the operating room, approximately 400 milliliters of coagulated blood were evacuated from the pericardial sac with 150 milliliters of surgical bleeding. The operative report notes resolution of tachycardia following this intervention with heart rate trending down to a range of 80-90 bpm with concomitant improvement in blood pressure. She was discharged two days post-operatively with a pericardial catheter in place. Echocardiogram performed on day of discharge noted a small, residual pericardial effusion.

DISCUSSION

Although no source of bleeding was identified intra-operatively during the pericardial window, we suspect that a small cardiac perforation occurred during pacemaker placement. Significantly, echocardiogram performed on the day of pacemaker placement immediately following the procedure noted no pericardial effusion. Given the temporal association between the development of tamponade physiology and the administration of alteplase, we believe that administration of thrombolytic medication led to recurrent bleeding and further progression of pericardial hemorrhage and the development of tamponade physiology by the time of the patient's arrival to our tertiary care center.

It is also noteworthy that point-of-care cardiac ultrasound was performed within 10 minutes of the patient developing hypotension, which led to an

CPC-EM Capsule

What do we already know about this clinical entity?

Pericardial effusions as a complication of pacemaker placement have been reported in anticoagulated patients but never in the setting of alteplase administration.

What makes this presentation of disease reportable?

We report a novel combination of use of thrombolytics for ischemic stroke, very recent pacemaker placement, and use of bedside ultrasound to diagnose cardiac tamponade.

What is the major learning point?

Cardiac tamponade is a potential risk of administration of alteplase in patients with recent cardiac procedures and should be considered when hypotension is present.

How might this improve emergency medicine practice?

Knowing this complication of alteplase administration may improve early diagnosis of pericardial tamponade in patients with a history of recent cardiac procedures.

immediate management change for this patient. She went immediately to the operating room based entirely on the POCUS findings. One question that remains unresolved is whether pericardial effusion was present prior to alteplase administration. As noted above, the outlying hospital chest radiograph demonstrated an enlarged cardiac silhouette compared to previous imaging at their facility, possibly representing the presence of pericardial effusion. Chest radiograph performed at the facility where pacemaker placement was performed noted stable cardiomegaly, which was followed by two-dimensional echocardiogram where no effusion was seen. Thus, it is unclear whether further change in the cardiac silhouette developed in this six-day span. However, the time between the chest radiograph being performed at the outlying facility and the administration of alteplase was greater than 60 minutes. Had ultrasound been performed at the outlying hospital during this time span, a pericardial

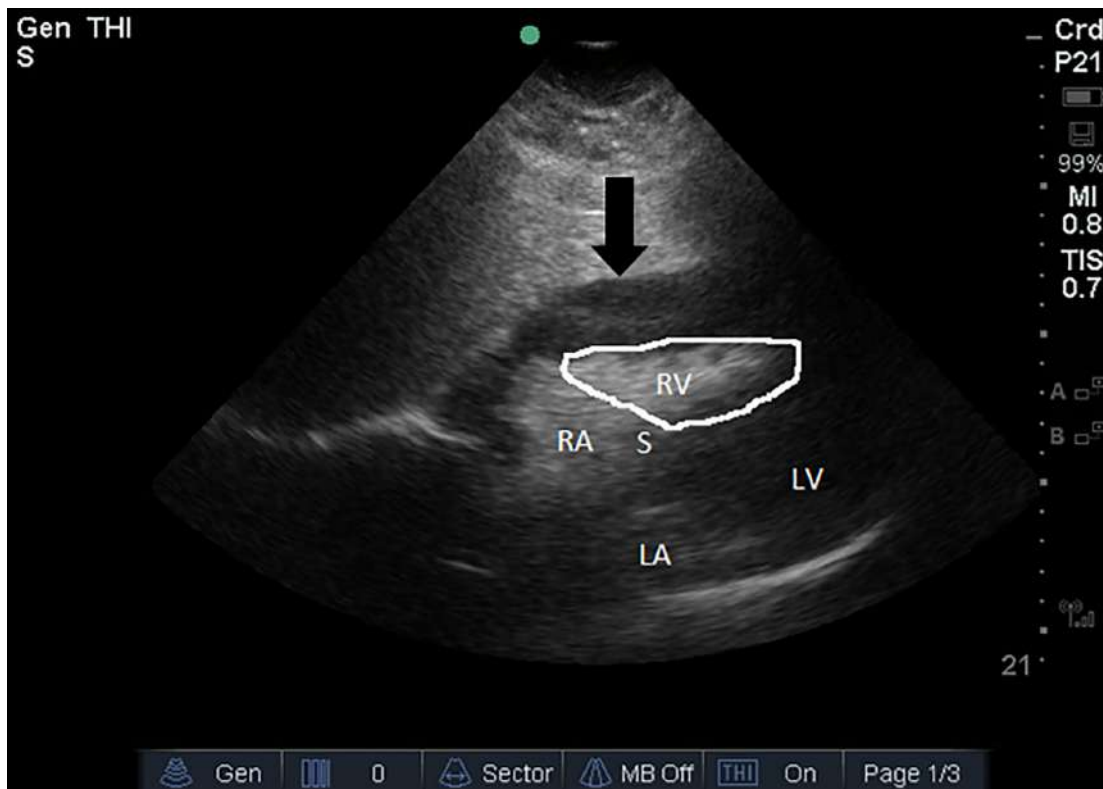


Image. Point-of-care ultrasound, subxiphoid view of the heart demonstrating a large pericardial effusion (arrow) with diastolic collapse of the right ventricle (outlined). The black arrow points to the pericardium with the large effusion contained within. RV, right ventricle; LV, left ventricle; RA, right atrium; LA, left atrium; S, intraventricular septum.

effusion may have been identified. This would have been a contraindication to the administration of thrombolytics in this patient.

CONCLUSION

Though major surgery is listed as a relative contraindication to alteplase, we recommend proceeding with caution in patients who have had any recent surgical procedure. We also stress the importance of assessment with ultrasound in patients at risk for pericardial effusion or cardiac complications from thrombolytic administration. We also recommend considering the use of point-of-care ultrasound to further evaluate patients with abnormal chest radiograph findings if the clinical scenario indicates a possible cardiac etiology. Finally, we highlight the importance of reassessment to recognize complications of high-risk medications such as thrombolytics.

Documented patient informed consent and/or Institutional Review Board approval has been obtained and filed for publication of this case report.

Address for Correspondence: Corey J. Warf, MD, University of Louisville, Department of Emergency Medicine, 530 South Jackson Street, Suite C1H17, Louisville, KY 40202. Email: cjwarf01@louisville.edu.

Conflicts of Interest: By the CPC-EM article submission agreement, all authors are required to disclose all affiliations, funding sources and financial or management relationships that could be perceived as potential sources of bias. The authors disclosed none.

Copyright: © 2018 Warf et al. This is an open access article distributed in accordance with the terms of the Creative Commons Attribution (CC BY 4.0) License. See: <http://creativecommons.org/licenses/by/4.0/>

REFERENCES

1. Jauch EC, Saver JL, Adams HP Jr, et al. Guidelines for the early management of patients with acute ischemic stroke: a guideline for healthcare professionals from the American Heart Association/American Stroke Association. *Stroke*. 2013;44(3):870–947.
2. Alteplase(R)[Package insert]. South San Francisco, CA.

- Genentech, Inc; 2015.
3. European Stroke Organisation (ESO) Executive Committee, ESO Writing Committee. Guidelines for Management of Ischaemic Stroke and Transient Ischaemic Attack 2008. *Cerebrovasc Dis*. 2008;25(5):457–507.
 4. Guilan M, Alonso-Canovas A, Garcia-Caldentey J, et al. Off-label intravenous thrombolysis in acute stroke. *Eur J Neurol*. 2012;19(3):390–4.
 5. Fugate J, Rabinstein A. Absolute and relative contraindications to IV rt-PA for acute ischemic stroke. *Neurohospitalist*. 2015;5(3):110-21.
 6. Kasner SE, Villar-Cordova CE, Tong D, et al. Hemopericardium and cardiac tamponade after thrombolysis for acute ischemic stroke. *Neurology*. 1998;50(6):1857-9.
 7. Levy Y, Shovman O, Granit C, et al. Pericarditis following pacemaker insertion. *Isr Med Assoc J*. 2004;6(10):599-602.
 8. Imazio M, Cecchi E, Demichelis B, et al. Indicators of poor prognosis of acute pericarditis. *Circulation*. 2007;115(21):2739.
 9. Imazio M, Cecchi E, Demichelis B, et al. Myopericarditis versus viral or idiopathic acute pericarditis. *Heart*. 2008;94(4):498.
 10. Nakanishi H, Kashiwase K, Nishio M, et al. Recurrent pericardial effusion caused by pacemaker lead perforation and warfarin therapy at seven years after implantation. *Europace*. 2012;14(2):297.

Fatal Influenza B Myocarditis in a 34-Year-Old Female

Taylor Dickey, MSIII*
Melanie Schweir, MSIII*
Matthew Hysell, MD†

*Michigan State University College of Osteopathic Medicine, East Lansing, Michigan
†Lakeland Health, Department of Emergency Medicine, Saint Joseph, Michigan

Section Editor: Rick A. McPheeters, DO

Submission history: Submitted January 25, 2018; Revision received March 14, 2018; Accepted March 28, 2018

Electronically published May 29, 2018

Full text available through open access at http://escholarship.org/uc/uciem_cpccem

DOI: 10.5811/cpcem.2018.3.37718

A 34-year-old female reported to the emergency department with a chief complaint of epigastric pain. Initial rapid screening was negative for both influenza A and B. The patient eventually developed myocarditis that led to pulseless ventricular tachycardia and death within 24 hours of admission. Viral smear was positive for influenza B postmortem despite the initial negative rapid screen. This case demonstrates the need for a new diagnostic criteria and treatment strategy for viral myocarditis due to influenza while concisely illustrating how the disease can progress in adults despite commonly presenting as a disease in adolescents. [Clin Pract Cases Emerg Med. 2018;2(3):219–222.]

INTRODUCTION

Myocarditis can be an exceptionally challenging diagnosis to make due to its multiple etiologies, highly variable nonspecific presentations, and the lack of universal treatment standards.¹ Therefore, it is also highly under-reported. The most common mechanism of myocarditis involves an invading virus through either the respiratory or gastrointestinal tract. These viruses infect cardiac myocytes causing an inflammatory reaction. Native macrophages and dendritic cells then form a response that triggers the release of cross-reactive self-antigens, leading to a T-cell mediated autoimmune response that further injures cardiac myocytes.¹ Delayed cardiac manifestations such as arrhythmias, congestive heart failure, sinus tachycardia, and embolic events can occur days or even weeks after the initial viral infection.¹ Untreated, this may eventually lead to unfavorable outcomes such as dilated cardiomyopathy, ventricular tachycardia, and sudden cardiac death.²

The classic culprits of viral myocarditis historically include Coxsackie virus, cytomegalovirus, and echovirus. However, there has been increasing evidence of influenza virus causing myocarditis in recent years. Based on the results of Karjalainen et al., the true incidence of myocarditis could be as high as 9%.³ Influenza B carries the lowest risk of developing myocarditis at 0.7% compared to type A (1.3%) and type C (3.6%).⁴ Additionally, 69% of patients who died due to an influenza B infection had some evidence of myocardial injury on autopsy report.⁵ However, most of

these patients were younger than 18 years of age. Myocarditis caused by influenza B has rarely been reported in adults.⁶

CASE REPORT

A 34-year-old female was brought to the emergency department (ED) by family with a chief complaint of severe epigastric pain. Her symptoms, which had begun five days earlier, consisted of general malaise, self-reported low-grade fevers, and a non-productive cough in addition to her epigastric pain. She had taken off work for the prior three days due to her symptoms. She reported one instance of nausea and vomiting the day prior to her ED admission. She denied any history of dysuria, hematuria, headache, or neck stiffness. Past medical history was significant for polycystic ovarian syndrome and attention deficit hyperactive disorder. Past surgical history was notable for a remote appendectomy and cholecystectomy. Social history revealed that she had quit smoking 10 years prior and drank one alcoholic beverage on average per day. She denied any recreational or intravenous (IV) drug abuse.

Triage temperature was 97.5°F, heart rate was 71 beats per minute (BPM), blood pressure measured at 136/93, respiratory rate was 20, and her oxygen saturation was 98% on room air. Approximately 20 minutes after triage, the patient remained afebrile but her heart rate had increased to 125 and blood pressure decreased to 96/56. She appeared fatigued and slightly diaphoretic. Her oropharynx was clear and moist, neck was supple with full range of motion, cardiac examination

revealed no evidence of a murmur, and she displayed normal respiratory effort without any signs of distress or wheezing. Her abdomen was soft and non-tender without rebound or guarding. Urinalysis showed a specific gravity of 1.024, trace ketones, 0-2 white blood cell count per high power field (HPF), 0-2 red blood cells per HPF, and 16-20 hyaline casts. Urine pregnancy test, mycoplasmal immunoglobulin M, and influenza A/influenza B rapid screen were all negative. Chest radiograph was negative for pathology and showed a heart size and vascularity within normal limits, with clear and fully expanded lungs. Blood test results are displayed in the table below.

Table. Notable components of complete blood count, blood metabolic panel, liver enzymes, and lipase.

Blood plasma, serum	Value
White blood cells	16,500/m ³
Polymorphonuclear leukocytes	81%
Hemoglobin	19 g/dL
Platelets	287,000/mm ³
Sodium	132 mEq/L
Potassium	4.2 mEq/L
Chloride	100 mEq/L
Bicarbonate	16 mEq/L
Blood urea nitrogen	20 mg/dL
Creatinine	1.1 mg/dL
Glucose	158 mg/dL
Aspartate aminotransferase	36 U/L
Alanine aminotransferase	24 U/L
Bilirubin	0.9 mg/dL
Lipase	33 U/L

Fluid resuscitation was started upon arrival to the ED. Despite infusing four liters of normal saline over the course of four hours, the patient's blood pressure never increased above a systolic pressure of 100 and she remained borderline hypotensive. Her admitting diagnosis was systemic inflammatory response syndrome (SIRS) due to a presumed viral but undetermined etiology with hypovolemia. At the time of admittance, her vital signs were a temperature of 97.5°F, a heart rate of 116 BPM, a respiratory rate of 18 breaths per minute, and a blood pressure of 94/67. She received ondansetron for nausea.

The next morning, the patient complained of worsening symptoms of malaise and weakness while denying any shortness of breath, cough, chest pain, headache, diarrhea, or anxiety. Except for her blood pressure, which had dropped to 80/50, her

CPC-EM Capsule

What do we already know about this clinical entity?

Myocarditis is one of the more rare, but potentially fatal, complications of influenza typically seen in the adolescent population.

What makes this presentation of disease reportable?

Viral myocarditis typically presents in the adolescent population. However, in this case the patient was an adult with multiple negative diagnostic tests.

What is the major learning point?

It is essential to keep viral myocarditis on the differential in adults and even when diagnostic tests come back negative.

How might this improve emergency medicine practice?

This case points out the challenges and inefficiencies of diagnosing viral myocarditis in the emergency setting.

vitals were stable. She was given a seventh liter of fluid with modest improvement of her blood pressure, but she remained clammy and required a central line placement in the intensive care unit (ICU). Physical examination was significant for mild epigastric tenderness and acrocyanosis. At this time, she was diagnosed with dehydration secondary to severe sepsis with septic shock. She was given ceftriaxone, vancomycin, and doxycycline to cover meningococcus, methicillin-resistant *Staphylococcus aureus*, and rickettsia. Additionally, blood cultures and an electrocardiogram (ECG) were ordered and revealed questionable 0.5mm ST-segment elevation of lateral chest leads (Image). Troponin I was elevated at 0.47 ng/ml.

The patient was sent for abdominal computed tomography (CT) to look for a cause of sepsis. The imaging showed some atelectasis/bibasilar infiltrates with small bilateral pleural effusions as well as patchy enhancement of the kidneys concerning for pyelonephritis, but no significant pulmonary edema or cause of sepsis. After completing the CT, the patient decompensated into pulseless ventricular tachycardia and eventual death despite attempts at resuscitation. A postmortem influenza smear was negative for influenza A, parainfluenza A1-A4, and positive for influenza B. This finding, coupled with

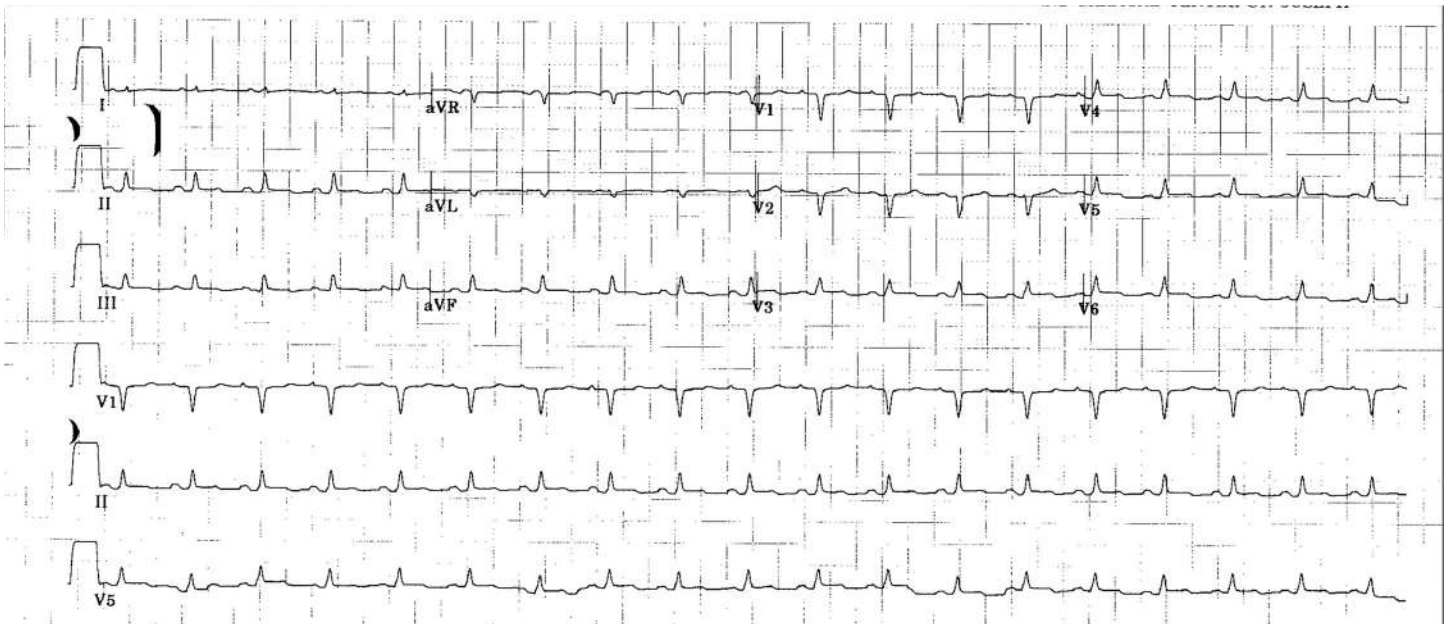


Image. Electrocardiogram revealed mild ST-segment elevation of lateral chest leads.

inflammation of the myocardium on the autopsy, led to the diagnosis of fatal myocarditis caused by influenza B.

DISCUSSION

A review of literature revealed few confirmed, documented cases of myocarditis secondary to influenza, and even fewer cases of myocarditis specifically caused by influenza B. The case shared some common themes with the other presentations. For example, hypotension refractory to IV fluids was a common finding.^{7,8} Additionally, ST-segment elevations on ECG are a common theme related to myocarditis.^{4,7,8} Finally, a positive culture is a required part of diagnosing myocarditis secondary to infection.^{4,7,8} However, there were some aspects of this case that deviated from the norm: Most cases of viral infection causing myocarditis are seen in the young adult population, while our patient was 34 years old.^{4,7} Furthermore, influenza B is a rare cause of myocarditis compared to the more common offenders such as Coxsackie virus.

Furthering the difficulty of this diagnosis lies in accuracy of testing. Diagnosis of influenza B via reverse transcriptase polymerase chain reaction relies on a sensitivity of 54% in adults and 62% overall, which is lower than the sensitivity for influenza A (65% overall).⁹ Diagnosis of viral myocarditis is based on the Dallas criteria, which require an endomyocardial biopsy consisting of an inflammatory infiltration with necrosis and/or degeneration of adjacent myocytes.¹⁰ This pathologic definition has been criticized for inaccuracy in the medical community, especially considering that endomyocardial biopsies only meet these specific definitive criteria with successful diagnosis rates of 25%.¹¹

In the treatment of influenza, oseltamivir phosphate is thought to be most efficacious within 48 hours from the onset of symptoms. In patients admitted to the ICU with hemagglutinin type 1 and neuraminidase type 1 influenza, there was a reported 75% survival rate in patients given oseltamivir phosphate within the time constraint (compared to 58% survival rate if left untreated).¹² However, oseltamivir phosphate administered within five days still showed some benefit in disease progression.¹² The combination of these factors makes the diagnosis of myocarditis caused by influenza B an exceptionally difficult, yet dangerous, diagnosis to miss.

CONCLUSION

We present an adult female with myocarditis secondary to influenza B infection. The case was complicated by low sensitivity of rapid influenza screening, inconsistent diagnosing criteria, and questionable treatment strategies. To better serve the population of patients that develop myocarditis from influenza, we need better-defined strategies to approach, diagnose, and treat myocarditis due to influenza B. Additionally, it must be recognized that, although rare, viral myocarditis should be considered in the differential diagnosis of both adults and adolescents.

Documented patient informed consent and/or Institutional Review Board approval has been obtained and filed for publication of this case report.

Address for Correspondence: Taylor Dickey, MSIII, Michigan State University College of Osteopathic Medicine, 1234 Napier Ave, St Joseph, MI 49085. Email: mhysell@lakelandhealth.org.

Conflicts of Interest: By the CPC-EM article submission agreement, all authors are required to disclose all affiliations, funding sources and financial or management relationships that could be perceived as potential sources of bias. The authors disclosed none.

Copyright: © 2018 Dickey et al. This is an open access article distributed in accordance with the terms of the Creative Commons Attribution (CC BY 4.0) License. See: <http://creativecommons.org/licenses/by/4.0/>

REFERENCES

1. Zipes D, Libby P, Bonow RO, et al. Braunwald's Heart Disease: A Textbook of Cardiovascular Medicine 7th Edition. 2005(2):1697–1706.
2. Cooper LT. Clinical Manifestations and Diagnosis of Myocarditis in Adults. Available at: <https://www.uptodate.com/contents/clinical-manifestations-and-diagnosis-of-myocarditis-in-adults>. Accessed November 2017.
3. Karjalainen J, Nieminen MS, Heikkila J. Influenza A1 myocarditis in conscripts. *Acta Med Scand*. 1980;207:27-30.
4. Muneuchi J, Kanaya Y, Takimoto T, et al. Myocarditis mimicking acute coronary syndrome following influenza B virus infection: a case report. *Cases Journal*. 2009;2:6809.
5. Paddock CD, Liu L, Denison AM, et al. Myocardial injury and bacterial pneumonia contribute to the pathogenesis of fatal influenza B virus infection. *J Infect Dis*. 2012;205(6):895-905.
6. Chang H, Hsu J, Tsai Y, et al. Acute respiratory distress syndrome and acute myocarditis developed in a previously healthy adult with influenza B. *BMC Pulm Med*. 2016;16:1.
7. Craver RD, Sorrells K, Gohd R. Myocarditis with influenza B infection. *Ped Infect Dis J*. 1997;16(6):629-30.
8. Sahin DY, Demir M, Kurturan B, et al. A case of myocarditis mimicking acute coronary syndrome associated with H1N1 influenza A virus infection. *Arch Turk Soc Cardiol*. 2010;38(8):572-5.
9. Chartrand C, Leeflang MM, Minion J, et al. Accuracy of rapid Influenza diagnostic tests: a meta-analysis. *Ann Int Med*. 2012;156(7):500-11.
10. Aretz HT, Billingham ME, Edwards WD, et al. Myocarditis. A histopathologic definition and classification. *Am J Cardiovasc Pathol*. 1987;1(1)3-14.
11. Baughman KL. Diagnosis of myocarditis: death of Dallas Criteria. *Circulation*. 2006;113(4):593-5.
12. Louie JK, Yang S, Acosta M, et al. Treatment with neuramidase inhibitors for critically ill patients with influenza A (H1N1)pmd09. *Clin Infect Dis*. 2012;55(9):1198-204.

Fatality Following Intentional Ingestion of *Cerbera odollam* Seeds

Ryan Misek, DO*
 Glenn Allen, PharmD†
 Valerie LeComte, DO*
 Nicholas Mazur, DO†

*Midwestern University, Chicago College of Osteopathic Medicine, Department of Emergency Medicine, Downers Grove, Illinois
 †Franciscan Health Hammond, Emergency Department Pharmacy, Hammond, Indiana

Section Editor: Scott Goldstein, DO

Submission history: Submitted March 17, 2018; Revision received April 26, 2018; Accepted May 3, 2018

Electronically published June 12, 2018

Full text available through open access at http://escholarship.org/uc/uciem_cpccem

DOI: 10.5811/cpcem.2018.5.38345

Seeds from the mangrove plant *Cerbera (C.) odollam*, known as the “suicide tree,” are responsible for a significant number of plant deaths worldwide but are not well recognized in Western medicine. Cerberin is a cardiac glycoside concentrated in the plant’s seeds, which causes disrupted cardiac electrical activity leading to fatal dysrhythmias. We present a fatal case of intentional *C. odollam* seed ingestion. The patient experienced high-degree heart block and cardiac arrest despite supportive treatment and digoxin immune fab administration. Clinicians should be aware of the potential morbidity and mortality associated with *C. odollam* poisoning and be prepared for resuscitative interventions. [Clin Pract Cases Emerg Med. 2018;2(3):223–226.]

INTRODUCTION

Toxins found in the seeds of the tree *Cerbera (C.) odollam*, also known as *C. mangha*, are responsible for hundreds of deaths worldwide, with 537 recorded deaths from 1989 to 1999 in the southern Indian state of Kerala alone.¹ *C. odollam* poisoning, however, has received little attention in Western medicine. Cerberin, a cardiac glycoside found in the seed, reversibly inhibits the sodium–potassium adenosine triphosphatase (Na–K–ATPase) exchanger in myocardial cells causing disruption in cardiac electrical activity and ultimately death.^{1,2} Cerberin is chemically related to other cardiac glycosides found in plant species including oleander (*Nerium oleander*), foxglove (*Digitalis lanata*, *Digitalis purpurea*), ouabain (*Strophanthus gratus*), and yellow oleander (*Thevetia peruviana*), which all produce similar effects as digoxin on the heart.¹ *C. odollam* is referred to as the “suicide tree” or “pong-pong” tree, as its seeds continue to contribute to a significant number of suicides and homicides each year, particularly in rural areas of South Asia. We present a fatal case of intentional self-ingestion of “pong-pong” seeds in an adult patient who purchased the seeds online.

CASE REPORT

A 22-year-old previously healthy, pre-operative male-to-female transgender patient presented via ambulance after a

suicide attempt. The patient admitted to ingesting one “pong-pong” seed approximately seven hours prior to arrival and said that he had purchased the seed online after researching suicide. He admitted to vomiting about two hours after ingestion of the ground seed, and upon initial emergency department (ED) presentation, reported chest pain and “feeling weird.”

Past medical history included a history of depression, post-traumatic stress disorder, and one previous suicide attempt with inpatient psychiatric admission. ED vital signs revealed a temperature of 36.2° Celsius, pulse rate of 53 beats per minute (bpm), respiratory rate of 16 breaths per minute, blood pressure 114/54 millimeters of mercury, and pulse oximetry of 99% on room air. On physical examination, the patient was alert and oriented to person, place and time with a Glasgow Coma Scale of 15. Patient’s pupils were three millimeters and reactive bilaterally; moist mucous membranes were noted and cardiovascular examination revealed bradycardia with a regular rhythm and no murmurs. Lungs were clear bilaterally and the abdomen was soft without tenderness. Skin was warm and dry. Neurological examination revealed normal strength in all extremities without sensory deficits; no clonus or rigidity was noted, and reflexes were 2+ throughout.

We notified Poison Control immediately upon the patient’s arrival, and initial recommendations were to give

five vials of digoxin immune fab with hourly potassium levels and supportive care. Poison Control cautioned the patient could develop second- and third-degree heart block, dysrhythmias, and refractory hypotension. The patient's initial electrocardiogram (ECG) (Image 1) demonstrated second-degree heart block with 2:1 atrioventricular (AV) conduction and ST-segment depression with biphasic T-waves. Five vials of digoxin immune fab were given intravenously and the patient's heart rate improved to 90 bpm. The second ECG (Image 2) was obtained after the initial dose of digoxin immune fab and showed improvement to a sinus rhythm with first-degree AV block with persistent ST-segment depression with biphasic T-waves. Initial serum chemistries were significant for a potassium level of 5.2 milliequivalents per liter (mEq/L) (normal 3.5-5.1) and troponin I <0.05 nanograms per milliliter (ng/ml). Serum toxicology was negative for digoxin (1.3 ng/ml), ethanol (<10 milligrams per deciliter), acetaminophen (<10 micrograms per milliliter) and salicylates (<2.5 milligrams per deciliter); a urine drug screening was pending.

Approximately two hours into the ED course, the patient became bradycardic again. When a third ECG (Image 3) demonstrated a high-degree heart block, five more vials of digoxin immune fab were ordered. Repeat serum potassium level was 5.7 mEq/L. Thirty minutes later, the patient became unresponsive and lost pulses, and the monitor showed pulseless electrical activity as the repeat dose of digoxin immune fab was administered. The patient was resuscitated per Advanced Cardiovascular Life Support protocols. During resuscitation, he was intubated and a right femoral central venous catheter was placed. Ten additional vials of digoxin immune fab and lipid emulsion 20% (100

CPC-EM Capsule

What do we already know about this clinical entity?

Cerbera (C.) odollam seeds contain active cardiac glycosides and account for significant worldwide mortality. Management of C. odollam poisoning is similar to that of digoxin toxicity.

What makes this presentation of disease reportable?

We present the second known C. odollam poisoning in the United States and the first fatality reported, despite treatment with digoxin immune fab administration.

What is the major learning point?

Severe C. odollam poisoning is associated with hyperkalemia, bradycardia, and lack of response to atropine. Clinicians should prepare for aggressive resuscitative interventions.

How might this improve emergency medicine practice?

We hope to educate clinicians about the lethality and treatments of C. odollam poisoning, while raising awareness about a common international means of suicide.

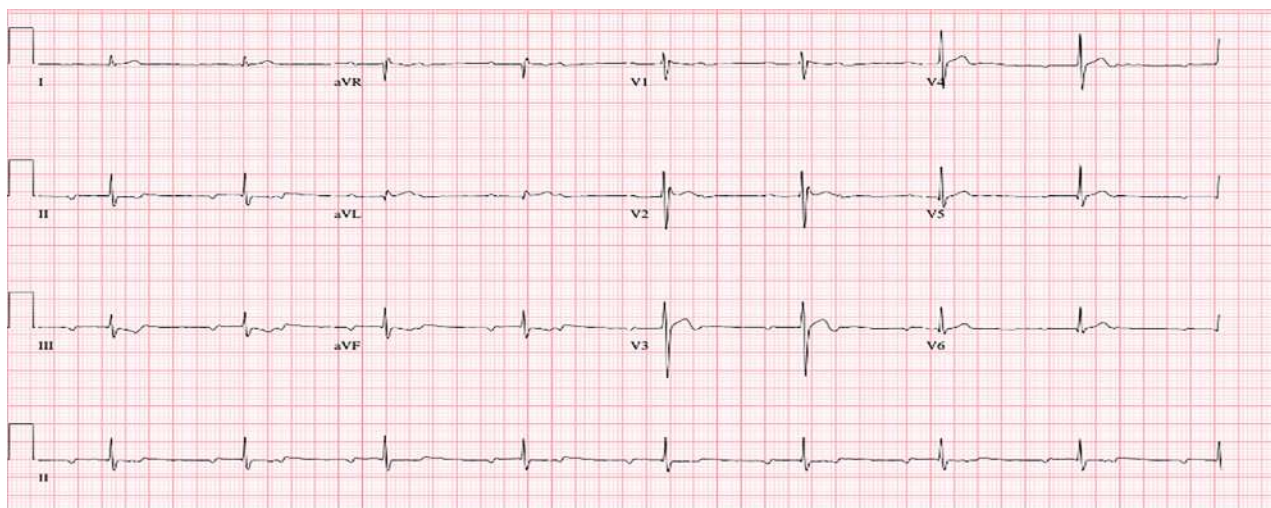


Image 1. Initial electrocardiogram demonstrating second-degree heart block with 2:1 atrioventricular conduction and ST-segment depression with biphasic T-waves.

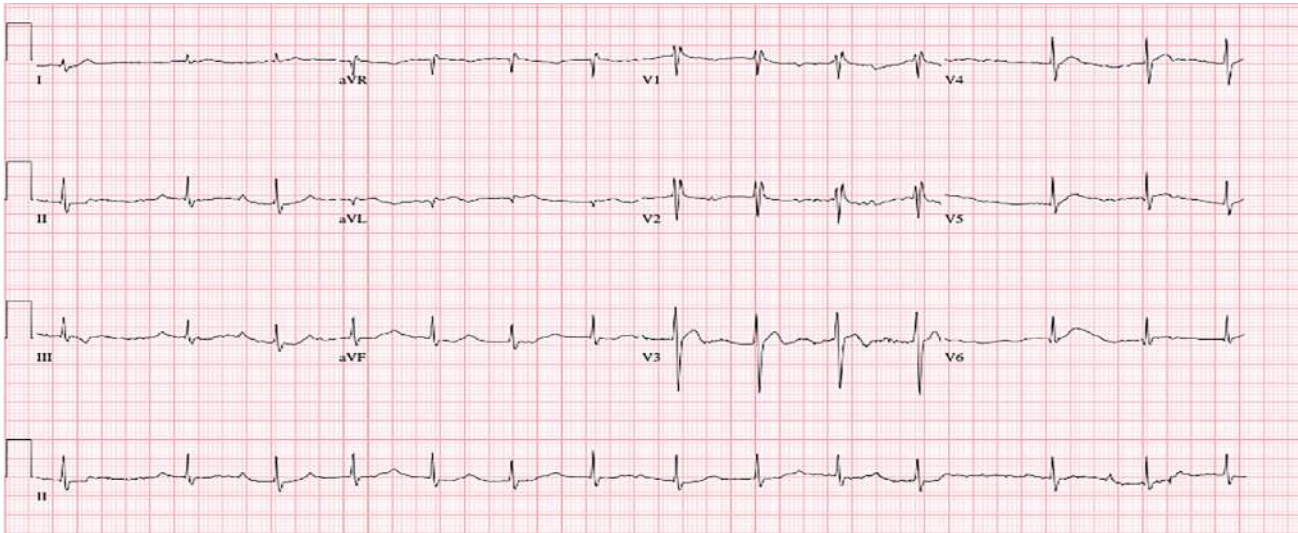


Image 2. Electrocardiogram following initial dose of digoxin immune fab demonstrating sinus rhythm with first-degree atrioventricular block, persistent ST-segment depression with biphasic T-waves.

ml) were given intravenously. Ultimately, after two hours of unsuccessful resuscitation, the patient expired. Postmortem, forensic toxicology testing failed to identify a causative agent; however, a *C. odollam* test was sent to the Federal Bureau of Investigation laboratory in Quantico, Virginia, and was still outstanding at time of this publication.

DISCUSSION

The *C. odollam* plant belongs to the Apocynacea family and grows predominantly in Southern India, Vietnam, Cambodia, Sri Lanka, Myanmar, Malaysia and Madagascar.¹ Its seed is

where the active cardiac glycosides cerberin, cerberoside, and odollin are concentrated.^{1,2} Three glycosides are thought to be responsible for the toxicity of *C. odollam*: cerberin, cerberoside and odollin,^{1,3} while a fourth glycoside was identified in 2004.⁴ These toxic compounds are concentrated in the seeds and oil of the plant. An alcohol extract produced from seeds of *C. odollam* was shown to have similar effects on anesthetized dogs and cats as a digoxin solution, showing a rise in blood pressure followed by a sudden fall and death.³ A standardized extract from the leaves of *C. odollam* administered intraperitoneally was found to produce a lethal dose in 50% (LD50) of study

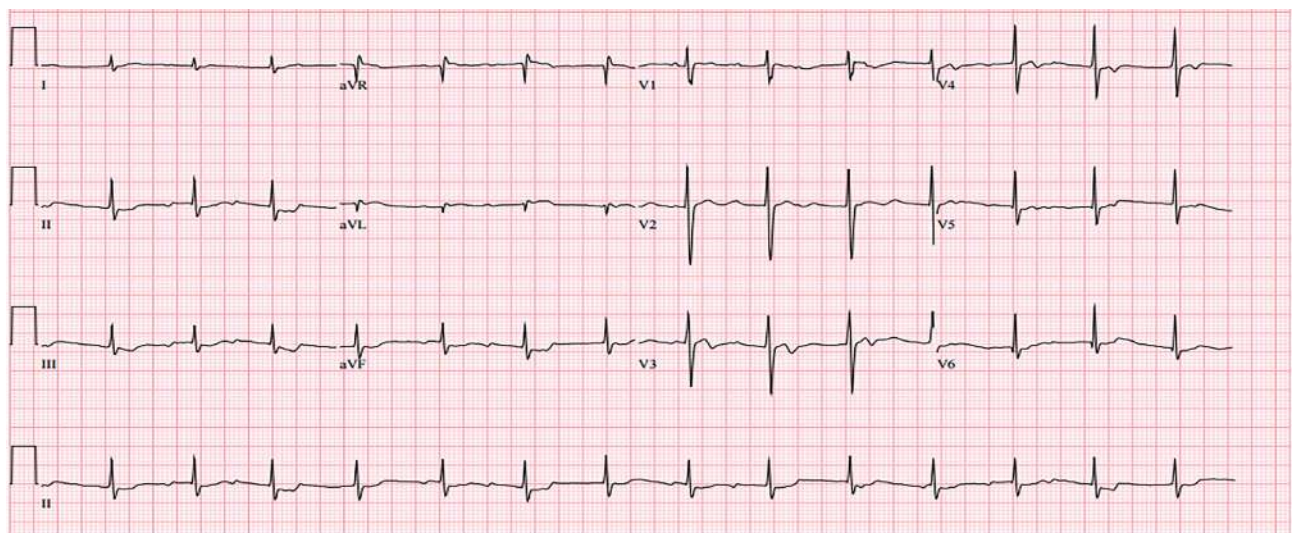


Image 3. Third electrocardiogram after patient decompensation demonstrating high-degree heart block.

mice at 20.8 grams per kilogram.⁴ By comparison, the LD50 of purified digoxin in mice is 17.8 milligrams per kilogram when administered orally.⁵

While nonpharmacologic cardiac glycoside toxicity is rare in the United States (U.S.), accounting for 1.5% (677) of the 44,731 plant exposures reported to the National Poison Data System in 2014, *C. odollam* toxicity has demonstrated significant worldwide mortality.⁶ Ritual *C. odollam* poisonings in Madagascar were at one point responsible for the death of 2% of the population.¹ Poisoning by “pong-pong” seed ingestion is widespread in southern India, with 537 reported deaths in the state of Kerala from 1989-99. Deaths, both homicides and suicides, are almost certainly underreported, as the only method of identifying *C. odollam* toxin is by thin-layer chromatography.⁷ For this reason we were unable to obtain a glycoside blood level; however, we believe that the patient’s history (admitted suicide attempt using “pong-pong” seeds) and hospital course (bradycardia, ECG changes, hyperkalemia) are sufficient to give a diagnosis of *C. odollam* poisoning.

Management of cerberin toxicity is similar to that of digoxin toxicity, consisting of supportive treatments for bradycardia and hyperkalemia as well as administration of digoxin immune fab.^{1,2,8,9} A Cochrane review stated that digoxin immune fab may be effective for the treatment of yellow oleander poisoning, another poisonous cardenolide-containing plant of the Apocynaceae family.¹⁰ In 2014 a patient in the U.S. who ingested an unknown number of “pong-pong” seeds was successfully treated with a total of 20 vials of digoxin immune fab.⁷ Narendranathas et al. analyzed 38 sequential *C. odollam* poisonings of which all four patients who presented with normal sinus rhythm survived and nine of the 25 patients with abnormal rhythm on admission died.¹¹ More severe poisoning was associated with hyperkalemia, bradycardia (heart rate below 50 bpm), and lack of response to atropine. Our patient was hyperkalemic (5.7 mEq/L) and developed bradycardia, indicating a severe poisoning.

CONCLUSION

This was the second known *C. odollam* poisoning in the U.S. and the first fatality reported.⁷ Our patient expired despite being treated with the same amount of digoxin immune fab, possibly indicating a more severe poisoning, or reduced affinity between digoxin immune fab and the digoxin-like toxins that our patient ingested. While poisoning from *C. odollam* is rare in Western medicine, clinicians should be aware of its potential morbidity and mortality and be prepared for resuscitative interventions including digoxin immune fab administration, correction of serum potassium concentration, lipid emulsion therapy with consideration of early transfer to a center with extracorporeal membrane oxygenation capabilities.

Documented patient informed consent and/or Institutional Review Board approval has been obtained and filed for publication of this case report.

Address for Correspondence: Ryan Misek, DO, Midwestern University, Department of Clinical Education, 555 31st Street, Downers Grove, IL 60615. Email: Ryan.misek@gmail.com.

Conflicts of Interest: By the CPC-EM article submission agreement, all authors are required to disclose all affiliations, funding sources and financial or management relationships that could be perceived as potential sources of bias. The authors disclosed none.

Copyright: © 2018 Misek et al. This is an open access article distributed in accordance with the terms of the Creative Commons Attribution (CC BY 4.0) License. See: <http://creativecommons.org/licenses/by/4.0/>

REFERENCES

- Gaillard Y, Krishnamoorthy A, Bevalot F. Cerbera odollam: a 'suicide tree' and cause of death in the state of Kerala, India. *J Ethnopharmacol.* 2004;95(2-3):123-6.
- Eddleston M, Haggalla S. Fatal injury in Eastern Sri Lanka, with special reference to cardenolide self-poisoning with Cerbera manghas fruits. *Clin Toxicol (Phila).* 2008;46(8):745-8.
- Guruswami MN, Ganapathy MN, Thampai CK. A preliminary study of the pharmacological actions and toxicity of “Cerbera odollam.” *Indian J Med Sci.* 1970;24(2)82-7.
- Laphookhieo S, Cheenpracha S, Karalai C, et al. Cytotoxic cardenolide glycoside from the seeds of Cerbera odollam. *Phytochemistry.* 2004;65(4)507-10.
- Material Safety Data Sheet: Product Name: Digoxin Injection, USP website. Available at: http://publicapps.hospira.com/Files/MSDS/Digoxin_091511.pdf. Accessed on October 20, 2016.
- Mowry JB, Spyker DA, Brooks DE, et al. 2014 Annual Report of the American Association of Poison Control Centers' National Poison Data System (NPDS): 32nd Annual Report. *Clin Toxicol (Phila).* 2015;53(10):962-1147.
- Kassop D, Donovan MS, Cohee BM, et al. An unusual case of cardiac glycoside toxicity. *Int J Cardiol.* 2014;170(3):434-7.
- Gunja N, Graudins A. Management of cardiac arrest following poisoning. *Emerg Med Australas.* 2011;23(1):16-22.
- Eddleston M, Haggalla S. Fatal injury in Eastern Sri Lanka, with special reference to cardenolide self-poisoning with Cerbera manghas fruits. *Clin Toxicol (Phila).* 2008;46(8):745-8.
- Roberts DM, Buckley N. Antidotes for acute cardenolide (cardiac glycoside) poisoning. *Cochrane Database Syst Rev.* 2006;(4):CD005490.
- Narendranathan M, Das KV, Vijayaraghavan G. Prognostic factors in Cerbera odollam poisoning. *Indian Heart J.* 1975;27(4):283-6.

Cor Triatriatum: Case Report of Emergency Department Diagnosis

Camille Halfman, MD
 Asalim Thabet, MD
 Rebecca Blue, MD, MPH
 Tyler Greenfield, DO

SUNY Upstate Medical University, Department of Emergency Medicine, Syracuse, New York

Section Editor: Manish Amin, DO

Submission history: Submitted February 13, 2018; Revision received April 27, 2018; Accepted May 3, 2018

Electronically published June 12, 2018

Full text available through open access at http://escholarship.org/uc/uciem_cpccem

DOI: 10.5811/cpccem.2018.5.37921

Cor triatriatum is a rare, congenital heart defect. When diagnosis does not occur in infancy, primary symptoms in an older patient may mimic reactive airway disease. We report a case of cor triatriatum in an older child, previously diagnosed with asthma, presenting to an emergency department with a chief complaint of wheezing. Initial treatment with bronchodilators and corticosteroids was unsuccessful, prompting thorough evaluation. Subsequent imaging diagnosed cor triatriatum sinister. When presentations consistent with common conditions, such as asthma, do not respond appropriately to classic intervention, emergency physicians must be prepared to consider alternative and rare diagnosis. [Clin Pract Cases Emerg Med. 2018;2(3):227–230.]

INTRODUCTION

Cor triatriatum is one of the rarest forms of congenital heart defect, estimated incidence of 0.1% of all the congenital heart diseases.¹ Classically, there is a membrane that separates the left atrium into two components: one chamber with the pulmonary veins and the other with the mitral valve and atrial appendage (Image 1). Most patients are identified shortly after birth with the evaluation of a distressed or cyanotic neonate. However, when presentation is delayed, primary symptoms may mimic reactive airway disease.² We report a case of cor triatriatum in an older child who presented to an emergency department (ED) with a chief complaint of wheeze and dyspnea with a previous diagnosis of asthma.

CASE REPORT

A five-year-old male with reported history of poor weight gain and mild intermittent “asthma” presented to the pediatric ED in respiratory distress. He was tachypneic and tachycardic, with an oxygen saturation of 86% on room air. According to the patient’s mother, he had been seen by a pediatric pulmonologist approximately two months prior and found to have normal pulmonary function tests that did not change with albuterol administration. He was diagnosed with asthma and given prescriptions for budesonide/formoterol and albuterol nebulizer.

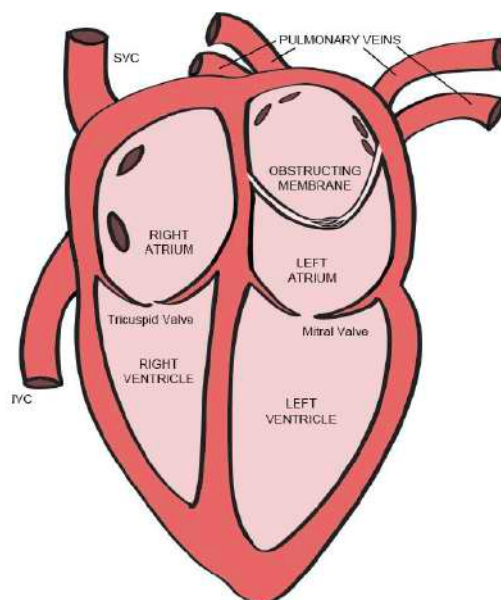


Image 1. Cor triatriatum sinister. Classic findings include a membrane separating the left atrium into two components: one chamber with the pulmonary veins and the other with the mitral valve and atrial appendage. The obstructing membrane is often partially fenestrated, allowing communication between the proximal and distal atrial segments. SVC, superior vena cava; IVC, inferior vena cava.

The patient had further presented to his primary pediatrician approximately one month before his ED visit for complaints of fever. At that time he was diagnosed with acute otitis media and started on azithromycin, but returned four days later with increasing wheezing, upper respiratory symptoms, and exercise intolerance. His antibiotic was changed to cefdinir with a five-day course of prednisolone; the mother reported that he improved with this regimen. He had otherwise been in “normal” health since that time, though his mother did endorse continued issues of poor weight gain and intermittent wheezing.

On the day of presentation, the mother reported that the patient was unable to tolerate a single flight of stairs without fatigue and wheezing. He had used the budesonide/formoterol inhaler earlier that morning and had received multiple albuterol nebulizer treatments prior to arrival without improvement. The patient’s respiratory status had been worsening for the previous two days, with increased dyspnea and wheezing on exertion the day prior to arrival such that he could not play for more than 10 minutes outside without becoming severely dyspneic and fatigued.

On initial exam, the patient was notably tachypneic and tachycardic as well as hypoxic on room air. An expiratory wheeze was appreciated, but no obvious murmur was heard on cardiac auscultation. Splenomegaly was noted. Given the reported history, nebulized albuterol with ipratropium was ordered. Following the breathing treatment, auscultation demonstrated improvement of wheezes, though bilateral coarse breath sounds were appreciated at that time. He remained tachypneic and tachycardic but improved to the point that he was able to speak in full sentences. Oxygen saturation initially improved to 95% but quickly declined to 85% when the nebulizer treatment was completed. Work of breathing increased drastically with worsening hypoxia. The patient was started on continuous albuterol and given magnesium, solumedrol, and ceftriaxone without significant improvement. Chest radiography demonstrated severe pulmonary edema (Image 2). At this time, the patient’s respiratory and mental status statuses rapidly declined and intubation was indicated. He was successfully intubated, but confirmatory chest radiograph demonstrated worsening edema consistent with acute respiratory distress syndrome (Image 3). At this time the patient was admitted and care was transferred to the pediatric intensive care unit (PICU).

After transfer to the PICU, the patient’s oxygen saturation gradually improved to 95% on 100% fraction of inspired oxygen (FiO₂) with a high positive end-expiratory pressure. The pediatric cardiology team was consulted and performed a bedside echocardiogram that revealed cor triatriatum with severe supralvalvar mitral stenosis and significant pulmonary hypertension. The patient was transferred for surgical correction of the malformation as pediatric cardiac surgery was not available at the admitting institution.

CPC-EM Capsule

What do we already know about this clinical entity?
Cor triatriatum is one of the rarest forms of congenital heart defect, estimated incidence of 0.1% of all the congenital heart disease.

What makes this presentation of disease reportable?
While most cases of cor triatriatum are diagnosed in early infancy, rare cases can present with primarily pulmonary complaints, leading to delayed or missed diagnostic opportunities.

What is the major learning point?
Pulmonary complaints that do not respond appropriately to common therapeutic interventions should raise emergency provider suspicion for alternative disease processes.

How might this improve emergency medicine practice?
This case highlights the need for diagnostic acumen and the expansion of differential and appropriate imaging in a case where a common presentation does not translate to a common diagnosis.

DISCUSSION

Cor triatriatum sinister is an exceedingly rare congenital cardiac malformation characterized by the presence of a membrane separating the left atrium into two components: one chamber with the pulmonary veins and the other with the mitral valve and atrial appendage.³ A communication between the right atrium and the proximal or distal chamber is not uncommon.^{4,5} The membrane arises in relationship to the left superior vena cava (LSVC); it is hypothesized that the LSVC normally obliterates during early embryonic atrial development but a prominent or persistent LSVC may induce an abnormal left atrial membrane by impingement.⁶

While the condition can occur in the right heart (cor triatriatum dexter), it is more common in the left (sinister).³ If there is a remaining communication between the divided atrial chambers of sufficient size to allow circulatory exchange, clinical presentation can be delayed from infancy until later childhood or even adulthood.^{3,7} Such presentation may closely mimic signs and symptoms of left heart outflow obstruction. Children may exhibit signs of poor weight gain and failure to thrive, potentially leading to delayed motor milestones.^{1,8} In addition to respiratory

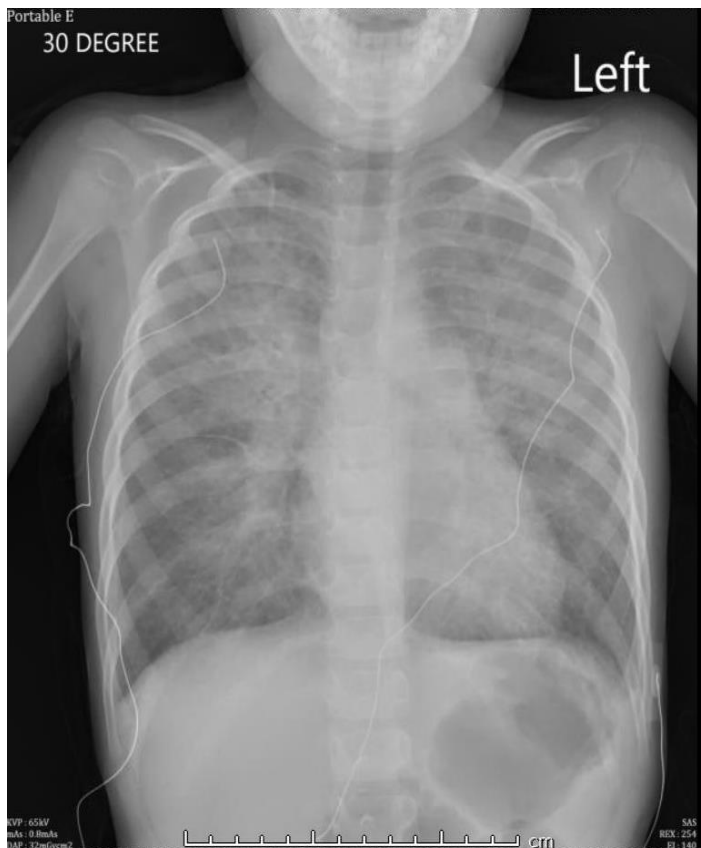


Image 2. Initial chest radiograph demonstrating pulmonary edema.

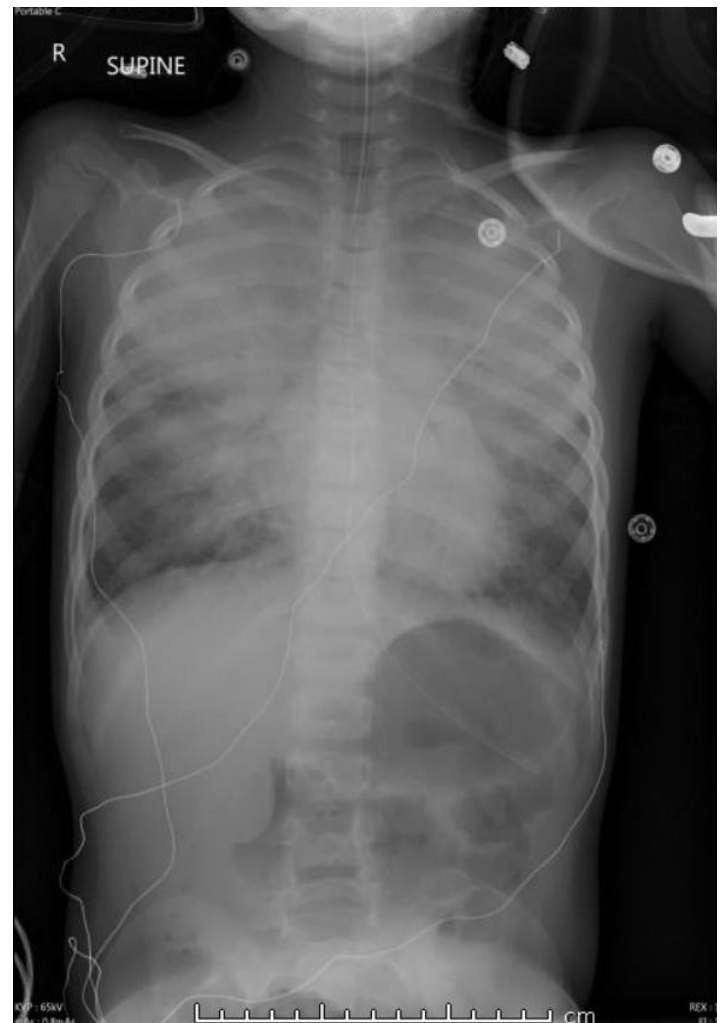

Image 3. Post-Intubation chest radiograph demonstrating worsening edema consistent with acute respiratory distress syndrome.

complaints, adolescents may complain of gastrointestinal symptoms including abdominal pain, nausea, and weight loss.⁸ Symptomatic atrial dysrhythmias may be seen.¹

Misdiagnosis of cor triatriatum as reactive airway disease or asthma has been reported occasionally.^{2,3,9,10} Even so, the diagnosis remains elusive and challenging particularly in the ED. Given the prevalence of asthma and other reactive airway disorders in childhood, with up to 11% of all children aged 10 years having episodes of reactive airway disease,¹¹ it is unsurprising that a presentation as in the case above would prompt initial ED management with bronchodilators, inhaled beta-agonists, and corticosteroids. However, poor response to such treatment mainstays or unexpectedly poor pulmonary function should prompt imaging and consideration of less-common causes of wheeze. Definitive diagnosis of cor triatriatum is easily made by echocardiogram.

Previous publications regarding the association between cor triatriatum and wheezing have suggested that the etiology may be related primarily to pulmonary hypertension, with pulmonary venous hypertrophy triggering spasm of pulmonary vasculature and associated bronchial smooth muscle reactivity.^{2,3} Initial improvement with bronchodilators may be observed given that the final mechanism remains smooth muscle activation and

resultant airway narrowing. As in this case, such response would be expected to be short-lived, with the patient experiencing additional pulmonary decline from pulmonary edema and associated respiratory distress. Temporizing management of acute pulmonary edema with non-invasive or invasive ventilatory support, or through cautious preload/afterload reduction or pulmonary vasodilation, may be helpful in stabilization prior to definitive intervention. Surgical correction offers good results once the correct diagnosis is made.¹

CONCLUSION

Common presentations in the ED prompt common interventions; most pediatric presentations of wheezing are indeed associated with reactive airways. However, emergency providers should not rely on the common diagnoses when faced with poor response to seemingly appropriate interventions. While congenital cardiac malformations are most commonly

diagnosed early in childhood, undiagnosed cases may present as clinical quandaries that should prompt more thorough evaluation. Cor triatriatum is rare, particularly in older children, but can be diagnosed by the discerning emergency physician through careful examination, evaluation of treatment response, and expanded imaging when a patient does not appropriately respond to common therapeutic interventions. Whether or not definitive diagnosis is made, identification of pulmonary edema, regardless of etiology, should prompt appropriate management of oxygenation and ventilation, medical stabilization, and consultation for further care.

Documented patient informed consent and/or Institutional Review Board approval has been obtained and filed for publication of this case report.

Address for Correspondence: Camille Halfman, MD, SUNY Upstate Medical University, Department of Emergency Medicine, 550 E Genesee Street, Syracuse, NY 13202. Email: halfmanc@upstate.edu.

Conflicts of Interest: By the CPC-EM article submission agreement, all authors are required to disclose all affiliations, funding sources and financial or management relationships that could be perceived as potential sources of bias. The authors disclosed none.

Copyright: © 2018 Halfman et al. This is an open access article distributed in accordance with the terms of the Creative Commons Attribution (CC BY 4.0) License. See: <http://creativecommons.org/licenses/by/4.0/>

REFERENCES

1. Hamdan R, Mirochnik N, Celermajer D, et al. Cor triatriatum sinister diagnosed in adult life with three-dimensional transesophageal echocardiography. *BMC Cardiovasc Disord.* 2010;10:54.
2. Pisanti A, Vitiello R. Wheezing as the sole clinical manifestation of cor triatriatum. *Pediatr Pulmonol.* 2000;30(4):346-9.
3. Ferreira SMA, Ferreira AG, Meguins LC, et al. Asthma as a clinical presentation of cor triatriatum sinister in a Brazilian Amazon child: a case report. *J Cardiovasc Med (Hagerstown).* 2009;10(10):795-7.
4. Marín-García J, Tandon R, Lucas RV, et al. Cor triatriatum: study of 20 cases. *Am J Cardiol.* 1975;35(1):59-66.
5. Thilenius OG, Bharati S, Lev M. Subdivided left atrium: an expanded concept of cor triatriatum sinistrum. *Am J Cardiol.* 1976;37(5):743-52.
6. Gharagozloo F, Bulkley BH, Hutchins GM. A proposed pathogenesis of cor triatriatum: impingement of the left superior vena cava on the developing left atrium. *Am Heart J.* 1977;94(5):618-26.
7. Alexi-Meskishvili V, Ovroutski S, Dähnert I, et al. Correction of cor triatriatum sinistrum in a Jehovah's Witness infant. *Eur J Cardio-Thorac Surg.* 2000;18(6):724-26.
8. Hollander SA, Addonizio LJ, Chin C, et al. Abdominal complaints as a common first presentation of heart failure in adolescents with dilated cardiomyopathy. *Am J Emerg Med.* 2013;31(4):684-6.
9. Karthik S, Kelpis TG, Abela CB, et al. "Asthma": an unusual presentation of cor triatriatum. *Hellenic J Cardiol.* 2007;48(1):50-2.
10. Lee M-L, Chen Y-C, Lee M-S, et al. Wheezing as a sign of cor triatriatum sinister culminating in multiple organ failure: cor triatriatum sinister. *Pediatr Int.* 2014;56(6):e92-5.
11. Williams H, McNicol KN. Prevalence, natural history, and relationship of wheezy bronchitis and asthma in children. An epidemiological study. *Br Med J.* 1969;4(5679):321-5.

Simultaneous Multiple Thromboembolic Events in a Postpartum Patient

Ibtisam Ghashimi, MBBS*
Linda Jafarah, MBBS†
Amal Bakhsh, MBBS†
Ahmed Azzazy, MBBS†
Ahmed Royashed, MBBS‡
Awad Awad, MBBS†
Ahmed Ramadan, MBBS†
Ghofran Hashimi, MBBS§
Refah Alqahtani, MBBS¶
Abdullah Bakhsh, MD†

*Ibn Sina National College of Medicine, Emergency Medicine, Jeddah, Saudi Arabia
†King Abdulaziz University, Emergency Medicine, Jeddah, Saudi Arabia
‡King Abdulaziz University, Intensive Care Unit, Jeddah, Saudi Arabia
§King Abdulaziz University, Radiology, Jeddah, Saudi Arabia
¶King Abdulaziz General Hospital, Radiology, Jeddah, Saudi Arabia

Section Editor: Manish Amin, DO

Submission history: Submitted January 4, 2018; Revision received April 28, 2018; Accepted May 3, 2018

Electronically published June 16, 2018

Full text available through open access at http://escholarship.org/uci/uciem_cpccem

DOI: 10.5811/cpcem.2018.5.37451

We report the case of a postpartum patient who presented to the emergency department in status epilepticus. She was initially treated for eclampsia; however, she was subsequently found to have simultaneous cerebral venous thrombosis (CVT) and pulmonary embolism (PE). While thromboembolic events may be seen frequently in the postpartum period, the combination of CVT and PE is an unusual occurrence. Although a challenging diagnosis, the emergency physicians played a critical role in the early recognition and rapid treatment of CVT in this case. [Clin Pract Cases Emerg Med. 2018;2(3):231–234.]

INTRODUCTION

Cerebral venous thrombosis (CVT) is an unusual but devastating neurological emergency.¹ It accounts for 0.5%-1% of all strokes in the general population.² The incidence increases during pregnancy and in the postpartum period, accounting for 6%-64% of pregnancy-related strokes.³ Nonetheless, CVT remains a diagnostic challenge in the emergency department (ED) due to the remarkably wide spectrum of signs and symptoms. In addition, magnetic resonance imaging (MRI) as a screening modality is not easily accessible in the ED.

CASE REPORT

An 18-year-old female who was 10 days post-vaginal delivery presented to the ED in status epilepticus for which she required endotracheal intubation. She had a blood pressure of 163/89 millimeters of mercury, a heart rate of 155 beats per minute, a temperature of 37.0°Celsius, a respiratory rate of 22 breaths per minute, and an oxygen saturation of 94% on 15L per minute of oxygen via a bag-valve mask. Physical

examination confirmed the presence of left leg swelling with mild erythema below the knee; otherwise, no palpable cords or other abnormalities were seen in her lower extremities. Initially it was thought to be deep venous thrombosis, but there was no evidence via venous Doppler ultrasound. Cardiac examination did not reveal murmurs, rubs, gallops, or other abnormalities, and her lungs were clear to auscultation. Upon questioning her family, it was revealed that a few hours prior to presentation the patient had developed sudden onset of difficulty breathing and subsequent loss of consciousness. She was rushed to the ED.

Further workup revealed leukocytosis of $19.84 \times 10^9/L$, elevated D-dimer of 19.9 milligrams per liter, fibrinogen of 457.9 milligrams per deciliter, and troponin of 2.42 micrograms per liter. An electrocardiogram (EKG) revealed an S1Q3T3 pattern. A urine dipstick revealed +2 protein and was otherwise normal.

A magnesium sulfate (MgSO₄) bolus dose of 4g intravenous (IV) over 30 minutes followed by a drip of 2 grams per hour was initiated for presumed eclampsia. A brain computed tomography (CT) without contrast was ordered for

the workup of a first-time seizure. This was unremarkable. At this point, the patient's differential diagnosis was reconsidered and prompted the team to order a CT venogram (CTV) of the brain with a CT pulmonary angiogram. It demonstrated CVT involving the superior sagittal and right transverse sinuses (Image 1), while her CT pulmonary angiogram showed bilateral pulmonary thromboses involving the main, lobar, and multiple segmental arteries bilaterally (Image 2).

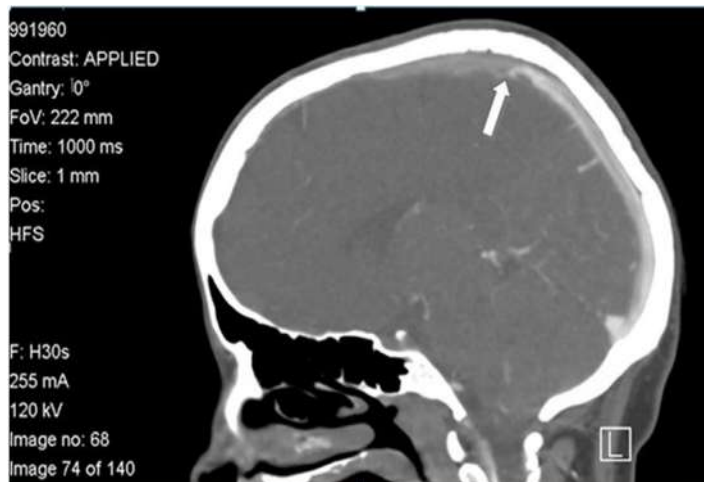


Image 1. Sagittal computed tomography venogram of the brain showing filling defects involving most of the superior sagittal sinus (arrow), except the posterior portion, suggesting superior sagittal sinus thrombosis.

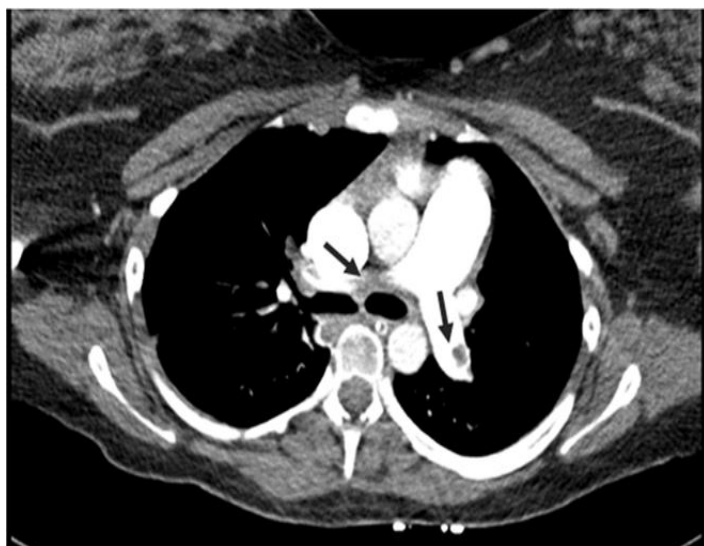

Image 2. Computed tomography pulmonary angiogram showing bilateral large filling defects involving the main pulmonary arteries (arrows).

CPC-EM Capsule

What do we already know about this clinical entity?

Cerebral venous thrombosis is a devastating neurological emergency. The incidence during pregnancy and postpartum period, account for 6% to 64% of pregnancy-related strokes.

What makes this presentation of disease reportable?

Although this case was not completely novel, pulmonary embolism and cerebral venous sinus thrombosis (CVST) are not reported in the literature as presenting simultaneously.

What is the major learning point?

CVST is a challenging diagnosis, and this case reinforces the reminder to consider it when evaluating syncope, seizure, headache, or any neurological complaint.

How might this improve emergency medicine practice?

This case is an important reminder to include CVST in there differentials when approaching postpartum patients with seizure or any neurological sequel.

Enoxaparin sodium was initiated in the ED and the patient was admitted to the intensive care unit (ICU) for further management. During her ICU stay, brain MRI with a magnetic resonance angiogram showed diffuse ischemia with a 5 mm tonsillar herniation and the absence of signal flow void in both internal carotid arteries (Image 3). She was started on 1 g/kg IV of mannitol over 60 minutes. Additionally, a presumptive diagnosis of seronegative antiphospholipid syndrome was made and IV immunoglobulin and methylprednisolone were initiated, with the addition of plasmapheresis. Unfortunately, none of the treatment measures showed a favorable response. Her poor prognosis was discussed with her family and the consensus was to place a do-not-resuscitate order. The patient died in the ICU two weeks later because of tonsillar herniation.

DISCUSSION

CVT is a major cause of morbidity and mortality if left unrecognized.⁴ Setbacks in the diagnosis are due to the

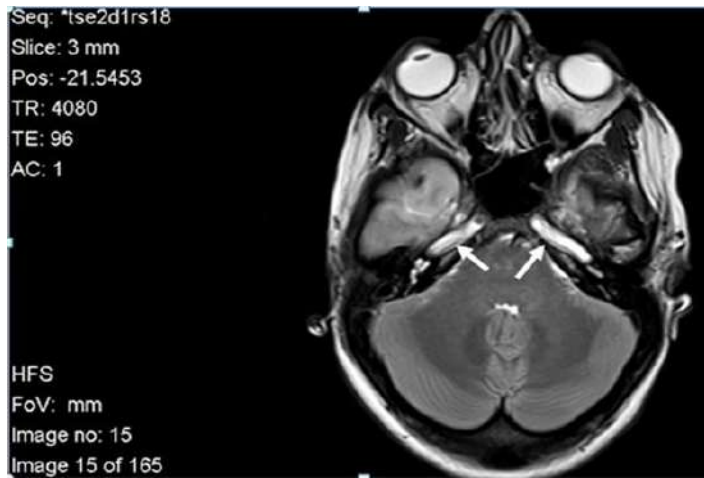

Image 3. Magnetic resonance angiogram showing absent signal flow in both internal carotid arteries (arrows), indicating occlusion.

infrequency of the disease combined with variability in manifestations and lack of specialized imaging in the ED.⁴ Patient outcomes can be enhanced with prompt recognition and treatment. Generalized tonic-clonic seizures are present in 40% of those with CVT, as was the case in our patient.¹ Therefore, it is prudent for emergency physicians to include a CVT in the differential diagnosis of seizing patients, especially in all hypercoagulable states. This will improve recognition, allow the early initiation of treatment, and reduce morbidity and mortality. Other initial findings include headache (81%), limb weakness (34%), disturbed consciousness (30%), blurred vision (11%), and fever (6.9%).¹

Head CT without contrast is the first-line investigation in patients with new headache, focal neurologic deficit, seizure, or altered mental status as per the guidelines of the American College of Emergency Physicians.⁵ Unfortunately, this test has a poor sensitivity for CVT and is normal in 30% of cases.⁶ Therefore, a normal non-contrasted CT of the brain should not be used alone to rule out the diagnosis of CVT.⁷ However, CT combined with venography is reliable with an overall sensitivity of 95%,⁶ which is comparable to the sensitivity of magnetic resonance venography. The widespread availability of CTV makes it the initial test of choice for the diagnosis of CVT.⁶ A normal D-dimer level may be considered to help identify patients with low probability of CVT. However, if there is a strong suspicion of CVT, a normal D-dimer level should not preclude further evaluation.⁶

In our patient, it is likely that a pulmonary embolism (PE) might have caused her CVT, as her respiratory symptoms appeared earlier than her neurological symptoms. The association of CVT and PE may be explained by a detached thrombus and global prothrombotic state.⁸

Mortality due to CVT can reach 5.6% during the acute phase, commonly due to herniation.⁹⁻¹¹ Postpartum women have a higher risk for both venous thromboembolism and eclampsia. Although this case was not completely novel, PE and cerebral venous sinus thrombosis (CVST) are not reported in the literature as presenting simultaneously, and our case was unique in that the patient's presentation was initially consistent with eclampsia (hypertension, syncope, seizure, and mild proteinuria). CVST is a challenging diagnosis, and this case reinforces the reminder to consider it when evaluating syncope, seizure, headache, or any neurological complaint. This case is applicable to emergency medicine providers to improve the survival rates of these patients.

CONCLUSION

Cerebral venous thrombosis can be commonly missed in the ED. It is critical for emergency physicians to include CVT in the differential diagnosis of patients in the ED and to proceed with appropriate imaging if suspicion is high. Venous thromboembolism remains the most common cause of direct maternal deaths, and morbidity and mortality are significantly reduced with improvements in recognition and treatment options.

Documented patient informed consent and/or Institutional Review Board approval has been obtained and filed for publication of this case report.

Address for Correspondence: Ibtisam Ghashimi, MBBS, King Abdulaziz University, Faculty of Medicine, Department of Emergency Medicine, P.O Box 80215, Jeddah 21589, Saudi Arabia. Email: ebts123@hotmail.com.

Conflicts of Interest: By the CPC-EM article submission agreement, all authors are required to disclose all affiliations, funding sources and financial or management relationships that could be perceived as potential sources of bias. The authors disclosed none.

Copyright: © 2018 Ghashimi et al. This is an open access article distributed in accordance with the terms of the Creative Commons Attribution (CC BY 4.0) License. See: <http://creativecommons.org/licenses/by/4.0/>

REFERENCES

1. Liang ZW, Gao WL, Feng LM. Clinical characteristics and prognosis of cerebral venous thrombosis in Chinese women during pregnancy and puerperium. *Sci Rep.* 2017;7:43866.
2. Bousser MG, Ferro JM. Cerebral venous thrombosis: an update. *Lancet Neurol.* 2007;6(2):162-70.
3. Lanska DJ, Kryscio RJ. Risk factors for peripartum and postpartum stroke and intracranial venous thrombosis. *Stroke.* 2000;31(6):1274-82.

4. Fischer C, Goldstein J, Edlow J. Cerebral venous sinus thrombosis in the emergency department: retrospective analysis of 17 cases and review of the literature. *J Emerg Med.* 2010;38(2):140-7.
5. Edlow JA, Panagos PD, Godwin SA, et al. Clinical policy: critical issues in the evaluation and management of adult patients presenting to the emergency department with acute headache. *Ann Emerg Med.* 2008;52(4):407-36.
6. Saposnik G, Barinagarrementeria F, Brown RD, et al. Diagnosis and Management of Cerebral Venous Thrombosis. A Statement for Healthcare Professionals from the American Heart Association/ American Stroke Association. *Stroke.* 2011;42(4):1158-92.
7. Linn J, Pfefferkorn T, Ivanicova K, et al. Noncontrast CT in deep cerebral venous thrombosis and sinus thrombosis: comparison of its diagnostic value for both entities. *AJNR Am J Neuroradiol.* 2009;30(4):728-35.
8. Dagli CE, Koksai N, Guler S, et al. Cerebral venous thrombosis and pulmonary embolism with prothrombin G20210A gene mutation. *Eurasian J Med.* 2010;42(1):38-9.
9. Piazza G. Cerebral venous thrombosis. *Circulation.* 2012;125(13):1704-9.
10. Thorell SE, Parry-Jones AR, Punter M, et al. Cerebral venous thrombosis – a primer for the haematologist. *Blood Rev.* 2015;29(1):45-50.
11. Bousser MG, Ferro JM. Cerebral venous thrombosis: an update. *Lancet Neurol.* 2007;6(2):162-70.

Pyogenic Flexor Tenosynovitis by Point-of-care Ultrasound in the Emergency Department

Daniel Hubbard, MD*
Scott Joing, MD†
Steven W. Smith, MD†

*Oregon Health & Science University, Department of Emergency Medicine, Portland, Oregon
†Hennepin County Medical Center, Department of Emergency Medicine, Minneapolis, Minnesota

Section Editor: Rick A McPheeters, DO

Submission history: Submitted December 28, 2017; Revision received March 25, 2018; Accepted March 28, 2018

Electronically published July 9, 2018

Full text available through open access at http://escholarship.org/uc/uciem_cpem

DOI: 10.5811/cpcem.2018.3.37415

Introduction: Pyogenic flexor tenosynovitis (PFT) is difficult to diagnose on clinical grounds alone as many patients requiring an operation do not have all four of Kanavel's signs. Previous studies have shown that hypoechoic fluid surrounding the flexor tendon on ultrasound is associated with this diagnosis. We sought to determine if emergency physicians (EPs) could recognize this finding in patients with suspected flexor tenosynovitis using point-of-care ultrasound (POCUS).

Methods: We present a retrospective case series of seven patients suspected of PFT who had hypoechoic fluid surrounding the tendon on POCUS performed by the treating EP. We report on the patient characteristics, history of trauma by puncture wound, number of Kanavel's signs, treatment course, and operative findings.

Results: We identified seven patients suspected to have flexor tenosynovitis by the emergency department attending physician who had anechoic or hypoechoic fluid surrounding the flexor tendon on real-time POCUS examination. Patients ranged in age from 16 – 51 years. All were male. All patients had at least two of Kanavel's signs on examination. Five of seven (71%) patients had history of recent trauma to the affected hand. Four of seven (57%) were managed in the operating room. One of seven (14%) had incision and drainage at the bedside, and the remaining two (28%) were managed non-operatively and successfully with antibiotics alone.

Conclusion: Our study demonstrates that EPs can recognize the finding of hypoechoic or anechoic fluid surrounding the flexor tendon on POCUS. [Clin Pract Cases Emerg Med. 2018;2(3):235-240.]

INTRODUCTION

Dr. Allen B. Kanavel's textbook, *Infections of the Hand. A Guide to the Surgical Treatment of Acute and Chronic Suppurative Processes in the Fingers, Hand, and Forearm*, was first published in 1912. The now-eponymous Kanavel's signs are as follows: 1) fusiform swelling; 2) finger held in partially flexed position; 3) pain on palpation of the flexor tendon; and 4) pain on passive stretch of the flexor tendon.¹ Since the first publication of these signs more than 100 years ago there have been no prospective data to determine their sensitivity and specificity. Retrospective series have come

to different conclusions regarding the significance of the different signs.

Dailiana et al. in 2008 found that all four of Kanavel's signs were present in only 22/41 (54%) patients taken to the operating room (OR) with acute pyogenic flexor tenosynovitis (PFT); they noted, however, that all 41 patients had tenderness along the tendon and pain on passive stretch.² Pang et al., in a series of 75 patients published in 2007, noted that only 72% of patients had pain on passive stretch and just 64% had tenderness along the tendon. This study noted that fusiform swelling was the most common finding (97%).³ Thus,

healthcare providers are still left with diagnostic uncertainty in patients presenting to the emergency department (ED) with painful, swollen fingers because physical examination criteria alone are not sufficient to identify patients requiring surgery.

Since at least the 1980s ultrasound (US) has been employed to attempt to differentiate between flexor tenosynovitis and other infections of the hand.^{4,5} These previous studies found that hypoechoic or anechoic fluid surrounding the flexor tendon is associated with purulent discharge at time of surgery and thus a useful adjunct in the diagnosis of PFT. US is particularly useful because the normal finger does not have appreciable synovial fluid on US images.⁶ Accordingly, presence of fluid is abnormal and, in the setting of clinical infection, suggests tenosynovitis. There have been at least three individual case reports from the emergency medicine (EM) point-of-care ultrasound (POCUS) literature in which a finding of fluid surrounding the flexor tendon in a patient presenting with multiple Kanavel signs was determined to be purulent at time of surgery.⁷⁻⁹ To date there have been no case series from the EM literature on this topic.

The objective of this study was to determine if emergency physicians (EP) could recognize this finding on patients with suspected flexor tenosynovitis by POCUS. We present here a case series of seven patients presenting to the ED with at least two of Kanavel's signs on exam and fluid seen on POCUS performed by an EP.

MATERIALS AND METHODS

This was a retrospective case series of patients presenting to our urban, academic emergency department (ED) over an eight-year time period. Our ED attending physicians have been using POCUS since the 1980s, and all are credentialed in the use of bedside US in our institution. Real-time sonography was performed in each patient using a high-frequency linear probe and either a water bath or gel mattress. All patients were determined to have anechoic or hypoechoic fluid surrounding a flexor tendon on POCUS performed by the ED attending. We identified cases by performing a search of the departmental POCUS image archive system for a diagnosis of "tenosynovitis." The electronic medical record was then reviewed for information regarding history of presenting illness, exam, additional diagnostics, specialist consultations, treatments, operative reports, hospital course, and follow-up (if available). All patients described here were found to have the finding of fluid surrounding the flexor tendon by POCUS by the ED attending. We only included cases if the consulting hand surgeon made a diagnosis of flexor tenosynovitis, with the exception of one case in which the final diagnosis by the consultant was "possible flexor tenosynovitis." The institutional review board (IRB) at our hospital does not require IRB approval for retrospective case series using deidentified information.

CPC-EM Capsule

What do we already know about this clinical entity?

For over 100 years the diagnostic criteria for pyogenic flexor tenosynovitis have been the presence of Kanavel's four cardinal signs on physical exam.

What makes this presentation of disease reportable?

This series demonstrates that ultrasound can be used to detect purulence within the tendon sheath and can do so in cases with an incomplete number of Kanavel's signs.

What is the major learning point?

Point-of-care ultrasound can be used to identify purulence in the tendon sheath.

How might this improve emergency medicine practice?

Recognition of flexor tenosynovitis by visualization of fluid in the tendon sheath in patients without all four Kanavel's signs might lead to improved patient outcomes.

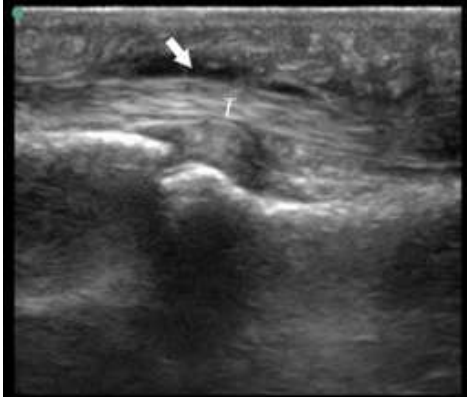
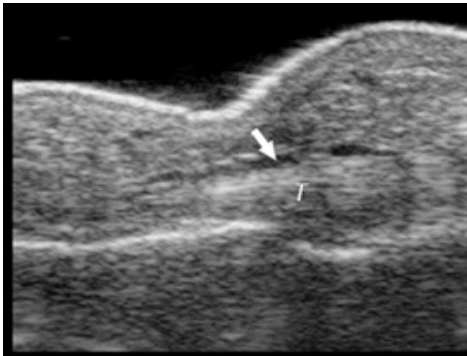
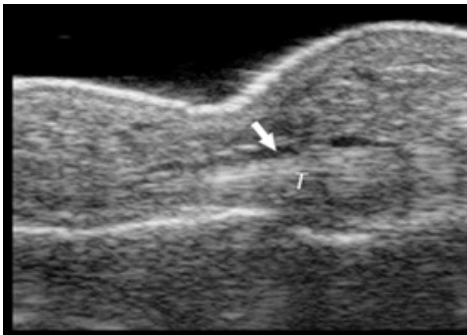

RESULTS

We identified seven patients who had anechoic or hypoechoic fluid surrounding the flexor tendon on real-time POCUS examination and were suspected to have flexor tenosynovitis by the ED attending. Patients ranged in age from 16 – 51 years, and all were male. All patients had at least two of Kanavel's signs on ED examination. Five of seven (71%) had history of recent trauma to the affected hand. Four of seven (57%) were managed in the OR. One of seven (14%) had incision and drainage (I&D) at the bedside, and the remaining two (28%) were managed non-operatively and successfully with antibiotics alone. See the table for summary of patient characteristics and key POCUS images.

DISCUSSION


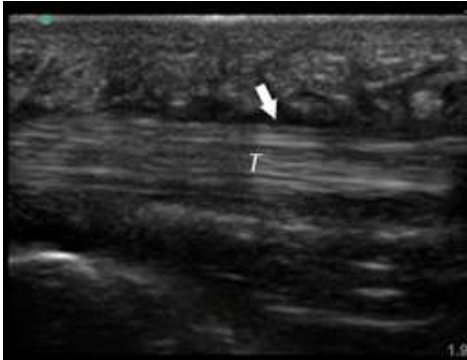

The currently available data on the association of fluid with purulent drainage at operation are scant. To our knowledge only two case series on the use of US in the diagnosis of acute PFT have been published, both in the 1980s by an identical author group.^{4,5} In these two case series of patients with suspected acute hand infections, anechoic

Table. Number of Kanavel signs and history of puncture trauma to the hand, key ultrasound images, treatment course, and final discharge diagnosis.

Case number US machine transducer conduction medium	Number of Kanavel's signs on ED exam: Previous trauma?	Key image	Operative findings and treatment course	Final discharge diagnosis
Case 1 Sonosite (Seattle, WA) Linear 25mm, 10-5 MHz Gel mattress	4/4 No history of trauma		No fluid at operation, Received antibiotics for three days prior to operation	Flexor tenosynovitis
Case 2 Sonosite (Seattle, WA) Linear 25mm, 10-5 MHz Gel mattress	2/4 No history of trauma		Non-operative management with antibiotics	Flexor tenosynovitis
Case 3 Toshiba (Tokyo, Japan) Linear 32mm, 11-6 MHz Water bath	4/4 History of puncture trauma		+Purulence and foreign body at operation	Flexor tenosynovitis
Case 4 Sonosite (Seattle, WA) Linear 25mm, 10-5 MHz Gel mattress	2/4 History of puncture trauma		I&D at bedside and IV antibiotics	Possible flexor tenosynovitis

US, ultrasound; ED, emergency department; OR, operating room; IV, intravenous, I & D, incision and drainage.

Table. Continued.

Case number US machine transducer conduction medium	Number of Kanavel's signs on ED exam: Previous trauma?	Key image	Operative findings and treatment course	Final discharge diagnosis
Case 5 Ultrasonix (Vancouver, Canada) Linear 38mm, 14-5 MHz Water bath	4/4 History of puncture trauma		+purulence at operation	Flexor tenosynovitis
Case 6 Sonosite (Seattle, WA) Linear 25mm, 10-5 MHz Gel mattress	3/4 History of puncture trauma		Non-operative management with antibiotics	Flexor tenosynovitis
Case 7 Sonosite (Seattle, WA) Linear 25mm, 10-5 MHz Gel mattress	2/4 History of puncture trauma		+Purulence at operation	Flexor tenosynovitis

US, ultrasound; ED, emergency department.

or hypoechoic fluid surrounding the tendons was associated with PFT. The first series by Jeffrey et al.⁴ in 1987 detailed a total of seven patients suspected of having purulent flexor tenosynovitis who underwent US. Six patients had hypochoic fluid areas surrounding the flexor tendon. Five of six patients with hypochoic fluid surrounding the tendon on US had a

final diagnosis of acute bacterial tenosynovitis with purulent drainage at surgery. Fluid around the tendon in the remaining patient was attributed to a viral inflammatory etiology. The patient in the study who did not have fluid surrounding the tendon on US but was found to have purulent tenosynovitis at surgery was noted to have 25% enlargement of the tendon on

the affected side compared to the normal contralateral side. In fact, all six patients with bacterial flexor tenosynovitis had at least 25% enlargement of the affected tendon.⁴ In our present cases series, we did not assess tendon diameter.

The group's second series,⁵ consisting of 18 patients and published in 1989, had somewhat mixed results. All 18 patients had >25% increase in tendon diameter by comparison to normal contralateral tendon. Twelve patients were taken to surgery, 11 of whom had the sonographic finding of fluid surrounding the tendon. However, purulence was found in only eight of these 11 US-positive cases. No explanation for the discrepancy between the sonographic and operative findings was offered. The authors do not report the time between image acquisition and surgery. Also of note, of the six remaining patients who were medically managed, one had fluid surrounding the tendon.

These series were published in 1987 and 1989 respectively, in an era in which US images were of inferior quality to today's US images. It is possible that artifacts were falsely interpreted as fluid in the negative operative cases. It is also possible that medical management, including the administration of parenteral antibiotics, allowed for the arrest of the suppurative process and reabsorption of fluid prior to operative exploration. It is possible that contemporary machines may also increase the sensitivity of diagnosing PFT, but may also be detecting early cases in which surgical drainage is not necessary to achieve a cure, and antibiotics alone may be sufficient.

Our findings are notable in that despite the presence of fluid on US and multiple Kanavel's signs, not all patients required operative treatment. It is unclear whether this was due to the absence of tenosynovitis or to early diagnosis with successful resolution with antibiotics alone. It is uncertain what role the US played in the diagnosis, but all who were evaluated for the possibility of tenosynovitis were found to have abnormal fluid. Patients with only two of Kanavel's signs might have gone undiagnosed without US. It is possible that US identifies patients with tenosynovitis with such high sensitivity that it could lead to over-triage to the OR. On the other hand, its sensitivity could lead to early diagnosis, appropriate antibiotic therapy, and beneficial avoidance of operative treatment. We did not report on all cases of tenosynovitis. It is possible that not all cases would have fluid and that a negative US could lead to a false dismissal of the diagnosis or even influence management away from surgery when surgery is actually necessary. Only a prospective trial could answer these questions. A finding of fluid in the sheath is also consistent with non-pyogenic processes; it is well documented that various rheumatologic conditions are also associated with fluid surrounding the flexor tendons.^{10,11}

All patients selected for our retrospective analysis were included because they presented with a suspected acute hand infection and were found to have fluid around the flexor

tendon at the time of ED evaluation. A conclusion from the previously published data reviewed is that the finding of fluid around the tendon does not identify a set of patients that requires operative management for resolution. Our data seem to support this observation as two of seven cases from our cohort did not undergo an operation or I&D despite the presence of multiple Kanavel signs and fluid visualized on POCUS. Neither of these patients was known to have a bad outcome at a minimum of two-month follow-up.

Non-surgical management of suspected flexor tenosynovitis has been previously reported. Nevasier and Gunther reported the successful nonsurgical management of PFT in four patients with a regimen of intravenous antibiotics, splinting, and elevation. The authors noted that all four of these patients presented within 48 hours of symptom onset and hypothesized that the early presentation allowed for successful medical management.¹² Schechter and colleagues reported on six patients with suspected early tenosynovitis who were medically managed. These patients were noted to have fewer of Kanavel's signs than in the group requiring surgery (2.1 vs 3.6 respectively).⁵

Our data highlight the potential utility of US in the early diagnosis of tenosynovitis. As this is a retrospective case series, with selection bias and without data on the influence of US in decision-making, further conclusions are not warranted.

LIMITATIONS

Our study is a retrospective series of patients for whom the consulting hand surgeon made a final diagnosis of flexor tenosynovitis and on whom POCUS had been performed by ED attendings. As such, the results of the study are subject to selection bias.

CONCLUSION

Our study of seven cases, the first case series in the EM literature on this topic, demonstrates that EPs can use POCUS to identify fluid surrounding the tendons in patients presenting with PFT. We also found that some patients presenting without all four of Kanavel's signs had the US finding of fluid surrounding the tendon and purulence at operation. Furthermore, we found that two patients were managed successfully with non-operative treatment. We conclude that POCUS may assist in the early diagnosis of PFT, possibly resulting in the success of conservative, non-operative management. We recommend that future study be directed at additional findings of tendon diameter and hyperemic flow in an effort to make POCUS of suspected PFT more specific for the diagnosis.

Documented patient informed consent and/or Institutional Review Board approval has been obtained and filed for publication of this case report.

Address for Correspondence: Daniel Hubbard, MD, Oregon Health & Science University, Department of Emergency Medicine, CDW-EM, 3181 SW Sam Jackson Park Road, Portland, Oregon 97239. Email: hubbadan@ohsu.edu.

Conflicts of Interest: By the CPC-EM article submission agreement, all authors are required to disclose all affiliations, funding sources and financial or management relationships that could be perceived as potential sources of bias. The authors disclosed none.

Copyright: © 2018 Hubbard et al. This is an open access article distributed in accordance with the terms of the Creative Commons Attribution (CC BY 4.0) License. See: <http://creativecommons.org/licenses/by/4.0/>

REFERENCES

1. Kanavel A. *Infection of the hand*. 1st ed. Philadelphia and New York: Lea and Febiger; 1912.
2. Dailiana H, Rigopoulos N, Varitimidis S, et al. Purulent flexor tenosynovitis: factors influencing the functional outcome. *J Hand Surgery Eur Vol*. 2008;33(3):280-5.
3. Pang HN, Teoh LC, Yam AK, et al. Factors affecting the prognosis of pyogenic flexor tenosynovitis. *J Bone Joint Surg Am*. 2007;89(8):1742-8.
4. Jeffrey RB Jr, Lain FC, Schechter WP, et al. Acute suppurative tenosynovitis of the hand: diagnosis with US. *Radiology*. 1987;162(3):741-2.
5. Schechter WP, Markison RE, Jeffrey RB, et al. Use of sonography in the early detection of suppurative flexor tenosynovitis. *J Hand Surg Am*. 1989;14(2 Pt 1):307-10.
6. Bianchi S, Martinoli C, de Gautard R, et al. Ultrasound of the digital flexor system: normal and pathological findings. *J Ultrasound*. 2007;10(2):85-92.
7. Bomann J, Tham E, McFadden P, et al. Bedside ultrasound of a painful finger: Kanavel's fifth sign? *Acad Emerg Med*. 2009;16(10):1034-5.
8. Marvel BA, Budhrum GR. Bedside ultrasound in the diagnosis of complex hand infections: a case series. *J Emerg Med*. 2015;48(1):63-8.
9. Padrez K, Bress J, Johnson B, et al. Bedside ultrasound identification of infectious flexor tenosynovitis in the emergency department. *West J Emerg Med*. 2015;16(2):260-2.
10. Naredo E, D'Agostino MA, Wakefield R, et al. Reliability of a consensus-based ultrasound score for tenosynovitis in rheumatoid arthritis. *Ann Rheum Dis*. 2013;72(8):1328-34.
11. Alcade M, D'Agostino MA, Bruyn G, et al. A systemic literature review of US definitions, scoring systems and validity according to the OMERACT filter for tendon lesion in RA and other inflammatory joint diseases. *Rheumatology (Oxford)*. 2012;51(7):1246-60.
12. Neviasser RJ, Gunther SF. Tenosynovial infections in the hand: diagnosis and management. *Instr Course Lect*. 1980;29:108-28.

Pyometra, an Unusual Case of Acute Abdomen

Kyle E. Nielsen, DO
 Sarah A. Medeck, DO
 Dan B. Brillhart, MD
 Kasey J. Mayclin, MD

Carl R. Darnall Army Medical Center, Department of Emergency Medicine, Fort Hood, Texas

Section Editor: Shadi Lahham, MD

Submission history: Submitted March 8, 2018; Revision received April 27, 2018; Accepted May 3, 2018

Electronically published July 12, 2018

Full text available through open access at http://escholarship.org/uc/uciem_cpccm

DOI: 10.5811/cpcem.2018.5.38221

A 49-year-old female six days post-endometrial biopsy presented to the emergency department with constant severe suprapubic abdominal pain, fevers and myalgia. A contrasted computed tomography noted an intrauterine fluid collection and a final diagnosis of pyometra was made in the operating room following total hysterectomy. Pyometra is an exceptionally rare clinical condition with significant mortality. [Clin Pract Emerg Med. 2018;2(3):241-243.]

INTRODUCTION

Non-traumatic abdominal pain is one of the most common reasons for emergency department (ED) visits. It is also a notoriously difficult complaint to approach in females due to the myriad of abdominal and pelvic etiologies. In female patients, pelvic pathology accounts for approximately 12% of acute abdominal pain presentations.¹ This case report illustrates an otherwise healthy female who, due to a unique series of events, developed an intrauterine infection that progressed to a rare surgical emergency called a pyometra.

CASE REPORT

A 49-year-old female presented to the ED with diffuse abdominal pain, fevers, myalgia and nausea. The patient had an unsuccessful cervical dilation and endometrial biopsy six days prior to presentation. She was seen in gynecology clinic on post-procedure day two and was started on oral metronidazole for suspected bacterial vaginosis due to a foul-smelling discharge, which subsequently resolved. Pertinent surgical history included an endometrial ablation and bilateral tubal ligation.

On arrival, the patient was mildly tachycardic but otherwise hemodynamically stable and afebrile. She was ill-appearing. On physical exam, severe diffuse abdominal tenderness and guarding was noted. A pelvic exam noted uterine tenderness and scant dark blood in the vaginal vault, but without appreciable discharge. Laboratory results were significant for mild leukocytosis with white blood cell count of $12 \times 10^3/\mu\text{L}$ (ref 3.98-10.04) but otherwise unremarkable.

Her contrasted abdominal and pelvis computed tomography demonstrated a 2.8 cm x 4.8 cm intrauterine fluid collection (Image 1). Ampicillin, clindamycin and gentamycin were started. Gynecology was consulted and patient was taken to the operating room for emergent dilation and curettage. The procedure was unsuccessful due to complete cervical stenosis and severe uterine tissue inflammation and edema. Repeated ultrasound-guided attempts failed, and a non-perforating

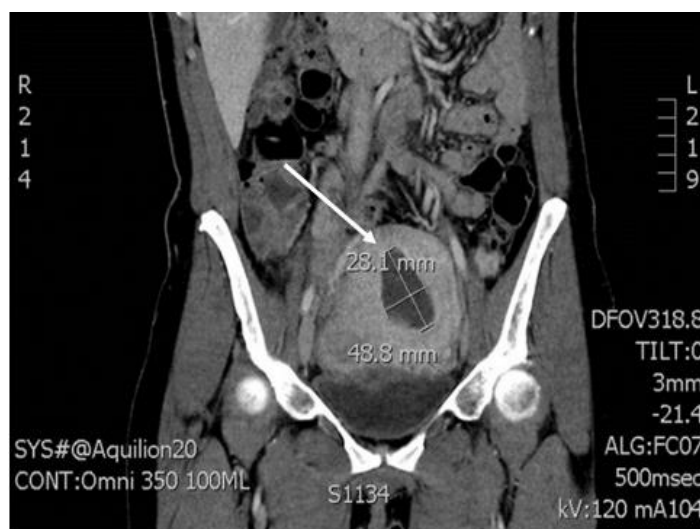


Image 1. Contrast computed tomography with the white arrow demonstrating the 2.8 cm x 4.8 cm intrauterine fluid collection.

iatrogenic false lumen was created in the posterior myometrium. The following day, the patient was taken back to the operating room for a total abdominal hysterectomy. The surgeon reported a tense, fluid-filled uterus that ruptured when bi-valved, consistent with a pyometra (Image 2).

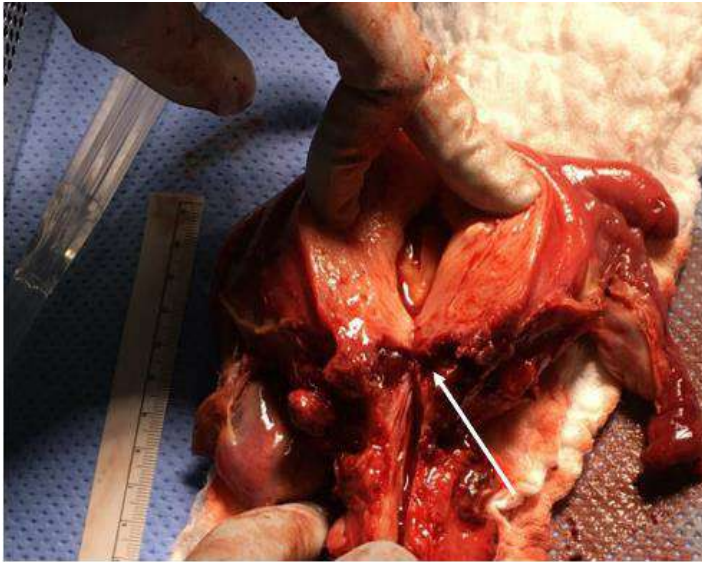


Image 2. Tense fluid in the uterine cavity ruptured when bi-valved. White arrow illustrates the cervical canal is completely obliterated due to patient's prior ablation.

DISCUSSION

Pyometra is an intrauterine infection and collection of purulent material due to the inability of the cervix to adequately drain the uterine contents. It is a well-known entity within the veterinary community due to its relative frequency in dogs and cattle,² but it is exceptionally rare in humans. A 2014 literature review found only 81 reported cases from 1949-2015, and noted a mortality rate of 31%.³ *Streptococcus* species, *Bacteroides fragilis* and *Escherichia coli* are the most common organisms isolated in pyometra.^{4,5} In the few reported human cases, the majority were caused by cervical obstruction due to malignancy.²

Our patient developed a hematometra (retention of blood in the uterus) due to her prior uterine ablation and resultant cervical stenosis.¹ Her prior bilateral tubal ligation, which prevented retrograde expulsion of the menses into the abdominal compartment, likely also contributed to her presentation. The chronic collection of stagnant proteinaceous bodily fluid likely served as an excellent medium for bacteria introduced via instrumentation during the patient's attempted endometrial biopsy six days prior.

CPC-EM Capsule

What do we already know about this clinical entity?

Pyometra is a serious, life-threatening infection within the uterus. It is typically caused by anaerobic bacteria growth within a poorly draining uterus.

What makes this presentation of disease reportable?

Pyometra, although a well-known entity within the veterinary community due to frequency in dogs and cattle, is exceptionally rare in humans.

What is the major learning point?

Early broad spectrum antibiotics to include anaerobic coverage and urgent surgical intervention are important in the treatment of pyometra.

How might this improve emergency medicine practice?

Increased awareness of rare abdominal pathology will allow for future recognition and management.

Although this patient's intrauterine cultures grew negative, by the time they were obtained the patient had been on ampicillin, gentamicin, and clindamycin for over 24 hours. The patient's symptoms resolved and she was discharged on hospital day three with gynecology follow-up.

CONCLUSION

This case was resultant from the culmination of a unique series of events including prior tubal ligation, cervical stenosis with development of a chronic hematometra and ultimately iatrogenic inoculation via recent instrumentation. As emergency physicians, we are often asked to make decisions on incomplete data. Although the ultimate diagnosis of pyometra was made in the operating room over 24 hours later, this patient benefited from early, broad-spectrum antibiotics and fluid resuscitation. Furthermore, this case illustrates the need to maintain a broad differential when evaluating nontraumatic abdominal pain. In summary, we report an exceptionally rare case of a pyometra in a human. To our knowledge, this has not been reported within the emergency medicine literature.

Documented patient informed consent and/or Institutional Review Board approval has been obtained and filed for publication of this case report.

Address for Correspondence: Kyle Nielsen, DO, Carl R Darnall Army Medical Center, 36065 Santa Fe, Room 41-114, Fort Hood, TX 76544-5095. Email: kyle.e.nielsen2.mil@mail.mil.

Conflicts of Interest: By the CPC-EM article submission agreement, all authors are required to disclose all affiliations, funding sources and financial or management relationships that could be perceived as potential sources of bias. The authors disclosed none. The views expressed are those of the authors and do not reflect the official policy of the Department of the Army, the Department of Defense or the U.S. Government.

Copyright: © 2018 Nielsen et al. This is an open access article distributed in accordance with the terms of the Creative Commons Attribution (CC BY 4.0) License. See: <http://creativecommons.org/licenses/by/4.0/>

REFERENCES

1. Kamin RA, Nowicki TA, Courtney DS, et al. Pearls and pitfalls in the emergency department evaluation of abdominal pain. *Emerg Med Clin North Am.* 2003;21(1):61–72.
2. Fieni F, Topie E, Gogny A. Medical treatment for pyometra in dogs. *Reprod Domest Anima.* 2014;49:2:28-32.
3. Ikeda M, Takahashi T, Kurachi H. Spontaneous perforation of pyometra: a report of seven cases and review of the literature. *Gynecol Obstet Invest.* 2013;75(4):243-9.
4. Ou YC, Lan KC, Lin H, et al. Clinical characteristics of perforated pyometra and impending perforation: specific issues in gynecological emergency. *J Obstet Gynecol Res.* 2010;36(3):661-6.
5. Kitai T, Okuno K, Ugaki H, et al. Spontaneous uterine perforation of pyometra presenting as acute abdomen. *Case Rep Obstet Gynecol.* 2014;2014:738568–738568.
6. Schlumbrecht M, Balgobin S, Word L. Pyometra after thermal endometrial ablation. *Obstet Gynecol.* 2007;110:538–540.

Spontaneous Diaphragmatic Hernia

Mark D. Darocki, DO
Anthony J. Medak, MD

University of California San Diego, Department of Emergency Medicine, San Diego, California

Section Editor: Christopher Sampson, MD

Submission history: Submitted April 8, 2018; Revision received May 14, 2018; Accepted May 16, 2018

Electronically published July 16, 2018

Full text available through open access at http://escholarship.org/uc/uciem_cpem

DOI: 10.5811/cpcem.2018.5.38587

A spontaneous diaphragmatic hernia (SDH) occurs when intra-abdominal contents extend into the thoracic cavity through a defect in the diaphragm after a sudden increase in intra-abdominal pressure. SDH is one of the rarest surgical emergencies with less than 30 reported cases in the literature.^{1,2} In our case a 94-year-old female presented to the emergency department in respiratory distress with unilateral breath sounds and was diagnosed with a SDH. The only treatment option for a SDH is surgical.^{3,11} However, nasogastric tube decompression of the gastrointestinal tract and supplemental oxygen can be used to alleviate symptoms until definitive operative management is performed. [Clin Pract Cases Emerg Med. 2018;2(3):244-246.]

INTRODUCTION

A patient presenting to the emergency department (ED) in respiratory distress with unilateral breath sounds does not have an extensive differential diagnosis. In a trauma scenario a pneumothorax or hemothorax quickly comes to mind. It is taught that a chest tube should be inserted without further diagnostic testing. In the non-traumatic patient a spontaneous pneumothorax, pleural effusion, pneumonia, or airway foreign body are among the most likely etiologies. Spontaneous diaphragmatic hernia (SDH) is not often considered, and thus may be a missed diagnosis during initial evaluation.

SDH is one of the rarest surgical emergencies comprising less than 1% of all diaphragmatic hernias, with fewer than 30 reported cases in the literature.^{1,2,4,5} A SDH occurs when intra-abdominal contents extend into the thoracic cavity through a defect in the diaphragm after a sudden increase in intra-abdominal pressure. SDH has been attributed to physical exercise, labor and delivery, coughing, vomiting, or defecation.¹⁻³ Diaphragmatic hernia is a rare surgical emergency that usually occurs in the setting of trauma. Blunt trauma is more common than penetrating trauma, and the most common cause is a motor vehicle accident.¹ The most common structures to enter the thoracic cavity are the stomach, colon, greater omentum, small intestine, spleen, and liver.^{1,2}

CASE REPORT

A 94-year-old woman with chronic obstructive pulmonary disease, hypertension, and breast cancer presented to the ED in respiratory distress. She reported dyspnea starting the night prior to presentation with no history of trauma. She was normothermic, had a normal heart rate and blood pressure, but was tachypneic and hypoxic to 88% on room air. Physical exam revealed significant accessory muscle use, no stridor, no jugular venous distention, normal heart sounds and diminished breath sounds in the left hemithorax.

While the nurse gathered a 14-gauge needle and a chest tube tray for needle decompression followed by tube thoracostomy, a bedside ultrasound was performed. The ultrasound showed bilateral pleural sliding without significant B-lines or effusion. Portable chest radiograph revealed that a large amount of intra-abdominal contents had entered the thoracic cavity resulting in a shift of the mediastinum (Image 1). A nasogastric tube was not inserted to decompress the bowel, as the patient declined to have this performed.

We consulted the general surgery service, which recommended obtaining a computed tomography (CT) scan to further characterize the defect in the diaphragm (Image 2). The patient and her family members declined surgical intervention. She was admitted to the hospital to arrange home hospice care and was discharged within 24 hours. She died at home with her family three days after presenting to the ED.

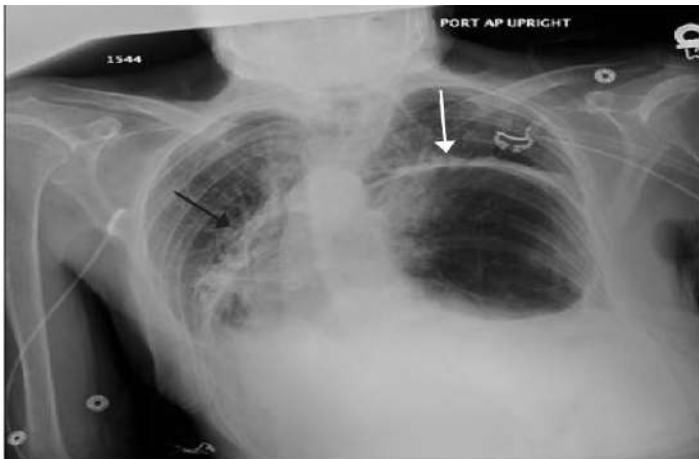


Image 1. Anterior-posterior chest radiograph demonstrating intrathoracic gastrointestinal contents (white arrow). Note the shift of the mediastinum into the right hemithorax (black arrow).

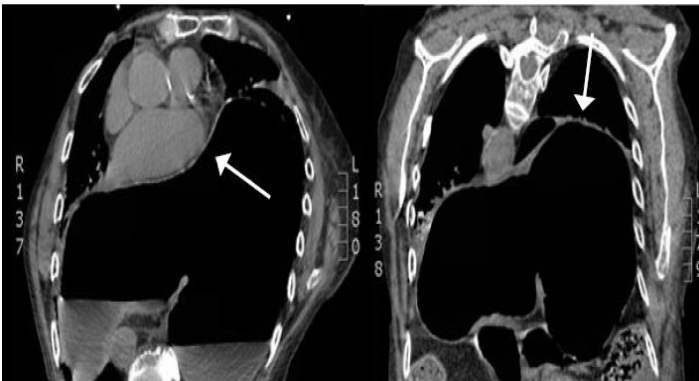


Image 2. Computed tomography (CT) of the chest. Left: Axial view of a CT chest demonstrating gastrointestinal (GI) contents in the thoracic cavity with cardiovascular compression (white arrow). Right: Coronal view of a CT chest demonstrating GI contents in the thoracic cavity (white arrow).

DISCUSSION

A SDH can be considered based on the history and physical exam, but imaging is required to make the diagnosis. It is important to consider SDH as part of an early differential diagnosis, as a delay in diagnosis increases the risk of strangulation, perforation, and pulmonary or vascular compression.^{1,6} Historical red flags include a known diaphragmatic defect,⁶ dyspnea preceded by a sudden increase in intra-abdominal pressure, and/or dyspnea in conjunction with vomiting. Patients commonly present with abdominal pain, chest pain, nausea, vomiting, and difficulty breathing.^{1,5} Physical exam findings include the absence of breath sounds, decreased breath sounds, or the presence of bowel sounds in the thoracic cavity.⁶

CPC-EM Capsule

What do we already know about this clinical entity?

A spontaneous diaphragmatic hernia (SDH) occurs when intra-abdominal contents extend into the thoracic cavity through a defect in the diaphragm after a sudden increase in intra-abdominal pressure.

What makes this presentation of disease reportable?

SDH is one of the rarest surgical emergencies with fewer than 30 reported cases in the literature.

What is the major learning point?

The diagnosis of SDH should be considered in patients presenting in respiratory distress with unilateral or asymmetrical breath sounds.

How might this improve emergency medicine practice?

Increased awareness of this rare diagnosis could prevent the unnecessary and potentially harmful placement of a chest tube in this patient population.

Diagnostic imaging options in the ED include chest radiograph, CT, ultrasound, magnetic resonance imaging, and upper gastrointestinal (GI) contrast studies. The most readily available options are radiograph, point-of-care ultrasound, and CT.⁹ Chest radiographs are diagnostic in only 25-50% of cases,^{7,9} and an estimated 66% of diaphragmatic hernias are missed on initial presentation.⁸ Common radiographic findings include the following: elevated left hemidiaphragm; blunting of the costophrenic angle; distortion of the diaphragm borders; curling of gastric tube into the thorax; mediastinal shift; pleural effusion; or presence of air-filled GI structures in the thorax.^{5,7,8} Ultrasound can be complicated by scattering of the beam by the aerated lung and gas-filled intestinal structures, as well as acoustic shadowing from the ribs.^{9,10} CT is the most accurate imaging modality available in the ED. Depending on the location of the lesion, the accuracy of CT ranges from 50-78%.⁹

The most accurate method of making the diagnosis is via exploration in the operating room.¹³ However, even this is not 100% accurate.¹⁴ The only treatment option for a diaphragmatic hernia is surgical.^{3,11} However, supplemental oxygen as well

as a nasogastric tube to decompress the GI tract can be used to alleviate symptoms until definitive operative management is performed.⁴ In our case, the bedside ultrasound exam did not confirm the diagnosis of SDH, but it did make the alternative diagnoses of pneumothorax or large pleural effusion much less likely. This prevented the patient from undergoing unnecessary needle decompression followed by tube thoracostomy, and the pain and morbidity associated with these procedures.

CONCLUSION

Spontaneous diaphragmatic hernia is a rare diagnosis that is often missed on the initial patient encounter. While the treatment is surgical, therapeutic measures can be taken in the ED to alleviate symptoms and suffering. The utility of bedside ultrasound in the diagnosis of SDH is yet unproven. However, in our case it rapidly excluded a pneumothorax and prevented the unnecessary placement of a chest tube in an elderly woman.

Documented patient informed consent and/or Institutional Review Board approval has been obtained and filed for publication of this case report.

Address for Correspondence: Mark Darocki, DO, University of California San Diego, Department of Emergency Medicine, 200 W Arbor Drive # 8819, San Diego, CA 92103, Email:Darockimark@gmail.com.

Conflicts of Interest: By the CPC-EM article submission agreement, all authors are required to disclose all affiliations, funding sources and financial or management relationships that could be perceived as potential sources of bias. The authors disclosed none.

Copyright: © 2018 Darocki et al. This is an open access article distributed in accordance with the terms of the Creative Commons Attribution (CC BY 4.0) License. See: <http://creativecommons.org/licenses/by/4.0/>

REFERENCES

- Ghidirim G, Mishin I, Condratsky E, et al. Spontaneous diaphragmatic rupture: case report and literature review. *Chirurgia (Bucur)*. 2013;108(1):99-101.
- Losanoff JE, Edelman DA, Salwen WA, et al. Spontaneous rupture of the diaphragm: case report and comprehensive review of the world literature. *J Thorac Cardiovasc Surg*. 2010;139(6):e127-8.
- Hamoudi D, Bouderkha MA, Benissa N, et al. Diaphragmatic rupture during labor. *Int J Obstet Anesth*. 2004;13(4):284-6.
- Kearney PA, Rouhana SW, Burney RE. Blunt rupture of the diaphragm: mechanism, diagnosis, and treatment. *Ann Emerg Med*. 1989;18(12):1326-30.
- Bekassy SM, Dave KS, Wooler GH, et al. "Spontaneous" and traumatic rupture of the diaphragm: long-term results. *Ann Surg*. 1973;177(3):320-4.
- Khan MA, Bilal A, Aslam V, et al. Management of traumatic diaphragmatic hernias. *J Postgrad Med Inst*. 2011;22(4):281-4.
- Reber PU, Schmied B, Seiler CA, et al. Missed diaphragmatic injuries and their long-term sequelae. *J Trauma*. 1998;44(1):183-8.
- Sandstrom CK, Stern EJ. Diaphragmatic hernias: a spectrum of radiographic appearances. *Curr Probl Diagn Radiol*. 2011;40(3):95-115.
- Eren S, Kantarcı M, Okur A. Imaging of diaphragmatic rupture after trauma. *Clin Radiol*. 2006;61(6):467-77.
- Gelman R, Mirvis SE, Gens D. Diaphragmatic rupture due to blunt trauma: sensitivity of plain chest radiographs. *AJR Am J Roentgenol*. 1991;156(1):51-7.
- McIndoe GA, Hopkins NF. Spontaneous' rupture of the diaphragm. *Postgrad Med J*. 1986;62(727):389-91.
- Gupta V, Singhal R, Ansari MZ. Spontaneous rupture of the diaphragm. *Eur J Emerg Med*. 2005;12(1):43-4.
- McDonald AA, Robinson BRH, Alarcon L, et al. Evaluation and Management of Traumatic Diaphragmatic Injuries: A Practice Management Guideline from the Eastern Association for the Surgery of Trauma. *J Trauma Acute Care Surg*. 2018. In Press.
- Friese RS, Coln CE, Gentilello LM. Laparoscopy is sufficient to exclude occult diaphragm injury after penetrating abdominal trauma. *J Trauma*. 2005;58(4):789-92.

Anti-factor Xa Monitoring and Activated Charcoal for a Pediatric Patient With Rivaroxaban Overdose

Brendan M. Carr, MD, MS*

David J. Roy, PharmD, BCPS*†

Stacey A. Bangh, PharmD, DABAT‡§

Thomas R. Hellmich, MD*

Laura E. Walker, MD*

*Mayo Clinic, Department of Emergency Medicine, Rochester, Minnesota

†Mayo Clinic, Pharmacy Services, Rochester, Minnesota

‡Hennepin County Medical Center, Minneapolis, Minnesota

§Minnesota Poison Control System, Minneapolis, Minnesota

Section Editor: Steven J. Walsh, MD

Submission history: March 20, 2018; Revision received May 15, 2018; Accepted May 16, 2018

Electronically published July 16, 2018

Full text available through open access at http://escholarship.org/uc/uciem_cpchem

DOI: 10.5811/cpchem.2018.5.38373

Rivaroxaban, an oral anticoagulant, directly inhibits factor Xa (FXa). A 35-month-old boy was brought to the emergency department 15 minutes after ingesting 200 mg of rivaroxaban (16 mg/kg). Activated charcoal (AC) was administered; the patient was observed with monitoring of plasma anti-FXa levels and discharged the following day after an uneventful hospital observation. We identified two case series and seven case reports of potentially toxic rivaroxaban ingestion in the literature. No serious adverse effects were reported. The present case is the first reported use of anti-FXa monitoring after rivaroxaban ingestion. The magnitude of the effect of AC administration in this patient is unclear. [Clin Pract Cases Emerg Med. 2018;2(3):247–250.]

INTRODUCTION

Rivaroxaban is an oral anticoagulant that directly inhibits factor Xa (FXa). The United States (U.S.) Food and Drug Administration (FDA) has approved its use in adults for prophylaxis and treatment of deep vein thrombosis, pulmonary embolism, and prevention of ischemic stroke in patients with nonvalvular atrial fibrillation. Typical daily doses in adults range from 10 to 30 mg depending on renal function and indication. No FDA-approved indications exist for pediatric patients. A favorable pharmaco-kinetic profile and absence of therapeutic drug monitoring have led to increasing popularity of rivaroxaban over vitamin K antagonists.

Until recently, no antidote was available in the U.S. to reverse the anticoagulant effects of rivaroxaban in an overdose. In May 2018, the FDA approved coagulation FXa (recombinant), inactivated-zhzo for reversal of anticoagulation in patients treated with rivaroxaban or apixaban who are experiencing life-threatening or uncontrolled bleeding. It is not yet widely available for clinical use, however, and it has not been studied in pediatric populations.¹

Anti-FXa assays quantitatively measure plasma levels of unfractionated heparin or low-molecular-weight heparin.²

Multiple, commercially available, automated assays exist, and the test is readily available throughout the U.S. Compared

with activated partial thromboplastin time (aPTT), a more traditional method of measuring response to heparin therapy, anti-FXa assays provide a more specific measurement of heparin activity. Other proposed advantages include faster time to achieving a therapeutic range for heparin anticoagulation, less variability in testing reagents, and fewer laboratory blood samples drawn compared with the aPTT. Anti-FXa is finalized in a similar amount of time and has been shown to be cost neutral compared with aPTT.³ Although there are no FDA-approved anti-FXa reagents for oral FXa inhibitors, a strong correlation has been shown with rivaroxaban concentrations using a heparin-calibrated anti-FXa assay.¹

CASE REPORT

A previously healthy 35-month-old boy (weight, 12.5 kg) was brought to the emergency department (ED) immediately after he was found with partially chewed rivaroxaban tablets in his mouth. His mother reported missing 10 20-mg tablets (200 mg total; approximately 16 mg/kg). The patient had no known family history of bleeding or hypercoagulable disorders.

He was examined within 15 minutes of ingestion by a physician who did not find evidence of bleeding, bruising, or altered mental status. The regional poison control center was then quickly contacted. Activated charcoal (AC) (2 g/kg) was orally

administered within 45 minutes of ingestion and was tolerated well by the patient. During the ED stay, a plasma anti-FXa level was obtained approximately four hours after ingestion. The result (>4.00 international units/mL) exceeded the upper limit of the reference range and markedly surpassed the therapeutic window for unfractionated heparin (0.30- 0.70 international units/mL).

The patient was admitted and observed overnight. At 13.5 hours after ingestion (a time chosen to correspond with the pediatric hospital service's morning rounds the following day), the anti-FXa level was rechecked and found to be 1.51 international units/mL. No other laboratory testing was performed by the ED or inpatient teams. The patient was discharged later that day, less than 24 hours after ingestion, without any complications. He did not receive blood products, reversal agents, or additional doses of AC during his stay.

We performed a literature search to identify case reports of rivaroxaban ingestion. All reports of pediatric ingestion are limited to pediatric subsets of two case series drawn from reports to poison control centers with limited details for individual cases. No reports of quantitative monitoring with anti-FXa levels or utility of AC in pediatric patients were identified.

In one case series, two "1.5-year-old" children accidentally ingested an unknown quantity of rivaroxaban but did not have further evaluation by a healthcare provider. Both patients were lost to follow-up without any treatment or adverse effects reported.⁴ The other case series identified 18 reports of one-time exposure in pediatric patients (age <12 years) who did not have adverse effects. An unspecified minority of patients had results of coagulation studies (international normalized ratio [INR], prothrombin time [PT], or partial thromboplastin time) that were all within the reference ranges.⁵

The other case reports, which involved adults, are summarized in the Table.⁶⁻¹² AC or prothrombin complex concentrate or both were given empirically in some cases with no report of serious morbidity.

DISCUSSION

We report the use of serum anti-FXa, a more specific marker of anticoagulation status than PT/INR in FXa inhibitors, as a means to guide management of rivaroxaban ingestion in a pediatric patient. For our patient, the true peak anti-FXa drawn at four hours was unknown, but the result (>4.00 international units/mL) exceeded the upper limit of the reference range. The anti-FXa level 13.5 hours after ingestion decreased to 1.51 international units/mL.

In healthy adult volunteers, maximal inhibition of FXa with rivaroxaban occurs in two to four hours. The bioavailability (66%-100%) is dependent on the dose and state of fasting.¹³ In healthy adults, a single rivaroxaban tablet has a half-life of six to seven hours. A dose-dependent relationship between the biologic effect and anti-FXa activity has been described.¹⁴

For our patient, if the most conservative peak concentration is used (4.00 international units/mL), we observed a 62%

CPC-EM Capsule

What do we already know about this clinical entity?

Rivaroxaban is an anti-factor Xa (FXa) inhibitor used for anticoagulation, and an overdose could be associated with bleeding. Reports of this are rare in adults and almost nonexistent in children.

What makes this presentation of disease reportable?

This is the first case report of a pediatric rivaroxaban ingestion presented in the literature and the first report of anti-FXa testing being used to confirm ingestion and monitor recovery.

What is the major learning point?

Morbidity from rivaroxaban overdose is rare. Also, anti-FXa is a common laboratory test that can be useful in cases of suspected ingestion, in lieu of traditional coagulation studies.

How might this improve emergency medicine practice?

Anti-FXa testing can be considered in diagnosing and treating a suspected rivaroxaban overdose.

reduction in anti-FXa activity over 9.5 hours. It is plausible that AC helped decrease the absorption and bioavailability of rivaroxaban. Administration of AC within two hours after ingestion has been shown to decrease the serum concentration of rivaroxaban relatively quickly, resulting in a 43% reduction over time in the rivaroxaban area under the curve.¹⁵

It is plausible to attribute the decrease in anti-FXa in our patient to the effect of AC and possible enterohepatic recirculation of rivaroxaban. No evidence is available on the enterohepatic recirculation of rivaroxaban; however, it has been described in animal studies for apixaban and edoxaban, which are in the same therapeutic drug class as rivaroxaban.^{16,17} One study suggested that AC given eight hours after ingestion decreased the rivaroxaban area under the curve even after drug absorption was complete.¹² No conclusions can be made regarding the influence of AC on our patient's outcome given the lack of data in this population. No adverse effects related to AC administration were observed.

CONCLUSION

In summary, our pediatric patient who accidentally ingested

Table. Published case reports of rivaroxaban overdoses.

Age (years)	Sex	Time to presentation	Intentional	Amount of rivaroxaban (mg)	Coingestants	Tests performed	Treatment	Bleeding	Reference
71	M	Unknown	Yes	1,940	None	PT 60.2 s; INR 7.2; aPTT 55.7 s; BUN 28 mg/dL; Cr 1.2 mg/dL	None	None	Repplinger et al ⁶
50s	M	12 h ^a	No	300a	None	INR about 2.1; PT 20 s; PTT 40 s	Activated charcoal	None	Sajkov and Gallus ⁷
28	F	3 mo	Yes	Unknown	Unknown	PT 19.2 s; INR 1.8; PTT 52 s; TEG "normal"	Unknown	Abnormal uterine bleeding	Katragadda et al ⁸
42	M	5 h	Yes	1,400	24 g acetaminophen; 1,200 mg codeine; 600 mg diphenhydramine; 8 mg lorazepam; unknown amount of naproxen	INR 2.4; PTT 46 s	Tranexamic acid; 4fPCC	None	Linkins and Moffat ⁹
63	M	2.5 h	Yes	1,960	90 mg diazepam; 1 g quetiapine; 50 mg zolpidem	PT 66 s; aPTT 64 s	Activated charcoal; 4fPCC	None	Lehmann et al ¹⁰
23	M	12 h	Yes	1,960	31.5 mg phenprocoumon; 1,425 mg diclofenac; 21 g metamizole	PT 34 s; aPTT 128 s	Vitamin K; PCC ^b ; pantoprazole	Single episode of gross hematuria	Pfeiffer et al ¹¹
54	M	3 h	Yes	1,800	1,800 mg enoxaparin	PT 21.4 s; aPTT >150 s; INR 1.9	None	None	Bandali et al ¹²

aPTT, activated partial thromboplastin time; BUN, blood urea nitrogen; Cr, creatinine; 4fPCC, four-factor prothrombin complex concentrate; F, female; g, grams; h, hours; INR, international normalized ratio; M, male; mg, milligrams; mo, months; PCC, prothrombin complex concentrate; PT, prothrombin time; PTT, partial thromboplastin time; s, seconds; TEG, thrombolastography; y, years.

^a Two 150-mg doses separated by 12 hours; recognized 10 minutes after the second dose.

^b Case report did not specify whether three-factor or four-factor PCC was used.

rivaroxaban was treated with early administration of AC and monitored with anti-FXa levels without showing clinically significant morbidity. This case showed the utility of monitoring anti-FXa levels in an ingestion of rivaroxaban and suggested that early use of AC should be considered for pediatric patients who ingest rivaroxaban. Additional pharmacokinetic and toxicokinetic studies of rivaroxaban in pediatric patients are needed to further understand optimal treatment and monitoring.

Documented patient informed consent and/or Institutional Review Board approval has been obtained and filed for publication of this case report.

Address for Correspondence: Brendan M. Carr, MD, MS, Mayo Clinic, Department of Emergency Medicine, 200 1st St SW Rochester MN 55905, Email: Carr.Brendan@mayo.edu.

Conflicts of Interest: By the CPC-EM article submission agreement, all authors are required to disclose all affiliations, funding sources and financial or management relationships that could be perceived as potential sources of bias. The authors disclosed none.

Copyright: © 2018 Carr et al. This is an open access article distributed in accordance with the terms of the Creative Commons Attribution (CC BY 4.0) License. See: <http://creativecommons.org/licenses/by/4.0/>

REFERENCES

1. Portola Pharmaceuticals, Inc. 2018. ANDEXXA [prescribing information]. Available at: <https://www.fda.gov/downloads/BiologicsBloodVaccines/CellularGeneTherapyProducts/ApprovedProducts/UCM606687.pdf>. Accessed May 15, 2018.
2. Gosselin RC, Francart SJ, Hawes EM, et al. Heparin-calibrated chromogenic anti-FXa activity measurements in patients receiving Rivaroxaban: can this test be used to quantify drug level? *Ann Pharmacother*. 2015;49(7):777-83.
3. Rosborough TK. Monitoring unfractionated heparin therapy with antifactor Xa activity results in fewer monitoring tests and dosage changes than monitoring with the activated partial thromboplastin time. *Pharmacotherapy*. 1999;19(6):760-6.
4. Stevenson JW, Minns AB, Smollin C, et al. An observational case series of dabigatran and rivaroxaban exposures reported to a poison control system. *Am J Emerg Med*. 2014;32(9):1077-84.
5. Spiller HA, Mowry JB, Aleguas A Jr, et al. An Observational study of the factor Xa inhibitors rivaroxaban and apixaban as reported to eight poison centers. *Ann Emerg Med*. 2016;67(2):189-95.
6. Repplinger DJ, Hoffman RS, Nelson LS, et al. Lack of significant bleeding despite large acute rivaroxaban overdose confirmed with whole blood concentrations. *Clin Toxicol (Phila)*. 2016;54(8):647-9.
7. Sajkov D, Gallus A. Accidental rivaroxaban overdose in a patient with pulmonary embolism: some lessons for managing new oral anticoagulants. *Clin Med Insights Case Rep*. 2015;8:57-59.
8. Katragadda L, Murphy MC, Harris NS, et al. Steps to diagnosis of a case of surreptitious intake of one of the newer direct oral anticoagulants: a case report and literature review. *Blood Coagul Fibrinolysis*. 2015;26(5):574-6.
9. Linkins LA, Moffat K. Monitoring the anticoagulant effect after a massive rivaroxaban overdose. *J Thromb Haemost*. 2014;12(9):1570-71.
10. Lehmann T, Hofer KE, Baumann M, et al. Massive human rivaroxaban overdose. *Thromb Haemost*. 2014;112(4):834-6.
11. Pfeiffer H, Herbst L, Schwarze B, et al. Massive intoxication with rivaroxaban, phenprocoumon, and diclofenac: a case report. *Medicine (Baltimore)*. 2016;95(44):e5343.
12. Bandali F, Thomas Z, Gozzo Y. 1205: Conservative management of massive rivaroxaban and enoxaparin overdose. *Crit Care Med*. 2014;42(12):A1642.
13. Janssen Pharmaceuticals, Inc. 2017. Xarelto [prescribing information]. Available at: <http://www.janssenlabels.com/package-insert/product-monograph/prescribing-information/XARELTO-pi.pdf>. Accessed February 28, 2018.
14. Kubitzka D, Becka M, Voith B, et al. Safety, pharmacodynamics, and pharmacokinetics of single doses of BAY 59-7939, an oral, direct factor Xa inhibitor. *Clin Pharmacol Ther*. 2005;78(4):412-21.
15. Ollier E, Hodin S, Lanoiselee J, et al. Effect of activated charcoal on rivaroxaban complex absorption. *Clin Pharmacokinet*. 2017;56(7):793-801.
16. Zhang D, Frost CE, He K, et al. Investigating the enteroenteric recirculation of apixaban, a factor Xa inhibitor: administration of activated charcoal to bile duct-cannulated rats and dogs receiving an intravenous dose and use of drug transporter knockout rats. *Drug Metab Dispos*. 2013;41(4):906-15.
17. Parasrampur DA, Truitt KE. Pharmacokinetics and pharmacodynamics of edoxaban, a non-vitamin K antagonist oral anticoagulant that inhibits clotting factor Xa. *Clin Pharmacokinet*. 2016;55(6):641-655.

Nutritional Rickets Presenting as Chronic Episodic Extremity Pain in a 9-year-old with Autism

Noopur Tripathi, BA*

Roopa Kanakatti Shankar, MBBS, MS**†

Aline Baghdassarian, MD, MPH*‡

*Virginia Commonwealth University School of Medicine, Richmond, Virginia

†Children's Hospital of Richmond at VCU, Department of Pediatrics, Division of Pediatric Endocrinology, Richmond, Virginia

‡Virginia Commonwealth University School of Medicine, Department of Emergency Medicine, Division of Pediatric Emergency Medicine, Richmond, Virginia

Section Editor: Rick A. McPheeters, DO

Submission history: Submitted December 6, 2017; Revision received February 15, 2018; Accepted February 27, 2018

Electronically published July 16, 2018

Full text available through open access at http://escholarship.org/uc/uciem_cpccem

DOI: 10.5811/cpcem.2018.2.37206

Rickets due to vitamin D deficiency, typically presenting as bowed legs in toddlers, is uncommon in the modern era. We describe the case of a nine-year-old girl with autism and developmental delay who was evaluated for chronic intermittent extremity pain for more than one year prior to referral to the emergency department for hypocalcemia and increased alkaline phosphatase, which eventually led to the diagnosis of rickets confirmed by radiographic and laboratory findings. This report highlights the importance of the patient's history of developmental delay and autism in the evaluation and approach to limb pain, and discusses the appropriate diagnostic approach. [Clin Pract Cases Emerg Med. 2018;2(3):251–254.]

INTRODUCTION

Nutritional rickets is a metabolic bone disease marked by failure of bone mineralization and architectural disruption at the growth plate. Calcipenic rickets is due to a deficiency in calcium; it can occur either due to inadequate intake or metabolism of vitamin D, or inadequate intake or absorption of calcium in the setting of normal vitamin D levels. This commonly presents at an early age with delayed closure of the fontanelle, frontoparietal bossing of the skull, bowing of the legs, widening of the wrists, and craniotabes. Rickets can also cause developmental delay, delayed achievement of motor milestones, hypocalcemic seizures in the first year of life, and neurologic as well as cardiac pathology. While essentially eradicated in the developed world due to vitamin D supplementation of newborns, there are still reports of nutritional rickets worldwide. This case highlights the importance of considering rickets in the differential diagnosis, especially if there is history of developmental delay and autism.

CASE REPORT

A nine-year-old Hispanic female with a past medical history of autism and global developmental delay presented to our emergency department (ED) complaining of a one-year history

of pain in her extremities. The pain initially started in the right leg causing her to limp, trip, and fall. She was evaluated by her primary care physician and referred to a physical medicine and rehabilitation clinic that prescribed supramalleolar/ankle foot orthosis (SMAFO). The leg pain resolved, but she developed episodic pain in her bilateral upper extremities a month later. Initially manifesting as pain in her left arm, it was managed with nonsteroidal anti-inflammatory medications; then as this resolved she developed pain in her right arm. The episodic chronic pain in her extremities prompted laboratory evaluation and eventually her referral to the ED because of an elevated alkaline phosphatase (1,847 international units/liter [L]) and low serum calcium (6.4 milligrams [mg]/ deci-liter [dL]). Her past medical history was significant for autism and developmental delay. She did not have a family history of frequent fractures, bone pathology, or calcium problems.

On exam, she was non-verbal but followed commands and was comfortable with no acute distress. Her weight and height were less than the third percentile for age with minimal subcutaneous fat but normal body mass index (twelfth percentile). She had angular deformity and diffuse tenderness in the right and left arms and proximal forearms. She was able to bear weight but

had lower extremity pain and difficulty with ambulation. The rest of her physical exam was normal. We noted no spine tenderness, brachydactyly or other dysmorphic features.

Initial laboratory findings were remarkable for hypocalcemia and elevated alkaline phosphatase (Table). Radiographs of her extremities revealed multiple healed and healing fractures (Image 1), initially raising concern for non-accidental trauma. Further review of films with radiology revealed generalized bony demineralization, widened growth plates and metaphyseal fraying and flaring consistent with the diagnosis of rickets (Image 2). No vertebral compression fractures were noted, nor was rachitic rosary noted on chest radiographs. An elevated intact parathyroid hormone level (PTH) and extremely low serum 25-hydroxyvitamin D (25-OH vitamin D) concentration (Table) confirmed a diagnosis of severe hypocalcemic rickets due to vitamin D deficiency.

Endocrinology was consulted and elicited on history that she was a picky eater, only eating rice, fries and potato chips. She drank homemade green juices and smoothies but had limited dairy intake. On further review of systems, the family had not noticed any muscle spasms, seizures or twitching. Physical exam by the endocrinologist revealed widened wrists and ankles and rachitic rosary-prominent costochondral junctions of the ribs. She had no symptoms of neuromuscular irritability (negative Chvostek sign) despite ionized calcium of only 0.93

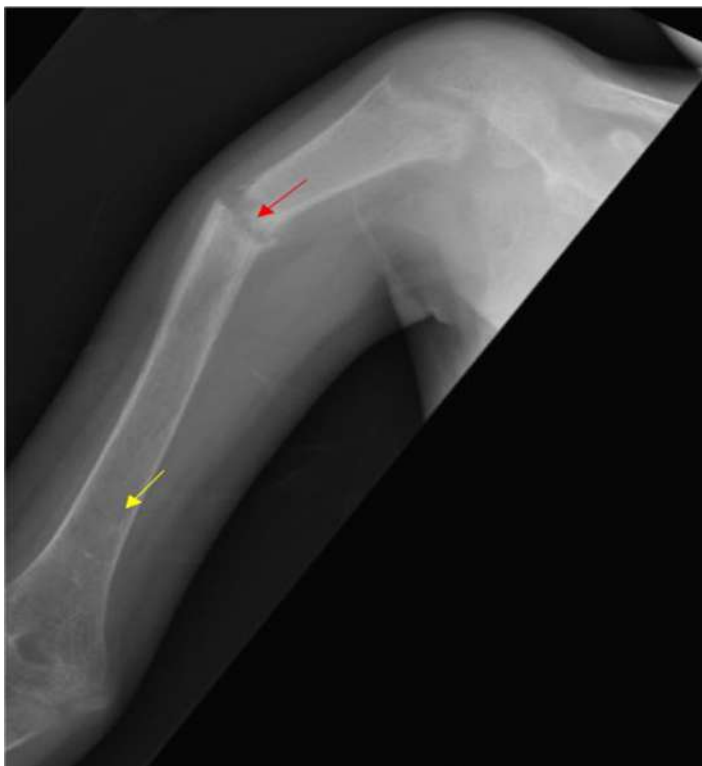

Image 1. Radiograph of the right humerus of a nine-year-old female patient showing demineralization (yellow arrow) and healing fracture (red arrow).

CPC-EM Capsule

What do we already know about this clinical entity?

Nutritional rickets commonly presents at an early age with delayed closure of the fontanelle, frontoparietal bossing of the skull, bowing of the legs, widening of the wrists, and craniotabes.

What makes this presentation of disease reportable?

Late presentation without overt and classical signs and symptoms. The initial differential focused on non-accidental trauma (NAT) and did not entertain rickets.

What is the major learning point?

While NAT should remain high on the differential diagnosis, it's important to remain mindful of the increased risk of nutritional rickets in patients with autism and developmental delay.

How might this improve emergency medicine practice?

With early diagnosis and management in the Emergency Department, Vitamin D deficiency causing rickets can be easily treated and serious complications avoided.

millimoles/L, highlighting the chronicity of the presentation.

The patient received calcium carbonate and calcitriol therapy followed by gradual supplementation of vitamin D3. She experienced significant improvement of pain and gait issues one month after initiation of calcitriol, calcium carbonate, and vitamin D3 supplementation along with orthotics. She was followed by endocrinology and was taken off calcitriol with normalization of calcium and serum 25-OH vitamin D concentrations in a month. One year after the diagnosis, calcium supplementation was also stopped with complete normalization of her calcium (10.1 mg/dL), PTH (38.6 picogram/mL), alkaline phosphatase (355 units/L) and vitamin D (48.7 nanogram/mL). All fractures were well healed except for a malaligned right humerus with no functional disability. She had improved dietary calcium intake with supplemental nutritional shakes and remained on 2,000 IU of vitamin D3 daily.

DISCUSSION

Rickets is a metabolic bone disease marked by failure of bone mineralization in the growth plates. The disease had been

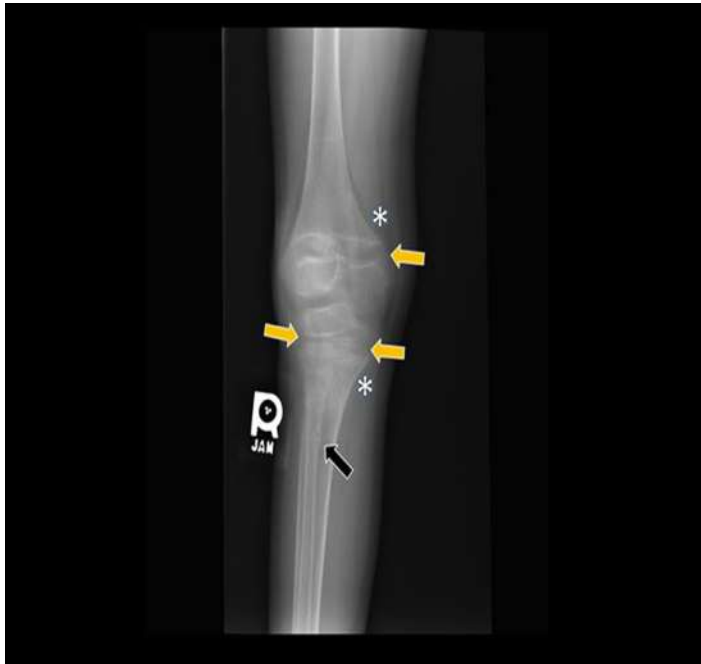

Image 2. Marked generalized bony demineralization with widening of the physes in the distal femur, proximal tibia, and proximal fibula (yellow arrows) with metaphyseal fraying and flaring (asterisk). Healing nondisplaced transverse fracture at the proximal metadiaphysis of fibula (black arrow).

largely eradicated in the United States since the 1930s, with a hospitalization rate of 1.23 per 100,000 in children younger than 10 years old.¹ Another study showed the prevalence of nutritional rickets to be approximately nine cases per one million children.² The Centers for Disease Control and Prevention reports a rate of five cases per one million children aged six months to five years.³ Causes of calcipenic rickets include nutritional deficiency of calcium and vitamin D (the most common cause) and genetic abnormalities in the enzyme 25(OH)D3-1-alpha-hydroxylase or vitamin D receptors. Other causes of rickets include malabsorption syndromes, medications, hypophosphatemic rickets, or renal disease.

Common presenting clinical signs of calcipenic rickets include bowing of the legs, frontal bossing, generalized hypotonia, Harrison's groove formation, pigeon-breast deformity, and rachitic rosary.⁴ Defects in bony mineralization result in an increase in osteoid and therefore an un-mineralized organic bone matrix that loses stability and strength.⁵ At the growth plate, chondrocytes become hypertrophic and disorganized with thickening of the growth plate and hypertrophic zone expansion.⁶ Typical age at presentation is in toddlers with the characteristic bowed legs when they start weight bearing.

Our patient's presentation was more insidious. She did not present with the classic physical exam findings. Instead she had chronic extremity pain at nine years of age. Generally, bone pain is the first symptom on presentation in pediatric

Table. Initial laboratory data for nine-year-old patient presenting with chronic episodic bone pain.

Laboratory test	Value	Reference range
Serum calcium (mg/dL)	6.4	9.1-10.5
Alkaline phosphatase (IU/L)	1847	134-349
Intact parathyroid hormone (PTH) (pg/mL)	1521.3	8.7-77.1
25-hydroxy vitamin D (ng/mL)	2.8	30-100
Ionized calcium (mmol/L)	0.93	2.2-2.7
Phosphorous (mg/dL)	3.6	2.5-4.5
Albumin (g/dL)	4.5	3.5-5.5

mg, milligram; dL, deci-liter; IU, international units; pg, picogram; mL, milliliter; mmol, millimoles; L, liter; g, gram.

patients with acute lymphoblastic leukemia.⁷ Bone pain was also the initial complaint in 67.5% of patients with primary lymphoma.⁸ When children present with chronic bone pain to the ED, clinical suspicion is generally high for physical and sexual abuse, musculoskeletal abnormalities, hematologic processes, or malignancy.¹⁵ Children with disabilities are at higher risk for physical/emotional abuse than those without disabilities.^{9,10} Hence, we entertained this diagnosis in the pediatric ED while the workup was ongoing and the Child Protective Team was consulted.

With its decreasing incidence in the developed world, nutritional rickets due to vitamin D deficiency was not high on the initial differential. However, children with autism must be evaluated on different premises. In fact, children with autism and developmental delay are five times more likely to have feeding difficulty, or specific feeding behaviors, and are particularly susceptible to calcium deficiencies.¹¹ Food selection in children with autism is often based on color and texture preferences, in addition to aversions to dairy products or foods rich in protein. Deficiencies have been observed in vitamins A, B6, B12, C, D, and K.¹² It has also been observed that children with autism have significantly lower vitamin D levels compared to those without autism and that children with vitamin D-dependent rickets have autistic markers, which have resolved after supplementation with vitamin D.¹³

CONCLUSION

Although the differential diagnosis of a child presenting with bone pain includes an extensive list of conditions ranging from benign growing pains to malignancies, in children with developmental delay, failure to thrive, or other musculoskeletal abnormalities, non-accidental trauma, and nutritional rickets should be high on the differential diagnosis. It is important for physicians to remain mindful of the increased risk of nutritional rickets in patients with autism and developmental delay. Vitamin D deficiency causing rickets can be easily treated and serious complications avoided with early diagnosis and management.

ACKNOWLEDGMENT

The authors would like to thank Dr. Joo Y. Cho, MD, Assistant Professor of Pediatric Radiology at Children's Hospital of Richmond at VCU, for the radiographs.

Documented patient informed consent and/or Institutional Review Board approval has been obtained and filed for publication of this case report.

Address for Correspondence: Aline Baghdassarian, MD, MPH, Virginia Commonwealth University School of Medicine, 1250 East Marshall Street, 2nd floor, Suite 500, PO Box 980401 Richmond, VA 23298-0401. Email: Aline.baghdassarian@vcuhealth.org

Conflicts of Interest: By the CPC-EM article submission agreement, all authors are required to disclose all affiliations, funding sources and financial or management relationships that could be perceived as potential sources of bias. The authors disclosed none.

Copyright: © 2018 Tripathi et al. This is an open access article distributed in accordance with the terms of the Creative Commons Attribution (CC BY 4.0) License. See: <http://creativecommons.org/licenses/by/4.0/>

REFERENCES

- Singleton R, Lescher R, Gessner BD, et al. Rickets and vitamin D deficiency in Alaska native children. *J Pediatr Endocrinol Metab.* 2015;28(7-8):815-23.
- Dietz, WH. Vitamin D Expert Panel Meeting October 11 - 12, 2001. Atlanta, Georgia. Final Report, 1-42.
- Severe Malnutrition Among Young Children --- Georgia, January 1997-June 1999. 2001. Available at: <https://www.cdc.gov/mmwr/preview/mmwrhtml/mm5012a3.htm>. Accessed on June 8, 2017.
- Arvind R. *100 Clinical Cases in Pediatrics.* 4th edition. New Delhi: Jaypee Brothers Medical Publishers Ltd, 2016.
- Tietz NW. *Textbook of Clinical Chemistry.* Third edition, edited by Burtis and Ashwood. Philadelphia, PA, WB Saunders Company, Philadelphia, 1999.
- Tiosano D, Hochberg Z. Hypophosphatemia: the common denominator of all rickets. *J Bone Miner Metab.* 2009;27(4):392-401.
- Jonsson OG, Sartain P, Ducore JM, et al. Bone pain as an initial symptom of childhood acute lymphoblastic leukemia: association with nearly normal hematologic indexes. *J Pediatr.* 1990;117(2):233-7.
- Horsman J, Thomas J. Primary bone lymphoma: a retrospective analysis. *J Oncol.* 2006. Available at: <https://www.spandidos-publications.com/ijo/28/6/1571/download>. Accessed on June 12, 2017.
- Mandell DS, Walrath CM, Manteuffel B, et al. The prevalence and correlates of abuse among children with autism served in comprehensive community-based mental health settings. *Child Abuse Negl.* 2005;29(12):1359-72.
- Horne BSV, Moffitt KB, Canfield MA, et al. Maltreatment of children under age 2 with specific birth defects: a population-based study. *Pediatrics.* 2015;136(6):e1504-12.
- Sharp WG, Berry RC, McCracken C, et al. Feeding problems and nutrient intake in children with autism spectrum disorders: a meta-analysis and comprehensive review of the literature. *J Autism Dev Disord.* 2013;43(9):2159-73.
- Shmaya Y, Eilat-Adar S, Leitner Y, et al. Nutritional deficiencies and overweight prevalence among children with autism spectrum disorder. *Res Dev Disabil.* 2015;38:1-6.
- Bener A, Khattab AO, Al-Dabbagh MM. Is high prevalence of Vitamin D deficiency evidence for autism disorder?: In a highly endogamous population. *J Pediatr Neurosci.* 2014;9(3):227-33.
- Roberts AL, Koenen KC, Lyall K, et al. Association of autistic traits in adulthood with childhood abuse, interpersonal victimization, and posttraumatic stress. *Child Abuse Negl.* 2015;45:135-42.
- McCarville MB. The child with bone pain:malignancies and mimickers. *Cancer Imaging.* 2009;(Special issue A):S115-21.

Esophageal Perforation After Failed Prehospital Intubation

Kaila Pomeranz, DO
Nicholas Mohr, MD

University of Iowa Hospitals and Clinics, Department of Emergency Medicine, Iowa City, Iowa

Section Editor: Shadi Lahham, MD

Submission history: Submitted February 28, 2018; Revision received May 18, 2018; Accepted June 14, 2018

Electronically published July 16, 2018

Full text available through open access at http://escholarship.org/uc/uciem_cpem

DOI: 10.5811/cpem.2018.6.38088

Esophageal perforation is a rare condition with high rates of mortality if not recognized quickly. This is a case of a 67-year-old male with a self-inflicted gunshot wound to the head. He had one failed intubation attempt prior to arrival. On postmortem autopsy it was discovered that in addition to significant head trauma he also had an esophageal and gastric rupture. [Clin Pract Cases Emerg Med. 2018;2(3):255–257.]

INTRODUCTION

Esophageal perforation occurs rarely, with an estimated 3.1/1,000,000 population per year.¹ Inciting events are typically iatrogenic or spontaneous rupture and, less commonly, trauma. Even with prompt diagnosis and recognition, mortality rates approach 20%. Gastric contents leak out from the site of rupture, leading to significant inflammation and infection.¹ Esophageal perforation can occur due to unrecognized esophageal intubation or improper bagging techniques.² While uncommon, these injuries are likely under-reported even when recognized, and can have serious implications if not identified. Few case reports cite this complication, and none previously attributed esophageal rupture to recognized prehospital esophageal intubation.

CASE REPORT

A 67-year-old male with past medical history only of hypertension was brought to the emergency department (ED) after a suspected self-inflicted gunshot wound to the head approximately 30 minutes prior to arrival. The patient was found supine and unresponsive by emergency medical services (EMS) with stridorous breath sounds. Paramedics attempted intubation once, but after recognizing esophageal intubation through auscultation they removed the endotracheal tube and placed a King laryngeal tube (LT) supraglottic airway (Ambu®). The second attempt was confirmed by auscultation of bilateral breath sounds and digital end-tidal carbon dioxide monitoring. The airway was suctioned through the King LT and 200 mL of blood was removed. Initial vital signs at the scene were pulse 77 beats per minute (bpm), blood pressure (BP) 134/63 millimeters of mercury (mmHg), room air oxygen saturation (SaO₂) 70%.

Upon arrival to the ED, the patient had a pulse of 74 bpm, respiratory rate 23 breaths per minute, a BP of 122/65 mmHg, SaO₂ 83%. During the primary survey, the King LT was removed and the patient was re-intubated with an endotracheal tube on the first attempt using direct laryngoscopy. He was pre-oxygenated with saturations maximizing in the mid-80s. Secondary survey findings were significant for a gunshot wound to the right temporal region. No additional injuries were found. Pupils were three millimeters bilaterally and fixed, weak corneal reflex, absent cough and gag reflex, and decerebrate posturing in all extremities. Head computed tomography revealed a right parietal entry wound with fragments scattered through the bullet tract and to the left of midline, a large subdural hematoma with rightward shift, diffuse cerebral edema, and a comminuted skull fracture. A chest radiograph (CXR) revealed widening of the superior right mediastinum with loss of definition of airspace in the right upper lobe and absence of the minor fissure, most consistent with complete collapse of right upper lobe (Image). Upon reexamination, no additional injuries or entry sites were found to correlate with the radiograph findings.

The patient was given 100 grams of mannitol for bradycardia and signs of herniation and one gram of levetiracetam prior to transfer to the intensive care unit (ICU) for expectant management of his head injury while waiting for family to arrive. At admission to ICU, his blood pressure was 80/50 mmHg with heart rate in the seventies. His neurologic exam remained poor. Bronchoscopy was performed in the ICU due to persistent hypoxia and revealed blood obstructing the right mainstem bronchus, which was suctioned and evacuated

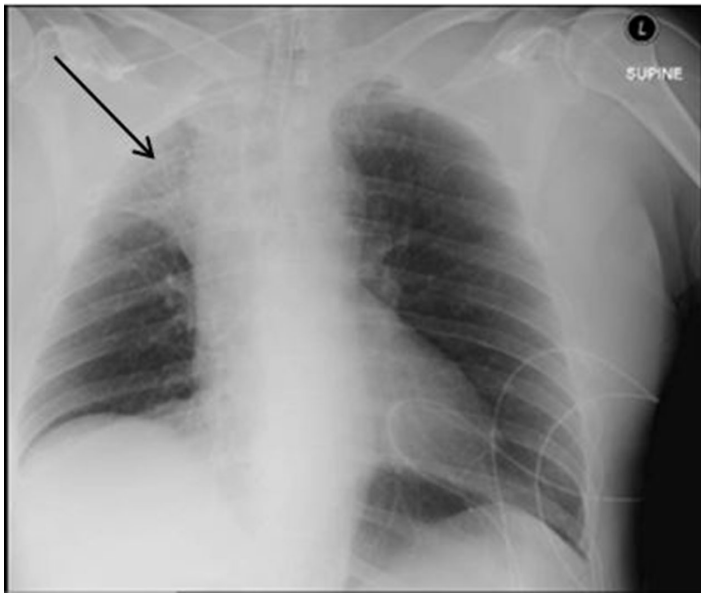


Image. Initial chest radiograph demonstrating mediastinal widening and collapse of the right upper lobe (arrow) in patient with esophageal perforation

from the right lung. A right-sided chest tube was placed for pneumothorax identified after bronchoscopy with blood evacuated from the chest cavity. Due to the poor prognosis of the patient, care was transitioned to comfort measures and he was compassionately extubated.

Autopsy was performed approximately 12 hours after death. In addition to significant intracranial hemorrhage and edema, the patient was noted to have a transection of the gastroesophageal junction and a large disruption of the greater curvature of the stomach. Blood was noted in the mediastinum and within the pleural and peritoneal cavities. No inflammation or ischemic changes were noted on histologic specimens of the stomach, but specimens from the esophagus and gastroesophageal junction were suggestive of ischemia.

DISCUSSION

Rupture of the esophagus and stomach are rare complications of esophageal or failed intubation. These injuries are likely under-recognized and under-reported. Esophageal or gastric rupture is more often associated with cardiopulmonary resuscitation (CPR), occurring in up to 12% of those who undergo CPR.³ In the case described, no CPR was performed, but he did have a failed intubation attempt.⁴ The use of bag-valve-mask ventilation, especially if improperly performed or performed after esophageal intubation, can greatly increase pressure in the stomach, with as little as 15 cm H₂O resulting in gastric distention. This distention decreases the amount of air that is able to leave the stomach, resulting in an increase in pressure and subsequent rupture.³ Risk factors for perforation are

CPC-EM Capsule

What do we already know about this clinical entity?

Esophageal perforation is rare but with significant mortality if not quickly identified. Iatrogenic and spontaneous ruptures are the most common causes.

What makes this presentation of disease reportable?

Esophageal rupture secondary to esophageal intubation is a rare event, but the conditions predisposing patients are common in the emergency department (ED) and it should remain a consideration for ED practitioners. We found no case reports of rupture secondary to prehospital intubation.

What is the major learning point?

Esophageal intubation can be recognized through a combination of radiography findings, clinical findings, and historical features.

How might this improve emergency medicine practice?

Recognition of esophageal perforation after intubation will improve emergency physicians' ability to initiate early evaluation, consultation, and therapy in affected patients.

similar to risk factors for difficult intubations, including poor visualization, macroglossia, trismus, and short neck.² Other potential causes of esophageal rupture could be direct trauma from the endotracheal tube or the esophageal airway placement, but the location of the perforation make direct trauma unlikely in this case.

Typical findings suggestive of esophageal rupture on chest radiography are a widened mediastinum and pneumomediastinum. Subcutaneous emphysema and loss of contour of the descending aorta can also be visualized.² CXR using water-soluble contrast can reveal sites of contrast leak and can be repeated if initial imaging is negative but clinical suspicion remains elevated.⁵ Esophageal tears are typically visualized in the upper one-third of the esophagus or the distal esophagus near the esophagogastric junction.² Subtle findings such as neck pain or dysphagia may be noted. Objective signs such as neck swelling or subcutaneous emphysema may be

recognized. More significantly, signs of sepsis can appear quickly if the injury is missed.^{2,6}

In the controlled surgical environment, patients may be able to report symptoms postoperatively; however, our patient remained intubated and sedated and the injury was not discovered until postmortem. On autopsy, the significant amount of hemorrhage present supported the assertion that the injury occurred before death. A failed intubation attempt in the field, abnormal mediastinum visualized on chest radiography, and treatment-resistant hypoxia suggest that this injury was likely present at the time of ED evaluation but was not recognized.

Treatment is controversial due to low incidence and very high mortality with little outcomes data guiding management. Early recognition and aggressive antimicrobial therapy is likely associated with best outcomes, with mortality rising sharply after the first 24 hours (over 60%), typically due to overwhelming infection.¹ Patients who are clinically stable may be managed in a non-operative fashion, but unstable patients require primary surgical repair or esophageal stent placement. Early recognition is key to improving clinical outcomes.⁵

An alternative diagnosis that can cause gastroesophageal perforation is postmortem gastromalacia and esophagomalacia, which are well documented in the literature. Endogenous enzymes, pepsinogen and hydrochloric acid are released leading to autolytic rupture with subsequent effects including pneumoperitoneum or pneumothorax.⁷ Although it can be difficult to discern timing of the rupture, gastromalacia is more common in the fundus or distal esophagus, with 70-80% of perforations occurring at the lesser curvature of the stomach.⁴ It is typically recognized as thinned tissue without inflammation, hemorrhage, or signs of peritonitis.⁷ The timing of these changes after death remains unclear, but it is reported to occur within the first 20 hours following death.^{7,8} In this case the patient's clinical presentation, recognized antemortem pneumothorax, and postmortem evidence of hemorrhage suggest an antemortem injury, most likely secondary to intubation trauma and esophageal insufflation.

CONCLUSION

In conclusion, this case displays a rare complication of a common procedure in the setting of trauma in the prehospital environment. Rapid recognition of esophageal or gastric perforation can be critical to initiating early therapy and limiting the morbidity and mortality of this serious condition.

Documented patient informed consent and/or Institutional Review Board approval has been obtained and filed for publication of this case report.

Address for Correspondence: Kaila Pomeranz, DO, University of Iowa Hospitals and Clinics, Department of Emergency Medicine, 200 Hawkins Drive, 1008 RCP, Iowa City, IA 52242.
Email: Kaila-Pomeranz@uiowa.edu.

Conflicts of Interest: By the *CPC-EM* article submission agreement, all authors are required to disclose all affiliations, funding sources and financial or management relationships that could be perceived as potential sources of bias. The authors disclosed none.

Copyright: © 2018 Pomeranz. This is an open access article distributed in accordance with the terms of the Creative Commons Attribution ([CC BY 4.0](http://creativecommons.org/licenses/by/4.0/)) License. See: <http://creativecommons.org/licenses/by/4.0/>

REFERENCES

1. Kaman L, Iqbal J, Kundil B, et al. Management of esophageal perforation in adults. *Gastroenterology Res.* 2010;3(6):235-44.
2. Ku PK, Tong MC, Ho KM, et al. Traumatic esophageal perforation resulting from endotracheal intubation. *Anesthesia Analg.* 1998;87(3):730-1.
3. Miller JS, Itani KM, Oza MD, et al. Gastric rupture with tension pneumoperitoneum: a complication of difficult endotracheal intubation. *Ann Emerg Med.* 1997;30(3):343-6.
4. Schvadron E, Moses Y, Weissberg D. Gastric rupture complicating inadvertent intubation of the esophagus. *Can J Surg.* 1996;39(6):487-9.
5. Soreide JA, Viste A. Esophageal perforation: diagnostic work-up and clinical decision-making in the first 24 hours. *Scand J Trauma Resusc Emerg Med.* 2011;19:66.
6. Jougon J, Cantini O, Delcambre F, et al. Esophageal perforation: life threatening complication of endotracheal intubation. *Eur J Cardiothoracic Surg.* 2001;20(1):7-10; discussion 10-11.
7. Laczniak AN, Sato Y, Nashelsky M. Postmortem gastric perforation (gastromalacia) mimicking abusive injury in sudden unexplained infant death. *Pediatr Radiol.* 2011;41(12):1595-7.
8. De-Giorgio F, Lodise M, Pascali VL, et al. An unusual case showing fatal rupture of a gastric ulcer or gastromalacia? The importance/role of histology for differential diagnosis. *J Forensic Sci.* 2015;60(1):240-2.

Invasive Fungal Sinusitis Minimally Evident by Physical Examination

Manish Amin, DO
Vikram S. Shankar, MD
Laura C. Castro, MS
Phillip Aguiñiga-Navarrete, RA

Kern Medical, Department of Emergency Medicine, Bakersfield, California

Section Editor: Shadi Lahham, MD, MS

Submission history: Submitted February 6, 2018; Revision received March 29, 2018; Accepted April 19, 2018

Electronically published May 18, 2018

Full text available through open access at http://escholarship.org/uc/uciem_cpccem

DOI: 10.5811/cpccem.2018.4.37872

[Clin Pract Emerg Med. 2018; 2(3):258-259.]

CASE PRESENTATION

A 35-year-old immunocompetent female with a history of intracranial fungal abscess with surgical resection 11 years prior presented with headache for four months. Her headache was located along frontal sinuses. Vital signs were normal. Head examination was significant for minimal left maxillary swelling with mild tenderness to palpation (Image 1). A fibrotic scar located on the right forehead was present from previous

craniectomy. Nasal turbinates were normal appearing. Neurologic examination was normal.

Complete blood count and electrolytes were within normal limits. Computed tomography of the face showed ethmoid and maxillary sinus bone destructions with extension into the right frontal lobe and surrounding facial structures, consistent with severe fungal disease (Image 2). Inpatient nasal endoscopy with biopsy showed fungal elements consistent with *Aspergillus* species.

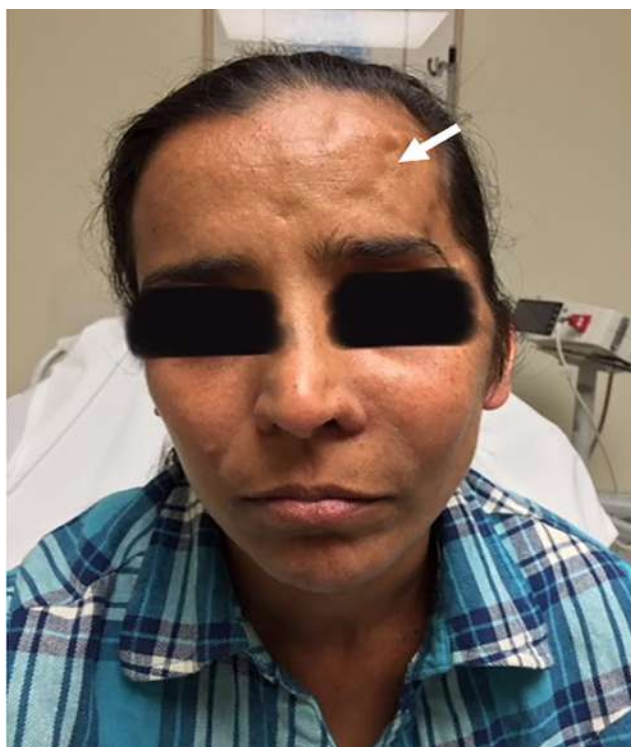

Image 1. Photograph of patient with minimally evident presentation of invasive fungal infection and old fibrotic scar (white arrow).

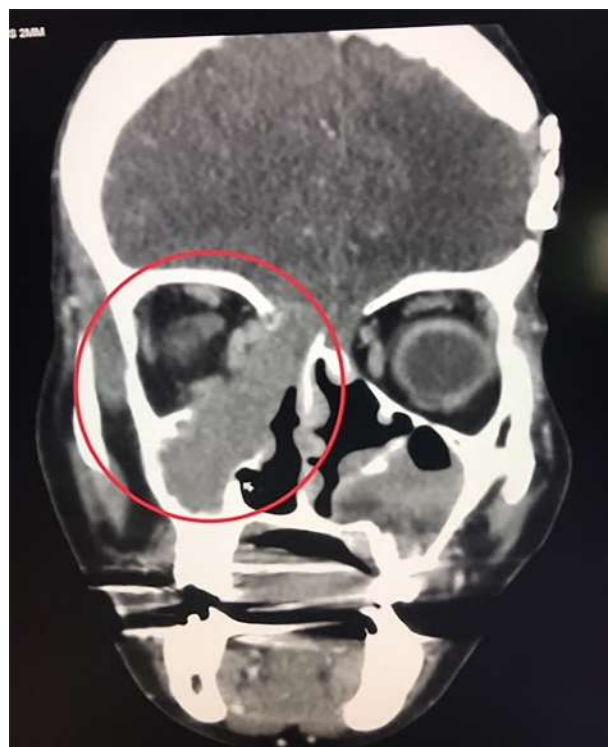


Image 2. Right-sided mass with extension into ethmoid and maxillary sinuses (red circle).

DISCUSSION

Aspergillus species, Fusarium species, the Mucorales, and dematiaceous (brown-black) molds are among the most common causative agents of invasive fungal sinusitis.^{1,2} The chronic course is typically greater than 12 weeks and takes an indolent form that may present with little or no systemic signs or symptoms.^{3,4} Therefore, the emergency physician must maintain a high index of suspicion for such pathology. In the case of our patient, the extensive and severe nature of her pathology was not appreciated by physical examination. Physical exam should include careful inspection of the nares and oral cavity for areas of necrosis.⁵ Other physical exam findings may include tenderness to palpation of the maxillary sinuses. Neurologic examination may reveal decreased sensation in malar areas and visual changes due to optic nerve and/or orbit involvement.

In general, invasive rhinosinusitis is difficult to cure and survival rates are poor. Long-term sinonasal complications such as mycotic aneurysms, cavernous sinus thrombosis, and cerebral infarcts or hemorrhage may develop.⁶ Because of the poor prognosis, early diagnosis and aggressive treatment is necessary. A high index of suspicion for invasive fungal infection should be maintained in patients complaining of sinus symptoms including facial pain and headache, especially in the setting of immunocompromised status.

Documented patient informed consent and/or Institutional Review Board approval has been obtained and filed for publication of this case report.

Address for Correspondence: Manish Amin, DO, Kern Medical, Department of Emergency Medicine, 1700 Mount Vernon Avenue, Bakersfield, CA 93306. Email: Amintribe@yahoo.com.

Conflicts of Interest: By the CPC-EM article submission agreement, all authors are required to disclose all affiliations, funding sources and financial or management relationships that could be perceived as potential sources of bias. The authors disclosed none.

Copyright: © 2018 Amin et al. This is an open access article distributed in accordance with the terms of the Creative Commons Attribution (CC BY 4.0) License. See: <http://creativecommons.org/licenses/by/4.0/>

CPC-EM Capsule

What do we already know about this clinical entity?

Aspergillus, Fusarium, and Mucorales are the most common causative agents of invasive fungal sinusitis. Computed tomography specificity and sensitivity is not optimal for diagnosis.

What is the major impact of the image(s)?

The images demonstrate how a chronic course may take an indolent form and present with little or no physical signs, and that aggressive treatment may be necessary given potentially benign findings.

How might this improve emergency medicine practice?

These images raise awareness of the need to maintain a high index of suspicion of a potentially acute disease that may be difficult to diagnose clinically, but where early intervention may be life-saving.

REFERENCES

1. Waitzman AA, Birt BD. Fungal sinusitis. *J Otolaryngol.* 1994;23(4):244-9.
2. deShazo RD, Chapin K, Swain RE. Fungal sinusitis. *N Engl J Med.* 1997;337(4):254-9.
3. Chakrabarti A, Denning DW, Ferguson BJ, et al. Fungal rhinosinusitis: a categorization and definitional schema addressing current controversies. *Laryngoscope.* 2009;119(9):1809-18.
4. Pekala KR, Clavenna MJ, Shockley R, et al. Chronic invasive fungal sinusitis associated with intranasal drug use. *Laryngoscope.* 2015;125(12):2656-9.
5. DelGaudio JM, Clemson LA. An early detection protocol for invasive fungal sinusitis in neutropenic patients successfully reduces extent of disease at presentation and long term morbidity. *Laryngoscope.* 2009;119(1):180-3.
6. Monroe MM, McLean M, Sautter N, et al. Invasive fungal rhinosinusitis: a 15-year experience with 29 patients. *Laryngoscope.* 2013;123(7):1583-7.

Traumatic Acetabular Protrusion

William Weber, MD, MPH
Jacob Moore, MD
Navneet Cheema, MD

The University of Chicago, Department of Medicine, Section of Emergency Medicine,
Chicago, Illinois

Section Editor: Manish Amin, DO

Submission history: Submitted January 29, 2018; Revision received March 23, 2018; Accepted March 28, 2018

Electronically published May 18, 2018

Full text available through open access at http://escholarship.org/uc/uciem_cpccem

DOI: 10.5811/cpcem.2018.3.37750

[Clin Pract Cases Emerg Med. 2018;2(3):260–261.]

CASE PRESENTATION

A 69-year-old woman with a history of osteopenia and left total hip arthroplasty three months prior presented from home to the emergency department with leg pain and inability to ambulate. She had fallen from standing onto a tile floor, making contact with her left hip. She was mildly hypertensive, with a blood pressure of 137/92 mmHg and tachycardic, with a heart rate of 105 beats per minute, but had otherwise unremarkable vitals. On examination, she had tenderness and developing ecchymosis over the greater trochanter of the left femur. Her left leg was slightly shortened and externally rotated but neurovascularly intact. A pelvic radiograph (Image) showed medial displacement of the acetabulum and femoral head into the lesser pelvis. Angiography failed to reveal any vascular disruption. She remained hemodynamically stable and was taken to surgery for an urgent but successful internal pelvic fixation.

DIAGNOSIS

Acetabular protrusion most commonly occurs as a chronic erosion of the acetabulum in patients with osteoporosis or other disease of the bone (e.g., osteomalacia, ankylosing spondylitis). Also, as in the case of acute trauma, force transmitted through joint can cause failure of acetabular integrity. This acetabular protrusion brings the femoral head in close proximity to pelvic contents, risking further injury. Providers should assess for sciatic nerve damage, which occurs in up to 30% of acute acetabular fractures, as well as injury to the iliac artery, which is at risk of shearing injury as it courses along the internal pelvic cavity.² Unlike with other pelvic fractures, there is no role for pelvic binding in acetabular protrusion, as it can potentially worsen neurovascular damage.³ For the hemodynamically unstable patient, interventional radiology should be consulted for embolization of the internal iliac.⁴

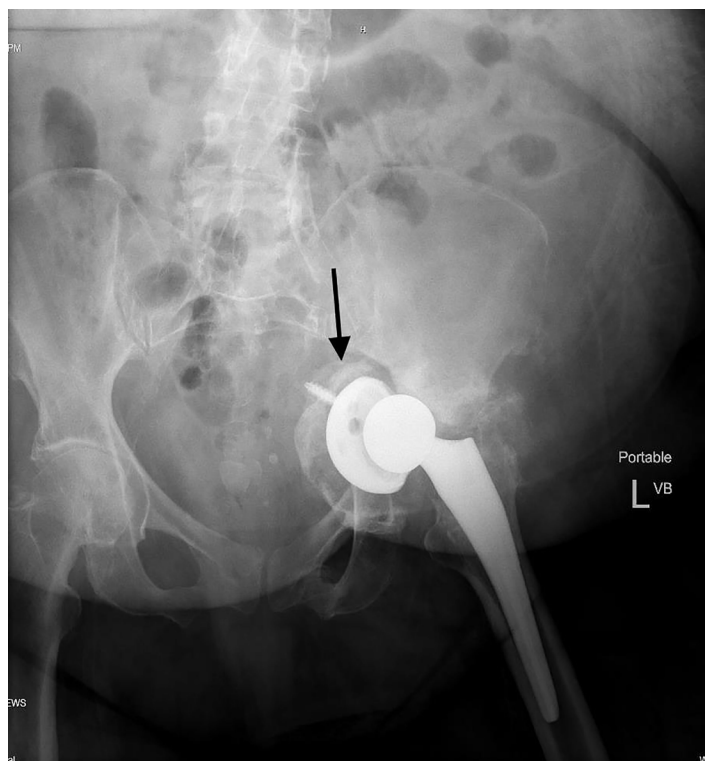


Image. Anterior-posterior radiograph of the pelvis demonstrating medial displacement of the acetabulum and femoral head (arrow) into the lesser pelvis.

Stable patients may be placed in traction to minimize medial force on the acetabulum.

Documented patient informed consent and/or Institutional Review Board approval has been obtained and filed for publication of this case report.

Address for Correspondence: William Weber, MD, MPH, The University of Chicago, Department of Medicine, Section of Emergency Medicine, 5841 S. Maryland Avenue, MC5068, Room L539 Chicago, IL 60637. Email: williamdanielweber@gmail.com.

Conflicts of Interest: By the CPC-EM article submission agreement, all authors are required to disclose all affiliations, funding sources and financial or management relationships that could be perceived as potential sources of bias. The authors disclosed none.

Copyright: © 2018 Weber et al. This is an open access article distributed in accordance with the terms of the Creative Commons Attribution (CC BY 4.0) License. See: <http://creativecommons.org/licenses/by/4.0/>

REFERENCES

1. McBride MT, Muldoon MP, Santore RF, et al. Protrusion acetabuli: diagnosis and treatment. *J Am Acad Ortho Surg.* 2001;9(2):79-88.
2. Issack PS, Helfet DL. Sciatic nerve injury associated with acetabular fractures. *HHS J.* 2009;5(1):12-8.
3. Auston DA, Simpson RB. Initial treatment of "pelvic injuries" with commercially available pelvic binders results in displacement of acetabular fractures. *JBJS Case Connect.* 2015;5(1)e:20-e4.
4. Lopera JE. Embolization in trauma: principles and techniques. *Semin Intervent Radiol.* 2010;27(1):14-28.

CPC-EM Capsule

What do we already know about this clinical entity?

Acetabular protrusion is a medial displacement of the acetabulum into the true pelvis. It usually occurs chronically, as natural forces cause the femoral head to erode through weakened bone.

What is the major impact of the image(s)?

Acute traumatic protrusion jeopardizes nearby structures, including iliac vessels. Traditional pelvic binding increases risk of neurovascular injury, acute hemorrhage, and limb ischemia.

How might this improve emergency medicine practice?

Physicians encountering traumatic acetabular protrusion should avoid pelvic binding, and have low threshold to consult interventional radiology for angiography and possible embolization.

Accidental Hydrogen Peroxide Ingestion

Rohit B. Sangal, MD*
Jonathan Bar, MD*
Brian Weiss, MD*
Matthew Kelly, MD*†
Timothy Medina, MD‡

*Perelman School of Medicine at the University of Pennsylvania, Department of Emergency Medicine, Philadelphia, Pennsylvania

†Perelman School of Medicine at the University of Pennsylvania, Department of Emergency Medicine, Division of Undersea and Hyperbaric Medicine, Philadelphia, Pennsylvania

‡Lancaster General Hospital, Department of Emergency Medicine, Lancaster, Pennsylvania

Section Editor: Shadi Lahham, MD, MS

Submission history: Submitted January 29, 2018; Revision received April 19, 2018; Accepted April 19, 2018

Electronically published May 18, 2018

Full text available through open access at http://escholarship.org/uc/uciem_cpccem

DOI: 10.5811/cpcem.2018.4.37749

[Clin Pract Cases Emerg Med. 2018;2(3):262–263.]

CASE PRESENTATION

A 69-year-old male with no significant past medical history presented to the emergency department (ED) after accidental ingestion of hydrogen peroxide. He used concentrated hydrogen peroxide as a home remedy. Intending to drink water, he had accidentally grabbed the incorrect bottle and ingested “multiple gulps.” He soon started to experience multiple symptoms including eructation, flatulence, nausea, non-bloody vomiting and generalized abdominal pain. His computed tomography is shown (Image 1A). During his stay in the ED he started to complain of headache, blurry vision and was found to have a left homonymous hemianopia, dysmetria and hyperreflexia. He was emergently transferred to a tertiary care hospital for hyperbaric therapy.

DISCUSSION

The patient was diagnosed with portal venous gas and presumed cerebral air embolism. Concentrated hydrogen peroxide (>10%) is primarily an industrial chemical (as opposed to the 3% concentration sold for consumer use), but it is also used as a natural remedy when diluted for “hyperoxygen” therapy.^{1,2} These ingestions not only cause direct caustic injury but the resulting exothermic reaction liberates large volumes of oxygen that distend the stomach and, if not expelled, diffuse into the blood stream and tissues.³ Some studies report that hyperbaric therapy improves outcomes from cerebral infarction secondary to air embolism.^{1,2}

Our patient, already experiencing a visual field deficit, emergently received hyperbaric therapy over advanced head imaging given concern for neurologic sequelae. His follow-up abdominal computed tomography less than 24 hours after completing hyperbaric therapy showed complete resolution of portal venous gas (Image 1B). His gastrointestinal and neurologic symptoms resolved, and he returned to baseline.

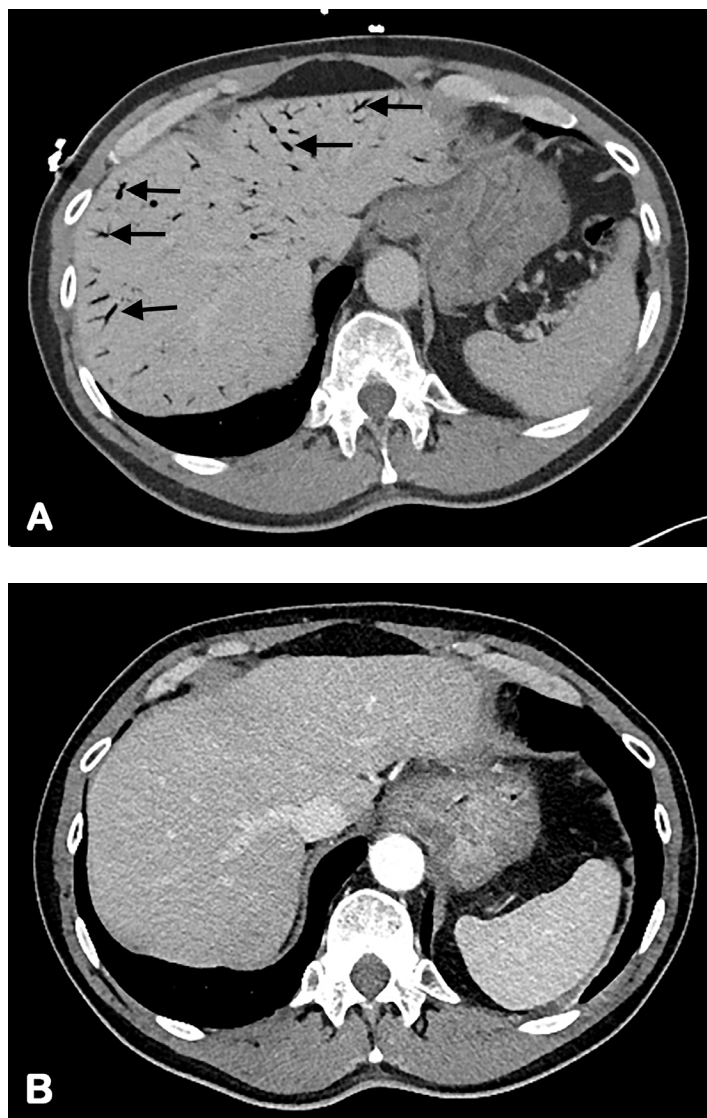


Image 1. Computed tomography of abdomen showing portal venous gas of the liver before hyperbaric oxygen therapy (arrows) (A) and resolution after therapy (B).

Documented patient informed consent and/or Institutional Review Board approval has been obtained and filed for publication of this case report.

Address for Correspondence: Rohit B. Sangal, MD, Hospital of the University of Pennsylvania, Department of Emergency Medicine, 3400 Spruce St Philadelphia PA USA 19104. Email: rohit.sangal@uphs.upenn.edu.

Conflicts of Interest: By the *CPC-EM* article submission agreement, all authors are required to disclose all affiliations, funding sources and financial or management relationships that could be perceived as potential sources of bias. The authors disclosed none.

Copyright: © 2018 Sangal et al. This is an open access article distributed in accordance with the terms of the Creative Commons Attribution ([CC BY 4.0](http://creativecommons.org/licenses/by/4.0/)) License. See: <http://creativecommons.org/licenses/by/4.0/>

REFERENCES

1. French LK, Horowitz BZ, McKeown NJ. Hydrogen peroxide ingestion associated with portal venous gas and treatment with hyperbaric oxygen: a case series and review of the literature. *Clin toxicol (Phila)*. 2010;48(6):533-8.
2. Hatten BW, French LK, Horowitz BZ, et al. Outcomes after high-concentration peroxide ingestions. *Ann Emerg Med*. 2017;69(6):726-36.e2.
3. Mullins ME, Beltran JT. Acute cerebral gas embolism from hydrogen peroxide ingestion successfully treated with hyperbaric oxygen. *J Toxicol Clin Toxicol*. 1998;36(3):253-6.

CPC-EM Capsule

What do we already know about this clinical entity?

Hydrogen peroxide is a common household item that has a variety of uses including as a home remedy. As such, providers need to be aware of the effects of toxic ingestions.

What is the major impact of the image(s)?

While portal venous gas can develop quickly and be extensive, it can be reversible with quick recognition and treatment.

How might this improve emergency medicine practice?

Providers should have a heightened awareness of the effect of this household ingestion and have a low threshold to image or observe patients for progression of symptoms.

Iliopsoas Abscess Due to Nephrolithiasis and Pyelonephritis

Daniel Frank, MD*
 Brian Neal, DO*
 Andrew Jacobs, MD†

*Southside Hospital, Department of Emergency Medicine, Bay Shore, New York
 †Southside Hospital, Department of Family Medicine, Bay Shore, New York

Section Editor: Manish Amin, DO

Submission history: Submitted March 7, 2018; Revision received April 20, 2018; Accepted April 25, 2018

Electronically published May 18, 2018

Full text available through open access at http://escholarship.org/uc/uciem_cpccem

DOI: 10.5811/cpcem.2018.4.38206

[Clin Pract Cases Emerg Med. 2018;2(3):264–265.]

CASE PRESENTATION

A 52-year-old-male presented to our emergency department with gradually worsening left lower back pain radiating to his left leg for six weeks. He had sustained a previous spinal cord injury from a motor vehicle accident with thoracolumbar fusion, and he self-catheterizes for urine due to a neurogenic bladder. He originally attributed his pain to his chronic ailments, but worsening pain and subjective fevers prompted his visit. He presented febrile to 38.6° Celsius, tachycardic to 130 beats per minute, and normotensive. Physical exam was significant for a firm, tender nodular mass to his left flank. Laboratory analysis revealed white blood cell count (WBC) 23.8 x 10³/uL, lactate 0.8 mmol/L, and urinalysis demonstrated bacteria too numerous to count and 50 WBC per high-power field.

Computed tomography of the abdomen and pelvis revealed a large fluid collection measuring 7.5 x 8.7 x 15 centimeters centered in the left psoas muscle that abuts and displaces the left kidney. The kidney demonstrates a staghorn calculus with surrounding cystic changes that is contiguous with the psoas collection (Images 1 and 2).

Our patient received broad spectrum antibiotics and underwent percutaneous drainage, which is often considered first-line treatment.^{1,2} Blood and body-fluid cultures grew beta-hemolytic *Streptococcus*. He was ultimately discharged with a pigtail catheter left in place and treated for six weeks with intravenous ceftriaxone.

DISCUSSION

Iliopsoas abscess is a rare condition often presenting with varied and non-specific symptoms. They are often characterized as either primary or secondary. Primary iliopsoas abscess occurs from hematogenous spread, while secondary iliopsoas results from direct extension of a nearby infectious process.¹ Most secondary cases result from gastrointestinal causes, such as inflammatory bowel disease, diverticulitis, or appendicitis. Cases resulting from genitourinary disease are exceedingly rare, accounting for only 3% of cases in one series.² Our patient was at high risk for genitourinary infections from self-

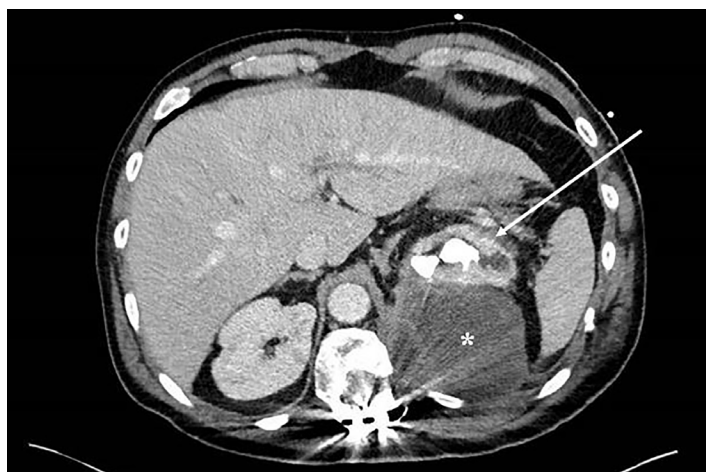


Image 1. Computed tomography, axial image, demonstrating large fluid collection (*) centered over the left psoas. The left kidney is displaced and demonstrates a staghorn calculus with cystic changes contiguous with the fluid collection (arrow). There is artifact from spinal fusion hardware.

catheterizing. We also discovered a large staghorn calculus that he was previously unaware of. Given that cystic changes in the kidney were contiguous with the collection, the imaging strongly suggests that a chronically infected renal calculus led to formation of the abscess.

Regardless of the cause of a psoas abscess, whether it is primary or secondary, most cases do not require open surgical drainage. In one retrospective review, 97% of patients were treated successfully with percutaneous drainage or antibiotics alone. The authors concluded that the initial management of psoas abscesses should be nonsurgical.³

Documented patient informed consent and/or Institutional Review Board approval has been obtained and filed for publication of this case report.

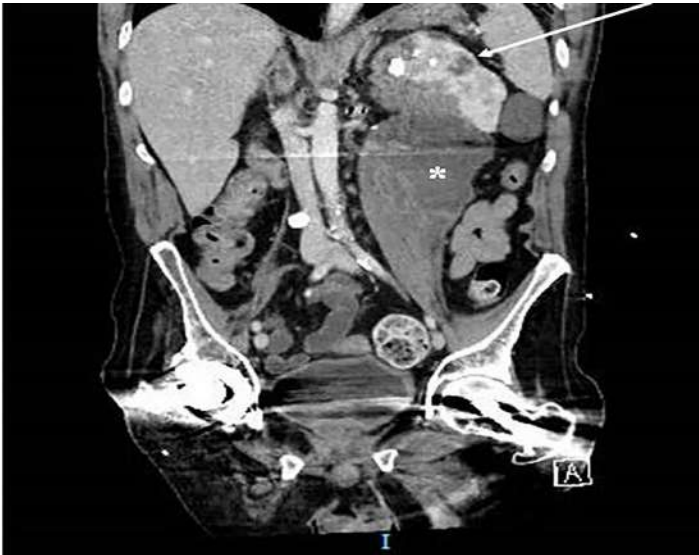

Image 2. Computed tomography, coronal image, demonstrating large fluid collection (*) centered over the left psoas. The left kidney is displaced and demonstrates a staghorn calculus with cystic changes contiguous with the fluid collection (arrow).

Address for Correspondence: Daniel Frank, MD, Southside Hospital, Department of Emergency Medicine, 301 East Main Street, Bay Shore, New York 11706. Email: danfrank@live.com.

Conflicts of Interest: By the CPC-EM article submission agreement, all authors are required to disclose all affiliations, funding sources and financial or management relationships that could be perceived as potential sources of bias. The authors disclosed none.

Copyright: © 2018 Frank et al. This is an open access article distributed in accordance with the terms of the Creative Commons Attribution (CC BY 4.0) License. See: <http://creativecommons.org/licenses/by/4.0/>

CPC-EM Capsule

What do we already know about this clinical entity?

Iliopsoas abscess is a rare clinical entity with various causes and non-specific symptoms. Mainstays of treatment are prompt antibiotics and procedural drainage.

What is the major impact of the image(s)?

Rarely has iliopsoas abscess been attributed to a genitourinary source, nor has such a case been described in the emergency medicine literature.

How might this improve emergency medicine practice?

This case adds to our understanding of the full scope of potential complications related to pyelonephritis and nephrolithiasis, two clinical entities frequently encountered.

REFERENCES

1. Shields D, Robinson P, Crowley TP. Iliopsoas abscess – a review and update on the literature. *Int J Surg.* 2012;10(9):466-9.
2. Tabrizian P, Nguyen SQ, Greenstein A, et al. Management and treatment of iliopsoas abscess. *Arch Surg.* 2009;144(10):946-9.
3. Yacoub WN, Sohn HJ, Chan S. Psoas abscess rarely requires surgical intervention. *Am J Surg.* 2008;196(2):223-7.

Open Globe: Corneal Laceration Injury with Negative Seidel Sign

Kyle Couperus, MD*

Andrew Zabel, DO†

Morohunranti O. Oguntoye, MD‡

*Madigan Army Medical Center, Department of Emergency Medicine, Tacoma, Washington

†William Beaumont Army Medical Center, El Paso, Texas

‡Kimbrough Ambulatory Care Center, Department of Ophthalmology, Fort Meade, Maryland

Section Editor: Rick A. McPheeters, DO

Submission history: Submitted February 28, 2018; Revision received April 15, 2018; Accepted April 25, 2018

Electronically published June 12, 2018

Full text available through open access at http://escholarship.org/uc/uciem_cpccem

DOI: 10.5811/cpcem.2018.4.38086

[Clin Pract Emerg Med. 2018;2(3):266-267.]

CASE PRESENTATION

We present a 31-year-old male who sustained an isolated stellate corneal laceration associated with an open globe injury. The patient presented with mild, right eye pain one hour after glass was sustained to the face during a motor vehicle collision. Visual acuity was 20/100 (baseline 20/20), but no obvious facial or ocular trauma was noted. Extraocular movements were intact. Slit lamp examination revealed a central stellate corneal laceration, peaked 4mm non-reactive pupil, flat anterior chamber, and a falsely negative Seidel sign (Image 1). Intraocular pressure was not measured given the nature of the injury. Computed tomography (CT) orbits revealed a flat anterior chamber (Image 2). The patient was placed in an eye shield, treated for nausea/

pain, initiated on antibiotics with levofloxacin, and updated on tetanus; ophthalmology then completed a surgical repair.

DISCUSSION

Ocular trauma accounts for roughly 3% of emergency department visits and is a major cause of unilateral visual impairment and permanent visual loss in young individuals.^{1,2} Open globe injuries occur more commonly in males and should be in the differential diagnosis with any injury involving high-velocity metal or glass.^{1,3} Penetrating mechanisms tend to be more common in the young, while a blunt mechanism is more common in the elderly.^{1,3} Exam findings can be subtle. Classic teaching revolves around Seidel's sign; it is not sensitive, but

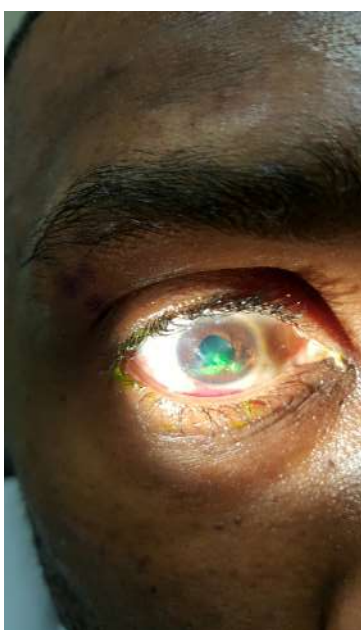

Image 1. Stellate corneal laceration with negative Seidel Sign.

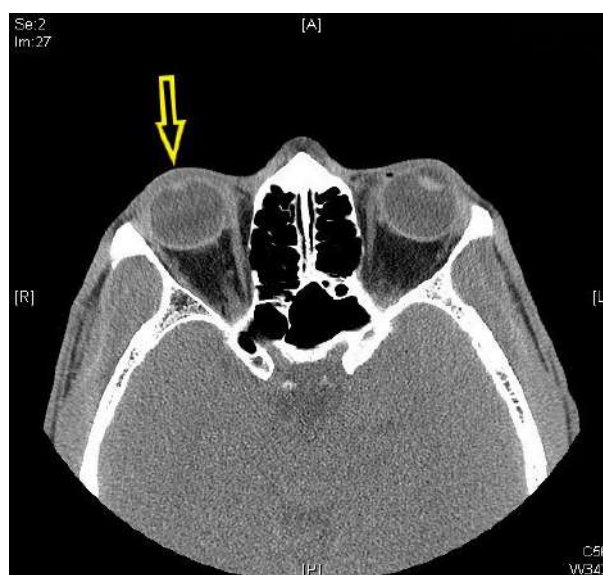


Image 2. Computed tomography of the orbits, axial view, revealing right flat anterior chamber (yellow arrow) with iris abutting the cornea.

it is specific.⁴ A globe rupture with false negative Seidel sign is a rare but known occurrence when ocular contents “plug” the opening, as seen in this patient, preventing aqueous outflow and causing a falsely negative Seidel sign. Other suggestive exam findings include a peaked pupil, poorly reactive pupil, flat anterior chamber, and visual acuity changes.⁴ Despite poor sensitivity, CT is very specific and can be helpful when identifying open globe injuries.

Documented patient informed consent and/or Institutional Review Board approval has been obtained and filed for publication of this case report.

Address for Correspondence: Andrew Zabel, DO, William Beaumont Army Medical Center, 5005 N Piedras St, El Paso, TX 79930. Email: andrew.d.zabel.mil@mail.mil.

Conflicts of Interest: By the CPC-EM article submission agreement, all authors are required to disclose all affiliations, funding sources and financial or management relationships that could be perceived as potential sources of bias. The authors disclosed none. The opinions or assertions contained herein are the private views of the authors and are not to be construed as official or reflecting the views of MAMC, WBAMC, Kimbrough Ambulatory Care Center, the Department of the Army or the DOD.

Copyright: © 2018 Couperus et al. This is an open access article distributed in accordance with the terms of the Creative Commons Attribution (CC BY 4.0) License. See: <http://creativecommons.org/licenses/by/4.0/>

REFERENCES

- Cheung CA, Rogers-Martel M, Golas L, et al. Hospital-based ocular emergencies: epidemiology, treatment, and visual outcomes. *Am J Emerg Med.* 2014;32(3):221-4.
- Lin KY, Ngai P, Echegoyen JC, et al. Imaging in orbital trauma. *Saudi J Ophthalmol.* 2012;26(4):427-32.
- Armstrong GW, Kim JG, Linakis JG, et al. Pediatric eye injuries presenting to United States emergency departments: 2001-2007. *Graefes Arch Clin Exp Ophthalmol.* 2013;251(3):629-36.
- Ritson JE, Welch J. The management of open globe eye injuries: a discussion of the classification, diagnosis and management of open globe eye injuries. *J R Nav Med Serv.* 2013;99(3):127-30.
- Duke-Elder S, MacFaul PA. "Injuries: Part 1 Mechanical Injuries." In: *System of Ophthalmology*, CV Mosby, St. Louis 1972. Vol 14.

CPC-EM Capsule

What do we already know about this clinical entity?

Open globe rupture is an ophthalmologic emergency. Speedy recognition by the emergency department provider and ophthalmologic intervention are essential to restoring functional outcome.

What is the major impact of the image(s)?

A globe rupture with false negative Seidel sign is a rare but known occurrence when ocular contents “plug” the opening, as seen in this patient image.

How might this improve emergency medicine practice?

The case highlights the importance of good clinical exam after ocular trauma. Providers should consider further workup with computed tomography imaging with any injury involving high-velocity metal or glass.

Orbital Compartment Syndrome Following Mechanical Fall

Arielle E. Schwitkis, BA
Talia L. Pollack, PA-C
Sam S. Torbati, MD

Cedars-Sinai Medical Center, Department of Emergency Medicine, Los Angeles, California

Section Editor: Shadi Lahham, MD

Submission history: Submitted January 30, 2018; Revision received April 19, 2018; Accepted April 25, 2018

Electronically published June 12, 2018

Full text available through open access at http://escholarship.org/uc/uciem_cpccem

DOI: 10.5811/cpccem.2018.4.37810

[Clin Pract Cases Emerg Med. 2018;2(3):268–269.]

CASE PRESENTATION

An 80-year-old woman with a history of hypertension presented to the emergency department (ED) with blunt facial trauma including a four-centimeter laceration of the right upper eyelid sustained during a ground-level mechanical fall. Upon arrival to the ED, she was confused, repetitive, and amnesic to events surrounding the fall. Computed tomography (CT) of the brain and orbits was rapidly obtained, and upon return from CT she reported new visual loss of the right eye with the ability to see only light. On exam, her globe was noted to be increasingly firm, full to palpation, and swollen shut. Physical examination also revealed new ophthalmoplegia, proptosis, subconjunctival hemorrhage, and afferent pupillary defect. Intraocular pressure (IOP) measured 50 mmHg in the right eye and 12 mm Hg in the left eye. CT demonstrated a hematoma within the right orbit impinging on orbital contents, confirming the diagnosis of orbital compartment syndrome (OCS). An emergent bedside lateral canthotomy and cantholysis (LCC) was performed by the emergency physician with reduction of her IOP and restoration of vision.

DISCUSSION

OCS is a rare complication of increased pressure within the confined orbital space. It may be caused by retro-orbital hematoma following blunt or penetrating trauma to the orbit. The pressure exerted by the hematoma reduces perfusion resulting in ischemia-induced vision loss, which may develop over minutes to hours.¹⁻³ OCS may present with ocular pain, diplopia, or vision loss.^{4,5} OCS is a clinical diagnosis with physical examination findings that may include ophthalmoplegia, proptosis, subconjunctival hemorrhage, and afferent pupillary defect.^{1,4,5} Diagnostic criteria include a constellation of the aforementioned signs and symptoms associated with an IOP of 30 mmHg or higher.^{2,6} LCC, the primary treatment for OCS, is a relatively simple procedure ideally performed within 60-120 minutes of symptom onset to prevent permanent vision loss.^{1,3,4,7}

Diagnosis of OCS can be challenging as the patient's examination may be limited by altered mental status; vision loss may be masked by inability to open edematous eyelids; and orbital pain may be explained by bony and soft tissue injury.⁷ CT findings concerning for OCS include tenting of the posterior sclera – otherwise known as “guitar pick” sign – caused by intraocular mass (Images 1 and 2).⁸ Although CT findings of

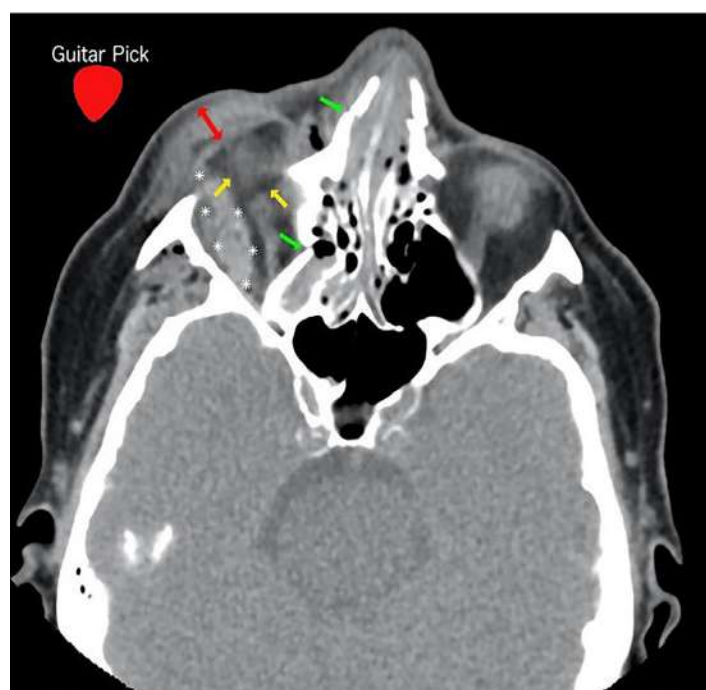


Image 1. Computed tomography of facial bones without contrast, axial view, demonstrating retro-orbital hematoma (asterisks); tenting of posterior sclera (also known as “guitar pick” sign) (yellow arrows); eyelid edema (red two-way arrow); bony fractures (green arrows), and superimposed image of a guitar pick (red guitar pick with white text). The hematoma within the orbit is impinging on the orbital contents, pushing it medially and slightly superiorly.

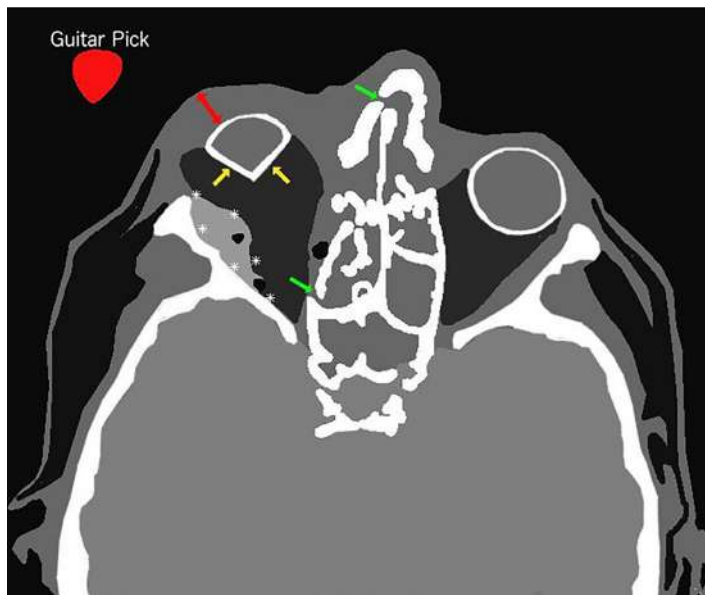


Image 2. Artistic rendering of computed tomography of facial bones without contrast, axial view, demonstrating retro-orbital hematoma (asterisks), tenting of posterior sclera (also known as “guitar pick” sign) (yellow arrows), eyelid edema (red two-way arrow), bony fractures (green arrows), and superimposed image of a guitar pick (red guitar pick with white text).

retro-orbital hematoma should raise suspicion for OCS, serial evaluations are essential for detecting OCS in evolution.

Documented patient informed consent and/or Institutional Review Board approval has been obtained and filed for publication of this case report.

Address for Correspondence: Arielle E. Schwitkis, BA, Cedars-Sinai Medical Center, Department of Emergency Medicine, 8700 Beverly Blvd., Los Angeles, CA 90048. Email: Arielle.Schwitkis@cshs.org.

Conflicts of Interest: By the *CPC-EM* article submission agreement, all authors are required to disclose all affiliations, funding sources and financial or management relationships that could be perceived as potential sources of bias. The authors disclosed none.

Copyright: © 2018 Schwitkis et al. This is an open access article distributed in accordance with the terms of the Creative Commons Attribution ([CC BY 4.0](http://creativecommons.org/licenses/by/4.0/)) License. See: <http://creativecommons.org/licenses/by/4.0/>

CPC-EM Capsule

What do we already know about this clinical entity?

Orbital compartment syndrome is a rare complication of increased pressure within the confined orbital space that may lead to permanent blindness if not treated in a timely fashion.

What is the major impact of the image(s)?

The “guitar pick” sign is a rarely reported radiographic sign that should alert physicians of the possibility of a syndrome requiring immediate intervention.

How might this improve emergency medicine practice?

Emergency physicians will be able to better recognize patients at risk for orbital compartment syndrome following blunt facial trauma.

REFERENCES

- Rowh AD, Ufberg JW, Chan TC, et al. Lateral canthotomy and cantholysis: emergency management of orbital compartment syndrome. *J Emerg Med.* 2015;48(3):325-30.
- Sun MT, Chan OW, Selva D. Traumatic orbital compartment syndrome: importance of lateral canthomy and cantholysis. *Emerg Med Australas.* 2014;26(3):274-8.
- Ujam A, Perry M. Emergency Management for orbital compartment syndrome—is decompression mandatory? *Int J Oral Maxillofac Surg.* 2016;45(11):1435-7.
- Fontenot TE, Carter JM, Friedlander P. Eye pain after traumatic orbital fracture. *JAMA Otolaryngol Head Neck Surg.* 2014;140(9):877-8.
- Scott M, Thomson A. Prompt Recognition and treatment in traumatic retro-orbital hematoma in anticoagulated elderly people can save sight. *J Am Geriatr Soc.* 2009;57(3):568-9.
- Capek KD, Culnan DM, Merkley K, et al. “Burn Injuries of the Eye.” In: Herndon DN. *Total Burn Care. 5th ed.* Galveston, TX: Elsevier; 2018:435-4.e6.
- Kniess CK, Fond TC, Reilly AJ, et al. Early detection of traumatic retrobulbar hemorrhage using bedside ocular ultrasound. *J Emerg Med.* 2015;49(1):58-60.
- Minkis K, Whittington A, Alam M. Dermatologic surgery emergencies. *J Am Acad Dermatol.* 2016;75(2):265-284.

“Swirl Sign”: A Case of Abdominal Pain After Roux-en-Y Gastric Bypass Surgery

Carlín Corsino, DO
Hillary Harper, MD
Vanessa Sieg, MD

Carl R. Darnall Army Medical Center, Department of Emergency Medicine, Fort Hood, Texas

Section Editor: Shadi Lahham, MD, MS

Submission history: Submitted December 4, 2017; Revision received March 28, 2018; Accepted March 28, 2018

Electronically published July 12, 2018

Full text available through open access at http://escholarship.org/uc/uciem_cpccem

DOI: 10.5811/cpcem.2018.3.37196

[Clin Pract Cases Emerg Med. 2018;2(3):270–271.]

CASE PRESENTATION

A 57-year-old female presented to the emergency department (ED) with periumbilical and left upper quadrant abdominal pain. The pain began abruptly 12 hours prior to presentation and was worsening. Her pain increased with supine position and was associated with nausea and vomiting. Her past medical history was significant for hypertension, gastroesophageal reflux disease and obesity. Prior to presentation in our ED, she underwent a laparoscopic Roux-en-Y procedure for weight loss 10 years prior at an outside hospital. On arrival, pertinent vitals included a heart rate of 115 beats per minute, 20 breaths per minute and blood pressure of 190/100 mmHg. Laboratory studies in the ED were significant for a leukocytosis ($14.7 \times 10^9/L$), and a lactate level of 5.4 mmol/L. The remainder of laboratory studies were normal. Computed tomography (CT) images were obtained (Images 1 and 2).

DIAGNOSIS: INTERNAL HERNIA

Obesity is an epidemic in America, and bariatric surgery is becoming more common. Roux-en-Y procedure is the “gold standard” of bariatric surgery.¹ It provides more overall weight loss than adjustable gastric band and more durable weight loss than sleeve gastrectomy.^{1,2} Complications of Roux-en-Y gastric bypass are categorized as early or late. Early complications include anastomotic or staple-line leak, hemorrhage and obstruction. Later complications can be difficult to differentiate from other more routine abdominal emergencies seen in the ED. Late complications include anastomotic stricture, marginal ulceration, fistula, nutritional deficiencies and bowel obstruction.³ Internal hernia can occur at any time after the procedure and has lifetime incidence of roughly 5%.⁴ Ironically, the potential space created by sudden, post-procedural weight loss is a risk factor for this complication.⁵

Internal hernias develop when bowel protrudes through iatrogenic defects in the mesentery. This is most common at the transverse mesocolon, Petersen’s space, or the meso/

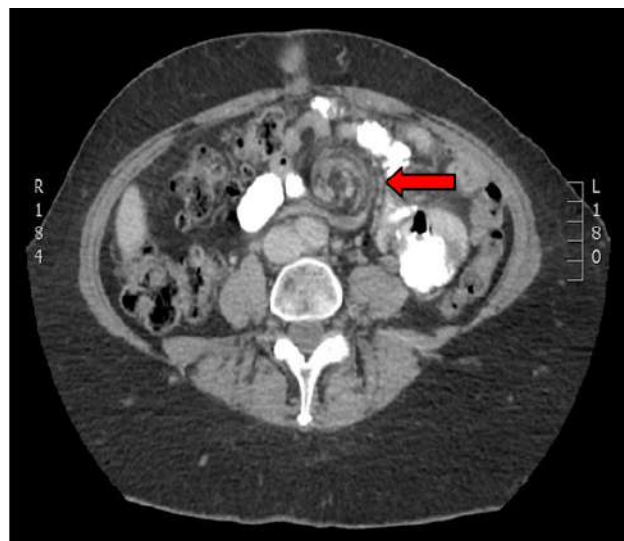


Image 1. Axial computed tomography of the abdomen shows “swirl sign” indicative of internal hernia (red arrow).

jejunojejunal anastomosis. Petersen’s space is a defect posterior to the Roux limb.⁶ Symptoms of internal hernia can be intermittent, vague and may mimic benign disease processes. This makes diagnosis of this uncommon yet life-threatening finding particularly difficult.

Diagnosis can be made by CT, where the “swirl sign” is sometimes seen (Images 1 and 2). If present it is 78-100% sensitive, and 80-90% specific for internal hernia.⁷ Even in the absence of swirl sign, patients should undergo exploratory surgery if suspicion of internal hernia is high based on clinical presentation, unexplained laboratory abnormalities that may suggest bowel ischemia, or imaging consistent with the stigmata of bowel obstruction. This patient underwent laparoscopic revision of her Roux-en-Y, and was discharged home after the procedure with no further complications.

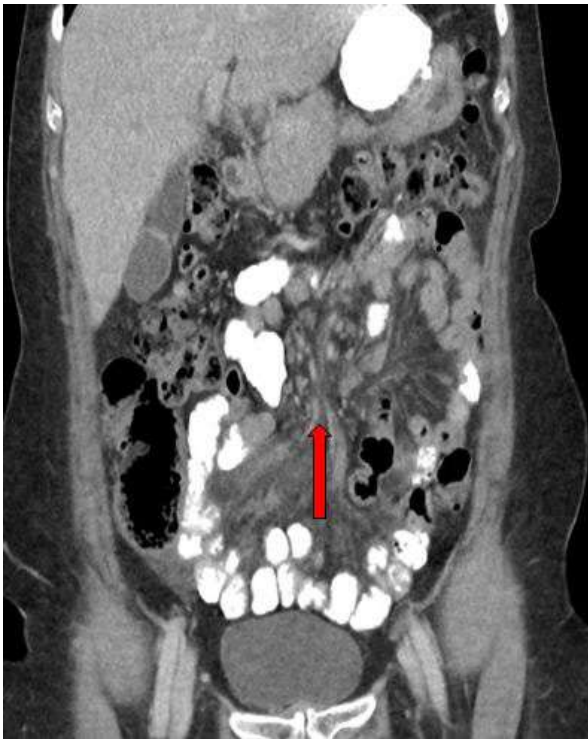

Image 2. Coronal computed tomography of the abdomen and pelvis showing site of internal hernia (red arrow).

CPC-EM Capsule

What do we already know about this clinical entity?

Internal hernias are a post-operative complication of bariatric surgeries. Diagnosis can be made by computed tomography (CT) imaging showing a characteristic “swirl sign.”

What is the major impact of the images?

While the surgically altered abdomen may seem intimidating anatomically, there are tell-tale abnormalities that can be easily recognized on CT by the informed physician.

How might this improve emergency medicine practice?

We can be better advocates for bariatric surgery patients by knowing their potential post-operative complications and associated findings on imaging.

Documented patient informed consent and/or Institutional Review Board approval has been obtained and filled for publication of this case report.

Address for Correspondence: Carlin Corsino, DO. Carl R. Darnall Army Medical Center, 36065 Santa Fe Rd, Room 41-114, Fort Hood, TX 76544-5095. Email: carlin.corsino@gmail.com, carlin.b.corsino.mil@mail.mil.

Conflicts of Interest: By the CPC-EM article submission agreement, all authors are required to disclose all affiliations, funding sources and financial or management relationships that could be perceived as potential sources of bias. The authors disclosed none.

Copyright: © 2018 Corsino et al. This is an open access article distributed in accordance with the terms of the Creative Commons Attribution (CC BY 4.0) License. See: <http://creativecommons.org/licenses/by/4.0/>

REFERENCES

1. American Society of Metabolic and Bariatric Surgery. Estimate of bariatric surgery numbers. The American Society for Metabolic and Bariatric Surgery (ASMBS) Website. Published July 2016. Available at: <https://asmbs.org/patients/bariatric-surgery-procedures>. Accessed November 12, 2017.
2. Maciejewski ML, Arterburn DE, Van Scoyoc L, et al. Bariatric surgery and long-term durability of weight loss. *JAMA Surg.* 2016;151(11):1046.
3. Griffith PS, Birch DW, Sharma AM, et al. Managing complications associated with laparoscopic Roux-en-Y gastric bypass for morbid obesity. *Can J Surg.* 2012;55(5):329-36.
4. Paroz A, Calmes JM, Giusti V, et al. Internal hernia after a laparoscopic Roux-en-Y bypass for morbid obesity: a continuous challenge in bariatric surgery. *Obes Surg.* 2006;16(11):1482-7.
5. Jeansonne L, Morgenthal C, White B, et al. Internal Hernia after Laparoscopic Gastric Bypass: A Review of the Literature. *Bar Times.* April 2007. Available at: <http://bariatrictimes.com/internalhernia-after-laparoscopic-gastric-bypass-a-review-of-the-literature>. Accessed November 1, 2017.
6. Kawkabani M, Denys A, Paroz A, et al. The four different types of internal hernia occurring after laparoscopic Roux-en-Y gastric bypass performed for morbid obesity: are there any multidetector computed tomography (MDCT) features permitting their distinction? *Obes Surg.* 2011;21(4):506-16.
7. Iannuccilli JD, Grand D, Murphy BL, et al. Sensitivity and specificity of eight CT signs in the preoperative diagnosis of internal mesenteric hernia following Roux-en-Y gastric bypass surgery. *Clin Radiol.* 2009;64(4):373.

Acute Respiratory Distress

James Maloy, MD
Nicholas Harrison, MD
Amit Bahl, MD

Beaumont Health System, Department of Emergency Medicine, Royal Oak, Michigan

Section Editor: Shadi Lahham, MD, MS

Submission history: Submitted February 23, 2018; Revision received May 7, 2018; Accepted May 9, 2018

Electronically published July 16, 2018

Full text available through open access at http://escholarship.org/uc/uciem_cpccem

DOI: 10.5811/cpcem.2018.5.38041

[Clin Pract Cases Emerg Med. 2018;2(3):272–273.]

CASE PRESENTATION

A 24-year-old woman presented to the emergency department by emergency medical services with severe respiratory distress and hypoxia. The patient complained of exertional chest pain and nonproductive cough. Her room air saturation was 65% with improvement to 95% with oxygen supplementation. Her vital signs were a pulse of 110 beats per minute, blood pressure of 140/100 mmHg and a temperature of 36.5 degrees Celsius. Lungs were clear to auscultation, heart was without murmur, and extremities had no edema. Electrocardiogram demonstrated sinus tachycardia with rSR' pattern, prominent p-waves, and an elevated R:S wave ratio in V1 and V2. Troponin was 0.08 ng/mL, d-dimer was 445 ng/mL, and hemoglobin was 16.4 g/dL. Portable chest radiograph was normal.

Point-of-care ultrasound (POCUS) demonstrated significant right ventricular dilatation (Image 1) with hypertrophy of the right ventricular myocardium (Image 2). On further questioning, the patient clarified that she had been diagnosed with “pulmonary hypertension” but hadn't seen a doctor in over a year and was not prescribed any treatment. Subsequent review of outside electronic medical records revealed an echocardiogram performed approximately one year prior to presentation that demonstrated concern for an atrial septal defect.

POCUS revealed significant right ventricular hypertrophy supporting a longstanding disease process. Computed tomography angiography did not reveal any abnormalities. The patient was admitted for hypoxia and pulmonary hypertension. On admission, formal echocardiogram demonstrated concern for atrial septal defect with left-to-right shunt. Two days later, repeat echocardiography with bubble study demonstrated right-to-left shunt across the interatrial septum. The patient rapidly decompensated during the admission, leading to intubation for respiratory distress and then pulseless electrical activity arrest and death despite resuscitation.

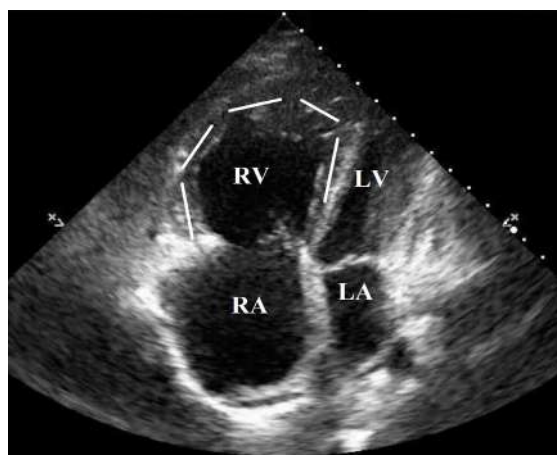


Image 1. Transthoracic echocardiogram apical view demonstrating severe right ventricular (RV, walls outlined) and right atrial (RA) dilation consistent with right heart strain.

LV, left ventricle; LA, left atrium.

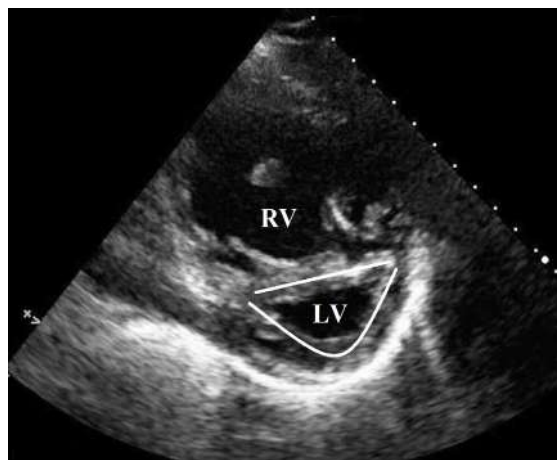


Image 2. Transthoracic echocardiogram parasternal short view demonstrating enlargement of the right ventricle (RV) with bowing of the interventricular septum (straight line) toward the left ventricle (LV), demonstrating the “D” sign (outlined) of right ventricular overload.

DIAGNOSIS

Eisenmenger syndrome is the process by which a longstanding, left-to-right cardiac shunt, secondary to congenital heart defect, reverses into a cyanotic right-to-left shunt.¹ The reversal is a result of progressive pulmonary over-circulation, with a subsequent increase of right ventricular pressures over the course of several years. This also gives rise to right ventricular and pulmonary artery hypertrophy. POCUS reveals evidence not only of right heart strain but also significant right ventricular hypertrophy,² helping differentiate the etiology from massive pulmonary embolism. In a patient with desaturation despite high supplemental oxygen and no evidence of lung consolidation, right-to-left cardiac shunt should be considered.

Documented patient informed consent and/or Institutional Review Board approval has been obtained and filed for publication of this case report.

Address for Correspondence: James Maloy, MD, Beaumont Health Systems, Department of Emergency Medicine, 3601 W 13 Mile Road, Royal Oak, MI 48073. Email: James.Maloy@beaumont.org.

Conflicts of Interest: By the CPC-EM article submission agreement, all authors are required to disclose all affiliations, funding sources and financial or management relationships that could be perceived as potential sources of bias. The authors disclosed none.

Copyright: © 2018 Maloy et al. This is an open access article distributed in accordance with the terms of the Creative Commons Attribution (CC BY 4.0) License. See: <http://creativecommons.org/licenses/by/4.0/>

CPC-EM Capsule

What do we already know about this clinical entity?

In Eisenmenger syndrome, a right to left intracardiac shunt causes progressive pulmonary hypertension. Once pressures in the right heart exceed those in the left, shunt reversal and severe hypoxia occurs.

What is the major impact of the image(s)?

While right ventricle (RV) dilation and hypoxia often suggests pulmonary embolus, RV hypertrophy should prompt consideration of chronic pulmonary hypertension and alternative diagnoses.

How might this improve emergency medicine practice?

Differentiating acute vs. chronic right heart strain is poorly described, but management of each can be very different. Ultrasound may be useful in distinguishing the two.

REFERENCES

1. Vongpatanasin W, Brickner ME, Hillis LD, et al. The Eisenmenger syndrome in adults. *Ann Intern Med.* 1998;128(9):745-55.
2. Hopkins WE, Waggoner AD. Severe pulmonary hypertension without right ventricular failure: the unique hearts of patients with Eisenmenger syndrome. *Am J Cardiol.* 2002;89(1):34-8.

Pre-Retinal Hemorrhage on Point-of-Care Ultrasound

Krystal Garcia, DO
Julian Jakubowski, DO
Linette Archer, MD

Marietta Memorial Hospital, Department of Emergency Medicine, Marietta, Ohio

Section Editor: Shadi Lahham, MD, MS

Submission history: Submitted March 28, 2018; Revision received June 15, 2018; Accepted June 26, 2018

Electronically published July 18, 2018

Full text available through open access at http://escholarship.org/uc/uciem_cpccem

DOI: 10.5811/cpcem.2018.6.38459

[Clin Pract Cases Emerg Med. 2018;2(3):274–275.]

CASE PRESENTATION

A 30-year-old male presented to the emergency department (ED) with sudden, painless, decreased vision in the left eye after an episode of severe vomiting. He noted a gray area in the center of his vision and was only able to distinguish objects' outlines with the affected eye. His visual acuity was 20/200 in the left eye vs. 20/50 in the right. Intraocular pressures were 18 millimeters of mercury (mmHg) in the left eye and 16 mmHg in the right eye. Point-of-care ultrasound (POCUS) (Image, Video) showed findings consistent with retinal pathology and hemorrhage. No further workup was obtained in the ED. Ophthalmology was consulted with the ultimate diagnosis of pre-retinal hemorrhage due to Valsalva action.

DIAGNOSIS

Valsalva retinopathy is a rare entity, most commonly presenting as pre-retinal hemorrhage either bilaterally or unilaterally, which to these authors' knowledge has not previously been identified on POCUS in an ED. It is normally self-limited with a favorable prognosis and resolution over several months.^{1,2} The mechanism of Valsalva retinopathy is due to a sudden increased thoracic/intra-abdominal pressure leading to a rapid increase in intraocular venous pressure and spontaneous rupture of capillaries.² Aside from conservative management, other treatments are available for resolution of pre-retinal hemorrhage including the following: pneumatic displacement of hemorrhage with yttrium-aluminum-garnet laser, tissue plasminogen activator, vitrectomy, or the less-invasive injection of intravitreal ranibizumab (anti-vascular endothelial growth factor).²

Use of POCUS allowed for quick diagnosis, consultation, and disposition without the need for extensive or expensive testing. POCUS findings seen in image and video revealed evidence of retinopathy, and subsequent

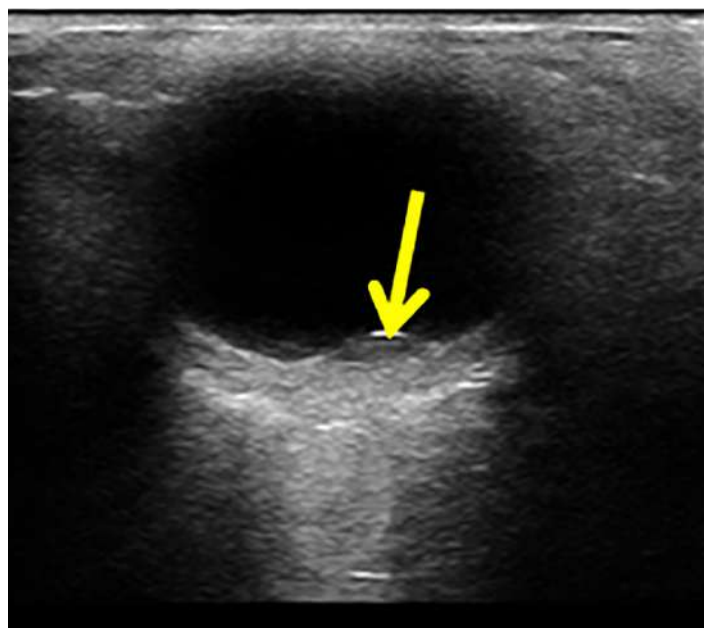


Image. Point-of-care ultrasound demonstrating a pre-retinal hemorrhage (arrow).

optic imaging confirmed pre-retinal hemorrhage. This furthers the evidence of the utility of POCUS in differentiating pathology and obtaining quick consultation as needed.³

Video. Pre-retinal hemorrhage.

Documented patient informed consent and/or Institutional Review Board approval has been obtained and filed for publication of this case report.

Address for Correspondence: Krystal Garcia, DO, Marietta Memorial Hospital, Department of Emergency Medicine, 267 Muskingum Drive, Marietta, OH 45750. Email: kgarcia@mhsystem.org.

Conflicts of Interest: By the CPC-EM article submission agreement, all authors are required to disclose all affiliations, funding sources and financial or management relationships that could be perceived as potential sources of bias. The authors disclosed none.

Copyright: © 2018 Garcia et al. This is an open access article distributed in accordance with the terms of the Creative Commons Attribution (CC BY 4.0) License. See: <http://creativecommons.org/licenses/by/4.0/>

REFERENCES

1. Al-Mujaini AS, Montana CC. Valsalva retinopathy in pregnancy: a case report. *J Med Case Rep.* 2008;2:101.
2. Noorlaila B, Zunaina E, Raja-Azmi M-N. Successful resolution of preretinal haemorrhage with intravitreal ranibizumab. *Case Rep Ophthalmol Med.* 2016;2016:4164198.
3. Blaivas M, Theodoro D, Sierzenski PR. A study of bedside ocular ultrasonography in the emergency department. *Acad Emerg Med.* 2002;9(8):791-9.

CPC-EM Capsule

What do we already know about this clinical entity?

Valsalva-induced pre-retinal hemorrhage is a known entity in ophthalmology but is a rare finding that would not normally be diagnosed in the emergency department (ED).

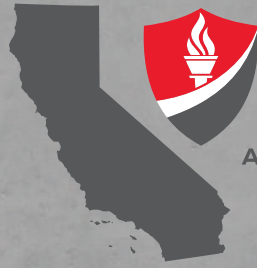What is the major impact of the image(s)?

The images allow emergency physicians to learn the importance of being able to obtain and recognize point-of-care ultrasound (US) images at bedside.

How might this improve emergency medicine practice?

This report shows the ever-increasing utility of point-of-care US not only as a tool for procedures, but also for diagnosis in the ED.

**JOIN
CAL/AAEM!**



CALAAEM

CALIFORNIA CHAPTER DIVISION OF THE
AMERICAN ACADEMY OF EMERGENCY MEDICINE

*Championing
individual physician rights
and workplace fairness*

BENEFITS

- *Western Journal of Emergency Medicine* Subscription
- CAL/AAEM News Service email updates
- Discounted AAEM pre-conference fees
- And more!

CAL/AAEM NEWS SERVICE

- Healthcare industry news
- Public policy
- Government issues
- Legal cases and court decisions

In collaboration with our official journal

WestJEM Integrating Emergency Care
with Population Health



[FACEBOOK.COM/CALAAEM](https://www.facebook.com/CALAAEM)



FOLLOW US @CALAAEM

[HTTP://WWW.CALAAEM.ORG](http://www.calaaem.org)



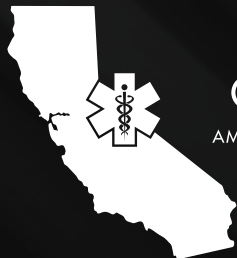ADVANCED >

**RESIDENTS & MED STUDENTS,
THIS ONE'S FOR YOU!**

> CALIFORNIA ACEP'S ANNUAL CONFERENCE 2018

Friday, September 7, 2018

Marriott, Marina Del Rey, CA



CALIFORNIA ACEP
AMERICAN COLLEGE OF EMERGENCY PHYSICIANS

IN PARTNERSHIP WITH

