

# UC Irvine

## Clinical Practice and Cases in Emergency Medicine

### Title

CPC-EM Full-Text Issue

### Permalink

<https://escholarship.org/uc/item/8nv1b3qh>

### Journal

Clinical Practice and Cases in Emergency Medicine, 6(1)

### Author

Nguyen, Trina

### Publication Date

2022

### DOI

10.5811/cpcem.2022.2.56356

### Copyright Information

Copyright 2022 by the author(s). This work is made available under the terms of a Creative Commons Attribution License, available at <https://creativecommons.org/licenses/by/4.0/>

Peer reviewed

# CPC Emergency Medicine

Volume 6, Number 1, February 2022

Open Access at [www.cpcem.org](http://www.cpcem.org)

ISSN: 2474-252X

## *Clinical Practice and Cases in Emergency Medicine*

In Collaboration with the *Western Journal of Emergency Medicine*

### Clinicopathological Cases from the University of Maryland

- 1 **57-year-old Female with Unusual Left-arm Movements**  
*Powell C, Rosenblatt LS, Bontempo LJ, Dezman ZDW*

### Medical Legal Case Report

- 8 **Let's Be Honest: These Medical Malpractice Cases Were a Pain in the Back**  
*Garcia SI, Ghiath S, Moore GP, Lindor RA, Hevesi S*

### Case Series

- 13 **Point-of-care Ultrasound for the Evaluation of Acute Arterial Pathology in the Emergency Department: A Case Series**  
*Drake A, Dreyer N, Hoffer M, Boniface K*

### Case Reports

- 20 **Fatal Abdominal Compartment Syndrome Due to Constipation: A Case Report**  
*Kongkatong MM, Patel MM, Thom C, Moak J*
- 25 **Case Report: Differential Diagnosis of Lower Extremity Weakness in a Young Male - Consider Foix Alajouanine Syndrome**  
*Siani A, Garrett A, Thomas N*
- 29 **Renal Vein Thrombosis on Point-of-care Ultrasound in the Emergency Department: A Case Report**  
*Haimowitz M, Gonzalez LK*
- 33 **A Case Report of Prolonged Anaphylaxis after COVID-19 Vaccine**  
*Armstrong L, Maguire N*
- 37 **Managing Subarachnoid Hemorrhage Precipitated by Anesthesia-assisted Rapid Opioid Detoxification: A Case Report**  
*Sobin MF, Ngo L, Lawrence DT, Kirwen AK*
- 41 **Leveraging Resources to Remove a Taser Barb Embedded in Bone: Case Report**  
*Willoughby L, Peyton K, Gorgas D, Li-Sauerwine S*

Contents continued on page iii



**UC Irvine Health**



A Peer-Reviewed, International Professional Journal



**ACOEP stands with all emergency  
physicians and providers on the  
front line. We thank you for your  
tireless work and effort.**

# Clinical Practice and Cases in Emergency Medicine

Indexed in PubMed and full text in PubMed Central

**Rick A. McPheeters, DO, Editor-in-Chief**  
Kern Medical/UCLA- Bakersfield, California

**Mark I. Langdorf, MD, MHPE, Senior Associate Editor**  
University of California, Irvine School of Medicine- Irvine, California

**Shahram Lotfipour, MD, MPH, Senior Associate Editor**  
University of California, Irvine School of Medicine- Irvine, California

**Shadi Lahham, MD, MS, Associate Editor**  
Kaiser Permanente- Orange County, California

**Manish Amin, DO, Associate Editor**  
Kern Medical/UCLA- Bakersfield, California

**John Ashurst, DO, Decision Editor/ ACOEP Guest Editor**  
Kingman Regional Health Network, Arizona

**Anna McFarlin, MD, Decision Editor**  
Louisiana State University Health Science Center- New Orleans, Louisiana

**Austin Smith, MD, Decision Editor**  
Vanderbilt University Medical Center-Nashville, Tennessee

**Christopher Sampson, MD, Decision Editor**  
University of Missouri- Columbia, Missouri

**Joel Moll, MD, Decision Editor**  
Virginia Commonwealth University School of Medicine- Richmond, Virginia

**Steven Walsh, MD, Decision Editor**  
Einstein Medical Center Philadelphia-Philadelphia, Pennsylvania

**Melanie Heniff, MD, JD, Decision Editor**  
University of Indiana School of Medicine- Indianapolis, Indiana

**Gentry Wilkerson, MD, Decision Editor**  
University of Maryland School of Medicine

**Rachel A. Lindor, MD, JD, Decision Editor**  
Mayo Clinic College of Medicine and Science

**Jacqueline K. Le, MD, Decision Editor**  
Desert Regional Medical Center

**Christopher San Miguel, MD, Decision Editor**  
Ohio State University Wexner Medical Center

## Editorial Board

Amin A. Kazzi, MD, MAAEM  
The American University of Beirut, Beirut,  
Lebanon

Anwar Al-Awadhi, MD  
Mubarak Al-Kabeer Hospital, Jabriya,  
Kuwait

Arif A. Cevik, MD  
United Arab Emirates University  
College of Medicine and Health Sciences, Al  
Ain, United Arab Emirates

Abhinandan A. Desai, MD  
University of Bombay Grant Medical  
College, Bombay, India

Bandr Mzahim, MD  
King Fahad Medical City, Riyadh, Saudi  
Arabia

Barry E. Brenner, MD, MPH  
Case Western Reserve University

Brent King, MD, MMM  
University of Texas, Houston

Daniel J. Dire, MD  
University of Texas Health Sciences Center  
San Antonio

David F.M. Brown, MD  
Massachusetts General Hospital/Harvard  
Medical School

Edward Michelson, MD  
Texas Tech University

Edward Panacek, MD, MPH  
University of South Alabama

Erik D. Barton, MD, MBA  
Icahn School of Medicine, Mount Sinai,  
New York

Francesco Dellacorte, MD  
Azienda Ospedaliera Universitaria "Maggiore  
della Carità," Novara, Italy

Francis Counselman, MD  
Eastern Virginia Medical School

Gayle Galletta, MD  
Sørlandet Sykehus HF, Akershus  
Universitetssykehus, Lorenskog, Norway

Hjalte Björmsón, MD  
Icelandic Society of Emergency Medicine

Jacob (Kobi) Peleg, PhD, MPH  
Tel-Aviv University, Tel-Aviv, Israel

Jonathan Olshaker, MD  
Boston University

Katsuhiko Kanemaru, MD  
University of Miyazaki Hospital, Miyazaki, Japan

Khrongwong Musikataworn, MD  
King Chulalongkorn Memorial Hospital,  
Chulalongkorn University, Bangkok,  
Thailand

Leslie Zun, MD, MBA  
Chicago Medical School

Linda S. Murphy, MLIS  
University of California, Irvine School of  
Medicine Librarian

Nadeem Qureshi, MD  
St. Louis University, USA  
Emirates Society of Emergency Medicine,  
United Arab Emirates

Niels K. Rathlev, MD  
Tufts University School of Medicine

Pablo Aguilera Fuenzalida, MD  
Pontificia Universidad Católica de Chile,  
Región Metropolitana, Chile

Peter A. Bell, DO, MBA  
Baptist Health Science University

Peter Sokolove, MD  
University of California, San Francisco

Robert M. Rodriguez, MD  
University of California, San Francisco

Robert Suter, DO, MHA  
UT Southwestern Medical Center

Robert W. Derlet, MD  
University of California, Davis

Rosidah Ibrahim, MD  
Hospital Serdang, Selangor, Malaysia

Samuel J. Stratton, MD, MPH  
Orange County, CA, EMS Agency

Scott Rudkin, MD, MBA  
University of California, Irvine

Scott Zeller, MD  
University of California, Riverside

Steven Gabaeff, MD  
Clinical Forensic Medicine

Steven H. Lim, MD  
Changi General Hospital, Simei, Singapore

Terry Mulligan, DO, MPH, FIFEM  
ACEP Ambassador to the Netherlands Society of  
Emergency Physicians

Vijay Gautam, MBBS  
University of London, London, England

Wirachin Hoonpongmanont, MD, MSBATS  
Siriraj Hospital, Mahidol University, Bangkok,  
Thailand

## Advisory Board

Amal Khalil, MBA  
UC Irvine Health School of Medicine

Elena Lopez-Gusman, JD  
California ACEP  
American College of Emergency Physicians

Adam Levy, BS  
American College of Osteopathic Emergency  
Physicians

John B. Christensen, MD  
California Chapter Division of AAEM

Randy Young, MD  
California ACEP  
American College of Emergency  
Physicians

Mark I. Langdorf, MD, MHPE  
UC Irvine Health School of Medicine

Jorge Fernandez, MD  
California ACEP  
American College of Emergency Physicians  
University of California, San Diego

Peter A. Bell, DO, MBA  
American College of Osteopathic Emergency  
Physicians  
Baptist Health Science University

Robert Suter, DO, MHA  
American College of Osteopathic Emergency  
Physicians  
UT Southwestern Medical Center

Shahram Lotfipour, MD, MPH  
UC Irvine Health School of Medicine

Brian Potts, MD, MBA  
California Chapter Division of AAEM  
Alta Bates Summit-Berkeley Campus

## Editorial Staff

Isabelle Nepomuceno, BS  
Executive Editorial Director

Shreya Gupta, BS  
WestJEM Editorial Director  
Associate Marketing Director

Sohrab Kharabaf, BS  
CPC-EM Editorial Director  
Associate Marketing Director

Stephanie Burmeister, MLIS  
WestJEM Staff Liaison

June Casey, BA  
Copy Editor

Cassandra Saucedo, BS  
Executive Publishing Director

Nathan Do, BS  
WestJEM Publishing Director

Trina Nguyen, BS  
CPC-EM Publishing Director

Paul Abdo, BS  
WestJEM Associate Publishing Director  
Associate Marketing Director

Official Journal of the California Chapter of the American College of Emergency Physicians, the American College of Osteopathic Emergency Physicians, and the California Chapter of the American Academy of Emergency Medicine



Available in MEDLINE, PubMed, PubMed Central, Google Scholar, eScholarship, DOAJ, and OASPA.

Editorial and Publishing Office: WestJEM/Department of Emergency Medicine, UC Irvine Health, 333 City Blvd, West, Rt 128-01, Orange, CA 92866, USA

Office: 1-714-456-6389; Email: Editor@westjem.org



# Clinical Practice and Cases in Emergency Medicine

Indexed in PubMed and full text in PubMed Central

This open access publication would not be possible without the generous and continual financial support of our society sponsors, department and chapter subscribers.

## Professional Society Sponsors

AMERICAN COLLEGE OF OSTEOPATHIC EMERGENCY PHYSICIANS  
CALIFORNIA ACEP

CALIFORNIA CHAPTER DIVISION OF  
AMERICAN ACADEMY OF EMERGENCY MEDICINE

## Academic Department of Emergency Medicine Subscribers

Albany Medical College Albany, NY	INTEGRIS Health Oklahoma City, OK	Robert Wood Johnson University Hospital New Brunswick, NJ	University of Florida, Jacksonville Jacksonville, FL
American University of Beirut Beirut, Lebanon	Kaweah Delta Health Care District Visalia, CA	Rush University Medical Center Chicago, IL	University of Illinois at Chicago Chicago, IL
Arrowhead Regional Medical Center Colton, CA	Kennedy University Hospitals Turnersville, NJ	Southern Illinois University Carbondale, IL	University of Illinois College of Medicine Peoria, IL
Augusta University Augusta GA	Kern Medical Bakersfield, CA	St. Luke's University Health Network Bethlehem, PA	University of Iowa Iowa City, IA
Baystate Medical Center Springfield, MA	Lakeland HealthCare St. Joseph, MI	Stanford/Kaiser Emergency Medicine Residency Program Stanford, CA	University of Louisville Louisville, KY
Beaumont Hospital Royal Oak, MI	Lehigh Valley Hospital and Health Network Allentown, PA	Staten Island University Hospital Staten Island, NY	University of Maryland Baltimore, MD
Beth Israel Deaconess Medical Center Boston, MA	Loma Linda University Medical Center Loma Linda, CA	SUNY Upstate Medical University Syracuse, NY	University of Michigan Ann Arbor, MI
Boston Medical Center Boston, MA	Louisiana State University Health Sciences Center New Orleans, LA	Temple University Philadelphia, PA	University of Missouri, Columbia Columbia, MO
Brigham and Women's Hospital Boston, MA	Madigan Army Medical Center Tacoma, WA	Texas Tech University Health Sciences Center El Paso, TX	University of Nebraska Medical Center Omaha, NE
Brown University Providence, RI	Maimonides Medical Center Brooklyn, NY	University of Alabama, Birmingham Birmingham, AL	University of South Alabama Mobile, AL
Carl R. Damall Army Medical Center Fort Hood, TX	Maricopa Medical Center Phoenix, AZ	University of Arkansas for Medical Sciences Little Rock, AR	University of Southern California/Keck School of Medicine Los Angeles, CA
Conemaugh Memorial Medical Center Johnstown, PA	Massachusetts General Hospital Boston, MA	University of California, Davis Medical Center Sacramento, CA	University of Tennessee, Memphis Memphis, TN
Desert Regional Medical Center Palm Springs, CA	Mayo Clinic College of Medicine Rochester, MN	University of California Irvine Orange, CA	University of Texas, Houston Houston, TX
Doctors Hospital/Ohio Health Columbus, OH	Mt. Sinai Medical Center Miami Beach, FL	University of California, Los Angeles Los Angeles, CA	University of Texas Health San Antonio, TX
Eastern Virginia Medical School Norfolk, VA	North Shore University Hospital Manhasset, NY	University of California, San Diego La Jolla, CA	University of Warwick Library Coventry, United Kingdom
Einstein Healthcare Network Philadelphia, PA	Northwestern Medical Group Chicago, IL	University of California, San Francisco San Francisco, CA	University of Washington Seattle, WA
Emory University Atlanta, GA	Ohio State University Medical Center Columbus, OH	UCSF Fresno Center Fresno, CA	University of Wisconsin Hospitals and Clinics Madison, WI
Genesys Regional Medical Center Grand Blanc, Michigan	Ohio Valley Medical Center Wheeling, WV	University of Chicago, Chicago, IL	Wake Forest University Winston-Salem, NC
Hartford Hospital Hartford, CT	Oregon Health and Science University Portland, OR	University of Colorado, Denver Denver, CO	Wright State University Dayton, OH
Hennepin County Medical Center Minneapolis, MN	Penn State Milton S. Hershey Medical Center Hershey, PA	University of Florida Gainesville, FL	
Henry Ford Hospital Detroit, MI	Presence Resurrection Medical Center Chicago, IL		

## State Chapter Subscribers

ARIZONA CHAPTER DIVISION OF THE  
AMERICAN ACADEMY OF EMERGENCY MEDICINE  
CALIFORNIA CHAPTER DIVISION OF THE  
AMERICAN ACADEMY OF EMERGENCY MEDICINE  
FLORIDA CHAPTER DIVISION OF THE  
AMERICAN ACADEMY OF EMERGENCY MEDICINE

GREAT LAKES CHAPTER DIVISION OF THE  
AMERICAN ACADEMY OF EMERGENCY MEDICINE  
TENNESSEE CHAPTER DIVISION OF THE  
AMERICAN ACADEMY OF EMERGENCY MEDICINE

UNIFORMED SERVICES CHAPTER DIVISION OF THE  
AMERICAN ACADEMY OF EMERGENCY MEDICINE  
VIRGINIA CHAPTER DIVISION OF THE  
AMERICAN ACADEMY OF EMERGENCY MEDICINE

## International Society Partners

EMERGENCY MEDICINE ASSOCIATION OF TURKEY  
LEBANESE ACADEMY OF EMERGENCY MEDICINE  
MEDITERRANEAN ACADEMY OF EMERGENCY MEDICINE

NORWEGIAN SOCIETY FOR EMERGENCY MEDICINE  
SOCIEDAD ARGENTINA DE EMERGENCIAS

SOCIEDAD CHILENO MEDICINA URGENCIA  
THAI ASSOCIATION FOR EMERGENCY MEDICINE

To become a *WestJEM* departmental sponsor, waive article processing fee, receive print and copies for all faculty and electronic for faculty/residents, and free CME and faculty/fellow position advertisement space, please go to <http://westjem.com/subscribe> or contact:

Alissa Fiorentino  
*WestJEM* Staff Liaison  
Phone: 1-800-884-2236  
Email: [sales@westjem.org](mailto:sales@westjem.org)

## JOURNAL FOCUS

*Clinical Practice and Cases in Emergency Medicine* (CPC-EM) is a MEDLINE-indexed internationally recognized journal affiliated with the *Western Journal of Emergency Medicine* (WestJEM). It offers the latest in patient care case reports, images in the field of emergency medicine and state of the art clinicopathological and medicolegal cases. CPC-EM is fully open-access, peer reviewed, well indexed and available anywhere with an internet connection. CPC-EM encourages submissions from junior authors, established faculty, and residents of established and developing emergency medicine programs throughout the world.

## Table of Contents *continued*

- 44 **Abilifright: A Case Report of Massive Aripiprazole Overdose in a Toddler**  
*Warstadt NM, Mohan S, Furlano ER, Shenker JH, Gibbs EP, Smith SW*
- 49 **Fungal Endophthalmitis on Ocular Ultrasound: A Case Report**  
*Fender K, Bautista M, Patel H, Ostro B, Boulger C*
- 53 **A Case Report of Massive Intraoperative Hemorrhage from Rare Cornual Pregnancy**  
*BM Carius, EJ Houston, SP Griffith*
- 57 **Necrotizing Mediastinitis Following Dental Extraction: A Case Report**  
*J Pinkston, CA Khoury, JD Raper*
- 61 **An Unusual Presentation of a Lymphatic Malformation in an Adult: A Case Report**  
*M Gilmore, SH Kim, CM McDowell*
- 65 **18-year-old with Abdominal Pain Due to Congenital Bowel Malrotation: A Case Report**  
*E McMahon, M Penfold, M Cain*
- 69 **Critical Point-of-care Ultrasound Diagnosis of Fournier's Gangrene: A Case Report**  
*L Ramm, K Guidry, A Cirilli, E Kurkowski, C Yu*
- 73 **An Unusual Case of Right Lower Quadrant Pain: A Case Report**  
*S Jabre, M Supino*
- 76 **Hemiplegia Following Fluid Administration Through an Implanted Venous Access Device: A Case Report**  
*J Waymack, C McDowell, N Feller, S Kim*
- 80 **Prompt Diagnosis of Ethylene Glycol Intoxication by an Unusual "Lactate Gap": A Case Report**  
*J Tang*
- 83 **Buprenorphine for High-dose Tramadol Dependence: A Case Report of Successful Outpatient Treatment**  
*L Mukau, K Wormley, C Tomaszewski, B Ahmad, R Vohra, AA Herring*
- 87 **Case Report of Torsion of Cryptorchid Testis Causing Abdominal Pain**  
*H Newhouse, J Minardi, F Rawlins*

Policies for peer review, author instructions, conflicts of interest and human and animal subjects protections can be found online at [www.cpcem.org](http://www.cpcem.org).

## Table of Contents *continued*

### Images in Emergency Medicine

- 90     **Nausea and Dyspnea on Exertion: Left Ventricular Free-wall Rupture**  
*J Wilson, M Mendes, ME Betz, JG Mingo*
- 93     **Delayed Tension Pneumocephalus Following Frontal Sinus Fracture**  
*EX Ortiz-Galloza, B Arechiga, J Heer, D Quesada*
- 95     **The Case of the Red Extremities**  
*K Abarikwu, JS Komara, A Urumov*
- 97     **Scrotal Pain Caused by a Segmental Testicular Infarct**  
*M Muradian, S Fox, P Barish, B Todd*
- 100    **Ruptured Urinary Bladder Diagnosed by Point-of-care Ultrasound**  
*JC Bates, V Kneller, L Abubshait*
- 103    **Case of an Infant with Intermittent Eye Swelling**  
*AH Baker, S Lipsett*
- 105    **Unintentional Epinephrine Auto-Injector Maxillofacial Injury in a Pediatric Patient**  
*J David, J Eldred, D Raper*
- 108    **Frontal Arteriovenous Malformation Presenting as Painful Unilateral Conjunctiva Injection**  
*A Harkins, C Bassig-Santos, M Cirone*

### Erratum

- 111    **This Article Corrects: “A Chemist with a Strange Etiology of Rhabdomyolysis: A Case Report of a Rare Toxicological Emergency”**  
*R Meenakshisundaram, JV Joseph, P Perumal, A Areeb, P Pancheti, DK Sampath, EM Jared, AK Ryan*

*Clinical Practice and Cases in Emergency Medicine* (CPC-EM) is a open-access Medline-indexed internationally recognized journal affiliated with the *Western Journal of Emergency Medicine* (WestJEM). CPC-EM is distributed electronically to 19,000 emergency medicine scholars. This includes our sponsors California ACEP, the American College of Osteopathic Emergency Physicians, California Chapter of AAEM, and over 83 academic department of emergency medicine subscribers and 8 AAEM State Chapters.



# Revenue Cycle & Practice Management Solutions.

Brault offers scalable services to support your emergency medicine practice.

Whether you're looking for a full-service RCM partner, a support team to manage your business functions, or a group of experts to advise and help grow your practice—**Brault has everything you need under one umbrella.**



Schedule a Free Review today at [www.Brault.us](http://www.Brault.us)

# CPC**EM** Clinical Practice & Cases

## **CALL FOR SUBMISSIONS**

- Patient Care Case Reports
- Images in Emergency Medicine

Fully open-access, peer reviewed, well indexed: CPC-EM is available anywhere with an internet connection at **CPCEM.org**

***Clinical Practice and Cases in Emergency Medicine*** is an internationally recognized journal affiliated with the MEDLINE-indexed ***Western Journal of Emergency Medicine***

**CPC-EM encourages submissions from junior authors and countries with developing emergency medicine programs**

# CPC**EM** Clinical Practice & Cases

## **CALL FOR CPC-EM SECTION EDITORS!**

- Medical-Legal Case Reports
- Case Reports/Images in Emergency Medicine

**Send your CV and letter of interest to [editor@westjem.org](mailto:editor@westjem.org)**



## 57-year-old Female with Unusual Left-arm Movements

Christina M. Powell, DO\*

Lauren S. Rosenblatt, MD<sup>†</sup>

Laura J. Bontempo, MD, MEd<sup>†</sup>

Zachary D.W. Dezman, MD, MS, MS<sup>†,‡</sup>

\*University of Maryland Medical Center, Baltimore, Maryland

<sup>†</sup>University of Maryland School of Medicine, Department of Emergency Medicine, Baltimore, Maryland

<sup>‡</sup>University of Maryland, Baltimore, Department of Epidemiology and Public Health, Baltimore, Maryland

Section Editor: Joel Moll, MD

Submission history: Submitted December 13, 2021; Revision received January 26, 2022; Accepted February 4, 2022

Electronically published February 28, 2022

Full text available through open access at [http://escholarship.org/uc/uciem\\_cpccm](http://escholarship.org/uc/uciem_cpccm)

DOI: 10.5811/cpcem.2022.2.55676

**Introduction:** A 57-year-old, right-hand dominant female presented to the emergency department striking herself with her left hand.

**Case Presentation:** The astute medical staff looked beyond a behavioral health etiology. A detailed history, physical examination, and workup reveals the fascinating final diagnosis.

**Discussion:** This case takes the reader through the differential diagnosis and systematic workup of uncontrolled limb movements with discussion of the studies which ultimately led to this patient's diagnosis. [Clin Pract Cases Emerg Med. 2022;6(1):1–7.]

**Keywords:** *stroke; alien hand syndrome; CPC.*

### CASE PRESENTATION (DR. POWELL)

A 57-year-old, right-hand dominant female presented to the emergency department (ED) with unusual movements and shaking of her left arm. In the ED, the staff had to restrain the patient from actively hitting herself in an excited manner. The nursing staff then requested medical evaluation and clearance from the physician team so the patient could be transferred to the psychiatric ED due to apparent self-destructive behavior.

The patient stated she had not been sleeping well recently. Her husband was away and she felt overwhelmed by caring for their dog. The patient stated she awoke that morning around 2:30 AM feeling weak to the point that she could not get out of bed. She felt as if her left arm did not belong to her and she could not control her arm's movements. She had to hold her left hand with her right to keep her left arm from moving. She denied ever having this problem before. Her husband stated that she had previously exhibited similar symptoms when faced with stressors. The patient also complained of numbness and tingling of her left hand and mild shortness of breath. She stated it felt like "cold water is running down my [left] arm." Additionally, she complained of a feeling in her throat that was making it "hard to breathe," and she had a headache located in the back of her head, described as slightly worse than her prior headaches.

The patient had previously been involuntarily admitted to a behavioral health unit after attempting to harm herself, although she did not have any psychiatric diagnoses.

She had a past medical history of breast cancer status post right mastectomy. She did not take any daily medications and had no drug allergies. Her family history was notable for cancer and coronary artery disease. She was a daily tobacco smoker and occasionally used marijuana. She denied any alcohol use. She denied any chest pain, nausea, vomiting, change in vision, lightheadedness, dropping of objects, or trauma. She recently had a mild, pruritic skin rash for which she completed a course of oral prednisone. She denied joint pain, fevers, chills, cough, or abdominal complaints.

On examination, she was alert and, although she appeared very anxious, was in no acute distress. She was afebrile (37.1° Celsius) with a heart rate of 94 beats per minute, blood pressure 108/62 millimeters of mercury, and her oxygen saturation was 97% while breathing room air. She weighed 51.8 kilograms (kg) (114 pounds), was 165.1 centimeters in height (5 foot 4 inches), and had a body mass index of 20.14 kg per meter<sup>2</sup>. She was well developed and well nourished. Her head was normocephalic and atraumatic. She had dry mucus membranes with a clear oropharynx. Pupils were



equal, round, and reactive to light and accommodation with normal extraocular movements and anicteric sclera. Her neck was supple, with full active range of motion, and without lymphadenopathy or carotid bruits. Her lungs were clear to auscultation bilaterally, without wheezes, crackles, or rhonchi. She did not have any increased work of breathing. Her heartbeat was regular at a normal rate without murmurs, rubs, or gallops. The patient's abdomen was soft with normal bowel sounds and without distention, tenderness, rebound, or guarding. Her extremities had no edema, had 2+ pulses, and were without tenderness or deformity bilaterally. Erythematous scaly plaques were observed on her neck, bilateral ankles, axilla, and lower arms.

Neurologic examination showed cranial nerves II-XII were intact except for a left homonymous inferior quadrantanopia. She had 5/5 strength throughout all extremities and normal muscle bulk and tone. The upper extremity exam was limited by flailing movements of her left arm, which were notably high in amplitude and non-rhythmic. The movements worsened with emotional distress and decreased with distraction. When the patient was asked to look at something specific, the flailing left-arm movements stopped. There was decreased sensation to light touch and pinprick over the left upper extremity in a patchy distribution. Her biceps, brachioradialis, and patellar reflexes were 1+ bilaterally. No dysmetria was noted on finger-nose-finger testing bilaterally, and the patient declined a gait exam. Her speech was clear. She followed commands and answered most questions appropriately but occasionally was tangential. She was oriented to self, place, and time.

Initial laboratory results are shown in Tables 1-2. An electrocardiogram (ECG) was completed, which showed sinus tachycardia without signs of ischemia. A chest radiograph did not show any focal consolidations, pneumothorax, or cardiomegaly. Computed tomography (CT) of the head without contrast did not show evidence of an acute intracranial bleed or acute infarction. There was non-specific asymmetric diffuse sulcal effacement of the right cerebral hemisphere relative to the left. No midline shift was noted. Neurology was consulted due to worsening left upper-extremity movements throughout her ED evaluation. A clock drawing completed by the patient is shown in Image 1. A diagnostic test was then performed, which confirmed the diagnosis.

### CASE DISCUSSION (DR. ROSENBLATT)

This is a case of a 57-year-old female who arrived in the ED with a very unusual presentation that could have easily been dismissed as a mental health issue. This patient is a great reminder that medical etiologies always need to be considered and ruled out alongside psychiatric etiologies. The medical team taking care of this patient astutely noted the unusual presentation and did an extensive exam and workup to consider, and presumably ultimately identify, a treatable medical condition. Now I am tasked with sorting through this

**Table 1.** Blood laboratory results of a 57-year-old female presenting with strange movements and shaking of her left arm.

Test Name	Patient Value	Reference Range
Complete blood count		
White blood cells	14.8 K/mcL	4.5 - 11 K/mcL
Hemoglobin	16.2 g/dL	11.9 - 15.7 g/dL
Hematocrit	47.6%	35.0 - 45.0%
Platelets	331 K/mcL	153 - 367 K/mcL
Differential		
Neutrophils	71.1%	42.6 - 74.5%
Lymphocytes	20.8%	20.8 - 50.5%
Monocytes	4.9%	2.0 - 10.3%
Eosinophils	2.0%	0.9 - 2.9%
Complete metabolic panel		
Sodium	143 mmol/L	136 - 145 mmol/L
Potassium	3.7 mmol/L	3.5 - 5.1 mmol/L
Chloride	111 mmol/L	98 - 107 mmol/L
Bicarbonate	28 mmol/L	21 - 30 mmol/L
Glucose	116 mg/dL	70 - 99 mg/dL
Blood urea nitrogen	15 mg/dL	7 - 17 mg/dL
Creatinine	0.84 mg/dL	0.52 - 1.04 mg/dL
Calcium	9.4 mg/dL	8.6 - 10.2 mg/dL
Magnesium	2.2 mg/dL	1.6 - 2.6 mg/dL
Phosphorous	3.8 mg/dL	2.5 - 4.5 mg/dL
Total protein	7.7 g/dL	6.3 - 8.2 g/dL
Albumin	4.4 g/dL	3.2 - 4.6 g/dL
Total bilirubin	0.5 mg/dL	0.3 - 1.2 mg/dL
Aspartate aminotransferase	31 u/L	14 - 36 units/L
Alanine aminotransferase	19 u/L	0 - 34 units/L
Alkaline phosphatase	66 u/L	38 - 126 units/L
Additional Labs		
Troponin I	<0.02 ng/mL	<=0.06 ng/mL
Acetaminophen	<10.0 mcg/mL	<10.0 mcg/mL
Salicylate level	<1.0 mg/dL	<1.0 mg/dL
Ethanol level	<10.0 mg/dL	<10.0 mg/dL

K, thousands; mCL, microliter; g, grams; dL, deciliter; mmol, millimole; L, liter; mg, milligram; u, unit; ng, nanogram; mcg, microgram; mL, milliliter.


presentation and workup to determine what facts are valuable in leading me to a correct final diagnosis.

To summarize, this patient presented to the ED with some striking exam findings. It would be hard not to notice a

**Table 2.** Urine laboratory results of a 57-year-old female presenting with strange movements and shaking of her left arm.

Test Name	Patient Value	Reference Range
Urinalysis		
pH	6.0	5.0 - 8.0
Specific gravity	1.008	1.002 - 1.030
Glucose	Negative	Negative
Ketones	Negative	Negative
Nitrates	Negative	Negative
Leukocyte esterase	3+	Negative
White blood cells	26-50 count/uL	0 – 5 /hpf
Red blood cells	26-50 count/uL	0 – 2/hpf
Squamous epithelial cells	6-10 count/uL	Negative
Bacteria	Negative	Negative
Urine Toxicology		
Amphetamine	Negative	Negative
Barbiturate	Negative	Negative
Benzodiazepine	Negative	Negative
Cannabinoid	Positive	Negative
Fentanyl	Negative	Negative
Methadone	Negative	Negative
Opiate	Positive	Negative
Oxycodone/oxymorphone	Negative	Negative
Phencyclidine	Negative	Negative
Additional Urine Studies		
Urine pregnancy	Negative	Negative

$\mu$ L, microliter; hpf, high power field.

**Image 1.** Clock drawn with the dominant (right) hand of a 57-year-old female presenting with strange movements and shaking of her left arm.

patient who appeared visibly anxious and was hitting herself repeatedly with her extremity. From the history provided, the patient developed the symptoms of uncontrolled arm movements, paresthesias (described as the sensation of water on her left upper extremity), and a feeling of lack of ownership of the left upper extremity acutely. It was noted that at 2:30 AM she felt tired and weak and, upon waking later that morning, developed the unusual movements. Although her husband reports suicidal ideation in the past with some self-injurious behavior of hitting her head against a counter, she does not have any formal psychiatric diagnoses nor any other chronic medical diagnoses in her past medical history.

While the patient's history certainly is informative, focusing on the physical exam provided the best starting point for developing a working differential diagnosis. The neurologic exam provided the most useful information. There were three exam findings that really stood out: 1) large amplitude flailing left upper extremity movement; 2) left homonymous inferior quadrantanopia; and 3) hemineglect. The left upper extremity movements are noted to be involuntary, large amplitude, and non-rhythmic, which is consistent with a description of chorea and, more specifically, ballismus. The hemineglect is particularly interesting as it is noted in both the history, by the patient expressing lack of ownership of her arm, as well as the physical exam, as demonstrated by her clock drawing (Image 1). It would have been helpful to see whether the patient could draw something from memory, as this would help differentiate visuospatial dysfunction from hemineglect. Additionally, it is important to note other exam findings such as the sensory deficits to light touch and pinprick in the left arm and a rash of unknown chronicity.

Using this information, I started to home in on a differential diagnosis. Just as you would in any clinical setting, it is important to start broadly. Each of the key neurologic findings noted above can be associated with a wide variety of etiologies. These etiologies can then be grouped into autoimmune, endocrine, hereditary, infectious, malignant, metabolic, toxic/drug-induced, traumatic, and vascular categories. Keeping the ballismus, vision changes, and hemineglect in mind, I developed the following list:

- Autoimmune: Sydenham's chorea; lupus; vasculitis
- Endocrine: Hyperthyroid; hyperparathyroid; hypoparathyroid
- Hereditary: Huntington's disease; Wilson's disease; ataxia-telangiectasia; Lesch-Nyhan syndrome
- Infectious: Human immunodeficiency virus (HIV); toxoplasmosis; meningitis; encephalitis
- Malignant: Primary neoplasm; metastatic disease
- Metabolic: Non-ketotic hyperglycemia; hyponatremia; hypernatremia; hypercalcemia; hypocalcemia
- Toxic/Drug induced: Toxic ingestion; side effect of chronic medication use (ie, levodopa, anti-psychotics)
- Traumatic: Head injury
- Vascular: Stroke.

Some of these diagnoses can be ruled out easily. Head trauma can be excluded immediately, as there is no history of recent trauma or head injury in her presentation. The hereditary etiologies of Huntington's disease, Wilson's disease, ataxia-telangiectasia, and Lesch-Nyhan are all unlikely diagnoses. All these diseases can be associated with chorea/ballismus but are unlikely to cause other neurologic symptoms. Additionally, many of them would present early in childhood (such as Lesch-Nyhan) or be associated with a strong family history (such as Huntington's disease). Given the patient's age and lack of reported family history of neurological problems, these are excluded. The metabolic etiologies can also be ruled out by the normal lab values provided.

Endocrine etiologies were also considered as they can cause neurologic and psychiatric manifestations; however, I would consider neurological and psychiatric symptoms to be the extreme presentation of these diseases and a part of a progression of symptoms. It would be unlikely to have an acute onset of symptoms associated with either hyperthyroidism, hyperparathyroidism, or hypoparathyroidism. When the thyroid is involved, one would expect additional symptoms of thyrotoxicosis such as tachycardia, weight loss, and even exophthalmos. However, this patient does not have any of those additional symptoms. Parathyroid disease can also be ruled out by the normal calcium and phosphorus lab values. Toxic ingestions and drug-induced causes can similarly be excluded. This patient is not currently on any medications and, although she has had a prior presentation for suicidal thoughts, she does not express recent or current thoughts of suicide. Her urine drug screen was positive for marijuana and opiates; however, her constellation of neurologic findings is not consistent with a typical opiate or cannabinoid toxidrome.

Next, I considered autoimmune causes, such as Sydenham's chorea, lupus, and vasculitis. Sydenham's chorea is a rare neurologic disorder, characterized by ballismus. It is usually a result of streptococcal infection and rheumatic fever. This is almost always a disorder in children, although there have been extremely rare case reports in adults. The rarity of Sydenham's chorea would make it an unlikely cause of this patient's presentation, especially in the absence of recent streptococcal infection or infectious symptoms. Lupus and vasculitis should be considered, as these diseases can affect any part of the body. Isolated acute neurologic presentations are rare, however, as the initial presentations of these diseases. Usually there is progression of symptoms over time. The rash that the patient has can certainly make these etiologies more favorable; however, the chronicity of the rash is unknown to me. Regardless of the duration of the rash, the acuity of this patient's clinical presentation, without additional history or a review of systems that paints a picture of progression of disease over time, makes an autoimmune diagnosis less likely.

Infection must also be considered. I have identified HIV, toxoplasmosis, meningitis, and encephalitis as possible

etiologies. However, the patient does not have a history of HIV or being immunocompromised, making HIV and toxoplasmosis unlikely. Meningitis and encephalitis are still possible, but lower on the differential diagnosis. The patient has not had any recent fevers and was afebrile on presentation. Additionally, she has had no recent complaints of nausea, vomiting, fatigue, decreased appetite, or malaise leading up to her ED presentation. On exam the patient did not have clinical signs of meningismus. The unusual neurologic physical exam findings could be due to central nervous system infection but would be a very uncommon presentation of meningitis or encephalitis.

This leaves me with two unexplored categories: malignancy and vascular. Malignancy is a feasible diagnosis for the patient's symptoms; however, I would expect a progression of symptoms. The patient does report a headache, but this seems to be a new symptom. A more likely presentation of malignancy would include progressive worsening of her headache, or intermittent or progressive worsening of neurologic symptoms. Additionally, this patient did not report any recent weight loss, night sweats, or fevers in her history. The acuity of the patient's presentation makes malignancy lower on my differential diagnosis.

Finally, a vascular etiology must be investigated. Remember, this patient presented with the acute onset of ballismus, hemineglect, and inferior quadrantanopia. When revisiting the patient's neurologic findings, I attempted to localize the areas of the brain that would most commonly need to be affected to cause these symptoms. The symptoms map to the following parts of the brain:

**Ballismus/chorea** – Caudate, putamen, thalamus, subthalamic nucleus

**Hemineglect** – Non-dominant parietal lobe infarct (most commonly right side)

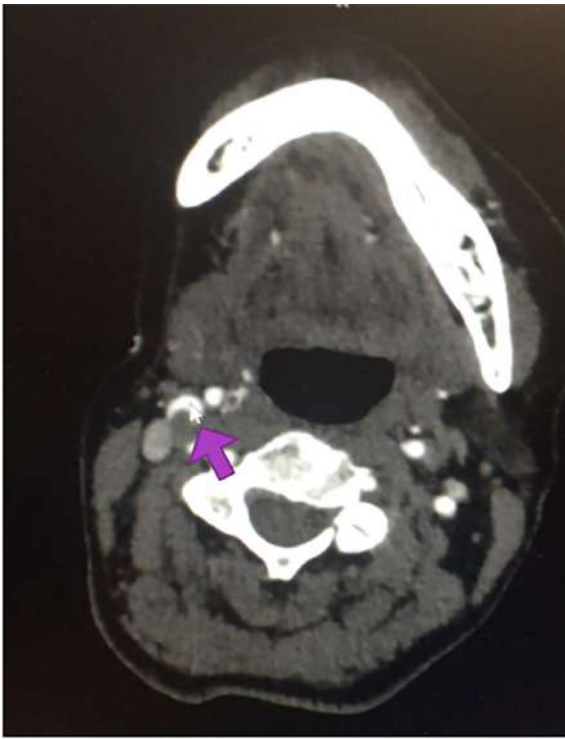
**Inferior quadrantanopia** – Superior optic radiations in the parietal lobe.

All the areas of the brain noted above are primarily supplied by the middle cerebral artery (MCA). Therefore, my final diagnosis is MCA stroke, and the diagnostic test would be magnetic resonance imaging (MRI).

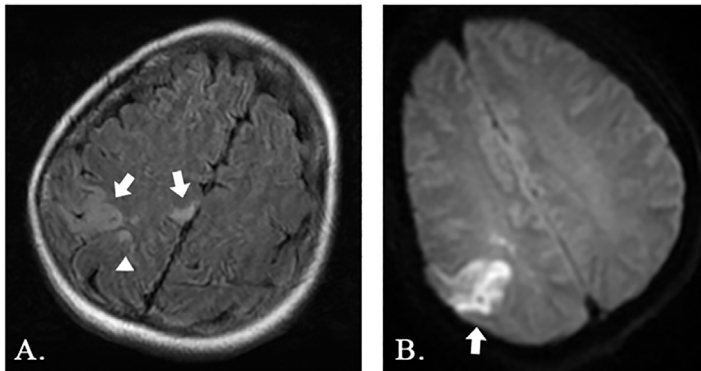
#### CASE OUTCOME (DR. POWELL)

The diagnostic study was a CT angiography of the head and neck. As described by the radiologist, the patient sustained small, recent infarctions involving the right parietal lobe and potentially the right precentral gyrus. A soft atherosclerotic plaque with extensive thrombus was present in the right external carotid artery. The patient proceeded to have an MRI of the brain which showed acute infarcts in both the right anterior cerebral artery (ACA) and MCA distributions suggesting an embolic etiology, likely from the carotid plaque seen on the CT angiography, demonstrated in Images 2 and 3. An ultrasound of the carotid arteries identified a smooth plaque in the right proximal internal carotid artery. The patient was subsequently admitted to the neurology stroke





**Image 2.** Computed tomography angiography of the neck identifying soft tissue at the right carotid bulb (arrow), mildly narrowing the lumen by less than 50%, potentially composed of soft atherosclerotic plaque with extensive thrombus.



**Image 3.** Brain magnetic resonance imaging showing (A) multiple foci of abnormal restricted diffusion predominantly involving the right parietal lobe (arrows) and right occipital lobe (arrowhead), and (B) hyperintense signal of the right parietal lobe on axial T2 fluid attenuated inversion recovery (FLAIR) sequence (arrow).

service. Heparin was initiated for anticoagulation. Vascular surgery was consulted and the patient underwent a right carotid endarterectomy. After surgery, her left arm's unusual movements had completely resolved. The sensory loss persisted, and she continued to feel the need to move, despite overall improvement in her symptoms. She was eventually transferred to acute rehabilitation, quit smoking, and was later discharged home.

## RESIDENT DISCUSSION (DR. POWELL)

In 1908, the German neurologist and psychiatrist Dr. Kurt Goldstein was bewildered by the strange behaviors manifested in one of his patients.<sup>1</sup> This patient had reported that her left hand had a “will of its own,” and it had tried to choke her, forcing her to defend herself with her more obedient arm. Autopsy later identified infarctions in the right hemisphere and corpus callosum. It was not until 1972 that this constellation of symptoms was officially recognized as alien hand syndrome (AHS).<sup>2</sup> It was coined by the French term “*le syndrome de la main étrangère*” (the sign of the foreign hand). Patients who present with AHS often do not recognize that the affected limb is a part of their own body. They state the limb feels foreign, complain of paresthesias, and are unable to voluntarily control its movement. This syndrome typically affects the hand but can also affect the leg.<sup>3</sup> Initially, this syndrome was thought to be a post-surgical complication from corpus callosotomy or frontal lobe ablation.<sup>4</sup> Today there are three main variants of AHS described in the literature.

Feinberg et al described two distinct syndromes: a frontal and a callosal variant.<sup>5</sup> The frontal variant affects the lesions of the supplementary motor area, cingulate cortex, and medial frontal cortex, typically caused by a stroke in the anterior communicating artery territory with or without involvement of the corpus callosum.<sup>6</sup> This variant commonly affects the dominant hand and presents with impulsive groping (where the hand seems to be constantly searching for nearby objects), compulsive manipulation of objects, and difficulty releasing objects.<sup>7</sup> Associated conditions frequently encountered with this variant are those seen in frontal lobe lesions or frontal lobe ablations, including frontal release signs (grasp reflex, glabellar sign, palmomental reflex, etc), hemiparesis, and non-fluent aphasia.<sup>8</sup>

The callosal variant is typically caused by a callosal hemorrhage, infarct or callosotomy. Alien hand syndrome in this variant exclusively affects the non-dominant (left) hand in right-handed patients.<sup>9</sup> The patient will present with intermanual conflict when the non-dominant hand is activated by conversation or voluntary activation of the dominant hand. Intermanual conflict is described as opposing, purposeful movements of the patient's hands.<sup>10</sup> The non-dominant hand behaves unilaterally, working against the dominant hand as if the hands are “fighting” against each other. There is minimal weakness associated with this variant. The associated findings include apraxia, tactile anomia, visual anomia, agraphia, and neglect.<sup>11</sup>

The final variant, and the type evidenced in this case presentation, is the posterior/opticosensory variant. The posterior variant is typically caused by a stroke in the parietal lobe or posterior cerebral artery territory, neurodegeneration of the parieto-occipital cortex (corticobasal syndrome) or Creutzfeldt-Jakob disease (CJD).<sup>9</sup> As in our patient, this variant most commonly affects the non-dominant hand and is associated with parietal sensory deficits, including visual or sensory neglect, hemisomatognosia, body schema

dysfunction, and spatial neglect.<sup>12</sup> Patients exhibit strong feelings of estrangement from the affected limb and experience less complex motor activity such as limb levitation, ataxia, or non-purposeful or non-conflicting movements.<sup>13</sup> These patients unintentionally withdraw the affected hand from the environment as an avoidance response or experience uncoordinated hand movements, which may be related to a task. In one reported case of corticobasal syndrome, exaggerated arm elevation only occurred while walking.<sup>14</sup> The three different variants can present as a mixed picture depending on the lesion. For example, two CJD cases were reported with mixed anterior and posterior variant AHS. The patients had significant intermanual conflict and hemispatial neglect.<sup>15</sup>

Our patient sustained infarctions in both the ACA and MCA distributions. In a paper describing 100 patients suffering from ischemic strokes of the ACA (including subsequent infarctions in the corpus callosum, cingulate gyrus, or supplementary motor area), AHS occurred in 10% of medial frontal strokes.<sup>16</sup> It is unknown how many MCA strokes involve AHS, due to the many additional symptoms presenting with MCA infarctions.

The ED workup includes basic labs, toxicological studies, ECG, and urine studies to look for alternative etiologies of the patient's presentation. The first imaging study to obtain is CT of the head, as it will assess for etiologies such as space-occupying lesions and intracranial hemorrhage. Magnetic resonance imaging is the diagnostic imaging modality of choice as it will show both infarcted tissue, areas of edema, and salvageable brain tissue. As in our patient, angiography and ultrasound helped isolate and localize plaques and vessel stenosis. Patients with AHS should be admitted to the hospital for further evaluation, diagnostic studies, and management.

The treatment of AHS follows the initial management goals of an ischemic infarction. The underlying etiology may be treated with targeted blood pressure control, anticoagulation, specialist consultation, thrombolytics, embolectomy, and/or endarterectomy. There are specific techniques designed to target the uncontrolled "alien" limb after initial stabilization. Abnormal motor activity can be reduced by occupying the affected limb (holding a cane), placing the affected limb in a glove or mitt, or using progressive muscle relaxation (including botulism toxin or muscle relaxants). Mirror box therapy has been described as a way to conduct visual-spatial coaching. Mirror box therapy is hypothesized to improve AHS symptoms by restoring the relationship between motor intentions and visual feedback.<sup>17</sup> The patient moves the unaffected limb in front of the mirror, hiding the "alien" limb from view. The reflection, where the affected limb should be, is perceived as their arm, and they can attribute sensorimotor features of that intact arm to their alien one.

In general, infarction-related AHS has a good prognosis. As in this case presentation, after standard-of-care stroke management, patient-tailored rehabilitation is very successful. The most debilitating aspects of AHS typically resolve within

weeks to months with proper treatment and therapy. In a literature review, decreases in AHS symptoms occurred in 68% of patients, whereas symptoms persisted in 32%.<sup>18</sup> Proper identification through an in-depth history and neurologic examination can aid in prompt diagnosis and treatment of this uncommon stroke variant.

## FINAL DIAGNOSIS

Alien hand syndrome secondary to acute non-dominant parietal lobe infarction.

## KEY TEACHING POINTS

- In addition to more prevalent stroke syndromes involving motor and sensory losses, consider stroke variants in patients who present with hyperkinetic movements and psychiatric overtones.
- Alien hand syndrome can present with abnormal hand movements and lack of subjective limb ownership.
- Alien hand syndrome can be caused by intracranial hemorrhage, infarction, or surgical alteration involving the frontal, callosal, and posterior brain territories.
- A thorough neurologic examination is critical to make the diagnosis of AHS, especially when faced with psychiatric bias.

The authors attest that their institution requires neither Institutional Review Board approval, nor patient consent for publication of this case report. Documentation on file.

---

*Address for Correspondence:* Laura Bontempo, MD, MEd, University of Maryland, Department of Emergency Medicine, 110 S Poca St, 6th Floor, Baltimore, MD 21201. Email: [Lbontempo@som.umaryland.edu](mailto:Lbontempo@som.umaryland.edu)

*Conflicts of Interest:* By the *CPC-EM* article submission agreement, all authors are required to disclose all affiliations, funding sources and financial or management relationships that could be perceived as potential sources of bias. The authors disclosed none.

*Copyright:* © 2022 Powell. This is an open access article distributed in accordance with the terms of the Creative Commons Attribution ([CC BY 4.0](https://creativecommons.org/licenses/by/4.0/)) License. See: <http://creativecommons.org/licenses/by/4.0/>

---

## REFERENCES

1. Brainin M, Seiser A, Matz K. The mirror world of motor inhibition: the alien hand syndrome in chronic stroke. *J Neurol Neurosurg Psychiatry*. 2008;79(3):246-52
2. Brion S and Jedynak CP. Disorders of interhemispheric transfer (callosal disconnection). 3 cases of tumor of the corpus callosum.

- The strange hand sign]. *Rev Neurol (Paris)*. 1972;126(4):257-66.
3. Chan JL, Chen RS, Ng KK. Leg manifestation in alien hand syndrome. *J Formos Med Assoc*. 1996;95(4):342-46.
  4. Akelaitis A. Studies on the corpus callosum, IV. Diagnostic dyspraxia in epileptics following partial and complete section of the corpus callosum. *Am J Psychiatry*. 1945;101(5):594-9.
  5. Feinberg TE, Schindler RJ, Flanagan NG, et al. Two alien hand syndromes. *Neurology*. 1992;42(1):19-24.
  6. Sarva H, Deik A, Severt WL. Pathophysiology and treatment of alien hand syndrome. *Tremor Other Hyperkinet Mov (NY)*. 2014;4:241.
  7. Huang Y and Jia J. Corpus callosum hematoma secondary to cerebral venous malformation presenting as alien hand syndrome. *Neurocase*. 2013;19:377-81.
  8. Mori E and Yamadori A. Unilateral hemispheric injury and ipsilateral instinctive grasp reaction. *Arch Neurol*. 1985;42:485-88.
  9. Hassan A and Josephs KA. Alien hand syndrome. *Curr Neurol Neurosci Rep*. 2016;16(8):73.
  10. Brainin M, Seiser A, Matz K. The mirror world of motor inhibition: the alien hand syndrome in chronic stroke. *J Neurol Neurosur PS*. 2008;79(3):246-52.
  11. Geschwind DH, Iacoboni M, Mega MS, et al. Alien hand syndrome: Interhemispheric motor disconnection due to a lesion in the midbody of the corpus callosum. *Neurology*. 1995;45(4):802-8.
  12. Yuan JL, Wang SK, Guo XJ, et al. Acute infarct of the corpus callosum presenting as alien hand syndrome: evidence of diffusion weighted imaging and magnetic resonance angiography. *BMC Neurol*. 2011;11(1):142.
  13. Kloesel B, Czarnecki K, Muir JJ, et al. Sequelae of a left-sided parietal stroke: posterior alien hand syndrome. *Neurocase*. 2010;16(6):488-93.
  14. Prakash KM, Ting SK, Ahmad MT. Unusually increased arm swing in an apraxic upper limb in corticobasal syndrome. *Parkinsonism Relat Disord*. 2011;17:126-7.
  15. MacGowan DJ, Delanty N, Petito F, et al. Isolated myoclonic alien hand as the sole presentation of pathologically established Creutzfeldt-Jakob disease: a report of two patients. *J Neurol Neurosur PS*. 1997;63(3):404-7.
  16. Kang SY and Kim JS. Anterior cerebral artery infarction: stroke mechanism and clinical-imaging study in 100 patients. *Neurology*. 2008;70(24):2386-93.
  17. Romano D, Sedda A, Dell'Aquila R, et al. Controlling the alien hand through the mirror box. A single case study of alien hand syndrome. *Neurocase*. 2014;20(3):307-16.
  18. Kikkert MA, Ribbers GM, Koudstaal PJ. Alien hand syndrome in stroke: a report of 2 cases and review of the literature. *Arch Phys Med Rehabil*. 2006; 87:728-32.



## Let's Be Honest: These Medical Malpractice Cases Were a Pain in the Back

**Samuel Isaias Garcia, MD\***  
**Summer Ghiath, BS<sup>†,‡</sup>**  
**Gregory P. Moore, MD, JD\***  
**Rachel A. Lindor, MD, JD<sup>§</sup>**  
**Sara Hevesi, MD\***

\*Mayo Clinic, Department of Emergency Medicine, Rochester, Minnesota  
<sup>†</sup>Mayo Clinic Alix School of Medicine, Scottsdale, Arizona  
<sup>‡</sup>Sandra Day O'Connor College of Law, Tempe, Arizona  
<sup>§</sup>Mayo Clinic, Department of Emergency Medicine, Scottsdale, Arizona

Section Editor: Melanie Heniff, MD, JD

Submission History: Submitted September 28, 2021; Revision received January 11, 2022; Accepted January 22, 2022

Electronically published February 28, 2022

Full text available through open access at [http://escholarship.org/uc/uciem\\_cpem](http://escholarship.org/uc/uciem_cpem)

DOI: 10.5811/cpem.2022.1.54908

**Introduction:** This series reviews three cases of back pain where a highly morbid diagnosis was missed by an emergency physician and subsequently successfully litigated.

**Case Report:** We review the clinical entities of spinal epidural abscess and cauda equina syndrome, challenging diagnoses that can be easily missed and lead to patient harm if not treated promptly. Here we offer suggestions for recognizing these conditions quickly, performing an adequate history and exam, and using documentation to support decision-making.

**Conclusion:** When confronted with an unfortunate medical outcome, maintaining honesty is of paramount importance in medical-legal environments.[*Clin Pract Cases Emerg Med.* 2022;6(1):8-12.]

**Keywords:** *back pain; cauda equina syndrome; spinal epidural abscess; medicolegal; medical malpractice; documentation honesty.*

### INTRODUCTION

Back pain is a common complaint seen in the emergency department (ED), and the vast majority of these cases are caused by a benign musculoskeletal etiology. However, there are several rare and serious diagnoses that emergency physicians must consider and treat promptly as they can lead to significant morbidity if missed. Here, we discuss three cases of back pain in which life-threatening causes were initially missed. We discuss the pitfalls and caveats that contributed to these misses and the factors that lead to successful litigation.

#### Case 1: *Anonymous v Anonymous*

Facts: A 26-year-old man presented with lower back pain that was radiating down his legs. He also complained of weakness in his legs. His rectal tone was intact. A screening evaluation was done and his white blood cell count was noted to be elevated. The facility did not have magnetic resonance imaging (MRI), and obtaining this study would have required transfer to another facility two miles away and then a return trip. Thus,

the emergency physician ordered a computed tomography (CT) of the lumbar spine, which revealed a possible right iliopsoas abscess. The patient was admitted to the hospital, and over the next 24 hours his condition neurologically deteriorated. He progressed from lower extremity weakness to complete paralysis and inability to breathe on his own. He was transferred to another hospital where an MRI of the cervical spine revealed a cervical spinal epidural abscess (SEA) and he was taken immediately to surgery. The patient remained quadriplegic and required 24-hour skilled care for his lifetime. Plaintiffs litigated, claiming that the delay in diagnosis and treatment resulted in the outcome of paralysis. The lawsuit was settled for \$1.98 million.<sup>1</sup>

#### Case 2: *Wilson v Abington Hospital-Virginia*

Facts: A 58-year-old male complained of back pain after raking leaves. He was seen and prescribed percocet. Two days later he was seen again. Radiographs revealed no fracture or evidence of arthritis. No neurologic examination was done. The pain continued for five more days despite his

use of percocet. The patient returned and an MRI was ordered that revealed a SEA. He subsequently died from resultant meningitis. The plaintiff brought suit claiming that if the diagnosis would have been considered earlier in the illness, the patient would have survived. The defense claimed that the pain was consistent with a musculoskeletal origin and that further evaluation was not indicated and the care the patient received was within the standard of care. The case went to trial and the jury rendered a verdict for \$4.7 million.<sup>2</sup>

### Case 3: *Amy Cook and Jason Cook v Betty Agbede*

Facts: A 37-year-old woman awoke with severe lower back pain and was unable to stand. She was carried to the car and taken by her husband to the ED. In triage she was greeted by a nurse, and the patient reported severe lower back pain that was radiating down her left leg along with tingling in her left buttocks and groin. The nurse only documented "severe back pain." She was triaged to the "minor" care part of the ED. A nurse evaluated her, and after the same history reported severe radiating back pain but no mention of tingling. Court testimony revealed that the patient was next seen by a physician and reported the same history but added that it was the worst pain she had ever experienced. The physician did a 2-5 minute evaluation and the only physical examination performed was brushing the front of the shins. The patient was never removed from the wheelchair. The physician described the pain as "moderate," not radiating, and like similar pain in the past. The physician later said the patient was too calm for it to be severe. The physician also stated that the patient moved herself to the bed, and a full body exam lasting 15 minutes had occurred. The physician claimed the patient denied numbness or tingling. The diagnosis of back strain and chronic back pain was made. The patient was discharged on analgesics. At discharge it was documented that the patient's pain was 10/10.

The pain persisted, and the next day the patient had difficulty making it to the bathroom before experiencing urinary incontinence. Her primary physician was unavailable, so she made an appointment with a chiropractor two days later. The chiropractor performed radiographs and referred the patient immediately to the ED. In the ED the patient was diagnosed with cauda equina syndrome (CES). Immediate surgery was done, but there was permanent nerve damage resulting in chronic pain, an unsteady gait, and numbness of the groin, leg, and foot, as well as bowel and bladder incontinence.

A lawsuit was brought claiming inadequate evaluation and that the lack of response to analgesics in the ED should have warned the staff of serious pathology and that imaging was indicated. The defense was that given the history and exam there was no reason to suspect the diagnosis of CES or pursue further workup. An investigation of the medical record and electronic footprinting revealed it was impossible that the physician had done a 15-minute exam. This was based on the

fact that there was no 15-minute gap in computer entries. A confidential settlement was reached.<sup>3</sup>

## DISCUSSION

### Spinal Epidural Abscess

Spinal epidural abscess is a medical emergency caused by a pyogenic infection in the epidural space. It is known to result in significant spinal cord damage by direct compression, thrombosis, ischemia, or inflammation. Prompt diagnosis and intervention are essential to prevent devastating neurologic compromise, sepsis, and death.<sup>4</sup> Unfortunately, most cases of SEA have multiple presentations before definitive diagnosis is made. Attorneys covet litigation involving this diagnosis as they can include multiple defendants who had individual opportunities to make the correct diagnosis in a timely fashion.

It is a rare etiology with an incidence of 5.1 cases per 10,000 admissions reported by a single institution.<sup>5</sup> The mean onset of presentation is at 50 years of age, with the greatest prevalence between 50-70 years. Common risk factors include a history of injection drug use, infective endocarditis, dental abscesses, history of spinal interventions, alcoholism, diabetes, human immunodeficiency virus, and trauma.<sup>6</sup> The posterior thoracolumbar spine is the region most often involved. The most common causative organisms are staphylococcus aureus, streptococcus, Gram-negative bacilli, and anaerobes.<sup>7,8,9</sup>

The classic diagnostic triad for SEA is fever, back pain, and neurologic deficits. However, the complete triad is present in only 13-37% of patients.<sup>4</sup> The most common symptom is back pain, which is seen in 70-100% of the cases. Neurologic deficits such as motor weakness, radiculopathy, and bladder and bowel dysfunction are present in up to 50% of the cases.<sup>10</sup> Fever is often absent, which may lead to a delayed or missed diagnosis.<sup>11,12</sup> Laboratory evaluation reveals a leukocytosis in only 60% of cases; however, erythrocyte sedimentation rate and C-reactive protein are significantly elevated in nearly all cases of SEA and thus may be more helpful.<sup>10,13,14</sup>

If a SEA is clinically suspected, imaging of the spinal column should be done emergently as delays in the diagnosis or treatment may worsen the prognosis.<sup>4</sup> Magnetic resonance imaging is the imaging modality of choice and provides the best localization and extent of inflammation.<sup>15,16,17</sup> A CT with intravenous contrast may be a reasonable alternative if an MRI is contraindicated or not available.<sup>18,19</sup> It is important to remember that multiple skip lesions representing several levels of involvement can occur despite patients not having pain in all the affected areas.<sup>10</sup> This phenomenon impacts many successful malpractice cases as physicians will frequently order an MRI involving only the painful area and the abscess is lurking elsewhere. If a physician is considering this diagnosis it is imperative that an MRI of the entire spine be ordered and not just the area of maximal pain. Once blood cultures are obtained, broad-spectrum antibiotics should be started immediately.

Surgical decompression and drainage is the critical emergent treatment of choice for most patients, especially in the presence of acute or progressive neurologic deficits, spinal instability, or ring-enhancing lesions on MRI.<sup>6,21</sup>

Spinal epidural abscess is a high-risk area for malpractice litigation. Most patients present to healthcare clinicians multiple times before the diagnosis is finally made.<sup>10</sup> Failing to make the diagnosis on early visits puts a physician at great risk for a lawsuit. Three large medicolegal databases queried for SEA-related malpractice cases demonstrated plaintiff rulings for approximately 35% (47/135) of all cases, which is significantly higher than ED litigation overall (7.4%). There was an average of \$4,291,400 awarded to the plaintiff compared to \$816,909 in all of emergency medicine plaintiff awards.<sup>4,22</sup> Previous studies have shown that a delay in the diagnosis, delay in treatment, and presence of neurologic complications are all associated with a significant increase in plaintiff awards.<sup>4</sup>

After assimilating the above information, it is clear why the first two cases above were successfully litigated. In the first case, successful litigation may have been avoided if SEA had been considered in the setting of low back pain, weakness, and leukocytosis. An MRI, if pursued, would have likely revealed the correct diagnosis but only if the entire spine had been examined rather than the lumbar spine alone where the patient was experiencing maximal pain. The physician may have anchored on the CT finding of a possible iliopsoas abscess and thus chose not to pursue the gold standard test (MRI) as it would have taken more effort. Often, successfully litigated lawsuits result from a clinician's willingness to accept a non-optimal study as an answer to a clinical question. If SEA is clinically suspected, broad-spectrum antibiotics should be initiated and an MRI immediately performed.

In the second case, there was again a successful litigation of SEA as a result of a common pattern in the entity. A clinician must be on guard and suspect SEA especially when there are recurrent visits for severe back pain being labeled as musculoskeletal in nature and should perform a thorough neurologic exam with documentation. Lack of exam/documentation will appear to the jury as an uncaring or less thorough clinician. This became an issue in case 3 as well.

### **Cauda Equina Syndrome**

Cauda equina is a rare syndrome consisting of one or more of the following: bladder and/or bowel dysfunction; reduced sensation in the saddle area; and sexual dysfunction with possible neurologic deficit in the lower limbs. It is estimated to occur in fewer than 1 in 2000 patients presenting with severe low back pain and is caused by an intraspinal lesion distal to the conus that involves greater than or equal to two of the 18 nerve roots of the cauda equina.<sup>23</sup> The clinical diagnosis is made through a thorough history and physical exam and is confirmed with radiographic studies. The radiographic modality of choice for CES is an MRI. In situations where an MRI is unobtainable, a CT with

myelography can be considered.<sup>24</sup> Once identified, prompt decompression is recommended.

Potential etiologies include structural causes such as intervertebral disc herniation or tumors, infection such as SEA, inflammatory conditions such as spinal arachnoiditis, chronic inflammatory demyelinating polyneuropathy or sarcoidosis, and iatrogenic causes, among other rare etiologies.<sup>23</sup> It is essential to identify any hallmark symptoms such as severe low back pain, saddle anesthesia, urinary retention, bowel or bladder dysfunction, or sexual dysfunction. The most common symptoms are severe back pain and radiculopathy seen in 83% and 90% of cases, respectively. It has been reported that most patients have an objective sensory/motor deficit in the lower extremities and approximately 76% have decreased perineal sensation.

Urinary retention is also commonly seen in about 60% of cases and can be evaluated by obtaining a post-void residual bladder volume. Values of more than 100 milliliters should raise suspicion of urinary retention. Urinary incontinence is similarly seen in about 55% of reports. Erectile dysfunction is uncommon, seen in less than 5% of cases on initial presentation, but has been reported to be a poor prognostic symptom. It is important to assess for rectal tone, as decreased tone would further support the diagnosis of CES.<sup>24</sup> Prompt diagnosis is imperative as failure to diagnose this can result in serious morbidity and increased medicolegal risk.<sup>23</sup>

Even though CES is a rare condition, it has a disproportionately higher frequency of malpractice litigation. This is because patients are often left with a high degree of disability. In a five-year period, Britain's National Health Service cited 24 malpractice claims where 50% of the cases resulted in damages paid with an average payout of \$309,166. The highest settlement was \$2,979,860.<sup>25</sup> In another 2004 study, 48% of finalized cases of CES reported to the Medical Defense Union in the United Kingdom resulted in payment of damages to the claimant with an average settlement of \$549,427 where about half of these cases involved an incorrect or delayed diagnosis.<sup>23</sup> In a third study over five years, 55% of finalized cases of CES reported to the Medical Protection Society resulted in payment of damages to the claimant with an average settlement of \$171,303 per case. The highest settlement was \$852,640.<sup>25</sup>

### **Charting Documentation Errors/Dishonesty**

Case 3 illustrates mistakes and inadequacies related to documentation in the patient chart that can increase liability for the physician. Lawsuits related to documentation are common, playing a role in up to 20% of malpractice cases.<sup>26</sup> One study found that the three most common documentation-related malpractice claims surround missing documentation (70%), inaccurate content (22%), and poor mechanics (18%).<sup>27</sup> Inaccurate content often arises from using templates that automatically populate a normal physical exam or review of systems, or by documenting information that contradicts what

was written by other healthcare clinicians. Cases involving poor mechanics increasingly revolve around transcription errors, resulting in wrong medications or wrong dosages being administered to patients. Lawyers are more likely to pursue litigation when the patient record has low quality documentation as it often provides irrefutable evidence of a mistake.<sup>27</sup>

An anonymous case from Massachusetts provides an example of contradicting patient charts. In this case, a patient presented to the ED with right-sided chest pain and was admitted for pain control after the ED evaluation failed to identify a cause.<sup>28</sup> In the hospital, the patient decompensated, was found to have a spontaneous, chest wall hematoma causing hemorrhagic shock, and subsequently died. The patient's family sued the emergency physician for not diagnosing the patient sooner. The physician tried to argue that the patient looked well with no signs of serious illness in the ED, which is what was documented in his physical exam, but the family's lawyer was able to show that the ED nurse had described the patient as "cool, moist, and mottled." This conflicting description cast doubt on the veracity of the physician's exam, and the patient's family was ultimately awarded \$800,000 in damages. This example illustrates the importance of reviewing other clinicians' notes to find and resolve any potential inconsistencies in the patient chart.

*Perry v. United States* highlights the dangers of altering the medical record.<sup>29</sup> In this case, a five-week-old was brought into the ED twice within the same day with complaints of a fever. The same physician discharged the patient without a thorough infectious workup. On the third visit, the patient was eventually diagnosed with meningitis but suffered permanent neurologic deficits as a result. During court proceedings, it was found that the physician had changed the chart to remove evidence of the patient's fever during the initial visits. The court found the physician at fault and issued a \$20 million verdict, an amount that likely reflected the dishonesty demonstrated by this attempt at alteration. Some medical malpractice policies will not cover physicians if there is evidence of chart alteration, and in some states such behavior could be grounds for losing licensure and negate any caps on damages that would otherwise be applicable. Electronic health systems keep records of all activities within a patient's chart, making this type of behavior easy to detect, and the consequences can be profound. Therefore, it is important to not engage in dishonest charting and to avoid inaccuracies in documentation. Evidence of dishonesty or blatant inaccuracies will ultimately lead to the courts finding the physician liable.

In case 3, the patient presented with severe lower back pain with signs of radiculopathy and was unable to stand. The clinician performed an inadequate history and physical examination and failed to recognize red flag symptoms. The clinician was also dishonest in her report of the length of assessment that was done. A delayed diagnosis in this situation resulted in permanent nerve damage resulting in an unsteady gait, urinary and fecal incontinence, and chronic pain.

After realizing the above information, in the third case, successful litigation may have been avoided if a thorough history and physical examination had been performed. In patients presenting with back pain, a full neurologic examination is essential. Key components of the exam include evaluating for saddle anesthesia, sensation, strength, rectal tone, and examining the patient's gait. Identification of concerning symptoms such as inability to stand, neurologic deficits, and severe pain unresponsive to analgesics should prompt further evaluation. Once CES is suspected, an MRI should be immediately performed.

## CONCLUSION

We have discussed several presentations of back pain and identified the factors that led to a failure to diagnose. In the first case a suboptimal study (CT) was performed, which identified an abnormality thought to be the cause of his symptoms, while missing the diagnosis that ultimately led to significant morbidity. If a spinal epidural abscess is suspected, an MRI of the entire spine should be performed as skip lesions can occur and be found outside the area of maximal pain. In the second case, a patient presented repeatedly with severe back pain requiring opiates for pain control. It is important to remember that repeat visits and severe pain warrant increased scrutiny to ensure the correct diagnosis is not being overlooked and that the care team is not succumbing to anchoring bias. A thorough physical exam would likely have revealed a concerning etiology in both the second and third cases. While prepopulated or templated physical exam notes can be a helpful time saver, they should accurately reflect the examination that was done and not falsify how much time physicians spent with patients. As highlighted by these cases, there is truly no substitute for a thorough history, physical exam, and complete workup in cases of back pain where there are red flag symptoms suggesting a dangerous underlying pathology.

## Take Home Points

- To avoid litigation for spinal epidural abscess and cauda equina syndrome, it should be realized that correct diagnosis is usually made after multiple visits: the key to diagnosis is suspecting it.
- It is imperative to image the entire spine when pursuing the diagnosis of spinal epidural abscess. This is because skip lesions can occur, and abscesses may be found in a separate location other than the site of maximal pain.
- Both spinal epidural abscess and cauda equina syndrome are a favorite litigating diagnosis of malpractice attorneys as they lead to both higher and more frequent awards.
- Clinicians must have a high index of suspicion as spinal epidural abscess and cauda equina often masquerade as musculoskeletal back pain and do not always present in a classic fashion.



- It is very difficult for a medical-legal defendant to be successful in a verdict when it has been discovered that they have been dishonest

---

**Address for Correspondence:** Samuel Isais Garcia, MD, Mayo Clinic, Department of Emergency Medicine, 200 First St. SW, Rochester, MN 55905. Email: [garcia.samuel@mayo.edu](mailto:garcia.samuel@mayo.edu)

**Conflicts of Interest:** By the CPC-EM article submission agreement, all authors are required to disclose all affiliations, funding sources and financial or management relationships that could be perceived as potential sources of bias. The authors disclosed none.

**Copyright:** © 2022 Garcia. This is an open access article distributed in accordance with the terms of the Creative Commons Attribution (CC BY 4.0) License. See: <http://creativecommons.org/licenses/by/4.0/>

---

## REFERENCES

1. *Anonymous v Anonymous*. Medical Malpractice: Verdicts, Settlements, and Experts. V35 N9 September 2019 p6.
2. *Wilson v Abington Hospital*. Medical Malpractice: Verdicts, Settlements, and Experts. V37 N7 July 2021 p4.
3. *Amy Cook and Jason Cook v Betty Agbede*, MD, Emergency Medical Professionals, P.A. and Memorial Hospital -West Volusia, Inc. d/b/a Florida Hospital-Deland Volusia County Circuit Court Case No. 2017-30063-CICI.
4. Shantharam G, DePasse JM, Eitorai AEM, et al. Physician and patient factors associated with outcome of spinal epidural abscess related malpractice litigation. *Orthop Rev (Pavia)*. 2018;10(3):7693.
5. Vakili M and Crum-Cianflone NF. Spinal epidural abscess: a series of 101 cases. *Am J Med*. 2017;130(12):1458-63.
6. Sendi P, Bregenzer T, Zimmerli W. Spinal epidural abscess in clinical practice. *QJM*. 2008;101(1):1-12.
7. Danner RL and Hartman BJ. Update on spinal epidural abscess: 35 cases and review of the literature. *Rev Infect Dis*. 1987;9(2):265-74.
8. Gellin BG, Weingarten K, Gamache FW Jr, et al. (1997). Epidural abscess. In: *Infections of the Central Nervous System*, 2nd Ed, Scheld WM, Whitley RJ, Durack DT (Eds). Lippincott-Raven Publishers: Philadelphia.
9. Nussbaum ES, Rigamonti D, Standiford H, et al. Spinal epidural abscess: a report of 40 cases and review. *Surg Neurol*. 1992;38(3):225-31.
10. Bond A and Manian FA. Spinal epidural abscess: a review with special emphasis on earlier diagnosis. *Biomed Res Int*. 2016;2016:1614328.
11. Chen WC, Wang JL, Wang JT, et al. Spinal epidural abscess due to *Staphylococcus aureus*: clinical manifestations and outcomes. *J Microbiol Immunol Infect*. 2008;41(3):215-21.
12. Curry WT Jr, Hoh BL, Amin-Hanjani S, et al. Spinal epidural abscess: clinical presentation, management, and outcome. *Surg Neurol*. 2005;63(4):364-71.
13. Davis DP, Salazar A, Chan TC, et al. Prospective evaluation of a clinical decision guideline to diagnose spinal epidural abscess in patients who present to the emergency department with spine pain. *J Neurosurg Spine*. 2011;14(6):765-70.
14. Reihnsaus E, Waldbaur H, Seeling W. Spinal epidural abscess: a meta-analysis of 915 patients. *Neurosurg Rev*. 2000;23(4):175-205.
15. Rigamonti D, Liem L, Wolf AL, et al. Epidural abscess in the cervical spine. *Mt Sinai J Med*. 1994;61(4):357-62.
16. Pradilla G, Ardila GP, Hsu W, et al. Epidural abscesses of the CNS. *Lancet Neurol*. 2009;8(3):292-300.
17. Wong D and Raymond NJ. Spinal epidural abscess. *N Z Med J*. 1998;111(1073):345-7.
18. Darouiche RO, Hamill RJ, Greenberg SB, et al. Bacterial spinal epidural abscess. Review of 43 cases and literature survey. *Medicine (Baltimore)*. 1992;71(6):369-85.
19. Moseley IF and Kendall BE. Radiology of intracranial empyemas, with special reference to computed tomography. *Neuroradiology*. 1984;26(5):333-45.
20. Sendi P, Bregenzer T, Zimmerli W. Spinal epidural abscess in clinical practice. *QJM*. 2008;101(1):1-12.
21. Tuchman A, Pham M, Hsieh PC. The indications and timing for operative management of spinal epidural abscess: literature review and treatment algorithm. *Neurosurg Focus*. 2014;37(2):E8.
22. Wong KE, Parikh PD, Miller KC, et al. Emergency department and urgent care medical malpractice claims 2001-15. *West J Emerg Med*. 2021;22(2):333-8.
23. Fraser S, Roberts L, Murphy E. Cauda equina syndrome: a literature review of its definition and clinical presentation. *Arch Phys Med Rehabil*. 2009;90(11):1964-8.
24. Gitelman A, Hishmeh S, Morelli BN, et al. Cauda equina syndrome: a comprehensive review. *Am J Orthop (Belle Mead NJ)*. 2008;37(11):556-62.
25. Gardner A, Gardner E, Morley T. Cauda equina syndrome: a review of the current clinical and medico-legal position. *Eur Spine J*. 2011;20(5):690-7.
26. Cohn S. (1974-2021) Medical malpractice - use of hospital records. In: *American Jurisprudence Proof of Facts* 2d.
27. Risk Management Tools & Resources. The Role of Documentation in Diagnosis-Related Malpractice Allegations | MedPro Group. <https://www.medpro.com/documentation-dx-allegations>. Accessed April 14, 2021.
28. *Plaintiff v. Defendant*, MA, 2006.
29. Perry Austin, Jr., by and through *Tiffanie Bennett vs. The United States*, 02 ACTR 11-35.

# Point-of-care Ultrasound for the Evaluation of Acute Arterial Pathology in the Emergency Department: A Case Series

Aaran Drake, MD  
Nicholas Dreyer, MD  
Megan Hoffer, DO  
Keith Boniface, MD

The George Washington University School of Medicine and Health Sciences,  
Department of Emergency Medicine, Washington, DC

Section Editor: Austin Smith, MD

Submission History: Submitted September 28, 2021; Revision received November 19, 2021; Accepted November 30, 2021

Electronically published January 28, 2022

Full text available through open access at [http://escholarship.org/uc/uciem\\_cpccem](http://escholarship.org/uc/uciem_cpccem)

DOI: 10.5811/cpcem.2021.11.54904

**Introduction:** The use of point-of care ultrasound (POCUS) in the evaluation of vascular emergencies including abdominal aortic aneurysm and deep vein thrombosis is well established. However, no current guidelines exist to outline the use of POCUS in the management of acute peripheral arterial pathology.

**Case Series:** Here, we present a case series that illustrates the utility of POCUS in the assessment of both traumatic and nontraumatic peripheral arterial disease. Direct visualization of the vasculature via B-mode, color Doppler, and pulsed-wave Doppler assisted in the diagnosis of the following: 1) an acute, post-catheterization thrombus of the proximal radial artery; 2) a complete, traumatic radial artery transection; 3) a forearm hematoma with active arterial extravasation; 4) a traumatic arteriovenous fistula; 5) an acute thrombosis of an artery bypass graft; and 6) an infected pseudoaneurysm.

**Conclusion:** The incorporation of POCUS into patient care allowed for rapid identification of significant peripheral arterial pathology and led to changes in clinical management, expedited patient care, and circumvented potentially harmful complications. [Clin Pract Cases Emerg Med. 2022;6(1):13-19.]

**Keywords:** *arterial ultrasound; emergency department; point-of-care ultrasound.*

---

## INTRODUCTION

The use of point-of-care ultrasound (POCUS) has expanded greatly since the introduction of the focused assessment with sonography for trauma exam.<sup>1</sup> The American College of Emergency Physicians' Emergency Ultrasound Guidelines include indications for POCUS such as trauma, pregnancy, cardiac and hemodynamic assessment, soft tissue infection, musculoskeletal injury, hepatobiliary and gastrointestinal pathology, ocular assessment, genitourinary complaints, and procedural guidance.<sup>2</sup> Other well-established indications for POCUS include vascular emergencies such as abdominal aortic aneurysm (AAA) and deep vein thrombosis (DVT). With sensitivity and specificity values approaching 100% for the detection of AAA and similar values for DVTs (95% and 96%, respectively), POCUS has been established as

a highly effective imaging modality in the rapid assessment of vascular pathology.<sup>3-8</sup>

Despite the efficacy of POCUS in these vascular emergencies, currently no published guidelines exist that outline the use of POCUS in the assessment and management of peripheral arterial pathology. Current practice for the rapid assessment of arterial pathology, both traumatic and non-traumatic, includes obtaining a history, physical examination, ankle-brachial index, and handheld (continuous-wave) Doppler evaluation. However, given the documented utility of POCUS in the real-time evaluation of other vascular pathology, hemodynamic assessment, and procedural guidance (eg, vascular access), it would likely prove to be extremely beneficial in the diagnosis of peripheral arterial emergencies as well.



In this case series, we aim to demonstrate the value of POCUS in the early detection of acute peripheral arterial disease within the emergency department (ED). Through the clinical cases outlined below, we illustrate instances in which the use of POCUS revealed significant arterial pathology that ultimately changed clinical management, facilitated specialist consultation, and expedited definitive care.

## CASE SERIES

### Case 1

A 56-year-old female with a past medical history of diabetes mellitus, hypertension, and hyperlipidemia presented to the ED with three days of right wrist pain that began on her way home following a cardiac catheterization via her right radial artery. The pain was described as severe, constant, radiating to her right forearm and shoulder, and 10/10 in severity. It was painful to move and tender to palpation but was improved by rest and acetaminophen. The patient denied any redness, swelling, tingling, numbness, or paresthesia.

On physical examination, she had a blood pressure (BP) of 144/77 millimeters of mercury (mm Hg), heart rate (HR) of 87 beats per minute (bpm), and she was afebrile. She was in no acute distress. Her right hand was warm, appeared symmetric to her left hand, and had no edema. She had tenderness to palpation over the right lateral forearm. Her right radial artery pulse was not palpable distal to the puncture site. All other pulses including the lower limb pulses were palpable bilaterally. Neurologic examination demonstrated mild subjective sensory loss over the right radial and median nerves distributions with no motor deficits.

Basic laboratory investigation and electrocardiography were normal. A POCUS of the right upper extremity arterial vasculature was performed given concern for vascular compromise. The distal portions of the right brachial artery, including its bifurcation into the radial and ulnar arteries were patent with normal flow, as was the entire right ulnar artery. However, we found clear sonographic evidence of an occlusive thrombus in the distal right radial artery, just proximal to the access site (Image 1a). There was no apparent flow within the proximal and mid portions of the radial artery due to outflow occlusion (Image 1b). Minimal retrograde flow was noted in the right ulnar artery distal to the access site—likely supplied by the palmar arch.

The interventional cardiology and interventional radiology services were consulted. Supported by the sonographic evidence of an acute arterial thrombus, along with evidence of perfusion of the hand via collateral flow, the involved services made a collaborative recommendation to begin anticoagulation with supportive therapy. The patient was started on enoxaparin and oral analgesia as conservative management for three months, with follow-up scheduled one week from the start of her therapy.

Diagnosis: Acute post-procedural thrombus of the proximal radial artery.

### CPC-EM Capsule

What do we already know about this clinical entity?

*Point-of-care ultrasound (POCUS) is a useful diagnostic tool in the identification of acute arterial pathology and vascular emergencies in the Emergency Department.*

What makes this presentation of disease reportable?

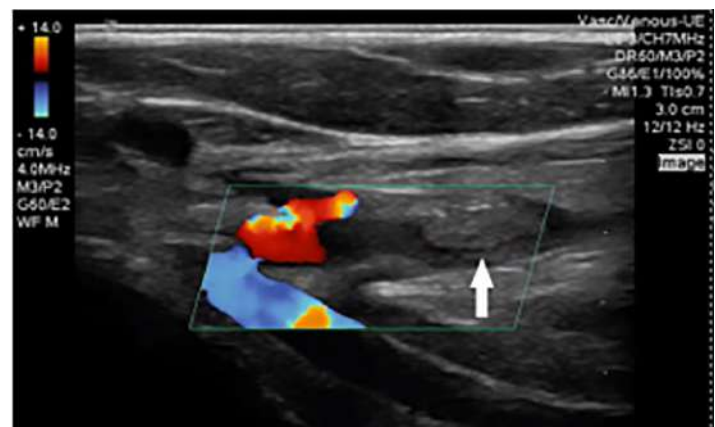
*Despite the efficacy of POCUS in vascular emergencies such as abdominal aortic aneurysm, currently no published guidelines exist which outline the use of POCUS in the assessment and management of peripheral arterial pathology.*

What is the major learning point?

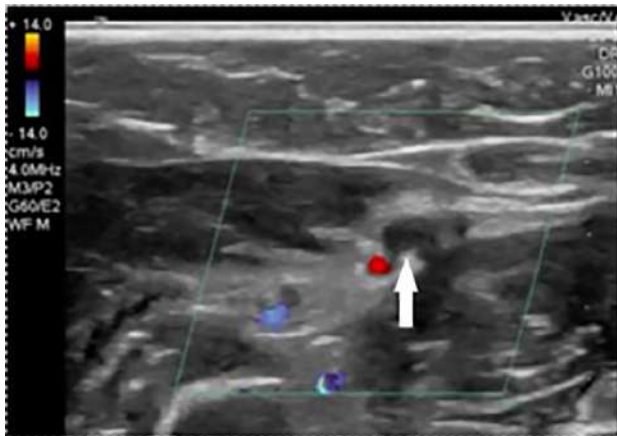
*This case series illustrates the utility of POCUS for the diagnosis of several peripheral arterial emergencies, including arteriovenous fistula, pseudoaneurysm, and arterial thrombus.*

How might this improve emergency medicine practice?

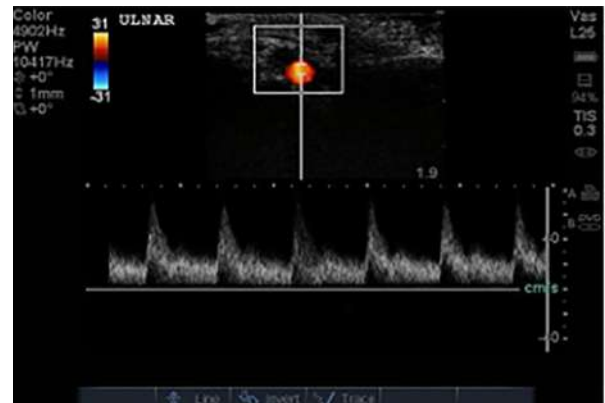*Given the documented utility of POCUS in the real-time evaluation of other vascular pathology, hemodynamic assessment, and procedural guidance (eg, vascular access), it would likely prove to be extremely beneficial in the diagnosis of peripheral arterial emergencies as well.*



**Image 1a.** Longitudinal view of the distal brachial artery at the bifurcation into ulnar artery (deep, blue) and radial artery (superficial, red). Note the occlusive thrombus to the right of the color flow just distal to the origin of the radial artery (arrow).



**Image 1b.** A transverse image through the distal radial artery (arrow) with absence of flow.



**Image 2a.** A transverse view of the ulnar artery obtained with the transducer tilted toward the patient's proximal arm. Color Doppler and pulsed-wave Doppler reveal normal velocity anterograde flow (toward the probe face, displayed as red on color Doppler and as positive deflection above the baseline on pulsed-wave Doppler).

## Case 2

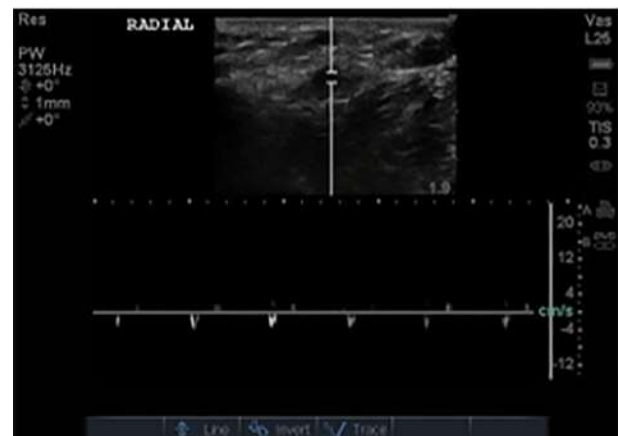A 45-year-old right hand dominant male with no significant past medical history presented to the ED after sustaining a power saw injury to the volar surface of his right forearm. While he was cutting overhead, the saw unexpectedly recoiled, striking his face and arm. Prior to transport, bleeding was controlled by emergency medical services (EMS) personnel using direct pressure. There were no hard or soft signs of vascular injury reported by EMS personnel.

Upon arrival to the ED, the patient had a BP of 130/87 mm Hg, HR of 76 bpm, temperature of 98° Fahrenheit, and an oxygen saturation (SpO<sub>2</sub>) of 96% on room air as measured on the right arm. Initial assessment revealed a four-centimeter (cm) gaping, oblique laceration through the volar aspect of his right forearm with no active hemorrhage. The patient was able to move all digits, but there was weakness of flexion of the second through fourth digits that localized to the flexor digitorum superficialis for the second through fourth digits; in addition, the flexor carpi radialis was compromised. The remainder of tendons were intact. Vascular assessment revealed a 2+ palpable pulse in the ulnar artery with no palpable radial pulse. The vascular surgery service was consulted and, using a handheld Doppler, demonstrated pulsatile flow in the radial artery.

Given the evidence of pulsatile flow with conventional handheld Doppler evaluation, the initial treatment plan was for operative repair of the tendon injuries by orthopedic surgery. However, POCUS revealed anterograde flow within the ulnar artery (Image 2a) but retrograde flow through the distal radial artery, indicating filling via the palmar arches due to radial artery interruption (Image 2b).

With this new sonographic finding, the patient was taken to the operating room (OR) for a joint vascular and orthopedic surgical operation involving saphenous vein grafting of the right radial artery in addition to the originally planned tendon repair.

Diagnosis: Complete arterial transection of the radial artery.



**Image 2b.** A transverse view of the radial artery distal to the injury site obtained with the transducer tilted toward the patient's proximal arm. Color Doppler reveals minimal flow, and pulsed-wave Doppler demonstrates low velocity retrograde flow (away from the probe face, displayed as a negative deflection below the baseline), indicating flow originating from the palmar arch.

## Case 3

A 60-year-old female with history of hypertension, hyperparathyroidism, generalized anxiety disorder, and left-sided total knee replacement (complicated by left lower extremity DVT two months prior, treated with enoxaparin and warfarin) presented to the ED with three days of right forearm pain and swelling. The pain was sudden onset and a 10/10 in severity. There was associated numbness and weakness of the right hand. Her pain was worsened with movement and relieved by placing her right hand and wrist in a flexed position.

Two days prior to her presentation, she had been evaluated at an outside hospital and discharged home with seven days of trimethoprim/sulfamethoxazole for a presumptive diagnosis of cellulitis. A right upper-extremity venous duplex ultrasound

performed during that evaluation revealed no evidence of DVT.

On physical examination, the patient had a BP of 127/84 mm Hg, HR of 89 bpm, SpO<sub>2</sub> of 100% on room air, and was afebrile. Her right hand and wrist were held in a flexed position, and pain was elicited with passive extension of her right second, third, and fourth digits. There was a noticeable area of swelling with overlying ecchymosis at the distal, volar aspect of her right forearm. The area of swelling was tense and tender to palpation.

Labs were significant for an international normalized ratio of 1.9 (reference range: 0.8- 1.1) but were otherwise unremarkable. A right upper-extremity computed tomography (CT) was obtained and identified evidence of an intramuscular hematoma within the anterior compartment of the forearm. However, the study was limited by artifact, and confirmation with ultrasound was recommended by the reading radiologist. Point-of-care ultrasound revealed pulsatile flow concerning for active extravasation at the site of a layering hematoma (Images 3a and 3b). The patient subsequently underwent ultrasound by the

department of radiology, which re-identified a large hematoma in the anterior forearm with evidence of internal pulsatile flow at the level of the patient's wrist, compatible with active internal hemorrhage or the possibility of pseudoaneurysm.

Following these radiographic findings, the patient was admitted by orthopedic surgery for neurovascular assessments every two hours with a low threshold for surgical intervention due to concern for impending compartment syndrome. Upon admission, her enoxaparin and warfarin were held, and internal medicine was consulted for updated anti-coagulation recommendations. With forearm compression and elevation, the patient symptomatically improved overnight and was discharged the following morning. Anti-coagulation recommendations from the internal medicine service included cessation of warfarin and continuation of enoxaparin for one additional month to complete her three-month treatment regimen for provoked DVT.

Diagnosis: Forearm hematoma with active arterial extravasation.

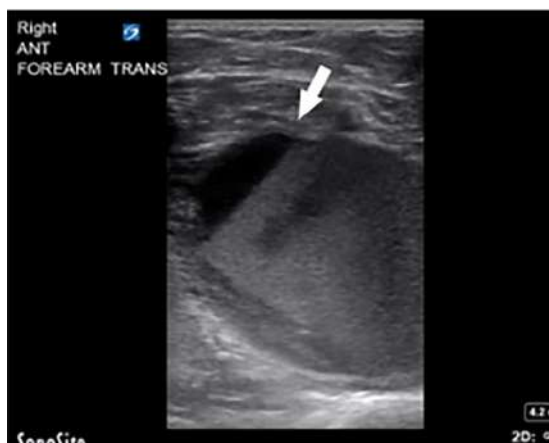#### Case 4

A 65-year-old female with a history of intravenous drug use presented to the ED with complaints of left forearm swelling. The patient stated that this swelling began recently in the area where she normally injects heroin. She reported having similar lesions in the past, which had always been “drained or cut out.” On physical examination, the patient was afebrile with a BP of 144/102 mm Hg, HR of 65 bpm, respiratory rate of 18 breaths per minute, and SpO<sub>2</sub> 99% on room air. There was a four-cm area of fluctuance over the radial aspect of the distal left forearm with multiple overlying injection sites linearly aligned. The area was absent of erythema, ecchymosis, bleeding, or drainage. Distal pulses were intact, and no sensory changes were present.

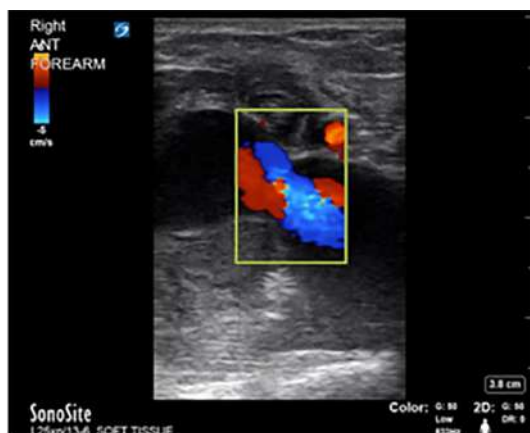
Given the presence of fluctuance, the treatment team considered an incision and drainage, but performed POCUS of the lesion prior to intervention. The POCUS revealed a large, vascular-appearing, hypoechoic structure with surrounding cobblestoning, initially concerning for thrombophlebitis of the cephalic vein (Image 4a). Upon application of color Doppler, evidence of arterial flow pulsating in the cephalic vein and distending the vein was identified, suggesting an arteriovenous fistula, which became evident on both the transverse (Image 4b and 4d) and longitudinal (Image 4c) views.

With sonographic evidence of a traumatic arteriovenous fistula—as opposed to a suspected abscess—a potentially harmful bedside incision and drainage was avoided. Instead, the patient was scheduled to undergo CT angiography (CTA) to further characterize this vascular pathology, and plan for appropriate intervention; however, she eloped prior to CTA and vascular surgery consultation.

Diagnosis: Traumatic arteriovenous fistula of the forearm.

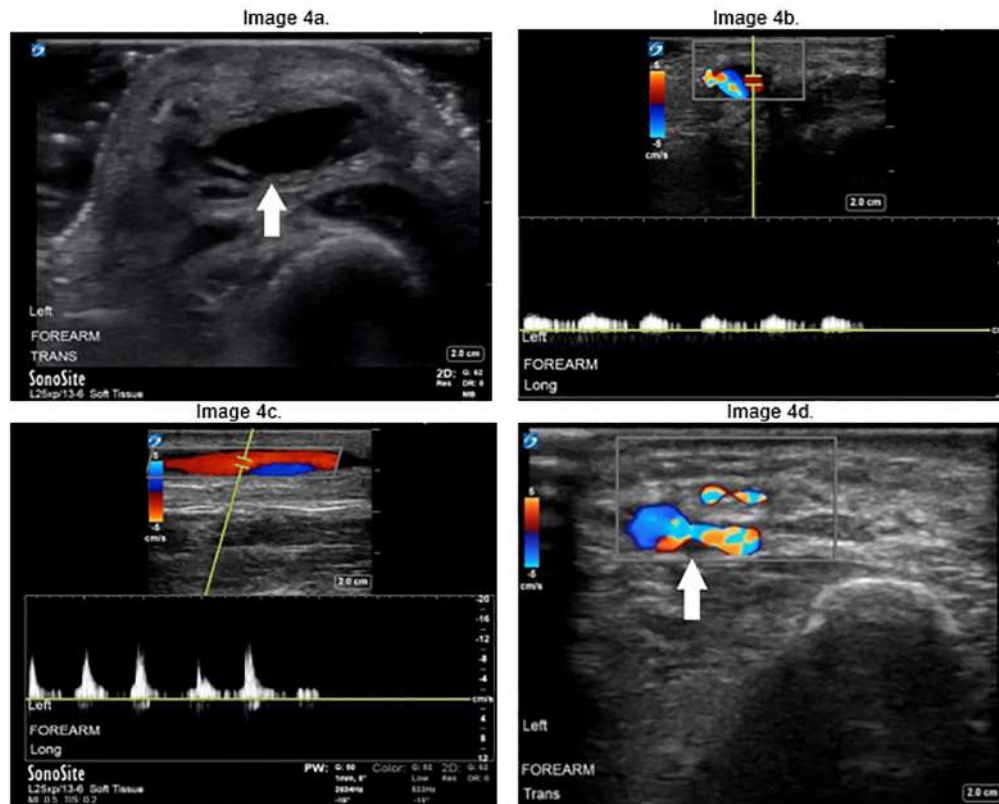


**Image 3a.** Transverse view of the mid-volar forearm demonstrates an echogenic fluid collection with fluid-debris level (arrow) consistent with a layering hematoma.



**Image 3b.** Color Doppler shows pulsatile flow into the hematoma.





**Image 4.** Transverse (a) view of the radial aspect of the distal forearm shows an enlarged cephalic vein (arrow) with surrounding cobblestoning. Transverse (b) and longitudinal (c) views of the cephalic vein demonstrate pulsatile flow in the vein, consistent with arteriovenous fistula; (d) Scanning distally along the cephalic vein with color Doppler demonstrates area of connection (arrow) between the radial artery (left) and vein (right).

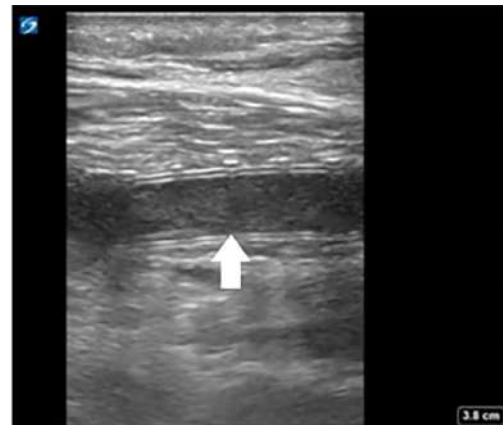### Case 5

A 56-year-old male with past medical history of coronary artery disease, hypertension, type 2 diabetes, and peripheral artery disease presented to the ED with two days of right foot numbness and coolness. His symptoms began the morning following his discharge from the intensive care unit (ICU) three days prior after undergoing a right lower extremity thromboemblectomy of his femoral-posterior tibial graft. Prior to this procedure, the patient had several previous revascularizations of the same extremity. He had been discharged on warfarin, aspirin and clopidogrel, and endorsed compliance with this regimen.

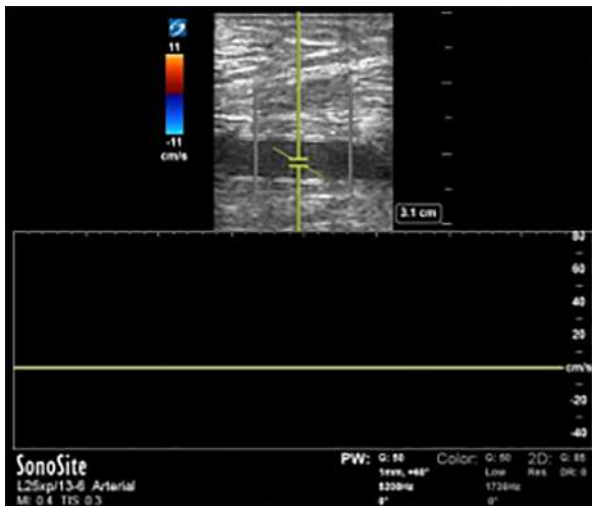
On physical examination, the patient was afebrile with a BP of 122/75 mm Hg, HR of 98 bpm, respiratory rate of 16 breaths per minute, and SpO<sub>2</sub> 100% on room air. His distal right lower extremity was cool to the touch, and neither the dorsal pedis nor the posterior tibial arteries could be palpated. Capillary refill was greater than three seconds and handheld Doppler evaluation revealed no pulse. Both sensation and range of motion of the limb were intact. His left lower extremity exam was normal.

Point-of-care ultrasound was performed and revealed extensive clot burden within the bypass graft with no detectable blood flow (Images 5a and 5b).

Based on these findings the vascular surgeon recommended direct admission to the OR without any need for further imaging. The patient underwent emergent thrombectomy and alteplase thrombolytic therapy of his right lower extremity. After several days of close observation in the ICU, he was discharged with close outpatient follow-up, avoiding amputation of his limb.



**Image 5a.** Longitudinal view of patient's femoral-posterior tibial graft (arrow) demonstrating echogenic thrombus inside.



**Image 5b.** Color Doppler and pulsed-wave Doppler show no flow in this segment of thrombosed graft.

Diagnosis: Acute thrombosis of femoral-posterior tibial artery bypass graft.

### Case 6

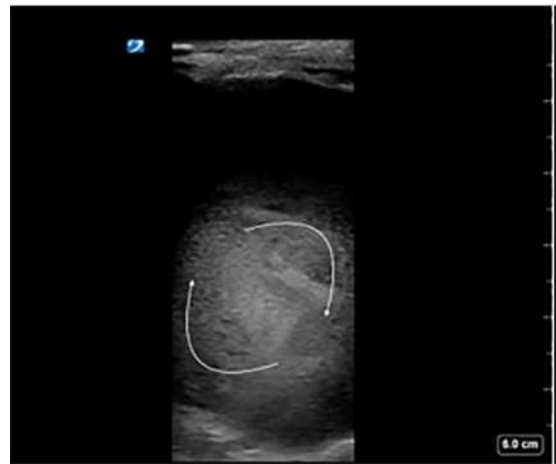A 48-year-old male with history of intravenous drug use, deep vein thrombosis, and multiple prior soft tissue abscesses, was transferred from an outside hospital due to concern for compartment syndrome. He had undergone CT at the outside hospital, which identified an upper arm abscess. He had been having symptoms of pain, swelling, and numbness of his hand for about a week. He had not been on anticoagulation.

On physical examination at our institution, the patient was afebrile with a BP of 169/91 mm Hg, HR of 89 bpm, respiratory rate of 18 breaths per minute, and SpO<sub>2</sub> 100% on room air. Laboratory studies from the outside facility were significant for a hemoglobin of 4.7 grams per deciliter (g/dL) (reference range: 13.5-17.5 g/dL). He had a diminished radial pulse with a normal motor examination of his upper extremity. There was an upper arm wound draining seropurulent material.

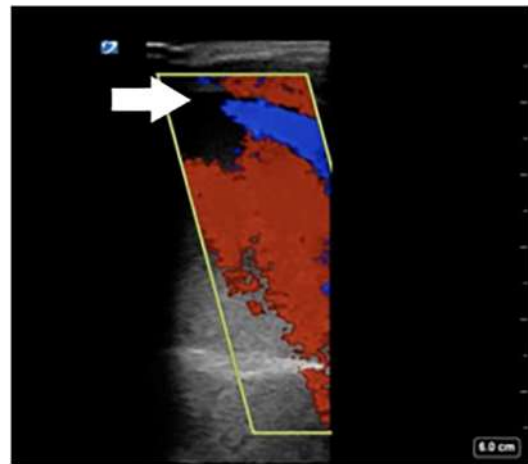
Point-of-care ultrasound of the area described by CT as an abscess demonstrated turbulent swirling flow, concerning for pseudoaneurysm (Images 6a and 6b). The vascular surgery service was consulted and, given the presence of bloody drainage, took the patient emergently to the OR for incision and drainage of a distal brachial artery infected pseudoaneurysm and vein patch repair using a brachial vein patch.

### DISCUSSION

In the evaluation of arterial injury and/or occlusion, catheter-directed angiography has traditionally been the “gold standard” imaging modality of choice. However, both the costly and invasive nature of angiography as well as the potential need to call in a specialist from home has



**Image 6a.** B-mode imaging of the distal medial upper arm revealed a heterogeneous circular collection with demonstration of swirling of contents.



**Image 6b.** Color Doppler demonstrates swirling clockwise flow (arrow).

led to a shift in clinical practice favoring less invasive methods of vascular evaluation.<sup>9,10</sup> With improvements in CT technology, CTA is becoming the test of choice for evaluating arterial pathology. This change has become particularly evident within the ED setting due to its general availability and relatively fast turnaround times. However, CTA also carries inherent risks to the patient including radiation exposure, potential adverse reactions to intravenous contrast, and transport out of the ED.

The application of ultrasound in the assessment of peripheral arterial disease is an established technique that has been shown to provide comparable results to that of arteriography.<sup>11,12</sup> Furthermore, its utility in rapidly identifying vascular trauma within the ED setting has also been shown.<sup>13-15</sup> Radiology-performed ultrasound spares the patient the radiation exposure of CTA but is not available at all times in all EDs.

Point-of-care ultrasound avoids the risks of CTA while still providing vital clinical information in the evaluation of arterial injury and ischemia, and it can be performed at the patient's bedside. Like the handheld, continuous-wave Doppler device, POCUS provides information regarding the presence and relative speed of flow. However, it is also able to provide information on the direction of flow, measure flow velocities, and display real-time visualization of the anatomy under investigation. This additional information is easy to obtain by emergency physicians with minimal training (which is not currently standard in emergency medicine residencies). By using POCUS, emergency physicians can expedite the evaluation of a patient, decreasing time to consultation and definitive treatment.

## CONCLUSION

In this series we present several cases that illustrate the utility of POCUS in the assessment of both traumatic and nontraumatic peripheral arterial disease. The incorporation of POCUS into patient care allowed for rapid identification of significant peripheral arterial pathology, led to changes in clinical management, expedited patient care, and circumvented potentially harmful complications. Thus, we argue that POCUS evaluation of peripheral arteries should replace the use of handheld (non-imaging) Doppler devices due to the additional information provided (direction of flow and B-mode image of underlying structures). Point-of-care ultrasound of peripheral arteries, and the optimization of color and pulsed-wave Doppler waveforms, should be a standard component of training for emergency physicians.

The authors attest that their institution requires neither Institutional Review Board approval, nor patient consent for publication of this case report. Documentation on file.

---

*Address for Correspondence:* Aaran Drake, MD, The George Washington University School of Medicine and Health Sciences, Department of Emergency Medicine, 900 23rd St NW, Washington, DC 20037. Email: [adrake@mfa.gwu.edu](mailto:adrake@mfa.gwu.edu).

*Conflicts of Interest:* By the CPC-EM article submission agreement, all authors are required to disclose all affiliations, funding sources and financial or management relationships that could be perceived as potential sources of bias. The authors disclosed none.

*Copyright:* © 2022 Drake. This is an open access article distributed in accordance with the terms of the Creative Commons Attribution (CC BY 4.0) License. See: <http://creativecommons.org/licenses/by/4.0/>

---

## REFERENCES

1. Kendall JL, Hoffenberg SR, Smith RS. History of emergency and critical care ultrasound: the evolution of a new imaging paradigm. *Crit Care Med*. 2007;35(5 Suppl):S126-S130.
2. Ultrasound Guidelines: Emergency, Point-of-Care and Clinical Ultrasound Guidelines in Medicine. *Ann Emerg Med*. 2017;69(5):e27–e54.
3. Kuhn M, Bonnin RL, Davey MJ, et al. Emergency department ultrasound scanning for abdominal aortic aneurysm: accessible, accurate, and advantageous. *Ann Emerg Med*. 2000;36(3):219-23.
4. Tayal VS, Graf CD, Gibbs MA. Prospective study of accuracy and outcome of emergency ultrasound for abdominal aortic aneurysm over two years. *Acad Emerg Med*. 2003;10(8):867-71.
5. Rubano E, Mehta N, Caputo W, et al. Systematic review: emergency department bedside ultrasonography for diagnosing suspected abdominal aortic aneurysm. *Acad Emerg Med*. 2013;20(2):128-38.
6. Burnside PR, Brown MD, Kline JA. Systematic review of emergency physician-performed ultrasonography for lower-extremity deep vein thrombosis. *Acad Emerg Med*. 2008;15(6):493-8.
7. Pomeroy F, Dentali F, Borretta V, et al. Accuracy of emergency physician-performed ultrasonography in the diagnosis of deep-vein thrombosis: a systematic review and meta-analysis. *Thromb Haemost*. 2013;109(1):137-45.
8. Jang T, Docherty M, Aubin C, et al. Resident-performed compression ultrasonography for the detection of proximal deep vein thrombosis: fast and accurate. *Acad Emerg Med*. 2004;11(3):319-22.
9. Miller-Thomas MM, West OC, Cohen AM. Diagnosing traumatic arterial injury in the extremities with CT angiography: pearls and pitfalls. *Radiographics*. 2005;25 Suppl 1:S133-42.
10. Allie DE, Patlola RR, Ingraldi A. Peripheral vascular CTA: Emerging role of PV-CTA in the therapeutic management of PVD. *Appl Radiol*. 2008; 37(4).
11. Legemate DA, Teeuwen C, Hoeneveld H, et al. The potential of duplex scanning to replace aorto-iliac and femoropopliteal angiography. *Eur J Vasc Surg* 1989;3(1):49-54.
12. London NJ, Sensier Y, Hartshorne T. Can lower limb ultrasonography replace arteriography? *Vasc Med*. 1996;1(2):115-9.
13. Montorfano MA, Montorfano LM, Perez Quirante F, et al. The FAST D protocol: a simple method to rule out traumatic vascular injuries of the lower extremities. *Crit Ultrasound J*. 2017;9(1):8.
14. Montorfano MA, Pla F, Vera L, et al. Point-of-care ultrasound and Doppler ultrasound evaluation of vascular injuries in penetrating and blunt trauma. *Crit Ultrasound J*. 2017;9(1):5.
15. Villarreal NA, Wagner W, Schoenfeld E. Occult vascular transection identified by point-of-care ultrasound demonstrating evidence of retrograde flow. *Clin Pract Cases Emerg Med*. 2019;3(4):372-5.



# Fatal Abdominal Compartment Syndrome Due to Constipation: A Case Report

**Matthew M. Kongkatong, MD**  
**Malav M. Patel, MD**  
**Christopher Thom, MD**  
**James Moak, MD**

University of Virginia Medical Center, Department of Emergency Medicine,  
Charlottesville, Virginia

Section Editor: Jacqueline Le, MD

Submission History: Submitted May 19, 2021; Revision received July 27, 2021; Accepted July 26, 2021

Electronically published January 4, 2022

Full text available through open access at [http://escholarship.org/uc/uciem\\_cpccem](http://escholarship.org/uc/uciem_cpccem)

DOI: 10.5811/cpccem.2021.7.53295

**Introduction:** Abdominal compartment syndrome (ACS) is a rare condition in which increased intra-abdominal pressure causes multiorgan dysfunction through decreased perfusion. Causes of this condition are variable, and early recognition is critical for favorable patient outcomes. Measurement of bladder pressure is recommended for diagnosis.

**Case Report:** A 64-year-old female on clozapine with a two-year history of chronic constipation presented to the emergency department in extremis with a protuberant abdomen. After resuscitative measures, computed tomography showed a dilated, stool-filled colon with a decompressed inferior vena cava and decreased perfusion. She died despite surgical decompression.

**Conclusion:** Severe constipation is a rare cause of ACS, and there is a lack of evidence-based guidelines. Options for bedside decompression are limited. To reduce morbidity and mortality in this population, early recognition of ACS is imperative. Initial interventions should support hemodynamics and respiration. Definitive management is surgical decompression. [Clin Pract Cases Emerg Med. 2022;6(1):20-24.]

**Keywords:** *abdominal compartment syndrome; constipation; case report; clozapine; surgical decompression.*

---

## INTRODUCTION

Abdominal compartment syndrome (ACS) is defined as organ dysfunction caused by an increase in intra-abdominal pressure greater than 20 millimeters of mercury (mm Hg). It is a rare condition that is more common in critically ill patients. The reported incidence of this condition ranges from 1-14% in studies of trauma patients and 12% in a study of patients with severe pancreatitis.<sup>1,2</sup> High intra-abdominal pressure leads to compromised global and regional perfusion, resulting in life-threatening organ dysfunction. Abdominal compartment syndrome can cause reduction of respiratory volumes through mass effect on the diaphragm with resultant hypercarbia and hypoxemia. It can also cause metabolic acidosis, diastolic failure, increased intracranial pressure, oliguria, intracranial hypertension, and intestinal ischemia.<sup>3</sup>

The World Society of the Abdominal Compartment Syndrome (WSACS) categorizes this disorder by its underlying cause: decreased abdominal compliance (eg, burns); increased intra-abdominal contents (eg, hemoperitoneum, ascites); increased intraluminal contents (eg, intestinal volvulus, ileus, and constipation); capillary leak/fluid resuscitation; and miscellaneous causes such as obesity and peritonitis.<sup>4</sup> Constipation, although a rare cause of ACS, is a common condition in older adults with a prevalence of 24-50%.<sup>5</sup> Morbidity and mortality from ACS can be mitigated by timely surgical decompression with careful anticipation of reperfusion syndrome.

## CASE REPORT

A 64-year-old female with a history of chronic constipation and schizoaffective disorder on clozapine,

risperidone, benztropine, and glycopyrrolate presented to the emergency department via emergency medical services (EMS) for a chief complaint of altered mental status concerning for acute stroke. The EMS personnel noted she was found by her boyfriend with slurred speech, left-sided weakness, and a severely distended abdomen. On first assessment she was obtunded and in shock with a heart rate of 131 beats per minute and blood pressure of 60/40 mm Hg. Oxygen saturation could not be obtained via skin probe, and respirations were 31 breaths per minute. She was hypothermic at 34.8 degrees Celsius. Her abdomen was grossly distended and tense with dullness to percussion in all quadrants. The patient was unable to provide any history but review of the electronic health record showed that she had a history of severe constipation and had seen her primary physician two weeks prior for the same complaint.

Femoral central access was obtained after three attempts with the first two attempts complicated by lack of blood return from the catheter after passage over the guidewire, which was misinterpreted as line misplacement. Point-of-care ultrasound demonstrated normal compression of the common femoral veins at both sites. Initial point-of-care blood testing showed a severe metabolic acidosis with pH of 6.36 and a lactic acid of 21.9 millimoles per liter (mmol/L) (reference range: 0.5-1.0 mmol/L) as well as profound anemia with a hemoglobin level of 3.7 grams per deciliter (g/dL) (reference range: 12.0-15.5 g/dL). Her creatinine level measured at 1.3 milligrams per deciliter (mg/dL), (reference range: 0.6-1.1 mg/dL) which was increased from her baseline of 0.9 mg/dL.

In total, she received two liters of 0.9% saline, three units of packed red cells, and two units of fresh frozen plasma without improvement of hemodynamics. A norepinephrine infusion was then initiated with improvement of blood pressure to 128/78 mm Hg. After improvement of hemodynamics the patient was intubated. Cefepime and metronidazole were given for presumed intra-abdominal sepsis. She also received a total of 250 milliliters (mL) of 8.4% sodium bicarbonate with improvement of her acidosis from pH 6.36 to pH 7.33. Her hyperkalemia of 7.8 mmol/L (reference range: 3.4-4.8 mmol/L) improved with fluids and sodium bicarbonate to 5.2 mmol/L. A forced-air warming device was applied to the patient after intubation.

Point-of-care ultrasound revealed no intra-abdominal fluid. Supine chest radiography (Image 1) performed after intubation showed low lung volumes with a massively dilated colon. General surgery was consulted for acute abdomen, and additional imaging was obtained once her hemodynamics stabilized. Computed tomography (CT) of the head showed no intracranial hemorrhage or ischemic stroke. However, CT angiography of the chest, abdomen and pelvis was remarkable for a markedly dilated, stool-filled colon with diffuse pneumatosis (Image 2); no transition point was identified. The inferior vena cava was compressed (Image 3), and there was ostial stenosis of the celiac trunk and superior mesenteric

### *CPC-EM Capsule*

What do we already know about this clinical entity?

*Abdominal compartment syndrome (ACS) is a rare but life-threatening condition that requires prompt identification and aggressive management.*

What makes this presentation of disease reportable?

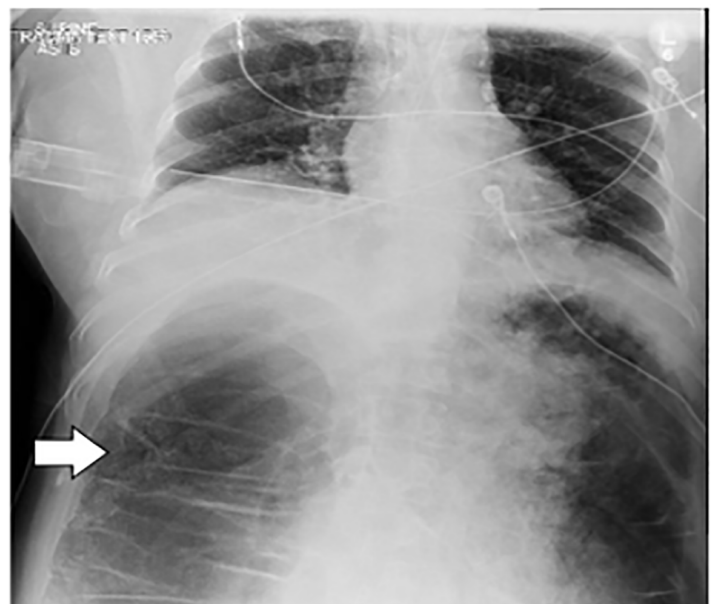
*Our patient presented with ACS due to constipation, which is often considered a benign condition. Constipation as the cause of ACS has not been commonly reported.*

What is the major learning point?

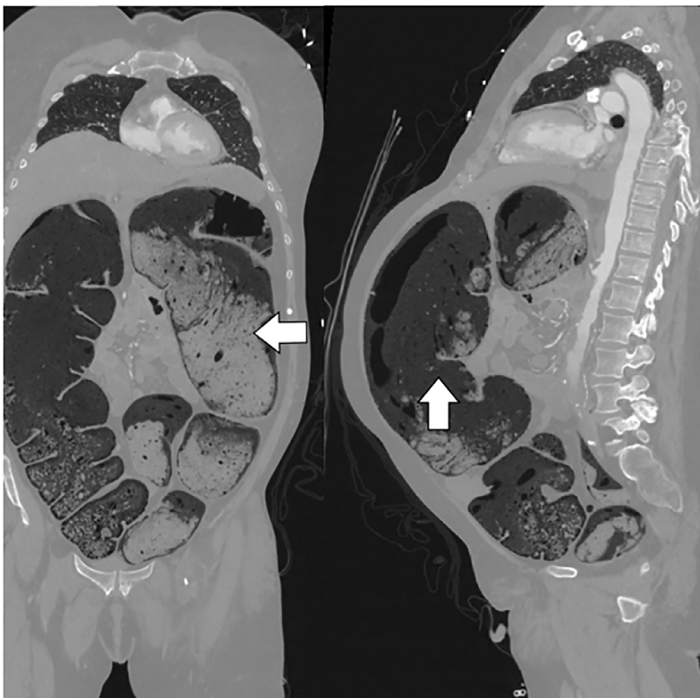
*Untreated constipation can have serious consequences. Attention should be paid to constipation-causing medications in patients presenting for this complaint.*

How might this improve emergency medicine practice?

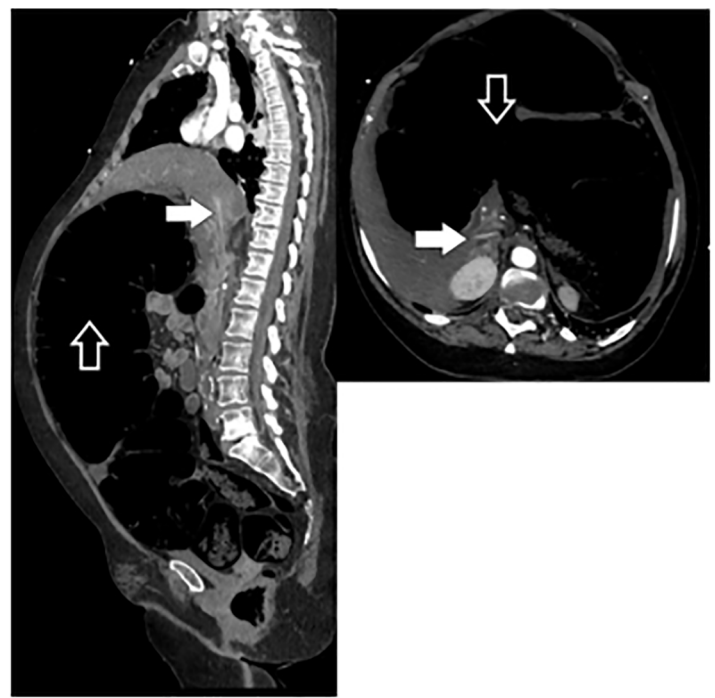
*Familiarization with the presentations of ACS, evaluation, and treatment of underlying causes may improve care of patients with this condition.*



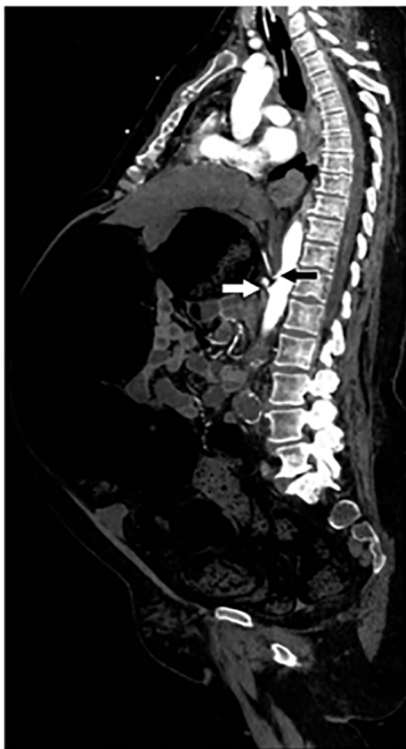**Image 1.** Supine chest radiograph after intubation demonstrating extremely dilated colon (arrow).



**Image 2.** Coronal (left) and sagittal (right) reconstructions of the computed tomography angiogram of the chest, abdomen, and pelvis showing stool impaction causing massive colonic distention (arrows). The image window is set to lung to better visualize the stool within the colon.



**Image 3.** Sagittal (left) and axial (right) windows of the computed tomography angiogram of the chest, abdomen, and pelvis. The inferior vena cava is compressed (white arrows) by the massively dilated colon (black arrows).



**Image 4.** Sagittal window of the computed tomography angiogram of the chest, abdomen, and pelvis demonstrating ostial stenosis of the celiac artery (black arrow) and superior mesenteric artery (white arrow).

artery (Image 4). Impaired perfusion of both kidneys was noted. Although intra-abdominal pressure was not transduced, the evidence of organ dysfunction with a tense abdomen and CT findings led to the diagnosis of ACS.

General surgery took the patient to the operating room emergently for decompressive laparotomy and total colectomy. Upon opening her fascia, the ischemic-appearing colon explosively decompressed, sending stool across the room. She subsequently experienced a wide complex tachycardia in the setting of a potassium of greater than 10 mmol/L. After multiple rounds of medications per Advanced Cardiac Life Support protocol, she was pronounced dead due to severe reperfusion injury. The surgeons noted a loop of sigmoid colon trapped by a band of tissue in the pelvis, when removing the colon for pathology assessment.

#### DISCUSSION

Our patient presented in profound shock due to constipation-induced ACS and died despite aggressive management. Abdominal compartment syndrome is a rare condition with a scarcity of evidenced-based guidelines. Abdominal compartment syndrome can be caused by diminished abdominal wall compliance caused by abdominal surgery, major trauma, ileus, and burns. Increased intra-abdominal contents including abscess, ascites, hemoperitoneum, masses or air should also be considered.



Furthermore, capillary leak that occurs in conditions such as sepsis, pancreatitis, acidosis, hypothermia, and coagulopathy can lead to this condition. If there is suspicion for intra-abdominal hypertension (IAH), then intra-abdominal pressure should be measured. The WSACS recommends trans-bladder measurement. This is done by attaching a pressure transducer to the sampling port of an indwelling urinary catheter via a 3-way stopcock, instilling 25 mL of saline into the bladder, then clamping the catheter distal to the sampling port.<sup>3</sup> Alternative apparatuses using water manometry such as those found in lumbar puncture kits have also been described.<sup>6</sup> When IAH is identified, point-of-care ultrasound and CT can help identify the underlying cause.<sup>4</sup>

Initial management is aimed at supporting organ perfusion. In obtunded patients with poor gas exchange, early intubation can optimize ventilation and alveolar recruitment. In addition to hemodynamic support with crystalloid, colloid, or vasopressors, consider evacuating intraluminal contents by nasogastric and/or rectal tube. Bedside paracentesis can be performed for large volume ascites, and emergent decompression of pneumoperitoneum can be considered.<sup>7</sup> Decreased abdominal wall compliance can be addressed by optimizing sedation or paralysis. Burn escharotomy may also be performed. Placing the patient in reverse Trendelenburg position can also help with this by off-loading pressure from the inferior vena cava, as well as reducing mass effect on the diaphragm to improve lung compliance.<sup>4</sup> Reperfusion injury should be anticipated after decompressive interventions.

Our patient's presentation was caused by severe constipation. Our literature review identified one case of ACS in an adult caused by constipation likely secondary to neurogenic bowel<sup>8</sup> and two cases thought to be due to clozapine use.<sup>9</sup> Her longstanding constipation was likely due to her medication regimen of clozapine, risperidone, and the anticholinergic medications glycopyrrolate and benztropine. Clozapine is effective for treatment-resistant schizophrenia but is prescribed uncommonly (66.7 per 100,000 persons in the 2010 Medicaid database).<sup>10</sup> In a meta-analysis from 2016, constipation was reported in 31% of patients taking clozapine, nearly three times more than patients taking other antipsychotics.<sup>11</sup> A recent study of reports concerning clozapine to the Australian Therapeutic Goods Administration and New Zealand Pharmacovigilance Center found an 18% mortality rate over 22 years in patients with gastrointestinal adverse reactions serious enough to require hospitalization or surgical intervention. The same study reported data from a World Health Organization registry with a case fatality rate of 13% for the complaint of constipation. Case fatality rates were higher when sequela of constipation such as intestinal obstruction (25%) and intestinal ischemia (68%) were reported.<sup>12</sup> It is unknown whether ACS was diagnosed in any of those patients. Risperidone, glycopyrrolate, and benztropine have also been implicated as causes for constipation.<sup>13-15</sup>

## CONCLUSION

Abdominal compartment syndrome causes multiorgan dysfunction and can result in shock and death despite timely recognition and aggressive management as in our patient. Emergency physicians should be suspicious for this condition in patients with a distended abdomen and abnormal vital signs. Interventions should be aimed at correcting metabolic, respiratory, and cardiovascular derangements as well as decompressing the peritoneal cavity via nasogastric/rectal decompression, paracentesis, or burn escharotomy as clinically indicated. The definitive treatment of ACS is surgical decompression. This case report demonstrates that severe constipation can be a fatal cause of ACS necessitating surgical intervention. It is an important reminder to the emergency physician that even seemingly benign conditions such as constipation can lead to severe complications if left unattended. It also underscores the importance of recognizing and treating chronic constipation, with particular attention to those patients on medications such as clozapine that are known to affect gastrointestinal motility.

The authors attest that their institution requires neither Institutional Review Board approval nor patient consent for publication of this case report. Documentation on file.

*Address for Correspondence:* Matthew Kongkatong, MD, University of Virginia Medical Center, Department of Emergency Medicine, 1215 Lee Street, Charlottesville, Virginia 22903. Email: mk3wk@hscmail.mcc.virginia.edu.

*Conflicts of Interest:* By the CPC-EM article submission agreement, all authors are required to disclose all affiliations, funding sources and financial or management relationships that could be perceived as potential sources of bias. The authors disclosed none.

*Copyright:* © 2022 Kongkatong. This is an open access article distributed in accordance with the terms of the Creative Commons Attribution (CC BY 4.0) License. See: <http://creativecommons.org/licenses/by/4.0/>

## REFERENCES

- Maffongelli A, Fazzotta S, Palumbo VD, et al. Abdominal compartment syndrome: diagnostic evaluation and possible treatment. *Clin Ter.* 2020;171(2):e156-e60.
- Siebert M, Le Foulter A, Sitbon N, et al. Management of abdominal compartment syndrome in acute pancreatitis. *J Visc Surg.* 2021. In press.
- Sosa G, Gandham N, Landaras V, et al. Abdominal compartment syndrome. *Dis Mon.* 2019;65(1):5-19.
- Kirkpatrick AW, Roberts DJ, De Waele J, et al. Pediatric Guidelines Sub-Committee for the World Society of the Abdominal Compartment Syndrome. *Intensive Care Med.* 2013;39(7):1190-206.
- Rao S. Constipation in the older adult. In: *UpToDate*, Talley N,



- Schmader K, Grover S (Eds), UpToDate, Waltham, MA.
6. Rao P, Chaudhry R, Kumar S. Abdominal compartment pressure monitoring – a simple technique. *Med J Armed Forces India*. 2006;62(3):269-70.
  7. Chiapponi C, Stoker U, Korner M, et al. Emergency percutaneous needle decompression for tension pneumoperitoneum. *BMC Gastroenterol*. 2011;11:48.
  8. Starnes S, Lawrence H, Navaratnam R. Is constipation a trivial matter? *BMJ Case Rep*. 2016;2016.
  9. Jambet S, Guiu B, Olive-Abergel P, et al. Psychiatric drug-induced fatal abdominal compartment syndrome. *Am J Emerg Med*. 2012;30(3):513.e5-7.
  10. Bachman C, Aagaard L, Bernardo M, et al. International trends in clozapine use: a study of 17 countries. *Acta Psychiatr Scand*. 2017;136(1):37-51.
  11. Shirazi A, Stubbs B, Gomez L, et al. Prevalence and predictors of clozapine-associated constipation: a systematic review and meta-analysis. *Int J Mol Sci*. 2016;17(6):863.
  12. Every-Palmer S and Ellis P. Clozapine-Induced gastrointestinal hypomotility: a 22 year bi-national pharmacovigilance study of serious or fatal 'slow gut' reaction and comparison with international drug safety advice. *CNS Drugs*. 2017;31(8):699-709.
  13. Lexicomp. Risperidone: Drug information. 2011. Available at: [https://somepomed.org/articulos/contenets/mobipreview.htm?18/16/18689?source=see\\_link](https://somepomed.org/articulos/contenets/mobipreview.htm?18/16/18689?source=see_link). Accessed April 11, 2021.
  14. Lexicomp. Glycopyrrolate (glycopyrronium) (systemic): Drug Information. 2011. Available at: <https://www.uptodate.com/contenets/glycopyrrolate-glycopyrronium-pediatric-drug-information>. Accessed May 17, 2021.
  15. Lexicomp. Benzotropine (benzatropine): Drug information. 2011. Available at: [https://somepomed.org/articulos/contenets/mobipreview.htm?7/51/7998?source=see\\_link](https://somepomed.org/articulos/contenets/mobipreview.htm?7/51/7998?source=see_link). Accessed May 17, 2021.

# Case Report: Differential Diagnosis of Lower Extremity Weakness in a Young Male - Consider Foix Alajouanine Syndrome

Avi Siani, MD  
Alexander Garrett, MD  
Natasha Thomas, MD, MPH

Harbor-UCLA Medical Center, Department of Emergency Medicine, Torrance, California

Section Editor: Scott Goldstein, MD

Submission History: Submitted April 1, 2021; Revision received August 7, 2021; Accepted August 12, 2021

Electronically published January 4, 2022

Full text available through open access at [http://escholarship.org/uc/uciem\\_cpccem](http://escholarship.org/uc/uciem_cpccem)

DOI: 10.5811/cpcem.2021.8.52660

**Introduction:** There is a limited list of emergent spinal cord pathology that must be considered in patients with focal neurological deficits in the emergency department. Identification of these conditions requires a detailed history and neurological exam and may also require advanced testing and imaging.

**Case Report:** Here we present the case of a patient with a rare arteriovenous malformation of the spinal cord vessels causing congestive myelopathy (Foix-Alajouanine syndrome) that presented as a clinical mimic of spinal cord compression.

**Conclusion:** Emergency physicians should be aware of Foix-Alajouanine syndrome, as its workup and management differ from more common pathologies that may present similarly.  
[Clin Pract Cases Emerg Med. 2022;6(1):25-28.]

**Keywords:** *case report; Foix-Alajouanine; spinal arteriovenous malformations; congestive myelopathy.*

---

## INTRODUCTION

Acute or progressive onset of bilateral lower extremity weakness, sensory loss, hypo- or hyperreflexia, and bladder dysfunction are concerning for emergent spinal pathology. These may include cauda equina syndrome, transverse myelitis, spinal cord compression, or spinal trauma. Demyelinating diseases such as Guillain-Barré syndrome (GBS), as well as chronic inflammatory demyelinating polyneuropathy (CIDP) must also be considered in the emergency department (ED).<sup>1</sup> Foix-Alajouanine syndrome is a rare disease described as intradural arteriovenous malformations (AVM) that can cause venous congestion and ischemic myelopathy, ultimately leading to a clinical presentation similar to the above diagnoses.<sup>2</sup> The syndrome was initially described by Foix and Alajouanine in 1926 as acute or subacute neurological deterioration in a patient who was found to have tortuous vessels lying on the surface of the spinal cord with associated necrosis on autopsy.<sup>3</sup>

In 1931 Lhermitte found an association with the syndrome and spinal AVMs.<sup>4</sup> Initially, it was hypothesized that these AVMs were likely to become thrombosed, resulting in ischemic and necrotic myelopathy. Based on this understanding of the syndrome, treatment and reversal of the progressive myelopathy was considered futile. However, recent literature shows that spinal venous thrombosis may not be responsible for the myelopathy. Rather, dural arteriovenous fistulas may cause congestive myelopathy from venous hypertension.<sup>5,6</sup> In this scenario, endovascular repair of the fistulas is likely to improve the likelihood of a meaningful neurological recovery.

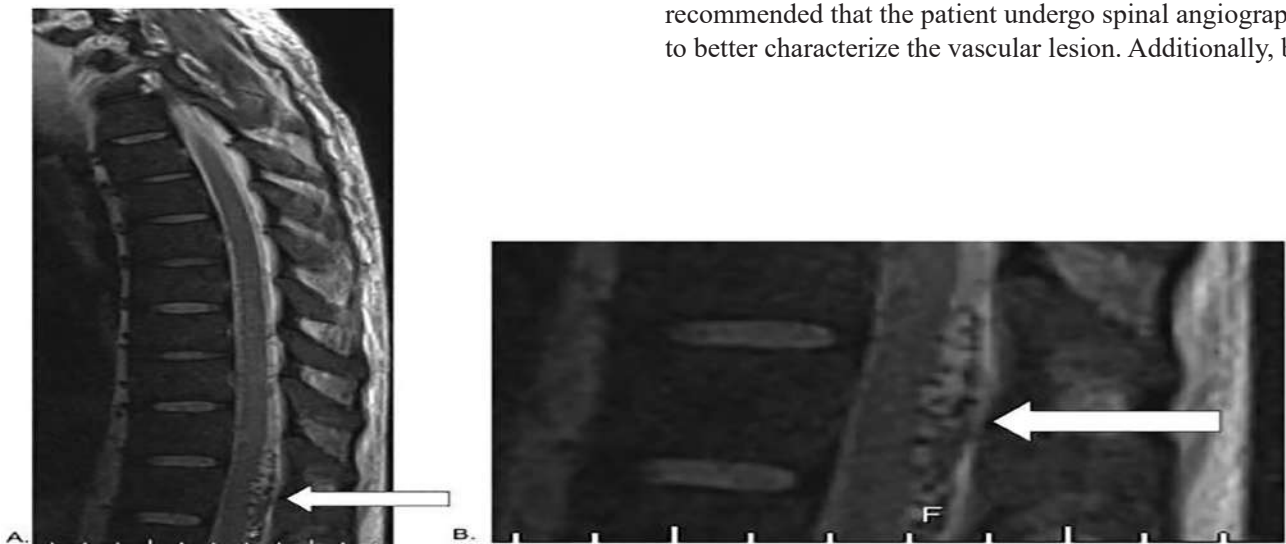
Diagnosing the condition requires a high level of suspicion as the necessary diagnostic modalities are not typically included in the ED workup for other emergent spinal pathologies. To the best of our knowledge, the ED workup and management for this rare syndrome has not been reviewed in the literature. Here we describe the case of a patient who

presented to the ED with Foix-Alajouanine syndrome, with an emphasis on in-department workup and management.

### CASE REPORT

A 38-year-old male presented to the ED with progressive bilateral lower extremity weakness and difficulty with ambulation for three months, acute urinary retention since waking up that morning, and lower back pain. He denied any saddle anesthesia, leg numbness, bowel incontinence, weight loss, intravenous drug use, fevers, or recent trauma. Of note, the patient had been admitted one month prior to presentation with septic shock secondary to cholangitis and pancreatitis. He had noted bilateral lower extremity weakness at the time, but this was thought to be secondary to deconditioning from the prolonged admission. The patient otherwise had a history of schizophrenia and hypothyroidism, with no prior surgical history.

On exam, he had 2/5 motor strength in the bilateral lower extremities with hip flexion and extension and knee flexion and extension, and 3/5 strength with ankle plantar flexion and dorsiflexion. He was unable to safely stand or walk without assistance. His sensation was intact to light touch throughout. Achilles and plantar reflexes were absent bilaterally, with a normal Babinski sign. Rectal tone was not checked due to patient preference. The patient had a distended bladder, and one liter of urine was drained immediately following Foley catheter placement, confirming concern for acute urinary retention. Given the concern for CIDP, cauda equina syndrome, and GBS, an immediate thoracic and lumbar spine magnetic resonance imaging (MRI) was ordered and neurology and neurosurgery were consulted. Although the MRI was initially interpreted as showing no acute pathology, further review of imaging with radiology was concerning for a vascular lesion along the lumbar spine (Image 1).



**Image 1.** A) T2-weighted magnetic resonance imaging of the thoracic spine without contrast showing flow voids (white arrow) in the intradural extramedullary region posterior to the spinal cord from the 11th thoracic vertebra to the first lumbar vertebra consistent with spinal arteriovenous malformation. B) Close-up image of flow void (white arrow).

### CPC-EM Capsule

What do we already know about this clinical entity?

*Foix-Alajouanine syndrome is a rare congestive myelopathy from spinal cord arteriovenous malformations that presents as acute or subacute neurological deterioration.*

What makes this presentation of disease reportable?

*The patient in our case presented with symptoms that were a near mimic of other emergent spinal cord pathologies.*

What is the major learning point?

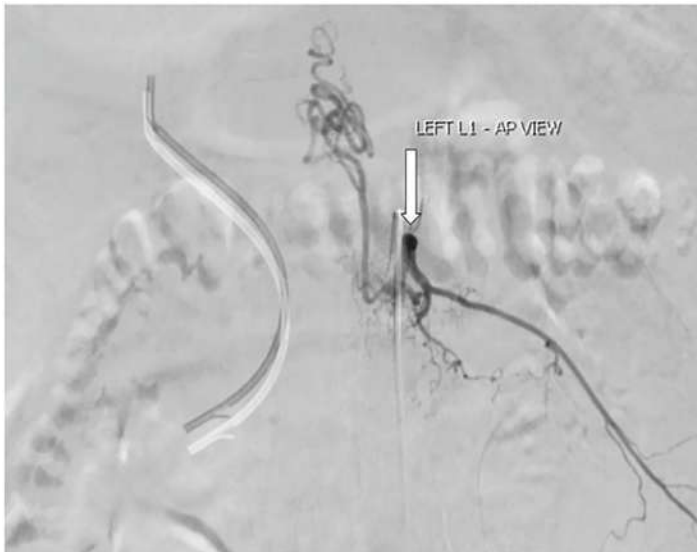*This syndrome can mimic other spinal cord pathologies; it can present as flow voids on MRI, which should prompt spinal angiography to confirm the diagnosis.*

How might this improve emergency medicine practice?

*Being aware of this syndrome could expedite diagnosis, as well as minimize risks of poor outcomes from contraindicated lumbar punctures.*

Neurosurgery noted multiple flow voids from the 11th thoracic (T11) to the first lumbar (L1) vertebra on MRI, which was consistent with spinal arteriovenous fistula and Foix-Alajouanine syndrome. Neurosurgery and neurology recommended that the patient undergo spinal angiography to better characterize the vascular lesion. Additionally, both

recommended that interventional radiology (IR) be consulted for an IR-guided lumbar puncture (LP) as GBS and CIDP were both still on the differential. Interventional radiology-guided LP was advised to minimize the risk of affecting the AVM. Spinal angiography showed a type one dural arteriovenous fistula supplied by a radiculomedullary branch that arose from the left L1 lumbar artery (Image 2), with a coiled venous component extending superiorly to the T6 level and inferiorly to the L5 level.



**Image 2.** Spinal angiogram showing dural arteriovenous fistula (white arrow) arising from left lumbar artery of the first lumbar vertebra (L1) between a dural branch of the spinal ramus of a radicular artery and an intradural medullary vein. Also shown is the venous component coming off the arteriovenous malformation, which is coiled and extends superiorly to the sixth thoracic vertebra (T6) level and inferiorly to the fifth lumbar vertebra (L5) level. AP, anteroposterior.

A nerve conduction study showed no evidence of demyelination. A repeat MRI of the spinal cord confirmed flow voids in the intradural extramedullary region posterior to the spinal cord from T11 to L1 consistent with spinal AVM. The patient was subsequently taken to surgery with IR placement of a 3-millimeter coil into the L1 feeder vessel for intraoperative identification, followed by a T12 through L2 laminectomy in addition to ligation of the dural arteriovenous fistula, which was performed by neurosurgery. The patient had a prolonged postoperative course complicated by wound dehiscence and poor nutrition requiring a lengthy stay at a rehabilitation facility. Approximately two months postop, the patient was able to ambulate with a walker, and was discharged home from the rehab facility. He had a follow-up MRI at six months that showed resolution of the previously identified flow voids. Eight months after the initial

presentation, the patient was able to ambulate safely with a walker, had no incontinence or retention symptoms, and had 4/5 strength in his bilateral lower extremities.

## DISCUSSION

Back pain with associated bowel and/or bladder incontinence, saddle anesthesia, numbness, or weakness of the lower extremities is concerning for emergent spinal pathology. These symptoms should prompt a differential diagnosis including cauda equina syndrome, epidural hematoma, epidural abscess, cord compression or injury from trauma, transverse myelitis, CIPD, and GBS. Foix-Alajouanine syndrome is not considered in most emergency clinicians' differential diagnosis for emergent spinal cord pathology; however, the management and diagnosis of the disease are unique enough to warrant understanding of this syndrome. Foix-Alajouanine syndrome describes a non-compressive myelopathy from venous hypertension in spinal AVMs, leading to decreased perfusion of the spinal cord and eventual cord necrosis.<sup>7,8</sup>

Regardless of the location of the AVM, the lower spinal cord seems to be predominantly affected. This is likely the result of the intraspinal veins lacking valves; thus, with gravity the lower cord becomes more congested. Also, there are fewer collateral veins in the lower part of the spinal cord to reduce the amount of venous hypertension caused by the AVM.<sup>9</sup> Due to this, patients often present with lower spinal cord myelopathies that involve acute or subacute lower extremity weakness and numbness, as well as urinary retention and bowel incontinence. These symptoms can be seen in cauda equina syndrome, CIDP, and GBS, which are "cannot miss" diagnoses considered commonly in the ED. Spinal cord MRI is often performed in the evaluation of these symptoms, and a LP may be considered. Unfortunately, MRI is not completely sensitive or specific for Foix-Alajouanine syndrome, and a traditional LP is contraindicated as the provider may cause vascular injury.

There have not been any studies on the sensitivity of MRI for diagnosing spinal arteriovenous lesions; however, studies have shown that it may take years to accurately diagnose these patients. One study showed that 40-63% of patients have the disease for one to three years, and 10-34% have it for more than three years before they are accurately diagnosed.<sup>9</sup> The MRI of an affected patient may show swelling of the medullary conus and some central spinal cord enhancement. On sagittal T2-weighted MRI, one should look for vascular flow voids on either the dorsal or ventral aspect of the spinal cord. If suspicion is high for spinal AVM and Foix-Alajouanine syndrome, the gold standard for diagnosis is spinal angiography, which would typically follow MRI.<sup>10,11</sup> Given the rarity of the disease, epidemiological data are limited; however, one study reported that patients are typically male and in the sixth decade of life when diagnosed with spinal dural arteriovenous fistulas.<sup>12</sup> Non-IR guided



LP is contraindicated in these patients due to the chance of puncturing the vascular lesion.

The management of Foix-Alajouanine syndrome or spinal AVMs should include immediate neurosurgical consultation and avoidance of steroids and blind LP. Theoretically, keeping the patient supine could be of benefit as well, as being upright can worsen spinal venous congestion due to gravity; however, this is purely speculative based on the pathophysiology and has not been formally studied. Additionally, maintaining high systemic mean arterial pressures (MAP), which is usually advised in traumatic spinal cord injuries, would be contraindicated as higher MAPs may actually worsen venous congestion. Studies have shown that steroid use in patients with spinal arteriovenous fistulas can acutely worsen motor and sensory symptoms.<sup>13</sup>

Ultimately, these patients are managed by either endovascular embolization of the AVM or clipping and ligation of the AVM.<sup>14</sup> Foix-Alajouanine syndrome is a rare cause of spinal cord pathology that may mimic more common diseases such as cauda equina syndrome and cord compression. It should be considered in patients with lower cord symptoms, as the workup and management in the ED differs from other myelopathies and demyelinating diseases.

## CONCLUSION

Foix-Alajouanine syndrome is a rare condition involving congestive myelopathy originating from spinal arteriovenous malformations, which can present similarly to other spinal cord pathologies that are considered to be emergent. However, the workup and management of Foix-Alajouanine largely deviates from other similar pathologies; so, albeit a rare diagnosis, it is important for emergency physicians to be familiar with this disease.

The authors attest that their institution requires neither Institutional Review Board approval nor patient consent for publication of this case report. Documentation on file.

*Address for Correspondence:* : Avi Siani, MD, Harbor-UCLA Medical Center, Department of Emergency Medicine, 1000 West Carson Street, Building D-9, Box 21, Torrance, California 90502. Email: asiani2@dhs.lacounty.gov.

*Conflicts of Interest:* By the CPC-EM article submission agreement, all authors are required to disclose all affiliations, funding sources and financial or management relationships that could be perceived as potential sources of bias. The authors disclosed none.

*Copyright:* © 2022 Siani. This is an open access article distributed in accordance with the terms of the Creative Commons Attribution (CC BY 4.0) License. See: <http://creativecommons.org/licenses/by/4.0/>

## REFERENCES

1. Menon KV, Sorour TM, Raniga SB. Foix-Alajouanine syndrome presenting as acute cauda equina syndrome: a case report. *Global Spine J.* 2014;4(4):269-72.
2. Mishra R and Kaw R. Foix-Alajouanine syndrome: an uncommon cause of myelopathy from an anatomic variant circulation. *South Med J.* 2005;98(5):567-9.
3. Foix C and Alajouanine T. La myélite nécrotique subaigüe. *Rev Neurol (Paris).* 1926;2:1-42.
4. Lhermitte J, Friboury-Blanc A, Kyriaco N. La gliose angéio-hyperthrophique de la moelle épinière (myélite nécrotique de Foix-Alajouanine). *Rev Neurol (Paris).* 1931;2:37-53.
5. Ferrell AS, Tubbs RS, Acakpo-Satchivi L, et al. Legacy and current understanding of the often-misunderstood Foix-Alajouanine syndrome. Historical vignette. *J Neurosurg.* 2009;111(5):902-6.
6. Krishnan P, Banerjee TK, Saha M. Congestive myelopathy (Foix-Alajouanine syndrome) due to intradural arteriovenous fistula of the filum terminale fed by anterior spinal artery: case report and review of literature. *Ann Indian Acad Neurol.* 2013;16(3):432-6.
7. Heros RC. Foix-Alajouanine syndrome: What is it? *J Neurosurg.* 2009;111(5):900-1.
8. Aminoff MJ, Barnard RO, Logue V. The pathophysiology of spinal vascular malformations. *J Neurol Sci.* 1974;23(2):255-63.
9. Jellema K, Tijssen CC, van Gijn J. Spinal dural arteriovenous fistulas: a congestive myelopathy that initially mimics a peripheral nerve disorder. *Brain.* 2006;129(Pt 12):3150-64.
10. Doppman JL, Di Chiro G, Dwyer AJ, et al. Magnetic resonance imaging of spinal arteriovenous malformations. *J Neurosurg.* 1987;66(6):830-4.
11. Krings T, Mull M, Gilsbach JM, et al. Spinal vascular malformations. *Eur Radiol.* 2005;15(2):267-78.
12. Jellema K, Canta LR, Tijssen CC, et al. Spinal dural arteriovenous fistulas: clinical features in 80 patients. *J Neurol Neurosurg Psychiatry.* 2003;74(10):1438-40
13. Nasr DM, Brinjikji W, Rabinstein AA, et al. Clinical outcomes following corticosteroid administration in patients with delayed diagnosis of spinal arteriovenous fistulas. *J Neurointerv Surg.* 2017;9(6):607-10.
14. Krings T, Thron AK, Geibprasert S, et al. Endovascular management of spinal vascular malformations. *Neurosurg Rev.* 2010;33(1):1-9.

# Renal Vein Thrombosis on Point-of-care Ultrasound in the Emergency Department: A Case Report

Michelle Haimowitz, MD  
Laura K. Gonzalez, MD

Maimonides Medical Center, Department of Emergency Medicine, Brooklyn, New York

Section Editor: Shadi Lahham, MD

Submission History: Submitted June 17, 2021; Revision received September 13, 2021; Accepted September 20, 2021

Electronically published January 24, 2022

Full text available through open access at [http://escholarship.org/uc/uciem\\_cpem](http://escholarship.org/uc/uciem_cpem)

DOI: 10.5811/cpem.2021.9.53714

**Introduction:** This case report of renal vein thrombosis found on emergency bedside ultrasound illustrates the expanding role of point-of-care ultrasound (POCUS) in rapidly identifying rare renal pathologies.

**Case Report:** A 16-year-old female with a complex medical history presenting with right-sided abdominal pain and tenderness was found to have significant renal POCUS findings consistent with renal vein thrombosis.

**Conclusion:** In the medically complex patient with nonspecific chief complaints, it can be challenging to rapidly narrow a broad differential diagnosis. Point-of-care ultrasound has proven to be an extremely useful tool for this purpose. As emergency physicians become more proficient in the use of ultrasonography, it is likely that POCUS will be used with increasing frequency to identify additional pathology outside its traditional applications. [Clin Pract Cases Emerg Med. 2022;6(1):29-32.]

**Keywords:** *case report; renal vein thrombosis; point-of-care ultrasound; renal ultrasound.*

## INTRODUCTION

During the last few decades, point-of-care ultrasound (POCUS) has become an important tool in the emergency department (ED) for rapid and accurate diagnosis of many conditions. It enables emergency physicians to answer specific clinical questions in a timely manner leading to improved patient care. Historically, renal ultrasonography (RUS) has been used in the ED to assess the presence or absence of hydronephrosis which is most commonly associated with obstructive uropathy or to identify urinary retention. With the widespread use of renal POCUS by trained emergency physicians other pathologies have been identified, contributing to the diagnosis of a broader range of disease than ever before. The following case illustrates the role of renal POCUS in identifying unusual renal pathology and expediting care in a medically complex patient.

## CASE REPORT

A 16-year-old female with a past medical history significant for well controlled human immunodeficiency virus

(HIV) infection, idiopathic thrombocytopenic purpura (ITP), menorrhagia, anemia, thyroid disease, and bilateral cholesteatomas with conductive hearing loss presented to the ED with severe acute right-sided abdominal pain and non-bilious, non-bloody emesis for eight hours. Of note, she had undergone a complicated right tympanomastoidectomy two days prior. The patient endorsed constipation but was passing flatus; she denied fevers, chills, cough, shortness of breath, diarrhea, hematochezia, melena, urinary complaints, or headaches. Her current medications included eltrombopag, abacivir-lamivudine, dolutegravir, levothyroxine, cephalexin, and ferrous sulfate. She denied sexual activity and had no history of tobacco, alcohol, or drug use.

The patient's vital signs on presentation were temperature 97.8° Fahrenheit, heart rate 87 beats per minute, respiratory rate 18 breaths per minute, blood pressure 112/78 millimeters (mm) of mercury, and oxygen saturation of 100% on room air. On exam, she was noted to be in moderate distress secondary to pain. Her right ear was covered by a large dressing; there was no scleral icterus, and she had moist mucous membranes.

Her neck was supple and her lungs were clear. Heart sounds were regular with normal rate; perfusion was normal. There was notable right upper and lower quadrant tenderness with guarding but no masses, rebound, or costovertebral tenderness. The patient was alert and appropriately responsive with a grossly normal neurological exam. No rash, petechiae, or bruising were noted. While in the ED, the patient experienced two episodes of gross hematuria.

Given the history and exam, a broad differential was considered including biliary tract disease, appendicitis, ovarian pathology, ureterolithiasis, urinary tract infection, and small bowel obstruction. Labs were notable for a white blood cell count of 21.8 thousands per cubic millimeter (K/uL) (reference range: 4.8-10.8 K/uL) with 94% neutrophils (50-70%), a hemoglobin of 10.1 grams per deciliter (g/dL) (12.0-16.0 g/dL), and platelets of 98 K/uL (150-400 K/uL); normal electrolytes, renal function, liver function, and coagulation tests; and a urinalysis with proteinuria, ketonuria, hemoglobinuria, urobilinogen, and small leukocyte esterase. (Images 1, 2 and Video) The patient was given intravenous (IV) hydration and pain medications after which a renal POCUS was performed. Sonographic findings were remarkable for mild right hydronephrosis, an enlarged kidney with surrounding free fluid, and a diffusely hyperechoic renal cortex with decreased corticomedullary differentiation. Although the underlying cause of these findings was uncertain, it was clear that the source of her abdominal pain was renal. She was sent for computed tomography (CT) with IV contrast showing an “edematous right kidney with markedly delayed enhancement, prominent surrounding inflammation and fluid, and fullness of the right renal vein with hypodensity extending into the inferior vena cava suspicious for renal vein thrombosis (RVT).”

Urology and vascular surgery were immediately consulted for thrombosis of the right renal vein with concern for ischemia

of the kidney; otolaryngology (ENT) was also consulted given the patient’s recent surgery. Vascular Surgery recommended

### *CPC-EM Capsule*

What do we already know about this clinical entity?

*Acute renal vein thrombosis (RVT) is a rare condition often seen in the setting of hypercoagulable states. Computerized tomography angiography and magnetic resonance angiography are usually used to diagnose this condition.*

What makes this presentation of disease reportable?

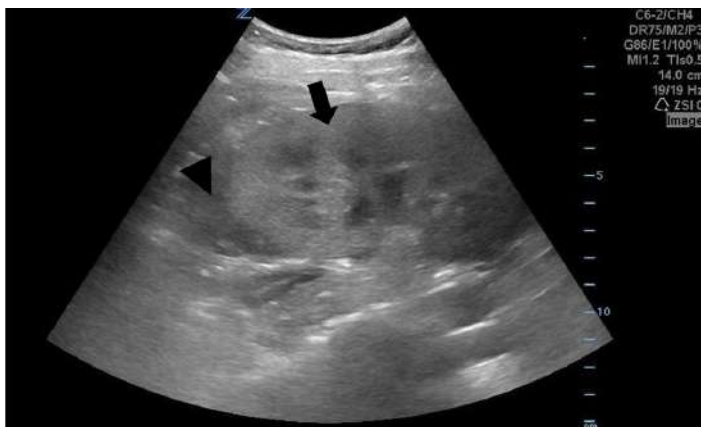*Although sonographic findings have been reported previously in radiology literature, point-of-care ultrasound (POCUS) findings of RVT have never been described in the emergency department literature.*

What is the major learning point?

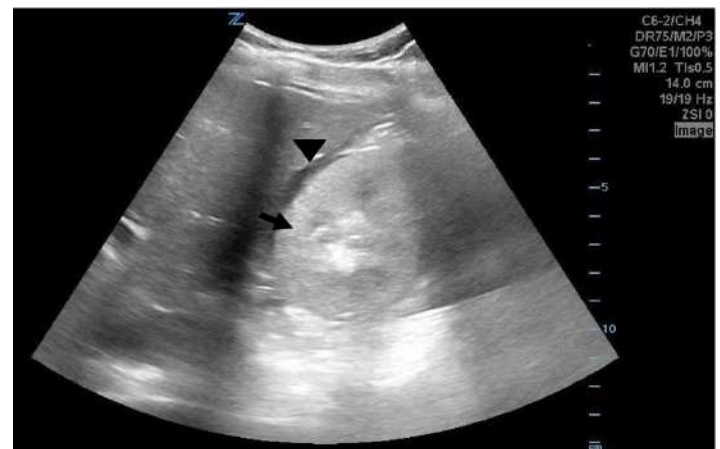*As the use of POCUS increases, physicians will identify findings of both common and uncommon diseases; this in turn will facilitate more refined and expeditious patient care.*

How might this improve emergency medicine practice?

*We hope that presenting this case will encourage emergency physicians to use POCUS to narrow differential diagnoses and expedite patient care.*



**Image 1.** Point-of-care ultrasound of the right kidney seen in the longitudinal plane with curvilinear probe showing loss of corticomedullary differentiation (arrow) and surrounding free fluid (arrowhead).



**Image 2.** Point-of-care ultrasound of the right kidney seen in the transverse plane with curvilinear probe showing an enlarged and hyperechoic kidney (arrow) with surrounding free fluid (arrowhead).

anticoagulation if deemed safe given her recent surgery; ENT agreed with anticoagulation, and treatment with enoxaparin was commenced. Eltrombopag was stopped given the associated risk of hypercoagulability. The patient was given ceftriaxone in light of the abnormal urinalysis and possible urinary tract infection, and she was admitted to the pediatric service for further evaluation and management.

While inpatient, additional workup revealed a pulmonary embolism in the left lung base. The patient developed fever and was treated for superimposed pneumonia. Additionally, a heart murmur prompted an echocardiogram, which was negative for endocarditis. Additional consults included infectious disease, hematology/oncology, cardiology, and nephrology. She was discharged home but returned with multiple pulmonary emboli a week later. She underwent another hospital stay during which an extensive thrombophilia workup was negative. It is thought that the most likely cause of her disease process was a combination of underlying HIV and ITP, use of eltrombopag, and relative immobility secondary to surgery.

## DISCUSSION

Point-of-care ultrasound has revolutionized the way emergency physicians evaluate patients at bedside. Whereas previously the exam was limited to visualization, auscultation, palpation and percussion, POCUS now allows physicians to directly visualize the underlying disease. Many abdominal pathologies can be successfully and rapidly identified at the bedside including gallbladder disease, small bowel obstruction, appendicitis, intussusception, hydronephrosis, and more. Additional benefits of POCUS include the avoidance of radiation, the ability to assess function, and the ability to do serial exams. The renal system is particularly well-visualized on ultrasound, which has a long and trusted role in diagnosis of renal pathology.

The primary application of renal POCUS has been the diagnosis of hydronephrosis, which is most often due to ureterolithiasis. The gold standard for urinary tract stones has been computed tomography (CT); however, there are many reasons CT may not be optimal including the risk of radiation, the relatively higher cost, a lack of availability, and an associated increased length of stay. In the hands of trained emergency physicians, renal POCUS has been shown to be a useful tool to identify the presence or absence of hydronephrosis, which may alleviate the necessity for further imaging.<sup>1</sup>

A randomized, multicenter controlled trial of patients with suspected urinary tract stones that compared ultrasound to CT found no difference in high-risk diagnoses with complications, serious adverse events, pain scores, hospital admissions, or ED readmissions in the two groups.<sup>2</sup> Furthermore, although ultrasound is less sensitive for renal colic, its use over CT did not lead to worse patient-centered outcomes. Leo et al. further investigated the use of ultrasound for urinary tract stones and

found that the degree of hydronephrosis could effectively rule out the presence of stones greater than five mm, which more often require surgical intervention. While there were higher rates of return to the ED within 30 days, this was found to be due to pain rather than serious adverse events or complications, further supporting the idea that ultrasound is a safe alternative to CT.<sup>3</sup>

In cases of suspected renal colic where there is no or only mild hydronephrosis on POCUS, studies have shown that patients are significantly less likely to have larger stones that require surgical intervention. In such cases, Goertz et al. argues that the use of POCUS and urinalysis is sufficient to diagnose renal colic. By avoiding CT in these patients, its use would be decreased by 73% while only missing 9% of patients with calculi greater than 5 mm. Additionally, none of these missed patients had stones greater than 10 mm, and thus all would have been appropriate for a trial of medical management.<sup>4</sup>

While the presence or absence of hydronephrosis is the primary clinical question the emergency physician must answer, clinicians using POCUS have become more adept at identifying additional renal pathologies. There are multiple case reports of other diseases identified on renal POCUS including renal trauma,<sup>5</sup> renal cell carcinoma,<sup>6</sup> urinomas,<sup>7</sup> emphysematous pyelonephritis,<sup>8</sup> pyonephrosis,<sup>9</sup> and xanthrogranulomatous pyelonephritis.<sup>10</sup> Furthermore, its routine use in some other conditions has been advocated. Chen et al. conducted a retrospective review of patients diagnosed with acute pyelonephritis (APN) and found that emergency renal ultrasonography identified pathology in 60.9% of complicated APN. ("Complicated APN" is defined as admission longer than 14 days, admission to intensive care unit, and need for invasive treatments.) More significantly, however, was that 34.3% of these patients were found to have significant sonographic abnormalities that led to a change in management including surgical interventions such as percutaneous nephrostomy, abscess aspiration, ureteroscopic stone manipulation, lithotripsy, or nephrectomy.<sup>11</sup>

In the case of our patient, renal POCUS was used to rapidly identify the kidney as the source of her acute presentation; given her complicated medical history and highly abnormal renal POCUS, further imaging was pursued. Acute RVT is a rare condition most often seen in the settings of dehydration, trauma, infection, nephrotic syndrome, or hypercoagulable states.<sup>12</sup> It can present similarly to renal colic with flank pain and hematuria and thus would often prompt renal POCUS in the ED. While the gold standard for diagnosis of RVT is selective renal venography, both CT angiography and magnetic resonance imaging have gained favor as they are less invasive.<sup>13</sup> Very few studies have investigated the use of ultrasound to diagnose RVT, and although sonographic findings have been reported previously in the radiology literature, to our knowledge they have never been described in the ED literature. Classic sonographic signs of RVT include abnormal echogenicity,



which can be increased or decreased depending on the age of insult<sup>14</sup> and “loss of corticomedullary differentiation in addition to renal enlargement.”<sup>15</sup> Color Doppler can also be used to assess flow in the renal vein.<sup>14</sup> These descriptions are consistent with the ultrasound findings seen in this patient, further supporting the final diagnosis made by the emergency physician using POCUS in conjunction with CT.

## CONCLUSION

Point-of-care ultrasound is an extremely useful tool available to emergency physicians, and its use is associated with decreased radiation exposure, reduction of healthcare costs, improvement in time to diagnosis, and better patient outcomes. Additionally, it has contributed to the identification of less common pathologies leading to life-saving interventions. The full spectrum of its utility has yet to be revealed. In the case reported here, the patient had an extensive medical history and presented with nonspecific abdominal pain leading to a broad differential diagnosis. Use of POCUS allowed the emergency care team to rapidly identify renal pathology and to tailor further workup accordingly, thus optimizing care for this very complicated pediatric patient with renal vein thrombosis.

**Video.** Point-of-care ultrasound of the right kidney seen in the longitudinal plane with curvilinear probe showing loss of corticomedullary differentiation (black arrow) and surrounding free fluid (white arrow).

The authors attest that their institution requires neither Institutional Review Board approval nor patient consent for publication of this case report. Documentation on file.

**Address for Correspondence:** Laura K. Gonzalez, MD, Maimonides Medical Center, Department of Emergency Medicine, 4802 Tenth Avenue, Brooklyn, New York 11219. Email: lagonzalez@maimonidesmed.org.

**Conflicts of Interest:** By the CPC-EM article submission agreement, all authors are required to disclose all affiliations, funding sources and financial or management relationships that could be perceived as potential sources of bias. The authors disclosed none.

**Copyright:** © 2022 Haimowitz. This is an open access article distributed in accordance with the terms of the Creative Commons Attribution (CC BY 4.0) License. See: <http://creativecommons.org/licenses/by/4.0/>

## REFERENCES

1. Wong C, Teitge B, Ross M, et al. The accuracy and prognostic value of point-of-care ultrasound for nephrolithiasis in the emergency

department: a systematic review and meta-analysis. *Acad Emerg Med.* 2018;25(6):684-98.

2. Smith-Bindman R, Aubin C, Bailitz J, et al. Ultrasonography versus computed tomography for suspected nephrolithiasis. *N Engl J Med.* 2014;371(12):1100-10.
3. Leo MM, Langlois BK, Pare JR, et al. Ultrasound vs. computed tomography for severity of hydronephrosis and its importance in renal colic. *West J Emerg Med.* 2017;18(4):559-68.
4. Goertz JK and Lotterman S. Can the degree of hydronephrosis on ultrasound predict kidney stone size? *Am J Emerg Med.* 2010;28(7):813-6.
5. Yeh J, Jafri F, Saul T, et al. Renal fracture. *J Emerg Med.* 2013;44(4):e337-8.
6. Mandavia DP, Pregerson B, Henderson SO. Ultrasonography of flank pain in the emergency department: renal cell carcinoma as a diagnostic concern. *J Emerg Med.* 2000;18(1):83-6.
7. Thom C, Eisenstat M, Moak J. Point-of-care ultrasound identifies urinoma complicating simple renal colic: a case series and literature review. *J Emerg Med.* 2018;55(1):96-100.
8. Brown N, Petersen P, Kinas D, et al. Emphysematous pyelonephritis presenting as pneumaturia and the use of point-of-care ultrasound in the emergency department. *Case Rep Emerg Med.* 2019;2019:6903193.
9. Kamboj M, Lee Loy J, Koratala A. Renal ultrasonography: a reliable diagnostic tool for pyonephrosis. *Clin Case Rep.* 2018;6(6):1176-8.
10. Gibbons R, Leonard N, Magee M, et al. Xanthogranulomatous pyelonephritis: a complicated febrile urinary tract infection detected by point-of-care ultrasound in the emergency department. *J Emerg Med.* 2018;55(1):e1-e4.
11. Chen KC, Hung SW, Seow VK, et al. The role of emergency ultrasound for evaluating acute pyelonephritis in the ED. *Am J Emerg Med.* 2011;29(7):721-4.
12. Llach F. Hypercoagulability, renal vein thrombosis, and other thrombotic complications of nephrotic syndrome. *Kidney Int.* 1985;28(3):429-39.
13. Singhal R and Brimble KS. Thromboembolic complications in the nephrotic syndrome: pathophysiology and clinical management. *Thromb Res.* 2006;118(3):397-407.
14. Asghar M, Ahmed K, Shah SS et al. Renal vein thrombosis. *Eur J Vasc Endovasc Surg.* 2007;34(2):217-23.
15. Al-Katib S, Shetty M, Jafri SMA, et al. Radiologic assessment of native renal vasculature: a multimodality review. *Radiographics.* 2017;37(1):136-56.

# A Case Report of Prolonged Anaphylaxis after COVID-19 Vaccine

Lisa Armstrong, MD  
Nicole Maguire, DO

RWJ Barnabas Health-Community Medical Center, Department of Emergency Medicine, Toms River, New Jersey

Section Editor: R. Wilkerson

Submission History: Submitted June 16, 2021; Revision received September 12, 2021; Accepted September 20, 2021

Electronically published December 14, 2021

Full text available through open access at [http://escholarship.org/uc/uciem\\_cpem](http://escholarship.org/uc/uciem_cpem)

DOI: 10.5811/cpcem.2021.9.53690

**Introduction:** As the medical community and world have combatted the coronavirus disease 2019 (COVID-19) pandemic, a significant advance was the development of a vaccine against the virus that has already claimed over 4.5 million lives worldwide.<sup>1</sup> Vaccines manufactured by Pfizer-BioNTech and Moderna were the first two COVID-19 vaccines given emergency use authorization by the United States Food and Drug Administration. Preliminary data demonstrated not only the vaccines' efficacy rates of greater than 95% after a second dose, but also marked safety. Initial data showed only 21 cases of anaphylaxis of greater than 1.8 million doses administered. The majority of those patients had a history of anaphylaxis and presented within the first 15 minutes after administration of the vaccine.<sup>2</sup>

**Case Report:** We describe a patient who had an anaphylactic reaction to her second dose of the Pfizer BioNTech severe acute respiratory syndrome coronavirus 2 (SARS CoV-2) vaccine with no prior history of allergic reactions or anaphylaxis. This reaction required multiple doses of epinephrine and a four-day hospitalization. We review both the available reports of anaphylaxis to the SAR CoV-2 vaccine and information on other prolonged cases of anaphylaxis.

**Conclusion:** Our case report is unique in that the patient, despite no prior history of anaphylaxis, had a prolonged course requiring a four-day hospitalization. To our knowledge this is one of the first case reports of prolonged anaphylaxis after the second dose of Pfizer BioNTech COVID-19 vaccine in a patient with no history of prior anaphylaxis.<sup>3</sup> [*Clin Pract Cases Emerg Med.* 2022;6(1):33-36.]

**Keywords:** COVID-19 vaccine; anaphylaxis; prolonged; case report.

## INTRODUCTION

The United States Food and Drug Administration has issued emergency use authorization for multiple severe acute respiratory syndrome coronavirus 2 (SARS CoV-2) vaccines. The first two vaccines, Pfizer BioNTech (Mainz, Germany) and Moderna (Moderna, Inc, Cambridge, MA), use messenger ribonucleic acid (mRNA) nanotechnology with a lipid-based nanoparticle base. These vaccines were considered by many to be a sign of hope amidst this global pandemic. While this is new technology, preliminary studies have shown it to be both effective with efficacy rates of greater than 95% and safe. Although the rates of anaphylaxis with mRNA vaccines are relatively low (4.7 cases per million doses), it is still believed to be tenfold higher than of prior vaccines.<sup>3,4</sup>

Anaphylaxis is a life-threatening condition that can occur after exposure to any medication, food, vaccine, or environmental trigger. It involves multiple systems including airway, skin, respiratory, and gastrointestinal tract, often presenting with a rash, nausea, shortness of breath, and in severe cases airway swelling. With the SARS CoV-2 vaccine, the majority of cases have presented after administration of the first dose, often within 30 minutes, with 75% of patients presenting in the first 15 minutes. Interestingly, 78% percent of cases occurred after the first dose, and the majority (77% percent) had a history of anaphylaxis. The majority (92%) of cases were treated with epinephrine, and 11% required intubation. While 48% required hospitalization, the average length of stay was 1–3 days.<sup>3</sup> The most recent guidelines have

cautioned against vaccination in those with a history of anaphylaxis, especially to medications or vaccines, as the majority of cases of anaphylaxis after vaccination have occurred in patients with a prior history.<sup>5</sup>

We present a case of a 43-year-old woman with no prior history of anaphylaxis, who had a prolonged anaphylactic reaction to her second Pfizer BioNTech coronavirus disease 2019 (COVID-19) vaccine, requiring a four-day hospital stay. The case is unique not only because the patient had no documented history of anaphylaxis, but also due to the length of symptoms and protracted course.

## CASE REPORT

The patient was a 43-year-old female with no significant past medical history. She received her first Pfizer BioNTech SARS CoV-2 vaccine without incident, and only reported mild fatigue and myalgias afterwards. After she received her second dose of the Pfizer BioNTech COVID-19 vaccine, at the end of her 15-minute observation period she reported a tingling sensation on the back of her tongue. After a short period of further observation and continued symptoms she was brought to the emergency department (ED). On arrival to the ED, she had normal vital signs and no abnormality on physical exam. She was offered steroids and diphenhydramine but declined. Within 15 minutes, she began to cough and complained of tightness in her throat.

On re-evaluation, the patient was noted to have wheezing and edema of her uvula. She was given diphenhydramine, methylprednisolone, and famotidine intravenously (IV), along with IV fluids and albuterol inhaler. After five minutes her symptoms progressed, and she began to vomit, reported worsening throat swelling, and was tachycardic with a heart rate of 150 beats per minute. She was then treated with epinephrine 0.3 milligrams intramuscular (IM) to her deltoid area. However, she continued to wheeze, had uvular swelling, was unable to talk (due to throat swelling), and was noted to be pale, with continued tachycardia. A second dose of epinephrine was given IM (to her deltoid), and within five minutes her wheezing and vomiting resolved, she was able to talk, and reported improvement in throat swelling. She was kept in the ED for two hours of observation, with a continued hoarse voice, subjective tightness in her throat, and noted uvular swelling on exam. Due to the persistence of swelling, she was placed in the observation unit for continued monitoring.

Several hours after arrival to the observation unit, the patient again rapidly developed increased throat tightness, vomiting, and shortness of breath, with wheezing and uvular swelling on exam. She was given additional methylprednisolone and diphenhydramine IV, along with a racemic epinephrine nebulizer and albuterol inhaler. When her symptoms did not improve, she was given a third epinephrine 0.3 milligrams IM (to her thigh). She was transferred to the intensive care unit for further monitoring; however, steroids

### *CPC-EM Capsule*

What do we already know about this clinical entity?

*The SARS-CoV-2 vaccine has been shown to be very safe. Most anaphylactic reactions had a history of prior reactions, unlike our patient who had no history of this.*

What makes this presentation of disease reportable?

*Our case is unique as it was to the second dose, in a patient with no prior history of anaphylaxis. It is also unusual due to the length of the reaction.*

What is the major learning point?

*Patients should be monitored for signs of anaphylaxis, even with no prior history. In addition, clinicians should be aware of the possibility of rebound reactions.*

How might this improve emergency medicine practice?

*Clinicians can counsel patients on the risk of anaphylaxis to this vaccine, and raise awareness of the dangers of rebound and prolonged anaphylactic reactions.*

and diphenhydramine were not further administered that night. She awoke in the morning hospital day (HD) #1, with subjective tightness in her throat, a hoarse voice, and was again noted to have uvular swelling. Later that morning, she began coughing, vomiting, and noted a fine macular rash to her forearms. Physical examination again showed wheezing with increased uvular swelling, along with tachycardia. She was started on diphenhydramine IV every eight hours, methylprednisolone IV every 12 hours, racemic epinephrine nebulizers every four hours, and albuterol inhaler every four hours. She received three racemic epinephrine nebulizers that day due to cough and throat tightness.

The following morning (HD# 2) she was noted to have a diffuse, pruritic macular rash to her chest, arms, and face, and uvular edema was still appreciated. She had two episodes of coughing, throat tightness, and wheezing requiring additional racemic epinephrine nebulizers and diphenhydramine IV. Her methylprednisolone was increased to every eight hours after these episodes, and she was transferred to the telemetry floor. On HD# 3 her cough and wheezing had resolved; however, her rash, sensation of

throat swelling, and uvular swelling persisted. Only one racemic epinephrine nebulizer was given on that day. On HD# 4 wheezing had resolved; however, rash, throat tightness, and hoarse voice continued. Pulmonary consult recommended trial to oral steroids with taper on discharge.

The patient was discharged home on HD# 4 with an epinephrine auto-injector, famotidine, and a prednisone taper. Rash was still present at discharge and did not resolve until two days after discharge. She was seen by her primary care physician (PCP) one week after the initial incident for follow-up, still complaining of throat tightness and a hoarse voice. The PCP visualized minimal edema of the uvula. The following day, she saw an otolaryngologist who performed laryngoscopy; no laryngeal swelling was noted. He recommended continuing famotidine and prednisone, and added a nasal antihistamine. The patient was seen by an allergist three weeks after her initial reaction. Skin tests for polyethylene glycol 3350 (using Miralax) and polysorbate 80 (using Refresh eye drops) were non-reactive. Patch testing was also performed, and negative as well. She was advised to continue to carry an epinephrine auto-injector. She has not had any further reactions to date.

## DISCUSSION

Anaphylaxis is a broad term given to a wide complex of symptoms, often presenting with quickly escalating respiratory or cardiovascular collapse. Less commonly, biphasic reactions can occur, with a recurrence of symptoms most commonly within three to four hours, rarely as late as 12-24 hours after the initial occurrence. Protracted anaphylaxis is even more rare and can present as persistent hypotension lasting for several days. The majority of patients with biphasic reactions presented with the same symptoms as their initial presentation.<sup>6</sup> Patients who presented greater than 30 minutes after exposure were 2.8 times as likely to have a protracted course. Our patient presented with signs of an allergic reaction within 15 minutes but did not devolve into anaphylaxis until almost 30 minutes had elapsed. While she did not develop hypotension, she was noted to have persistent mucous membrane swelling, wheezing, throat tightness, hoarse voice, and a pruritic rash. Her symptoms lasted for almost a week after her initial exposure, which is unusual. While our patient had multiple episodes it is unlikely that this was truly a biphasic reaction, as her symptoms never completely resolved during this time.

It is important that patients be carefully monitored after anaphylaxis for the potential of a second phase or protracted reaction. Failure to identify and correctly treat can lead to recurrent reaction, with potentially fatal consequences.<sup>7</sup> While epinephrine is a mainstay of treatment, other medications are often necessary, including antihistamines and/or glucocorticoids. It is possible that our patient's recurrence and prolonged course was related to glucocorticoids and antihistamines being held the night of her admission, and then

when restarted were at a relatively low dose with twice daily dosing. This theory is somewhat supported as her symptoms improved once she received both medications every eight hours. Prolonged observation (eight to 24 hours) should be recommended in cases with a slow onset of symptoms resulting in severe anaphylaxis, or those with the risk of continued exposure of allergen due to the risk of recurrent reactions.<sup>8</sup> This would apply to our patient, as she had a delayed presentation, and the IM administration of a vaccine should raise concern for continued exposure.

The Vaccine Adverse Event Reporting System is used in the United States to monitor adverse reactions, including anaphylaxis to the SARS-CoV-2 vaccines. While 175 cases of severe allergic reactions had been reported, only 21 were determined to be anaphylaxis. The majority experienced symptoms within 15 minutes, and 90% were treated with epinephrine. While 90% of cases were treated in the ED, only 20% required hospitalization. Fortunately, 95% of cases reported recovering with no adverse effects, and there were no reported deaths. The median age was 43, and 81% had a history of prior allergic reaction. Interestingly, 90% of anaphylaxis occurred in women, but this may be related to a higher percentage of women receiving the vaccine.<sup>2</sup> Our 43-year-old patient had no history of anaphylaxis and had several episodes of recurrent symptoms during her four-day hospital stay.

## CONCLUSION

The development of vaccines against SARS-CoV-2 has been a source of hope in the global pandemic. While the vaccine was rapidly developed, studies have demonstrated not only is it efficacious in preventing death and severe disease, but it is also extremely safe. Despite this there have been several reported episodes of anaphylaxis. The majority of those patients had a history of anaphylaxis and developed symptoms shortly after vaccine administration. While most cases of anaphylaxis were treated with epinephrine, the vast majority were able to be discharged home. Our case is unique in that it occurred in a patient with no known history of anaphylaxis, who had a protracted case requiring a four-day hospitalization. Fortunately, our patient recovered, and has had no long-term complications from this event.

The authors attest that their institution requires neither Institutional Review Board approval nor patient consent for publication of this case report. Documentation on file.

---

*Address for Correspondence:* Lisa Armstrong, MD, RWJBH-Community Medical Center, Department of Emergency Medicine, 99 Highway 37 West, Toms River, New Jersey 08755. Email: lisa.armstrong2@rwjbh.org.

*Conflicts of Interest:* By the CPC-EM article submission agreement, all authors are required to disclose all affiliations,



funding sources and financial or management relationships that could be perceived as potential sources of bias. The authors disclosed none.

*Copyright:* © 2022 Armstrong. This is an open access article distributed in accordance with the terms of the Creative Commons Attribution (CC BY 4.0) License. See: <http://creativecommons.org/licenses/by/4.0/>

## REFERENCES

1. Johns Hopkins University & Medicine. COVID-19 Dashboard by the Center for Systems Science and Engineering (CCSE) at Johns Hopkins University (JHU). Available at: <https://coronavirus.jhu.edu/map.html>. Accessed August 25, 2021.
2. CDC COVID-19 Response Team, Food and Drug Administration. Allergic reactions including anaphylaxis after receipt of the first dose of the Pfizer-BioNTech COVID-19 Vaccine – United States, December 14-23, 2020. *MMWR Morb Mortal Wkly Rep.* 2021;70(2):46-51.
3. Shimabukuro TT, Cole M, Su JR. Reports of anaphylaxis after receipt of mRNA COVID-19 vaccines in the US—December 14, 2020–January 18, 2021. *JAMA.* 2021;325(11):1101-2.
4. Castells MC and Phillips E. Maintaining safety with SARS-CoV2 vaccines. *N Engl J Med.* 2021;384(7):643-9.
5. Caminati M, Guarnieri G, Senna G. Who is really at risk of anaphylaxis due to COVID-19 vaccine? *Vaccines.* 2021;9(1):38-40.
6. Stark BE and Sullive TJ. Biphasic and protracted anaphylaxis. *J Allergy Clin Immunol.* 1986;78(1 Pt 1):76-83.
7. Ellis AK and Day JH. Diagnosis and management of anaphylaxis. *CMAJ.* 2003;169(4):307-12.
8. Kemp SF. The post-anaphylaxis dilemma: How long is long enough to observe a patient after resolution of symptoms? *Curr Allergy Asthma Rep.* 2008;8(1):45-8.

# Managing Subarachnoid Hemorrhage Precipitated by Anesthesia-assisted Rapid Opioid Detoxification: A Case Report

Michael F. Sobin, MD  
Liem Ngo, MD  
Danielle Turner-Lawrence, MD  
Abigail Kirwen, PharmD

Beaumont Health-Royal Oak, Department of Emergency Medicine, Royal Oak, Michigan

Section Editor: Rachel Lindor, MD, JD

Submission History: Submitted June 26, 2021; Revision received September 20, 2021; Accepted September 28, 2021

Electronically published January 6, 2022

Full text available through open access at [http://escholarship.org/uc/uciem\\_cpsem](http://escholarship.org/uc/uciem_cpsem)

DOI: 10.5811/cpcem.2021.9.53868

**Introduction:** Anesthesia-assisted rapid opioid detoxification (AAROD) is a controversial method of treating opioid dependence that involves sedating patients during a period of provoked withdrawal. Reported adverse outcomes of the procedure demonstrate the importance of recognizing the potential complications of AAROD.

**Case Presentation:** We present a case of a 41-year-old male presenting with a subarachnoid hemorrhage following an AAROD procedure.

**Conclusion:** This case report and discussion reviews the pathophysiology of opioid withdrawal syndrome, potential complications following AAROD, and important management considerations. [Clin Pract Cases Emerg Med. 2022;6(1):37-40.]

**Keywords:** *case report; anesthesia; opioid withdrawal; subarachnoid hemorrhage.*

---

## INTRODUCTION

Emergency department (ED) visits and hospitalizations for opioid withdrawal have occurred at an increasing rate over the past 20 years.<sup>1</sup> Treatment of symptomatic withdrawal and opioid dependence have been subjects of research for the past three decades.<sup>2</sup> One such method involves acutely precipitating withdrawal with opioid antagonists while ameliorating the symptoms using sedatives, a treatment known as anesthesia-assisted rapid opioid detoxification (AAROD). This treatment method, while sought after for its perceived ease and short course, has been found to provide inconsistent rates of opioid abstinence while being costlier and riskier compared to available alternatives.<sup>2</sup> Additionally, little is known about how to manage adverse effects of AAROD in the ED setting. Here, we present a case describing the emergent treatment of a patient with subarachnoid hemorrhage after AAROD.

## CASE REPORT

A 41-year-old male with history of opioid and cocaine use disorders was brought to the ED after being found unresponsive at an opioid detoxification center. The day prior to admission, the patient underwent an observed AAROD where he received buprenorphine while undergoing general anesthesia. After completion of treatment the patient was transferred to a local center where he was observed by onsite staff, receiving as-needed benzodiazepines for any continued withdrawal symptoms. Subsequently, the patient began to complain of a severe headache and ataxia and exhibited agitated behavior. Early the following morning he was found unresponsive and in respiratory distress. Emergency medical services administered naloxone without a change in his condition. A laryngeal mask airway was placed, and he was transported to the ED.

Upon arrival, the patient's vitals were heart rate 152 beats per minute, blood pressure 162/101 millimeters (mm) of mercury, respiratory rate 64 breaths per minutes, oxygen saturation 100% on 15 liters of oxygen via a nonrebreather, and temperature 37.9 Celsius. The patient was diaphoretic and had a Glasgow Coma Scale score of three. His head was atraumatic, and his pupils were 3 mm and reactive bilaterally. He had significant upper airway secretions, and lung auscultation revealed diffuse bilateral rhonchi. His peripheral pulses were bounding and his skin was mottled and pale. There was no evidence of traumatic injury. After he failed to improve with an additional dose of naloxone, the patient was sedated and intubated.

An initial electrocardiogram (ECG) revealed supraventricular tachycardia that failed to convert with administration of multiple doses of adenosine. Initial labs were notable for a pH of 7.17, lactic acid of 8.0 millimoles per liter (mmol/L) (reference range: 0.5 – 2.0 mmol/L), white blood cell count of 37.1 billion per liter (bil/L) (3.5 – 10.1 bil/L) with left shift, and troponin of 16.38 nanograms per milliliter (ng/mL) (<0.3 ng/mL). Chest radiograph was significant for diffuse pulmonary edema. A non-contrast head computed tomography (CT) revealed extensive subarachnoid hemorrhage and right temporal intraparenchymal hemorrhage with 5 mm of midline shift. A CT angiogram revealed a 3-mm right internal carotid artery aneurysm as the source of the bleeding. Treatment with continuous nicardipine infusion was initiated, and neurosurgery placed an external ventricular drain in the ED.

The patient was admitted to the surgical intensive care unit for aneurysmal repair. Further conversation with family indicated no family history suggestive of cerebral aneurysmal disease or known preceding symptoms. His procedure, completed successfully, was complicated by a four-minute episode of pulseless electrical activity cardiac arrest. He subsequently developed a right middle cerebellar artery infarct with evidence of herniation. With poor neurologic prognosis, the family chose comfort measures, and the patient died on hospital day three.

## DISCUSSION

Opioid use disorder in the United States remains at an all-time high, with hospitalization rates increasing 219% between 1998 (58.9 per 100,000) and 2016 (190.7 per 100,000).<sup>1</sup> Opioid withdrawal is a complicated neurobiological interaction caused by the decreased responsiveness of opioid receptors in the brain from chronic use. In the locus coeruleus, periaqueductal gray and rostral ventromedial medulla the lack of mu opioid response leads to an overwhelming surge of noradrenaline and other monoamines.<sup>3</sup> These surges produce electrolyte derangements and respiratory alkalosis, which have been linked to episodes of cardiac arrest and seizure in previous opioid withdrawal cases.<sup>4,5</sup> Outside of opioid withdrawal, massive catecholamine surges have been

### *CPC-EM Capsule*

What do we already know about this clinical entity?

*Anesthesia-assisted rapid opioid detoxification (AAROD) is a rare treatment method of opioid use disorder with reported significant procedural complications.*

What makes this presentation of disease reportable?

*This is the first reported case in the literature of AAROD complicated by subarachnoid hemorrhage.*

What is the major learning point?

*Treatment of AAROD complications is based on reducing opioid withdrawal symptoms from the pathologic sympathetic surge while providing long-acting opioid agonists.*

How might this improve emergency medicine practice?

*Early recognition and prompt treatment of AAROD complications may lead to improved outcomes in these patients.*

documented as possible precipitants of subarachnoid hemorrhage.<sup>6</sup> Historically, treatment regimens focused on treating the acute sympathetic overdrive with alpha-2 agonists and benzodiazepines and weaning patients with long-acting opioid agonists such as methadone and buprenorphine.<sup>7</sup> However, concerns of limited availability and length of treatment have continued to push researchers and clinicians to search for additional strategies.<sup>8</sup>

In the 1990s, the combination of difficulties prescribing long-acting opioids and the desire for a faster resolution of opioid withdrawal symptoms led clinicians to investigate opioid withdrawal induction in conjunction with sedation.<sup>8</sup> The method described, known as AAROD, involves precipitating withdrawal using various opioid antagonists while sedating or anesthetizing patients to mask withdrawal symptoms. Although pre-procedure evaluations are not standardized, a general medical exam, blood work, ECG, and urine drug screen are often employed.<sup>2</sup> Patients are typically excluded if there has been recent cocaine use or significant medical or psychiatric disease history.<sup>2</sup> While initial studies did show the effectiveness of AAROD in transitioning patients to opioid abstinence.<sup>9</sup> over the 20 years of its use additional concerns have been raised on the safety and efficacy of AAROD.<sup>10-12</sup>

A randomized clinical trial examining AAROD vs buprenorphine and clonidine alone found equivalent rates of opioid abstinence, while AAROD conferred significantly increased patient risks such as acute psychiatric disturbances, cardiac arrhythmias, and pulmonary edema.<sup>2</sup> A 2013 report from the US Centers for Disease Control and Prevention detailed one New York City AAROD clinic where seven of 75 patients experienced serious adverse events requiring hospitalization with two resultant deaths.<sup>10</sup> Additionally, two Cochrane reviews found AAROD to be equally effective compared to traditional treatment options but with significantly higher mortality, out-of-pocket patient cost, and medicolegal risk; the reviews recommended avoidance of the technique.<sup>11,12</sup> Currently, only methadone and buprenorphine have shown consistent evidence for effective treatment of opioid use disorders, with superior rates of long-term opioid abstinence compared to AAROD, abstinence alone, naltrexone, alpha agonists, and benzodiazepines.<sup>2,14</sup> Yet numerous AAROD programs still exist across the country.

Clinicians should maintain a broad differential when approaching critically ill patients after AAROD. Evaluations should focus on potential neurologic, cardiac, electrolyte, and metabolic abnormalities. Reported complications from the procedure include the following: those due to opioid withdrawal symptoms, such as vomiting, diarrhea, hypovolemia and electrolyte abnormalities; those related to adverse effects of the resultant catecholamine surge; and complications arising from general anesthesia.<sup>4,5</sup> Documented adverse outcomes of AAROD include severe psychiatric disturbances, aspiration, cardiac dysrhythmias, cardiac arrest, respiratory arrest and death.<sup>10-12</sup>

In our literature review, we did not find any previously documented cases of subarachnoid hemorrhage following AAROD. Management should focus on reducing withdrawal symptoms, decreasing the catecholamine surge, and providing additional supportive care as necessary. Clonidine has been used to reduce sympathomimetic hyperactivity. Adding short-acting opioid analgesics or increasing the frequency of long-acting opioids are additional options.<sup>13</sup> Pain management, which can be complicated by the type and level of opioid antagonist used in the AAROD procedure, can be achieved by non-opioid means including intravenous acetaminophen, dexmedetomidine, and gabapentin.<sup>15</sup> Early utilization of these management options may confer improved outcomes for critically ill post-AAROD patients.

## CONCLUSION

Anesthesia-assisted rapid opioid detoxification is an uncommon and controversial procedure used to treat opioid use disorder. This case of subarachnoid hemorrhage precipitated by AAROD to our knowledge represents the first such documented instance in the literature. Clinicians seeing patients brought to the ED after AAROD should be aware of the potential for serious complications as outlined here.

Strategies for managing AAROD complications focuses on supportive care while decreasing withdrawal symptoms and sympathetic surge. In addition, clinicians should remain educated on best practices of opioid use disorder management including methods for using and referring for buprenorphine and methadone treatments.

The authors attest that their institution requires neither Institutional Review Board approval nor patient consent for publication of this case report. Documentation on file.

*Address for Correspondence:* Michael F. Sobin, MD, Beaumont Health-Royal Oak, Department of Emergency Medicine, 3601 W. Thirteen Mile Road, Royal Oak, Michigan 48703. Email: Michael.sobin@beaumont.org.

*Conflicts of Interest:* By the *CPC-EM* article submission agreement, all authors are required to disclose all affiliations, funding sources and financial or management relationships that could be perceived as potential sources of bias. The authors disclosed none.

*Copyright:* © 2022 Sobin. This is an open access article distributed in accordance with the terms of the Creative Commons Attribution ([CC BY 4.0](http://creativecommons.org/licenses/by/4.0/)) License. See: <http://creativecommons.org/licenses/by/4.0/>

## REFERENCES

1. Singh JA and Clavland JD. National U.S. time-trends in opioid use disorder hospitalizations and associated healthcare utilization and mortality. *PLoS One*. 2020;15(2):e0229174.
2. Collins ED, Kleber HD, Whittington RA, et al. Anesthesia-assisted vs buprenorphine or clonidine-assisted heroin detoxification and naltrexone induction: a randomized trial. *J Am Med Assoc*. 2005;294(8):903-13.
3. Kosten TR and George TP. The neurobiology of opioid dependence: implications for treatment. *Sci Pract Perspect*. 2002;1(1):13-20.
4. Kugasia IR and Shabarek N. Opiate withdrawal complicated by tetany and cardiac arrest. *Case Reports Crit Care*. 2014;2014:1-4.
5. Darke S, Larney S, Farrell M. Yes, people can die from opiate withdrawal. *Addiction*. 2017;112(2):199-200.
6. Haddad YW, Korcari E, Polsinelli GN, et al. The effect of cocaine and methamphetamine on saccular aneurysm formation and rupture: a literature review. *Brain Hemorrhages*. 2020;2(3):111-5.
7. Kleber HD. Neuropsychiatric manifestations of neurodegenerative disease. *Dialogues Clin Neurosci*. 2007;9(2):455.
8. Bearn J, Gossop M, Strang J. Rapid opiate detoxification treatments. *Drug Alcohol Rev*. 1999;18(1):75-81.
9. Gold CG, Cullen DJ, Gonzales S, et al. Rapid opioid detoxification during general anesthesia: a review of 20 patients. *Anesthesiology*. 1999;91(6):1639-47.
10. Centers for Disease Control and Prevention (CDC). Deaths and severe adverse events associated with anesthesia-assisted rapid



- opioid detoxification--New York City, 2012. *MMWR Morb Mortal Wkly Rep.* 2013;62(38):777-80.
11. Gowing L, Ali R, White JM. Opioid antagonists with minimal sedation for opioid withdrawal. *Cochrane Database Syst Rev.* 2017;2017(5):CD002021.
  12. Gowing L, Ali R, White JM. Opioid antagonists under heavy sedation or anaesthesia for opioid withdrawal. *Cochrane Database Syst Rev.* 2010;(1):CD002022.
  13. Alford DP, Compton P, Samet JH. Acute pain management for patients receiving maintenance methadone or buprenorphine therapy. *Ann Intern Med.* 2006;144(2):127-34.
  14. Schuckit MA. Treatment of opioid-use disorders. *N Engl J Med.* 2016;375(16):1596-7.
  15. Rasouli J, Watson C, Yaeger K, et al. Pain control after aneurysmal subarachnoid hemorrhage: a contemporary literature review. *J Clin Neurosci.* 2019;68:9-12.

# Leveraging Resources to Remove a Taser Barb Embedded in Bone: Case Report

Lauren Willoughby, MD  
Kelee Peyton, MD  
Diane Gorgas, MD  
Simiao Li-Sauerwine, MD, MS

The Ohio State University, Department of Emergency Medicine, Columbus, Ohio

Section Editor: R. Wilkerson, MD

Submission History: Submitted July 19, 2021; Revision received October 14, 2021; Accepted October 16, 2021

Electronically published January 28, 2022

Full text available through open access at [http://escholarship.org/uc/uciem\\_cpem](http://escholarship.org/uc/uciem_cpem)

DOI: 10.5811/cpem.2021.10.54196

**Introduction:** Conducted electrical weapons, commonly known by their proprietary eponym, TASER, are frequently used by law enforcement. A review of the literature yielded descriptions of taser barb removal from soft tissue and surgical intervention for barbs lodged in sensitive areas such as the eye and head, but not from other osseous sites.

**Case Report:** We report the case of a 30-year-old male transferred from another hospital with a taser dart embedded in his clavicle. Prior attempts at bedside removal had been unsuccessful. We describe bedside removal of the taser barb from bone using local anesthesia and simple fulcrum technique.

**Conclusion:** We describe a novel fulcrum technique for removal of a taser dart embedded in bone. This is a reasonable technique to attempt in patients with involvement of superficial osseous structures to avoid operative intervention. [Clin Pract Cases Emerg Med. 2022;6(1):41-43.]

**Keywords:** *conducted electrical weapon; taser; foreign body removal; fulcrum technique; case report.*

## INTRODUCTION

The conducted electrical weapon was invented in 1974 by Jack Cover, a former National Aeronautics and Space Administration researcher. He named the device TASER (Axon Enterprise, Inc., Scottsdale, AZ) after the 1911 children's science fiction book *Tom Swift and His Electric Rifle*. These devices have remained popular as a less-lethal tool in law enforcement and self-defense when compared to traditional firearms. When activated, a taser fires two darts from a cartridge via compressed nitrogen canister at 55 meters per second and has a range of 15-35 feet. Each dart is made of a fish-hook barb on a metal shaft attached to a metal and plastic cylinder that is then connected to the taser by thin copper wires. An electrical pulse can then be delivered between the darts, causing contraction of skeletal muscle and incapacitating the target.<sup>1</sup>

Although the size of the dart (9.5 millimeters [mm] long, 0.8 mm diameter) often prevents clinically significant depth of penetration, the fish-hook barb is designed so that darts will lodge in place upon impact. Three methods for removal were described previously by Koscove in 1985: 1) grasp the wire or

dart firmly and pull it out with in-line traction; 2) cover the barb with a 16 G needle and then withdraw the dart in a method similar to fish-hook removal; and 3) prep the skin and administer local anesthetic prior to cutting down to the barb and removing it through the incision.<sup>2</sup>

We were unable to find any current literature comparing or documenting the efficacy of these strategies, although one article did advise in-line traction as the first step.<sup>3</sup> However, the methods described by Koscove are intended specifically for the removal of darts embedded in skin or soft tissue. For darts embedded in other sensitive regions (most often defined as the face, groin, breast, eye, or head), operative or specialist intervention is often recommended.<sup>4</sup> To our knowledge, no bedside strategy for the removal of taser darts embedded in bone has been described.

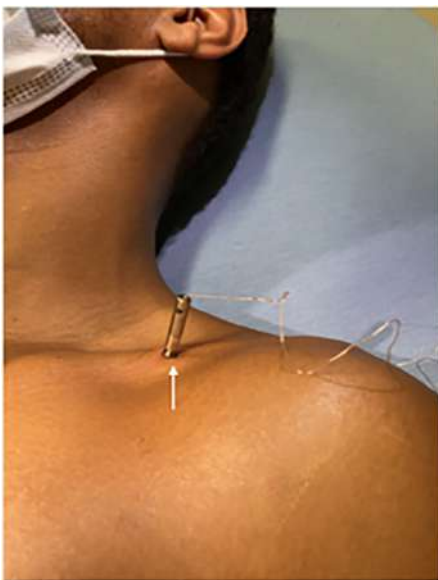## CASE REPORT

A 30-year-old male presented with a taser dart embedded in his left clavicle. He was initially seen at another hospital and multiple attempts were made to remove the dart after administration of local anesthetic (1% lidocaine without

epinephrine) and manual in-line traction along the axis of the dart, perpendicular to the clavicle. These attempts had been unsuccessful despite the patient tolerating the procedure well and reporting minimal discomfort. He was ultimately transferred to our institution for further management and possible surgical evaluation.

On arrival to the emergency department, the patient's physical exam showed the taser barb still lodged in his clavicle but with no active bleeding or other soft tissue injury (Image 1). Additionally, no neurovascular deficits were identified. A repeat radiograph of the clavicle showed the barb embedded approximately 4 mm into the clavicle with a small hook deformity of the barb tip, but no associated fractures. To avoid surgery and with consent of the patient, bedside removal was again attempted.

Prior to the procedure, ketorolac 15 milligrams was administered intravenously. The surrounding skin was prepped with a betadine solution. Anesthesia was achieved via local infiltration of a 50/50 mixture of 1% lidocaine and 0.5% bupivacaine without epinephrine at the periosteum and along the track of the barb. The patient reported excellent pain relief and complete anesthesia at the site of the clavicular foreign body. A pair of vise-grip locking pliers was then used to grasp the metal cylinder, and a 10-cubic centimeter (cc) syringe was placed under the pliers, adjacent to the cylinder. The syringe was used as a fulcrum to lever the barb out of the bone (Image 2). The taser barb was easily removed and the patient tolerated the procedure with no bleeding or additional trauma noted to the surrounding soft tissues. A post-procedure radiograph showed no fracture but did demonstrate a small retained foreign body of the taser-barb tip in the clavicle.



**Image 1.** Taser barb embedded in the left, anterior, mid clavicle (white arrow).

### *CPC-EM Capsule*

What do we already know about this clinical entity?

*Bedside removal of taser barbs from soft tissue sites and surgical intervention for barbs lodged in sensitive locations have been previously described.*

What makes this presentation of disease reportable?

*We describe bedside removal of a taser barb percutaneously embedded in an osseous site.*

What is the major learning point?

*An alternative to in-line traction is the use of a syringe as a fulcrum, which leverages clinician effort when removing a taser dart from an osseous site.*

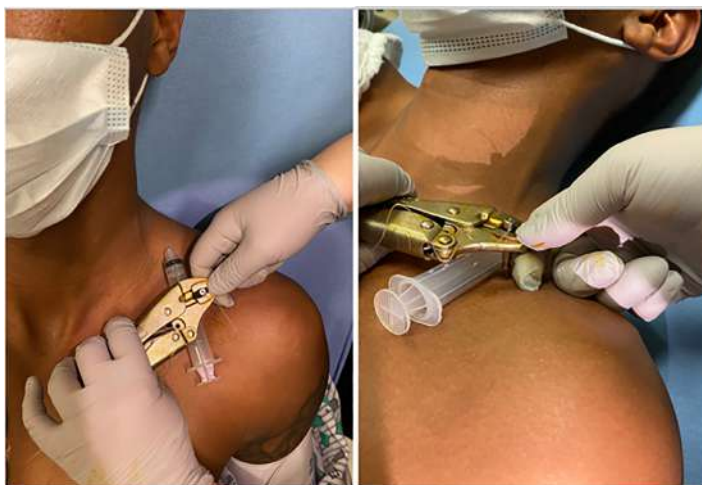How might this improve emergency medicine practice?

*Using the fulcrum method allows for greater likelihood of success for bedside removal of a taser barb and may eliminate the need for operative management.*

Local wound care was administered, and a seven-day course of cephalexin was prescribed for prophylaxis in the setting of penetrating trauma involving the bone. The patient's tetanus status was confirmed to be up to date. He was then discharged in stable condition.

### **DISCUSSION**

Currently there is a paucity of literature addressing strategies for removal of taser barbs. Most reports focus on cases of ocular and cranial penetration, which are relatively rare and almost always require immediate specialist intervention.<sup>3</sup> Due to lack of available data, it is not clear how often emergency physicians remove these barbs from patients. One study in Salt Lake City, Utah, identified 648 emergency medical service (EMS) activations over five years for the indication of taser barb removal, indicating that this is a relatively rare procedure with a prevalence of 4.55 per 1,000,000 EMS activations.<sup>5</sup> However, it should also be noted that there is significant regional variance in removal policies. While some EMS agencies have protocols for dart removal, others prohibit emergency medical technicians from doing so in the field. As the use of tasers has become more widespread



**Image 2.** Vise-grip locking pliers were used to grasp the metal cylinder, and a 10-cc\* syringe was placed below the pliers to act as a fulcrum when downward pressure was applied to the plier handles.

\*cc, cubic centimeter.

over the years, there is an ongoing need for emergency physicians to be trained in taser-related injuries.

In our case, the traditional in-line traction method had been attempted previously and was unsuccessful, likely due to depth of osseous penetration. For this presentation, it was not practical to use the removal methods described by Koscove. Ultimately, our use of the 10-cc syringe as a fulcrum allowed us to gain sufficient leverage on the dart for removal. This had the benefit of averting the need for operative intervention and potential associated risks of surgery. Additionally, the administration of local and periosteal anesthetic in conjunction with intravenous analgesics was found to be sufficient to achieve pain control and eliminated the need for conscious sedation.

While there were no immediate complications from our procedure, we identified several potential considerations in choosing this method. We recommend assessing the appropriateness of the location over which the syringe will be placed, to decrease the likelihood of injury to underlying structures or exacerbating previously existing injuries such as fractures. Additionally, care must be taken to protect the free hand stabilizing the dart to prevent the clinician from being injured by the barb as it is pulled free of the patient. Our patient's tetanus status was up to date, but out of an abundance of caution we decided to administer prophylactic antibiotics given the presence of a retained foreign body and penetrating

injury to the bone. Unfortunately, our patient was lost to follow-up; so it is unclear what his ultimate outcome was and whether secondary infection occurred.

## CONCLUSION

We describe an alternative method for the removal of taser darts embedded in bone. This strategy was ultimately effective after the traditional methods of removal by in-line traction proved to be insufficient. While it is no substitute for expert consultation in circumstances where the dart has become embedded in sensitive areas, we feel it is reasonable to attempt in patients with osseous involvement as it may help avoid the risks of operative intervention.

Patient consent has been obtained and filed for the publication of this case report.

*Address for Correspondence:* Simiao Li-Sauerwine, MD, MS, The Ohio State University, Department of Emergency Medicine, 775 Prior Hall, 376 W 10<sup>th</sup> Ave., Columbus, OH 43210. Email: simiao.li-sauerwine@osumc.edu.

*Conflicts of Interest:* By the *CPC-EM* article submission agreement, all authors are required to disclose all affiliations, funding sources and financial or management relationships that could be perceived as potential sources of bias. The authors disclosed none.

*Copyright:* © 2022 Willoughby. This is an open access article distributed in accordance with the terms of the Creative Commons Attribution ([CC BY 4.0](http://creativecommons.org/licenses/by/4.0/)) License. See: <http://creativecommons.org/licenses/by/4.0/>

## REFERENCES

1. Robb M, Close B, Furyk J, et al. Review article: emergency department implications of the TASER. *Emerg Med Australas.* 2009;21(4):250-8.
2. Koscove, EM. The taser weapon: a new emergency medicine problem. *Ann Emerg Med.* 1985;14(12):1205-8.
3. Pasquier M, Pierre-Nicolas C, Vallotton L, et al. Electronic control device exposure: a review of morbidity and mortality. *Ann Emerg Med.* 2011;58(2):178-88.
4. Magnus BE, Shen LY, Helmer SD, et al. Taser and taser associated injuries: a case series. *Am Surg.* 2008;74(9):862-5.
5. El Sayed M, El Tawil C, Tamim H, et al. Emergency medical services experience with barb removal after taser use by law enforcement: a descriptive national study. *Prehosp Disaster Med.* 2019;34(1):38-45.



# Abilifright: A Case Report of Massive Aripiprazole Overdose in a Toddler

Nicholus M. Warstadt, MD\*  
Sanjay Mohan, MD†  
Emma R. Furlano, MD†  
Jennifer H. Shenker, MD‡  
Eric P. Gibbs, MD‡  
Silas W. Smith, MD†,§

\*New York University Grossman School of Medicine, Ronald O. Perelman Department of Emergency Medicine, New York, New York  
†New York University Grossman School of Medicine, Ronald O. Perelman Department of Emergency Medicine, Division of Medical Toxicology, New York, New York  
‡New York University Grossman School of Medicine, Department of Pediatrics, New York, New York  
§New York University Grossman School of Medicine, Institute for Innovations in Medical Education, New York, New York

Section Editor: Steven Walsh, MD

Submission History: Submitted August 24, 2021; Revision received October 14, 2021; Accepted October 15, 2021

Electronically published January 28, 2022

Full text available through open access at [http://escholarship.org/uc/uciem\\_cpccem](http://escholarship.org/uc/uciem_cpccem)

DOI: 10.5811/cpcem.2021.10.54520

**Introduction:** Aripiprazole is an atypical antipsychotic with unique receptor-binding properties that has a favorable safety profile in therapeutic doses compared to other antipsychotics. Massive aripiprazole overdose in children, however, presents with profound lethargy and may have neurologic, hemodynamic, and cardiac effects, often requiring admission to a high level of care.

**Case Report:** We describe a case of a 21-month-old male with a reported 52-milligram aripiprazole ingestion. Initial vital signs were remarkable for tachycardia and hypertension, which rapidly resolved. The patient did not develop hypotension throughout hospitalization. He experienced 60 hours of lethargy. Irritability associated with upper extremity spasms and tremors occurred from 36-72 hours post ingestion, which resolved without intervention. The initial electrocardiogram demonstrated ST-segment depressions in the anteroseptal leads; further cardiac workup was normal. Concurrent medical workup was unrevealing. Aripiprazole and dehydro-aripiprazole serum concentrations sent 46 hours after reported exposure were 266.5 nanograms per milliliter (ng/mL) and 138.6 ng/mL, respectively. He returned to neurologic baseline and was discharged 72 hours after ingestion.

**Conclusion:** Antipsychotics, including aripiprazole, should be considered as a potential toxicological cause of persistent central nervous system depression; ingestion of a single dose has the potential to cause significant toxicity. [Clin Pract Cases Emerg Med. 2022;6(1):44-48.]

**Keywords:** *atypical antipsychotic; aripiprazole; overdose; pediatrics; toxicology; emergency medicine.*

## INTRODUCTION

Aripiprazole has become a commonly prescribed antipsychotic due to its broad indications and tolerability. Unlike other antipsychotics, extrapyramidal symptoms (EPS) and QT interval prolongation are rarely observed with appropriate use. In the few cases of pediatric aripiprazole overdose, prolonged lethargy is common, EPS and hypotension are infrequent, electrocardiographic effects are rare, and no cardiac death has been reported. We describe a

case of a 21-month-old male with a large, confirmed aripiprazole overdose complicated by prolonged lethargy, EPS, and possible electrocardiogram (ECG) changes, although baseline ECG was not available for comparison. This report contributes to the understanding that pediatric aripiprazole overdose may present with profound and long-lasting lethargy and EPS. To our knowledge this is the first case report to describe self-limiting spasticity and abnormal ECG findings following confirmed ingestion.

## CASE REPORT

A previously healthy ex-full term, unimmunized, 21-month-old male presented to the pediatric emergency department with lethargy in the setting of an unwitnessed ingestion. Twenty-six two-milligram (mg) aripiprazole tablets were missing from a pill container prescribed for another household member. The ingestion occurred approximately six hours prior to presentation, with subsequent onset of lethargy at the home 2-3 hours later. On presentation, vital signs were as follows: heart rate 151 beats per minute; blood pressure 144/92 millimeters of mercury (mm Hg); respiratory rate 28 breaths per minute; rectal temperature 36.1° Celsius; room air digital oximetry 98%; and weight 12.2 kilograms (kg). Venous blood glucose was 147 mg per deciliter (mg/dL) (normal range 70-99 mg/dL). On initial evaluation, he was lethargic but arousable to physical stimulation. There was no atony, rigidity, tremor, clonus, or spasticity. Bowel sounds were present but decreased. He voided spontaneously. The remainder of the physical examination was unremarkable.

Laboratory analysis, including venous blood gas, complete blood count, electrolytes, hepatic panel, and creatine kinase were normal. Serum acetaminophen, salicylate, ethanol, and troponin concentrations were undetectable. An ECG revealed sinus tachycardia with a heart rate of 160 beats per minute, a QRS interval of 70 milliseconds (ms), and a QTc interval of 359 ms, corrected with Bazett's formula.<sup>1</sup> ST-segment depressions were present in the anteroseptal leads (Image). Activated charcoal (AC) was not administered due to sedation and decreased bowel sounds. He was admitted to the pediatric intensive care unit for neurologic and cardiovascular monitoring.

The patient's tachycardia and hypertension resolved within four hours of presentation. The abnormal ECG prompted pediatric cardiology consultation. A transthoracic echocardiogram on hospital day one was normal. QRS and

### *CPC-EM Capsule*

What do we already know about this clinical entity?

*Aripiprazole overdose in young pediatric patients presents with lethargy. Additional neurologic symptoms and cardiovascular effects are occasionally reported.*

What makes this presentation of disease reportable?

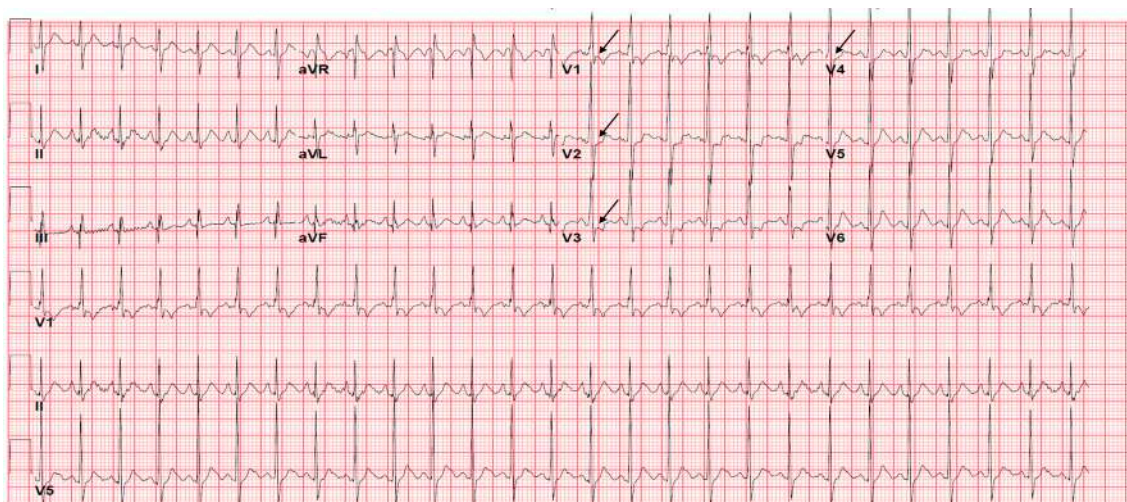
*The relatively large ingestion, prolonged lethargy, and occurrence of extrapyramidal symptoms in this patient add to the understanding of aripiprazole's toxidrome.*

What is the major learning point?

*Given existing dosing formulations, ingestion of one pill of aripiprazole has the potential to cause severe symptoms in a pediatric patient.*

How might this improve emergency medicine practice?

*This report may help emergency physicians, toxicologists, pediatricians, and intensivists manage pediatric patients with known or suspected aripiprazole overdose.*



**Image.** Electrocardiogram shows sinus tachycardia at 160 beats per minute. The QRS complex is 77 milliseconds (ms), and the corrected QT interval is 359 ms by the Bazett method. ST-segment depressions are noted throughout the anteroseptal leads (black arrows).

QTc intervals remained within normal limits throughout the hospitalization. The ECG ST-segment depressions persisted at discharge 72 hours after ingestion. Upon discharge, the child was scheduled for a pediatric cardiology clinic appointment to obtain a repeat ECG, but he was lost to follow up.

Decreased level of consciousness persisted for 60 hours post ingestion. He was initially lethargic; then he became more arousable but still slept excessively, before gradually returning to baseline alert state. Starting 36 hours post ingestion, while awake, he was noted to have coarse tremors, worsened with intention, and spasticity of the bilateral upper extremities. While he was asleep, the tremors and spasticity resolved, and he otherwise had normal tone. Pupils were 3 mm, equal and briskly reactive. Hyperreflexia was present in both patellar tendons, without clonus.

Pediatric neurology consultants evaluated other etiologies of the abnormal neurologic exam. Brain non-contrast computed tomography and a 24-hour video electroencephalogram performed on hospital day two were normal. The patient's tremors and spasticity resolved 72 hours after reported ingestion, and he was at neurologic baseline. Lumbar puncture was deferred due to return to baseline. A social work safety assessment was performed at hospital discharge. Parental education reinforced supervision and safe medication storage.

Aripiprazole and dehydro-aripiprazole serum concentrations obtained approximately 46 hours after reported ingestion (on hospital day two) were 266.5 ng/mL (proposed therapeutic range 150-300 ng/mL)<sup>2</sup> and 138.6 ng/mL, respectively (ARUP Laboratories, Salt Lake City, UT), confirming aripiprazole exposure.

## DISCUSSION

Aripiprazole is an atypical antipsychotic, differing from other medications in class due to its unique receptor binding properties. Aripiprazole is indicated to treat schizophrenia, bipolar 1 disorder, irritability associated with autism spectrum disorder, Tourette syndrome, and tic disorders in pediatric patients.<sup>3</sup> First- and second-generation antipsychotics exert much of their effect through dopamine D<sub>2</sub> receptor antagonism.<sup>4</sup> In contrast, aripiprazole's mechanism results from its partial agonist activity at dopamine D<sub>2</sub> and serotonin 5-HT<sub>1A</sub> receptors and antagonism at 5-HT<sub>2A</sub> receptors, with which the drug binds with high affinity.

Aripiprazole has low affinity for alpha-1-adrenergic and histamine H<sub>1</sub> receptors. Aripiprazole elimination mainly occurs through hepatic metabolism involving P450 isozymes CYP2D6 and CYP3A4. The major metabolite, dehydro-aripiprazole, has similar D<sub>2</sub> receptor affinity. Oral bioavailability is 87%; mean elimination half-lives of aripiprazole and dehydro-aripiprazole are approximately 75 hours and 94 hours, respectively. The mean elimination aripiprazole half-life in CYP2D6 poor metabolizers increases to 146 hours.<sup>3</sup> Aripiprazole has a high volume of distribution (4.9 liters per kg), indicating extensive extravascular

distribution, and greater than 99% of parent drug and its active metabolite are protein bound, particularly albumin. Due to high affinity at central nervous system (CNS) D<sub>2</sub> and D<sub>3</sub> receptors, drug dissociation is slow. Toxicokinetics in overdose likely result in prolonged target receptors saturation, as suggested by reports of persistent neurologic sequelae that have followed single, large ingestions.

Neurologic toxicity, particularly lethargy, has been reported as a defining feature in pediatric aripiprazole overdose cases. Several reports describe lethargy in toddlers lasting from 30 hours to seven days.<sup>5-9</sup> Lethargy may be encountered with therapeutic dosing when titration is not performed. One report described a nine-year-old girl with lethargy for 48 hours after starting aripiprazole (15 mg) without dose titration.<sup>10</sup> In overdose cases, lethargy was self-limited and airway patency and respiratory drive were maintained.

While lethargy is uniformly reported in cases of aripiprazole overdose in younger children, EPS are only occasionally described. Intention tremor was noted in three confirmed aripiprazole ingestions in children younger than three years.<sup>5-7</sup> One case described a 2.5-year-old child with 10-hour serum aripiprazole and dehydro-aripiprazole concentrations of 1420 nanograms per milliliter (ng/mL) and 453 ng/mL, respectively; she exhibited an intention tremor for two weeks.<sup>5</sup> In all reported cases, tremor resolved without neurological sequelae. Dystonic reactions from aripiprazole occur infrequently. One case described a three-year-old who developed tongue fasciculations, arm twitching, suppressible rhythmic jaw movements, and ataxia following reported ingestion of 200 mg of aripiprazole.<sup>8</sup> Symptoms improved over three days without intervention. One case reported a six-year-old boy who developed flaccid facial muscles and drooling after the ingestion of aripiprazole 10 mg, which was successfully treated with diphenhydramine 25mg.<sup>9</sup> In our patient, diphenhydramine administration was deferred due to the profound lethargy that accompanied his EPS.

Cardiac toxicity, particularly QT interval prolongation, is a major concern in antipsychotic drug exposure due to the risk of torsades des pointes, dysrhythmia, and sudden cardiac death. Drug-related QT prolongation typically occurs in a dose-dependent fashion due to impaired currents of the delayed rectifier potassium current channel (I<sub>Kr</sub>), encoded by the human ether-a-go-go related (hERG) gene. In vitro, aripiprazole demonstrates low hERG channel binding, and aripiprazole's dopamine D<sub>2</sub> selectivity is approximately 774 times that of I<sub>Kr</sub>.<sup>11</sup> In a trial of 24 children (mean age, 8.6 years) initiating aripiprazole at therapeutic doses (titrating to a maximum of 15 mg/day), there were no significant changes in QRS or QT intervals from baseline ECGs at the 14-week mark.<sup>12</sup>

Within the scope of our literature review, we found no prior cases of cardiac arrhythmias or death following aripiprazole overdose. Although serum aripiprazole concentrations were not reported, we identified one case report of QRS prolongation lasting nine days in the setting of



aripiprazole overdose (400 mg) in a 14-year-old, who was subsequently determined to be a poor metabolizer of CYP2D6.<sup>13</sup> To our knowledge, our case is the first to describe ST-segment depressions in a patient following aripiprazole overdose. We were unable to infer causality since there was no prior ECG available and his ECG could have been abnormal at baseline; the child was lost to follow-up. Additional cardiac workup, including a transthoracic echocardiogram, was unremarkable; therefore, the significance of the ECG findings is questionable.

Hemodynamic effects of aripiprazole, specifically hypotension, appear less common in both therapeutic dosing and overdose compared to other antipsychotics. While aripiprazole does cause  $\alpha$ 1-adrenergic receptor antagonism, its affinity for  $\alpha$ 1-adrenergic receptors is low, and orthostatic hypotension occurred in only 0-1% of children ages 6-18 years old when used therapeutically in clinical trials.<sup>3</sup> In a literature review of a large case series of 485 children with reported aripiprazole overdose, 5.5-18.8% experienced tachycardia and 0.5% experienced hypotension.<sup>14</sup> In that study, however, not all patients had confirmed ingestions. Tachycardia and hypotension appear to be more commonly reported in case reports.<sup>5-8</sup> Hypotension has been treated successfully with intravenous fluid bolus administration. To our knowledge, there have been no reported cases of pediatric aripiprazole overdose requiring vasopressors.

Desired therapeutic effects of aripiprazole occur at steady state concentrations of 150-300 ng/mL, with side effects uncommon at a concentration of less than 250 ng/mL.<sup>2</sup> In therapeutic aripiprazole concentrations between 100-150 ng/mL, striatal and extrastriatal D<sub>2</sub> and D<sub>3</sub> receptors remain nearly saturated for up to one week after drug discontinuation.<sup>15</sup> In this case, an initial serum concentration range of 337.3 – 403.8 ng/mL was calculated assuming instantaneous absorption and using the known 46-hour aripiprazole concentration of 266.5 ng/mL, the above described half-life range, bioavailability, and volume of distribution. This correlates with a calculated initial ingestion dose range of 23.3 – 27.7 mg. Aripiprazole tablets are manufactured in dosages ranging from 2-30 mg. Thus, ingestion of a single pill has the potential to be of significant consequence in young children exhibiting oral exploratory behavior.

## CONCLUSION

In addition to common CNS depressants such as opioids, ethanol, sedative-hypnotics, antihistamines, and antiepileptics, emergency physicians should consider antipsychotics in toxicological etiologies of persistent depressed mental status in children. Aripiprazole should be considered along with other xenobiotics that can cause significant toxicity to young children after ingestion of a single pill or dose. Management of pediatric aripiprazole overdose is largely supportive. Gastric decontamination with activated charcoal may reduce absorption early in presentations,<sup>2</sup> although safe administration is often precluded by CNS depression. Lethargy following

overdose may be profound and last for days. Extrapyrimal symptoms, including tremor or dystonia, have been reported and have been treated with diphenhydramine. Hypotension typically responds to fluid resuscitation. A screening ECG is recommended for infrequent QRS and QT intervals abnormalities. Aripiprazole's high protein binding and large volume of distribution make hemodialysis unlikely to benefit. As aripiprazole serum concentrations typically do not result within clinically meaningful timeframes, concurrent medical workup to exclude organic etiologies is often required. Families with children should be counseled on potentially significant effects of unintentional overdose at the time of aripiprazole prescription to enact safe storage to mitigate the possibility of unintentional exposure.

A brief abstract describing the case was presented at the North American Congress of Clinical Toxicology, October 16-18, 2021, in Atlanta, Georgia.

Patient consent has been obtained and filed for the publication of this case report.

---

*Address for Correspondence:* Author, Nicholas Warstadt, MD, New York University Grossman School of Medicine, Ronald O. Perelman Department of Emergency Medicine, 570 First Avenue, New York, NY 10016. Email: nicholus.warstadt@nyulangone.org.

*Conflicts of Interest:* By the CPC-EM article submission agreement, all authors are required to disclose all affiliations, funding sources and financial or management relationships that could be perceived as potential sources of bias. The authors disclosed none.

*Copyright:* © 2022 Warstadt. This is an open access article distributed in accordance with the terms of the Creative Commons Attribution (CC BY 4.0) License. See: <http://creativecommons.org/licenses/by/4.0/>

---

## REFERENCES

1. Qiu H, Bird GL, Qu L, et al. Evaluation of QT interval correction methods in normal pediatric resting ECGs. *Comput Cardiol. IEEE.* 2007:431-4.
2. Kirschbaum KM, Muller MJ, Malevani J, et al. Serum levels of aripiprazole and dehydroaripiprazole, clinical response and side effects. *World J Biol Psychiatry.* 2008;9(3):212-8.
3. Bristol-Myers Squibb Company. Aripiprazole: Full Prescribing Information. 2014. Available at: [https://www.accessdata.fda.gov/drugsatfda\\_docs/label/2014/021436s038,021713s030,021729s022,021866s023lbl.pdf](https://www.accessdata.fda.gov/drugsatfda_docs/label/2014/021436s038,021713s030,021729s022,021866s023lbl.pdf). Accessed May 5, 2021.
4. Juurlink DN. Antipsychotics. (2019). In: Nelson LS, Howland MA, Lewin NA, et al., eds. *Goldfrank's Toxicologic Emergencies. 11 ed.* New York:McGraw-Hill Education.
5. Seifert SA, Schwartz MD, Thomas JD. Aripiprazole (Abilify) overdose in a child. *Clin Toxicol.* 2005;43(3):193-5.
6. Isbister GK, Balit CR, Kilham HA. Antipsychotic poisoning in young



- children: a systematic review. *Drug Saf.* 2005;28(11):1029-44.
7. Melhem S, Katz K, Jameson A, et al. Prolonged toxicity in a 2-year-old after accidental ingestion of aripiprazole. *Pediatr Emerg Care.* 2009;25(2):105-6.
  8. Gupta D and O'Hara C. Aripiprazole toxicity with a biphasic course of somnolence. *Pediatr Emerg Care.* 2019;35(8):e145-e6.
  9. Lofton AL and Klein-Schwartz W. Atypical experience: a case series of pediatric aripiprazole exposures. *Clin Toxicol.* 2005;43(3):151-3.
  10. Davenport JD, McCarthy MW, Buck ML. Excessive somnolence from aripiprazole in a child. *Pharmacotherapy.* 2004;24(4):522-5.
  11. Polcwiartek C, Sneider B, Graff C, et al. The cardiac safety of aripiprazole treatment in patients at high risk for torsade: a systematic review with a meta-analytic approach. *Psychopharmacology.* 2015;232(18):3297-308.
  12. Ho JG, Caldwell RL, McDougle CJ, et al. The effects of aripiprazole on electrocardiography in children with pervasive developmental disorders. *J Child Adolesc Psychopharmacol.* 2012;22(4):277-83.
  13. Mazer-Amirshahi M, Porter R, Dewey K. Prolonged QRS widening after aripiprazole overdose. *Pediatr Emerg Care.* 2019;35(11):e209-e12.
  14. Tan HH, Hoppe J, Heard K. A systematic review of cardiovascular effects after atypical antipsychotic medication overdose. *Am J Emerg Med.* 2009;27(5):607-16.
  15. Grunder G, Fellows C, Janouschek H, et al. Brain and plasma pharmacokinetics of aripiprazole in patients with schizophrenia: an [18F]fallypride PET study. *Am J Psychiatry.* 2008;165(8):988-95.

# Fungal Endophthalmitis on Ocular Ultrasound: A Case Report

Kimberly Fender, MD  
Merrick Bautista, MD  
Hiten Patel, MD  
Benjamin Ostro, MD  
Creagh Boulger, MD

The Ohio State University Wexner Medical Center, Department of Emergency  
Medicine, Columbus, Ohio

Section Editor: Shadi Lahham, MD

Submission History: Submitted June 22, 2021; Revision received October 24, 2021; Accepted October 22, 2021

Electronically published January 28, 2022

Full text available through open access at [http://escholarship.org/uc/uciem\\_cpchem](http://escholarship.org/uc/uciem_cpchem)

DOI: 10.5811/cpchem.2021.10.53797

**Introduction:** Endophthalmitis is a rare intraocular infection caused by numerous organisms from several possible sources. Fungal endophthalmitis is a rare subset of this pathology with limited diagnostics available. One of the few options to make this diagnosis is vitreous sampling, which is invasive, and results are not immediately available.

**Case Report:** This case report describes the successful use of point-of-care ultrasound to visualize an intraocular fungal mass in a 60-year-old male who presented to the emergency department (ED) with two weeks of left eye pain and erythema approximately two months postoperative from a cataract extraction surgery.

**Conclusion:** Fungal endophthalmitis is a rare and challenging diagnosis. Methods of diagnosing this pathology are not readily available in the ED. Point-of-care ultrasound may be a useful adjunct for the prompt diagnosis of fungal endophthalmitis. [Clin Pract Cases Emerg Med. 2022;6(1):49–52.]

**Keywords:** *point-of-care ultrasound; POCUS; ocular; endophthalmitis; case report.*

## INTRODUCTION

Endophthalmitis refers to any bacterial or fungal infection of the vitreous or aqueous humor. Endophthalmitis is a rare but serious intraocular infection that can result in irreversible vision loss in a matter of hours.<sup>1</sup> The infection can originate from an external source, such as surgery or trauma, or from an endogenous source by way of hematologic spread.<sup>3</sup> Fungal endophthalmitis occurs rarely and is difficult to diagnose, with often non-specific presentations, and has a poor prognosis.<sup>4</sup> Prompt diagnosis and treatment are of the utmost importance. While point-of-care-ultrasound (POCUS) is frequently used in the emergency department (ED) to diagnose emergent ophthalmologic conditions such as vitreous hemorrhage, retinal detachment, lens dislocation, and retained intraocular foreign body, it is less commonly used to diagnose endophthalmitis, and there is limited literature regarding diagnostic capabilities in the ED for this condition.<sup>1,2</sup> This case report describes the successful use of POCUS to visualize

fungal endophthalmitis in a patient with a history of cataract extraction surgery who presented to the ED with a complaint of left eye blurry vision.

## CASE REPORT

A 60-year-old male with a past medical history of cataracts, hypertension, and insulin-dependent diabetes mellitus presented to the ED with a chief complaint of left eye blurred vision. He was 10 weeks postoperative from a left eye cataract extraction surgery. Three weeks prior to his ED presentation, he had noticed a vague left eye ache associated with redness and worsening blurry vision. He denied fever, photophobia, and eye discharge.

The patient initially presented to an ophthalmologist for evaluation of his symptoms. Five days prior to his ED visit a fluid sample was collected from the anterior chamber of his left eye. Retinal imaging revealed mild macular edema and mild vitritis. Intravitreal ceftazidime and vancomycin were

administered with an initial concern for endophthalmitis, and he was prescribed ofloxacin drops. He returned for follow-up the next day endorsing mild improvement of his left eye pain, and he was additionally started on prednisone drops. Three days later he returned for another follow-up appointment with progressive vision loss, and he received intravitreal amphotericin B. Despite this treatment, he re-presented to the clinic the following day with progressively worsening vision. Ophthalmologic exam revealed worsening inflammation and new hypopyon. With this progression of symptoms, he was instructed to present to the ED for further ophthalmologic evaluation and admission.

Vital signs on presentation to the ED were a temperature of 97.1° Fahrenheit, blood pressure 170/88 millimeters mercury, heart rate of 70 beats per minute, a respiratory rate of 20 breaths per minute, and an oxygen saturation of 99% on room air. Physical exam was notable for left eye conjunctival injection and chemosis, Pupils were equally round and reactive bilaterally, extraocular movements were intact and performed without additional discomfort, and intraocular pressures were within normal limits. Visual acuity was 20/25 on the right and 20/70 on the left.

Point-of-care ultrasound of his left eye revealed a mobile, hyperechoic spherical mass with an anechoic center in the posterior chamber. The mass was approximately 0.5 centimeters in diameter. Additional intraocular ultrasound views revealed multiple hypoechoic structures stemming from the lateral aspects of the mass. No clear anchoring was seen to the retina, no retinal detachment was seen, nor was there any dilation of the optic nerve.

The patient was admitted to the hospital for continued workup and management where blood cultures, aqueous cultures, and cultures of tubular angle mass aspirate were negative. The patient was ultimately discharged with a presumptive diagnosis of fungal endophthalmitis based on his acute clinical deterioration after initiation of steroids and lack of bacterial culture growth. Two weeks after discharge he was improving but still had some blurry vision and was taken back to the operating room for another vitreous washout and intraocular antifungals. His cultures from this operation were also negative, bacterial, viral, and fungal. Two weeks after this washout his visual acuity returned to 20/25 in his left eye, and he reported resolution of the pain, blurry vision, and floaters in his visual field.

## DISCUSSION

Endophthalmitis is a serious intraocular infection that can lead to irreversible vision loss within a few hours. Classically, this infection occurs following ocular surgery, eye trauma, or systemic bacteremia or fungemia.<sup>1</sup> Patients may present with any combination of unilateral eye pain, floaters, blurry vision, and photophobia; however, it may be asymptomatic, creating a diagnostic challenge for providers. Thus, the prompt diagnosis and treatment of this uncommon

### *CPC-EM Capsule*

What do we already know about this clinical entity?

*Fungal endophthalmitis is an uncommon, serious ocular infection with a non-specific presentation; it is difficult to diagnose and treat.*

What makes this presentation of disease reportable?

*This case demonstrates the possible utility of ultrasound in making this challenging diagnosis.*

What is the major learning point?

*Ocular ultrasound can be useful in the diagnosis of fungal endophthalmitis. The lesion may appear as a hyperechoic mass in the posterior chamber.*

How might this improve emergency medicine practice?

*Using point-of-care ultrasound could expedite time to diagnosis and treatment of a disease with significant complications that is challenging to diagnose.*

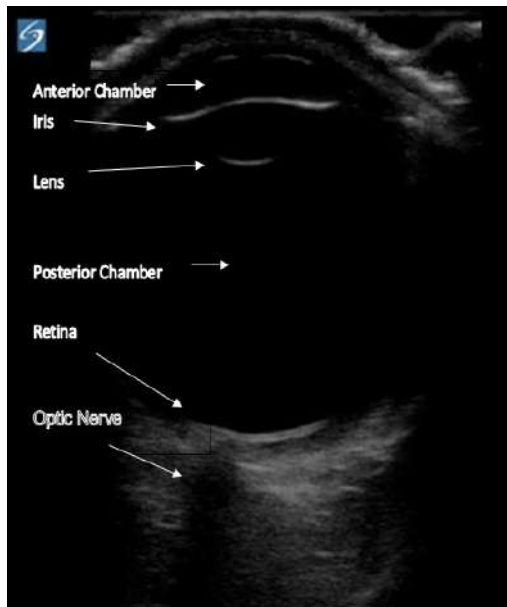
condition is of the utmost importance to preserve visual function and eye structure. Unfortunately, despite the seriousness of this condition, there are few tools available to aid providers in the diagnosis of this infection.<sup>1</sup>

The diagnosis of endophthalmitis requires a thorough ophthalmologic evaluation, intraocular and blood cultures, and imaging such as computed tomography or radiographs to evaluate for endogenous sources.<sup>1</sup> The variation of presentations and lack of a diagnostic protocol pose a challenge for providers, especially in the ED. One study reviewing endophthalmitis found that up to 30% of cases are asymptomatic at the time of diagnosis.<sup>5</sup> Another study revealed that intraocular cultures were positive in only 41.7% of cases and in 28.6% of cases in which treatment already had been started.<sup>6</sup> Blood cultures provided little diagnostic benefit and were positive in only 48.5% of these cases.<sup>6</sup> There are no clear treatment guidelines regarding the use of intravenous or intravitreal antimicrobials or vitrectomy.<sup>7</sup> Regardless of the vast differences in diagnostics and treatments, the visual outcome of endophthalmitis tends to be poor.<sup>1</sup>

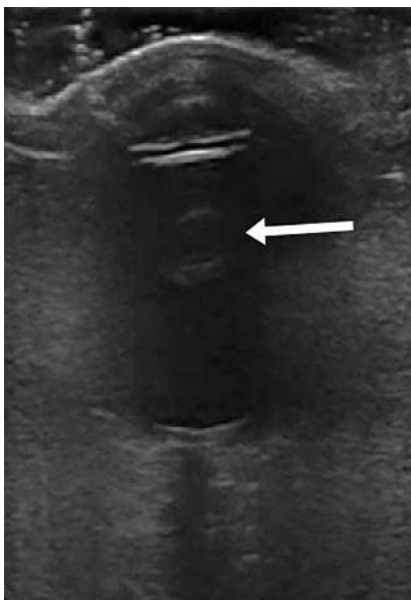
While ocular ultrasound is commonly used in the ED to evaluate retinal detachment, vitreous hemorrhage, and papilledema, there is limited literature regarding its utility in

evaluating patients for suspected endophthalmitis. One case report using POCUS focused on evaluating the presence of hyperechoic vitreous debris while another article focused on hyperechoic, membranous material in the vitreous humor.<sup>8,9</sup> Image 1 demonstrates a normal ocular ultrasound with the important anatomy labeled.

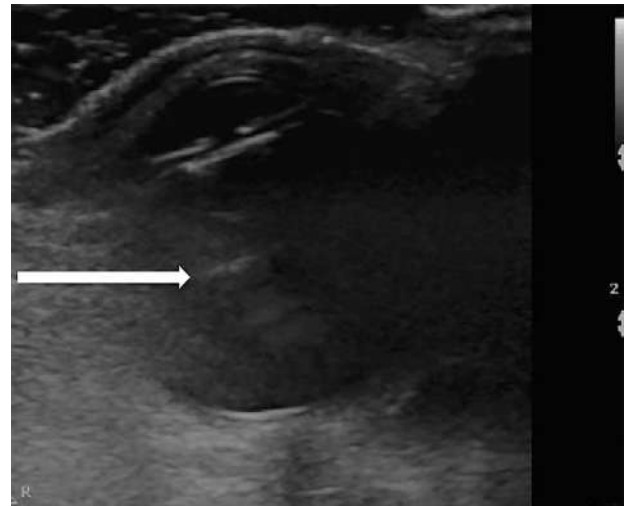
Upon literature review, we found no identifiable case reports describing the presence of a hyperechoic circular mass in the vitreous humor related to the diagnosis of endophthalmitis (Image 2). Additionally, some hypoechoic material is visible in Image 3 and the supplemental video, which could be anchoring the structure laterally; however, this



**Image 1.** Normal ocular ultrasound with relevant anatomy.



**Image 2.** Hyperechoic spherical structure seen in the posterior chamber of the left eye noted at the tip of the arrow.



**Image 3.** Hypoechoic anchoring of previous spherical structure as indicated at the tip of the arrow.

is not clearly visualized on all images. While these images alone are insufficient to diagnose endophthalmitis, the visualized mass on POCUS is strongly suspected to be related to the patient's left eye symptoms. Given the minimal number of tools for diagnosing endophthalmitis, POCUS findings of a hyperechoic mass within the vitreous should be considered as a useful adjunct for timely diagnosis.

## CONCLUSION

Fungal endophthalmitis is an uncommon, serious ocular infection with a non-specific presentation, making it difficult to diagnose and treat. This case report demonstrates the use of POCUS in the ED as an adjunct in the diagnosis of this condition. While ultrasound findings are not definitive for the diagnosis of endophthalmitis, there may be some benefit in using POCUS findings in the ED to aid in the prompt diagnosis and treatment of this devastating condition, which could potentially lead to a better visual outcome.

**Video.** Point-of-care ultrasound demonstrating a hyperechoic spherical structure in the posterior chamber of the left eye noted in the center of the red circle.

Documented patient informed consent and Institutional Review Board approval has been obtained and filed for publication of this case report.

*Address for Correspondence:* Creagh Boulger, MD, The Ohio State University Wexner Medical Center, Department of Emergency Medicine, 376 W 10th Ave, 750 Prior Hall, Columbus, OH 43210. Email: creagh.boulger@osumc.edu.

*Conflicts of Interest:* By the CPC-EM article submission agreement, all authors are required to disclose all affiliations, funding sources and financial or management relationships that could be perceived as potential sources of bias. The authors disclosed none.



Copyright: © 2022 Fender. This is an open access article distributed in accordance with the terms of the Creative Commons Attribution (CC BY 4.0) License. See: <http://creativecommons.org/licenses/by/4.0/>

## REFERENCES

1. Durand ML. Bacterial and fungal endophthalmitis. *Clin Microbiol Rev.* 2017;30(3):597-613.
2. Pujari A, Swamy DR, Singh R, et al. Ultrasonographic assessment of paediatric ocular emergencies: a tertiary eye hospital based observation. *World J Emerg Med.* 2018;9(4):272-5.
3. Chang CC and Chen SC. Fungal eye infections: new hosts, novel emerging pathogens but no new treatments?. *Curr Fungal Infect Rep.* 2018;2:66-70.
4. Gursimrat KH, Dawkins RC, Paul RA, et al. Fungal endophthalmitis: a 20-year experience at a tertiary referral centre. *Clin Exp Ophthalmol.* 2020;48(7):964-72.
5. Corredores J, Hemo I, Jaouni T, et al. Endogenous fungal endophthalmitis: risk factors, clinical course, and visual outcomes in 13 patients. *Int J Ophthalmol.* 2021;14(1):97-105.
6. Regan KA, Radhakrishnan NS, Hammer JD, et al. Endogenous endophthalmitis: yield of the diagnostic evaluation. *BMC Ophthalmol.* 2020;20(1):138-44.
7. Tabatabaei SA, Soleimani M, Mirshahi R, et al. Culture-proven endogenous endophthalmitis: microbiological and clinical survey. *Int Ophthalmol.* 2020;40(12):3521-8.
8. Barboza K and Lobo V. Sonographic findings on endophthalmitis. *Vis J Emerg Med.* 2021;23:2405-6.
9. Tucker J, Patane J, Lahham S. Point-of-care ultrasound detection of endophthalmitis. *J Educ Teach Emerg Med.* 2018;3(1):25-6.

# A Case Report of Massive Intraperitoneal Hemorrhage from Rare Cornual Pregnancy

Brandon M. Carius, DSc, MPAS, PA-C  
Edward J. Houston, MD  
Stephen P. Griffith, MD, JD, FAAEM

Brian D. Allgood Army Community Hospital, Department of Emergency Medicine, Camp Humphreys, Republic of Korea

Section Editor: Austin Smith, MD

Submission History: Submitted August 10, 2021; Revision received October 18, 2021; Accepted October 22, 2021

Electronically published January 28, 2022

Full text available through open access at [http://escholarship.org/uc/uciem\\_cpem](http://escholarship.org/uc/uciem_cpem)

DOI: 10.5811/cpem.2021.10.54388

**Introduction:** A cornual pregnancy describes a rare ectopic location positioned within the myometrium next to the fallopian tube, which can be difficult to find on traditional ultrasound imaging. Given its location and the stretch within the uterine wall, cornual pregnancies can progress for weeks prior to diagnosis. Ruptures can, therefore, be catastrophic with disproportionately high maternal mortality rates compared to other ectopic pregnancies.

**Case Report:** A 34-year-old female recently treated with methotrexate for ectopic pregnancy presented to the emergency department (ED) for acute onset of lower abdominal cramping without vaginal bleeding. She arrived clinically stable and quickly decompensated with witnessed syncope in the ED, prompting point-of-care ultrasound showing free fluid in the abdomen. The patient was taken for emergent surgery by obstetrics while receiving transfusion of blood products for suspected ruptured ectopic pregnancy. A fetus estimated to be 10 weeks of age was discovered in the left cornual region. Approximately two liters of intraperitoneal blood were drained without complication.

**Conclusion:** Cornual pregnancy is a difficult to diagnose but potentially disastrous type of ectopic pregnancy due to massive hemorrhage. Emergency clinicians should be aware of this condition given its rare occurrence but potentially catastrophic outcomes. [Clin Pract Cases Emerg Med. 2022;6(1):53-56.]

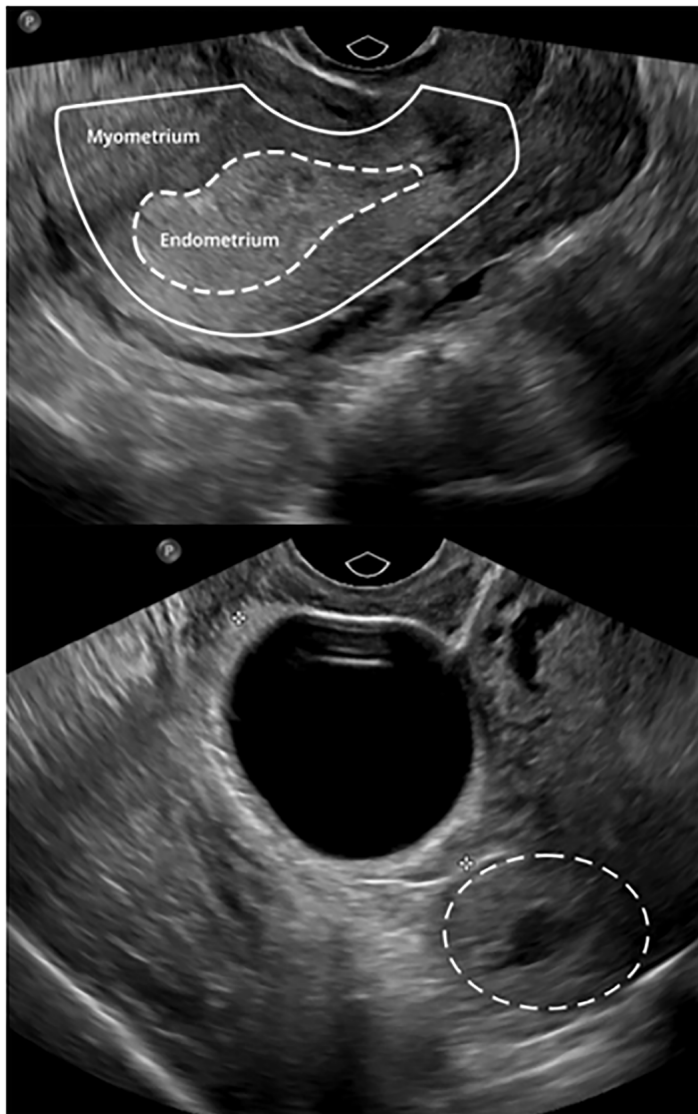
**Keywords:** *ectopic; abdominal pain; pregnancy; case report.*

## INTRODUCTION

Pregnancy complications are frequently seen in the emergency department (ED) setting, where evaluation includes hemodynamic stability and pregnancy location and viability. While modern ultrasound (US) can help locate pregnancy and assess viability, some may be difficult to locate. Cornual pregnancy is a rare type of ectopic pregnancy rarely described in emergency medicine literature. Because it may go unidentified for weeks cornual pregnancy demonstrates high maternal mortality because of its delayed diagnosis and massive hemorrhage with rupture. We report a case of this rare type of ruptured ectopic pregnancy presenting as stable abdominal pain with sudden hemodynamic instability due to severe intraperitoneal hemorrhage.

## CASE REPORT

A 34-year-old gravida four, para two female with history of two ectopic pregnancies arrived at the ED complaining of 20 minutes of left-sided lower abdominal pain with four episodes of non-bloody emesis. She denied other symptoms, including vaginal bleeding. Initial medical history included two previous ectopic pregnancies; the first, approximately six months prior to arrival at the ED, resolved with intramuscular methotrexate. Her second ectopic pregnancy was suspicious for cornual pregnancy based on history and US at seven weeks estimated gestational age (Image 1) but had been officially diagnosed by obstetrics as an ectopic pregnancy of unknown location and deemed resolved after intramuscular methotrexate one month prior to arrival. After initial



**Image 1.** Initial transvaginal ultrasound six weeks prior to presentation, revealing an empty uterus (top) and a “cystic area” measuring 2.3 x 2.5 x 3.2 centimeters in the left cornual region (bottom, dashed circle).

quantitative beta-human chorionic gonadotropin ( $\beta$ hCG) of over 16,000 milli-international units per milliliter (mIU/mL) (normal hCG range:  $<3$  mIU/mL), her levels fell to 1700 mIU/mL two weeks prior to arrival.

Triage vital signs were significant for blood pressure (BP) of 86/51 millimeters mercury (mm Hg) but were otherwise within normal limits, including a heart rate (HR) of 85 beats per minutes (bpm). Physical examination revealed voluntary guarding of the abdomen and only moderate tenderness of the left lower quadrant. A one-liter saline intravenous bolus provided transient BP improvement to 108/58 mm Hg with other vital signs within normal limits. While preparing for an abdominal and pelvic computed tomography, initial complete blood count (CBC) found stable hemoglobin and hematocrit of 12.0 grams/deciliter (g/dL)

### *CPC-EM Capsule*

What do we already know about this clinical entity?

*Cornual pregnancy describes a rare, potentially disastrous implantation within the myometrium beside the fallopian tube, difficult to find on traditional ultrasound.*

What makes this presentation of disease reportable?

*This case illustrates a ruptured cornual pregnancy in the ED with severe hemorrhage, previously thought resolved by methotrexate via obstetrics.*

What is the major learning point?

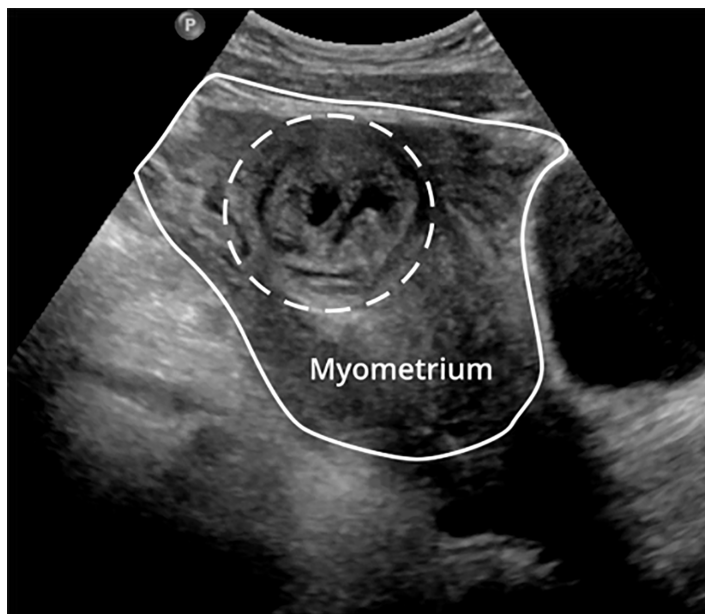
*Given extended progression prior to diagnosis and disproportionate maternal mortality, cornual pregnancy should be a chief concern in suspected ectopic pregnancy.*

How might this improve emergency medicine practice?

*Cornual pregnancy is best diagnosed by three-dimensional ultrasound. Given high mortality from hemorrhage, all cases require emergent obstetrics consultation.*

(reference range: 12.0 – 16.5 g/dL) and 36.1% (reference range 36.0 – 49.5%), respectively. Approximately five minutes after last vital signs were taken, the patient stood to provide a urine sample and nursing witnessed sudden diffuse pallor immediately followed by syncope lasting less than 60 seconds. Repeat vital signs revealed BP of 68/38 mm Hg and HR of 108 bpm. After being placed in Trendelenburg position, type and cross, quantitative  $\beta$ hCG, and repeat CBC were drawn.

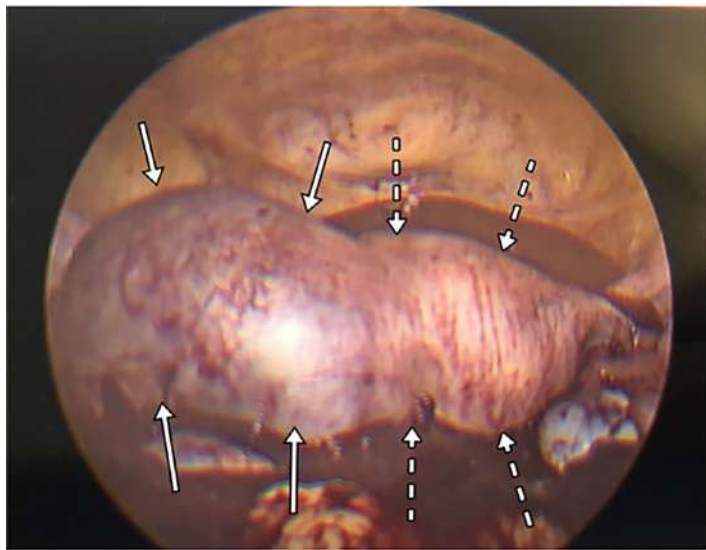
Point-of-care US revealed free fluid in the abdomen as well as a thickened endometrium with an endometrial mass (Image 2). Obstetrics was emergently consulted for suspected ectopic rupture; upon arrival to bedside, repeat hemoglobin and hematocrit revealed a dramatic decline to 6.2 g/dL and 20.1%, suspected due to hemorrhage. Two units of packed red blood cells were administered en route to the operating room. The surgeons found approximately two liters of intraperitoneal blood and diagnosed a ruptured, left cornual ectopic pregnancy (Image 3). A cornual wedge resection and a unilateral salpingectomy were performed. The patient recovered uneventfully and was discharged on postoperative day three.



**Image 2.** Transabdominal ultrasound demonstrating a mass in the left lateral uterus (dashed circle).

## DISCUSSION

In the past, a cornual pregnancy described implantation and development of a gestational sac in a bicornate or septate uterus. Today the term more broadly describes implantation in the myometrium of the horn (cornual region) of a normal uterus.<sup>1-4</sup> Although cornual pregnancy is sometimes used interchangeably with interstitial pregnancy, the latter is distinguished by a gestational sac within the myometrium not specific to the cornual region.<sup>1-5</sup> These constitute 2-4% of all ectopic pregnancies.<sup>5-9</sup> Cornual pregnancy carries a 2.5%



**Image 3.** Laparoscopic image of visualized cornual pregnancy (solid arrow) and uterus (dashed arrow) surrounded by large hemorrhage.

mortality rate but disproportionately accounts for 20% of maternal deaths from ectopic pregnancy.<sup>4,7,10</sup>

Compared to more common tubal pregnancies, the ability of the cornual uterine tissue to stretch allows pregnancies to progress undetected for weeks longer prior to rupture.<sup>4,9,11</sup> Traditional ectopic pregnancy risk factors such as previous ectopic gravidity, pelvic inflammatory disease, fibroids, fallopian tube obstruction, and in vitro fertilization may be present but are largely absent in case series.<sup>3,4,7,8</sup> Most ruptured cornual pregnancy patients complain of abdominal pain, but vaginal bleeding is less frequent than in other ectopic pregnancies, likely given the sequestered location.<sup>4,8,9</sup> However, as pregnancy may progress as long as 12 weeks prior to rupture, women may present with hemorrhagic shock, confounding initial evaluation, differential considerations, and management.<sup>3,9,12</sup>

Cornual location within the interstitium can be confused with an uncomplicated intrauterine pregnancy on traditional two-dimensional US.<sup>4,13</sup> A proposed, sonographic “interstitial line sign” extending from the upper region of the uterine horn to border the intramural portion of the fallopian tube has been described with high specificity but low sensitivity.<sup>7,13,14</sup> Diagnostic criteria center on sonographic findings of an empty uterine cavity, a chorionic sac seen separately greater than one centimeter from the most lateral edge of the uterine cavity, and a thin myometrial layer surrounding the gestational sac.<sup>8,13,15</sup> Like the interstitial line sign, these models demonstrate high specificity but low sensitivity of 40%.<sup>14</sup> Radiologists and obstetricians advocate for three-dimensional US to improve diagnosis, as it can image the coronal plane of the uterus, although validation of increased accuracy is lacking.<sup>3,4,12,13</sup>

Suspicion of cornual pregnancy necessitates emergent obstetric consultation. Initial management focuses on stabilization and pregnancy confirmation. Unstable vital signs with free fluid on abdominal US should prompt consideration for blood product transfusion. In stable patients, early detection ( $\beta$ hCG < 3000 mIU/mL) of cornual pregnancy can be considered for outpatient methotrexate therapy, through oral, intramuscular, or sonographic-guided injection with obstetrics consultation.<sup>4,8,13</sup> Most cited surgical cases are past this threshold, requiring either laparoscopic cornual resection or hysterectomy, although some are successfully treated with outpatient methotrexate.<sup>4-9,13</sup>

## CONCLUSION

Given the difficulties in imaging and extended gestational age prior to diagnosis of cornual pregnancy, and high mortality rates, it is important that emergency clinicians be familiar with diagnostic pitfalls and treatment plans for management. Proper resuscitation and supportive care in the ED setting are essential, and immediate obstetric surgical consult is critical to limit catastrophic hemorrhage.

The authors wish to acknowledge the contributions of Peter Max Dodge in helping with reviewing the manuscript and refining the images for submission.



The authors attest that their institution requires neither Institutional Review Board approval nor patient consent for publication of this case report. Documentation on file.

**Address for Correspondence:** Brandon M. Carius, DSc, MPAS, PA-C, Brian D. Allgood Army Community Hospital, Department of Emergency Medicine, 3030 Gimlet Drive, Camp Humphreys, Republic of Korea, APO, AP 96273. Email: brian.m.carius.mil@mail.mil.

**Conflicts of Interest:** By the CPC-EM article submission agreement, all authors are required to disclose all affiliations, funding sources and financial or management relationships that could be perceived as potential sources of bias. The authors disclosed none. The views expressed here are those of the authors and do not reflect the official policy of the Department of the Army, the Department of Defense, or the U.S. Government.

**Copyright:** © 2022 Carius. This is an open access article distributed in accordance with the terms of the Creative Commons Attribution (CC BY 4.0) License. See: <http://creativecommons.org/licenses/by/4.0/>

## REFERENCES

- Arleo EK and DeFilippis EM. Cornual, interstitial, and angular pregnancies: clarifying the terms and a review of the literature. *Clin Imaging*. 2014;38(6):763-70.
- Malinowski A and Bates SK. Semantics and pitfalls in the diagnosis of cornual/interstitial pregnancy. *Fertil Steril*. 2006;86(6):1764.e1711-64.
- Valsky DV and Yagel S. Ectopic pregnancies of unusual location: management dilemmas. *Ultrasound Obstet Gynecol*. 2008;31(3):245-51.
- Brincat M, Bryant-Smith A, Holland TK. The diagnosis and management of interstitial ectopic pregnancies: a review. *Gynecological Surgery*. 2019;16(1):2.
- Marchand G, Taher Masoud A, Sainz K, et al. A systematic review and meta-analysis of laparotomy compared with laparoscopic management of interstitial pregnancy. *Facts Views Vis Obgyn*. 2021;12(4):299-308.
- Ma K, Kaur N, Winters U. Cornuostomy and cornuectomy: laparoscopic management of interstitial ectopic pregnancies. *J Minim Invasive Gynecol*. 2020;27(7):1480-1.
- Molinaro TA and Barnhart KT. Ectopic pregnancies in unusual locations. *Semin Reprod Med*. 2007;25(2):123-30.
- MacRae R, Olowu O, Rizzuto MI, et al. Diagnosis and laparoscopic management of 11 consecutive cases of cornual ectopic pregnancy. *Arch Gynecol Obstet*. 2009;280(1):59-64.
- Chan LY, Fok WY, Yuen PM. Pitfalls in diagnosis of interstitial pregnancy. *Acta Obstet Gynecol Scand*. 2003;82(9):867-70.
- Tang A, Baartz D, Khoo SK. A medical management of interstitial ectopic pregnancy: a 5-year clinical study. *Aust N Z J Obstet Gynaecol*. 2006;46(2):107-11.
- Surekha SM, Chamaraja T, Nabakishore SN, et al. A ruptured left cornual pregnancy: a case report. *J Clin Diagn Res*. 2013;7(7):1455-6.
- Sargin MA, Tug N, Ayas S, et al. Is interstitial pregnancy clinically different from cornual pregnancy? A case report. *J Clin Diagn Res*. 2015;9(4):Qd05-06.
- Dagar M, Srivastava M, Ganguli I, et al. Interstitial and cornual ectopic pregnancy: conservative surgical and medical management. *J Obstet Gynaecol India*. 2018;68(6):471-6.
- Ackerman TE, Levi CS, Dashefsky SM, et al. Interstitial line: sonographic finding in interstitial (cornual) ectopic pregnancy. *Radiology*. 1993;189(1):83-7.
- Timor-Tritsch IE, Monteagudo A, Matera C, et al. Sonographic evolution of cornual pregnancies treated without surgery. *Obstet Gynecol*. 1992;79(6):1044-9.

## Necrotizing Mediastinitis Following Dental Extraction: A Case Report

Justin Pinkston, MD  
Charles A. Khoury, MD  
Jaron D. Raper, MD

University of Alabama at Birmingham, Department of Emergency Medicine,  
Birmingham, Alabama

Section Editor: Joel Moll, MD

Submission History: Submitted August 30, 2021; Revision received October 26, 2021; Accepted November 10, 2021

Electronically published January 28, 2022

Full text available through open access at [http://escholarship.org/uc/uciem\\_cpccem](http://escholarship.org/uc/uciem_cpccem)

DOI: 10.5811/cpcem.2021.11.54567

**Introduction:** Necrotizing mediastinitis is a rare complication following a dental procedure. It is frequently lethal and requires prompt diagnosis with advanced imaging, administration of broad-spectrum antimicrobials, and early surgical consultation.

**Case Report:** A 19-year-old, otherwise healthy male presented to the emergency department with chest pain, muffled voice, and facial and neck swelling six days following dental extraction. He was found to have a retropharyngeal abscess causing necrotizing mediastinitis and septic shock. The patient was started on broad-spectrum antimicrobials, required 10 surgical procedures, and experienced a prolonged hospitalization.

**Conclusion:** Consider necrotizing mediastinitis in patients presenting with chest pain and signs of retropharyngeal infection after dental procedures. Prompt imaging, antimicrobial therapy, and surgical consultation is critical in treating this frequently fatal disease. [Clin Pract Cases Emerg Med. 2022;6(1):57-60.]

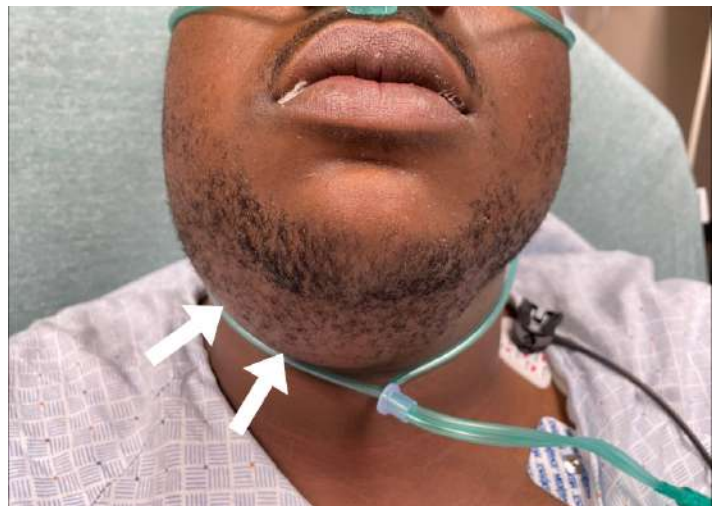
**Keywords:** *descending necrotizing mediastinitis; odontogenic infections; facial abscess; septic shock; pericarditis; dental emergency; case report.*

### INTRODUCTION

Odontogenic infections are largely polymicrobial, and occasionally they may spread down the cervical fascial planes, resulting in complications including descending necrotizing mediastinitis, airway obstruction, and pericarditis.<sup>1</sup> Treatment consists of prompt identification and drainage of the odontogenic infection source by a surgical subspecialty. However, the mortality rate remains high and is estimated to be between 25-40% and as high as 60% despite advancements in computed tomography (CT) imaging, directed antibiotic therapy, and improvements in intensive care and surgical drainage.<sup>2,3</sup>

### CASE REPORT

A 19-year-old, otherwise healthy male presented to the emergency department (ED) with worsening chest pain, muffled voice, facial, and neck swelling (Image 1) six days following a right-sided wisdom tooth extraction.

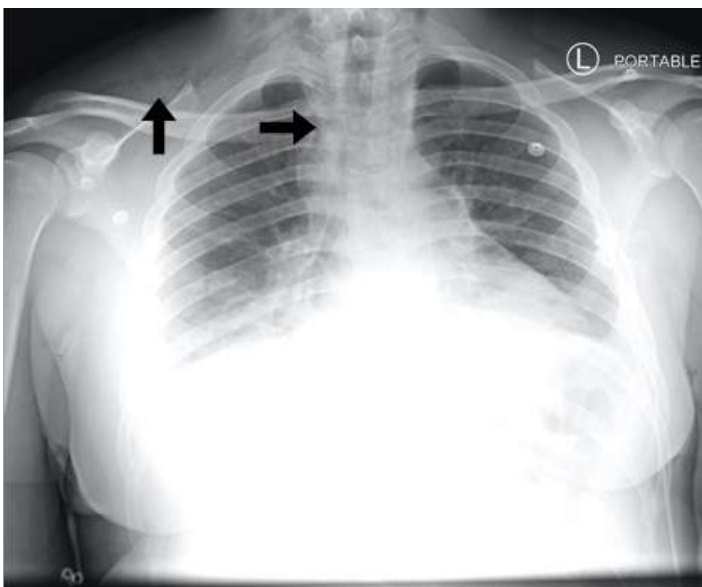


**Image 1.** Photograph of patient's lower jaw and neck demonstrating sublingual and submandibular swelling (arrows).

On presentation, the patient's vital signs included a blood pressure of 117/77 millimeters of mercury (mm Hg), heart rate of 130 beats per minute, respiration rate of 28 breaths per minute, and an oral temperature of 98.4°F. Physical examination revealed mild respiratory distress and a muffled voice with diffuse submandibular swelling. The patient demonstrated trismus but was able to protrude his tongue, albeit painfully. The submandibular space on the right side was particularly tender, swollen, and fluctuant, without associated erythema. Crepitus was noted under the right side of the mandible and extended to the ipsilateral clavicle. Breath sounds were diminished on the right. Cardiac auscultation demonstrated a distant first and second heart sounds without appreciable murmur, rub, or gallop. During the examination, the patient reported orthopnea on several occasions, stating that he would prefer to remain upright in the stretcher.

A chest radiograph was obtained to evaluate the crepitus noted over the right clavicle (Image 2). The radiograph demonstrated pneumomediastinum and subcutaneous emphysema, which was concerning for esophageal perforation. As a result, a CT chest with contrast and esophagram were ordered. Initial labs included a white blood cell (WBC) count of  $8.65 \times 10^3$ /cells per cubic millimeter (reference range 4500 to 11,000 WBCs per microliter) and lactic acid of 3.3 millimoles per liter (mmol/L) (reference range 0.5-2.2 mmol/L).

Computed tomography imaging demonstrated mediastinal air, small bilateral pleural effusions, and subcutaneous air tracking into the neck, all of which were concerning for esophageal perforation (Image 3). Following source identification by CT, the patient received vancomycin, piperacillin-tazobactam, clindamycin, metronidazole, and



**Image 2.** Chest radiograph demonstrating pneumomediastinum and subcutaneous emphysema just above the right clavicle (arrows).

### CPC-EM Capsule

What do we already know about this clinical entity?

*Odontogenic infections can rarely cause descending necrotizing infections of the mediastinum, with mortality ranging from 25-60%.*

What makes this presentation of disease reportable?

*This patient suffered a complicated and protracted course of necrotizing mediastinitis following an otherwise uncomplicated dental extraction.*

What is the major learning point?

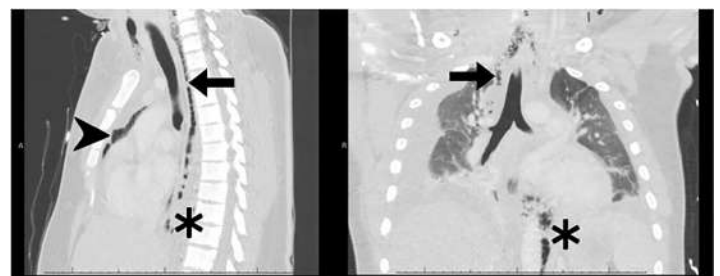*Consider necrotizing mediastinitis in patients with chest pain after dental procedures. Early imaging, antimicrobials, and surgical consultation is critical to management.*

How might this improve emergency medicine practice?

*Readers will have an improved ability to recognize and manage patients suffering from a life-threatening complication of dental extraction.*

fluconazole to treat for necrotizing soft tissue infection (NSTI), severe sepsis, and esophageal perforation.

Thoracic surgery and oral and maxillofacial surgery were emergently consulted. Following the surgeons' bedside evaluation, the patient was taken to the operating room (OR). While in the ED, the patient remained normotensive and did not



**Image 3.** Computed tomography of the chest with intravenous contrast in coronal (right) and sagittal (left) planes, demonstrating mediastinal air and fluid tracking from the retropharyngeal space (arrows), extensive pneumo-mediastinum (arrowhead), and retrocrural subcutaneous gas (asterisks).

require a definitive airway. He was intubated in the OR using video-assisted laryngoscopy. Oral and maxillofacial surgery performed an incision and drainage of the patient's facial abscess, and thoracic surgery performed a right-sided, video-assisted thoracoscopic surgery to drain the mediastinal abscess. Following surgery, the patient was admitted to the surgical intensive care unit (SICU) with septic shock and was placed on norepinephrine and phenylephrine due to persistent mean arterial pressure less than 60 mm Hg (reference range: normal greater than 65 mm Hg) and a peak lactic acid of 12 mmol/L.

The patient subsequently underwent numerous washouts over the following weeks and was weaned off vasopressors and mechanical ventilation after 35 days in the SICU. He was discharged home at 42 days. At his three-week follow-up appointment, he reported persistent oral pain, left-sided chin numbness, and limited opening of his mouth secondary to pain.

## DISCUSSION

Complications from odontogenic surgeries such as descending necrotizing mediastinitis, retropharyngeal abscess, and pericarditis are rare. Most cases are reported in dental and oral surgery literature, with relatively few in the emergency medicine literature. The incidence of complications from these surgeries ranges from 1-30%, with the most common complications being alveolar osteitis, postoperative hemorrhage, wound dehiscence, and fracture of the bone cortices. More serious infections including NSTI and complex abscesses have a reported rate of less than 2%, although some studies report rates as high as 15%. The variance in reported rate is most likely due to inconsistencies in defining NSTI, with the more aggressive pathology occurring in less than 2% of reported cases.<sup>2</sup>

As estimated 60-70% of all cases of descending necrotizing mediastinitis are secondary to odontogenic or cervicofacial infections. These necrotizing infections can carry a mortality rate as high as 60% and are frequently associated with pleural and pericardial effusions, sepsis, and multisystem organ failure.<sup>3</sup> Patients presenting to the ED following odontogenic surgeries should be thoroughly evaluated for airway compromise, complicating infections, and sepsis.<sup>5</sup>

Airway compromise may present with subtle but specific findings including muffled voice secondary to retropharyngeal abscess. Changes in tongue articulation may be evident secondary to sublingual space infections.<sup>5</sup> Patients with more advanced airway compromise may present with drooling, in a sniffing position, or with accessory muscle use.<sup>5</sup> Endotracheal intubation of these patients may be challenging due to deviation of the airway and associated trismus. Emergency physicians should prepare for difficult airways in these patients by planning for nasopharyngeal fiberoptic intubation and potential cricothyrotomy.<sup>5</sup>

Once the airway is secure, the emergency physician should focus on identifying the source of infection and assessing for potential spread. Surgical exploration is the gold standard for

the diagnosis of NSTI.<sup>6</sup> Magnetic resonance imaging (MRI) is reported to attain a 100% sensitivity and 86% specificity for diagnosing NSTI.<sup>6</sup> However, MRI is not always a feasible option in the ED due to timing and clinical instability. Computed tomography is reported to attain a 86% sensitivity and 92% specificity based on the presence of fascial air, muscle or fascial edema, fluid tracking, lymphadenopathy, and subcutaneous edema.<sup>6</sup> If CT is unavailable, posteroanterior and lateral radiography of the neck and chest may demonstrate gas in soft tissue space, mediastinal widening, and increased thickness of the retropharyngeal tissues.<sup>5</sup>

Emergent surgical intervention is an important step in improving patient outcomes for those with NSTI.<sup>2</sup> Primary treatment includes surgical drainage of the pharyngeal or odontogenic infection source.<sup>2</sup> For NSTI, the Infectious Diseases Society of America recommends vancomycin or linezolid plus piperacillin-tazobactam or a carbapenem; if there is concern for esophageal perforation, antifungal coverage with fluconazole or micafungin should be added.<sup>7</sup> Despite these therapies, the mortality rate remains as high as 60% for descending necrotizing mediastinitis.<sup>5</sup>

## CONCLUSION

Life-threatening odontogenic infections are rare complications of dental procedures. However, complications such as descending necrotizing mediastinitis and associated septic shock carry mortality rates as high as 60%.<sup>5</sup> Clinicians should have a high index of suspicion for necrotizing soft tissue infections in patients presenting in respiratory distress following recent dental procedures. Prompt airway assessment and management, directed imaging, antimicrobial therapy, and surgical consultation are all essential for improving patient outcomes.

Patient consent has been obtained and filed for the publication of this case report.

*Address for Correspondence:* Jaron D. Raper, MD, University of Alabama at Birmingham, Department of Emergency Medicine, 990E Admin Building 701 20th St S Birmingham, AL 35233. Email: jdraper@uabmc.edu

*Conflicts of Interest:* By the CPC-EM article submission agreement, all authors are required to disclose all affiliations, funding sources and financial or management relationships that could be perceived as potential sources of bias. The authors disclosed none.

*Copyright:* © 2022 Pinkston. This is an open access article distributed in accordance with the terms of the Creative Commons Attribution (CC BY 4.0) License. See: <http://creativecommons.org/licenses/by/4.0/>

## REFERENCES

1. Tanner A and Stillman N. Oral and dental infections with anaerobic bacteria: clinical features, predominant pathogens, and treatment. *Clin Infect Dis.* 1993;16(Suppl 4):S304-9.



2. Sandner A and Börgermann J. Update on necrotizing mediastinitis: causes, approaches to management, and outcomes. *Curr Infect Dis Rep.* 2011;13(3):278-86.
3. Freeman RK, Vallières E, Verrier ED, et al. Descending necrotizing mediastinitis: an analysis of the effects of serial surgical debridement on patient mortality. *J Thorac Cardiovasc Surg.* 2000;119(2):260-7.
4. Dallaserra M, Poblete F, Vergara C, et al. Infectious postoperative complications in oral surgery. An observational study. *J Clin Exp Dent.* 2020;12(1):e65-e70.
5. Bali RK, Sharma P, Gaba S, et al. A review of complications of odontogenic infections. *Natl J Maxillofac Surg.* 2015;6(2):136-43.
6. Henry SM, Davis KA, Morrison JJ, et al. Can necrotizing soft tissue infection be reliably diagnosed in the emergency department? *Trauma Surg Acute Care Open.* 2018;3(1)e000157.
7. Stevens DL, Bisno AL, Chambers HF, et al. Practice Guidelines for the Diagnosis and Management of Skin and Soft Tissue Infections: 2014 Update by the Infectious Diseases Society of America. *Clin Infect Dis.* 2014;59(2):147–59.

# An Unusual Presentation of a Lymphatic Malformation in an Adult: A Case Report

Marguerite Gilmore\*  
Sharon H. Kim, PhD†  
Christopher M. McDowell, MD, MED, MBA‡

\*College of the Holy Cross, Worcester, Massachusetts  
†Southern Illinois University School of Medicine, Center for Clinical Research, Springfield, Illinois  
‡Southern Illinois University School of Medicine, Department of Emergency Medicine, Springfield, Illinois

Section Editor: Jacqueline Le, MD

Submission History: Submitted September 3, 2021; Revision received November 17, 2021; Accepted November 15, 2021

Electronically published January 28, 2022

Full text available through open access at [http://escholarship.org/uc/uciem\\_cpce](http://escholarship.org/uc/uciem_cpce)

DOI: 10.5811/cpce.2021.11.54618

**Introduction:** Patients commonly present with neck masses to the Emergency Department. The acute presentation of such a mass can be alarming to patients and their families. In this report we discuss a rare etiology of an acutely presenting neck mass in an adult.

**Case Report:** We present a 19-year-old patient with an acute neck mass. The mass developed abruptly soon after initiation of a new upper body strength-training regimen. The patient's history was unremarkable for any trauma or constitutional symptoms. Physical examination revealed the mass, which was diagnosed as a lymphatic malformation by imaging. Surgical removal was successful with pathology confirming the diagnosis.

**Conclusion:** Lymphatic malformations, although rare, may present in adulthood. The acute presentation of a new mass, coupled with a lack of concerning constitutional symptoms, should increase the diagnostic suspicion of a lymphatic malformation. [Clin Pract Cases Emerg Med. 2022;6(1):61–64.]

**Keywords:** *lymphatic malformation; lymphangioma; case report.*

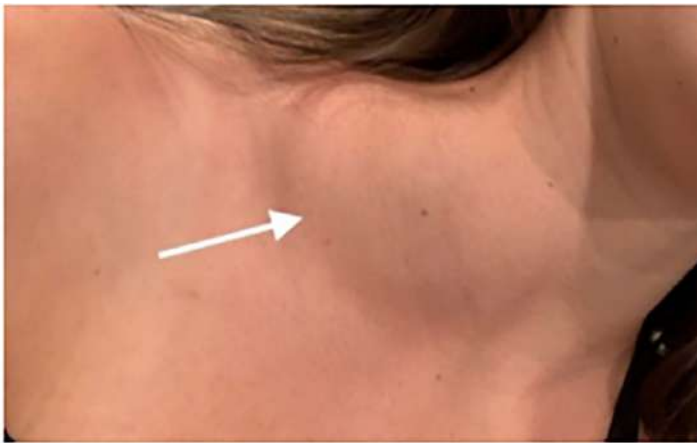## INTRODUCTION

Neck masses are a common presenting complaint among adult patients.<sup>1</sup> The differential for these masses is vast but may be organized by acuity. Acute masses are more likely to be related to infection or trauma, whereas subacute are more likely to be malignant.<sup>2</sup> An acute presentation without constitutional symptoms may indicate nonmalignant etiology. This case report highlights the importance of considering lymphatic malformation as a rare etiology of an acutely presenting neck mass. These malformations are typically detected and treated at birth or within the first two years of a child's life and rarely present in adulthood.<sup>3,4</sup> Although trauma has been implicated in rare presentations in adult cases, new strength-training regimens have not been previously reported as precipitating factors.<sup>5</sup> In this case report, we discuss the presentation, physical examination, imaging studies,

diagnosis, and surgical removal of an acute presentation of a lymphatic malformation in an adult.

## CASE REPORT

An otherwise healthy 19-year-old female presented to an outlying emergency department (ED) on the same day that she noted an acutely developed mass on the distal right neck (Image 1). The patient's past medical history was unremarkable, and she denied any constitutional symptoms such as fever, chills, night sweats, weight loss, or fatigue. There was no reported trauma. She denied difficulty swallowing but had noted slight shortness of breath. She was treated for a possible allergic reaction with diphenhydramine, but there was no response. An ultrasound was completed that showed a fluid collection in the supraclavicular area but no definitive diagnosis. The patient was instructed to follow



**Image 1.** Image taken on same day patient found a new mass (arrow) on the right supraclavicular region of her neck.

up with her primary physician or return to the ED for any worsening symptoms.

The patient presented to our ED the following day as concern grew for the lack of definitive diagnosis, and she was evaluated again. Once again, she denied trauma, constitutional symptoms, or difficulty swallowing. She noted the mass was new and first discovered while showering the day prior. She had recently initiated a new strength-training regimen for her upcoming athletic season, which focused on upper body development 14 days prior to discovery of the neck mass. She was afebrile at 36.8° Celsius with blood pressure of 131/54 millimeters of mercury, pulse of 64 beats per minute, respiratory rate of 14 breaths a minute, and oxygen saturation of 100% on room air.

Physical examination revealed a large, easily palpable, nonerythematous, slightly tender mass that extended from eight centimeters (cm) proximal to the clavicle to the supraclavicular region. There was no palpable associated lymphadenopathy. Laboratory studies included complete blood count with white blood count of 10 thousand cells per cubic millimeter (K/uL) (reference range: 3.4-9.4 k/uL), platelets of 175 K/uL (140-410 K/uL), hemoglobin of 13.5 grams per deciliter (gm/dL) (12-16 gm/dL), erythrocyte sedimentation rate of 4 millimeters per hour (mm/hr) (0-20 mm/hr); thyroid-stimulation hormone of 1.15 microinternational units per milliliter (μIU/ML) (0.45-5.33 μIU/ML); and mononucleosis test negative.

Computed tomography (CT) of the neck and soft tissue revealed a large cystic collection along the right neck deep to the sternocleidomastoid muscle and extending inferiorly into the supraclavicular region with two smaller, adjacent cystic collections. No aerodigestive tract mass or cervical lymphadenopathy was noted. The primary consideration was a large lymphatic malformation. Outpatient otolaryngology follow-up was arranged after they reviewed the CT results and concurred with the presumed lymphatic malformation diagnosis.

### *CPC-EM Capsule*

What do we already know about this clinical entity?

*Lymphatic malformations are usually diagnosed within the first two years of life.*

What makes this presentation of disease reportable?

*This was an acute presentation of a lymphatic malformation in an adult which is unusual in both acuteness and age of the patient.*

What is the major learning point?

*Lymphatic malformation should be considered in the differential diagnosis of an acutely presenting neck mass regardless of age.*

How might this improve emergency medicine practice?

*Emergency physicians can provide reassurance that acutely presenting masses lacking constitutional symptoms, recent illness, or associated lymphadenopathy may portend a better prognosis.*

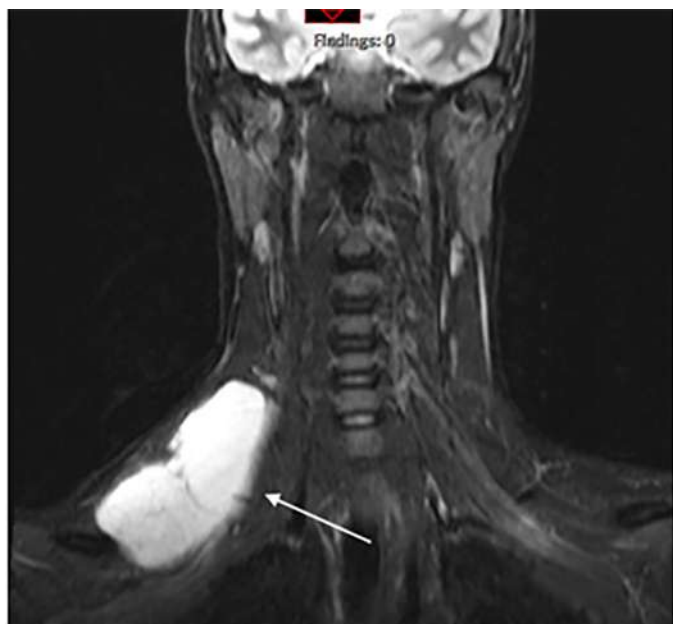The patient subsequently underwent magnetic resonance imaging (MRI) that was consistent with a lymphatic malformation (Image 2). Approximately three weeks after discovery, otolaryngology removed the mass, and pathology revealed a 68-gram 10.5 x 5.5 x 3.5 cm mass that was diagnosed as a lymphangioma.

After recovering from the surgery, the patient began physical therapy for her shoulder. At 10 weeks post-surgery, the patient was continuing with physical therapy and able to return to her collegiate crew participation.

### **DISCUSSION**

The differential for neck masses can be differentiated by acuity of presentation. Acute masses are most often infectious or traumatic. Subacute or chronic masses are more often considered to be malignant or related to other chronic illness (Table).<sup>11</sup>

Lymphatic malformations are uncommon, benign masses that result from abnormal lymphatic system development. The preferred term lymphatic malformation encompasses cystic hygromas, lymphangiomas, cavernous lymphangiomas, cystic



**Image 2.** Coronal view T2 short T1 inversion recovery magnetic resonance image with arrow depicting hyperintense supraclavicular lesion consistent with lymphatic malformation.

lymphangiomas, and lymphangioma circumscriptum. In the majority of cases, these masses are recognized by two years of age, where prevalence is believed to be approximately 1:4000 live births.<sup>6</sup> These abnormalities are most commonly found in the head or neck but can be seen throughout the body’s lymphatic system.<sup>7</sup> These presentations are so rare in adulthood that the prevalence is not well defined.<sup>8</sup> Although precipitation by trauma has been reported in very rare circumstances, we are unaware of prior presentations due to new exercise regimens.<sup>5,9,10</sup> In our case, the patient had initiated a new upper body strength-training regimen about 14 days prior to mass discovery. These sessions included a 20-30 minute arm circuit that focused on arm flies, shoulder presses,

and push-ups. The patient denied any new trauma or noted injuries during strength training.

Diagnosis of lymphatic malformations usually requires advanced imaging. Determining which imaging modality to choose can be difficult for the emergency physician. Ultrasound can determine cystic structures but lacks the ability to reliably establish mass etiology.<sup>11</sup> Computed tomography and MRI multiplanar images reveal better identifying characteristics. In addition, these images are especially helpful in surgical planning.<sup>11</sup> Histopathological assessment is necessary to confirm diagnosis in adults.<sup>12</sup> In the absence of dysphagia or breathing difficulty, a stepwise diagnostic progression would be reasonable. This may include ED referral to the primary physician or otolaryngology for more definitive imaging.

Treatment options for lymphatic malformations include percutaneous drainage, surgery, sclerotherapy, laser therapy, and radiofrequency ablation.<sup>3</sup> Aspiration can be helpful in diagnosis but often does not prevent recurrence. Previous cases suggest surgical excision as the preferred treatment modality in adults to mitigate tumor recurrence.<sup>12,13</sup> Decisions regarding treatment strategies will depend on location and associated symptoms as well. For instance, patients suffering from dysphagia, dyspnea, or other vital structures at risk often require surgery. Conversely, complete resection may not be possible due to localization and microvasculature of the mass near essential organs, in which case alternative methods must be considered.<sup>9</sup>

**CONCLUSION**

We report a case of a lymphatic malformation that presented acutely as a new neck mass in an adult. Rapidly developed new-onset masses should be evaluated as possible lymphatic malformations. The lack of constitutional symptoms and rapid onset make malignant neoplasm less likely. Advanced CT and MRI imaging led to the diagnosis and helped to prepare for successful surgical excision.

**Table.** Neck mass etiologies by onset.<sup>2</sup>

Presentation	Common	Uncommon
Acute	Viral upper respiratory infection Reactive lymphadenopathy: Epstein-Barr virus Cytomegalovirus Toxoplasmosis	Human immunodeficiency virus <i>Mycobacterium tuberculosis</i> Hematoma Acute sialoadenitis Pseudoaneurysm Trauma
	Subacute (weeks to months)	Cancer: Hodgkin & non-Hodgkin lymphoma Human papillomavirus-related Squamous cell carcinoma Metastatic cancer Parotid tumor



The authors attest that their institution requires neither Institutional Review Board approval nor patient consent for publication of this case report. Documentation on file.

**Address for Correspondence:** Christopher M. McDowell, MD, MBA, MEd, Southern Illinois University School of Medicine, Department of Emergency Medicine, 701 North First Street, Springfield, IL 62781. Email: cmcdowell@siu.edu.

**Conflicts of Interest:** By the CPC-EM article submission agreement, all authors are required to disclose all affiliations, funding sources and financial or management relationships that could be perceived as potential sources of bias. The authors disclosed none.

**Copyright:** © 2022 Gilmore. This is an open access article distributed in accordance with the terms of the Creative Commons Attribution (CC BY 4.0) License. See: <http://creativecommons.org/licenses/by/4.0/>

## REFERENCES

1. Pynnonen MA, Gillespie MB, Roman B, et al. Clinical practice guideline: evaluation of the neck mass in adults. *Otolaryngol Head Neck Surg.* 2017;157(2\_suppl):S1-S30.
2. Haynes J, Arnold KR, Aguirre-Oskins C, et al. Evaluation of neck masses in adults. *Am Fam Physician.* 2015;91(10):698-706.
3. Elluru RG, Balakrishnan K, Padua HM. Lymphatic malformations: diagnosis and management. *Semin Pediatr Surg.* 2014;23(4):178-85.
4. Mukakala AK, Banza MI, Musapudi EM, et al. Cystic hygroma of the neck in a young adult: about a case and literature review. *Pan Afr Med J.* 2020;36:54.
5. Aneeshkumar MK, Kale S, Kabbani M, et al. Cystic lymphangioma in adults: Can trauma be the trigger? *Eur Arch Otorhinolaryngol.* 2005;262(4):335-7.
6. Sun RW, Tuchin VV, Zharov VP, et al. Current status, pitfalls and future directions in the diagnosis and therapy of lymphatic malformation. *J Biophotonics.* 2018;11(8):e201700124.
7. Perkins JA, Manning SC, Tempero RM, et al. Lymphatic malformations: current cellular and clinical investigations. *Otolaryngol Head Neck Surg.* 2010;142(6):789-94.
8. Gow L, Gulati R, Khan A, et al. Adult-onset cystic hygroma: a case report and review of management. *Grand Rounds.* 2011;11(1):5-11.
9. Evman MD and Aydin S. A giant cervical lymphangioma. *J Craniofac Surg.* 2019;30(3):e275-e276.
10. Gleason TJ, Tuh WT, Tali ET, et al. Traumatic cervical cystic lymphangioma in an adult. *Ann Otol Rhinol Laryngol.* 1993;102(7):564-6.
11. National Organization for Rare Disorders. Lymphatic malformations. Available at <https://rarediseases.org/rare-diseases/lymphatic-malformations/>. Accessed March 12, 2021.
12. Colangeli W, Facchini V, Kapitonov A, et al. Cystic lymphangioma in adult: a case report and a review of the literature. *J Surg Case Rep.* 2020;2020(7):rjaa179.
13. Basurto-Kuba EOP, Hurtado-Lopez LM, Campos-Castillo C, et al. Cervical lymphangioma in the adult. A report of 2 cases. *Cir Cir.* 2016;84(4):313-7.

# 18-year-old with Abdominal Pain Due to Congenital Bowel Malrotation: A Case Report

Ellen McMahon, MD\*  
Michael Penfold, MD†  
Meghan Cain, MD‡

\*Vanderbilt University Medical Center, Division of General Pediatrics, Department of Pediatrics, Nashville, Tennessee

†Mayo Clinic, Department of Pediatrics, Rochester, Minnesota

‡Mayo Clinic, Department of Emergency Medicine, Rochester, Minnesota

Section Editor: Melanie Heniff, MD, JD

Submission History: Submitted July 13, 2021; Revision received November 5, 2021; Accepted November 15, 2021

Electronically published January 28, 2022

Full text available through open access at [http://escholarship.org/uc/uciem\\_cpem](http://escholarship.org/uc/uciem_cpem)

DOI: 10.5811/cpcem.2021.11.52611

**Introduction:** Congenital bowel malrotation resulting in midgut volvulus is traditionally regarded as a diagnosis of infancy. Rarely, congenital bowel malrotation is diagnosed in adolescents or adults and requires a high index of suspicion. Presentations can be acute or chronic, and physical examination findings are nonspecific. Diagnosis is primarily achieved through abdominal computed tomography (CT) or during exploratory laparotomy. The pathophysiology in late-onset malrotation is similar to neonatal malrotation, with a division of Ladd's bands – peritoneal fibrous bands that connect the cecum to the right lower quadrant retroperitoneum – as the definitive treatment. We present a case of congenital bowel malrotation in an adolescent with persistent and worsening migratory abdominal pain.

**Case Report:** An 18-year-old female presented to the emergency department with two days of poorly localized abdominal pain and nausea. Initial evaluation was unremarkable and she was discharged home with a diagnosis of constipation. She returned two days later with worsening abdominal pain and new onset emesis. Given her persistent and worsening symptoms an abdominal CT was performed, which revealed malrotation of the bowel. Taken together, her CT findings and abdominal symptoms were concerning for symptomatic congenital bowel malrotation and she underwent a Ladd procedure. She remained asymptomatic both at discharge and at two-week postoperative follow-up.

**Conclusion:** Symptomatic congenital bowel malrotation is more common in older children and adults than has traditionally been thought. Physicians must consider this diagnosis in their differential when working up a patient for acute or chronic intermittent abdominal pain to prevent potentially severe sequelae. [Clin Pract Cases Emerg Med. 2022;6(1):65-68.]

**Keywords:** case report; emergency medicine; abdominal pain; bowel malrotation; Ladd procedure.

## INTRODUCTION

An 18-year-old female presented to the emergency department (ED) with acute onset of diffuse abdominal pain and nausea without vomiting. Initial differential diagnosis included etiologies of abdominal pain that are commonly considered in this age group in the emergency setting, such as appendicitis, constipation, obstruction, inflammatory bowel disease, urinary tract infection, pregnancy, cholecystitis, ovarian cyst, and ovarian torsion. The ED evaluation, including ultrasound imaging of the appendix was reassuring, and she was discharged to home with

treatment for constipation. She returned to the ED two days later with severe right lower quadrant (RLQ) abdominal pain and non-bloody, nonbilious vomiting. A thorough workup was notable for congenital bowel malrotation; symptoms were relieved following surgical treatment. This case demonstrates that, while traditionally thought of as a diagnosis of infancy, congenital bowel malrotation should be considered in the differential diagnosis of older children, adolescents, and adults with abdominal complaints. Surgical management is the definitive treatment and leads to resolution of abdominal symptoms.

## CASE REPORT

An 18-year-old girl with a history of migraine headaches, allergic rhinitis, ovarian cysts, and multiple food allergies was referred to the ED with complaints of poorly localized abdominal pain and nausea without vomiting. She had presented to her primary care physician (PCP) earlier in the day with similar complaints and was noted to have decreased bowel sounds and diffuse abdominal tenderness to palpation. At that time, her PCP recommended she proceed to the ED for further evaluation. She had been started on omeprazole one month prior for presumed gastroesophageal reflux disease and endorsed a longstanding history of constipation. In the ED, she complained of two days of intermittent, migratory, cramping abdominal pain associated with diarrhea. Vitals signs were within normal limits. Her exam was notable for tenderness in the epigastrium and RLQ. Gallbladder and appendix ultrasounds (US) were negative for cholelithiasis, cholecystitis, or appendicitis. The patient's abdominal pain improved over a matter of hours, and she was discharged home with instructions to return to the ED if her symptoms returned.

The patient returned to the ED two days later with worsening abdominal pain. It was rated at a 10 of 10 in severity, stabbing in nature, located in the RLQ, with associated nausea and non-bloody, nonbilious vomiting. She was afebrile, tachycardic, and had flushing of the face, neck, and chest. She had an intrauterine device (IUD) and noted two days of bright red vaginal bleeding that she felt was different in quality than her typical menses. She reported having a bowel movement the previous day without blood in the stool, and her diarrhea had resolved. On exam, she had tenderness to palpation in the RLQ and right flank. Physical exam was otherwise unremarkable. Differential diagnosis at this time included gallbladder pathology, such as cholelithiasis or cholecystitis, or appendicitis not seen on initial US, inflammatory bowel disease, irritable bowel syndrome, pancreatitis, urinary tract infection, pyelonephritis, abdominal migraine, or pelvic pathology such as ovarian torsion, ovarian cyst, or ruptured ectopic pregnancy.

Initial labs were obtained and included complete blood count, C-reactive protein, hepatic function panel, lipase, coronavirus disease 2019, and urine pregnancy test, all of which were negative or unremarkable. Laboratory studies were notable for a bicarbonate of 18 milliequivalents per liter (mEq/L) (reference range: 23-30 mEq/L) and an anion gap of 16 mEq/L (3-10 mEq/L). Transabdominal and transvaginal pelvic US were negative for ovarian torsion, cysts, or ectopic pregnancy. Her IUD was noted to be in the proper position. Given progression of symptoms and prior unremarkable abdominal US, an abdominal computed tomography (CT) with intravenous (IV) contrast was performed. Abdominal CT demonstrated congenital bowel malrotation with small bowel on the right side and colon on the left side of the abdomen (Image). The appendix was identified and normal in

### CPC-EM Capsule

What do we already know about this clinical entity?

*Congenital bowel malrotation resulting in midgut volvulus is typically regarded as a diagnosis of infancy and can result in bowel necrosis, a surgical emergency.*

What makes this presentation of disease reportable?

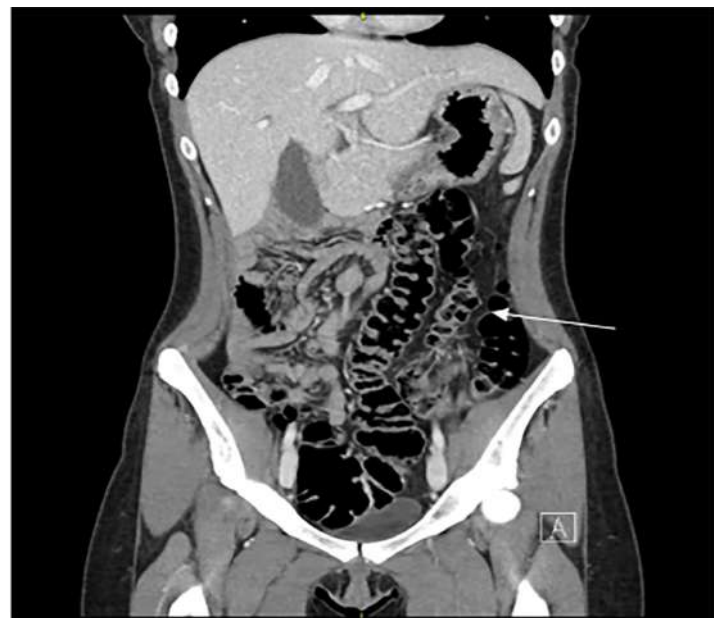*Congenital bowel malrotation is rarely considered in the differential diagnosis of patients presenting with a chief complaint of abdominal pain.*

What is the major learning point?

*It is a rare but increasingly reported cause of abdominal pain in adolescents and adults. The presentation is highly variable and may include acute or chronic abdominal pain.*

How might this improve emergency medicine practice?

*Emergency clinicians should consider congenital bowel malrotation in the differential diagnosis, particularly for patients who present multiple times.*



**Image.** Abdominal computed tomography demonstrating congenital bowel malrotation with small bowel on the right side and colon on the left side of the abdomen. Arrow indicates the location of the colon on the left side of the abdomen.

appearance. There was no evidence of bowel obstruction or active bowel inflammation on CT. All other identified organs, including ovaries, gallbladder, liver, spleen, and kidneys, were normal in appearance.

The patient was given IV fluids, morphine for pain control, and ondansetron for nausea. Pediatric surgery was consulted for consideration of surgical intervention. The patient was admitted to the hospital for pain control and brought to the operating room three days after her initial presentation for a laparoscopic Ladd's procedure given her CT findings of bowel malrotation without alternative diagnosis. Her abdominal pain was thought to be secondary to intermittent volvulus. Intraoperatively, the gallbladder, uterus, and ovaries were normal in appearance. The appendix was grossly normal; however, an appendectomy was performed and sent for pathology. There were few adhesions noted between the right colon and the right abdominal wall. The duodenum had numerous adhesions between the liver and small bowel. She tolerated the procedure without any complications.

The patient's symptoms of abdominal pain and nausea improved postoperatively, and she was discharged to home two days after the procedure. On post-hospital follow-up two weeks after discharge the patient reported complete resolution of gastrointestinal symptoms. Pathology demonstrated an appendix with minimal focal mucosal inflammation and without perforation or fecalith.

## DISCUSSION

Congenital bowel malrotation results from a disruption of normal embryologic development of the intestine when the midgut fails to rotate around the superior mesenteric vessels.<sup>1,2</sup> The total incidence is thought to be approximately one in 500 to one in 6000 live births.<sup>3,4</sup> It is most often thought of as a disease process of infancy, and it is estimated that between 64-80% of cases present within the first month of life and approximately 90% within the first year. Malrotation results in a bowel with a narrow base of mesenteric fixation, which is a risk factor for the development of midgut volvulus.<sup>5</sup> Midgut volvulus is an emergent complication that occurs when the bowel twists around the superior mesenteric artery axis, which can result in intestinal necrosis.<sup>6</sup> In infants, this presents most commonly with bilious emesis, prompting an emergent workup using upper gastrointestinal fluoroscopy and barium contrast to reveal malposition of the duodenal-jejunal junction.<sup>7</sup> In older children and adults, presentation is more varied: symptoms may include recurrent episodes of colicky abdominal pain, nausea, vomiting, and diarrhea, or may have a more acute presentation.<sup>8,9,10</sup> Chronic intermittent symptoms in these populations are likely due to intermittent volvulus or obstruction from Ladd's bands.<sup>11</sup>

Malrotation of the bowel can be identified on abdominal CT with IV contrast by identification of the ascending colon on the left side of the abdomen with small bowel on the right.<sup>5</sup> There is no reliable means to determine which patients with congenital bowel malrotation will develop complications, such

as midgut volvulus, as some patients remain asymptomatic with the diagnosis only noted on autopsy.<sup>3,8,10,11</sup>

The definitive treatment for bowel malrotation is a Ladd's procedure, in which the Ladd's bands, the mesenteric bands extending from the colon across the duodenum, are divided. Associated adhesions are lysed to broaden the base of the mesentery, and in some cases a concomitant appendectomy is performed.<sup>13,14</sup> This results in anatomical correction of the anatomy with the small bowel repositioned to the right side of the abdomen and the colon on the left.<sup>13</sup>

Some clinicians suggest that patients with chronic symptoms or asymptomatic patients with incidental discovery of congenital malrotation should undergo a Ladd's procedure as there is no way to determine who may go on to develop future complications including midgut volvulus.<sup>7,15</sup> It has been reported that up to 89% of patients with symptomatic congenital bowel malrotation will have complete resolution of symptoms following a Ladd's procedure.<sup>15</sup> Our case demonstrates a previously healthy adult with acute abdominal symptoms from congenital malrotation of the bowel that resolved after undergoing a Ladd's procedure.

## CONCLUSION

While symptomatic congenital bowel malrotation has been traditionally thought of as a disease of infancy, this case illustrates that it must also be considered as a part of the differential diagnosis of abdominal pain in older children and adults. Given the lower degree of suspicion for this diagnosis in these populations, delays in diagnosis may result in increased morbidity as intestinal necrosis can result from volvulus secondary to bowel malrotation, and the time to surgical intervention is crucial in preventing this complication. This case further illustrates that uncommon etiologies for a common chief complaint must be considered when a patient presents on multiple occasions despite an unremarkable initial evaluation.

The authors attest that their institution requires neither Institutional Review Board approval nor patient consent for publication of this case report. Documentation on file.

*Address for Correspondence:* Ellen McMahon, MD, Vanderbilt Children's Hospital, Doctor's Office Tower 8232, 2200 Children's Way, Nashville, TN 37232-9225. Email: ellen.mcmahon@vumc.org.

*Conflicts of Interest:* By the CPC-EM article submission agreement, all authors are required to disclose all affiliations, funding sources and financial or management relationships that could be perceived as potential sources of bias. The authors disclosed none.

*Copyright:* © 2022 McMahon. This is an open access article distributed in accordance with the terms of the Creative Commons Attribution (CC BY 4.0) License. See: <http://creativecommons.org/licenses/by/4.0/>



## REFERENCES

1. Nehra D and Goldstein AM. Intestinal malrotation: varied clinical presentation from infancy through adulthood. *Surgery*. 2011;149(3):386-93.
2. Alemany VS, Truong T, Monserrate GR, et al. Adult midgut malrotation: a case report. *J Surg Proc & Case Rep*. 2020;2(101):1-5.
3. Torres AM and Ziegler MM. Malrotation of the intestine. *World J Surg*. 1993;17:326-31.
4. Aboagye J, Goldstein SD, Salazar JH, et al. Age at presentation of common pediatric surgical conditions: reexamining dogma. *J Pediatr Surg*. 2014;49:995-9.
5. Pickhardt, PJ and Bhalla, S. Intestinal malrotation in adolescents and adults: spectrum of clinical and imaging features. *AJR Am J Roentgenol*. 2002;179(6):1429-35.
6. Lampl B, Levin TL, Verdon WE, et al. Malrotation and midgut volvulus: a historical review and current controversies in diagnosis and management. *Pediatr Radiol*. 2009;39(Suppl 2):S164-166.
7. Kapfer SA and Rappold JF. Intestinal malrotation-not just the pediatric surgeon's problem. *J Am Coll Surg*. 2004;199:628-35.
8. von Flue M, Herzog U, Ackermann C, et al. Acute and chronic presentation of intestinal nonrotation in adults. *Dis Colon Rectum*. 1994;37:192-8.
9. Gamblin TC, Stephens RE Jr, Johnson RK, et al. Adult malrotation: a case report and review of the literature. *Curr Surg*. 2003;60:517-20.
10. Berdon WE, Baker DH, Bull S, et al. Midgut malrotation and volvulus. Which films are most helpful? *Radiology*. 1970;96:375-84.
11. Maxson RT, Franklin PA, Wagner CW. Malrotation in the older child: surgical management, treatment, and outcome. *Am Surg*. 1995;61:135-8.
12. Durkin ET, Lund DP, Shaaban AF, et al. Age-related differences in diagnosis and morbidity of intestinal malrotations. *J Am Coll Surg*. 2008;206:658-63.
13. Ladd W. Surgical disease of the alimentary tract in infants. *N Engl J Med*. 1936;215:705-8.
14. Kotze PG, Martins JF, Rocha JG, et al. Ladd procedure for adult intestinal malrotation: case report. *Arq Bras Cir Dig*. 2011;24:89-91.
15. Malek MM and Burd RS. Surgical treatment of malrotation after infancy: a population-based study. *J Pediatr Surg*. 2005;40:285-9.

# Critical Point-of-care Ultrasound Diagnosis of Fournier's Gangrene: A Case Report

Lauren Ramm, MD  
Kayla Guidry, MD  
Angela Cirilli, MD  
Ellen Kurkowski, MD  
Connie Yu, MD

St. John's Riverside Hospital, Department of Emergency Medicine, Yonkers, New York

Section Editor: Shadi Lahham, MD

Submission History: Submitted September 23, 2021; Revision received November 12, 2021; Accepted November 22, 2021

Electronically published January 28, 2022

Full text available through open access at [http://escholarship.org/uc/uciem\\_cpem](http://escholarship.org/uc/uciem_cpem)

DOI: 10.5811/cpcem.2021.11.54849

**Introduction:** Fournier's gangrene is a severe, necrotizing, and potentially fatal, soft tissue infection of the perineum that can be difficult to diagnose clinically. Point-of-care ultrasound (POCUS) has established a critical role in emergency medicine as a quick diagnostic tool due to its safety, accuracy, and cost effectiveness.

**Case Report:** We present a case in which POCUS was used to rapidly confirm diagnosis in an unstable, severely septic patient presenting to the emergency department with Fournier's gangrene.

**Conclusion:** Point-of-care ultrasound can be used to make the diagnosis of Fournier's gangrene in critical patients when other diagnostic modalities are not feasible due to a patient's clinical state. [Clin Pract Cases Emerg Med. 2022;6(1):69-72.]

**Keywords:** *point-of-care ultrasound; Fournier's gangrene; necrotizing infections; emergency medicine; case report.*

## INTRODUCTION

Fournier's gangrene is a subset of necrotizing fasciitis most commonly caused by a polymicrobial infection of the perineal, genital, or perianal area. Affected patients are typically immunocompromised, with the most frequent comorbidities being diabetes mellitus and chronic alcohol abuse.<sup>1,2</sup> Patients often present reporting only erythema and pain, making it tough to differentiate from scrotal cellulitis with physical exam alone.<sup>2</sup> Visible necrosis and crepitus are typically late findings, and severe infection can develop rapidly despite the overlying skin appearance.<sup>3</sup> There can be profound systemic findings out of proportion to the local extent of disease, eventually leading to shock, multiorgan system failure, and death.

Fournier's gangrene is a synergistic necrotizing infection that produces leukocidal toxins and causes obliterating endarteritis that leads to micro-thrombophlebitis in the small subcutaneous vessels, thus leading to ischemia and necrosis

as well as facilitating bacterial spread.<sup>3</sup> Definitive treatment is immediate surgical debridement. Delay in treatment can result in significant morbidity, including extensive tissue loss, and mortality rates of 3-75%.<sup>1,2,4,5</sup> Our case report shows the vital role point-of-care ultrasound (POCUS) played in early diagnosis and management of a hemodynamically unstable case of Fournier's gangrene in the emergency department (ED).

## CASE REPORT

A 71-year-old male with past medical history significant for diabetes mellitus, coronary artery disease, chronic hypotension, hyperglycemia, chronic obstructive pulmonary disease, nicotine use, obstructive sleep apnea, and peripheral artery disease presented to the ED with right buttock and scrotal swelling for three days, associated with generalized weakness, shortness of breath, and urinary retention with dysuria. One day prior to presentation, the patient noticed non-traumatic bruising to his scrotum. He

additionally reported increasing buttock pain that was not controlled by home oxycodone/acetaminophen 5/325 milligram (mg) tablets.

Upon arrival, his vital signs were notable for an oral temperature of 38.2° Celsius, blood pressure of 119/54 millimeters of mercury (mm Hg), and heart rate of 93 beats per minute. He was also tachypneic with a respiratory rate of 25 breaths per minute; oxygen saturation was 97% on room air. The physical examination was notable for an ill-appearing gentleman. He was awake and alert. Heart sounds were unremarkable aside from tachycardia, and lungs were clear to auscultation. Abdominal examination was soft, protuberant, and nontender. A focused genitourinary examination revealed an edematous, erythematous and exquisitely tender scrotum. Of note, there was a coin-sized, ecchymotic-appearing lesion on the scrotum with erythema and induration extending from the scrotum and perineum to the right buttock. No crepitus or fluctuance was palpated on examination.

Laboratory results were remarkable for leukocytosis to 15,000 thousand per millimeters cubed (K/mm<sup>3</sup>) (reference range: 4–10 K/mm<sup>3</sup>), lactic acidosis of 3.4 millimoles per liter (mmol/L) (0.4–2.0 mmol/L), marked acute kidney injury with creatinine of 5 mg per deciliter (mg/dL) (0.55–1.3mg/dL), and venous blood gas pH of 7.22 (7.310–7.410) secondary to the lactic acidosis and severe sepsis. The patient was mildly hyponatremic at 133 mmol/L (136–145 mmol/L) and hyperkalemic at 5.3 mmol/L (3.5–5.1 mmol/L), with the remainder of electrolytes within reference range. Intravenous antibiotics were initiated and emergent consultations with surgery and urology promptly obtained. Despite initial fluid resuscitation with administration of 30 milliliters per kilogram (ml/kg) of normal saline, the patient decompensated into septic shock. His blood pressure decreased to 88/41 mm Hg during the ED course; thus, he was not stable for transport or advanced imaging. By this time, the ecchymotic-appearing lesion and edema had expanded across his scrotum and perineum.

We used POCUS for the rapid assessment of the patient's presumed clinical diagnosis of Fournier's gangrene, a specific type of necrotizing fasciitis involving the perineum. Transverse and sagittal views of the perineum and scrotum were obtained using a high-frequency linear probe and revealed diffuse hyperechoic foci with posterior "dirty" shadowing, representative of subcutaneous air, and small fluid collections tracking along the fascial planes (Image).

After confirming the diagnosis using POCUS imaging, the patient was taken directly from the ED to the operating room for immediate surgical debridement within three hours of his arrival at the hospital. An area of tissue measuring 25 centimeters (cm) x 30 cm that included both fascia and muscle was debrided from the scrotum, perineum, and right buttock. Dark, necrotic tissue and foul-smelling fluid were noted during surgery, consistent with Fournier's gangrene.

### CPC-EM Capsule

What do we already know about this clinical entity?

*Fournier's gangrene is a severe, necrotizing, and potentially fatal, soft tissue infection of the perineum that can be difficult to diagnose clinically.*

What makes this presentation of disease reportable?

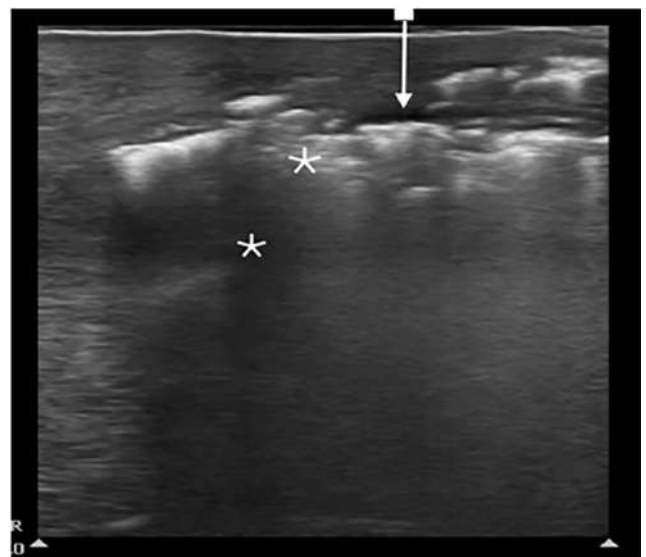
*We used point-of-care ultrasound (POCUS) to rapidly confirm Fournier's gangrene in an unstable, severely septic patient in place of advanced imaging.*

What is the major learning point?

*Sonographic diagnosis of Fournier's gangrene is a skill similar to other soft tissue diagnoses; POCUS can be performed looking for the signs identified in this case.*

How might this improve emergency medicine practice?

*Point-of-care ultrasound to diagnose Fournier's gangrene and other necrotizing soft tissue infections has the potential to decrease the time to diagnosis and treatment.*



**Image.** Ultrasound image using high-frequency linear probe showing presence of hypoechoic fluid collection (arrow) between fascial layers and underlying "dirty" hyperechoic A-lines with shadowing (\*) indicating the presence of subcutaneous air.

The patient was admitted to the intensive care unit until being transferred to a tertiary care center where he ultimately died of complications related to his illness.

## DISCUSSION

Fournier's gangrene is an illness with significant morbidity and mortality. Diagnosis requires a high degree of clinical suspicion as it is often difficult to diagnose accurately based solely on examination. Physical examination often displays scrotal or perineal swelling, pain out of proportion to physical findings (72%), erythema (72%), edema beyond the area of erythema (75%), and crepitus (12-36%), but clinical diagnosis can be difficult in the early stages of the disease.<sup>3</sup> Frequently, erythema and pain are the only initial presenting signs.<sup>2,6</sup> Systemic inflammatory marker release can cause fever, tachycardia, and hypotension with potentially rapid progression to cardiovascular collapse and shock.<sup>3</sup>

If clinical suspicion is high for a necrotizing soft tissue infection, then early operative debridement is imperative as necrotic tissue and sepsis can progress rapidly.<sup>1</sup> Current guidelines state the best initial radiographic examination is computed tomography (CT) with contrast, which can detect subcutaneous gas in soft tissues, a highly specific finding for necrotizing soft tissue infections, in addition to showing the source of infection.<sup>7</sup> Due to rapid patient decline and hemodynamic instability, however, it may be difficult to obtain the necessary imaging to confirm the diagnosis without compromising patient safety. Additionally, intravenous contrast necessary to highlight surrounding inflammation, such as fat stranding, may not be possible due to significant kidney injury that frequently occurs with septic shock such as in this case.

Ultrasound is well known to be an excellent modality for detection of necrotizing soft tissue infections in other anatomical areas such as extremities.<sup>5</sup> A few published articles have reported the diagnosis of Fournier's gangrene using ultrasound, but all those cases were confirmed with subsequent CT or magnetic resonance imaging.<sup>2,4,6,8</sup> Only one prior publication discussed the utility of POCUS performed by an emergency physician for rapid diagnosis of Fournier's gangrene.<sup>9</sup> Currently, the available literature describes POCUS as a useful tool to distinguish Fournier's gangrene from other sonographically diagnosed causes of scrotal pain such as torsion, abscess, epididymitis, orchitis, testicular fracture, or incarcerated or strangulated hernia. Most authors suggest that confirmatory imaging is needed following sonographic evaluation of Fournier's gangrene to show the extent of infection, presence of gas, and to guide surgical debridement.<sup>4,6,8</sup>

One prospective, observational study that looked at the accuracy of ultrasound in the diagnosis of necrotizing fasciitis demonstrated POCUS had a sensitivity of 88.2-100%, a specificity of 87.5-93.3%, a positive predictive value of 83.3%, and negative predictive value of 95.4% with an overall accuracy of 91.1%. Authors of the study reported that all the patients in the false negative group survived to discharge from the hospital, and

all patients in the false positive group were ultimately diagnosed with cellulitis. The study was limited, however, to necrotizing infections of the limbs and excluded any patients who were suspected of having necrotizing infections of the scrotum.<sup>5,7</sup> There is little, if any, data available to date regarding the sensitivity or specificity of POCUS for diagnosing necrotizing infections of the scrotum and perineum specifically.

Although testicular ultrasound for torsion is considered an advanced POCUS skill, diagnosis of Fournier's gangrene is a skill that any emergency physician who has experience performing soft tissue ultrasound can and should be credentialed to perform. A high-frequency, linear transducer is used as is the case for most soft tissue examinations, using adequate gel. The scrotal tissue and surrounding inguinal tissue can then be surveyed looking for the classic findings of any necrotizing skin infection as seen in this case.

Sonographic findings include thickened subcutaneous tissues with characteristic hyperechoic foci with reverberation artifacts causing "dirty shadowing" indicative of subcutaneous gas. The underlying testes are spared as they have a separate blood supply. These findings are typically present before crepitus or air in the tissues can be appreciated clinically.<sup>6</sup> In addition, ultrasound may display abnormal anechoic fluid collections between hyperechoic fascial planes, and this finding will often precede the presence of subcutaneous air, which is a late finding. All these findings can be remembered with the STAFF mnemonic, which stands for subcutaneous thickening, acoustic shadowing, and fascial fluid.<sup>10</sup> There are few additional teaching tools regarding POCUS diagnosis of Fournier's gangrene except for a few published case reports and radiologic resources; however, the diagnosis follows the same sonographic principles as taught and published for the diagnosis of necrotizing fasciitis in other areas of the body.<sup>2,4,6,9,10</sup>

Point-of-care ultrasound allows for rapid diagnosis of necrotizing soft tissue infections including Fournier's gangrene and is readily available at the bedside, precluding the need for potentially dangerous transport of a critical patient out of the department. The time saved by making a diagnosis of Fournier's gangrene with POCUS is significant compared to the time it takes to obtain advanced imaging such as CT with contrast, which can often be delayed in a busy ED for several hours due to various reasons. This time can be critical time saved to definitive surgical treatment and expedite the initiation of the appropriate resuscitation once this grave illness is recognized.

In this case, our patient presented with a relatively small area of visible necrosis and surrounding erythema and edema on physical exam but had a deeper infection. Performing POCUS allowed for rapid diagnosis of a deep infection and prompt surgical consult and debridement when CT imaging was not possible due to the patient's hemodynamic instability and organ failure. This case highlights that using ultrasound routinely to confirm the diagnosis of Fournier's gangrene and other necrotizing soft tissue infections has the potential to decrease the time to diagnosis and definitive treatment



and to mobilize the surgical team, thereby improving patient outcomes. In addition, ultrasound imaging does not transmit radiation, is low cost, rapidly accessible, and allows the patient to safely remain in the ED.

## CONCLUSION

Clinical diagnosis of Fournier's gangrene is often difficult and unreliable with physical examination and history alone, but it is a diagnosis that cannot be missed. The degree of disease is often hidden beneath the surface of benign-appearing cutaneous tissue until rapid hemodynamic decompensation occurs. Advanced imaging such as CT is currently the gold standard for diagnosis but can be impractical due to the instability of many patients affected, as in the case described here, in addition to added time, cost considerations, and exposure to radiation and contrast. This case highlights point-of-care ultrasound as a potential alternative and timesaving measure in critical patients. In addition, it may reduce the time to diagnosis and, therefore, mobilization of the appropriate specialist to decrease the overall time to treatment.

Patient consent has been obtained and filed for the publication of this case report. The authors attest that their institution does not require Institutional Review Board approval for the publication of this case report. Documentation on file.

*Address for Correspondence:* Angela Cirilli, MD, St. John's Riverside Hospital, Department of Emergency Medicine, 967 N Broadway, Yonkers, NY 10701. Email: [angcirilli@gmail.com](mailto:angcirilli@gmail.com).

*Conflicts of Interest:* By the CPC-EM article submission agreement, all authors are required to disclose all affiliations, funding sources and financial or management relationships that could be perceived as potential sources of bias. The authors disclosed none.

*Copyright:* © 2022 Ramm. This is an open access article distributed in accordance with the terms of the Creative Commons Attribution (CC BY 4.0) License. See: <http://creativecommons.org/licenses/by/4.0/>

## REFERENCES

1. Eke N. Fournier's gangrene: a review of 1726 cases. *Br J Surg.* 2000;87:718-28.
2. Morrison D, Blaivas M, Lyon M. Emergency diagnosis of Fournier's gangrene with bedside ultrasound. *Am J Emerg Med.* 2005;23(4):544-7.
3. Stevens DL and Bryant AE. Necrotizing soft-tissue infections. *N Engl J Med.* 2017;377(23):2253-65.
4. Oktar SO, Yucel C, Ercan NT, et al. Fournier's gangrene: US and MR imaging findings. *Eur J Radiol.* 2004;50(3):81-7.
5. Yen ZS, Wang HP, Ma HM, et al. Ultrasonographic screening of clinically suspected necrotizing fasciitis. *Acad Emerg Med.* 2002;9(12):1448-51.
6. Di Serafino M, Gullotto C, Gregorini C, et al. A clinical case of Fournier's gangrene: imaging ultrasound. *J Ultrasound.* 2014;17(4):303-6.
7. Levenson RB, Singh AK, Novelline RA. Fournier gangrene: role of imaging. *Radiographics.* 2008;28(2):519-28.
8. Conzi R, Damasio MB, Bertolotto M, et al. Scrotal Imaging Group of the European Society of Urogenital Radiology. Sonography of scrotal wall lesions and correlation with other modalities. *J Ultrasound Med.* 2017;36(10):2149-63.
9. Penalosa P, Drachman MA, Han V. Bedside ultrasound for the rapid diagnosis of Fournier's gangrene. *J Ed Teach Emerg Med.* 2019;4(2):5-6.
10. Castleberg E, Jenson N, Dinh V. Diagnosis of necrotizing fasciitis with bedside ultrasound: the STAFF exam. *West J Emerg Med.* 2014;15(1):111-3.

# An Unusual Case of Right Lower Quadrant Pain: A Case Report

Sarah Jabre, MD  
Mark Supino, MD

Jackson Memorial Hospital, Department of Emergency Medicine, Miami, Florida

Section Editor: Christopher Sampson, MD

Submission History: Submitted June 22, 2021; Revision received November 19, 2021; Accepted November 30, 2021

Electronically published January 28, 2022

Full text available through open access at [http://escholarship.org/uc/uciem\\_cpsem](http://escholarship.org/uc/uciem_cpsem)

DOI: 10.5811/cpcem.2021.11.53795

**Introduction:** The perforation of a cecal diverticulum is a rare and challenging condition for the emergency physician.

**Case Report:** A 47-year-old man with a past surgical history of bilateral inguinal hernia repair presented to the emergency department (ED) with acute abdominal pain of three days' duration. Pain was localized to the right lower quadrant (RLQ), with anorexia as the only associated symptom. Upon arrival to the ED, his exam demonstrated focal RLQ tenderness to palpation, rebound tenderness, and guarding. Labs did not show any elevation in inflammatory markers, liver enzymes, or lipase. Computed tomography showed no evidence of acute appendicitis, colitis, or hernia recurrence. After morphine and reassessment, the patient still had a focal peritoneal exam in the RLQ. Surgical consultation was obtained and recommended additional non-opioid analgesia as well as serial abdominal exams. After several repeat abdominal exams, there was no change in the focality of the patient's pain. Surgery was reconsulted and opted to take the patient to the operating room for exploratory laparoscopy with "appendicitis" as the presumptive diagnosis. Pathology report revealed a perforated cecal diverticulum that was adherent to the abdominal wall. The patient did well and was discharged on his third postoperative day.

**Conclusion:** This case further underlines that even in the era of sensitive imaging tools, the diagnostic value of a targeted physical exam with clinical re-evaluation can never be overestimated. [Clin Pract Cases Emerg Med. 2022;6(1):73-75.]

**Keywords:** *right lower quadrant pain; peritonitis; perforated cecal diverticulum; case report.*

---

## INTRODUCTION

The perforation of a cecal diverticulum is a rare and potentially challenging condition for the emergency physician. It is uncommonly diagnosed in the emergency department (ED) and generally undiagnosed pre-operatively. Most patients are taken to surgery for suspected appendicitis, and only on pathology is the actual etiology discovered.<sup>1</sup> We present this unusual case of abdominal pain given the absence of objective findings on workup, which could have easily led to misdiagnosis and increased patient morbidity were it not for a very convincing physical exam.

## CASE REPORT

A 47-year-old male with no past medical history and a past surgical history of bilateral inguinal hernia repairs presented to the ED with acute right lower quadrant pain of three days' duration. Pain was constant, progressive, and associated with anorexia. There was no associated nausea, vomiting, fever, chills, dysuria, or constipation. He had never experienced any similar episodes of pain in the past. Upon arrival to the ED, his temperature was 37° Celsius, heart rate 85 beats per minute, blood pressure 114/77 millimeters of mercury, and his respiratory rate was 18 breaths per minute.

On exam, his abdomen was soft and non-distended with severe, focal right-sided tenderness around McBurney’s point with associated guarding. Rovsing’s and psoas signs were negative. Coughing elicited pain in the patient, but there was no bulge suggesting recurrence of his hernia. His laboratory values and urine analysis were relatively unremarkable (Table).

A computed tomography (CT) of the abdomen with intravenous contrast showed “no evidence of acute appendicitis.” The report also stated: “no evidence of recurrence of right inguinal hernia, and numerous fluid-filled small bowel loops in the right abdomen that in the appropriate setting could reflect enteritis” (Image 1 and 2).

Upon reassessment, after one dose of four milligrams of morphine, the patient still had the same exam: focal point tenderness to an area near McBurney’s point. A decision was made to consult surgery. The surgical team recommended serial abdominal exams by the emergency physician as well as administration of ketorolac as an attempt to rule out a musculoskeletal etiology of the pain. However, after serial exams six hours later, there was no change in the findings, and peritonitis remained a concern. Surgery was reconsulted and reassessed the patient, deciding to take him for exploratory laparoscopy and appendectomy, with appendicitis as the presumptive diagnosis. In the operating room, findings were consistent with cecal diverticulitis, and the surgeon removed the affected part of the cecum. The surgeon also opted to remove the appendix. Pathology reports revealed a perforated cecal diverticulum that was adherent to the abdominal wall, and a normal appendix. The patient was discharged three days postoperatively on oral antibiotics to complete a total of four days of antibiotics. He had no complications during his stay.

**DISCUSSION**

Cecal diverticulosis represents only 1–2% of diverticular disease in North America with the prevalence much more common in Western countries.<sup>2</sup> It is estimated that 1 in 300 cases with a preoperative diagnosis of “acute appendicitis” were in fact “cecal diverticulitis.”<sup>3</sup> A review of the literature shows no definitive distinctive features between the diagnosis

*CPC-EM Capsule*

What do we already know about this clinical entity?  
*Cecal diverticulosis represents 1-2% of diverticular disease in North America. It presents as right lower quadrant pain with no clear distinctive features.*

What makes this presentation of disease reportable?  
*In this case cecal diverticulitis acted as a mimic to acute appendicitis, leading to laparoscopy that revealed a perforated cecal diverticulum.*

What is the major learning point?  
*The real diagnostic tools were the history and serial physical exams, which prompted us to not rely on a falsely reassuring workup.*

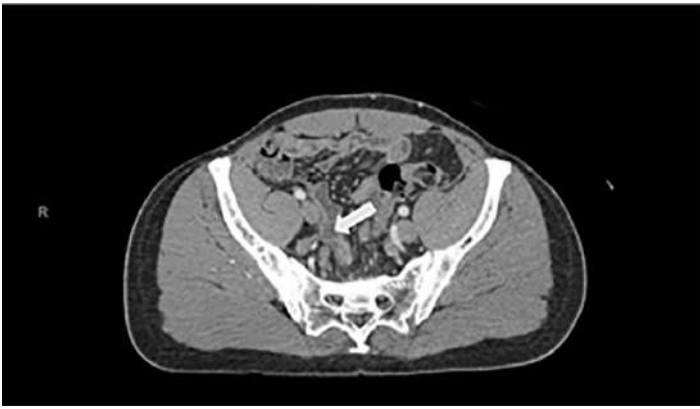How might this improve emergency medicine practice?  
*Even in the age of sensitive imaging tools, we should not entirely rely on those diagnostic means to make a final diagnosis. History and physical exam remain the major tools of a good physician.*

of the two entities. Some authors discuss a less toxic appearance or a longer duration of symptoms for people with cecal diverticulitis, but there is no clear consensus.<sup>4,5</sup> As for the management, if the diagnosis is made preoperatively through CT, conservative treatment with antibiotics is usually advised. However, if the imaging reveals evidence of complicated diverticulitis (abscess or perforation), surgery remains the modality of choice.<sup>6</sup> In rare cases, right hemicolectomy or ileocolic resection is indicated.

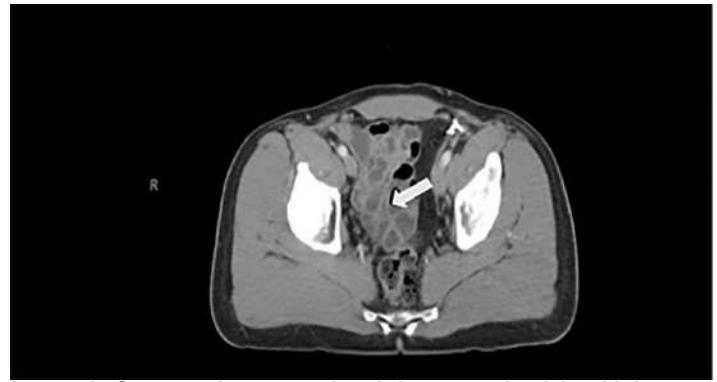
**Table.** Laboratory values obtained in the emergency department.

Test	Value	Unit	Reference Range
WBC	6.4 x103	cells/mcL	4.0-10.5 x103
Hb	12.3	g/dL	13.3-16.3
Platelets	282 x103	cells/mcL	140-400 x103
AST	31	unit/L	15-46
ALT	26	unit/L	21-72
Lactic acid	1.1	mmol/L	0.7-2.1
Creatinine	1.15	mg/dL	0.66-1.25

WBC, white blood cell count; Hb, hemoglobin; AST, aspartate transaminase; ALT, alanine transaminase; mcL, microliter; g, gram; dL, deciliter; L, liter; mmol, millimole; mg, milligram.



**Image 1.** Computed tomography abdomen and pelvis with intravenous contrast with the arrow pointing to a normal appendix.



**Image 2.** Computed tomography abdomen and pelvis with intravenous contrast with the arrow pointing to numerous fluid-filled, small bowel loops.

## CONCLUSION

In the ED evaluation and workup of abdominal pain, the emergency physician should consider a perforated cecal diverticulum in an atypical presentation of right lower quadrant pain with findings that do not completely fit the clinical picture of appendicitis. It is imperative to involve a surgeon early. Finally, CT is helpful but not 100% sensitive; the clinician should keep in mind the importance of a physical exam and of clinical reevaluation to help guide final diagnosis and treatment.

The authors attest that their institution requires neither Institutional Review Board approval nor patient consent for publication of this case report. Documentation on file.

*Address for Correspondence:* Sarah Jabre, MD, Jackson Memorial Hospital, Department of Emergency Medicine, 1611 NW 12th Ave, Miami, FL 33136. Email: sarah.jabre@jhsmiami.org.

*Conflicts of Interest:* By the CPC-EM article submission agreement, all authors are required to disclose all affiliations, funding sources and financial or management relationships that could be perceived as potential sources of bias. The authors disclosed none.

*Copyright:* © 2022 Jabre. This is an open access article distributed in accordance with the terms of the Creative Commons Attribution (CC BY 4.0) License. See: <http://creativecommons.org/licenses/by/4.0/>

## REFERENCES

1. Zuckerman J, Garfinkle R, Vasilevsky C-A, et al. Short- and long-term outcomes of right-sided diverticulitis: over 15 years of North American experience. *World J Surg.* 2020;44(6):1994-2001.
2. Radhi JM, Ramsay JA, Boutross-Tadross O. Diverticular disease of the right colon. *BMC Res Notes.* 2011;4(1):383.
3. Yildar M, Ozkan OF, Caglayan K, et al. An unusual cause of right lower quadrant pain: the caecum diverticulitis. *Case Rep Surg.* 2012;2012:789397.
4. Cristaudo A, Praga P, Sanjeev N. Caecal diverticulitis: presentation and management. *Ann. Med. Surg.* 2015;4(1):72-5.
5. Wagner D and Zollinger R. Diverticulitis of the cecum and ascending colon. *Arch Surg.* 1961;83:436-43.
6. Kumar S, Fitzmaurice GJ, O'Donnell ME, et al. Acute right iliac fossa pain: not always appendicitis or a caecal tumour: two case reports. *Cases J.* 2009;2(1):88.



# Hemiplegia Following Fluid Administration Through an Implanted Venous Access Device: A Case Report

James Waymack, MD\*

Christopher McDowell, MD, MEd, MBA\*

Nida Feller, MD\*

Sharon Kim, PhD†

\*Southern Illinois University School of Medicine, Department of Emergency Medicine, Springfield, Illinois

†Southern Illinois University School of Medicine, Center for Clinical Research, Springfield, Illinois

Section Editor: Steven Walsh, MD

Submission History: Submitted October 27, 2021; Revision received December 27, 2021; Accepted December 27, 2021

Electronically published January 28, 2022

Full text available through open access at [http://escholarship.org/uc/uciem\\_cpem](http://escholarship.org/uc/uciem_cpem)

DOI: 10.5811/cpem.2021.12.55230

**Introduction:** Many patients seen in the emergency department (ED) have central venous access placed or previously established placement. Catheters inadvertently placed in the arterial circulation may lead to complications or adverse events.

**Case Report:** We present a case of hemiplegia in a 63-year-old man following intravenous fluid administration through a malpositioned catheter that was initially unrecognized. The patient initially presented to the ED for stroke-like symptoms and was discharged following workup. On a subsequent visit for similar symptoms, intra-arterial placement of the catheter was diagnosed.

**Conclusion:** It is important for emergency physicians to be aware of this potential complication of central venous cannulation and that arterial malposition of a previously placed central line may go unrecognized with the potential to cause cerebral ischemia when cerebral blood flow is reduced by the infusion of intravenous fluids or medications. [Clin Pract Cases Emerg Med. 2022;6(1):76-79.]

**Keywords:** *hemiplegia; central venous catheter malposition; case report.*

## INTRODUCTION

Central venous lines are commonly placed in emergency department (ED) patients, and many patients seen in the ED with chronic conditions have indwelling central venous devices. We present a case of hemiplegia following intravenous (IV) fluid administration through an implanted venous device that had been inadvertently placed in the subclavian artery and unrecognized as such until malposition was identified on computed tomography angiography (CTA) of the chest following a stroke evaluation. Awareness of this potential complication and how it may present as transient neurologic symptoms is important to the emergency physician who routinely places central venous lines.

## CASE REPORT

A 63-year-old male with a history of stage IV metastatic esophageal adenocarcinoma and recent placement of an

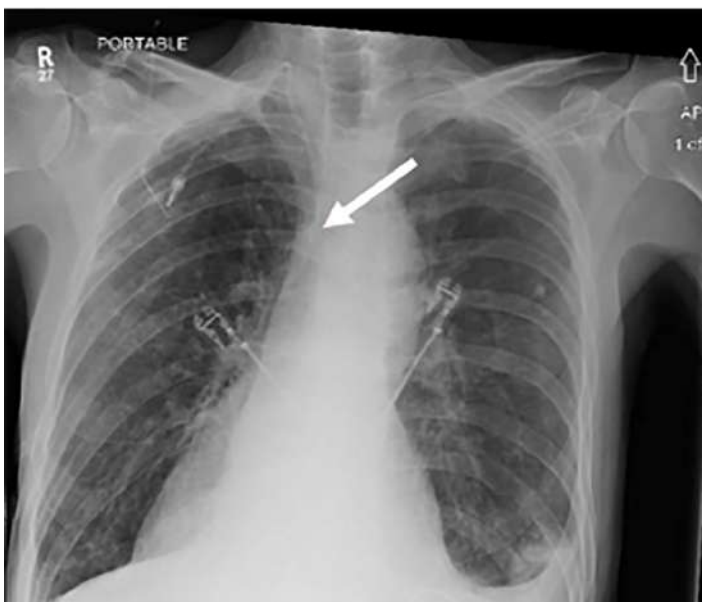implanted venous access device three weeks prior presented to the ED from the infusion clinic at the hospital with a chief complaint of left-sided arm and leg weakness. The patient had no known cerebral involvement of metastatic disease. The patient, who was receiving IV fluids for rehydration, noted left-sided weakness upon attempting to rise to use the restroom. He was emergently transported to the ED for evaluation. Upon arrival he confirmed the left-sided weakness without other motor deficit reported. He denied visual disturbance or headache. He denied numbness or tingling of the face or extremities.

The patient noted that he had been seen in the ED two weeks prior for a similar presentation of left-sided weakness with urinary incontinence and possible left leg shaking while receiving chemotherapy via the same port. During the prior evaluation a stroke team was activated with emergent neurologic consultation. Non-contrast computed tomography

(CT) of the head was negative, but the patient was unable to undergo magnetic resonance imaging (MRI) of the brain due to extreme gastric reflux as a complication from previous surgery for his esophageal cancer. No head or neck CTAs were obtained. He was observed overnight, the left-sided weakness was resolved, and he was subsequently diagnosed with Todd's paralysis. Levetiracetam was prescribed, and he had been compliant in taking the medication since the previous visit.

Upon arrival at the second visit his vital signs included a temperature of 36.5° degrees Celsius, blood pressure of 131/78 millimeters of mercury, heart rate of 82 beats per minute, respirations at 18 breaths per minute, and an oxygen saturation of 97% on room air. His blood glucose level was 96 milligrams per deciliter (mg/dL) (reference range: 70-105 mg/dL). Physical examination was significant for no movement of the left arm and no effort against gravity of the left leg, giving him a National Institutes of Health Stroke Scale score of 7. The remainder of the neurologic exam including level of consciousness, orientation, speech, visual exam, and right-sided strength and coordination were normal. A stat stroke activation was declared with neurology consultation.

A non-contrast CT of the head was obtained with no acute abnormality. Plain chest radiograph demonstrated a right-sided port with central line coursing medially, suggesting a possible arterial course (Image 1). The patient again was unable to tolerate MRI of the brain. Due to recurrence of his symptoms and the situational similarities (both episodes occurring during infusions through his port) CTA imaging of the chest, neck, and head were obtained to evaluate for vessel stenosis or catheter malposition.



**Image 1.** A chest radiograph depicting the right-sided chest port (arrow) with line coursing medially.

### *CPC-EM Capsule*

What do we already know about this clinical entity?

*Central venous access catheters or devices are commonly used in medicine. Complications from malposition of these devices may lead to adverse events.*

What makes this presentation of disease reportable?

*We present a case of an unrecognized, arterially placed central catheter that presented as transient hemiplegia following the administration of intravenous fluid through the catheter.*

What is the major learning point?

*Chest radiography may not obviously identify an arterially placed central venous catheter. Subsequent Computed tomography angiography may be helpful.*

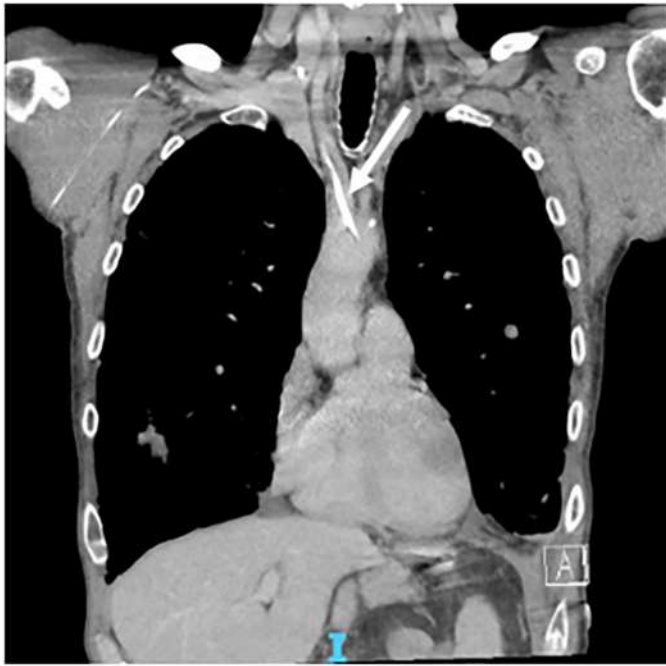
How might this improve emergency medicine practice?

*This case highlights the need to confirm appropriate catheter placement and consider implanted devices as a contributing source of a patient's presentation.*

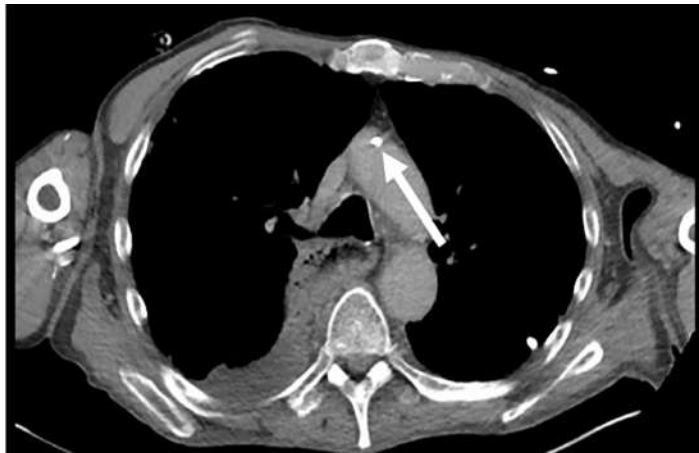The CTA revealed a right-sided chest port in place appearing to enter the right subclavian artery with the tip located in the anterior aspect of the aortic arch (Images 2 and 3). Vascular surgery was consulted to see the patient. During the patient's stay in the ED his symptoms improved within three hours to normal strength on the left side. He subsequently underwent operative removal of the malpositioned catheter from where it was found to have initially entered the internal jugular vein, went through the back wall and through a smaller possibly vertebral vein. The catheter entered arterial circulation through a vertebral artery and then traveled into the right subclavian artery. The port and catheter were removed entirely, vascular defects were repaired, and the patient recovered from the procedure well with no circulatory or neurologic deficit. He was diagnosed with transient ischemic attack due to infusion through an intra-arterial catheter and was discharged home on hospital day five.

### **DISCUSSION**

We report a case of a patient with transient cerebral ischemia presenting as hemiplegia following infusion of IV



**Image 2.** Coronal view of a computed tomography angiogram depicting the central venous line coursing through the internal carotid artery and terminating at the aortic arch (arrow).



**Image 3.** Axial view of a computed tomography angiogram depicting the central venous line tip seen in the aortic arch (arrow).

fluids through a subcutaneous venous access device that had been inadvertently placed arterially and initially unrecognized. It is suspected that intra-arterial infusion led to hemodilution and decreased cerebral oxygen delivery, resulting in the patient's presentation with neurologic deficits.<sup>1</sup> While accidental arterial puncture or cannulation is often cited and common knowledge, a review of the literature did not reveal any cases similar to ours.

Cannulation of the central veins with subsequent placement of a catheter is commonplace in medicine. More than five million centrally accessed venous lines are placed each year

with approximately 8% of hospitalized patients requiring the procedure.<sup>2,3</sup> Complication rates for central venous access are around 15% to include pneumothorax, arterial puncture or cannulation, air embolism, arrhythmia, infections, thrombosis, or medical device embolization.<sup>4</sup> Arterial injury occurs in 3-12% of central venous catheter placements.<sup>5-8</sup>

Subcutaneous ports or implanted venous access devices are often placed in the anterior chest wall with an internal jugular or subclavian catheter. These devices are chosen for patients who will need long-term central venous access. Venous access is obtained in the usual fashion with the Seldinger technique for catheter placement; however, a subcutaneous pocket is made for the port device to be implanted and attached to the catheter. This procedure is often performed by a surgeon or interventional radiologist in a non-emergent setting. Complications from port placement occur more often due to infection than arterial injury or malposition. One single-center study of 117 insertions reported infection as the primary complication and reason for premature port removal.<sup>9</sup>

The operative report for port placement stated dark pulsatile blood was encountered on initial puncture; therefore, ultrasound was used to demonstrate that the wire was seen in the internal jugular vein. A venogram was then performed showing the catheter in the right internal jugular vein with an abnormal-appearing superior vena cava. It was concluded that these findings were due to venous hypertension, and the port insertion was completed. Initial postoperative images were interpreted as the line terminating at the brachiocephalic junction. On further retrospective chart review of our case, radiography demonstrates the catheter coursing toward the midline, which could be concerning for arterial cannulation and catheter malposition.

Appropriate venous cannulation is often localized or guided by ultrasound and initially visually confirmed by return of deoxygenated-appearing blood. However, clinical judgment may only have an accuracy of 70% for malposition.<sup>10</sup> Chest radiography is commonly used to rule out pneumothorax and to confirm appropriate line placement by noting the course of the line through the approaching vasculature with termination in the superior vena cava or cavoatrial junction at the right heart border. Some studies have questioned the quality and accuracy of chest radiography, primarily focusing on its utility for identification of pneumothorax.<sup>11,12</sup> Bailey et al found in 184 central venous catheter placements a complication rate of 9%, most commonly malposition, and that clinician gestalt and fewer than three needle passes correlated with an absence of complication.<sup>11</sup> Those placing central venous lines may need to consider multiple modalities to confirm appropriate venous cannulation depending on comfort and potential complicating factors of each line placement.

We share this case as many patients have central venous access placed, and EDs encounter many patients with neurologic deficits that may be due to various underlying

causes. The root cause of this patient's ischemia was not identified on his first presentation of transient ischemia, further evidence that this constellation of procedural complications and subsequent symptomatology was not clearly evident to those involved in his care.

## CONCLUSION

This case of a patient presenting with transient neurologic symptoms due to intravenous fluid administration through an intra-arterial central venous line highlights the importance of considering uncommon causes of a patient's presentation. It is important for emergency physicians to be aware of this potential complication of central venous cannulation and that arterial malposition of a previously placed central line may go unrecognized, with the potential to cause cerebral ischemia when cerebral blood flow is reduced by the infusion of IV fluids or medications.

The authors attest that their institution requires neither Institutional Review Board approval nor patient consent for publication of this case report. Documentation on file.

---

*Address for Correspondence:* James Waymack, MD, Southern Illinois University School of Medicine, Department of Emergency Medicine, 701 North First Street, Springfield, IL 62781. Email: [jwaymack@siu.edu](mailto:jwaymack@siu.edu).

*Conflicts of Interest:* By the CPC-EM article submission agreement, all authors are required to disclose all affiliations, funding sources and financial or management relationships that could be perceived as potential sources of bias. The authors disclosed none.

*Copyright:* © 2022 Waymack. This is an open access article distributed in accordance with the terms of the Creative Commons Attribution (CC BY 4.0) License. See: <http://creativecommons.org/licenses/by/4.0/>

---

## REFERENCES

1. Tomiyama Y, Jansen K, Brian JE Jr, et al. Hemodilution, cerebral O<sub>2</sub> delivery, and cerebral blood flow: a study using hyperbaric oxygenation. *Am J Physiol*. 1999;276(4):H1190-6.
2. Ruesch S, Walder B, Tramèr MR. Complications of central venous catheters: Internal jugular versus subclavian access—a systematic review. *Crit Care Med*. 2002;30(2):454-60.
3. McGee DC and Gould MK. Preventing complications of central venous catheterization. *N Engl J Med*. 2003;348(12):1123-33.
4. Eisen LA, Narasimhan M, Berger JS, et al. Mechanical complications of central venous catheters. *J Intensive Care Med*. 2006;21(1):40-6.
5. Bowdle A. Vascular complications of central venous catheter placement: evidence-based methods for prevention and treatment. *J Cardiothorac Vasc Anesth*. 2014;28(2):358-68.
6. Gilbert MC, Elkouri S, Bracco D, et al. Arterial trauma during central venous catheter insertion: case series, review and proposed algorithm. *J Vasc Surg*. 2008;48(4):918-25.
7. Dixon O, Smith GE, Carradice D, et al. A systematic review of management of inadvertent arterial injury during central venous catheterization. *J Vasc Access*. 2017;18(2):97-102.
8. Nicholson T, Ettles D, Robinson G. Managing inadvertent arterial catheterization during central venous access procedures. *Cardiovasc Intervent Radiol*. 2004;27(1):21-5.
9. D'Souza PC, Kumar S, Kakaria A, et al. Use of port-a-cath in cancer patients: a single-center experience. *J Infect Dev Ctries*. 2014;8(11):1476-82.
10. Aboud GJ, Davis KA, Esposito TJ, et al. Comparison of routine chest radiograph versus clinician judgment to determine adequate central line placement in critically ill patients. *J Trauma*. 2007;63(1):50-6.
11. Bailey SH, Shapiro SB, Mone MC, et al. Is immediate chest radiograph necessary after central venous catheter placement in a surgical intensive care unit? *Am J Surg*. 2000;180(6):517-21.
12. Puls LE, Twedt CA, Hunter JE, et al. Confirmatory chest radiographs after central line placement: Are they warranted? *South Med J*. 2003;96(11):1138-41.



# Prompt Diagnosis of Ethylene Glycol Intoxication by an Unusual “Lactate Gap”: A Case Report

Jie Tang, MD, MSc, MPH

Alpert Medical School of Brown University, Division of Kidney Diseases and Hypertension, Providence, Rhode Island

Section Editor: Steven Walsh, MD

Submission History: Submitted September 29, 2021; Revision received December 9, 2021; Accepted December 27, 2021

Electronically published January 28, 2022

Full text available through open access at [http://escholarship.org/uc/uciem\\_cpccem](http://escholarship.org/uc/uciem_cpccem)

DOI: 10.5811/cpcem.2021.12.54928

**Introduction:** Ethylene glycol intoxication can be lethal if diagnosis is delayed. Often, prompt diagnosis may need to be based on indirect laboratory findings.

**Case report:** We present a case of severe ethylene glycol intoxication whose diagnosis was based on an unusual “lactate gap.” The patient responded well to the treatment and had a full recovery.

**Conclusion:** A “lactate gap” can be helpful in establishing a diagnosis of ethylene glycol intoxication. [Clin Pract Cases Emerg Med. 2022;6(1):80-82.]

**Keywords:** *case report; ethylene glycol intoxication; lactate.*

---

## INTRODUCTION

Ethylene glycol (EG) intoxication can lead to severe metabolic acidosis and acute kidney injury and can be lethal if diagnosis is delayed. Direct measurement of ethylene glycol is often not readily available. Prompt recognition and intervention may require recognition of indirect laboratory findings. Here, the author presents a case of EG intoxication whose diagnosis was based on an unusual “lactate gap.”

## CASE REPORT

A 61-year-old male was found unresponsive at home by police. He reportedly texted his friend stating that he was going to “hurt himself,” which prompted his friend to call the police. His past medical history was significant for human immunodeficiency virus infection with history of Kaposi sarcoma (recent viral load undetectable), autism spectrum disorder, depression, and post-traumatic stress disorder. Home medications included atorvastatin 10 milligrams (mg) daily and Genvoya (elvitegravir, cobicistat, emtricitabine, tenofovir alafenamide) 150/150/200/10 mg daily. He lived alone, smoked one-quarter pack of cigarettes a day, and had a history of heavy alcohol use in the past. Family history was noncontributory.

On presentation, he was afebrile, heart rate was 60 beats per minute, blood pressure was 134/71 millimeters of mercury (mm Hg), respiratory rate was 16 breaths per minute, and oxygen saturation was 100% on room air. However, he was unresponsive with a Glasgow Coma Scale score of three. The rest of the physical exams was unrevealing. Laboratory testing showed acute kidney injury with a high anion gap metabolic acidosis. We also observed a large discrepancy in lactate measurements between the whole blood and serum samples (Table).

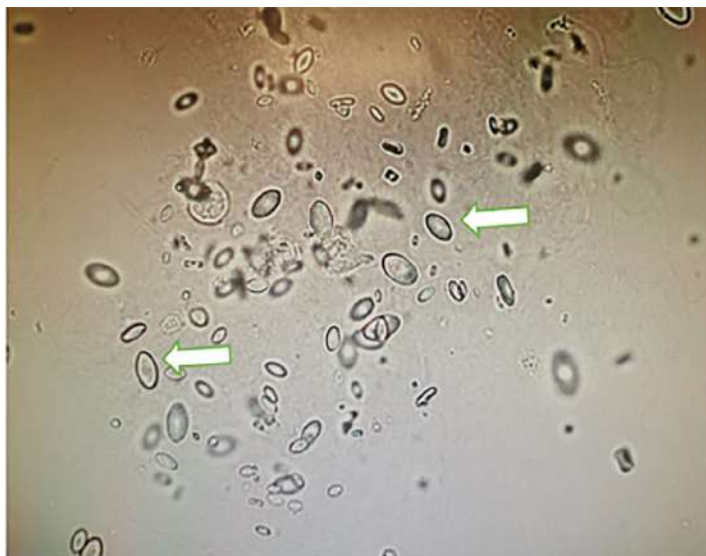His liver function test and complete blood count with differential were unremarkable. Blood salicylate and ethanol levels were not detected, and urine drug screen was negative. Electrocardiogram, head computed tomography and chest radiograph were unremarkable. He was oliguric at the time and was intubated for airway protection.

Based on his clinical presentation and the discrepancy between his whole blood and serum lactate measurements, an EG ingestion was suspected. Urine sediment showed calcium oxalate monohydrate crystals (Image). Serum osmolality was measured subsequently and showed an osmolar gap of 56. Fomepizole was started with an initial loading dose of 15 mg/

**Table.** Laboratory values in patient who presented with altered mental status.

Measurement (units)	Reference value	2 months prior	On admission
Blood urea nitrogen (mg/dL)	7-20		20
Serum creatinine (mg/dl)	0.6-1.2	1.1	1.7
Serum bicarbonate (mEq/L)	22-32		12
Anion gap	3-13		25
Serum lactate (mEq/L)	0.2-1.9		0.5
Venous blood gas pH	7.32-7.42		7.10
Venous blood gas partial pressure of carbon dioxide (pCO <sub>2</sub> ) (mm Hg)	42-50		41
Whole blood lactate (mEq/L)	0.2-1.9		17

mg/dL, milligrams per deciliter; mEq/L, milliequivalents per liter; pCO<sub>2</sub>, partial pressure of carbon dioxide; mm Hg, millimeters of mercury.



**Image.** Urine sediment examination showed characteristic calcium oxalate monohydrate crystals (white arrows).

kilogram (kg) followed by an urgent four-hour hemodialysis (HD) session 3.5 hours later. Subsequent fomepizole dosing frequency at the standard 10 milligrams (mg) per kg (mg/kg) dose were adjusted according to his dialysis schedule. His blood EG level after the initial HD session was 127 mg per deciliter (mg/dL).

Considering the clearance of EG via standard HD is about 150 milliliters per minute,<sup>1</sup> a three-hour session in a 100-kg person will clear 45% of EG. Thus, an extra three-hour HD session brought the patient's EG level down to 71 mg/dL as predicted. He received another four-hour HD session the next day, and his EG level went down to 31 mg/dL. His whole blood lactate level was also normalized soon after. He

### CPC-EM Capsule

What do we already know about this clinical entity?

*In cases of ethylene glycol (EG) intoxication, direct measurement of ethylene glycol may not be available. Recognition may have to rely on indirect lab findings.*

What makes this presentation of disease reportable?

*Timely diagnosis of EG intoxication was made based on a “lactate gap,” which can be quickly obtained using a point-of-care analyzer.*

What is the major learning point?

*Ethylene glycol intoxication can lead to a “lactate gap,” which is the difference in lactate measured using two different analyzers.*

How might this improve emergency medicine practice?

*The “lactate gap” can be a surrogate marker for the ethylene glycol metabolite, leading to early diagnosis and initiation of effective treatment.*

subsequently recovered his kidney function, was extubated, and discharged to the in-patient psychiatric service.

## DISCUSSION

Ethylene glycol is metabolized via alcohol dehydrogenase, aldehyde dehydrogenase, and lactate dehydrogenase (LDH). While oxalate is the metabolite primarily responsible for end-organ damage including kidney injury, glycolic acid is mostly responsible for anion gap acidosis. Clinical manifestations include altered mental status (due to the parent compound), and organ damage (from oxalate deposition). The presenting signs and symptoms are often non-specific, with signs of initial central nervous system depression occurring within 12 hours after ingestion. Cardiopulmonary manifestations develop approximately 24 hours after the ingestion and are characterized by hyperventilation, tachycardia, and hypertension. Ethylene glycol poisoning requires rapid recognition and early treatment in a time-dependent fashion as it can lead to permanent organ damage and high mortality.<sup>2,3</sup> However, its diagnosis is challenging due to lack of ingestion history and a lack of readily available assays for the toxic alcohols.

Despite these diagnostic obstacles, certain laboratory clues can help clinicians identify the causative toxic agent. The presence of metabolic acidosis with high anion gap and osmolar gap should raise suspicion for toxic alcohol ingestions. The presence of calcium oxalate crystal in urine sediment is an important clue for EG intoxication. The “lactate gap” is the difference in values obtained from two different analyzer methods to detect a falsely elevated lactate level. The radiometry method for lactate is commonly used in point-of-care testing reported in the blood gas. It uses the enzyme L-lactate oxidase to accelerate the oxygenation of L-lactate producing hydrogen peroxide and pyruvate. The L-lactate concentration is then computed from the measured hydrogen peroxide concentration. Glycolic acid, a metabolite of EG, cross-reacts with L-lactate oxidase and produces a significant amount of hydrogen peroxide leading to a falsely elevated lactate level. Serum lactate levels, however, are typically computed using a non-radiometry method. Analyzers, such as the iSTAT, Bayer, or Beckman and Vitros, measure LDH (instead of lactate oxidase) activity, which is not affected by glycolic acid. In our case, the “lactate gap” served as a surrogate marker for the EG metabolite that prompted the clinician to an early diagnosis and initiation of effective treatment.

## CONCLUSION

Timely diagnosis of toxic alcohol ingestion is essential to improve clinical outcome. However, the detection of parent alcohol or its metabolites in blood is labor intensive and time consuming. In suspected cases of ethylene glycol ingestion,

“Lactate gap” can be a quick and helpful laboratory clue for ethylene glycol intoxication.

The author attests that their institution requires neither Institutional Review Board approval nor patient consent for publication of this case report. Documentation on file.

---

*Address for Correspondence:* Jie Tang, MD, MSc, MPH, Alpert Medical School of Brown University, Division of Kidney Diseases and Hypertension, APC 920, Rhode Island Hospital, Providence, RI 02906. Email: jie\_tang@brown.edu.

*Conflicts of Interest:* By the *CPC-EM* article submission agreement, all authors are required to disclose all affiliations, funding sources and financial or management relationships that could be perceived as potential sources of bias. The authors disclosed none.

*Copyright:* © 2022 Tang. This is an open access article distributed in accordance with the terms of the Creative Commons Attribution ([CC BY 4.0](http://creativecommons.org/licenses/by/4.0/)) License. See: <http://creativecommons.org/licenses/by/4.0/>

---

## REFERENCES

1. Cheng JT, Beysolow DT, Kaul B, et al., Clearance of ethylene glycol by kidneys and hemodialysis. *J Toxicol Clin Toxicol*, 1987;25(1-2):95-108.
2. Latus J, Kimmel M, Alscher MD, et al., Ethylene glycol poisoning: a rare but life-threatening cause of metabolic acidosis: a single-centre experience. *Clin Kidney J*. 2012;5(2):120-3.
3. Kraut JA and Kurtz I. Toxic alcohol ingestions: clinical features, diagnosis, and management. *Clin J Am Soc Nephrol*, 2008;3(1):208-25.

# Buprenorphine for High-dose Tramadol Dependence: A Case Report of Successful Outpatient Treatment

Leslie Mukau, MD<sup>\*,†</sup>

Kadia Wormley, MD<sup>‡</sup>

Christian Tomaszewski, MD, MS, MBA<sup>\*,†</sup>

Bushra Ahmad, MD<sup>§</sup>

Rais Vohra, MD<sup>¶</sup>

Andrew A. Herring, MD<sup>‡,||</sup>

<sup>\*</sup>University of California, San Diego, Department of Emergency Medicine, San Diego, California

<sup>†</sup>El Centro Regional Medical Center, Department of Emergency Medicine, El Centro, California

<sup>‡</sup>Highland Hospital – Alameda Health System, Department of Emergency Medicine, Oakland, California

<sup>§</sup>Imperial County Behavioral Health Services, Division of Substance Use Disorder Treatment Program, El Centro, California

<sup>¶</sup>University of California, San Francisco-Fresno, Department of Emergency Medicine, Fresno, California

<sup>||</sup>University of California, San Francisco, Department of Emergency Medicine, San Francisco, California

Section Editor: R. Wilkerson, MD

Submission History: Submitted September 1, 2021; Revision received December 2, 2021; Accepted December 27, 2021

Electronically published January 28, 2022

Full text available through open access at [http://escholarship.org/uc/uciem\\_cpccem](http://escholarship.org/uc/uciem_cpccem)

DOI: 10.5811/cpccem.2021.12.54602

**Introduction:** During the coronavirus disease 2019 pandemic caused by the severe acute respiratory syndrome coronavirus 2, deaths from opiate drug overdoses reached their highest recorded annual levels in 2020. Medication-assisted treatment for opiate use disorder has demonstrated efficacy in reducing opiate overdoses and all-cause mortality and improving multiple other patient-centered outcomes. Treatment of tramadol dependence in particular poses unique challenges due to its combined action as opioid agonist and serotonin-norepinephrine reuptake inhibitor. Tramadol puts patients with dependence at risk for atypical withdrawal syndromes when attempting to reduce use. Little evidence is available to guide treatment of tramadol dependence.

**Case Report:** We present a case of high-dose tramadol addiction that began with misuse of medically prescribed tramadol for treatment of musculoskeletal back pain. The patient's use reached oral consumption of 5000-6000 milligrams of illicit tramadol daily. She complained of common complications of tramadol use disorder including memory impairment, excessive sedation, and tramadol-induced seizures. The patient was referred to the emergency department in a withdrawal crisis seeking treatment where she was successfully managed with buprenorphine and phenobarbital and then linked to ongoing outpatient treatment.

**Conclusion:** Our report adds to the limited guidance currently available on the acute management of tramadol withdrawal and treatment of tramadol use disorder. Our case suggests the initiation of high-dose buprenorphine may be an effective and feasible option for emergency clinicians.

[Clin Pract Cases Emerg Med. 2022;6(1):83-86.]

**Keywords:** *case report; tramadol addiction; serotonin-norepinephrine reuptake inhibitor (SNRI) withdrawal symptoms; buprenorphine induction.*



## INTRODUCTION

In the midst of the coronavirus disease 2019 pandemic caused by the severe acute respiratory syndrome coronavirus 2, drug overdose deaths rose nearly 30% to a record 93,000 in 2020, representing the most drug overdose deaths in a year, the most deaths from opioid overdoses, and the most overdose deaths from synthetic opioids.<sup>1</sup> Treatment of opioid use disorder with buprenorphine or methadone has been shown to decrease opioid overdose, reduce all-cause mortality, improve quality of life, decrease human immunodeficiency virus/hepatitis C transmission, and reduce drug cravings and criminality.<sup>2</sup>

Tramadol is a centrally acting opioid agonist and serotonin/norepinephrine reuptake inhibitor (SNRI) used for the management of moderate to severe pain in adults. Tramadol differs from other traditional opioid medications in that it doesn't just act as a  $\mu$ -opioid agonist, but also affects monoamines by modulating the effects of neurotransmitters involved in the modulation of pain such as serotonin and norepinephrine, which activate descending pain inhibitory pathways.<sup>3</sup> Unlike other opioid medications, tramadol use, especially at sustained high doses also carries a risk of seizure and serotonin syndrome, especially if used with other serotonergic medications.<sup>4</sup> Unfortunately, there is little in the literature to guide emergency treatment of tramadol addiction.

Although attempts to treat tramadol withdrawal with buprenorphine have been published, this is the first case of high-dose tramadol addiction and dependence successfully managed with buprenorphine in an emergency department (ED) setting. Given the increased interest and use of ED-initiated buprenorphine we believe cases like this one could be a useful guide for other clinicians confronted by similar cases.

## CASE REPORT

A 29-year-old Latina female with a past medical history of post-traumatic stress disorder (PTSD), depression, and anxiety self-referred to a behavioral health center seeking treatment for severe tramadol use disorder. She had a remote history of marijuana use, without other recreational drug or alcohol use. She had no history of any other opioid use, apart from tramadol. At age 24 she first began taking tramadol 50 milligrams (mg) daily as prescribed by her primary care physician for treatment of back pain but continued use after this pain had resolved. She began crossing the border into Mexico to purchase tramadol in increasing quantities and slowly increased her dose to approximately 5000-6000 mg daily, costing her \$200 US dollars monthly.

Complications of her tramadol use included memory impairment, excessive sedation, and tramadol-induced seizures, occurring about every two weeks. Prior to presentation for care, she had independently tried numerous times to quit by tapering but was limited by intolerable withdrawal symptoms, never dropping usage below 4000 mg daily. At time of presentation, she had not yet participated in any formal detoxification program. Withdrawal symptoms began two hours

*CPC-EM Capsule*

What do we already know about this clinical entity?  
*Opioid use disorder (OUD) is an intensifying national epidemic due to many factors including overuse of prescription pain medication and relative lack of resources for those seeking OUD recovery.*

What makes this presentation of disease reportable?  
*Tramadol is widely prescribed and can cause toxicity due to both opioid and serotonin effects. Opioid withdrawal symptoms from tramadol may be managed with buprenorphine.*

What is the major learning point?  
*Rapid identification of tramadol use disorder and tramadol withdrawal with urgent induction of buprenorphine can help patients avoid the complications related to tramadol addiction.*

How might this improve emergency medicine practice?  
*Clinicians can help prevent overdose, complications, and deaths from tramadol overuse by identifying OUD in emergency department patients and offering medication assisted treatment with buprenorphine.*

after her last use and included anxiety, restlessness, diaphoresis, and arthralgias. During this time, she was concomitantly experiencing hopelessness and passive suicidality in the setting of untreated depression, anxiety, and PTSD from childhood sexual, physical, and emotional abuse. Her family history was notable for active substance dependence in multiple members, including a sister who had recently died from a heroin overdose four months prior to presentation. Her mother had a history of methamphetamine abuse, and her brother was actively abusing multiple illicit drugs including fentanyl.

Given tramadol's combined action as a  $\mu$ -receptor agonist and SNRI, the patient was at risk for an atypical opioid withdrawal syndrome. For this reason, inpatient detoxification with tramadol tapering and buprenorphine induction was preferred. Ultimately, given limitations of local resources and in consultation with addiction specialists, a plan was made to coordinate outpatient buprenorphine induction from the ED. Seven days following initial presentation to the behavioral health facility the patient was asked to go to the ED but did not and decided to taper the tramadol dose herself. She went down to 4000 mg of tramadol per day but started having withdrawal

symptoms and went back up to 5000-6000 mg a day. Three days later she finally showed up for her first ED visit.

At her first outpatient induction attempt, she presented to the ED and was given sublingual buprenorphine 8 mg with phenobarbital 200 mg added to prevent withdrawal seizures. She was discharged home on buprenorphine/naloxone 8/2 mg twice a day with instructions to return the next day for follow-up. On the night of discharge, she noted significant withdrawal symptoms, reported difficulty with sleep and anxiety, and ultimately resumed tramadol use. The patient never filled her prescriptions. She received additional counseling regarding her available treatment options: slowly tapering use vs medication-assisted treatment.

On one of her trips from Mexico the patient was apprehended for illegal drug possession, and all her tramadol pills were confiscated. She returned to the ED eight days later after her initial visit. Before coming to the ED, the patient had taken buprenorphine/naloxone (8/2) mg. After examination she was given an additional 8 mg buprenorphine. About an hour later she was feeling slightly better but still having some residual withdrawal symptoms. She was given another 8 mg of buprenorphine. She felt much better and was discharged after spending slightly less than four hours in the ED.

She was discharged with a prescription for buprenorphine/naloxone 16/4 mg twice a day. Venlafaxine, a SNRI, was concomitantly prescribed to forestall possible SNRI withdrawal symptoms. Ten days post induction, she was still taking prescribed buprenorphine/naloxone at the same dose and was not having withdrawal symptoms, drug cravings or using tramadol. She had not yet started taking venlafaxine. Almost a year out after induction, she reported stable abstinence from tramadol with buprenorphine/naloxone 16/4 mg twice a day. She had also started treatment for depression and anxiety with buspirone 10 mg and sertraline 150 mg once daily.

## DISCUSSION

We present a complicated case of high-dose tramadol addiction and dependence successfully treated with high-dose buprenorphine induction and high-dose buprenorphine maintenance initiated in the ED setting. Previous case studies have shown some success with transitioning tramadol-dependent patients to buprenorphine. Using a residential inpatient treatment facility, a patient with a dependence of 1400 mg of tramadol a day was transitioned successfully over 28 days to stable treatment with buprenorphine 8 mg/naloxone 2 mg orally daily.<sup>5</sup> The biggest hindrance was complications with antidepressant discontinuation syndrome, which was due to tramadol's serotonergic activity.<sup>6</sup> Hence, we offered the patient a prescription for venlafaxine, which she did not fill, in addition to the buprenorphine.

After hydrocodone and oxycodone, tramadol is the third highest used and misused opioid per data from the Drug Abuse Warning Network, a nationwide public health surveillance system that improves ED monitoring of substance use crises,

including those related to opioids, with over a million cases of misuse reported annually.<sup>7</sup> Tramadol abuse accounts for over 20,000 ED visits annually.<sup>8</sup> The effect of rescheduling hydrocodone from schedule III to II in 2012 has been associated with an increase in tramadol prescribing based on data available in four states.<sup>9</sup> In addition to opioid dependence and adverse effects, such as seizures and serotonergic syndrome associated with tramadol, its use naively for post-surgical pain is associated with an increased risk of prolonged opioid use when compared to other short-acting opioids.<sup>10</sup> Its use has also been associated with increased all-cause mortality compared to non-opioid pain medications, suggesting it is no safer than traditional opioids.<sup>11</sup> Therefore, in addition to preventing opioid dependence, it behooves clinicians to wean patients off tramadol, especially when they are using excessively high levels, since toxicity of this drug is high.

In the case of our patient there were concerns for unpleasant SNRI discontinuation syndrome and withdrawal seizures due to tramadol dose tapering, but we managed without inpatient admission. Since tramadol is also an SNRI we were uncertain whether we should be concerned about SNRI withdrawal syndrome and whether the patient should also have been concomitantly started on an antidepressant in addition to buprenorphine. We prescribed an antidepressant, venlafaxine, but she did not take it. The patient reported that initial attempts with lower doses of buprenorphine did not adequately treat withdrawal symptoms and craving. High-dose buprenorphine appears to have been successful for this patient.

Physical dependence on tramadol can occur at doses as low as 200 mg/day.<sup>12</sup> In addition to the usual opioid withdrawal symptoms tramadol may have atypical opioid withdrawal syndrome symptoms that may include unusual extremity sensory experiences including numbness and prickling, hallucinations, confusion, intense paranoia, high anxiety and panic attacks, and disorientation and depersonalization.<sup>13</sup> Although these atypical symptoms may not be generally life-threatening, they may be uncomfortable or put the individual in dangerous situations or at high risk of making bad decisions.

Literature is sparse regarding how to treat such individuals short of an inpatient, medically supervised detox center. Herring et al have recently shown that high-dose buprenorphine (high-dose induction dose defined as greater than 12 mg) is both efficacious and safe in treating patients with opioid use disorder in the ED.<sup>14</sup> Extended-release (ER) tramadol has been shown to be as effective as buprenorphine for treating opioid withdrawal in two randomized controlled trials. Doses up to 600 mg/day of tramadol ER were used successfully in one randomized controlled trial, but the drug was quickly tapered over one week during their residential treatment.<sup>15</sup> Another study showed that buprenorphine results in lower withdrawal symptoms within two to three days of detoxification vs tramadol.<sup>16</sup> The downside in that trial was that three patients (10%) sustained seizures, limiting

tramadol's use for severe opioid dependence long term. Therefore, substituting high-dose buprenorphine for opioids, including tramadol, may be more efficacious for induction and sustainability in patients with high-dose opioid dependence, particularly those who are trying to end tramadol dependence.

## CONCLUSION

Little has been written about specific treatment for patients with tramadol use disorder. This case illustrates that buprenorphine induction and maintenance without concomitant use of an SNRI agent may be all that is needed in high-dose tramadol detoxification and or treatment of withdrawal symptoms in an outpatient setting.

The authors attest that their institution requires neither Institutional Review Board approval nor patient consent for publication of this case report. Documentation on file.

*Address for Correspondence:* Leslie Mukau, MD, UC San Diego, Department of Emergency Medicine, 200 W. Arbor Dr. #8676, San Diego, CA 92103. Email: [lmukau@health.ucsd.edu](mailto:lmukau@health.ucsd.edu).

*Conflicts of Interest:* By the CPC-EM article submission agreement, all authors are required to disclose all affiliations, funding sources and financial or management relationships that could be perceived as potential sources of bias. Drs. Mukau and Vohra are active and current members of the California chapter of the American College of Emergency Physicians (ACEP), and Dr. Mukau is a former board member of California ACEP. Dr. Mukau used funds from the California Bridge grant for processing fees to publish this report. Drs. Mukau, Herring, and Vohra each have grants from the California Public Health Institute Bridge program and the Department of Health Care Services Behavioral Health Pilot Project, which combine Medication for Addiction Treatment in hospital EDs with support from a substance use counselor to help people enter ongoing substance use treatment. Drs. Tomaszewski, Herring, Vohra, and Mukau are individually supported by the Sierra Health Foundation Stimulant Use Prevention and Treatment in Communities of Color Awards. None of the above grant funders had a role in the design, preparation, review, or approval of the manuscript, or in our decision to submit it for publication.

*Copyright:* © 2022 Mukau. This is an open access article distributed in accordance with the terms of the Creative Commons Attribution (CC BY 4.0) License. See: <http://creativecommons.org/licenses/by/4.0/>

## REFERENCES

- Ahmad FB, Rossen LM, Sutton P. Provisional drug overdose death counts. National Center for Health Statistics. 2021. Available at <https://www.cdc.gov/nchs/nvss/vsrr/drug-overdose-data.htm>. Accessed July 24, 2021.
- Hawk K, Hoppe J, Ketcham E, et al. Consensus recommendations on the treatment of opioid use disorder in the emergency department. *Ann Emerg Med*. 2021;78(3):434-42.
- Drugbank. Tramadol Pharmacodynamics. 2005. Available at <https://go.drugbank.com/drugs/DB00193#reference-A182279>. Accessed July 24, 2021.
- Hassamal S, Miotto K, Dale W et al. Tramadol: understanding the risk of serotonin syndrome and seizures. *Am J Med*. 2018;131(11):1382.e1-1382.e6.
- Cupples N and Moore TA. A case of tramadol dependence and successful treatment with buprenorphine/naloxone." *Mental Health Clinician*. 2013;(3):283-5.
- Ritvo JI, Koonce R, Thurstone C, et al. Letters to the Editor: tramadol dependence: treatment with buprenorphine/naloxone. *Am J Addict*. 2007;16(1):67-8.
- Substance Abuse and Mental Health Services Administration. 2019 National Survey on Drug Use and Health. 2020. Available at: <https://www.samhsa.gov/data/report/2019-nsduh-detailed-tables>. Accessed August 16, 2021.
- Vosburg SK, Severtson SG, Dart RC, et al. Assessment of tapentadol API abuse liability with the Researched Abuse, Diversion and Addiction-Related Surveillance (RADARS) System. *J Pain*. 2018;19(4):439-53.
- Harrison M and Walsh TL. The effect of a more strict 2014 DEA schedule designation for hydrocodone products on opioid prescription rates in the United States. *Clin Toxicol (Phila)*. 2019;57(11):1064-72.
- Thiels CA, Habermann EB, Hooten WM, et al. Chronic use of tramadol after acute pain episode: cohort study. *BMJ*. 2019;365:11849.
- Zeng C, Dubreuil M, LaRochelle MR, et al. Association of tramadol with all-cause mortality among patients with osteoarthritis. *JAMA*. 2019;321(10):969-82
- Lanier RK, Lofwall MR, Mintzer MZ, et al. Physical dependence potential of daily tramadol dosing in humans. *Psychopharmacology (Berl)*. 2010;211(4):457-66.
- Senay EC, Adams EH, Geller A, et al. Physical dependence on Ultram (tramadol hydrochloride): both opioid-like and atypical withdrawal symptoms occur. *Drug Alcohol Depend*. 2003;69(3):233-41.
- Herring AA, Vosooghi AA, Luftig J, et al. High-dose buprenorphine induction in the emergency department for treatment of opioid use disorder. *JAMA Netw Open*. 2021;4(7):e2117128.
- Dunn KE, Tompkins DA, Bigelow GE, et al. Efficacy of tramadol extended-release for opioid withdrawal: a randomized clinical trial. *JAMA Psychiatry*. 2017;74(9):885-93.
- Chawla JM, Pal H, Lal R, et al. Comparison of efficacy between buprenorphine and tramadol in the detoxification of opioid (heroin)-dependent subjects. *J Opioid Manag*. 2013; 9(1): 35-41.

# Case Report of Torsion of Cryptorchid Testis Causing Abdominal Pain

Hannah Newhouse, PA-C, MSPAS\*  
Joseph Minardi, MD\*  
Frederic Rawlins, DO†

\*West Virginia University Camden Clark Medical Center, Department of  
Emergency Medicine, Parkersburg, West Virginia

†Virginia College of Osteopathic Medicine, Department of Emergency Medicine,  
Blacksburg, Virginia

Section Editor: Anna McFarlin, MD

Submission History: Submitted September 23, 2021; Revision received December 9, 2021; Accepted December 30, 2021

Electronically published January 28, 2022

Full text available through open access at [http://escholarship.org/uc/uciem\\_cpem](http://escholarship.org/uc/uciem_cpem)

DOI: 10.5811/cpcem.2021.12.54845

**Introduction:** A myriad of pathologies can cause abdominal pain. Genitourinary causes including testicular torsion must be considered.

**Case Report:** In this report, we present a 17-year-old male evaluated in the emergency department for lower abdominal pain. After physical exam, computed tomography, and ultrasound were completed, torsion of undescended testicle within the inguinal canal was diagnosed. Surgical exploration revealed a twisted, ischemic testis, and subsequent orchiectomy was performed.

**Conclusion:** This case highlights the importance of a thorough genitourinary exam in patients with lower abdominal pain. [Clin Pract Cases Emerg Med. 2022;6(1):87-89.]

**Keywords:** Cryptorchid; undescended; testicle; torsion; case report.

## INTRODUCTION

Representing approximately 8% of all visits, abdominal pain is the most common complaint encountered in the emergency department (ED).<sup>1</sup> While the etiology may vary, genitourinary sources of pain must be considered including testicular torsion. Although testicular torsion frequently presents as acute scrotal pain, torsion of an undescended testicle may present as non-specific lower abdominal or groin pain. We present a case of torsion of a cryptorchid testis in an adolescent male.

## CASE REPORT

A healthy 17-year-old male presented to the ED with left lower-quadrant abdominal pain. The patient experienced onset of severe pain upon awakening two days earlier with associated nausea and vomiting. The pain had persisted although vomiting had since resolved. He had a history of constipation but recently had normal bowel movements. He denied hematuria, dysuria, fever, or any other symptoms. Vital signs were normal. On physical exam, he had a firm, non-reducible mass in the left inguinal region with tenderness and guarding to the left lower quadrant. Testicular exam was not performed initially.

Laboratory studies including urinalysis were unremarkable. Computed tomography of the abdomen and pelvis was obtained, which revealed an undescended testicle in the left inguinal canal with adjacent edema, as seen in Images 1 and 2.

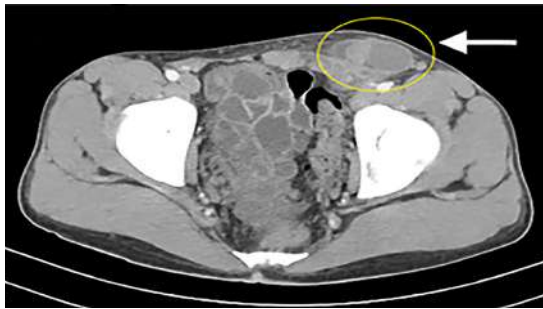The patient was reassessed, and testicular exam was performed revealing a normal right testis and empty left hemiscrotum. At this point, the patient and his mother confirmed history of undescended left testicle. Testicular Doppler ultrasound revealed a hypoechoic testicle with absence of blood in the left inguinal canal, as seen in Image 3.

Urology was consulted and promptly took the patient to the operating room. The left undescended testis was found to be nonviable with 720 degrees of torsion of the spermatic cord. A left orchiectomy and prophylactic right orchiopexy were performed.

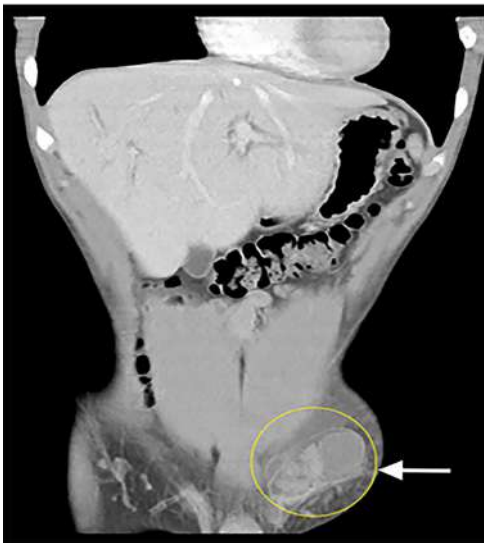## DISCUSSION

Testicular torsion is a urologic emergency with annual incidence less than 0.004% for males  $\leq 18$ .<sup>2</sup> Torsion must be promptly identified and rapidly treated due to risk of ischemia and infertility. Ideally, surgical management should

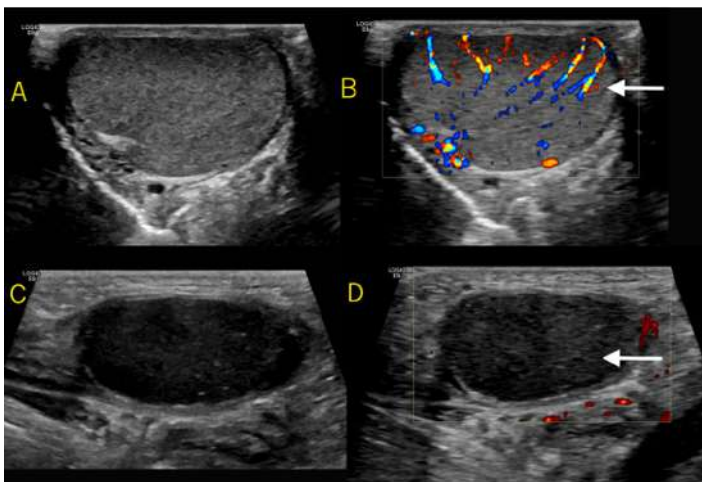




**Image 1.** Axial computed tomography at the lower margin of the pelvis with the cryptorchid testicle shown in the left inguinal canal (circle).



**Image 2.** Coronal reconstruction computed tomography demonstrating the cryptorchid testicle in the left inguinal canal (circle).



**Image 3.** Frame A shows the normal right testicle with the diffuse internal color Doppler signal present seen in Frame B (see arrow). Frame C shows a hypoechoic testicle in the left inguinal canal with absent internal power Doppler signal demonstrated in Frame D (see arrow).

### *CPC-EM Capsule*

What do we already know about this clinical entity?

*Testicular torsion is a relatively uncommon phenomenon that typically presents with scrotal pain. Torsion must be promptly identified and surgically managed within six hours.*

What makes this presentation of disease reportable?

*Torsion of a cryptorchid testis is exceedingly rare and presents differently than torsion of descended testis, often with lower abdominal pain.*

What is the major learning point?

*A high index of suspicion is necessary to make this diagnosis, as the etiology of undifferentiated lower abdominal pain is vast.*

How might this improve emergency medicine practice?

*A thorough genitourinary exam in patients presenting with lower abdominal pain will aid in diagnosis and improve patient care.*

be completed within six hours as testicular salvage rates are reportedly 90% or greater within this window.<sup>3,4</sup> Beyond six hours, salvage rates progressively decline and are virtually zero by 48 hours.<sup>5</sup>

Cryptorchidism, or undescended testis, affects 2-4% of full-term males with higher incidence seen in preterm infants.<sup>6</sup> Orchiopexy is ideally performed within the first year of life due to increased risk of infertility and malignancy.<sup>6,7</sup> Interestingly, the first described case of testicular torsion was in 1840 by Delasiauve in a 15-year-old male with cryptorchid testis.<sup>8</sup> Overall, torsion of an undescended testis is rare, most commonly occurring in pediatric patients, particularly during the perinatal period.<sup>7</sup> The exact risk of torsion with cryptorchid testis is still unknown, although some articles suggest it may be up to 10 times more likely than torsion of a descended testis.<sup>8,9</sup>

The clinical presentation of undescended testicular torsion includes lower abdominal pain, vomiting, and decreased oral intake. Physical examination typically reveals inguinal swelling with a firm, tender mass and empty ipsilateral hemiscrotum.<sup>7,8</sup> Doppler ultrasonography, computed

tomography, and technetium Tc-99m scrotal scintigraphy can aid in diagnosis.<sup>7</sup> Torsion of cryptorchid testicle is more commonly left sided.<sup>9</sup> According to case review, average time from symptom onset to hospital evaluation was 48 hours.<sup>7</sup> Subsequently, rates of salvage are substantially lower at 10% in cryptorchid torsion.<sup>9</sup>

## CONCLUSION

Torsion of a cryptorchid testicle is an uncommon phenomenon that clinicians should be aware of and must include in their differential for abdominal pain. Torsion is one of the few urologic emergencies. A high index of suspicion is required to make this diagnosis as it may imitate other acute abdominal emergencies including incarcerated inguinal hernia. Lower abdominal pain should always prompt consideration of genitourinary pathology. A thorough physical examination of the genitourinary tract should decrease diagnostic error and improve patient care in such cases.

The authors attest that their institution requires neither Institutional Review Board approval nor patient consent for publication of this case report. Documentation on file.

*Address for Correspondence:* Hannah Newhouse, PA-C, West Virginia University Camden Clark Medical Center, Department of Emergency Medicine, 800 Garfield Ave., Parkersburg, WV 26101. Email: hannah.newhouse@wvumedicine.org.

*Conflicts of Interest:* By the *CPC-EM* article submission agreement, all authors are required to disclose all affiliations, funding sources and financial or management relationships that could be perceived as potential sources of bias. The authors disclosed none.

*Copyright:* © 2022 Newhouse. This is an open access article distributed in accordance with the terms of the Creative Commons Attribution ([CC BY 4.0](https://creativecommons.org/licenses/by/4.0/)) License. See: <http://creativecommons.org/licenses/by/4.0/>

## REFERENCES

1. Rui P and Kang K. National Hospital Ambulatory Medical Care Survey: 2015 Emergency Department Summary Tables. 2015. Available at: [http://www.cdc.gov/nchs/data/ahcd/nhamcs\\_emergency/2015\\_ed\\_web\\_tables.pdf](http://www.cdc.gov/nchs/data/ahcd/nhamcs_emergency/2015_ed_web_tables.pdf). Accessed February 3, 2021.
2. Zhao LC, Lautz TB, Meeks JJ, et al. Pediatric testicular torsion epidemiology using a national database: incidence, risk of orchiectomy and possible measures toward improving the quality of care. *J Urol*. 2011;186(5):2009-13.
3. Sharp V, Kieran K, Arlen A. A Testicular torsion: diagnosis, evaluation, and management. *Am Fam Physician*. 2013;88(12):835-40.
4. Mäkelä E, Lahdes-Vasama T, Rajakorpi H, et al. A 19-year review of paediatric patients with acute scrotum. *Scand J Surg*. 2007;96(1):62-6.
5. Cline D, Ma OJ, Meckler GD, et al. (2015). Pediatric urologic and gynecologic disorders. In: JE Tintinalli & JS Stapczynski (Eds.), *Tintinalli's Emergency Medicine: A Comprehensive Study Guide (595-596,874)*. New York City:McGraw-Hill Education.
6. Hutson J, Balic A, Nation T, et al. Cryptorchidism. *Semin Pediatr Surg*. 2010;19(3):215-24.
7. Geng J-H and Huang C-N. Torsion of undescended testis: clinical, imaging, and surgical findings. *Urol Sci*. 2014;25(1):31-4.
8. Naouar S, Braiek S, El Kamel R. Testicular torsion in undescended testis: a persistent challenge. *Asian J Urol*. 2017;4(2): 111-5.
9. Zilberman D, Inbar Y, Heyman Z, et al. Torsion of the cryptorchid testis—can it be salvaged? *J Urol*. 2006;175(6):2287-9.

# Nausea and Dyspnea on Exertion: Left Ventricular Free-wall Rupture

**Juliana Wilson, DO, MPH<sup>††</sup>**  
**Matthew Mendes, MD<sup>\*</sup>**  
**Marian E. Betz, MD, MPH<sup>\*</sup>**  
**Juan Galindez Mingo, BS<sup>‡</sup>**

<sup>\*</sup>University of Colorado Denver – Anschutz Medical Campus, Department of Emergency Medicine, Aurora, Colorado  
<sup>†</sup>Denver Health Medical Center, Department of Emergency Medicine, Denver, Colorado  
<sup>‡</sup>University of Colorado School of Medicine, Aurora, Colorado

Section Editor: Rick A. McPheeters, DO

Submission history: Submitted November 17, 2020; Revision received April 7, 2021; Accepted April 1, 2021

Electronically published December 16, 2021

Full text available through open access at [http://escholarship.org/uc/uciem\\_cpem](http://escholarship.org/uc/uciem_cpem)

DOI: 10.5811/cpsem.2021.4.50265

**Case Presentation:** A 53-year-old female presented to the emergency department with three days of nausea and dyspnea on exertion after using methamphetamine. Initial electrocardiogram revealed an ST-elevation myocardial infarction. While awaiting transfer to the cardiac catheterization lab the patient suffered a witnessed cardiac arrest. During resuscitative efforts an enlarging pericardial effusion on point-of-care ultrasound led to the detection of a left ventricular free-wall rupture (LVFWR). This case illustrates the progression of a left ventricular free-wall rupture using point-of-care ultrasound.

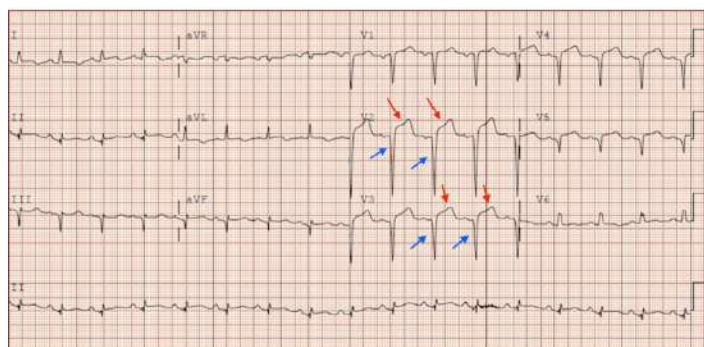
**Discussion:** Left ventricular free-wall rupture has a low incidence rate in the setting of an acute myocardial infarction. Ultrasonography is the tool of choice for detecting a LVFWR. [Clin Pract Cases Emerg Med. 2022;6(1):90–92.]

**Keywords:** *Left ventricular free-wall rupture; POCUS; acute myocardial infarction.*

## CASE PRESENTATION

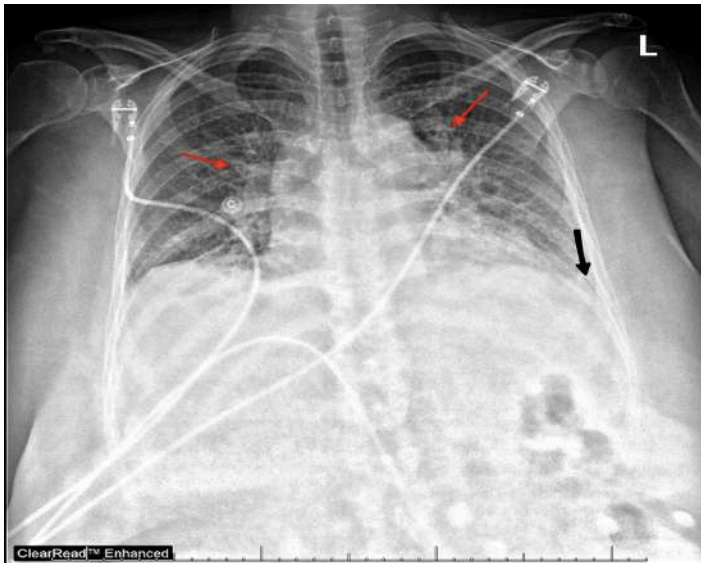
A 53-year-old female with a past medical history of diabetes mellitus, hypertension, and substance use disorder presented to the emergency department with three days of nausea, dyspnea on exertion, and orthopnea. The patient’s initial vital signs showed a heart rate of 104 beats per minute, blood pressure of 193/109 millimeters of mercury, respiratory rate of 18 breaths per minute, and pulse oximetry of 94% oxygen saturation on room air. Her initial workup and evaluation demonstrated ST-segment elevations and Q waves on electrocardiogram (ECG) (Image 1). The cardiac catheterization laboratory was immediately activated upon review of the ECG. Chest radiograph (Image 2) was obtained indicating pulmonary edema and small pleural effusions.

An initial point-of-care ultrasound (POCUS) (Video 1) showed evidence of a very small pericardial effusion. The patient was initially hesitant to undergo cardiac catheterization but 30 minutes after arrival agreed to intervention. Prior to



**Image 1.** Electrocardiogram from initial workup demonstrating ST-segment elevations (red arrows) and Q waves (blue arrows).

transfer to the catheterization laboratory, she suffered a cardiac arrest. Cardiopulmonary resuscitation and advanced cardiac life support were initiated. During resuscitative efforts POCUS was obtained, which showed a large pericardial effusion with concern for a mechanical complication of acute myocardial



**Image 2.** Chest radiograph showing pulmonary edema (red arrows) and small pleural effusions (black arrow).

infarction (MI). Left ventricular free-wall rupture (LVFWR) was the most concerning given the enlarging pericardial effusion (Video 2). Emergent pericardiocentesis via the subxiphoid approach was performed and 80 milliliters of bloody fluid was obtained. Repeat POCUS did not show any residual pericardial effusion following pericardiocentesis. Despite pericardiocentesis and resuscitative efforts, the patient did not survive.

## DISCUSSION

Diagnosis of LVFWR with hemopericardium following MI was confirmed through autopsy. A number of risk factors including diabetes mellitus, hypertension, and methamphetamine use could have contributed to a subacute MI (three days prior) resulting in LVFWR. Autopsy revealed the patient suffered from a 90% occluded left anterior descending artery. Left ventricular free-wall rupture will typically occur within five days of an MI due to vulnerable necrotic tissue.<sup>1</sup> Due to coronavirus disease 2019-related factors such as fear of virus contraction, patients may be more likely to present later to the hospital, leading to higher incidence of post-MI complications.<sup>2</sup> The incidence rate of LVFWR in acute MI is 2.2%.<sup>3</sup> The use of methamphetamine can also increase the risk of developing atherosclerotic plaque and acute coronary vasospasm.<sup>4</sup> Ultrasonography is indicated as the primary diagnostic tool if a patient is suspected of suffering from a LVFWR.<sup>5</sup> Management of a LVFWR includes pericardiocentesis and positive inotropic agents along with emergent surgical repair.<sup>5</sup>

**Video 1.** Point-of-care ultrasound (parasternal short axis) prior to cardiac arrest showing a small pericardial effusion (black arrowheads) and a small myocardium rupture (white arrow).

### *CPC-EM Capsule*

What do we already know about this clinical entity?

*A Left ventricular free wall rupture (LVFWR) can occur due to weakening of the myocardium following a myocardial infarction. Ultrasonography is the primary tool used to diagnose LVFWR.*

What is the major impact of the image(s)?

*The echocardiograms presented in this case demonstrate the progression of a left ventricular free wall rupture leading to a large pericardial effusion.*

How might this improve emergency medicine practice?

*Recognizing patients at risk for LVFWR and identifying a pericardial effusion and myocardial rupture through ultrasonography can lead to prompt diagnosis and improved patient outcomes.*

**Video 2.** Point-of-care ultrasound during resuscitative efforts showing a large pericardial effusion (white arrows).

Consent from patient's family has been obtained and filed for the publication of this case report. Documentation on file.

*Address for Correspondence:* Juan Galindez Mingo, BS, University of Colorado School of Medicine, 13001 E 17th PI, Aurora, CO 80045. Email: [juan.galindez@cuanschutz.edu](mailto:juan.galindez@cuanschutz.edu).

*Conflicts of Interest:* By the CPC-EM article submission agreement, all authors are required to disclose all affiliations, funding sources and financial or management relationships that could be perceived as potential sources of bias. The authors disclosed none.

*Copyright:* © 2022 Wilson et al. This is an open access article distributed in accordance with the terms of the Creative Commons Attribution (CC BY 4.0) License. See: <http://creativecommons.org/licenses/by/4.0/>

## REFERENCES

- Okabe T, Julien HM, Kaliyadan AG, et al. Prompt recognition of left ventricular free-wall rupture aided by the use of contrast echocardiography. *Tex Heart Inst J.* 2015;42(5):474-8.
- Hammad TA, Parikh M, Tashtish N, et al. Impact of COVID-19



- pandemic on ST-elevation myocardial infarction in a non-COVID-19 epicenter. *Catheter Cardiovasc Interv.* 2020;97(2):208-14.
3. Moreno R, López de Sá E, López-Sendón JL, et al. Frequency of left ventricular free-wall rupture in patients with acute myocardial infarction treated with primary angioplasty. *Am J Cardiol.* 2000;85(6):757-60, A8.
  4. Kevil CG, Goeders NE, Woolard MD, et al. Methamphetamine use and cardiovascular disease. *Arterioscler Thromb Vasc Biol.* 2019;39:1739-46.
  5. Amir O, Smith R, Nishikawa A, et al. Left ventricular free wall rupture in acute myocardial infarction: a case report and literature review. *Tex Heart Inst J.* 2005;32(3):424-6.

# Delayed Tension Pneumocephalus Following Frontal Sinus Fracture

Eddie X. Ortiz-Galloza, MD  
Bianca Arechiga, DO  
Jagdipak Heer, MD  
Daniel Quesada, MD

Kern Medical, Department of Emergency Medicine, Bakersfield, California

Section Editor: Austin Smith, MD

Submission History: Submitted June 11, 2021; Revision received September 16, 2021; Accepted September 28, 2021

Electronically published January 6, 2022

Full text available through open access at [http://escholarship.org/uc/uciem\\_cpem](http://escholarship.org/uc/uciem_cpem)

DOI: 10.5811/cpem.2021.9.53603

**Case Presentation:** We describe a delayed case of tension pneumocephalus in a newly altered patient 21 days status-post auto-vs-pedestrian accident. After her initial hospital course, the patient was discharged to an acute rehabilitation facility in stable condition with Glasgow Coma Scale 15. The patient returned to the emergency department for an acute change in mental status.

**Discussion:** Tension pneumocephalus is a neurosurgical and otolaryngological emergency. [Clin Pract Cases Emerg Med. 2022;6(1):93-94.]

**Keywords:** *tension pneumocephalus; altered mental status.*

## CASE PRESENTATION

A 72-year-old female with a history of auto-vs-pedestrian accident 21 days prior presented from an acute rehabilitation facility (ARF) for altered mental status. Nursing staff at the ARF reported that the patient had become gradually less responsive and interactive over a period of one hour prior to arrival. She was previously hospitalized for traumatic brain injury including right frontal lobe contusion, small right frontal lobe sub-arachnoid hemorrhage, small drops of pneumocephaly in the right frontal lobe, right anterior and posterior frontal sinus fractures extending to the medial aspect of the orbital roof, and a fracture of the medial wall of the right orbit (Image 1).

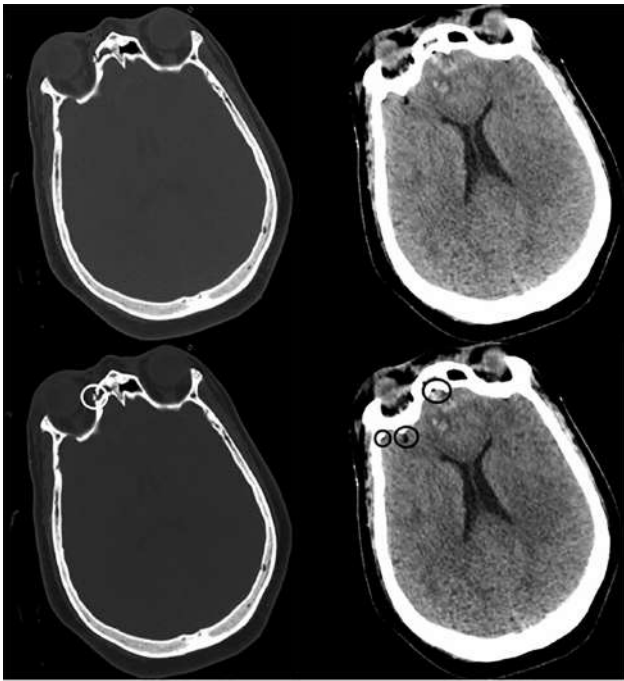
Vital signs included a heart rate 114 beats per minute, blood pressure 137/58 millimeters of mercury, respiratory rate 18 breaths per minute, and oxygen saturation 100% on room air. Physical exam revealed somnolence but arousing to minor stimulation, severe aphasia, Glasgow Coma Score (GCS) 11 (eyes 4, verbal 1, motor 6), right gaze deviation with inability to track left past the midline, and left hemiparesis of both extremities.

Computed tomography (CT) of the brain showed interval development of right frontal loculated pneumocephalus measuring 6.6 x 5.5 x 4.9 centimeters exerting mass effect

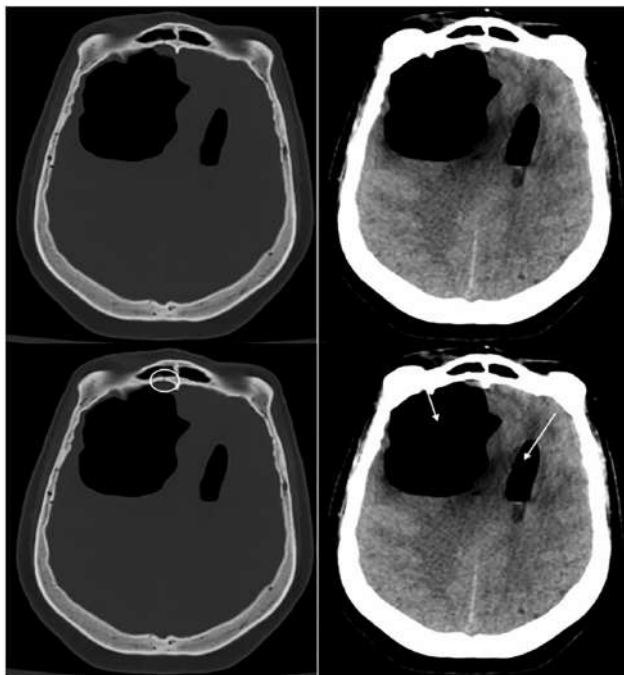
resulting in diffuse cerebral sulci effacement, 14 millimeters leftward subfalcine herniation, and suspected early right uncal herniation (Image 2). Neurosurgery and otolaryngology were consulted, and the patient subsequently went to the operating room for frontal bone repair, ethmoidectomy and closure of cerebrospinal-fluid leak. She had an uneventful recovery and was discharged to a skilled nursing facility with a GCS of 15, consistent with her mental status at the time of her initial discharge.

## DISCUSSION

This case demonstrates the complexity of a geriatric patient presenting with acute altered mental status. A broad differential diagnosis was considered. Infection and metabolic derangements were investigated; however, given the patient's neurological exam and recent history of trauma, CT of the head was ordered. This case elucidates the potential complications that can occur when facial fractures are present and observation rather than surgical repair is chosen. Tension pneumocephalus is a neurosurgical and otolaryngological emergency. Treatment is surgical decompression and fracture repair by the respective specialties.<sup>1</sup> The incidence of tension pneumocephalus associated with head trauma is less than 1%. However, the incidence increases to 8% with paranasal sinus or skull base fractures.<sup>2</sup>



**Image 1.** Computed tomography brain without contrast at initial presentation of a patient injured in an automotive-vs-pedestrian accident. LEFT: Bone window shows fractures in the medial wall of the right orbit (*white circle*). RIGHT: Brain window shows small drops of pneumocephaly in the right frontal lobe (*black circles*).



**Image 2.** Computed tomography brain without contrast at presentation 21 days later. LEFT: Bone window shows a right frontal sinus posterior wall fracture (*white circle*). RIGHT: Brain window shows right frontal loculated pneumocephalus (*white arrows*) with extension into ventricular system and left midline shift.

### *Educational Merit Capsule*

What do we already know about this clinical entity?

*Tension pneumocephalus (TP) is a surgical emergency. Paranasal sinus and skull base fractures have a significantly increased risk of developing TP.*

What is the major impact of the image(s)?

*These images reveal the potential complications that can occur when facial fractures are present and observation, rather than surgical repair, is chosen.*

How might this improve emergency medicine practice?

*Clinicians must repeat imaging on patients with a history of recent head trauma, specifically facial fractures, as tension pneumocephalus is a rare but possible diagnosis.*

The Institutional Review Board approval has been documented and filed for publication of this case report.

*Address for Correspondence:* Bianca Arechiga, DO, Kern Medical, Department of Emergency Medicine, 1700 Mount Vernon Ave, Bakersfield, California 93306. Email: bianca.arechiga@kernmedical.com.

*Conflicts of Interest:* By the CPC-EM article submission agreement, all authors are required to disclose all affiliations, funding sources and financial or management relationships that could be perceived as potential sources of bias. The authors disclosed none.

*Copyright:* © 2022 Ortiz-Galloza. This is an open access article distributed in accordance with the terms of the Creative Commons Attribution (CC BY 4.0) License. See: <http://creativecommons.org/licenses/by/4.0/>

### REFERENCES

1. Harvey JJ, Harvey SC, Belli A. Tension pneumocephalus: the neurosurgical emergency equivalent of tension pneumothorax. *BJR Case Rep.* 2016;2(2):20150127.
2. Al-Aieb A, Peralta R, Ellabib M, et al. Traumatic tension pneumocephalus: two case reports. *Int J Surg Case Rep.* 2017;31:145-9.

## The Case of the Red Extremities

Kelechi Abarikwu, BS\*  
James S. Komara, DO†  
Andrej Urumov, MD†

\*University of Arizona College of Medicine, Tucson, Arizona  
†Mayo Clinic, Department of Emergency Medicine, Phoenix, Arizona

Section Editor: Manish Amin, DO

Submission History: Submitted July 17, 2021; Revision received September 20, 2021; Accepted October 8, 2021

Electronically published January 28, 2022

Full text available through open access at [http://escholarship.org/uc/uciem\\_cpccem](http://escholarship.org/uc/uciem_cpccem)

DOI: 10.5811/cpccem.2021.10.52891

**Case Presentation:** A 37-year-old man with severe obstructive sleep apnea presented to the emergency department with burning pain, redness and swelling in his hands and feet, worsening for several weeks. Pertinent laboratory studies revealed polycythemia.

**Discussion:** Erythromelalgia is a clinical diagnosis characterized by painful burning, erythema, warmth, and edema usually involving the distal extremities. Therapeutic goals are focused on symptom reduction, while also managing the underlying condition in cases of secondary erythromelalgia. Pharmacological and non-pharmacological therapies have proven to be of limited success. [Clin Pract Cases Emerg Med. 2022;6(1):95-96.]

**Keywords:** *erythromelalgia; red extremities.*

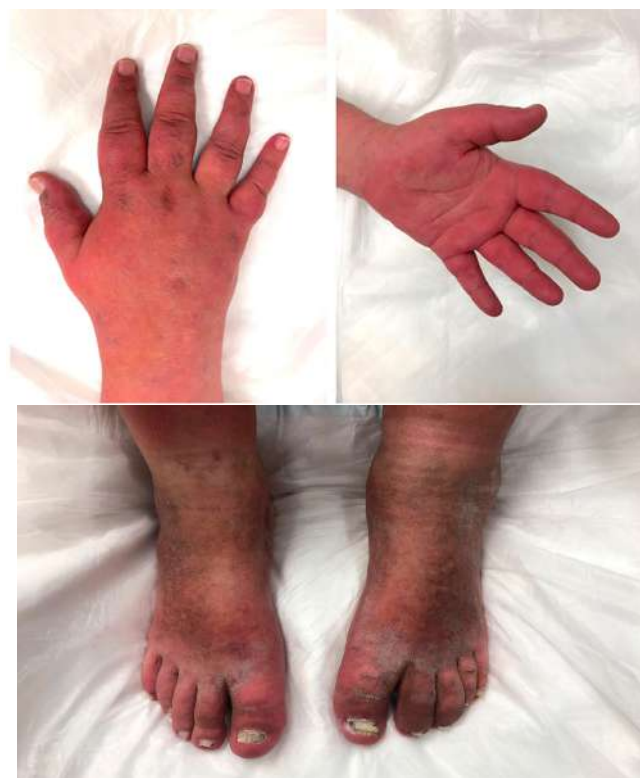### CASE PRESENTATION

A 37-year-old man with severe obstructive sleep apnea presented to the emergency department (ED) with burning pain, redness and swelling in his hands and feet (Image), worsening for several weeks. On physical examination, the extremities exhibited a blanching circumferential erythema. The extremities were warm to touch, with a non-pitting edema.

Laboratory evaluation demonstrated a hemoglobin of 19.8 grams per deciliter (g/dL) (reference range: 13.2-16.6 g/dL) and hematocrit of 59.9% (38.3-48.6%), suggestive of polycythemia, presumably secondary to sleep apnea.

### DISCUSSION

Erythromelalgia is a clinical diagnosis characterized by painful burning, erythema, warmth, and edema usually involving the distal extremities. The pain of erythromelalgia may be intermittent, lasting between minutes to days, and is frequently precipitated by heat exposure. Erythromelalgia may occur as a primary or secondary disorder. In its primary form, it has been linked to an autosomal dominant mutation in the sodium voltage-gated channel alpha subunit 9 (SCN9A) gene.<sup>1</sup> Secondary erythromelalgia occurs as a result of a multitude of conditions, including myeloproliferative disorders, connective tissue diseases, infections, and malignancy.<sup>2</sup> We



**Image.** Hands and feet erythema and edema in a patient with erythromelalgia.



postulate that the etiology of erythromelalgia in our patient was secondary to polycythemia.

Therapeutic goals are focused on symptom reduction, while also managing the underlying condition in cases of secondary erythromelalgia. Most therapy has limited efficacy. Non-pharmacological treatments include trigger avoidance, cooling of affected areas, and psychological counseling.<sup>3</sup> Pharmacological interventions include topical anesthetics, antidepressants, gabapentin, and glucocorticoids. Aspirin has been suggested for treatment in patients with erythromelalgia secondary to myeloproliferative disorders.<sup>4</sup> Given that our patient's presenting symptoms were not debilitating, no specific therapy was provided in the ED. Prognosis is dependent on the underlying condition as well as on the patient's ability to mitigate the symptoms.

The authors attest that their institution requires neither Institutional Review Board approval nor patient consent for publication of this case report. Documentation on file.

---

*Address for Correspondence:* Andrej Urumov, MD, Mayo Clinic, Department of Emergency Medicine, 5777 E. Mayo Boulevard, Phoenix, Arizona 85054. Email: [urumov.andrej@mayo.edu](mailto:urumov.andrej@mayo.edu).

*Conflicts of Interest:* By the CPC-EM article submission agreement, all authors are required to disclose all affiliations, funding sources and financial or management relationships that could be perceived as potential sources of bias. The authors disclosed none.

*Copyright:* © 2022 Abarikwu. This is an open access article distributed in accordance with the terms of the Creative Commons Attribution (CC BY 4.0) License. See: <http://creativecommons.org/licenses/by/4.0/>

---

### *CPC-EM Capsule*

What do we already know about this clinical entity?

*Erythromelalgia is an episodic, painful, pruritic, and edematous erythroderma of the distal part of the extremities with the diagnosis made on clinical grounds.*

What is the major impact of the image(s)?

*The image provides awareness of this condition to the emergency medicine provider.*

How might this improve emergency medicine practice?

*Early recognition of erythromelalgia results in faster initiation of therapy that hastens symptomatic relief and promotes improved patient experience.*

### REFERENCES

1. Cohen, JS. Erythromelalgia: new theories and new therapies. *J Am Acad Dermatol.* 2000;43(5):841-7.
2. Kurzrock R, Cohen PR. Erythromelalgia and myeloproliferative disorders. *Arch Intern Med.* 1989;149(1):105–9.
3. Mann N, King T, Murphy R. Review of primary and secondary erythromelalgia. *Clin Exp Dermatol.* 2019;44(5):477-82.
4. Klein-Weigel PF, Volz TS, Richter JG. Erythromelalgia. *Vasa.* 2018;47(2):91-7.

## Scrotal Pain Caused by a Segmental Testicular Infarct

Michael Muradian, MD\*  
Stephen Fox, MD\*  
Patrice Barish, MD\*†  
Brett Todd, MD\*†

\*Beaumont Health, Department of Emergency Medicine, Royal Oak, Michigan  
†Oakland University William Beaumont School of Medicine, Department of Emergency Medicine, Auburn Hills, Michigan

Section Editor: Shadi Lahham, MD

Submission History: Submitted July 6, 2021; Revision received October 12, 2021; Accepted October 15, 2021

Electronically published January 15, 2022

Full text available through open access at [http://escholarship.org/uc/uciem\\_cpem](http://escholarship.org/uc/uciem_cpem)

DOI: 10.5811/cpem.2021.10.53840

**Case Presentation:** A 44-year-old Black male presented to the emergency department with left scrotal pain. His initial workup did not identify an etiology of his symptoms; however, he returned the following day with worsening pain and a radiology-performed ultrasound then revealed a segmental testicular infarct.

**Discussion:** Segmental testicular infarcts are a rare, often idiopathic, source of scrotal pain. Diagnosis is made by ultrasound, and repeat imaging may be required if not apparent on initial evaluation. Management is typically conservative although some require surgical intervention. [Clin Pract Cases Emerg Med. 2022;6(1):97-99.]

**Keywords:** *ultrasound; scrotal pain.*

### CASE PRESENTATION

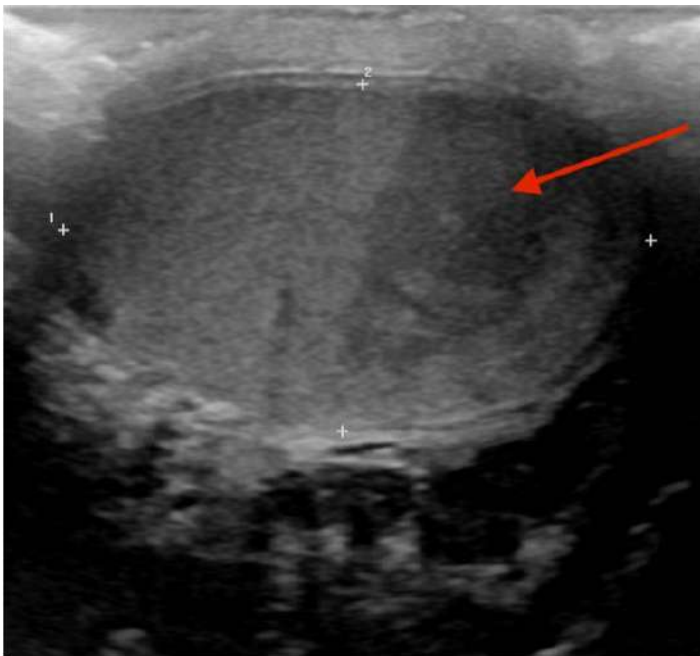
A 44-year-old Black male with history of diverticulitis and anabolic steroid use presented to the emergency department with the complaint of sudden onset right groin and testicular pain. Vitals on initial presentation were within normal limits. Physical examination showed mild tenderness to the right side of the scrotum without testicular tenderness or a mass. Labs were notable for an elevated white blood cell (WBC) count of 12.8 billion/L (reference range: 3.5-10.1 bil/L), hemoglobin of 18.1 bil/L (14.5-17 bil/L), and urinalysis was unremarkable. A scrotal duplex ultrasound demonstrated scrotal wall thickening along with a small hydrocele but no evidence of torsion. Non-contrast enhanced computed tomography of the abdomen and pelvis showed fat stranding around the prostate. Urology was consulted and recommended symptom control, but there was no acute intervention. The patient was discharged with strict return precautions.

The following day he returned with worsening right scrotal pain. Vitals at that time were notable for tachycardia to 105 beats per minute and a blood pressure of 160/112 millimeters mercury. Exam showed exquisite tenderness to the right lateral testicle. Repeat lab work showed the WBC count had risen to 14.8 bil/L and a hemoglobin of 18.7 bil/L. Although his age and atypical presentation made

intermittent torsion appear unlikely, a repeat radiology-performed ultrasound showed a hypoechoic, wedge-shaped abnormality in the right testicle with absent perfusion. The remainder of the testicle had relatively increased vascularity consistent with a segmental testicular infarct (Images 1 and 2). The patient was admitted for further evaluation and was managed conservatively with aspirin. He then had a workup including testing for clotting disorders, other primary or secondary causes of polycythemia, and tumor markers, which was unrevealing. The infarct was attributed to polycythemia caused by long-term anabolic steroid use.

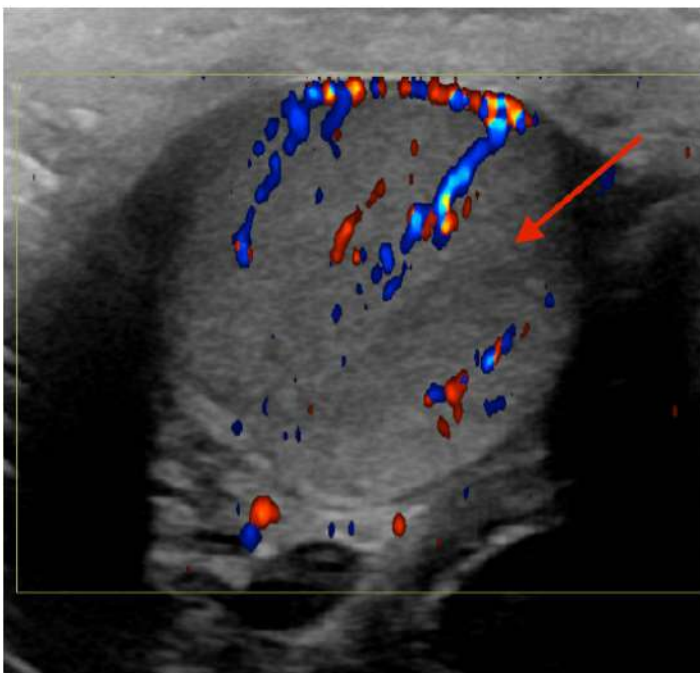
### DISCUSSION

Segmental testicular infarction is a rare but important cause of testicular pain that can mimic other etiologies of scrotal and testicular pain. It is most common in men ages 20-40. While most cases are idiopathic, it is associated with vasculitis, sickle cell disease, trauma, torsion, infection, malignancy, and polycythemia.<sup>1,2</sup> In this case, it is likely the patient's use of steroids and subsequent polycythemia were the cause of his infarct given the lack of other risk factors. The use of anabolic steroids is known to contribute to polycythemia and increase the risk of thrombosis and ischemic events.<sup>3</sup>



**Image 1.** A hypoechoic wedge-shaped area (arrow) seen on ultrasound in the right testicle on sagittal view.

Testicular ultrasound with color Doppler is diagnostic and can differentiate this process from etiologies that present similarly, such as torsion. It typically reveals a hypoechoic area with decreased or absent Doppler flow.<sup>1</sup> This condition is usually managed conservatively; however, some undergo orchiectomy if their diagnosis is unclear or there is concern



**Image 2.** A hypoechoic wedge-shaped area (arrow) showing no flow on ultrasound with Doppler in this transview.

### *CPC-EM Capsule*

What do we already know about this clinical entity?

*Segmental testicular infarcts are a rare cause of scrotal pain that are diagnosed by ultrasound with Doppler showing a hypoechoic area with decreased flow.*

What is the major impact of the image(s)?

*These images show the characteristic findings of a segmental testicular infarct of which emergency physicians should be aware.*

How might this improve emergency medicine practice?

*This case highlights a risk factor for testicular segmental infarcts and demonstrates the importance of considering repeat imaging.*

for malignancy.<sup>4</sup> This case highlights steroid use and polycythemia as important risk factors for segmental infarcts, which have not been well reported in the emergency medicine literature. It also illustrates the need for repeat imaging for a patient with persistent or worsening testicular pain as a segmental infarct may not be apparent on initial presentation.

The Institutional Review Board approval has been documented and filed for publication of this case report.

*Address for Correspondence:* Michael Muradian, MD, Beaumont Hospital - Royal Oak, GME Office, 3601 W Thirteen Mile Road, Royal Oak, Michigan 48703. Email: michael.muradian@beaumont.org.

*Conflicts of Interest:* By the CPC-EM article submission agreement, all authors are required to disclose all affiliations, funding sources and financial or management relationships that could be perceived as potential sources of bias. The authors disclosed none.

*Copyright:* © 2022 Muradian. This is an open access article distributed in accordance with the terms of the Creative Commons Attribution (CC BY 4.0) License. See: <http://creativecommons.org/licenses/by/4.0/>

### REFERENCES

1. Sweet D, Feldman M, Remer E. Imaging of the acute scrotum: keys to a rapid diagnosis of acute scrotal disorders. *Abd Radio*. 2020;45(7):2063-81.
2. Palmisano F, Serrago M, Gallioli A, et al. Segmental testicular infarction: case series and brief literature review of a great mime. *Urol Ann*. 2019;11(3):334-7.

3. Low MS, Vilcassim S, Fedele P, et al. Anabolic androgenic steroids, an easily forgotten cause of polycythemia and cerebral infarction. *Int Med J.* 2016;35(4):497-9.
4. Bak-Ipsen CB, Degn S, Blichert-Refsgaard LS, et al. Segmental testicular infarction – is conservative management feasible? *Ultrasound Int Open.* 2020;6(2):E50-2.



## Ruptured Urinary Bladder Diagnosed by Point-of-care Ultrasound

John C. Bates, PA-C  
Victoria Kneller, DO  
Layla Abubshait, MD

Einstein Healthcare Network, Department of Emergency Medicine,  
Philadelphia, Pennsylvania

Section Editor: Christopher Sampson, MD

Submission History: Submitted August 12, 2021; Revision received October 15, 2021; Accepted October 15, 2021

Electronically published December 15, 2021

Full text available through open access at [http://escholarship.org/uc/uciem\\_cpem](http://escholarship.org/uc/uciem_cpem)

DOI: 10.5811/cpcem.2021.10.54410

**Case Presentation:** We describe a case of abdominal pain in a male patient who performed daily self-catheterization and developed a ruptured urinary bladder, which was diagnosed at bedside in the emergency department with point-of-care ultrasound (POCUS).

**Discussion:** Ruptured urinary bladder is commonly associated with blunt abdominal trauma. It is a rare complication of Foley catheter insertion. These images demonstrate that POCUS can be used as a screening tool to evaluate for bladder rupture when clinically suspected. [Clin Pract Cases Emerg Med. 2022;6(1):100-102.]

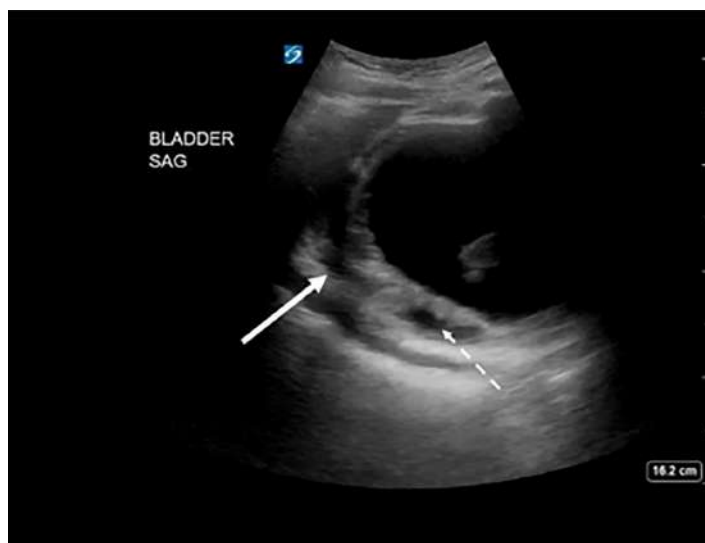**Keywords:** POCUS; ultrasound; bladder rupture.

### CASE PRESENTATION

An 83-year-old male with a history of metastatic prostate cancer requiring daily self-catheterization presented to the emergency department (ED) complaining of abdominal pain. His abdominal pain was mild and intermittent over the prior several days, without any aggravating or alleviating factors. The patient had been self-catheterizing five times per day, without resistance or gross hematuria. On arrival to the ED his vital signs were stable. Physical exam showed an elderly gentleman in pain with pale conjunctiva. His abdomen was soft, non-distended, and tender over the suprapubic area.

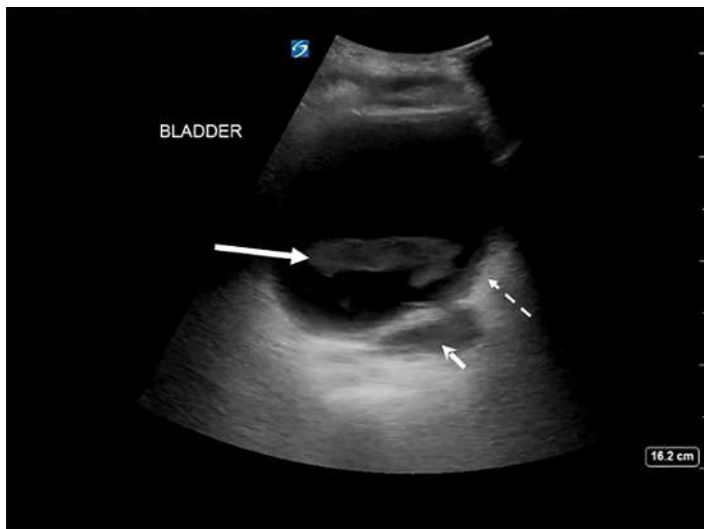
To further evaluate him, a curvilinear probe was used to perform point-of-care renal and bladder ultrasound. Bladder images showed a loculated fluid collection in the superior and posterior aspect of the bladder and fluid outside the wall of the bladder, as well as hyperechoic dependent densities within the bladder lumen (Images 1 and 2).

The patient was found to be anemic with a hemoglobin of 5.5 grams per deciliter (g/dL) (reference range: 14.0-18.0 g/dL). His renal function was slightly worse than his baseline with a blood urea nitrogen of 39 milligrams/dL (11-23 mg/dL), and creatinine of 1.50 mg/dL (0.7-1.5 mg/dL). His urinalysis was positive for leukocyte esterase, nitrites, and moderate red blood cells. After placing two large-bore



**Image 1.** Sagittal view of the bladder on point-of-care ultrasound showing posterior, fluid-filled loculations (solid arrow) and wall thickening (dashed arrow).

intravenous lines and initiating a blood transfusion, a computed tomography (CT) of the abdomen and pelvis was obtained, which showed fluid-filled loculation of the posterior

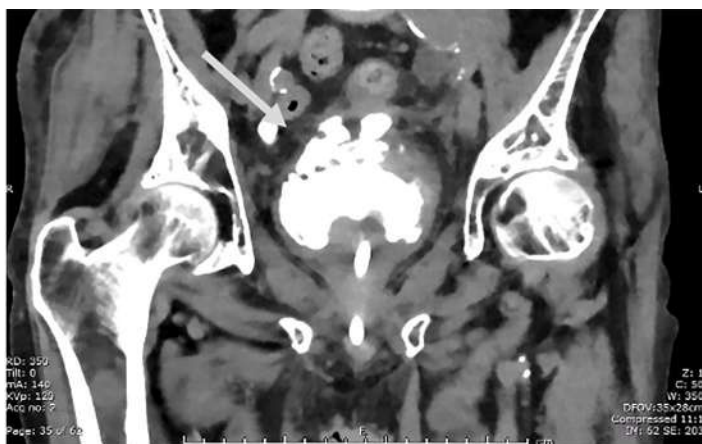


**Image 2.** Transverse view of the bladder on point-of-care ultrasound showing echodense material in the lumen of the bladder (solid arrow), wall thickening (dashed arrow), and extravasicular fluid deep to the bladder wall (arrowhead).

aspect of the bladder measuring 9.5 centimeters, suspicious for a partially contained bladder rupture. Urology was consulted and obtained CT cystogram, which demonstrated a partially contained bladder rupture, without extension of bladder contents into the peritoneum (Image 3). Urology recommended keeping a Foley catheter in place for three weeks with repeat imaging at that time.

## DISCUSSION

Bladder rupture is commonly associated with blunt abdominal trauma or surgical complication.<sup>2</sup> It is a rare complication of Foley catheter insertion.<sup>3</sup> Bladder rupture is generally categorized as either intraperitoneal or extraperitoneal, or combined.<sup>2,4</sup> It usually presents as acute abdominal pain, typically in the setting of trauma or after



**Image 3.** Computed tomography cystogram showing extravasated contrast contained in the extraperitoneal space (arrow).

### *CPC-EM Capsule*

What do we already know about this clinical entity?

*Bladder injuries are commonly associated with blunt abdominal injury. There are only few cases that reported bladder injuries with self-catheterization.*

What is the major impact of the image(s)?

*These images show that performing a point-of-care (POC) ultrasound can easily detect bladder injuries in the right clinical settings.*

How might this improve emergency medicine practice?

*POC ultrasound can expedite the diagnosis of bladder rupture.*

surgery. Retrograde cystography, whether plain film or CT, is the gold standard imaging modality to diagnose bladder rupture. However, point-of-care ultrasound (POCUS) offers a rapid alternative to assess bladder injury. The non-traumatized bladder is easily recognized on ultrasound as a well-circumscribed area of anechoic fluid in roughly a rectangular shape in the transverse plane, sometimes described as having the shape of a piece of toast.

Bladder rupture is recognized as an irregular-shaped bladder with free fluid adjacent to the bladder, or fluid in the right or left upper abdominal quadrants. The patient in the case had been self-catheterizing up to five times per day, increasing his risk of iatrogenic bladder injury. Clinicians should have a high yield of suspicion of bladder rupture in cases of self-catheterization. When used in the right context POCUS is a useful bedside tool to help clinicians diagnose this condition.

The authors attest that their institution requires neither Institutional Review Board approval nor patient consent for publication of this case report. Documentation on file.

*Address for Correspondence:* Layla Abubshait, MD, Einstein Healthcare Network, Department of Emergency Medicine, 559 West Germantown Pike, East Norriton, 19403. Email: abubshal@einstein.edu.

*Conflicts of Interest:* By the CPC-EM article submission agreement, all authors are required to disclose all affiliations, funding sources and financial or management relationships that could be perceived as potential sources of bias. The authors disclosed none.

*Copyright:* © 2022 Bates. This is an open access article distributed in accordance with the terms of the Creative Commons Attribution (CC BY 4.0) License. See: <http://creativecommons.org/licenses/by/4.0/>

---

## REFERENCES

1. Neto A, Bell D. Spontaneous rupture of the urinary bladder. 2021. Available at: <https://radiopaedia.org/articles/90135>. Accessed October 11, 2021.
2. Simon LV, Sajjad H, Lopez RA, et al. Bladder Rupture. [Updated 2021 Sep 17]. In: StatPearls [Internet]. Treasure Island (FL): StatPearls Publishing; 2021 Jan. Available from: <https://www.ncbi.nlm.nih.gov/books/NBK470226/>
3. Ogawa S, Date T, Muraki O. Intraperitoneal urinary bladder perforation observed in a patient with an indwelling urethral catheter. *Case Rep Urol.* 2013;2013:765704.
4. Kang L, Geube A. Bladder Trauma. [Updated 2021 May 28]. In: StatPearls [Internet]. Treasure Island (FL): StatPearls Publishing; 2021 Jan-. Available from: <https://www.ncbi.nlm.nih.gov/books/NBK557875/>

## Case of an Infant with Intermittent Eye Swelling

Alexandra H. Baker, MD\*†  
Susan Lipsett, MD\*†

\*Boston Children's Hospital, Department of Pediatrics/Division of Emergency Medicine, Boston, Massachusetts

†Harvard Medical School, Department of Pediatrics, Boston, Massachusetts

Section Editor: Anna McFarlin, MD

Submission History: Submitted July 28, 2021; Revision received October 20, 2021; Accepted October 22, 2021

Electronically published January 15, 2022

Full text available through open access at [http://escholarship.org/uc/uciem\\_cpem](http://escholarship.org/uc/uciem_cpem)

DOI: 10.5811/cpcem.2021.10.54287

**Case Presentation:** An eight-week-old infant presented to the emergency department with two weeks of fluctuating swelling and erythema of her right upper eyelid. On examination, she had swelling of the right upper eyelid with ptosis and proptosis as well as a nevus simplex on the upper eyelid. Orbital magnetic resonance imaging demonstrated a proliferating orbital hemangioma.

**Discussion:** Periorbital erythema and swelling are often infectious or allergic, but in infants with a fluctuating course, underlying vascular malformation must be considered. Without early provider recognition, periorbital hemangiomas have the potential to cause vision-related complications. [Clin Pract Cases Emerg Med. 2022;6(1):103-104.]

**Keywords:** *infantile hemangioma; eye swelling; pediatric emergency medicine.*

### CASE PRESENTATION

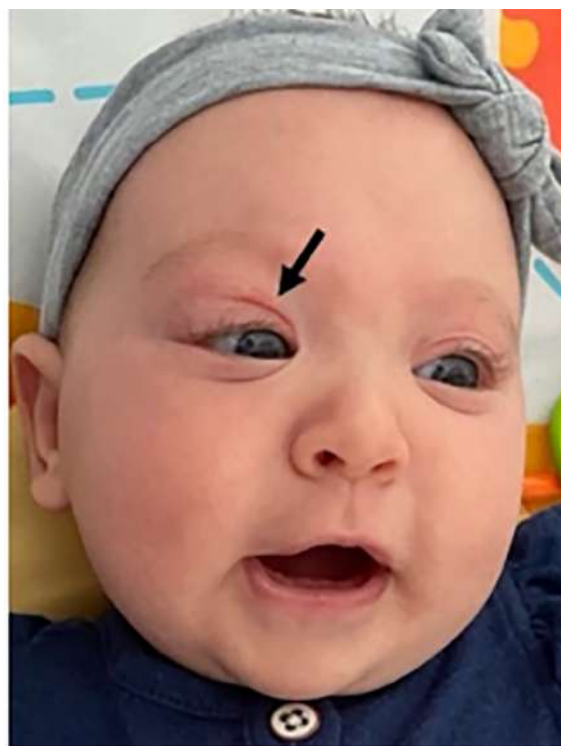An eight-week-old infant presented to the emergency department (ED) with two weeks of fluctuating swelling and erythema of her right upper eyelid. She had been otherwise well without fever, apparent pain, or involvement of the conjunctiva. During her course, she had seen multiple other providers and on day of presentation had been referred from a community ED for concerns of orbital cellulitis. On exam, the patient had moderate swelling of the right upper eyelid with ptosis and proptosis, as well as mild swelling of the lower eyelid. She was also noted to have a nevus simplex "angel kiss" on her right eyelid (Image 1).

Given the fluctuating course of her symptoms and the abnormal exam findings, concern was raised for underlying lesion, and urgent follow-up with ophthalmology was arranged. Magnetic resonance imaging of the brain and orbits revealed signal abnormality in the pre- and post-septal spaces of the right superolateral orbit that involved the right upper eyelid and lateral aspect of the lower eyelid consistent with orbital hemangioma with associated mild, right-sided proptosis (Image 2).

### DISCUSSION

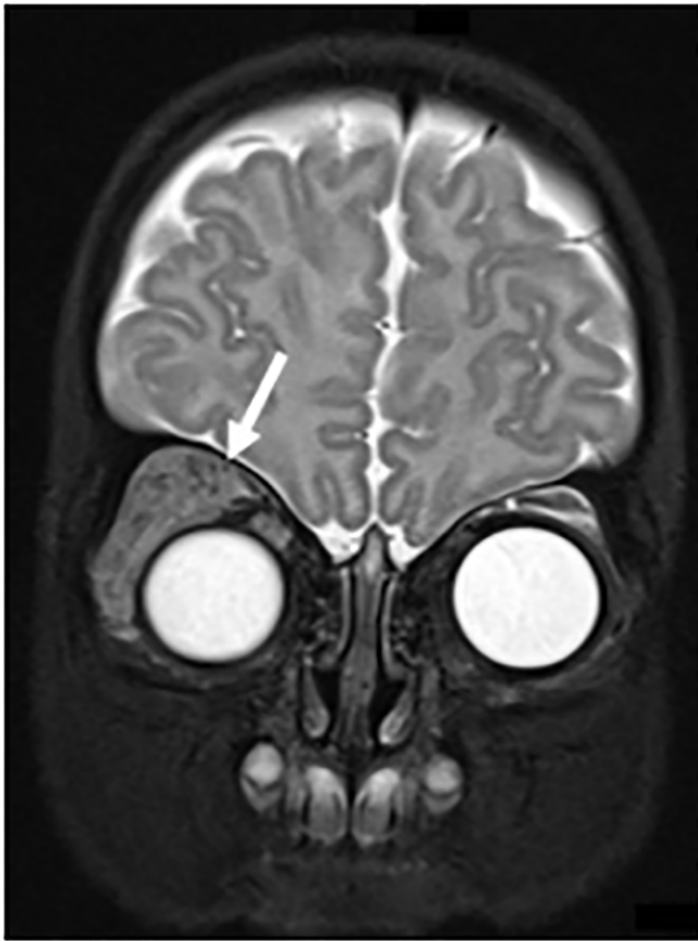Diagnosis: *Proliferating orbital infantile hemangioma*

Although periorbital swelling and erythema in the pediatric patient are most often consistent with an infectious or allergic etiology, a fluctuating time course and lack of



**Image 1.** Infant with swelling of the right upper and lower eyelid. Upper eyelid with "angel kiss" (arrow).





**Image 2.** Magnetic resonance imaging of brain and orbits demonstrating signal abnormality consistent with orbital infantile hemangioma (arrow).

associated symptoms should raise concern for underlying vascular malformation. While a nevus simplex, or “angel kiss,” is often an isolated finding, it can also be associated with deeper vascular lesions and should heighten suspicion. When this is suspected, magnetic resonance imaging and consultation with the appropriate subspecialty can lead to the correct diagnosis and management.

While infantile hemangiomas are the most common benign tumor of infancy and occur in 4-5% of infants,<sup>1</sup> periocular hemangiomas have the potential to cause vision-related complications. Without physician recognition and appropriate therapy, children are at significant risk for vision loss secondary to amblyopia, astigmatism, strabismus, or corneal exposure and damage related to proptosis.<sup>2</sup> While difficult to manage surgically due to their location, periocular hemangiomas, like other infantile hemangiomas, generally respond well to medical management.<sup>3</sup> Our patient was started on propranolol and has had improvement in her swelling. She will continue to be followed closely by an ophthalmologist to monitor her vision development as she ages.

### *CPC-EM Capsule*

What do we already know about this clinical entity?

*Infantile hemangiomas are the most common benign tumor of infancy, and periocular hemangiomas have the potential to cause vision-related complications.*

What is the major impact of the image(s)?

*Periorbital erythema and swelling in an infant with a fluctuating course should raise concern for underlying vascular malformation.*

How might this improve emergency medicine practice?

*Emergency physician recognition of a possible underlying vascular lesion will expedite referral to pediatric ophthalmology prior to permanent vision loss.*

Patient consent has been obtained and filed for the publication of this case report. The authors attest that their institution does not require Institutional Review Board for publication of this case report. Documentation on file.

*Address for Correspondence:* Alexandra H. Baker, MD, Boston Children’s Hospital, Department of Pediatrics, 300 Longwood Avenue, Boston, Massachusetts 02115. Email: alexandra.baker@childrens.harvard.edu.

*Conflicts of Interest:* By the CPC-EM article submission agreement, all authors are required to disclose all affiliations, funding sources and financial or management relationships that could be perceived as potential sources of bias. The authors disclosed none.

*Copyright:* © 2022 Baker. This is an open access article distributed in accordance with the terms of the Creative Commons Attribution (CC BY 4.0) License. See: <http://creativecommons.org/licenses/by/4.0/>

### REFERENCES

1. Munden A, Butschek R, Tom WL, et al. Prospective study of infantile haemangiomas: incidence, clinical characteristics and association with placental anomalies. *Br J Dermatol.* 2014;170(4):907-13.
2. Ceisler EJ, Santos L, Blei F. Periocular hemangiomas: what every physician should know. *Pediatr Dermatol.* 2004;21(1):1-9.
3. Novoa M, Baselga E, Beltran S, et al. Interventions for infantile haemangiomas of the skin. *Cochrane Database Syst Rev.* 2018;4:CD006545.

# Unintentional Epinephrine Auto-Injector Maxillofacial Injury in a Pediatric Patient

Jason David, MD\*  
Jerad Eldred, MD†  
David Raper, DDS\*

\*Nellis Air Force Base, Mike O'Callaghan Military Medical Center, Department of  
Emergency Medicine, Las Vegas, Nevada

†University of Nevada, Las Vegas, University Medical Center of Southern Nevada,  
Department of Emergency Medicine, Las Vegas, Nevada

Section Editor: Anna McFarlin, MD

Submission History: Submitted August 20, 2021; Revision received October 29, 2021; Accepted November 10, 2021

Electronically published January 15, 2022

Full text available through open access at [http://escholarship.org/uc/uciem\\_cpem](http://escholarship.org/uc/uciem_cpem)

DOI: 10.5811/cpem.2021.11.54464

**Case Presentation:** A four-year-old female patient presented to the emergency department with an epinephrine auto-injector that had unintentionally discharged into her mandible. There was difficulty removing the auto-injector at bedside. Images we acquired noted needle curvature not present in an off-the-shelf model. She was sedated, and the auto-injector was removed by retracing the angle of discharge, with care taken not to inject epinephrine into the patient.

**Discussion:** Epinephrine auto-injector accidental discharges are an unusual injury pattern, but the incidence of such events is increasing in the United States. The emergency clinician should be cognizant of complicating factors with discharges, such as bent needles. Here we discuss a case of discharge into the maxillofacial region (lower jaw), with approaches to treatment. [Clin Pract Cases Emerg Med. 2022;6(1):105-107.]

**Keywords:** *epinephrine auto-injector; EpiPen; discharge, maxillofacial; pediatrics.*

## CASE PRESENTATION

A four-year-old female presented to the emergency department (ED) with an epinephrine auto-injector unintentionally injected and lodged in her lower jaw that entered through the gingiva. Radiographs of the skull and computed tomography (CT) revealed a hooked epinephrine auto-injector embedded between the lower central incisors beneath the gingival line, bent at an approximately 140° angle (Images 1 and 2).

An initial attempt was made by the parents to remove the object at home followed by an attempt at ED bedside, which proved to be difficult due to needle angulation. We consulted oral-maxillofacial surgery; the patient was sedated with intravenous ketamine, and under sedation the hook was pulled in a retrograde manner following the noted posterior-lateral trajectory of the bent needle tip on maxillofacial imaging (Image 3). With some force, the needle was removed with care that it not accidentally discharge epinephrine into the patient. There was a very minor avulsion of gingival mucosa, which we learned did not interfere with patient's oral intake or speech after following up with parent.

## DISCUSSION

Unintentional epinephrine auto-injector injuries typically occur in the digits or the legs.<sup>1</sup> These cases are on the rise, as epinephrine auto-injectors have become more commonly prescribed.<sup>2</sup> However, exploring the world by placing

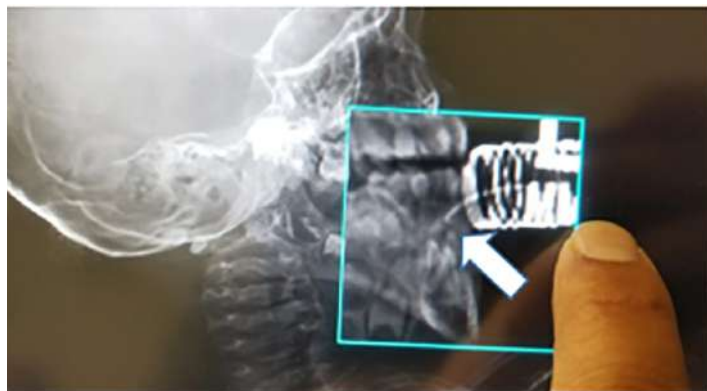
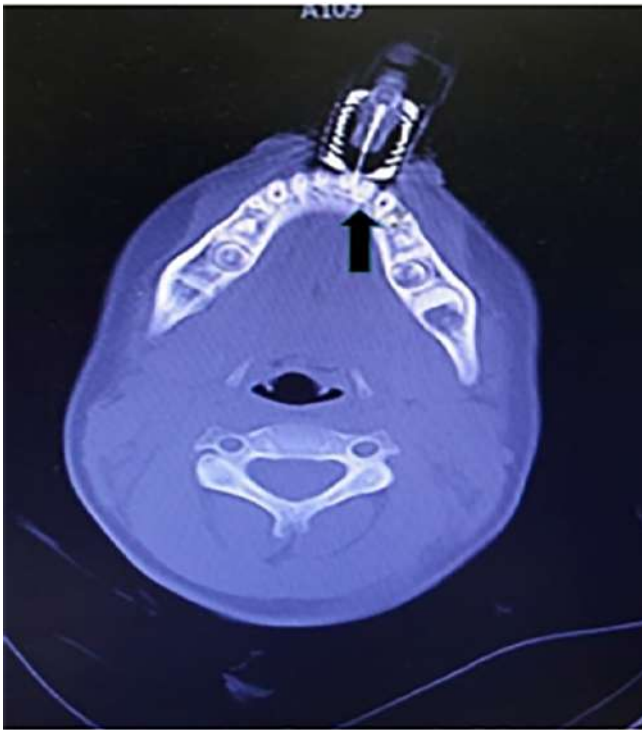

Image 1. Cranial radiographs identifying foreign body (arrow).



**Image 2.** Maxillofacial computed tomography with axial view reconstruction demonstrating hooked foreign body (arrow).



**Image 3.** Removed epinephrine auto-injector and bent needle (arrow).

objects in their mouths is a normal stage of early childhood development.<sup>3</sup> This case was particularly concerning due to the initial difficulty in removing the auto-injector and fear of accidentally discharging the adult-dose epinephrine into the patient. Efforts were made to stabilize the auto-injector with a bulky dressing and pillow. Due to the difficulty with initial removal, imaging was pursued. Maxillofacial CT is the optimal imaging study.<sup>4</sup>

### *CPC-EM Capsule*

What do we already know about this clinical entity?

*Epinephrine auto-injector accidental discharges are a unique and rising injury pattern in the United States and can have deceptively simple presentations.*

What is the major impact of the image(s)?

*Emergency medicine physicians should be aware of complicating factors with accidental auto-injector injuries, such as bent needles, and appreciate nuances to treatment.*

How might this improve emergency medicine practice?

*Emergency medicine physicians will be more familiar with this particular injury pattern and be more effective at treating similar auto-injector injuries.*

The mechanism behind the hooking of the needle of the auto-injector could presumably be due to hitting the subgingival areas of the incisor and curving, as well as bending, during attempted removals. Postulations from similar case studies regarding the curvature of auto-injector needles include bending when hitting a bone during injection, bending when the patient moves during injection, or if the needle fires off center and hits the cartridge carrier, hooking the needle prior to injection.<sup>5</sup> This situation should be anticipated and investigated with imaging by the treating physician before attempting to remove the needle blindly. Stabilizing the auto-injector with a pillow and bulky dressing will also prevent further bending of the needle, which would make removal more difficult. Furthermore, care should be taken not to accidentally discharge the epinephrine dose, either by securing the pen with a bulky dressing as we did, or by removing the chamber (which we found to be extremely difficult). Prudent emergency physicians should keep these factors (object stabilization, needle curvature, and remaining epinephrine dose) in mind when treating a victim of accidental auto-injector discharge to a sensitive area such as the face.

The authors attest that their institution requires neither Institutional Review Board approval nor patient consent for publication of this case report. Documentation on file.

*Address for Correspondence:* Jason David, MD, Mike O Callaghan Military Medical Center, 4700 Las Vegas Blvd N Nellis

AFB, 89191 Email: Jason.w.david.mil@mail.mil.

**Conflicts of Interest:** By the *CPC-EM* article submission agreement, all authors are required to disclose all affiliations, funding sources and financial or management relationships that could be perceived as potential sources of bias. The authors disclosed none. The views expressed here are those of the authors and do not reflect the official policy of the Department of the Army, the Department of Defense, or the U.S. Government.

**Copyright:** © 2022 David. This is an open access article distributed in accordance with the terms of the Creative Commons Attribution ([CC BY 4.0](http://creativecommons.org/licenses/by/4.0/)) License. See: <http://creativecommons.org/licenses/by/4.0/>

## REFERENCES

1. Anshien M, Rose SR, Wills BK. Unintentional epinephrine auto-injector injuries: A National Poison Center observational study. *Am J Ther.* 2019;26(1):e110-e4.
2. Campbell RL, Manivannan V, Hartz M, et al. Epinephrine auto-injector pandemic. *Pediatric Emerg Care.* 2021;28(9):938-42.
3. Koch G and Poulsen S. Paediatric dentistry—a clinical approach. In: *Mental Development of the Child, 1st ed.*. Copenhagen: Munksgaard; 2001;35:41.
4. Javadrashid R, Fouladi DF, Golamian M, et al. Visibility of different foreign bodies in the maxillofacial region using plain radiography, CT, MRI and ultrasonography: an in vitro study. *Dentomaxillofac Radiol.* 2015;44(4):20140229.
5. Goldman RD, Long KC, Brown JC. Hooked epinephrine auto-injector devices in children: four case reports with three different proposed mechanisms. *Allergy Asthma Clin Immunol.* 2020;16:19.



# Frontal Arteriovenous Malformation Presenting as Painful Unilateral Conjunctiva Injection

Andrew Harkins, MD\*  
Christine Bassig-Santos, BS†  
Michael Cirone, MD\*,‡

\*Advocate Christ Medical Center, Department of Emergency Medicine, Oak Lawn, Illinois  
†Chicago Medical School at Rosalind Franklin University, North Chicago, Illinois  
‡University of Illinois-Chicago, Department of Emergency Medicine, Chicago, Illinois

Section Editor: Jacqueline Le, MD

Submission History: Submitted July 26, 2021; Revision received October 19, 2021; Accepted October 16, 2021

Electronically published January 31, 2022

Full text available through open access at [http://escholarship.org/uc/uciem\\_cpem](http://escholarship.org/uc/uciem_cpem)

DOI: 10.5811/cpem.2021.10.54268

**Case Presentation:** Arteriovenous malformations (AVM) have a variety of clinically significant manifestations. This report details a patient who presented with unilateral conjunctiva injection, which was found to be due to an atypical manifestation of an AVM with a large draining vein mimicking carotid cavernous fistula.

**Discussion:** While imaging for patients presenting with eye pain and unilateral conjunctiva injection is not always warranted, emergency physicians should keep their differential diagnosis broad and pursue additional workup when warning signs of more sinister pathology present. [Clin Pract Cases Emerg Med. 2022;6(1):108-110.]

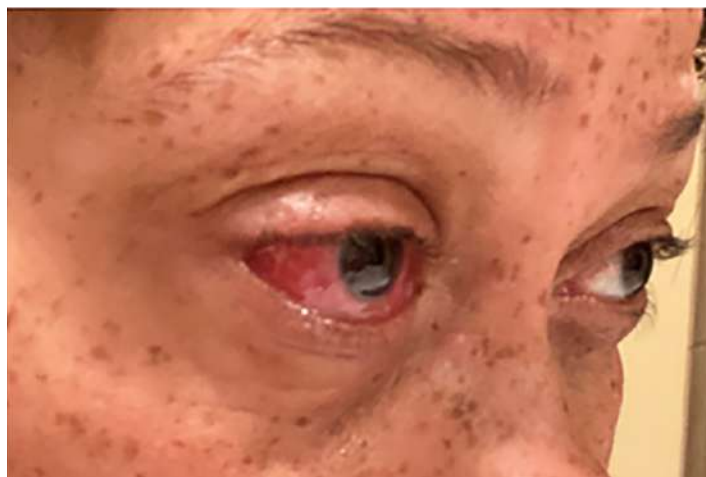**Keywords:** *case report; arteriovenous malformation; carotid cavernous fistula.*

## CASE PRESENTATION

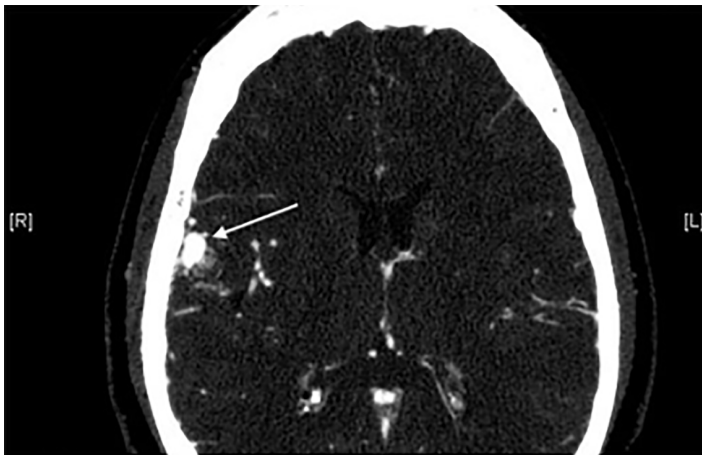
A 54-year-old female with history of hypertension presented to the emergency department with right eye pain for three days (Image 1). Her primary care physician previously prescribed erythromycin ointment without relief of her symptoms. Pertinent review of systems included pain with eye movement, sensitivity to light, mild associated swelling, and a mild headache. There was no loss of vision, purulent discharge, or history of previous eye pathology.

The patient's vital signs were within normal limits. Physical examination revealed right conjunctiva injection and pain with extraocular range of motion. The cornea was clear without evidence of foreign bodies or fluorescein uptake. Pupils were equal, round, and reactive to light bilaterally. There was no perilimbal injection, hyphema, or hypopyon noted. Ocular acuities were 20/50 for the left eye and 20/25 for the right eye. Intraocular pressures unfortunately were not obtained. The patient was otherwise neurologically intact. Computed tomography of the orbits with intravenous contrast was obtained demonstrating an arteriovenous malformation (AVM) within the right frontal lobe with a draining vein extending into the sphenoparietal and cavernous sinuses (Images 2 and 3).

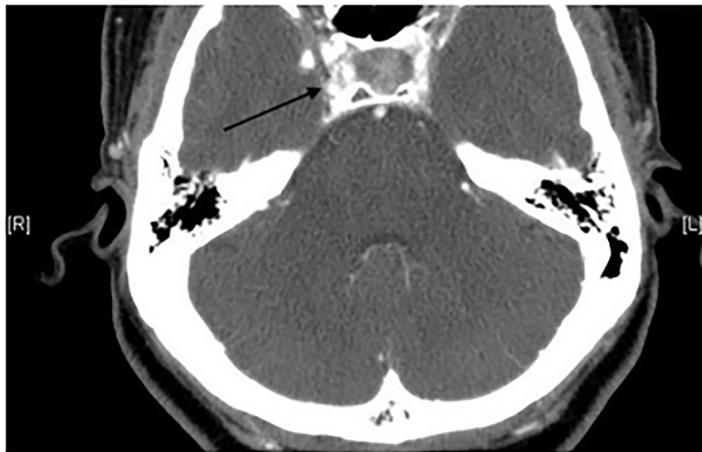Neuroendovascular specialists performed an angiogram, which showed a 1.5-centimeter right frontal lobe AVM draining via one enlarged, arterialized draining vein into the right cavernous sinus. The patient subsequently underwent onyx embolization and operative AVM resection.



**Image 1.** Home photograph brought to the emergency department depicting conjunctiva injection of the patient's right eye.



**Image 2.** Computed tomography of the orbits with intravenous contrast, axial image, demonstrating a large right frontal arteriovenous malformation (arrow).



**Image 3.** Computed tomography of the orbits with intravenous contrast, axial image, demonstrating a large right draining vein into the cavernous sinus (arrow).

## DISCUSSION

Intracranial AVMs occur with a new-case incidence of 1/100,000 each year, with orbital AVMs making up a minor proportion of cases.<sup>1</sup> Ruptured AVMs have an associated mortality as high as 29%, with previous studies showing resulting significant disability at a rate as high as 33%.<sup>2</sup> Orbital AVMs may manifest as visual changes, proptosis, periocular swelling or pain, and increased intracranial pressure.<sup>3</sup> The related malformation of carotid cavernous fistulas (CCF) present with pulsations, headache, reduced visual acuity, diplopia, ophthalmoplegia, chemosis, pain, proptosis, and conjunctiva injection.<sup>4,5</sup>

Because of abnormal connectivity, symptoms from AVMs are mostly due to mass effect if unruptured, the effects of hemodynamic changes on surrounding tissue, or rupture and hemorrhage.<sup>5</sup> However, this patient's symptoms were more consistent with a CCF presentation due to abnormal vein drainage into the cavernous sinus with subsequent congestion.

### *CPC-EM Capsule*

What do we already know about this clinical entity?

*Arteriovenous malformations have differing clinical presentations dependent on location and anatomy, most commonly due to mass effect or changes to surrounding tissue.*

What is the major impact of the image(s)?

*Unilateral scleral injection when associated with ophthalmoplegia, proptosis, or other signs of more sinister pathologies should warrant further investigation.*

How might this improve emergency medicine practice?

*Emergency physicians should seek alternative diagnoses when symptoms do not fit more common and benign etiologies.*

This case highlights the need for further investigation if unique and worrisome symptoms such as ophthalmoplegia, proptosis, neurologic change, pain with extraocular range of motion, or other signs of more sinister pathologies present in order to provide prompt and appropriate care.

Patient consent has been obtained and filed for the publication of this case report. The authors attest that their institution does not require Institutional Review Board for publication of this case report. Documentation on file.

*Address for Correspondence:* Andrew Harkins, MD, Advocate Christ Medical Center, Department of Emergency Medicine, Suite 1320M 4440 W 95th St. Oak Lawn, IL 60453. Email: andrew.harkins@aah.org.

*Conflicts of Interest:* By the CPC-EM article submission agreement, all authors are required to disclose all affiliations, funding sources and financial or management relationships that could be perceived as potential sources of bias. The authors disclosed none.

*Copyright:* © 2022 Harkins. This is an open access article distributed in accordance with the terms of the Creative Commons Attribution (CC BY 4.0) License. See: <http://creativecommons.org/licenses/by/4.0/>

## REFERENCES

1. Mohr JP, Kejda-Scharler J, Pile-Spellman J. Diagnosis and treatment of arteriovenous malformations. *Curr Neurol Neurosci Rep.* 2013;13(2):324.

2. Choi J, Mast H, Sciacca R, et al. Clinical outcome after first and recurrent hemorrhage in patients with untreated brain arteriovenous malformation. *Stroke*. 2006;37(5):1243-7.
3. Gregory ME, Berry-Brincat A, Ghosh YK, et al. An arteriovenous malformation masquerading as a carotid-cavernous sinus fistula. *Am J Ophthalmol*. 2005;140(3):548-50.
4. Warriar S, Prabhakaran VC, Valenzuela A, et al. Orbital arteriovenous malformations. *Arch Ophthalmol*. 2008;126(12):1669–75.
5. Dumont AS, Lanzino G, Sheehan JP. (2017). Development of the cerebrovasculature and pathogenesis of arteriovenous malformations and arteriovenous fistulas & Physiology and hemodynamics of arteriovenous malformations and arteriovenous fistulas. T. Hiscock & S. Landis (Eds.), *Brain arteriovenous malformations and arteriovenous fistulas (19-24, 25-33)*. New York: Thieme Publishers New York.

## This Article Corrects: “A Chemist with a Strange Etiology of Rhabdomyolysis: A Case Report of a Rare Toxicological Emergency”

**Rajadurai Meenakshisundaram, MBBS, MD\***  
**Joshua Vijay Joseph, MBBS, MEM, PG\***  
**Prabakaran Perumal, MBBS\***  
**Akmal Areeb, MBBS\***  
**Prathap Pancheti, MBBS, MD\***  
**Dinesh Kannan Sampath, MBBS, MD\***  
**Esther Monica Jared, MBBS\***  
**Allison K Ryan, MD†**

\*Apollo KH Hospital, Department of Emergency Medicine and Critical Care, Melvisharam, Tamil Nadu, India

†Einstein Medical Center, Department of Emergency Medicine, Philadelphia, Pennsylvania

Electronically published February 13, 2022

Full text available through open access at [http://escholarship.org/uc/uciem\\_cpchem](http://escholarship.org/uc/uciem_cpchem)

DOI: 10.5811/cpcem.2022.2.56452

*Clin Pract Cases Emerg Med. 2021;5(4)432-435.*

A Chemist with a Strange Etiology of Rhabdomyolysis: A Case Report of a Rare Toxicological Emergency  
R Meenakshisundaram, JVJoseph, P Perumal, A Areeb, P Pancheti, DK Sampath, EM Jared, AK Ryan

[*Clin Pract Cases Emerg Med. 2022;6(1):111.*] This article includes an additional author, Allison K Ryan, MD.





Journal of Education & Teaching *in* Emergency Medicine

*A publication of* **CORD**

*Education*

We believe that all learners should benefit from active learning.

We are an online, open access, peer-reviewed journal-repository for EM educators in all major topic areas.

*Scholarship*

We believe educators should advance through the scholarship of their educational work. JETem gives you the opportunity to publish & distribute your outstanding, scholarly academic work.

**Submit your content or contact us to become a reviewer!**



*visualem*



*small groups*



*tbl*



*simulation*



*lecture*



*oral boards*



*podcasts*



*curriculum*



*innovations*

[www.jetem.org](http://www.jetem.org)



*published by*

**eScholarship University of California**



**CALIFORNIA ACEP**

**50**

**ANNIVERSARY**