

CPC Emergency Medicine

Volume 8, Number 1, February 2024

Open Access at www.cpcem.org

ISSN: 2474-252X

Clinical Practice and Cases in Emergency Medicine

In Collaboration with the *Western Journal of Emergency Medicine*

Case Report

- 1 **Aortic Thrombus with Bilateral Renal Infarcts: A Case Report**
Lev Libet

- 5 **Case Report: Pediatric Thyroid Storm Presenting to the Emergency Department with Afebrile Seizure**
Daniel J. Klein, Emily Rose

- 9 **Complications of Bacterial Keratitis Impacted by Social Determinants of Health: A Case Report**
Taylor Diederich, Mary Velagapudi, Hope Ring

- 14 **Delayed Onset of Symptoms After a Rattlesnake Bite in a Renal Transplant Patient: A Case Report**
Thomas A. Rogers, John Herrick

- 18 **Isolated Laryngeal Angioedema in a Patient with Long-term ACE Inhibitor Use: A Case Report**
Carney Flinn, Inna Massaro

- 22 **Peripartum Cardiac Arrest with Terminal QRS Distortion: A Case Report**
Timothy D. Kelly, Nicholas E. Harrison

- 26 **Spontaneous Coronary Artery Dissection Presenting as Electrical Storm: A Case Report**
Nathan Escorial, Coleman Cowart, Matthew Papanian, Joel Stillings

- 30 **The Other Aortic Syndrome—Intramural Hematoma and Neurological Deficit: Case Report**
Laura E. Walker, Chris Marcellino, Bhargavi Gali

- 34 **The Rare Sore Throat: A Case of Thyroid Storm and Agranulocytosis**
Matthew J. Kunz, Wayne A. Martini, Levi Filler

- 38 **Vitamin C and D Deficiency in Urban America: A Case Report**
Alyssa A. Lombardi, Maura Sammon, Kraftin E. Schreyer

Contents continued on page iii



UC Irvine Health





**ACOEP stands with all emergency
physicians and providers on the
front line. We thank you for your
tireless work and effort.**



Penn State Health Emergency Medicine

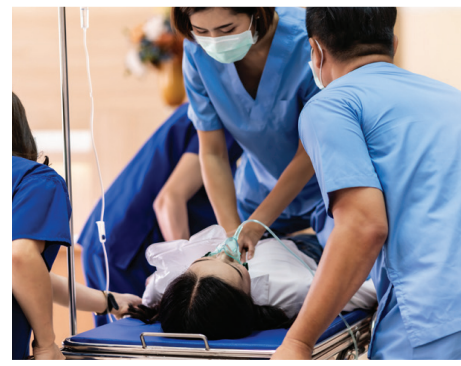About Us:

Penn State Health is a multi-hospital health system serving patients and communities across central Pennsylvania. We are the only medical facility in Pennsylvania to be accredited as a Level I pediatric trauma center and Level I adult trauma center. The system includes Penn State Health Milton S. Hershey Medical Center, Penn State Health Children's Hospital, and Penn State Cancer Institute based in Hershey, Pa.; Penn State Health Hampden Medical Center in Enola, Pa.; Penn State Health Holy Spirit Medical Center in Camp Hill, Pa.; Penn State Health St. Joseph Medical Center in Reading, Pa.; Penn State Health Lancaster Pediatric Center in Lancaster, Pa.; Penn State Health Lancaster Medical Center (opening fall 2022); and more than 3,000 physicians and direct care providers at more than 126 outpatient practices in 94 locations. Additionally, the system jointly operates various health care providers, including Penn State Health Rehabilitation Hospital, Hershey Outpatient Surgery Center, Hershey Endoscopy Center, Horizon Home Healthcare and the Pennsylvania Psychiatric Institute.

We foster a collaborative environment rich with diversity, share a passion for patient care, and have a space for those who share our spark of innovative research interests. Our health system is expanding and we have opportunities in both academic hospital as well community hospital settings.

Benefit highlights include:

- Competitive salary with sign-on bonus
- Comprehensive benefits and retirement package
- Relocation assistance & CME allowance
- Attractive neighborhoods in scenic central Pa.



PennState Health

FOR MORE INFORMATION PLEASE CONTACT:
Heather Peffley, PHR CPRP - Penn State Health Lead Physician Recruiter
hpeffley@pennstatehealth.psu.edu

Penn State Health is fundamentally committed to the diversity of our faculty and staff. We believe diversity is unapologetically expressing itself through every person's perspectives and lived experiences. We are an equal opportunity and affirmative action employer. All qualified applicants will receive consideration for employment without regard to age, color, disability, gender identity or expression, marital status, national or ethnic origin, political affiliation, race, religion, sex (including pregnancy), sexual orientation, veteran status, and family medical or genetic information.

Clinical Practice and Cases in Emergency Medicine

Indexed in PubMed and full text in PubMed Central

Rick A. McPheeters, DO, Editor-in-Chief
Kern Medical/UCLA- Bakersfield, California

R. Gentry Wilkerson, MD, Deputy Editor
University of Maryland School of Medicine

Mark I. Langdorf, MD, MHPE, Senior Associate Editor
University of California, Irvine School of Medicine- Irvine, California

Shahram Lotfipour, MD, MPH, Senior Associate Editor
University of California, Irvine School of Medicine- Irvine, California

Shadi Lahham, MD, MS, Associate Editor
Kaiser Permanente- Orange County, California

Manish Amin, DO, Associate Editor
Kern Medical/UCLA- Bakersfield, California

John Ashurst, DO, Decision Editor/ ACOEP Guest Editor
Kingman Regional Health Network, Arizona

Anna McFarlin, MD, Decision Editor
Louisiana State University Health Science Center- New Orleans, Louisiana

Lev Libet, MD, Decision Editor
Kern Medical/UCLA- Bakersfield, California

Christopher Sampson, MD, Decision Editor
University of Missouri- Columbia, Missouri

Joel Moll, MD, Decision Editor
Virginia Commonwealth University School of Medicine- Richmond, Virginia

Steven Walsh, MD, Decision Editor
Einstein Medical Center Philadelphia-Philadelphia, Pennsylvania

Melanie Heniff, MD, JD, Decision Editor
University of Indiana School of Medicine- Indianapolis, Indiana

Austin Smith, MD, Decision Editor
Vanderbilt University Medical Center-Nashville, Tennessee

Rachel A. Lindor, MD, JD, Decision Editor
Mayo Clinic College of Medicine and Science

Jacqueline K. Le, MD, Decision Editor
Desert Regional Medical Center

Christopher San Miguel, MD, Decision Editor
Ohio State University Wexner Medical Center

Editorial Board

Amin A. Kazzi, MD, MAAEM
The American University of Beirut, Beirut, Lebanon

Barry E. Brenner, MD, MPH
Case Western Reserve University

Brent King, MD, MMM
University of Texas, Houston

Daniel J. Dire, MD
University of Texas Health Sciences Center San Antonio

Edward Michelson, MD
Texas Tech University

Edward Panacek, MD, MPH
University of South Alabama

Erik D. Barton, MD, MBA
Icahn School of Medicine, Mount Sinai, New York

Francesco Dellacorte, MD
Azienda Ospedaliera Universitaria "Maggiore della Carità," Novara, Italy

Gayle Galletta, MD
Sorlandet Sykehus HF, Akershus Universitetssykehus, Lorenskog, Norway

Hjalti Björnsson, MD
Icelandic Society of Emergency Medicine

Leslie Zun, MD, MBA
Chicago Medical School

Linda S. Murphy, MLIS
University of California, Irvine School of Medicine Librarian

Niels K. Rathlev, MD
Tufts University School of Medicine

Pablo Aguilera Fuenzalida, MD
Pontificia Universidad Católica de Chile, Región Metropolitana, Chile

Peter A. Bell, DO, MBA
Baptist Health Science University

Peter Sokolove, MD
University of California, San Francisco

Robert Suter, DO, MHA
UT Southwestern Medical Center

Robert W. Derlet, MD
University of California, Davis

Scott Rudkin, MD, MBA
University of California, Irvine

Scott Zeller, MD
University of California, Riverside

Steven Gabaeff, MD
Clinical Forensic Medicine

Steven H. Lim, MD
Changi General Hospital, Simei, Singapore

Vijay Gautam, MBBS
University of London, London, England

Wirachin Hoonpongsimanont, MD, MSBATS
Siriraj Hospital, Mahidol University, Bangkok, Thailand

Advisory Board

Amal Khalil, MBA
UC Irvine Health School of Medicine

Elena Lopez-Gusman, JD
California ACEP American College of Emergency Physicians

DeAnna McNett, CAE
American College of Osteopathic Emergency Physicians

John B. Christensen, MD
California Chapter Division of AAEM

Randy Young, MD
California ACEP American College of Emergency Physicians

Mark I. Langdorf, MD, MHPE
UC Irvine Health School of Medicine

Jorge Fernandez, MD
California ACEP American College of Emergency Physicians University of California, San Diego

Peter A. Bell, DO, MBA
American College of Osteopathic Emergency Physicians Baptist Health Science University

Robert Suter, DO, MHA
American College of Osteopathic Emergency Physicians UT Southwestern Medical Center

Shahram Lotfipour, MD, MPH
UC Irvine Health School of Medicine

Brian Potts, MD, MBA
California Chapter Division of AAEM Alta Bates Summit-Berkeley Campus

Editorial Staff

Isabelle Nepomuceno, BS
Executive Editorial Director

Visha Bajaria, BS
CPC-EM Editorial Director

Emily Kane, MA
CPC-EM Editorial Director

Stephanie Burmeister, MLIS
CPC-EM Staff Liaison

Cassandra Saucedo, MS
Executive Publishing Director

Nicole Valenzi, BA
CPC-EM Publishing Director

June Casey, BA
Copy Editor

Official Journal of the California Chapter of the American College of Emergency Physicians, the American College of Osteopathic Emergency Physicians, and the California Chapter of the American Academy of Emergency Medicine



Available in MEDLINE, PubMed, PubMed Central, Google Scholar, eScholarship, DOAJ, and OASPA.

Editorial and Publishing Office: *WestJEM*/Department of Emergency Medicine, UC Irvine Health, 3800 W. Chapman Ave. Suite 3200, Orange, CA 92868, USA

Office: 1-714-456-6389; Email: Editor@westjem.org

Clinical Practice and Cases in Emergency Medicine

Indexed in PubMed and full text in PubMed Central

This open access publication would not be possible without the generous and continual financial support of our society sponsors, department and chapter subscribers.

Professional Society Sponsors

AMERICAN COLLEGE OF OSTEOPATHIC EMERGENCY PHYSICIANS
CALIFORNIA ACEP

CALIFORNIA CHAPTER DIVISION OF
AMERICAN ACADEMY OF EMERGENCY MEDICINE

Academic Department of Emergency Medicine Subscribers

Albany Medical College Albany, NY	INTEGRIS Health Oklahoma City, OK	Robert Wood Johnson University Hospital New Brunswick, NJ	University of Florida, Jacksonville Jacksonville, FL
American University of Beirut Beirut, Lebanon	Kaweah Delta Health Care District Visalia, CA	Rush University Medical Center Chicago, IL	University of Illinois at Chicago Chicago, IL
Arrowhead Regional Medical Center Colton, CA	Kennedy University Hospitals Turnersville, NJ	Southern Illinois University Carbondale, IL	University of Illinois College of Medicine Peoria, IL
Augusta University Augusta GA	Kern Medical Bakersfield, CA	St. Luke's University Health Network Bethlehem, PA	University of Iowa Iowa City, IA
Baystate Medical Center Springfield, MA	Lakeland HealthCare St. Joseph, MI	Stanford/Kaiser Emergency Medicine Residency Program Stanford, CA	University of Louisville Louisville, KY
Beaumont Hospital Royal Oak, MI	Lehigh Valley Hospital and Health Network Allentown, PA	Staten Island University Hospital Staten Island, NY	University of Maryland Baltimore, MD
Beth Israel Deaconess Medical Center Boston, MA	Loma Linda University Medical Center Loma Linda, CA	SUNY Upstate Medical University Syracuse, NY	University of Michigan Ann Arbor, MI
Boston Medical Center Boston, MA	Louisiana State University Health Sciences Center New Orleans, LA	Temple University Philadelphia, PA	University of Missouri, Columbia Columbia, MO
Brigham and Women's Hospital Boston, MA	Madigan Army Medical Center Tacoma, WA	Texas Tech University Health Sciences Center El Paso, TX	University of Nebraska Medical Center Omaha, NE
Brown University Providence, RI	Maimonides Medical Center Brooklyn, NY	University of Alabama, Birmingham Birmingham, AL	University of South Alabama Mobile, AL
Carl R. Darnall Army Medical Center Fort Hood, TX	Maricopa Medical Center Phoenix, AZ	University of Arkansas for Medical Sciences Little Rock, AR	University of Southern California/Keck School of Medicine Los Angeles, CA
Conemaugh Memorial Medical Center Johnstown, PA	Massachusetts General Hospital Boston, MA	University of California, Davis Medical Center Sacramento, CA	University of Tennessee, Memphis Memphis, TN
Desert Regional Medical Center Palm Springs, CA	Mayo Clinic College of Medicine Rochester, MN	University of California Irvine Orange, CA	University of Texas, Houston Houston, TX
Doctors Hospital/Ohio Health Columbus, OH	Mt. Sinai Medical Center Miami Beach, FL	University of California, Los Angeles Los Angeles, CA	University of Texas Health San Antonio, TX
Eastern Virginia Medical School Norfolk, VA	North Shore University Hospital Manhasset, NY	University of California, San Diego La Jolla, CA	University of Warwick Library Coventry, United Kingdom
Einstein Healthcare Network Philadelphia, PA	Northwestern Medical Group Chicago, IL	University of California, San Francisco San Francisco, CA	University of Washington Seattle, WA
Emory University Atlanta, GA	Ohio State University Medical Center Columbus, OH	UCSF Fresno Center Fresno, CA	University of Wisconsin Hospitals and Clinics Madison, WI
Genesys Regional Medical Center Grand Blanc, Michigan	Ohio Valley Medical Center Wheeling, WV	University of Chicago, Chicago, IL	Wake Forest University Winston-Salem, NC
Hartford Hospital Hartford, CT	Oregon Health and Science University Portland, OR	University of Colorado, Denver Denver, CO	Wright State University Dayton, OH
Hennepin County Medical Center Minneapolis, MN	Penn State Milton S. Hershey Medical Center Hershey, PA	University of Florida Gainesville, FL	
Henry Ford Hospital Detroit, MI	Presence Resurrection Medical Center Chicago, IL		

State Chapter Subscribers

ARIZONA CHAPTER DIVISION OF THE
AMERICAN ACADEMY OF EMERGENCY MEDICINE
CALIFORNIA CHAPTER DIVISION OF THE
AMERICAN ACADEMY OF EMERGENCY MEDICINE
FLORIDA CHAPTER DIVISION OF THE
AMERICAN ACADEMY OF EMERGENCY MEDICINE

GREAT LAKES CHAPTER DIVISION OF THE
AMERICAN ACADEMY OF EMERGENCY MEDICINE
TENNESSEE CHAPTER DIVISION OF THE
AMERICAN ACADEMY OF EMERGENCY MEDICINE

UNIFORMED SERVICES CHAPTER DIVISION OF THE
AMERICAN ACADEMY OF EMERGENCY MEDICINE
VIRGINIA CHAPTER DIVISION OF THE
AMERICAN ACADEMY OF EMERGENCY MEDICINE

International Society Partners

EMERGENCY MEDICINE ASSOCIATION OF TURKEY
LEBANESE ACADEMY OF EMERGENCY MEDICINE
MEDITERRANEAN ACADEMY OF EMERGENCY MEDICINE

NORWEGIAN SOCIETY FOR EMERGENCY MEDICINE
SOCIEDAD ARGENTINA DE EMERGENCIAS

SOCIEDAD CHILENA MEDICINA URGENCIA
THAI ASSOCIATION FOR EMERGENCY MEDICINE

To become a *WestJEM* departmental sponsor, waive article processing fee, receive print and copies for all faculty and electronic for faculty/residents, and free CME and faculty/fellow position advertisement space, please go to <http://westjem.com/subscribe> or contact:

Stephanie Burmeister
WestJEM Staff Liaison
Phone: 1-800-884-2236
Email: sales@westjem.org

JOURNAL FOCUS

Clinical Practice and Cases in Emergency Medicine (CPC-EM) is a MEDLINE-indexed internationally recognized journal affiliated with the *Western Journal of Emergency Medicine* (WestJEM). It offers the latest in patient care case reports, images in the field of emergency medicine and state of the art clinicopathological and medicolegal cases. CPC-EM is fully open-access, peer reviewed, well indexed and available anywhere with an internet connection. CPC-EM encourages submissions from junior authors, established faculty, and residents of established and developing emergency medicine programs throughout the world.

Table of Contents

- 42 **A Case Report of Unilateral Syphilitic Uveitis: A Diagnostic Challenge and the Role of Point-of-care Ultrasound**
Susana Gutierrez-Luke, Thijs Wolf, Kyle Green, Philip Graber
- 46 **Cerebral Air Embolism After Endoscopy: A Case Report**
James Whall, Eli Besser, Jaymes Lonzanida, Ryan Roten
- 49 **Diagnosis and Management of *Amanita Phalloides* Toxicity in the Emergency Department Observation Unit: A Case Report**
Matthew Tobias, Mary McGoldrick, Mary Rometti, Jessica Laub, Grant Wei, Denise Fernandez
- 53 **Lithium Toxicity: A Case Report of Toxicity Resulting in a Third-degree Heart Block**
Samantha L. Gaetani, Alexandra M. Amaducci, Derek Fikse, Andrew L. Koons
- 57 **Median Arcuate Ligament Syndrome in 17-year-old Male with Abdominal Pain: Case Report**
Jessica Doctor, Jonathan Henderson
- 60 **Septic Arthritis of the Sternoclavicular Joint**
George V. Koshy, Richard Davis, Christopher Wilson
- 64 **Spontaneously Conceived Ruptured Heterotopic Pregnancy Presenting with Chest Pain and Dyspnea: A Case Report**
Farrah Nasrollah, Kevin Cao, Janae Hohbein, Wesley Eilbert
- 69 **Ultrasound-Guided, Mid-Forearm Median Nerve Block for Relief of Carpal Tunnel Syndrome Pain in the Emergency Department: A Case Report**
Daniel L. Puebla, Ilya Luchitsky, Roman Montes De Oca, Michael Shalaby, Robert A. Farrow II
- Images in Emergency Medicine**
- 72 **A Case of Perforating Folliculitis in a Peritoneal Dialysis Patient**
Glenn Goodwin, Katherine L. O'Neil, Megan Dekok, Moshe Bengio, Philip O. Scumpia, Abhishek Roka, Alexander J. Scumpia
- 74 **Insidious Manifestations of Cutaneous T-cell Lymphoma**
Alexis L. Cates, Heather P. Kahn
- 77 **Man Presenting After Hydrochloric Acid Ingestion**
Emma R. Furlano, Gregory P. Wu, Brendan Vosburgh, Cameron R. Waldman, Jessica Noonan, Alexander Bracey

Policies for peer review, author instructions, conflicts of interest and human and animal subjects protections can be found online at www.westjem.com.

JOURNAL FOCUS

Clinical Practice and Cases in Emergency Medicine (CPC-EM) is a MEDLINE-indexed internationally recognized journal affiliated with the *Western Journal of Emergency Medicine* (WestJEM). It offers the latest in patient care case reports, images in the field of emergency medicine and state of the art clinicopathological and medicolegal cases. CPC-EM is fully open-access, peer reviewed, well indexed and available anywhere with an internet connection. CPC-EM encourages submissions from junior authors, established faculty, and residents of established and developing emergency medicine programs throughout the world.

Table of Contents *continued*

Letter to the Editor

80 Caution Regarding Self-reported Tramadol Dependence

James Dunford, Aaron Schneir

81 Buprenorphine for High-dose Tramadol Dependence: A Case Report of Successful Outpatient Treatment

Leslie Mukau, Kadia Wormley, Christian Tomaszewski, Bushra Ahmad, Rais Vohra, Andrew A. Herring

Policies for peer review, author instructions, conflicts of interest and human and animal subjects protections can be found online at www.westjem.com.

CPC*EM* Clinical
Practice
& Cases

CALL FOR CPC-EM SECTION EDITORS!

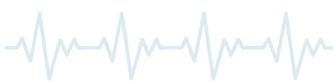- Medical-Legal Case Reports
- Case Reports/Images in
Emergency Medicine

**Send your CV and letter of interest to
editor@cpcem.org**

**Clinical Practice and Cases in
Emergency Medicine (CPC*EM*) is
now indexed on Scopus – Elsevier's
Abstract and Citation Database!**



CPC*EM* Clinical
Practice
& Cases



PubMed[®]

Also indexed in PubMed and PubMed Central

Call for Section Editors

- Behavioral Emergencies
- Cardiac Care
- Geriatrics
- Musculoskeletal
- Trauma
- Toxicology
- Legal Medicine

WestJEM Integrating Emergency Care
with Population Health
westjem.org

Send CV and letter of interest to
Editor@WestJEM.org

CALL FOR REVIEWERS!

WestJEM Integrating Emergency Care
with Population Health
westjem.org

CPCEM Clinical
Practice
& Cases

Send CV and letter of interest to
editor@cpcem.org

Aortic Thrombus with Bilateral Renal Infarcts: A Case Report

Lev Libet, MD Kern Medical, Department of Emergency Medicine, Bakersfield, California

Section Editors: R. Gentry Wilkerson, MD

Submission history: Submitted February 24, 2023; Revision received September 20, 2023; Accepted October 9, 2023

Electronically published January 23, 2024

Full text available through open access at http://escholarship.org/uc/uciem_westjem

DOI: 10.5811/cpcem.60031

Introduction: The presence of a hypercoagulable state predisposes to venous and arterial thrombi. While the relationship between protein C and S deficiencies with venous thrombus formation is clear, the relationship to arterial thrombi formation is less common. Thromboembolic disease of the renal arteries may result in renal infarction. The development of simultaneous bilateral renal infarction is rare and can lead to significant morbidity and mortality.

Case Report: This is a case of a 48-year-old male with known protein C deficiency who presented to the emergency department with sudden onset abdominal pain. A computed tomography angiogram of the abdomen showed bilateral renal infarctions. The patient required significant analgesia and developed acute kidney injury. He was treated conservatively, and dialysis was not required.

Conclusion: There are no reports in the emergency medicine literature of bilateral renal infarction secondary to protein C and S deficiency. Prompt evaluation with definitive imaging is necessary for patients who are at high risk for arterial thrombi and present with symptoms suggestive of the diagnosis. [Clin Pract Cases Emerg Med. 2024;8(1)1–4.]

Keywords: *thrombophilias; protein C deficiency; protein S deficiency; renal infarction.*

INTRODUCTION

Abdominal pain is a common emergency department (ED) complaint comprising 7–10% of all ED visits. Renal artery infarction is a rare cause of abdominal pain. While the most common cause of renal artery infarction is cardiogenic, 6.6% are due to a hypercoagulable state.¹ Protein C and S deficiencies are clearly linked with venous thromboembolism with a 5–7 fold increase in risk compared with the general population. Arterial thromboembolic manifestations are less common, affecting 6% of those with protein C deficiency.² Renal infarction carries significant morbidity depending on the severity of associated acute kidney injury. In one case series of 44 patients published in 2004, there was a 30-day mortality of 11.4% associated with renal infarction in patients with atrial fibrillation.³ We describe a case of a patient with known protein C deficiency who presented with abdominal pain secondary to bilateral renal infarctions.

CASE REPORT

A 48-year-old male presented to the ED with sudden onset abdominal pain commencing 45 minutes prior to arrival. The

pain was described as sharp, non-radiating, and severe and was poorly localized. He had no shortness of breath or chest pain and denied any fevers. He had a history of protein C deficiency with prior arterial thrombi including a chronic aortic thrombus for which he was prescribed warfarin. The patient's past medical history was also significant for hypertension, and he was known to be non-compliant with his medications. He previously underwent a right iliofemoral embolectomy, bilateral above knee amputations, and placement of an abdominal infrarenal aortoiliac stent graft. He reported regular use of tobacco, cannabis, and methamphetamines.

On examination he was afebrile, with a heart rate of 98 beats per minute, respiratory rate of 22 breaths per minute, and blood pressure of 189/108 millimeters of mercury. He was in severe distress secondary to his abdominal pain, diaphoretic, and moaning. His abdomen was soft and diffusely tender without guarding or rebound.

Laboratory evaluation was remarkable for white blood cell count 23×10^3 per microliter (μL) (reference range: $4.5\text{--}11.0 \times 10^3/\mu\text{L}$), hemoglobin 15.5 grams per deciliter

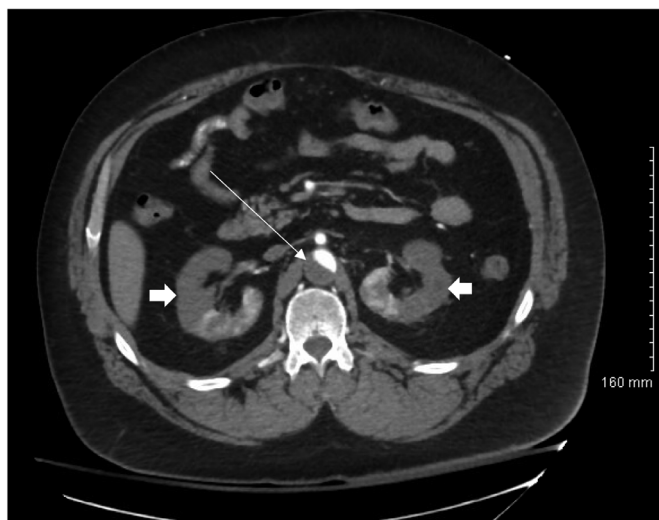

Image 1. Computed tomography angiogram abdomen in axial plane showing aortic thrombus (thin arrow) and renal cortical hypodensities (thick arrows).

(g/dL) (13.8–17.2 g/dL), international normalized ratio of 1.02 (<1.1), lactic acid 2.8 millimoles per liter (mmol/L) (0.5–2.2 mmol/L), bicarbonate of 17 milliequivalents (mEq)/dL (22–29 mEq/dL), normal anion gap, and creatinine of 2.13 milligrams (mg)/dL (0.67–1.17 mg/dL) with the patient's baseline creatinine 1.14 mg/dL. Computed tomography (CT)

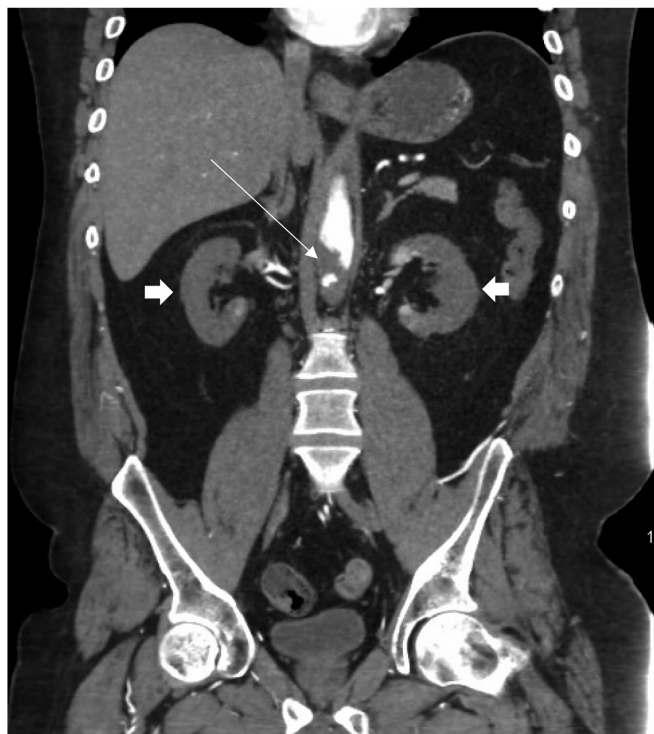

Image 2. Computed tomography angiogram of abdomen in coronal plane showing aortic thrombus (thin arrow) and hypodense renal cortices (thick arrows).

Population Health Research Capsule

What do we already know about this clinical entity?

Renal artery infarction is an uncommon presentation of abdominal pain in the emergency department.

What makes this presentation of disease reportable?

A presentation of acute abdominal pain secondary to bilateral renal artery infarction in the setting of protein C and S deficiencies has not been previously reported in the EM literature.

What is the major learning point?

Protein C and S deficiencies predispose to arterial thrombi and a sufficient index of suspicion is prudent.

How might this improve emergency medicine practice?

Elevate the suspicion for renal artery infarction in those presenting with abdominal pain and a hypercoagulable state.

angiogram of the abdomen and pelvis showed significant thrombus burden from the suprarenal aorta down to the femoral arteries, with near complete occlusion at the level of the renal arteries. Hypodensities of the renal cortices bilaterally indicating bilateral renal infarcts were also noted (**Images 1–3**).

While in the ED, the patient required several doses of hydromorphone, and a dose of sub-dissociative ketamine. Vascular surgery and interventional radiology were consulted, and both recommended against surgical or endovascular intervention citing questionable benefit with significant risk. Anticoagulation with a heparin infusion was started, and the patient was admitted to the intensive care unit. During the patient's hospitalization protein S deficiency was also diagnosed. The elevated lactic acid normalized by the following day, and his creatinine peaked at 5.28 mg/dL on day 5 of hospitalization. He did not require dialysis and was discharged on day seven of hospitalization.

DISCUSSION

Bilateral renal infarction is a rare etiology of abdominal pain. From a sample of all ED visits, the incidence of diagnosed renal infarction is 0.004%.⁴ Of these, the presence of bilateral infarctions is even more uncommon making up

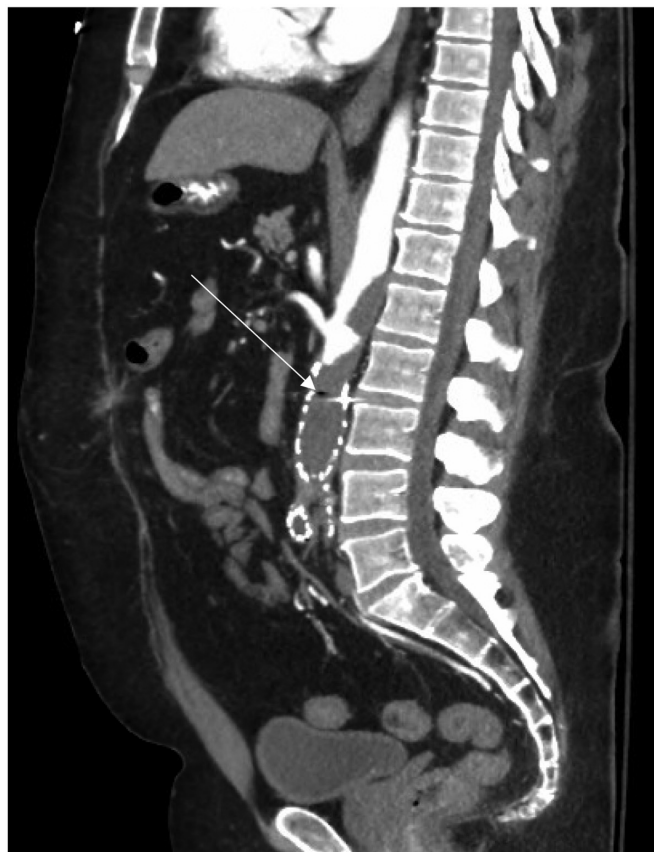

Image 3. Computed tomography angiogram abdomen in sagittal plane showing degree of clot burden within aortic stent graft (thin arrow).

only 4.5–20% of renal infarction cases.³ Oh et al noted 16.9% had bilateral involvement. Thrombophilias increase the risk of thromboembolism as compared with the general population; however, the highest risk emboli are secondary to cardiogenic sources.^{1,4} Most patients with renal infarction present more than 24 hours after the onset, and the majority have generalized abdominal or flank pain.⁵ Many have nausea and vomiting, and 16% have fever.⁵ Our patient presented with severe, abrupt generalized abdominal pain and arrived to the ED within 45 minutes of onset.

Protein C is a vitamin K-dependent proenzyme produced by the liver that activates when bound to thrombin. The activated form is creatively called activated protein C (APC). Protein S is a glycoprotein, also produced in the liver, which acts as a cofactor for protein C. Together APC and protein S participate integrally in the endogenous anticoagulation system mostly via proteolysis of factors V and VIII. Protein C deficiency affects 0.2–0.5% of the population, with clinically significant protein C deficiency being present in only 1 in 20,000 individuals. The association between protein C deficiency and venous thromboembolism (VTE) is well established with a 7-fold increase in risk; however, arterial

thromboembolism may be present in only 6% of those with protein C deficiency.² The prevalence of protein S deficiency is less clear in part because the laboratory testing is more difficult to interpret. As with protein C deficiency, protein S deficiency is also associated with VTE. The hazard ratio for development of arterial thrombi is 6.9% and 4.6% for protein C deficiency and protein S deficiency, respectively.¹¹

Our patient was at higher risk for complications with his known aortic thrombus and the presence of previously placed endovascular stent coupled with his noncompliance with anticoagulation. The patient's acute abdominal pain was likely due to new renal infarcts and less likely related to sudden occlusion of the infrarenal aorta and iliac arteries. The presence of aortic thrombus in the setting of protein C deficiency has previously been described.^{6–8} Kulahcioglu et al described the only other case we found of bilateral renal infarcts in a patient with protein C deficiency.⁹

While others have noted bilateral renal artery involvement in those with hypercoagulable states in the form of case series, this is the first case to be reported in the emergency medicine literature.^{1,3} In our case the patient suffered acute kidney injury but did not require hemodialysis. The incidence of renal dysfunction associated with renal infarcts is between 5–19%, with 2.1–9.1% requiring hemodialysis.^{1,3} In the studies summarizing a heterogeneous group with renal infarction, the mortality is between 5–10.2%.^{1,3} Further research will more fully describe the risk of renal infarction in the setting of protein C and protein S deficiencies and the resulting clinical effects.

CONCLUSION

Renal infarction is an important consideration in acute, sudden onset abdominal pain. While arterial thromboembolism is uncommon, the morbidity is significant, and the possibility must be considered in at-risk patients.

The Institutional Review Board approval has been documented and filed for publication of this case report.

Address for Correspondence: Lev Libet, MD, Kern Medical, Department of Emergency Medicine, 1700 Mt. Vernon Ave., Bakersfield, CA 93306. Email: Lev.Libet@kernmedical.com

Conflicts of Interest: By the WestJEM article submission agreement, all authors are required to disclose all affiliations, funding sources and financial or management relationships that could be perceived as potential sources of bias. No author has professional or financial relationships with any companies that are relevant to this study. There are no conflicts of interest or sources of funding to declare.

Copyright: © 2024 Libet This is an open access article distributed in accordance with the terms of the Creative Commons Attribution (CC BY 4.0) License. See: <http://creativecommons.org/licenses/by/4.0/>

REFERENCES

1. Oh YK, Yang CW, Kim YL, et al. Clinical characteristics and outcomes of renal infarction. *Am J Kidney Dis*. 2016;67(2):243–50.
2. Tormene D, Noventa F, Campello E, et al. The risk of arterial thrombosis in carriers of natural coagulation inhibitors: a prospective family cohort study. *Intern Emerg Med*. 2021;16(4):997–1003.
3. Hazanov N, Somin M, Attali M, et al. Acute renal embolism. Forty-four cases of renal infarction in patients with atrial fibrillation. *Medicine (Baltimore)*. 2004;83(5):292–9.
4. Huang CC, Lo HC, Huang HH, et al. ED presentations of acute renal infarction. *Am J Emerg Med*. 2007;25(2):164–9.
5. Antopolsky M, Simanovsky N, Stalnikowicz R, et al. Renal infarction in the ED: 10-year experience and review of the literature. *Am J Emerg Med*. 2012;30(7):1055–60.
6. Onwuanyi A, Sachdeva R, Hamirani K, et al. Multiple aortic thrombi associated with protein C and S deficiency. *Mayo Clin Proc*. 2001;76(3):319–22.
7. Ueda K, Morishita E, Shiraki H, et al. Aortic mural thrombus associated with congenital protein C deficiency in an elderly patient. *J Atheroscler Thromb*. 2020;27(1):100–3.
8. Hamza M, Sabir Khan H, Arshad A, et al. Mesenteric ischemia due to thrombosis involving the aorta, celiac artery, and superior mesenteric artery in a young female with protein C deficiency. *Cureus*. 2019;11(11):e6151.
9. Kulahcioglu S, Ayturk M, Sari M. Multiple thrombotic sources and embolic events at arterial sites in a patient with protein-C deficiency. *Blood Coagul Fibrinolysis*. 2021;32(8):607–10.
10. Boekholdt SM and Kramer MH. Arterial thrombosis and the role of thrombophilia. *Semin Thromb Hemost*. 2007;33(6):588–96.
11. Mahmoodi BK, Brouwer JL, Veeger NJ, et al. Hereditary deficiency of protein C or protein S confers increased risk of arterial thromboembolic events at a young age: results from a large family cohort study. *Circulation*. 2008;118(16):1659–67.

Case Report: Pediatric Thyroid Storm Presenting to the Emergency Department with Afebrile Seizure

Daniel J. Klein, MD
Emily Rose, MD

Los Angeles General Medical Center, Keck School of Medicine of the University of Southern California, Department of Emergency Medicine, Los Angeles, California

Section Editor: Austin Smith, MD

Submission history: Submitted May 15, 2023; Revision received October 25, 2023; Accepted November 2, 2023

Electronically published January 23, 2024

Full text available through open access at http://escholarship.org/uc/uciem_cpccem

DOI: [10.5811/cpcem.1359](https://doi.org/10.5811/cpcem.1359)

Introduction: Seizures are a common presenting complaint and account for approximately 1% of total emergency department (ED) visits. Seizures are especially common in children less than five years old as they have a lower seizure threshold as compared to adults. One potentially dangerous etiology that is far less common, especially in children, is thyroid storm, the extreme manifestation of hyperthyroidism.

Case Report: We describe the case of a 3-year-old girl who presented to the ED with an afebrile seizure but was found to be in thyroid storm. This case should serve as a reminder for emergency physicians to consider thyroid disease when evaluating patients presenting with seizures.

Conclusion: Although most pediatric seizures are self-limited and frequently benign, it is imperative that the emergency physician evaluate for and rule out any potentially associated dangerous conditions such as thyroid storm. [Clin Pract Cases Emerg Med. 2024;8(1)5–8.]

Keywords: *thyroid storm; pediatric afebrile seizure; thyrotoxicosis; emergency medicine; case report.*

INTRODUCTION

Seizures are a common presenting complaint and account for approximately 1% of total emergency department (ED) visits¹; they are common in young children.² While febrile seizures are more common, affecting 2–5% of children, approximately 1% of children <14 years in age have had one afebrile seizure.^{2,3} The differential diagnosis of a first-time afebrile seizure is broad, including both benign and life-threatening etiologies.⁴ One less common but potentially life-threatening cause of seizures is thyroid storm. Thyroid storm is the extreme manifestation of hyperthyroidism and brings with it a mortality rate between 7–30%.^{2,5–7} As such, it is an important consideration in patients of all ages presenting to the ED with seizures, but especially important for pediatric patients, as early diagnosis and treatment will decrease the overall incidence of morbidity and mortality. This case demonstrates a rare presentation of Graves disease in the ED in a young patient with thyroid storm as the cause of her first afebrile seizure.

CASE REPORT

A female aged two years and 11 months was brought to the ED by ambulance for a generalized tonic-clonic first-time seizure. The patient had otherwise been in her usual state of health with no recent febrile illnesses. Her mother noted that the patient had an acute episode of unresponsiveness with a blank stare and called 9–1–1. Upon emergency medical services arrival, the child developed generalized tonic-clonic seizure activity. She received a weight-based dose of 1.7 milligrams (mg) of midazolam en route to the hospital, which resolved the movements. Upon arrival to the hospital, the child was no longer actively seizing and appeared to be sleepy, consistent with a postictal state. The estimated total seizure length was approximately two minutes. The patient had no notable past medical history. Family history was notable for Graves disease in the patient's mother.

Vital signs on arrival were as follows: temperature 37.9° Celsius measured rectally; heart rate 188 beats per minute; respiratory rate 27 breaths per minute; and blood pressure

125/62 millimeters of mercury. Her height was 103 centimeters, 99th percentile, and her weight was 16 kilograms, 87th percentile. Her physical exam was notable for exophthalmos (Image 1) and small goiter (Image 2) but was otherwise unremarkable, including a non-focal neurological examination. Of note, her tachycardia and widened pulse pressure persisted after resolution of her seizure and postictal period.

Her electrocardiogram was notable for left ventricular hypertrophy and sinus tachycardia but had no evidence of ischemia or abnormal intervals. Her laboratory evaluation was notable for a normal fingerstick blood glucose, elevated alkaline phosphatase with mild transaminitis, mild microcytic anemia, undetectably low thyroid-stimulating hormone (TSH) and unmeasurably high free thyroxine.

The pediatric endocrinologist was consulted who, based on the patient's weight, recommended starting atenolol 12.5 mg, methimazole 7.5 mg, and 1 milliliter (mL) potassium iodide-iodine (Lugol's saturated solution of potassium iodide {SSKI} solution (to be given one hour after atenolol and methimazole). After treatment was initiated, the patient's heart rate improved to the 160s, and she was admitted to the pediatric intensive care unit (PICU). While in the PICU, further levels were obtained and were notable for unmeasurably high free triiodothyronine (T3), unmeasurably high total T3, and elevated thyroid-stimulating immunoglobulins (328% baseline). While in the PICU, the patient was continued on atenolol, methimazole, Lugol's solution, and hydrocortisone 50 mg every eight hours. She was in the PICU for approximately 24 hours and then transferred to the medical ward.

The patient remained in the hospital for one week and was discharged home with methimazole, propranolol, and SSKI. She was followed in endocrinology clinic multiple times over the next few months. The SSKI was eventually stopped, and propranolol was changed to atenolol. She had trouble with

compliance with medications as the formulations available for atenolol are not child friendly. She was referred to another hospital system for a total thyroidectomy given inability to tolerate swallowing pills. She has not had recurrent seizure activity since initiating thyroid treatment.

Population Health Research Capsule

What do we already know about this clinical entity?

Thyroid storm is a potentially life-threatening condition that can cause seizures as well as multiorgan failure.

What makes this presentation of disease reportable?

Seizures are common in young children, but thyroid storm/thyrotoxicosis as an etiology is not.

What is the major learning point?

Thyroid storm should be considered for any patient with a new-onset afebrile seizure, especially those with exophthalmos, a palpable goiter, and family history.

How might this improve emergency medicine practice?

By increasing awareness of this rare condition clinicians will be more able to diagnose and treat it before irreversible organ dysfunction occurs.

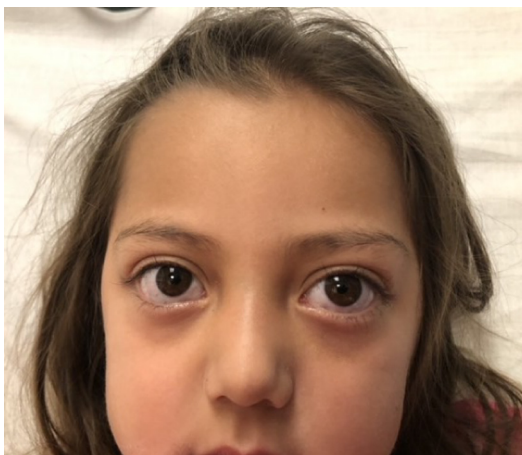

Image 1. Exophthalmos noted in a pediatric patient with Graves disease.

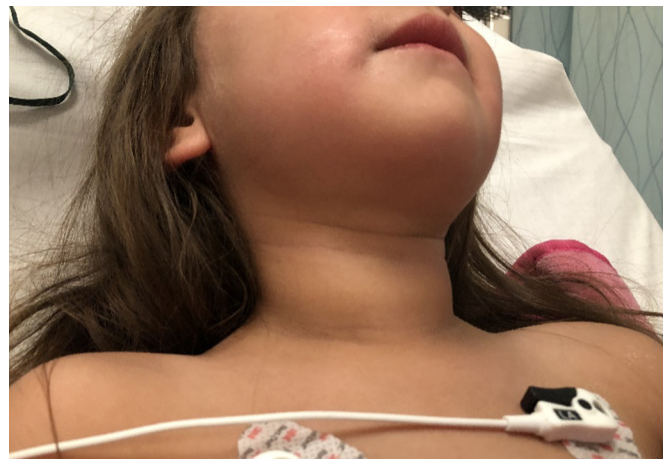

Image 2. Palpable goiter noted in a pediatric patient with Graves disease.

DISCUSSION

Graves disease is uncommon in young children, and seizure is a rare presentation of thyrotoxicosis secondary to this disease. Hyperthyroidism is the state of having higher than normal levels of circulating thyroid hormone; this disorder can present sub-clinically or profoundly symptomatic. Symptomatic patients are commonly considered to have thyrotoxicosis, although the terms thyrotoxicosis and hyperthyroidism are sometimes used interchangeably.⁸ Hyperthyroidism/thyrotoxicosis has a case rate of 1–14 cases/100,000 patient-years in children under 17, with Graves disease being the most common cause.^{9–12} Graves disease also appears to be increasing in incidence when compared to the last 20–30 years and affects females more frequently than males in a 3–4:1 ratio.^{9,11} Graves disease is the result of TSH receptor stimulation by thyrotropin receptor antibodies causing increased thyroid hormone production and release.^{2,10–13}

While Graves disease is the most common cause of thyroid storm, diagnosing thyroid storm itself can be difficult.^{5,6} Thyroid storm, the extreme manifestation of thyrotoxicosis, is a life-threatening condition that results in multiorgan dysfunction.^{5–7,13} All systems can be affected, and patients commonly demonstrate some combination of the following: central nervous system (CNS) alteration; cardiac manifestations including tachycardia, other arrhythmias, and sometimes congestive heart failure and cardiovascular collapse; and gastrointestinal symptoms such as vomiting, diarrhea, and hepatic failure.^{5,6,11} There are no universally accepted criteria or validated clinical tools to confirm the diagnosis of thyroid storm. Two decision tools used in adults are the Burch-Wartofsky point scale (BWPS)¹⁴ and the Japanese Thyroid Association (JTA)¹⁵ diagnostic criteria. The BWPS, which was developed in 1993, assigns points based on level of organ dysfunction with scores >45 suggestive of thyroid storm, between 25–45 suggestive of impending storm, and scores <25 unlikely to be thyroid storm. The JTA, developed in 2012, requires thyrotoxicosis to be present (the BWPS does not incorporate thyroid studies) and evaluates for the presence of organ dysfunction. The JTA suggests thyroid storm based on a combination of systems involved rather than the severity of symptoms. Notably, seizures are included in the BWPS but not in the JTA. Given the rarity of pediatric thyroid storm, these decision tools were developed in adult populations and their extrapolation to pediatric populations must be done with caution.

Thyroid storm can affect the CNS in several ways including restlessness, agitation, lethargy, delirium, psychosis, seizures, and coma.^{5,6,14} However, it is worth noting that seizures in the setting of thyroid storm are relatively uncommon; this is likely why seizure is not included in the JTA diagnostic criteria.^{10,13} Some animal studies suggest that thyroid hormone can lower the seizure

threshold.¹³ Thyroid storm is a well-known cause for developing hyperthermia, which leads to a decreased seizure threshold in children. Given that the seizure threshold for children is already lower than that for adults, these factors likely further exacerbate the risk of seizing. Pediatric patients may be more likely to have seizures in the setting of thyroid storm.¹⁰

CONCLUSION

Thyroid storm is an uncommon illness with high mortality; thus, emergency physicians must make this diagnosis and initiate treatment promptly. Thyroid storm should be considered in an altered and tachycardic patient and should be considered in the differential diagnosis for a child presenting with seizure. Early diagnosis and treatment reduce the incidence of morbidity and mortality. A detailed physical exam evaluating for exophthalmos and goiter, family history, and careful attention to vital sign abnormalities that persist after resolution of the seizure can facilitate making this critical diagnosis.

Patient consent has been obtained and filed for the publication of this case report.

Address for Correspondence: Daniel J. Klein, MD, Los Angeles General Medical Center, Keck School of Medicine of the University of Southern California, Department of Emergency Medicine, 1200 North State Street, GNH 1060K, Los Angeles, CA 90033. Email: Daniel.klein3@med.usc.edu

Conflicts of Interest: By the CPC-EM article submission agreement, all authors are required to disclose all affiliations, funding sources and financial or management relationships that could be perceived as potential sources of bias. The authors disclosed none.

Copyright: © 2024 Klein et al. This is an open access article distributed in accordance with the terms of the Creative Commons Attribution (CC BY 4.0) License. See: <http://creativecommons.org/licenses/by/4.0/>

REFERENCES

- Pallin DJ, Goldstein JN, Moussally JS, et al. Seizure visits in US emergency departments: epidemiology and potential disparities in care. *Int J Emerg Med.* Jun 2008;1(2):97–105.
- Rose E (ed.). *Pediatric Emergencies: A Practical, Clinical Guide.* Oxford, UK: Oxford University Press, 2021.
- Patterson JL, Carapetian SA, Hageman JR, Kelley KR. Febrile seizures. *Pediatr Ann.* 2013;42(12):249–54.
- Santillanes G and Luc Q. Emergency department management of seizures in pediatric patients. *Pediatr Emerg Med Pract.* 2015;12(3):1–25; quiz 26–7.
- Angell TE, Lechner MG, Nguyen CT, et al. Clinical features and hospital outcomes in thyroid storm: a retrospective cohort study. *J Clin Endocrinol Metab.* 2015;100(2):451–9.

6. Chiha M, Samarasinghe S, Kabaker AS. Thyroid storm: an updated review. *J Intensive Care Med.* 2015;30(3):131–40.
7. Galindo RJ, Hurtado CR, Pasquel FJ, et al. National trends in incidence, mortality, and clinical outcomes of patients hospitalized for thyrotoxicosis with and without thyroid storm in the United States, 2004-2013. *Thyroid.* 2019;29(1):36–43.
8. Rosen P, Marx JA, Hockberger RS, et al. *Rosen's Emergency Medicine: Concepts and Clinical Practice.* 8th ed. Philadelphia, PA: Elsevier/Saunders; 2014.
9. Kaplowitz PB and Vaidyanathan P. Update on pediatric hyperthyroidism. *Curr Opin Endocrinol Diabetes Obes.* 2020;27(1):70–6.
10. Ladd JM, Sabsabi B, von Oettingen JE. Thyroid storm in a toddler presenting as a febrile seizure. *Pediatrics.* 2020;145(2):e20191920.
11. Niedziela M. Hyperthyroidism in adolescents. *Endocr Connect.* 2021;10(11):R279–92.
12. Song A, Kim SJ, Kim MS, et al. Long-term antithyroid drug treatment of Graves disease in children and adolescents: a 20-year single-center experience. *Front Endocrinol (Lausanne).* 2021;12:687834.
13. Lee HS and Hwang JS. Seizure and encephalopathy associated with thyroid storm in children. *J Child Neurol.* 2011;26(4):526–8.
14. Burch HB and Wartofsky L. Life-threatening thyrotoxicosis. Thyroid storm. *Endocrinol Metab Clin North Am.* 1993;22(2):263–77.
15. Akamizu T, Satoh T, Isozaki O, et al. Diagnostic criteria, clinical features, and incidence of thyroid storm based on nationwide surveys. *Thyroid.* 2012;22(7):661–79.

Complications of Bacterial Keratitis Impacted by Social Determinants of Health: A Case Report

Taylor Diederich, MD
Mary Velagapudi, DO, BSN
Hope Ring, MD

Department of Emergency Medicine, University of Kansas Medical Center,
University of Kansas Health System, Kansas City, Kansas

Section Editor: Rachel Lindor, MD, JD

Submission history: Submitted August 7, 2023; Revision received November 17, 2023; Accepted November 20, 2023

Electronically published January 25, 2024

Full text available through open access at http://escholarship.org/uc/uciem_cpccem

DOI: [10.5811/cpcem.1594](https://doi.org/10.5811/cpcem.1594)

Introduction: The emergency department commonly evaluates eye pain and vision loss. Typically, these conditions can be managed outpatient; however, delays can lead to advanced pathology.

Case Report: A 48-year-old homeless male presented with left-eye vision loss and pain. His exam revealed monocular decreased visual acuity, corneal ulcer, and hypopyon. The patient was diagnosed with bacterial keratitis and admitted for treatment but left against medical advice. He returned and was admitted for further treatment but was lost to follow-up thereafter.

Conclusion: Our case features complicated bacterial keratitis with several treatment interruptions, demonstrating how healthcare disparities contribute to potentially preventable advanced pathology. [Clin Pract Cases Emerg Med. 2024;8(1)9–13.]

Keywords: *keratitis; vision loss; hypopyon; corneal ulcer; pain.*

INTRODUCTION

Ophthalmologic complaints are common in the emergency department (ED).¹ Pain and vision loss are among the most common chief complaints. Although eye infections are commonplace, advanced bacterial disease is uncommon.² In this report, we discuss the case of a man who suffered infectious bacterial keratitis but delayed presentation to care until the presence of a severe corneal ulcer with hypopyon threatened his vision. We speculate that his delay in presentation was complicated by use of contact lenses, medication theft, and barriers imposed by healthcare disparities.

CASE REPORT

A 48-year-old homeless male presented to the ED with left-eye vision loss and pain. The patient described the gradual onset of these symptoms over three weeks, causing him to stop wearing his contact lenses two weeks prior to presentation. The patient endorsed a similar problem in the past that resolved with the use of eye drops. He also noted that the center of his eye had begun to appear white. The

patient denied fever, chills, nausea, vomiting, and headache. Upon initial evaluation, the patient demonstrated 20/25 vision bilaterally, 20/30 vision in his right eye, and only finger counting at approximately two feet in his left eye. Extraocular movements were intact; intraocular pressures were 13 millimeters of mercury (mm Hg) in the right and 24 mm Hg in the left (reference range 10–21 mm Hg).³ Bilateral pupils were reactive to light without afferent pupillary defect. By visual examination, the patient demonstrated prominent conjunctival injection, a 4 mm × 4 mm round corneal ulcer in the three o'clock position of the cornea, and a hypopyon covering one third of the anterior chamber with a line of sediment covering one half the anterior chamber (reaching a height of five mm). On fluorescein staining, the corneal ulcer appeared yellow without any other dye uptake or Seidel sign (Image 1).

Computed tomography (CT) of the orbits demonstrated asymmetric decrease in volume and enhancement along the left anterior chamber, without evidence of posterior inflammation or retrobulbar abscess. Ophthalmology was

consulted but could not attain a dilated retinal exam on the left due to overlying anterior chamber opacity. B-scan ultrasound was performed without evidence of endophthalmitis. Ophthalmology collected corneal cultures, and the patient was admitted for monitoring and administering topical vancomycin, tobramycin, and atropine drops. Unfortunately, the patient left against medical advice (AMA) two days later; he stated that this choice was due to difficulty with his insurance. The corneal culture collected on admission ultimately grew *Staphylococcus epidermidis* with resistance to clindamycin and erythromycin.

The patient returned five days later due to concern for worsening symptoms. He reported good compliance to his vancomycin drops six times per day and tobramycin drops twice daily. He demonstrated 20/20 vision in his right eye but only hand motions with light perception in his left eye, which was worse than his first exam. Extraocular movements remained intact. Pupils were reactive to light bilaterally without afferent pupillary defect. Visual examination yielded continued conjunctival injection, enlarged 6 mm x 4 mm round corneal ulcer at three o'clock, and similar hypopyon covering one third to one half of the anterior chamber (*Image 2*).

Ophthalmology was consulted, and corneal cultures were re-collected. He was admitted for continued vancomycin, tobramycin, and atropine drops. Repeat corneal cultures grew *Cutibacterium acnes* and *Psychrobacter faecalis/pulmonis*. The patient remained inpatient for six days with improved sight and pain control. At this point, he was noted to show a reduction in the size of the hypopyon and severity of the ulcer (*Image 3*).

He was then discharged to continue vancomycin and atropine drops for one week and follow up with ophthalmology. Unfortunately, the patient returned to the ED six days after discharge reporting that his medications had been stolen from him; he was provided with refills and discharged from the ED.

Population Health Research Capsule

What do we already know about this clinical entity?

Bacterial keratitis is an ophthalmologic infection; if untreated it can progress to complications, some of which cause permanent vision loss.

What makes this presentation of disease reportable?

Emergency Department eye complaints are common. Understanding of complications and the ways that health disparities affect outcomes is important for physicians.

What is the major learning point?

Treatment of bacterial keratitis is paramount to prevention of life-altering complications. Social factors can strongly influence disease course and management.

How might this improve emergency medicine practice?

Emergency physicians must understand serious implications of bacterial keratitis and must consider social barriers to care.

DISCUSSION

Infectious keratitis is defined as an infection of the cornea, which is the anterior-most layer of the eye. These infections can be due to bacteria, viruses, fungi, and protozoa; they are commonly polymicrobial. Most causes of infectious keratitis are bacterial, *Pseudomonas* and *Staphylococci* species being most common.^{4,5} Of note, *Staphylococcus* and

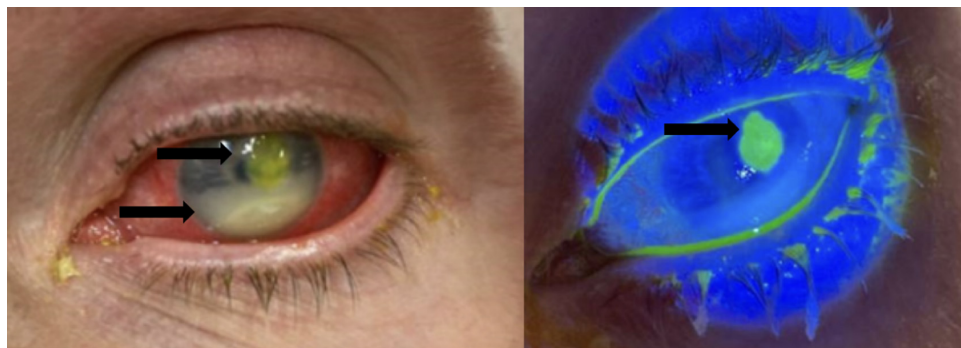


Image 1. Left eye on initial presentation under normal lighting (left) and Woods lamp (right), demonstrating conjunctival injection, hypopyon, and fluorescein-stained paracentral corneal ulcer. Top arrow in the left image points to fluorescein-stained corneal ulcer, while the bottom arrow in the left image points to hypopyon. The arrow in the right image points to fluorescein-stained corneal ulcer.

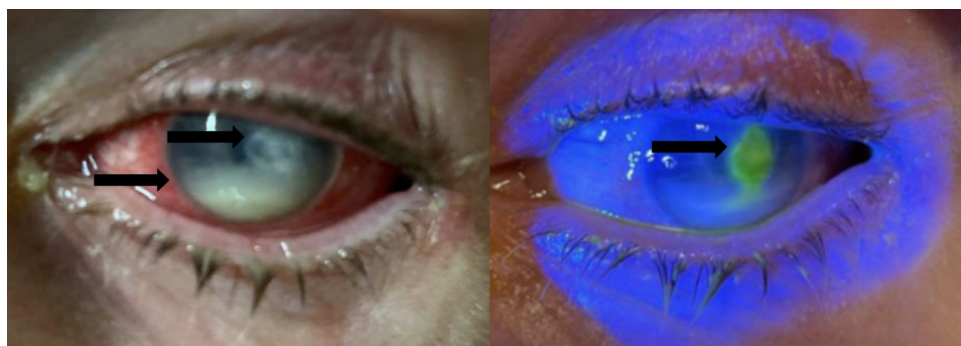

Image 2. Left eye on second emergency department presentation under normal lighting prior to fluorescein staining (left) and under Woods lamp after fluorescein administration (right), demonstrating conjunctival injection, hypopyon, and paracentral corneal ulcer with fluorescein uptake. Top arrow in the left image points to unstained corneal ulcer, while the bottom arrow in the left image points to hypopyon. The arrow in the right image points to fluorescein-stained corneal ulcer.

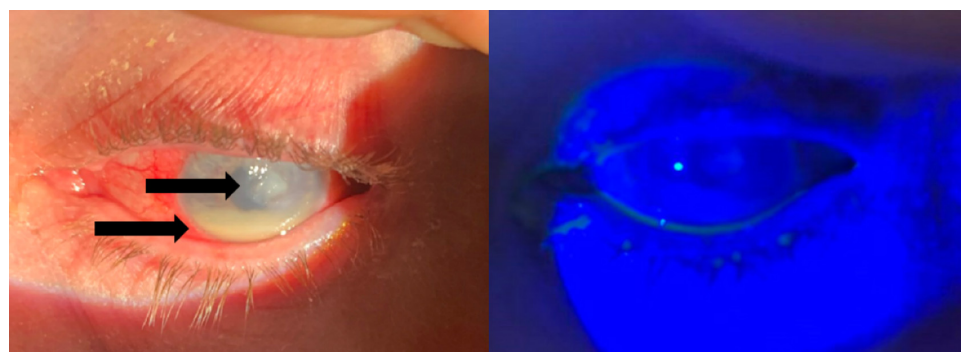


Image 3. Left eye on the day of discharge under normal lighting prior to fluorescein staining (left) and under Woods lamp after fluorescein administration (right), demonstrating conjunctival injection, reduction in the size of hypopyon, and paracentral corneal ulcer without fluorescein uptake under Woods lamp. The top arrow in the left image points to an unstained corneal ulcer, while the bottom arrow in the left image points to hypopyon.

Streptococcus are considered normal flora of the eye, but are also possible culprits.⁶ Patient typically present within 24 hours of infectious keratitis development, complaining of eye pain, photophobia, and vision changes. Although diagnosis of the culpable organism can be made by corneal culture, this is not typically considered necessary.

Although readily treatable, infectious keratitis can progress to more serious complications. These complications include corneal scarring, corneal anesthesia, perforation, secondary glaucoma, hyphema, hemorrhage, lens subluxation, anterior subcapsular cataract, corneal fistula, scleritis, retinal detachment, choroidal detachment, endophthalmitis, panophthalmitis, keratectasia, atrophic bulbi, autoevisceration, and retrobulbar abscess.^{4–8} Corneal ulcer—thinning and compromised integrity of the cornea—can occur with severe infectious keratitis. Clinically, one may distinguish ulceration from keratitis by fluorescein uptake. When severe, it may lead to corneal perforation.⁸

Hypopyon, on the other hand, may occur with or without accompanying ulceration in the setting of infectious keratitis

and involves layering of inflammatory cell milieu in the anterior chamber.⁸ This appears clinically as an opaque, white layer within the bottom of the anterior chamber. This is typically visualized easily on physical exam, with better definition via slit lamp.

Another rare albeit serious complication of infectious keratitis is endophthalmitis—infection of the anterior and posterior chambers without spreading exteriorly (ie, no scleral involvement). This typically occurs in advanced keratitis leading to corneal perforation, and it may progress rapidly.^{5,7–9} Panophthalmitis is an extension of infection to sclera and exterior eye structures, such as the eyelid. This can be an especially severe complication since the appearance mimics cellulitis; thus, underlying infection is more difficult to detect. Exam findings can include chemosis, proptosis, and eyelid edema. These are probably the most serious potential complications in that they may lead to permanent vision loss without rapid treatment.⁹ In 2022, Zeng et al demonstrated a progression rate of 9.46% from bacterial keratitis with hypopyon to endophthalmitis; in this study, a hypopyon of

greater than 3 mm was found to demonstrate a 4.12 odds ratio of eventual endophthalmitis.¹⁰

Even when treated appropriately and complications do not occur, the scarring associated with central or paracentral infection can cause substantial loss of vision.⁵ Workup of suspected infectious keratitis and its associated complications initially involves slit lamp exam, measurement of intraocular pressure (IOP), and fluorescein staining.⁵ These measures should be sufficient to diagnose and initiate appropriate treatment for infectious keratitis, corneal ulceration, corneal perforation, and hypopyon. If concern exists for corneal ulcer, perforation, or posterior spread of infection, ophthalmology should be consulted. When endophthalmitis, panophthalmitis, or retrobulbar abscess are suspected, imaging with ultrasound and/or CT of the orbits is indicated. Clinical factors that may raise suspicion for these entities include sepsis, preceding intraocular surgery, and penetrating trauma; unfortunately, the symptoms and presenting signs overlap significantly with the above alternative diagnoses; therefore, one must keep a high index of suspicion.^{5,9} Regarding retrobulbar abscess, proptosis and/or increased IOP should raise a red flag to prompt further imaging.

Contact lens use is a major cause of bacterial keratitis.^{2,4-6,8,11} Various factors contribute, including prolonged lens use, inadequate cleaning, using tap water as a cleaning agent, contaminated solution, and contact lens trauma.⁵ Our patient's history of substance use and homelessness may have negatively impacted his hygiene.

Initial antibiotic therapy, as in our patient, includes a dual-agent topical regimen (vancomycin and tobramycin). Other options include monotherapy with a fourth-generation fluoroquinolone.⁴⁻⁶ Cycloplegics are also indicated for pain control as they prevent ciliary muscle constriction.^{5,6,8} Hourly administration of eye drops is necessary for the first 24–48 hours.^{6,8} Daily eye examinations are indicated for a minimum of three days, and treatment typically continues for at least two weeks.⁶ Since there were concerns about our patient's ability to follow up on an outpatient basis, he was admitted for six days; however, most individuals may seek outpatient care for the entirety of their course.

The prognosis of bacterial keratitis is governed by a multitude of factors. Ulcer confinement superficial to the middle third of the stroma, which is the corneal layer between the outer and inner epithelia, portends a favorable prognosis. Deeper ulcers and those involving visual axis, stromal melt, and corneal thinning tend to fare worse. Treatment and follow-up access and adherence also play into overall prognosis.⁸

In 2021, Ting et al found poor visual outcomes with delayed healing correlated to the following risk factors at presentation: age >50 years; infiltrate size greater than 3 mm; and reduced visual acuity.¹¹ Our patient demonstrated two of these risk factors, in addition to the unstudied but likely substantial risk factors of homelessness, inability to pursue

outpatient follow-up, and inability to comply with outpatient medical therapy. Notable complications revealed in this retrospective review included glaucoma, recurrent infection, loss of vision, corneal perforation, and enucleation; 16.3% of patients in this population were found to require surgical intervention.¹¹

In this case, social factors adversely affected this patient's course. The patient presented at an advanced stage of bacterial keratitis, with complications compromising his vision. Homelessness and poor access to healthcare likely weighed heavily into the decisions made by these physicians. For example, physicians favored admission, whereas outpatient management might have otherwise been pursued. In cases such as these, emergency clinicians must also ask themselves how they can address the driving forces. As one example, might this patient have benefited from housing resources, given the theft of his medications on the street? We must remember it is within our scope to connect patients to social resources and make moves within the system to make preventative care more accessible to underserved patients.

CONCLUSION

Bacterial keratitis is a significant cause for vision loss. This presentation with corneal ulcer, hypopyon, and compromised visual acuity starkly demonstrates the adverse effects of healthcare disparities. Our patient presented to care with advanced pathology and went on to fail inpatient and outpatient therapy, putting him at risk for further life-altering complications. One can envision the interplay of improper contact lens care, homelessness, and poor healthcare access contributing to his complications. It reinforces the importance of the ED's role in making this diagnosis and escalating care. We are also the primary point of contact for vulnerable individuals; thus, we must address healthcare disparities as they relate to the acute presentation and ongoing underlying threat to our patients' health.

Patient consent has been obtained and filed for the publication of this case report.

Address for Correspondence: Taylor Diederich, MD, University of Kansas Medical Center, University of Kansas Health System, Department of Emergency Medicine, 3901 Rainbow Blvd, MS 1045, Kansas City, KS 66160. Email: tdaniel4@kumc.edu

Conflicts of Interest: By the *CPC-EM* article submission agreement, all authors are required to disclose all affiliations, funding sources and financial or management relationships that could be perceived as potential sources of bias. The authors disclosed none.

Copyright: © 2024 Diederich et al. This is an open access article distributed in accordance with the terms of the Creative Commons Attribution (CC BY 4.0) License. See: <http://creativecommons.org/licenses/by/4.0/>

REFERENCES

1. Channa R, Zafar SN, Canner JK, et al. Epidemiology of eye-related emergency department visits. *JAMA Ophthalmol*. 2016;134(3):312–9.
2. Alipour F, Khareshi S, Soleimanzadeh M, et al. Contact lens-related complications: a review. *J Ophthalmic Vis Res*. 2017;12(2):193–204.
3. Boyd K. Eye Pressure Testing. American Academy of Ophthalmology. 2022. Available at: <https://www.aao.org/eye-health/tips-prevention/eye-pressure-testing>. Accessed October 29, 2023.
4. Otri AM, Fares U, Al-Aqaba MA, et al. Profile of sight-threatening infectious keratitis: a prospective study. *Acta Ophthalmol*. 2013;91(7):643–51.
5. Lin A, Rhee MK, Akpek EK, et al. Bacterial keratitis preferred practice pattern. *Ophthalmology*. 2019;126(1):1–55.
6. Soong HK, Hood CT, DeLoss KS. Complications of contact lenses. *UpToDate*. 2023. Available at: <https://www.uptodate.com/contents/complications-of-contact-lenses>. Accessed October 29, 2023.
7. Al-Mujaini A, Al-Kharusi N, Thakral A, et al. Bacterial keratitis: perspective on epidemiology, clinico-pathogenesis, diagnosis and treatment. *Sultan Qaboos Univ Med J*. 2009;9(2):184–95.
8. Gurnani B and Kaur K. Bacterial keratitis. In: *StatPearls*. 2023. Available at: <https://www.ncbi.nlm.nih.gov/books/NBK574509/>. Accessed October 29, 2023.
9. Sheu SJ. Endophthalmitis. *Korean J Ophthalmol*. 2017;31(4):283–9.
10. Zeng F, Sun Y, Ning N, et al. Risk factors and microbiological characteristics: from bacterial keratitis with hypopyon to keratitis-related endophthalmitis. *Graefe's Arch Clin Exp Ophthalmol*. 2022;260(9):3019–25.
11. Ting DSJ, Cairns J, Gopal BP, et al. Risk factors, clinical outcomes, and prognostic factors of bacterial keratitis: the Nottingham Infectious Keratitis Study. *Front Med (Lausanne)*. 2021;8:715118.

Delayed Onset of Symptoms After a Rattlesnake Bite in a Renal Transplant Patient: A Case Report

Thomas A. Rogers, MD
John Herrick, DO

Christus Spohn Health System, Department of Emergency Medicine, Corpus Christi, Texas

Section Editor: Steven Walsh, MD

Submission history: Submitted April 3, 2023; Revision received August 30, 2023; Accepted September 21, 2023

Electronically published December 6, 2023

Full text available through open access at http://escholarship.org/uc/uciem_cpce

DOI: [10.5811/cpcem.1280](https://doi.org/10.5811/cpcem.1280)

Introduction: The United States is home to two major families of venomous snakes, Crotalids and Elapids. The Crotalid family, also known as pit vipers, is well known for being among the most frequent causes of snakebites reported. Crotalid envenomation can present with local findings, hematologic toxicity, and systemic toxicity. Identification of envenomated patients is key to determining who needs antivenom. Most sources recommend an observation period of six to eight hours after the snakebite to determine whether the bite was “dry” or the patient was exposed to venom.

Case Report: We present the case of a 33-year-old patient with a history of renal transplantation who had delayed onset of symptoms of envenomation 18 hours after an initial emergency department observation. The patient did well after a course of antivenom and was discharged on hospital day three.

Conclusion: The patient’s immunosuppressive regimen may have delayed the onset of clinical symptoms, thus delaying treatment. To the best of our knowledge, this is the first case reported of a patient presenting with a delayed onset of initial snakebite envenomation symptoms. [Clin Pract Cases Emerg Med. 2024;8(1)14–17.]

Keywords: *case report; envenomation; transplant; immunosuppression; snakebite.*

INTRODUCTION

Venomous North American snakes come from two families: Elapidae and Viperidae, the latter of which can be divided into two subfamilies: Crotalinae and Viperinae. Snakes from the Crotalinae subfamily are those that are found in North America, whereas snakes from Viperinae are found in Europe, Asia, and Africa.¹ The Crotalid family of snakes includes three genera: *Crotalus* and *Sistrurus* (rattlesnakes), as well as *Agkistrodon* (water moccasins and copperheads).¹ Reported cases of venomous snakebites in the United States range from 5,000–10,000 cases per year.^{1,2} Crotalinae envenomation syndromes present with three major categories of symptoms: local swelling, hematologic toxicity, and systemic toxicity.³ Local reactions include swelling at the bite site, which can progress to hemorrhagic bleb formation and spreading of the swelling proximal to the bite. Hematologic toxicity is generally due to

hypofibrinogenemia and thrombocytopenia.⁴ Systemic toxicity is the shock state that may occur at any point in the hours after envenomation.

Treatment of these bites starts with the basics of trauma care and resuscitation. Assuming the patient is asymptomatic, the common teaching is to observe the patient for six to eight hours after the bite with a full laboratory workup and physical exam repeated during the observation time frame.⁵ Of all patients who are bitten, however, approximately 80% will require antivenom, which in the US is either ANAVIP or CroFab.⁵ Cases of delayed hematologic complications are described in the literature after antivenom administration, but delayed presentation of envenomation is less well described.⁶ We present the case of a patient with a history of a renal transplant who presented with delayed onset of symptoms of envenomation after initial emergency department (ED) observation.

CASE REPORT

A 33-year-old male patient with a past medical history of hypertension, type II diabetes mellitus, and renal transplant presented to an outside ED at approximately 7 PM, one hour after suffering a rattlesnake bite to his right third digit. The patient reported that he was prescribed tacrolimus 10 milligrams (mg) daily and prednisone 10 mg daily for rejection prophylaxis. His initial vital signs were within normal limits. Laboratory workup showed a prothrombin time of 10.4 seconds (s) (reference range 11–13.5 s), international normalized ratio 1.0 (reference range 0.8–1.1), a fibrinogen of 240 mg per deciliter (dL) (200–400 mg/dL), and platelets of 192,000 per microliter (μL) (150,000–450,000/ μL). The patient received three doses of hydromorphone intravenous (IV) injection for pain control and underwent serial measurements of his digit across the span of his seven-hour observation recommended by the Unified Treatment Guidelines for snakebites.⁵

Laboratory workup was repeated at 9:15 PM, and values were unchanged from his initial measurements aside from a fibrinogen of 183 mg/dL; however lab tests were not repeated immediately prior to discharge. The initial emergency physician administered 1 mg ceftriaxone and discharged the patient with a prescription for oral analgesia and an antibiotic at 1 AM. The documentation at the time of discharge noted that the patient's pain was under control and that his finger had no evidence of injury aside from the puncture wound.

At 11 AM later that day, the patient presented to a second ED with complaints of significant swelling and discoloration of his right arm. The physician documentation at that time was that the third digit of his right hand appeared necrotic. His workup at that time was significant for platelets of 69,000 per μL and an INR of 2.1. The patient was started on five vials of CroFab antivenom and was transferred to our facility at 1 PM. On arrival to our facility, the patient was noted to have a PT of 22.9s and INR of 2.4 and his platelets had rapidly improved to 203,000/ μL . In consultation with the South Texas Poison Control Network, the emergency physician and admitting physician started the patient on maintenance dosing of antivenom with two vials every six hours and initiated laboratory monitoring until resolution of his coagulopathy. The admitting physician also started the patient on IV clindamycin 900 mg every eight hours. A timeline of the events of the patient's care is below (Figure 1).

He was then admitted to the general wards for two days. His coagulopathy and symptoms completely resolved by hospital day three. The patient was discharged home with primary care follow-up and a prescription for oral clindamycin and analgesia.

DISCUSSION

The most well-known treatment algorithms recommend an observation period of six to eight hours after the initial

Health Population Research Capsule

What do we already know about this issue?
To the best of our knowledge, this is the first instance of the occurrence of a delayed reaction to a snakebite in a renal transplant patient or any patient undergoing immunosuppression.

What was the research question?
The question in our case was, "Is there a physiological reason for patient's undergoing immunosuppression to have a delayed response to crotalid venom?"

What was the major finding of the study?
This case report found that the patient underwent an appropriate duration of observation at a rural emergency department but developed symptomatic envenomation from the bite approximately 18 hours later.

How does this improve population health?
This case is a reminder that immunosuppressed patients can have delayed onset of physical exam findings and may present differently in cases of acute envenomation. Furthermore, it is a reminder to involve specialists in the care of the majority of transplant patients presenting to the emergency department.

snakebite before discharge.⁵ Our patient underwent observation of approximately seven hours after the initial bite, and his only indication that he may have been envenomated was pain, which resolved prior to discharge. Serial measurements from his first ED visit were consistent and unchanging throughout his stay. The classic envenomation syndrome with swelling and coagulopathy occurred 18 hours after the bite, well outside the recommended window of observation. We believe this may have been an effect modulated by his immunosuppressive regimen of tacrolimus and prednisone. Snake venoms contain several enzymes meant to assist the animal in the capture and consumption of prey. One component, snake venom metalloproteinases, assists in tissue necrosis at the site of the bite by activating tumor necrosis factor, which in turn results in cytokine release, leukocyte migration, neutrophil recruitment and degranulation, and macrophage differentiation.^{1,3,4,7,8} Tacrolimus and prednisone are both

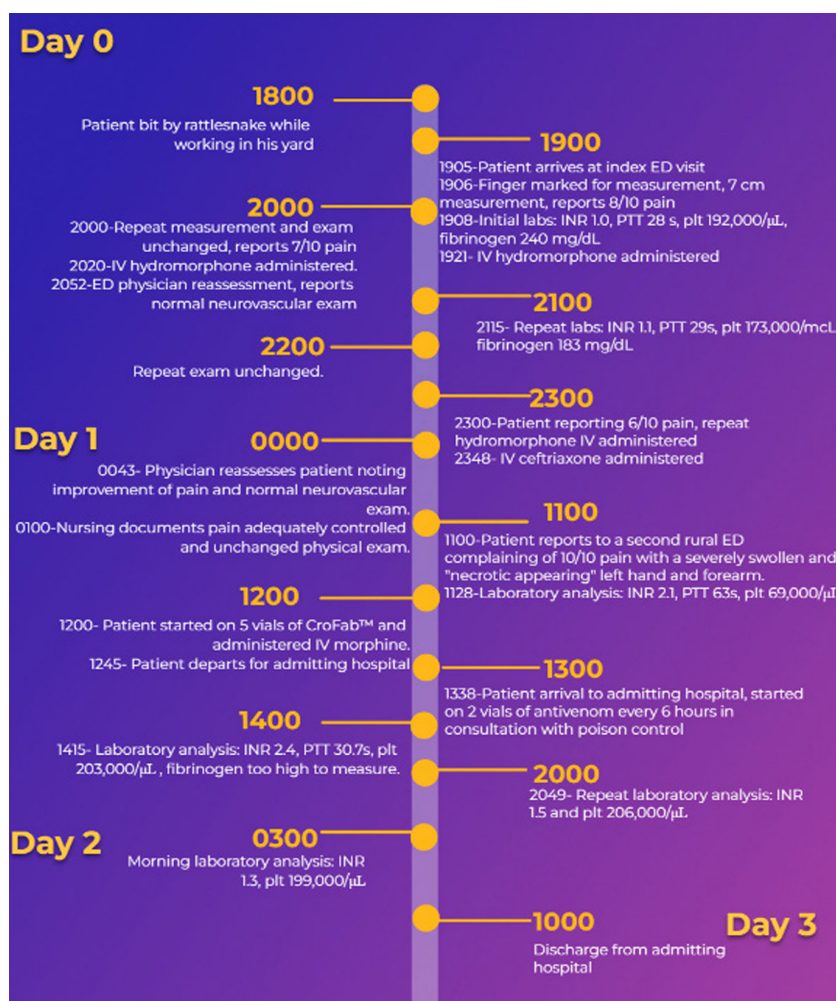


Figure 1. Timeline of the care and evaluation of an immunocompromised patient suffering a snakebite. IV, intravenous; INR, international normalized ratio; PTT, partial thromboplastin time; plt, platelets.

known to modulate inflammatory responses due to cytokine release and decrease the chances of acute rejection.^{9–11}

We theorize that these immunosuppressive effects may have blunted the physical exam findings of acute envenomation, resulting in a delayed presentation of our patient with envenomation syndrome. There are some limitations to this report. The most important of which is that this patient initially reported to two different, remote EDs, which are generally staffed by non-emergency medicine trained physicians. That being said, the documentation at that time suggests that the patient was asymptomatic and pain free at the time of discharge. We also contend that patients with immunosuppression syndromes should likely undergo prolonged observation due to the chance of delayed reactions to Crotalid envenomation.

CONCLUSION

We present the case of a young man who had delayed onset of rattlesnake envenomation syndrome after the traditional observation period in the ED. The patient had a

complicating medical history of renal transplantation, which may have caused his delayed presentation. The patient was discharged on hospital day three in good condition. To the best of our knowledge, this is one of the only cases of delayed presentation of a snakebite envenomation syndrome presented in the literature.

The authors attest that their institution requires neither Institutional Review Board approval, nor patient consent for publication of this case report. Documentation on file.

Address for Correspondence: Thomas A Rogers, MD, Christus Spohn Health System, Department of Emergency Medicine, 600 Elizabeth St, 9B/GME, Corpus Christi, TX 78404. Email: Thomas.rogers@christushealth.org

Conflicts of Interest: By the CPC-EM article submission agreement, all authors are required to disclose all affiliations, funding sources and financial or management relationships that could be perceived as potential sources of bias. The authors disclosed none.

Copyright: © 2024 Rogers et al. This is an open access article distributed in accordance with the terms of the Creative Commons Attribution (CC BY 4.0) License. See: <http://creativecommons.org/licenses/by/4.0/>

REFERENCES

1. Holstege CP, Miller MB, Wermuth M, et al. Crotalid snake envenomation. *Crit Care Clin*. 1997;13(4):889–921.
2. Greene S, Cheng D, Vilke GM, et al. How should native Crotalid envenomation be managed in the emergency department? *J Emerg Med*. 2021;61(1):41–48.
3. Warpinski GP and Ruha AM. North American envenomation syndromes. *Emerg Med Clin of North Am*. 2022;40(2):313–326.
4. Corbett B and Clark RF. North American snake envenomation. *Emerg Med Clin of North Am*. 2017;35(2):339–354.
5. Lavonas EJ, Ruha AM, Banner W, et al. Unified treatment algorithm for the management of crotaline snakebite in the United States: results of an evidence-informed consensus workshop. *BMC Emerg Med*. 2011;11(1):2.
6. Lavonas EJ, Schaeffer TH, Kokko J, et al. Crotaline Fab antivenom appears to be effective in cases of severe North American pit viper envenomation: an integrative review. *BMC Emerg Med*. 2009;9:13.
7. Teixeira C, Fernandes CM, Leiguez E, et al. Inflammation induced by platelet-activating viperid snake venoms: perspectives on thromboinflammation. *Front Immunol*. 2019;10:2082.
8. Sanhajariya S, Duffull SB, Isbister GK. Pharmacokinetics of snake venom. *Toxins (Basel)*. 2018;10(2):73.
9. Man Shrestha B. Two decades of tacrolimus in renal transplant: basic science and clinical evidences. *Exp Clin Transplant*. 2017;15(1):1–9.
10. Liu MC, Proud D, Lichtenstein LM, et al. Effects of prednisone on the cellular responses and release of cytokines and mediators after segmental allergen challenge of asthmatic subjects. *J Allergy Clin Immunol*. 2001;108(1):29–38.
11. Fujiwara N and Kobayashi K. Macrophages in inflammation. *Curr Drug Targets Inflamm Allergy*. 2005;4(3):281–286.

Isolated Laryngeal Angioedema in a Patient with Long-term ACE Inhibitor Use: A Case Report

Carney Flinn*
Inna Massaro, DO[†]

*Virginia Tech Carilion School of Medicine, Roanoke, Virginia
[†]Roanoke Memorial Hospital, Department of Emergency Medicine, Carilion Health System, Roanoke, Virginia

Section Editor: Steven Walsh, MD

Submission history: Submitted July 29, 2023; Revision received October 20, 2023; Accepted November 1, 2023

Electronically published January 23, 2024

Full text available through open access at http://escholarship.org/uc/uciem_cpem

DOI: [10.5811/cpcem.1565](https://doi.org/10.5811/cpcem.1565)

Introduction: Angiotensin converting enzyme (ACE) inhibitor-associated angioedema is the most common cause of angioedema seen in the emergency department (ED) and can be associated with a high morbidity. Most cases occur within months of initiation of an ACE inhibitor and are associated with facial and/or oropharyngeal swelling. We present a case of isolated laryngeal edema requiring intubation following 10 years of ACE inhibitor therapy.

Case Report: An 82-year-old female, who was on lisinopril therapy for 10 years, presented to the ED with shortness of breath and a sensation that her throat was swelling. She appeared to be in mild respiratory distress and could only speak in one-word sentences. On the physical exam, there was no swelling in the tongue, lips, or face, and the uvula was midline. There was mild posterior pharyngeal edema and swelling noted, but the airway was not visibly obstructed. She was tachypneic and stridor was present. After no improvement with medications, anesthesia successfully intubated her in the operating room. It was deemed a difficult airway secondary to posterior pharyngeal erythema and edema. She was diagnosed with ACE inhibitor-associated angioedema and was extubated four days later. Her lisinopril was discontinued, and she has not had a recurrence of angioedema.

Conclusion: ACE inhibitor-induced angioedema commonly presents with facial and oropharyngeal swelling. Its recognition, even years after starting an ACE inhibitor, is necessary to ensure swift and appropriate treatment of potentially life-threatening posterior pharyngeal edema. [Clin Pract Cases Emerg Med. 2024;8(1)18–21.]

Keywords: *angioedema; laryngeal edema; ACE inhibitor; case report.*

INTRODUCTION

Angioedema (AE), defined by non-dependent, non-pitting edema, is a potentially life-threatening condition, complicated by a compromised airway due to laryngeal edema. There are two main types: histamine mediated, and bradykinin mediated. In all types of AE, facial swelling, including the lips and the oral mucous membranes, is common. Histamine-mediated forms present similarly to anaphylaxis while the bradykinin-mediated forms typically present with greater face and oropharyngeal involvement with increased risk for progression and morbidity.^{1,2,3,4,5}

Angiotensin converting enzyme (ACE) inhibitors are the leading cause of drug-induced AE and commonly presents with swelling of the lips, tongue, or face.^{6,7} One study found 100% of participants with ACE inhibitor-related AE reported facial swelling.⁸ Swelling of the larynx, which has the potential to develop rapidly with life-threatening implications, was highest in ACE inhibitor-induced AE.⁸ Most cases typically occur within the first three months of therapy, although there is a recognized persistent risk of AE in patients taking an ACE inhibitor despite an uneventful initiation of treatment.^{2,9,10,11}

In previously documented cases of AE occurring after years of stable therapy, patients typically presented with facial and oropharyngeal swelling,^{6,7,9} although one case report in the internal medicine literature describes isolated posterior pharyngeal and supraglottic swelling while on ACE inhibitor therapy for one year.¹² The far more common AE presentation is facial and oropharyngeal swelling after one year of ACE inhibitor use.^{11,12} We present a case of isolated laryngeal AE following 10 years of ACE inhibitor therapy. This case features an atypical presentation of bradykinin-mediated AE and highlights the importance of a high index of suspicion and securing/maintaining an airway in patients with possible AE.

CASE REPORT

An 82-year-old female presented to the emergency department (ED) with a chief complaint of throat swelling and difficulty breathing with a past medical history including chronic obstructive pulmonary disease, lung cancer, congestive heart failure, dyslipidemia, diabetes mellitus type two, gastroesophageal reflux disease, hypertension, and hypothyroidism. Her outpatient medications included lisinopril 20 milligrams (mg), aspirin 81 mg, atenolol 25 mg, budesonide-formoterol 160–4.5 micrograms (mcg), hydrochlorothiazide 25 mg, insulin glargine 100 Units (U) per milliliter (mL), levothyroxine 100 mcg, metformin 500 mg, omeprazole 20 mg, and simvastatin 20 mg. The patient stated she awoke the same morning with an inability to swallow water or her own saliva because it felt like her throat was swelling. She'd had a very mild cough for the prior few days and a sore throat the night before, which resolved with acetaminophen. She stated she felt well before going to bed. She denied a history of anaphylaxis or allergic reactions.

On review of systems, the patient denied nausea, vomiting, fevers, or chills. Her vitals included a temperature of 36° Celsius, respiratory rate of 26 breaths per minute, oxygen saturation of 95% on room air, pulse rate of 93 beats per minute, and a blood pressure of 119/56 millimeters of mercury. Physical exam revealed the patient was alert, age-appropriate, and markedly anxious. She was spitting into a bag and speaking in single-word sentences. Her voice was not hoarse. Mild posterior pharyngeal edema and swelling was noted. The airway was not visibly obstructed; there was no tongue or lip swelling, and the uvula was midline and not enlarged. Her cardiovascular exam displayed a regular rate and rhythm. She was tachypneic, but breath sounds were normal in all lung fields; however, stridor was present. Her exam was otherwise unremarkable.

Lab values were as follows: complete blood count was within normal limits except for mild thrombocytopenia, complete metabolic panel showed an elevated carbon dioxide of 32 millimoles per liter (mmol/L) (reference range 21–31 mmol/L), elevated creatinine of 1.22 mg per deciliter (dL) (0.5–1.2 mg/dL), elevated urea nitrogen of 23 mg/dL

Population Health Research Capsule

What do we already know about this clinical entity?

Angiotensin converting enzyme (ACE) inhibitor-associated angioedema (AE) often occurs in initial months and is associated with facial and/or oropharyngeal swelling.

What makes this presentation of disease reportable?

In this atypical presentation, isolated laryngeal AE required intubation after 10 years of ACE inhibitor therapy.

What is the major learning point?

Recognizing AE, even years after a patient has started therapy, is necessary to ensure appropriate treatment of potential life-threatening posterior pharyngeal edema.

How might this improve emergency medicine practice?

ACE inhibitor-associated AE is the most common cause of drug-induced AE and can have high morbidity. Awareness of unusual presentations may be life-saving.

(6–20 mg/dL), and elevated blood glucose of 181 mg/dL (70–99 mg/dL). Additionally, her magnesium was low at 1.0 mg/dL (1.7–2.8 mg/dL). All other lab values including a venous blood gas, troponin, brain natriuretic peptide, creatine kinase, and lactate dehydrogenase were within normal levels. After nasal swabbing, no respiratory syncytial virus, influenza, adenovirus, human metapneumovirus, or rhinovirus were detected. No imaging was done initially.

Medications administered included racemic epinephrine 2.25% nebulized solution, methylprednisolone 125 mg intravenous (IV), famotidine 20 mg IV, and diphenhydramine 25 mg IV. Intramuscular epinephrine was withheld secondary to patient's coronary artery disease. Her symptomology did not improve following administration of medications, and her shortness of breath continued to worsen. The patient had been taking lisinopril for 10 years, and there was a strong clinical suspicion for upper airway compromise. After consult with general surgery and anesthesia, she was taken electively to the operating room (OR) for intubation.

The anesthesia team successfully intubated her after two attempts with a 7–0 endotracheal tube after bougie exchange.

It was deemed a difficult airway secondary to posterior pharyngeal edema. The epiglottis did not appear to be inflamed, but there was a pooling of secretions in the posterior pharynx. She was assigned an American Society of Anesthesiologists physical status classification of 4. The patient was successfully extubated four days later after the swelling subsided. Her lisinopril was discontinued, and to date she has not had a recurrence of AE.

DISCUSSION

Angioedema is a potentially life-threatening condition characterized by non-pitting, non-dependent edema. Angioedema can be either histamine-mediated, which presents similar to an allergic reaction, or bradykinin-mediated.^{1,2} The bradykinin-mediated types include a rare disorder called hereditary angioedema in which patients lack complement 1 inhibitor (C1-INH), leading to excessive production of bradykinin and an increased risk for AE attacks.^{1,13} A second, more common cause of bradykinin-mediated AE is ACE inhibitors. It is well established that ACE inhibitors, which are widely used to treat hypertension, congestive heart failure, and diabetic nephropathy, lead to a buildup of bradykinin.

ACE inhibitor-associated AE is one of the most common causes of AE seen in the ED and can be associated with a high morbidity. Presentation can range from mild facial edema to acute laryngeal or subglottic involvement, which could prove life-threatening. Cases commonly present with swelling of the face (52%), lips (49%), or tongue (approximately 20%). While symptoms typically present within four weeks of starting therapy, they have been documented to occur after years of stable therapy.^{6,7,14} Cases of acute facial and airway edema due to ACE inhibitors may be misdiagnosed as an anaphylactic reaction, and the association with ACE inhibitors may be ignored or missed; thus, it is important to distinguish between the two.^{4,9,15} Atypical presentations such as difficulty swallowing (9%), difficulty speaking (6%), stridor/dyspnea (5%), hoarseness (3%), and increased salivation and difficulty handling oral secretions (2%) may cause a delay of treatment and potential increase in morbidity.¹⁴ As airway compromise is not uncommon among patients with ACE inhibitor-associated AE, it is critical to have early recognition and management.¹²

Management of ACE inhibitor-associated AE in the ED includes assessment of the airway. Medications rarely alleviate the swelling, unlike in histamine-mediated AE. Angioedema can progress rapidly, and for patients who require definitive airway management, cricothyrotomy or tracheostomy is needed in up to 50% of cases.⁴ The presence of epiglottic or laryngeal edema suggests the need for a definitive airway. If the swelling is restricted to the structures anterior to the teeth, such as the lips, intubation is generally not needed. Noninvasive positive pressure ventilation is not a definitive therapy for patients with airway involvement.

Additionally, supraglottic and extraglottic airway devices are not recommended in patients with AE, as it will not secure an airway below the site of obstruction and can worsen edema due to trauma.

Severe edema may prohibit passage of an endotracheal tube through the glottis, even with the use of fiberoptic or video laryngoscopy guidance; therefore, the resuscitation team should be prepared for cricothyrotomy before an attempt at intubation is started. If the patient does not require immediate airway intervention, it may be beneficial to consult anesthesia and otolaryngology and consider transferring the patient to the OR.^{4,12} Ultimately, treatment for ACE inhibitor-associated AE is to stop use of the ACE inhibitor and for the patient to consider an alternate medication with their primary care physician.

CONCLUSION

An elderly female who had been using an ACE inhibitor for 10 years presented to the ED with a chief complaint of throat swelling and difficulty breathing. Recognition of angioedema is necessary to ensure swift and appropriate treatment. There should be a low threshold to treat and a high suspicion of AE, even years after initial treatment with ACE inhibitors.

The authors attest that their institution requires neither Institutional Review Board approval, nor patient consent for publication of this case report. Documentation on file.

Address for Correspondence: Carney Flinn, Virginia Tech Carilion School of Medicine, 2 Riverside Circle, Roanoke, VA 24016. Email: carneyflinn@vt.edu

Conflicts of Interest: By the CPC-EM article submission agreement, all authors are required to disclose all affiliations, funding sources and financial or management relationships that could be perceived as potential sources of bias. The authors disclosed none.

Copyright: © 2024 Flinn et al. This is an open access article distributed in accordance with the terms of the Creative Commons Attribution (CC BY 4.0) License. See: <http://creativecommons.org/licenses/by/4.0/>

REFERENCES

1. Bas M, Adams V, Suvorava T, et al. Nonallergic angioedema: role of bradykinin. *Allergy*. 2007;62(8):842–56.
2. Gabb GM, Ryan P, Wing LM, et al., Epidemiological study of angioedema and ACE inhibitors. *Aust N Z J Med*. 1996;26(6):777–82.
3. Kaplan AP and Greaves MW. Angioedema. *J Am Acad Dermatol*. 2005;53(3):373–88; quiz 389–92.
4. Long BJ, Koyfman A, Gottlieb M. Evaluation and management of angioedema in the emergency department. *West J Emerg Med*. 2019;20(4):587–600.

5. Makani H, Messerli FH, Romero J, et al. Meta-analysis of randomized trials of angioedema as an adverse event of renin-angiotensin system inhibitors. *Am J Cardiol*. 2012;110(3):383–91.
6. Maurer M and Magerl M. Differences and similarities in the mechanisms and clinical expression of bradykinin-mediated vs. mast cell-mediated angioedema. *Clin Rev Allergy Immunol*. 2021;61(1):40–9.
7. Vleeming W, Van Amsterdam JG, Stricker BH, et al. ACE inhibitor-induced angioedema. Incidence, prevention, and management. *Drug Saf*. 1998;18(3):171–88.
8. Schulkes KJG, Van Den Elzen MT, Hack EC, et al. Clinical similarities among bradykinin-mediated and mast cell-mediated subtypes of non-hereditary angioedema: a retrospective study. *Clin Transl Allergy*. 2015;5(1):5.
9. Banerji A, Blumenthal KG, Lai KH, et al. Epidemiology of ACE inhibitor angioedema utilizing a large electronic health record. *J Allergy Clin Immunol Pract*. 2017;5(3):744–9.
10. Banerji A, Clark S, Blanda M, et al., Multicenter study of patients with angiotensin-converting enzyme inhibitor-induced angioedema who present to the emergency department. *Ann Allergy Asthma Immunol*. 2008;100(4):327–32.
11. Toh S, Reichman ME, Houstoun M, et al. Comparative risk for angioedema associated with the use of drugs that target the renin-angiotensin-aldosterone system. *Arch Intern Med*. 2012;172(20):1582–9.
12. Patel H, Kant S, Chow R. A rare presentation of angioedema with isolated retropharyngeal and supraglottic involvement. *J Community Hosp Intern Med Perspect*. 2019;9(1):36–9.
13. Abdulkarim A and Craig TJ. Hereditary angioedema. 2023. Available at: <https://www.ncbi.nlm.nih.gov/books/NBK482266/>. Accessed October 17, 2023.
14. Kostis JB, Kim HJ, Rusnak J, et al. Incidence and characteristics of angioedema associated with enalapril. *Arch Intern Med*. 2005;165(14):1637–42.
15. Sarkar P, Nicholson G, Hall G. Brief review: angiotensin converting enzyme inhibitors and angioedema: anesthetic implications. *Can J Anaesth*. 2006;53(10):994–1003.

Peripartum Cardiac Arrest with Terminal QRS Distortion: A Case Report

Timothy D. Kelly, MD, MPH*
Nicholas E. Harrison, MD, MSc†

*Indiana University School of Medicine Emergency Medicine Residency,
Indianapolis, Indiana

†Indiana University School of Medicine, Department of Emergency Medicine,
Indianapolis, Indiana

Section Editor: Anna McFarlin, MD

Submission history: Submitted April 18, 2023; Revision received July 28, 2023; Accepted September 5, 2023

Electronically published December 6, 2023

Full text available through open access at http://escholarship.org/uc/uciem_cpem

DOI: [10.5811/cpcem.1323](https://doi.org/10.5811/cpcem.1323)

Introduction: Peripartum cardiac arrest is increasing in incidence. While pulmonary embolism (PE) remains an important cause of peripartum morbidity and mortality, other cardiovascular emergencies such as myocardial infarction (MI) are now the leading cause of pregnancy-related death. Emergency physicians (EP) need to be well versed in subtle electrocardiographic (ECG) signs of coronary ischemia to better care for peripartum patients in cardiac arrest.

Case Report: A 38-year-old gravida 2 parity 1 female three days post-partum presented in cardiac arrest. After approximately 12 minutes of Advanced Cardiac Life Support including electric defibrillation, the patient experienced sustained return of spontaneous circulation. The physician team was primarily concerned for PE based on an initial ECG demonstrating terminal QRS distortion in V2 but no ST-segment elevation myocardial infarction (STEMI). Computed tomography angiography (CTA) of the chest did not reveal PE. Repeat ECG after CTA demonstrated STEMI criteria, and the patient was emergently taken to the cardiac catheterization laboratory where she was found to have 99% occlusion of the left anterior descending artery.

Conclusion: Emergency physicians should have a high index of suspicion for MI when managing peripartum patients in cardiac arrest. The ECG findings specific for coronary-occlusive acute MI but not included in the classic STEMI criteria increase accuracy and prevent delays in diagnosis; however, the clinical uptake of this paradigm has been slow. Early recognition of terminal QRS distortion can help EPs more rapidly diagnose the etiology of cardiac arrest. [Clin Pract Cases Emerg Med. 2024;8(1)22–25.]

Keywords: *cardiac arrest; case report; myocardial Infarction; terminal QRS distortion.*

INTRODUCTION

The rate of pregnancy-related mortality has more than doubled in the past 30 years. In 1987, 7.2 deaths per 100,000 live births were pregnancy related; by 2017, pregnancy-related death accounted for 17.3 deaths per 100,000 live births.¹ Given these epidemiological trends, emergency physicians (EP) are increasingly likely to provide care to peripartum patients in cardiac arrest.

Previously, pulmonary embolism (PE) was the leading cause of maternal death following a live birth.² More recent research, however, indicates that complications of

cardiovascular disease (ie, relating to coronary artery disease, hypertension, pulmonary hypertension, congenital valvular disease, and/or vascular malformations) are now the leading cause of pregnancy-related death.³ This shift is thought to be driven by increasing maternal age and worsening population cardiovascular health.⁴ We present a case study of peripartum cardiac arrest due to myocardial infarction (MI) and demonstrate the need for EPs to be facile with subtle electrocardiogram (ECG) findings suggestive of acute MI not captured by the traditional ST-elevation myocardial infarction (STEMI) criteria.

CASE REPORT

A 38-year-old gravida 2 parity1 female with past medical history of hypertension and gestational diabetes presented in cardiac arrest three days postpartum. Labor and delivery course was notable for preeclampsia with severe features. The patient experienced a ventricular fibrillation arrest, was intubated, and underwent 10 minutes of cardiac pulmonary resuscitation with one cardiac defibrillation at which point return of spontaneous circulation (ROSC) was obtained. Four minutes later, the patient experienced a second ventricular fibrillation cardiac arrest, and ROSC was once again obtained with one additional round of Advanced Cardiac Life Support without defibrillation.

Post-arrest, the patient's rhythm was sinus tachycardia with a heart rate of 119 beats per minute and blood pressure of 122/85 millimeters of mercury. Point-of-care ultrasound revealed a dilated right ventricle and globally reduced systolic function. Point-of-care ultrasound did not demonstrate any free fluid within the peritoneum. Initial ECG demonstrated a new incomplete right bundle branch block, terminal QRS distortion in V2, and inferior ST depression (**Image 1**). The physician team was initially most concerned for massive PE in the postpartum period and decided to proceed with computed tomography angiography (CTA) of the chest.

The CTA was negative for PE. Subsequently, serial increase in high-sensitivity troponin (5,480 nanograms per liter (ng/L) (reference range: <3 ng/L–34 ng/L) led to a repeat ECG being obtained, which demonstrated a STEMI pattern (**Image 2**). The patient was taken to the cardiac catheterization lab where she was found to have a 99% occlusion of the left anterior descending artery with

thrombolysis in myocardial infarction (TIMI) 2 flow. Percutaneous coronary intervention was performed with TIMI 3 flow thereafter.

CPC-EM Capsule

What do we already know about this clinical entity?

Peripartum mortality is increasing in incidence, although it remains rare.

What makes this presentation of disease reportable?

There are other electrocardiogram patterns apart from ST-elevation myocardial infarction (STEMI) suggestive of occlusive myocardial infarction such as terminal QRS distortion.

What is the major learning point?

In the correct clinical setting, terminal QRS distortion is specific for occlusive MI and requires emergent cardiology consultation/ intervention.

How might this improve emergency medicine practice?

Identifying terminal QRS distortion can help clinicians more expediently identify the cause of cardiac arrest and facilitate appropriate resuscitation.

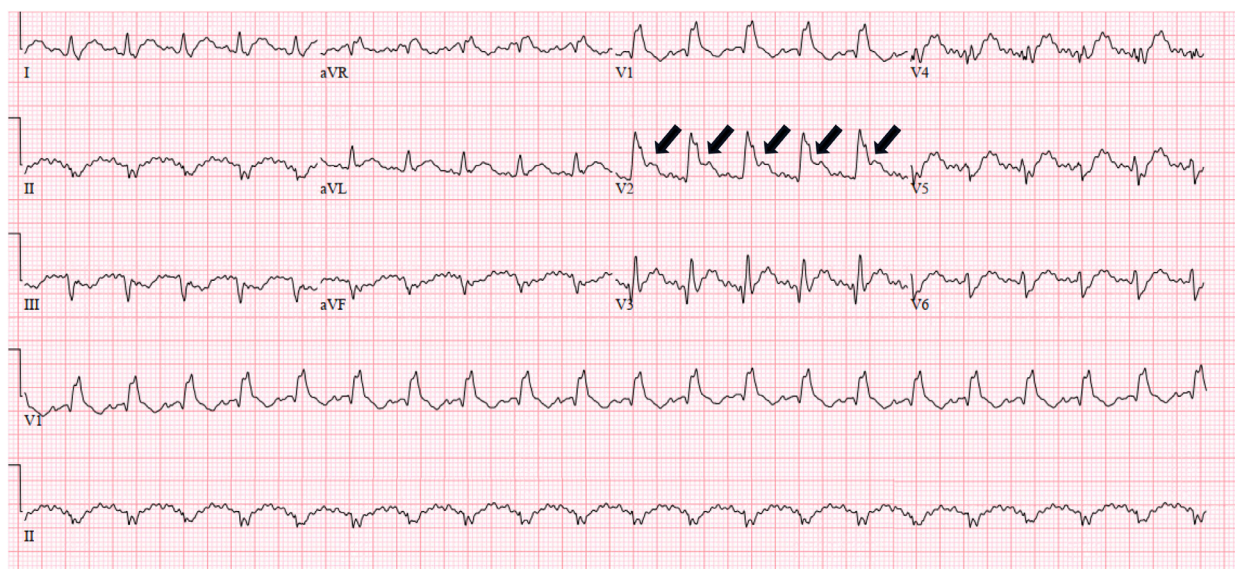


Image 1. Initial electrocardiogram in a patient post-cardiac arrest demonstrating terminal QRS distortion (arrows) in lead V2 which is not captured by traditional ST-segment elevation myocardial infarction criteria.

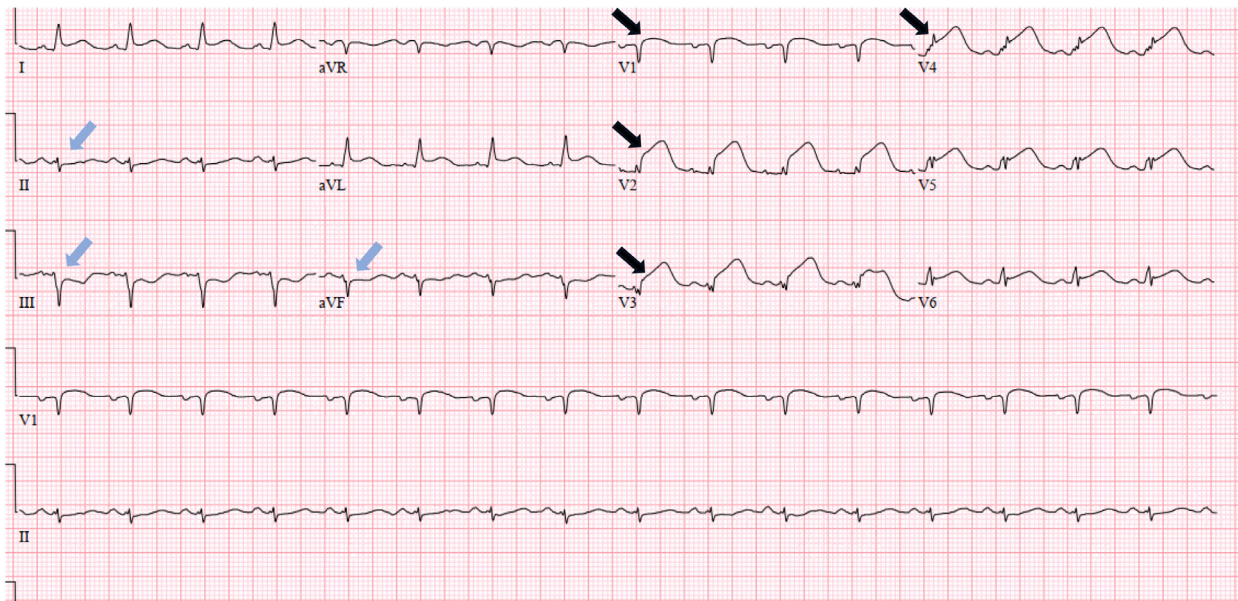


Image 2. Repeat electrocardiogram in a patient post-cardiac arrest demonstrating ST-segment elevation in leads V1-V4 (black arrows) with reciprocal depressions in the inferior leads (blue arrows) consistent with ST-segment elevation myocardial infarction criteria.

DISCUSSION

The presented case scenario highlights the evolving epidemiology of peripartum cardiac arrest and need for EPs to be aware of ECG findings consistent with acute MI not included in the traditional STEMI criteria. Insufficient sensitivity of the STEMI criteria to diagnose MI that would benefit from emergent percutaneous coronary intervention (PCI) has led to the development of a new ECG paradigm called occlusive myocardial infarction (OMI).⁵ Occlusive myocardial infarction criteria include the traditional STEMI patterns but go further to include other ECG patterns specific for MIs. These other ECG patterns include Wellens sign, hyperacute T-waves, terminal QRS distortion, among others, and are commonly missed under the STEMI paradigm.⁶

Although traditionally thought of as the most-evidenced ECG pattern of OMI, STEMI criteria are not sufficiently sensitive to reliably diagnose OMI. In fact, multiple studies demonstrate that almost 30% of patients who present with acute coronary syndrome (ACS) but without clear STEMI pattern have acute coronary occlusion.^{7,8} The OMI criteria have similar specificity but approximately double the sensitivity of STEMI criteria, allowing EPs to reliably identify more patients that would benefit from emergent PCI. Moreover, use of the OMI criteria reduces time to catheterization for angiographically significant lesions when compared to STEMI criteria alone.⁹

Terminal QRS distortion is very specific for OMI yet remains one of the least discussed ECG patterns associated with ACS. Terminal QRS distortion is defined as the absence of both S and J waves in the anterior precordial leads and is clearly visible in lead V2 of [Image 1](#). Terminal QRS

distortion has been found to be 100% specific to left-anterior descending artery occlusion and should never be misinterpreted as benign early repolarization.¹⁰ Anecdotally, our professional experiences suggest that terminal QRS distortion has received far less discussion and educational emphasis compared to other ECG findings consistent with OMI such as Wellens sign or hyperacute T-waves. Earlier angiography and intervention could have potentially been facilitated by noting the terminal QRS distortion pattern on the initial ECG.

While the STEMI paradigm remains the most common ECG classification relating to acute coronary ischemia, the American College of Cardiology now recognizes multiple ECG patterns as STEMI equivalents.¹¹ This recognition of multiple ECG patterns consistent with angiographically significant coronary lesions lends further evidence to the OMI paradigm.

Moving forward, EPs should become more comfortable introducing this novel paradigm into their clinical decision-making when presented with patients at risk of ACS, peripartum or otherwise. Familiarity with terminal QRS distortion and other ECG patterns consistent with OMI will benefit EPs when confronted with peripartum patients who present with undifferentiated chest pain, dyspnea, shock, or cardiac arrest. Given the rising incidence of peripartum cardiovascular disease and associated mortality, EPs should expect to care for more patients experiencing ACS and critical illness in the peripartum period. In these scenarios, identifying terminal QRS distortion (and other ECG patterns of OMI) can provide critical diagnostic information and help expedite PCI or thrombolysis.

CONCLUSION

Cardiac arrest occurring in the peripartum period is a challenging clinical scenario for the emergency physician. Complications from cardiovascular disease are the leading cause of pregnancy-related death. Consideration of terminal QRS distortion and other non-STEMI ECG findings suggestive of OMI may help emergency physicians more appropriately identify post-cardiac arrest patients who would benefit from emergent PCI.

The authors attest that their institution requires neither Institutional Review Board approval, nor patient consent for publication of this case report. Documentation on file.

Address for Correspondence: Timothy Kelly MD, MPH, Indiana Emergency Medicine Residency, 6349 N. College Ave., Apt. 523, Indianapolis, IN, 46220. Email: tykell@iu.edu

Conflicts of Interest: By the CPC-EM article submission agreement, all authors are required to disclose all affiliations, funding sources and financial or management relationships that could be perceived as potential sources of bias. This publication was made possible with support from Grant Numbers, KL2TR002530 (Sheri L. Robb, PI), and UL1TR002529 (Sharon M. Moe and Sarah E. Wiehe, co-PIs) from the National Institutes of Health (NIH), National Center for Advancing Translational Sciences, Clinical and Translational Sciences Award.

Nicholas Harrison and their institution Indiana University has received grant money to conduct investigator-initiated research conceived and written by Nicholas Harrison from the Blue Cross Blue Shield of Michigan Foundation, the Doris Duke Foundation, the NIH (5KL2TR002530-05), and the Indiana Clinical and Translational Sciences Institute (UL1TR002529). NH's institution, Indiana University, has received grant money for industry-initiated research from Abbott Laboratories, Siemens, and Beckman-Coulter. Nicholas Harrison has received funding from Vave Health Inc. for consulting.

Copyright: © 2024 Kelly et al. This is an open access article distributed in accordance with the terms of the Creative Commons Attribution (CC BY 4.0) License. See: <http://creativecommons.org/licenses/by/4.0/>

REFERENCES

1. CDC. *Pregnancy Mortality Surveillance System*. Atlanta, GA: US Department of Health and Human Services, CDC; 2019. Available at: <https://www.cdc.gov/reproductivehealth/maternalinfanthealth/pregnancy-mortality-surveillance-system.htm>. Accessed May 1, 2023.
2. Chang J, Elam-Evans LD, Berg CJ, et al. Pregnancy-related mortality surveillance—United States, 1991–1999. *MMWR Surveill Summ*. 2003;52(2):1–8.
3. Davis NL, Smoots AN, Goodman DG. *Pregnancy-Related Deaths: Data from 14 U.S. Maternal Mortality Review Committees, 2008-2017*. Atlanta, GA: Centers for Disease Control and Prevention, U.S. Department of Health and Human Services; 2019. <https://www.cdc.gov/reproductivehealth/maternal-mortality/erase-mm/mmr-data-brief.html>. Accessed May 1, 2023.
4. Mehta LS, Warnes CA, Bradley E, et al. American Heart Association Council on Clinical Cardiology; Council on Arteriosclerosis, Thrombosis and Vascular Biology; Council on Cardiovascular and Stroke Nursing; and Stroke Council. Cardiovascular Considerations in Caring for Pregnant Patients: A Scientific Statement from the American Heart Association. *Circulation*. 2020;141(23):e884–e903.
5. Meyers HP, Weingart SD, Smith SW. The OMI Manifesto. Dr. Smith's ECG Blog 2018. <http://hqmeded-ecg.blogspot.com/2018/04/the-omi-manifesto.html>. Accessed May 1, 2023.
6. Miranda DF, Lobo AS, Walsh B, et al. New insights into the use of the 12-lead electrocardiogram for diagnosing acute myocardial infarction in the emergency department. *Can J Cardiol*. 2018;34(2):132–45.
7. Schmitt C, Lehmann G, Schmieder S, et al. Diagnosis of acute myocardial infarction in angiographically documented occluded infarct vessel: limitations of ST-segment elevation in standard and extended ECG leads. *Chest*. 2001;120(5):1540–6.
8. Wang TY, Zhang M, Fu Y, et al. Incidence, distribution, and prognostic impact of occluded culprit arteries among patients with non-ST-elevation acute coronary syndromes undergoing diagnostic angiography. *Am Heart J*. 2009;157(4):716–23.
9. Meyers HP, Bracey A, Lee D, et al. Comparison of the ST-elevation myocardial infarction (STEMI) vs. NSTEMI and occlusion MI (OMI) vs. NOMI paradigms of acute MI. *J Emerg Med*. 2021;60(3):273–84.
10. Lee DH, Walsh B, Smith SW. Terminal QRS distortion is present in anterior myocardial infarction but absent in early repolarization. *Am J Emerg Med*. 2016;34(11):2182–5.
11. Writing Committee; Kontos MC, de Lemos JA, et al. 2022 ACC Expert Consensus Decision Pathway on the Evaluation and Disposition of Acute Chest Pain in the Emergency Department: a report of the American College of Cardiology Solution Set Oversight Committee. *J Am Coll Cardiol*. 2022;80(20):1925–60.

Spontaneous Coronary Artery Dissection Presenting as Electrical Storm: A Case Report

Nathan Escorial, MD
Coleman Cowart, DO
Matthew Paparian, DO
Joel Stillings, DO

Desert Regional Medical Center, Department of Emergency Medicine, Palm Springs, California

Section Editor: Christopher San Miguel, MD

Submission history: Submitted May 15, 2023; Revision received September 12, 2023; Accepted September 22, 2023

Electronically published January 23, 2024

Full text available through open access at http://escholarship.org/uc/uciem_cpccm

DOI: [10.5811/cpcem.1372](https://doi.org/10.5811/cpcem.1372)

Introduction: Spontaneous coronary artery dissection (SCAD) is an important cause of myocardial infarction in patients of younger age without typical atherosclerotic risk factors and can present with ventricular arrhythmia such as ventricular tachycardia (VT) or ventricular fibrillation (VF). Electrical storm (ES) is defined as greater than or equal to 3 episodes of VT or VF occurring within 24 hours.

Case Report: A healthy 38-year-old-male developed chest pain while exercising at the gym and presented to the emergency department unresponsive in a ventricular arrhythmia defined as ES. The patient's cardiac arrest was initially refractory to standard defibrillation and Advanced Cardiac Life Support medications. He was ultimately diagnosed with SCAD of the left anterior descending artery, which was stented. The patient survived neurologically intact after a 13-day hospital stay.

Conclusion: Spontaneous coronary artery dissection is a significant cause of acute coronary syndrome and occurs in healthier patients without cardiac risk factors. Electrical storm represents a unique manifestation of SCAD. Emergency physicians should maintain a heightened suspicion for SCAD for accurate diagnosis and treatment. [Clin Pract Cases Emerg Med. 2024;8(1)26–29.]

Keywords: *spontaneous coronary artery dissection; electrical storm; case report.*

INTRODUCTION

Spontaneous coronary artery dissection (SCAD) is a significant cause of acute coronary syndrome (ACS), myocardial infarction (MI), and sudden death; it is particularly associated with female gender, pregnancy, and physical and emotional triggers.¹ It may be the cause of up to 1–4% of ACS cases overall and up to 35% of MIs in women >50 years old; SCAD is the most common cause of pregnancy-associated MI.¹ Spontaneous coronary artery dissection causes myocardial injury by causing an intramural hematoma resulting in coronary artery obstruction. Spontaneous coronary artery dissection is frequently misdiagnosed or underdiagnosed and treated like typical ACS.²

Electrical storm (ES) is a life-threatening syndrome involving recurrent episodes of ventricular arrhythmias,

specifically ≥ 3 in a 24-hour period.³ Initial management is aimed at identifying the underlying cause, which is often myocardial ischemia. The most effective agents in terminating ES are β -blockers and amiodarone.³ It is estimated that ventricular arrhythmias occur in 8–14% of patients with SCAD.² In the following report, we present a young male who presented in ES and was ultimately diagnosed with SCAD. Recognizing ES is paramount to correctly treating this diagnosis. If epinephrine is administered, per the standard used in Advanced Cardiac Life Support (ACLS), it may make these patients more prone to recurrent arrhythmias.³

CASE REPORT

A 38-year-old male with no known past medical history presented to the hospital as a transfer from an outside facility

status post cardiac arrest. The patient had been experiencing chest pain for two weeks prior to the arrest. On the day of the arrest, the patient had ingested a pre-workout nutritional supplement before working out at the gym. He then developed chest pain, and emergency medical services were called. Initially he had a normal electrocardiogram (ECG) and stable vital signs. Paramedics administered one dose of nitroglycerin en route to the emergency department (ED) at the first hospital. On arrival, he went into ventricular tachycardia (VT) and became unresponsive.

Cardiopulmonary resuscitation (CPR) was initiated, and he received one synchronized cardioversion of 150 joules (J) and a second shock of 200 J. He was intubated while CPR was in progress and had an emergent central line placed. During the initial arrest, the patient received in total 10 doses of one milligram (mg) epinephrine (1:10,000 dilution) intravenously (IV), three doses of 8.4% sodium bicarbonate 50 milliequivalent (mEq) IV, 300 mg amiodarone IV, two grams (g) of calcium gluconate IV, and 50 mg esmolol IV. During resuscitation the patient was defibrillated a total of six times, including the two initial defibrillations at 150 J and then 200 J, followed by four dual sequence defibrillations at 400 J, total for each attempt.

After 44 minutes of CPR, return of spontaneous circulation (ROSC) was achieved with a sinus bradycardia rhythm. However, the patient went into a second cardiac arrest, secondary to ventricular fibrillation (VF), with an additional three rounds of CPR before ROSC was achieved. The ECG after the second ROSC showed ST-segment elevations in V4, V5, V6, I and aVL with reciprocal changes in II, III and aVF. (ECG image unavailable) The patient then had a third cardiac arrest—a VT arrest—for which he was cardioverted and received one dose of epinephrine 1 mg IV and magnesium sulfate 2 g IV before ROSC was achieved.

We were unable to learn the exact times at which the arrests occurred or the length of the time between the arrests, as these had not been documented in the chart. We know the first arrest occurred at 2 PM; however, the details of the timing of each subsequent arrest were unclear. Other medications given at the first hospital included lidocaine 100 mg IV, propranolol 5 mg IV, aspirin 300 mg per rectum, 0.9% normal saline two liters (L) IV, post-intubation sedation with fentanyl and midazolam drips (guttae [gtt]). The patient was started on amiodarone gtt, lidocaine gtt, norepinephrine gtt, and sodium bicarbonate gtt. Laboratory values obtained from the ED visit are noted in [Table 1](#). Of note, the patient had a normal sensitive troponin of greater than 800 nanograms per milliliter (ng/mL) (reference range: 0.0–0.08 ng/mL) consistent with myocardial infarction secondary to SCAD.

The patient was transferred to the regional trauma center for interventional cardiology for the diagnosis of acute ST-segment elevation myocardial infarction (STEMI), ES, status post cardiac arrest. Upon arrival to the higher level of

Population Health Research Capsule

What do we already know about this clinical entity?

Spontaneous coronary artery dissection (SCAD) is the most common cause of pregnancy-associated myocardial infarction.

What makes this presentation of disease reportable?

We describe the case of a young male patient without any traditional atherosclerotic risk factors uniquely presenting with electrical storm.

What is the major learning point?

In younger patients with chest pain who present to the emergency department, SCAD should be included in the differential.

How might this improve emergency medicine practice?

Awareness of this clinical entity in younger patients, especially pregnant women, will facilitate diagnosis and management of acute coronary syndrome.

care facility, a repeat ECG showed ST-segment elevation in I and aVL with depressions in III and aVF ([Image 1](#)). The patient was taken to the catheterization lab for percutaneous coronary intervention (PCI) and was diagnosed with SCAD resulting in acute total occlusion of the left anterior descending (LAD) artery at its proximal segment with an extension of intramural hematoma into the long segment of the mid LAD, as well as into the proximal major diagonal branch ([Image 2](#)). The patient had three overlapping drug-eluting stents placed in the proximal to mid LAD and one stent placed in the proximal major diagonal branch off the LAD.

The patient was diagnosed with severe dilated cardiomyopathy with an ejection fraction of 15% and severe hypokinesis in all mid and apical left ventricular segments and stress-induced cardiomyopathy. One week later the patient had an internal cardiac defibrillator placed and was discharged to acute rehabilitation after a 13-day hospital stay. He survived neurologically intact. After acute rehabilitation and discharge, the patient subsequently presented to the ED frequently and required hospital admissions for complications related to his SCAD. Specifically, he suffered from consequences related to heart

Table 1. Laboratory values obtained in the emergency department from a 38-year-old patient status post cardiac arrest.

Labs	Value	Reference range
1 st Troponin	0.61	0.0–0.08 ng/mL
2 nd Troponin	800	0.0–0.08 ng/mL
White blood cells	14.51	4.8–10.8 × 10 ³ /mcl
Hemoglobin	13.6	14%–18%
Platelets	218 × 10 ³	130–400 × 10 ³ /mcl
Sodium	143	136–145 mEq/L
Potassium	3.9	3.5–5.1 mEq/L
Carbon dioxide	15	21–32 mEq/L
Anion gap	23	4–14
Calcium	11.1	8.5–10.1 mg/dL
Blood urea nitrogen	17	7–18 mg/dL
Creatinine	1.9	0.6–1.3 mg/dL
Glomerular filtration rate	40	normal high < 60
Glucose	324	74–106 mg/dL
1 st Alanine transaminase	310	30–65 IU/L
2 nd Alanine transaminase	2372	30–65 IU/L
1 st Aspartate transaminase	254	15–37 IU/L
2 nd Aspartate transaminase	842	15–37 IU/L
Lipase	274	73–393 IU/L
Arterial blood gas		
pH	6.854	7.35–7.45
Carbon dioxide	34.2	35–45 mm Hg
Oxygen	144.2	60–80 mm Hg
Bicarbonate	5.9	20–26 mm Hg
Base excess	–27.5	–3 to 3 mmol/L

ng/mL, nanograms per milliliter; mcl, microliters; mEq/L, milliequivalents per liter; IU, international units; mm HG, millimeters of mercury; mmol, millimole.

failure exacerbations, requires supplemental oxygen at home, and takes apixaban for atrial fibrillation.

DISCUSSION

This patient presented to the hospital in cardiac arrest. He met criteria for ES with multiple rounds of ACLS with defibrillation and cardioversion including dual sequence, despite IV amiodarone, esmolol and propranolol, which are the recommended antiarrhythmics for terminating ES.⁴ It is thought that most patients with ES have severe underlying structural heart disease or other known triggers such as drug toxicity, electrolyte disturbances, acute myocardial ischemia, thyrotoxicosis, or QT prolongation.⁴ In this case, the patient presented with STEMI with elevated cardiac biomarkers and ES secondary to SCAD of his LAD and proximal diagonal branch. Patients who survive and present for initial evaluation of SCAD almost universally experience ACS and elevated troponin.¹ The gold standard of diagnosis for SCAD is coronary angiography.¹ Treatment varies between conservative therapy with inpatient monitoring vs coronary artery bypass grafting vs PCI.

Our patient was taken for PCI due to his hemodynamic instability and active ischemia. Interestingly, the patient had ingested a pre-workout supplement known to contain multiple ingredients such as nitric oxide, caffeine, beta-alanine, and nitric oxide agents, with limited data on safety.⁵ The patient was undergoing physical exertion at the gym, which is the most commonly reported trigger and precipitating factor in 28.9% of cases of SCAD.⁶ He had been experiencing chest pain for two weeks prior to his presentation to the hospital. This highlights the fact that there are varying presentations of SCAD ranging from mild chest pain to sudden cardiac death.³ Given SCAD's underdiagnosis and unknown prevalence, it is difficult to state whether this patient's presentation was typical as there are limited case reports of young men with SCAD. He does

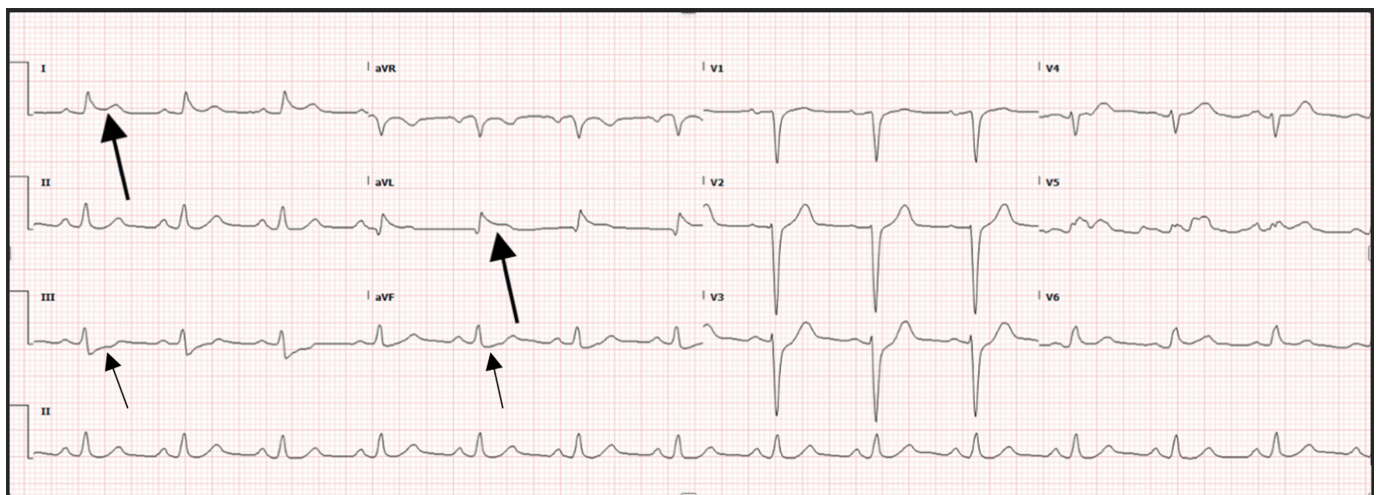


Image 1. Electrocardiogram in a patient status post cardiac arrest demonstrating ST-segment elevations in lead I and aVL (large arrows). There are also ST-segment depressions in leads III and aVF (small arrows).

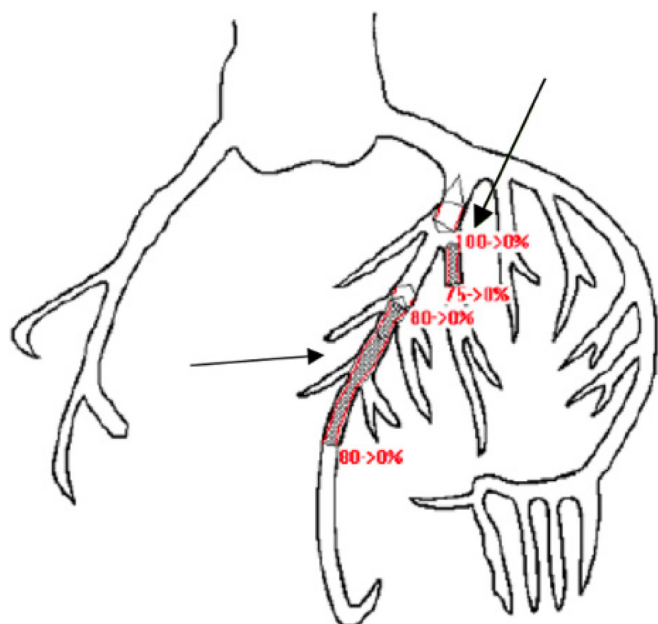


Image 2. Coronary artery tree from cath lab report in a patient status post cardiac arrest. Shaded areas represent areas of occlusion. Red percentage values indicate the amount of occlusion prior to stenting. Lower arrow indicates the proximal to mid-left anterior descending artery. Upper arrow indicates the proximal diagonal branch off the left anterior descending artery. Shaded areas were stented.

not fit the typical risk profile of patients previously diagnosed with SCAD who are typically healthy, young and middle-aged individuals, particularly women, without traditional cardiovascular risk factors.¹ While ventricular arrhythmias or sudden cardiac death are reportedly present in up to 3–11% in patients with SCAD, our patient presented in ES. There are limited reports on the prevalence of ES as the clinical presentation of SCAD.

CONCLUSION

It seems likely that the combination of physical exertion, unknown underlying genetic risk factors, and unknown family history had a cumulative effect in precipitating SCAD and, therefore, electrical storm. We do not know the specific pre-workout supplement the patient ingested, its ingredients, or whether it contained stimulants or had any effect at all regarding this patient's presentation. It remains an interesting question as to another trigger of this patient's SCAD. The recommended treatment for ES in patients in cardiac arrest includes adrenergic blockade with propranolol as the first-line agent, which is not typically used in the ACLS algorithm.⁷ The use of epinephrine may make the patient pro-arrhythmic, further perpetuating ventricular arrhythmias and ES; therefore, it should not be used as a standard part of ACLS in this clinical scenario, highlighting the importance for emergency physicians of recognizing electrical storm early.³

This patient was treated with a multitude of cardioactive medications, electricity, and ultimately PCI and was eventually discharged from the hospital neurologically intact. Despite the increased recognition of SCAD, there are large gaps in knowledge regarding this disease entity as a clinical presentation for acute coronary syndrome. If SCAD is suspected, emergency physicians should consult with cardiology early, as coronary angiography should be performed as soon as possible. Physicians must maintain a heightened suspicion for SCAD as a potential diagnosis for a wide array of presentations related to ACS.

The authors attest that their institution requires neither Institutional Review Board approval, nor patient consent for publication of this case report. Documentation on file.

Address for Correspondence: Nathan Escorial, MD, Desert Regional Medical Center, Department of Emergency Medicine, 3594 Penny Lane, Palm Springs, CA 92262. Email: nathanm.escorial@gmail.com

Conflicts of Interest: By the CPC-EM article submission agreement, all authors are required to disclose all affiliations, funding sources and financial or management relationships that could be perceived as potential sources of bias. The authors disclosed none.

Copyright: © 2024 Escorial et al. This is an open access article distributed in accordance with the terms of the Creative Commons Attribution (CC BY 4.0) License. See: <http://creativecommons.org/licenses/by/4.0/>

REFERENCES

- Hayes SN, Kim ESH, Saw J, et al. Spontaneous coronary artery dissection: current state of the science. A scientific statement from the American Heart Association. *Circulation*. 2018;137(19):e523–e557.
- Yip A and Saw J. Spontaneous coronary artery dissection; a review. *Cardiovasc Diagn Ther*. 2015;5(1):37–48.
- Eifling M, Razavi M, Massumi A. The evaluation and management of electrical storm. *Tex Heart Inst J*. 2011;38(2):111–21.
- Haegeli LM, Della Bella P, Brunckhorst CB. Management of a patient with electrical storm. *Circulation*. 2016;133(7):672–6.
- Harty PS, Zabriskie HA, Erickson JL, et al. Multi-ingredient pre-workout supplements, safety implications, and performance outcomes: a brief review. *J Int Soc Sports Nutr*. 2018;15(1):41.
- Saw J, Aymong E, Sedlak T, et al. Spontaneous coronary artery dissection: association with predisposing arteriopathies and precipitating stressors and cardiovascular outcomes. *Circ Cardiovasc Interv*. 2014;7(5):645–55.
- Al-Khatib SM. Correction to: 2017 AHA/ACC/HRS guideline for management of patients with ventricular arrhythmias and the prevention of sudden cardiac death: a report of the American College of Cardiology/American Heart Association Task Force on Clinical Practice Guidelines and the Heart Rhythm Society. *Circulation*. 2018;138(13):e272–e391.

The Other Aortic Syndrome—Intramural Hematoma and Neurological Deficit: Case Report

Laura E. Walker, MD*
Chris Marcellino, MD†‡
Bhargavi Gali, MD§||

*Department of Emergency Medicine, Mayo Clinic, Rochester, Minnesota

†Department of Anesthesiology and Perioperative Medicine, Mayo Clinic, Rochester, Minnesota

‡Department of Neurologic Surgery, Mayo Clinic Health System Eau Claire, Eau Claire, Wisconsin

§Division of Intensive Care and Respiratory Therapy, Mayo Clinic, Rochester, Minnesota

||Department of Anesthesiology and Perioperative Medicine, Mayo Clinic, Rochester, Minnesota

Section Editor: Lev Libet, MD

Submission history: Submitted May 31, 2023; Revision received September 15, 2023; Accepted September 19, 2023

Electronically published December 28, 2023

Full text available through open access at http://escholarship.org/uc/uciem_cpccm

DOI: 10.5811/cpcem.1421

Introduction: Acute thoracic aortic syndromes are among the most concerning presentations in emergency medicine and are associated with significant morbidity and mortality. Thoracic aortic dissection is most common, followed by penetrating aortic ulcer and, least commonly, intramural hematoma.

Case Report: A 67-year-old woman presented to the emergency department with chest and back pain, and sudden onset of paraparesis. Aortic intramural hematoma was diagnosed, and she underwent spinal drain placement with blood pressure control to optimize spinal cord perfusion.

Discussion: When neurological deficits are present, rapid diagnosis of spinal ischemia and blood pressure optimization is vital. Spinal drains may be considered as an adjunctive treatment. [Clin Pract Cases Emerg Med. 2024;8(1)30–33.]

Keywords: *aortic syndromes; spinal cord ischemia; paraparesis; spinal drain.*

INTRODUCTION

Acute aortic syndromes are among the most concerning potential presentations in emergency medicine. The most common culprit of thoracic aortic syndromes is aortic dissection, followed by penetrating aortic ulcer and intramural hematoma. Incidences of each are 4.4, 2.1 and 1.2 per 100,000 person-years, respectively. Aortic dissection is associated with a higher rate of mortality, ranging between 1% risk of mortality per hour to 10–25% 30-day mortality rates. Intramural hematoma may progress to dissection and is also associated with a high risk of mortality.¹ Commonly associated complications at presentation include pleural effusion, pericardial effusion and tamponade, periaortic effusion, aortic regurgitation, shock, stroke, cerebral malperfusion, visceral malperfusion, coronary ostial

involvement, and renal impairment.² Spinal cord ischemia is a rarer complication and can present with various deficits depending on the area of perfusion that is restricted.³

Typical management of aortic syndromes is focused on minimizing the risk of progression of dissection. This involves regulating blood pressure, with a goal systolic blood pressure of 100–120 millimeters of mercury (mm Hg).⁴ For situations in which there is concern for neurological ischemia, the balance between ensuring adequate perfusion and avoiding further vascular injury is tenuous.

CASE REPORT

A 67-year-old woman presented to the emergency department (ED) via emergency medical services (EMS) after an initial call for chest pain. On initial assessment by

EMS personnel, she complained of both chest pain and back pain that had been ongoing for several days. While en route to the ED she had sudden onset of paraparesis and increased emotional distress. There was no report of any recent trauma. Review of systems was otherwise negative.

Her initial exam revealed blood pressure of 165/99 mm Hg and otherwise normal vital signs. Pulses to all extremities were 2+, warm and well perfused. Strength was 5/5 in bilateral upper extremities, left lower extremity was 4/5 and right lower extremity was 0/5. Reflexes were normal in the upper extremities and on the left lower extremity but were absent on the right lower extremity. Initial laboratory studies including complete blood count, coagulation panel and basic metabolic panel were unremarkable, except for a mildly elevated high-sensitivity troponin of 23 nanograms per liter (ng/L) (reference range less than 12 ng/L), which did not have a significant change on repeat evaluation.

Imaging studies of the chest, abdomen, pelvis, and spine were obtained. An initial portable chest radiograph identified prominence of the aorta, which was attributed to technique. Computed tomography (CT) angiography of the aorta revealed an intramural hematoma extending from just proximal to the left subclavian and extending into the abdomen and including the renal arteries (Images 1 and 2). No dissection flap was identified, but there was a potential ulceration described as “tiny” in the thoracic aorta. Spinal and brain CT imaging did not reveal any acute abnormalities.

Cardiothoracic and vascular surgeons were emergently consulted. Initial plans were developed for blood pressure control using clevidipine; however, after establishing concern for spinal cord ischemia (SCI) the recommended treatment

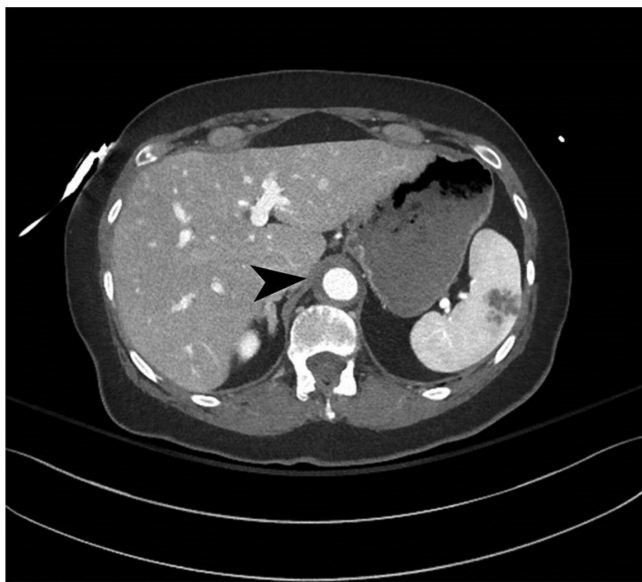


Image 1. Demonstration of intramural thrombus of the thoracic aorta (arrow) in a patient with acute aortic syndrome, axial view.

Population Health Research Capsule

What do we already know about this clinical entity?

Acute thoracic aortic syndromes are concerning presentations associated with significant morbidity and mortality.

What makes this presentation of disease reportable?

Emergency placement of a spinal drain to maximize spinal cord blood flow has not been reported for acute aortic syndrome presentations.

What is the major learning point?

Spinal drain placement to optimize blood flow to the spinal cord can be considered as adjunct treatment in cases of aortic syndrome to mitigate spinal cord ischemia.

How might this improve emergency medicine practice?

In cases of spinal cord ischemia associated with aortic syndromes, placement of a spinal drain is an opportunity to potentially improve long-term outcomes.

was to maintain a goal mean arterial pressure (MAP) between 70–90 mm Hg to optimize spinal cord blood flow, as perfusion to the dominant segmental arteries was presumed to be impaired due to pressure from the hematoma.

The patient was rapidly admitted to the surgical critical care unit where a spinal drain was placed to reduce intrathecal pressure and promote perfusion from both the involved and uninvolved segmental arteries to the spinal cord by optimizing the perfusion gradient between systemic and intrathecal pressure. After drain placement, the patient had mild improvement in her weakness of the left lower extremity but persistent weakness of the right lower extremity. Cerebral spinal fluid (CSF) drainage was maintained for approximately 48 hours and weaned without neurological worsening. During her intensive care unit course she had additional improvement in right lower extremity strength. She did require clevidipine early in her course and norepinephrine infusions during sleep to keep MAP within the 70–90 mm Hg range. Use of both antihypertensive and pressors enabled the team to strike a balance between the risk of uncontrolled hypertension causing further intravascular hematoma formation and providing optimal perfusion to the spinal cord during the period of critical collateral formation.

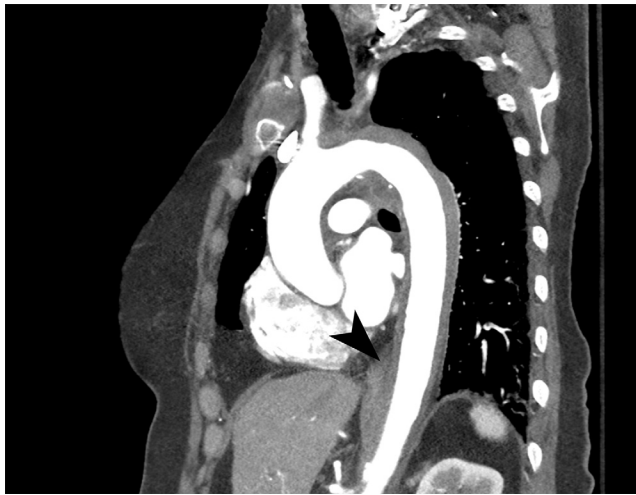


Image 2. Demonstration of intramural thrombus of the thoracic aorta (arrow) in a patient with acute aortic syndrome, sagittal view.

At the time of discharge from the hospital the patient had persistent, right-sided lower extremity weakness, but was able to perform activities of daily living with assistive devices.

DISCUSSION

Spinal cord ischemia is a rare finding that can lead to permanent disability including paraplegia. Most cases of SCI or infarction are reported periprocedurally, commonly with thoracoabdominal aortic aneurysm repair.⁵ Spontaneous causes of SCI include aortic intramural hematoma, as in our patient, as well as other arterial occlusions resulting from arteriosclerosis, vasculitis, infection, embolic occlusion, thrombosis, and hypoperfusion of the spinal cord.⁵

The spinal cord is supplied proximally by three main longitudinal arteries: the anterior spinal artery (ASA); and two posterior spinal arteries.⁶ The ASA supplies approximately two-thirds of the spinal cord, and its diameter changes throughout its course. The narrowest segment of the ASA is in the thoracic region. Numerous segmental arteries provide collateral supply and typically arise from the vertebral and intercostal arteries. The thoracic spinal cord is most dependent on the collateral supply from these arteries, which typically enter from the left neural foramen. The great anterior segmental artery (of Ademkiewicz) is the most prominent radicular artery, between the ninth and twelfth thoracic vertebrae in most individuals (Figures 1 and 2).

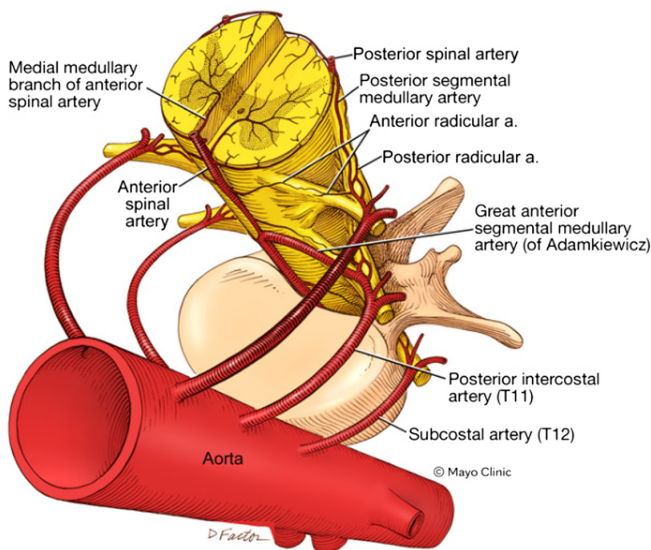


Figure 1. Diagram of the vascular supply to the spinal cord. An oblique diagram of the interface of the segmental vascular supply of the spinal cord from the intercostal and subcostal arteries as radicular branches to the longitudinal arteries of the spinal cord. The great anterior segmental artery (of Ademkiewicz) is the superior-most segmental artery in the diagram on the left anatomical side, which in most individuals anastomoses between the ninth and twelfth thoracic vertebrae, although occasionally it arises from a lumbar segment or on the right. In acute aortic syndromes, Spibal cord ischemia (SCI) typically is caused by injury to multiple segmental arteries, or the great anterior segmental artery alone (often in iatrogenic SCI.) Used with permission of Mayo Foundation for Medical Education and Research, all rights reserved. a, artery; SCI, spinal cord ischemia; T11, eleventh thoracic vertebra level; T12, twelfth thoracic vertebra level.

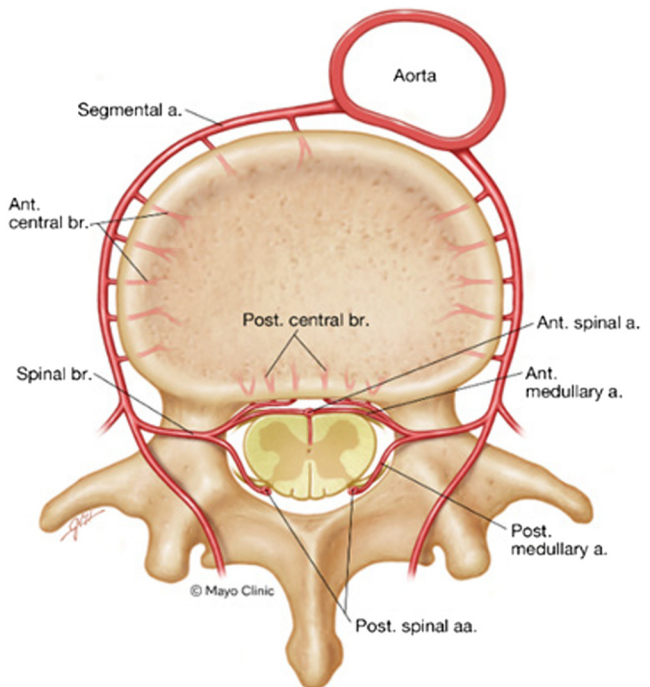


Figure 2. Cross-sectional diagram of a single segmental vascular physiological anastomosis to the spinal cord. A segmental artery of the aorta supplies collateral circulation to the longitudinal spinal arteries of the spinal cord and branches to bone and other supporting musculature and ligaments of the spine. Used with permission of Mayo Foundation for Medical Education and Research, all rights reserved. a, artery; aa, arteries; ant, anterior; br, branch; post, posterior.

The thoracic spinal cord receives arterial supply from the narrowest section of the ASA and is highly dependent on collaterals, thus most likely to suffer from SCI or infarction. Optimizing arterial supply to the spinal cord is the focus of periprocedural management of patients undergoing thoracic aortic repair and reduces the risk of spinal cord ischemia.⁷ This intervention is less commonly reported in acute treatment of aortic syndromes with SCI. One method involves increasing the MAP to increase spinal cord perfusion pressure (as spinal cord perfusion pressure gradient is equal to MAP minus intrathecal pressure). The second method, which our patient experienced, aims to control cerebrospinal perfusion pressure by use of a lumbar drain or intermittent draws of CSF to lower intrathecal pressure and improve perfusion. Complications of drain placement include intracranial hemorrhage, meningitis, spinal epidural hematoma, and subdural hematoma.⁵ Complications are reported in 1–4% of cases, with a recent retrospective, single-center study reporting a complication rate of 6.4%.⁸

CONCLUSION

Our patient developed SCI from acute intramural hematoma and presented with chest and back pain. She did have persistent deficits related to SCI; however, her symptoms improved with placement of the spinal drain and elevation of the spinal cord perfusion pressure gradient. Using this treatment modality is different from typical management of aortic syndromes in the ED. The acute focus pivots from maintaining a reduced MAP to providing adequate pressure to perfuse the spinal cord. Our patient needed both pressors and antihypertensives during the acute phase of her presentation and treatment and was provided control of intrathecal pressure to ensure optimal spinal cord perfusion. Rapid diagnosis of SCI provides an opportunity to mitigate morbidity and should be considered when acute aortic syndromes are in the differential, accompanied by neurological deficits in the setting of normal extremity perfusion.

The authors attest that their institution requires neither Institutional Review Board approval, nor patient consent for publication of this case report. Documentation on file.

Address for Correspondence: Laura E. Walker, MD, Mayo Clinic, Department of Emergency Medicine, 200 First St. SW, GE_410, Rochester MN 55902. Walker.laura@mayo.edu

Conflicts of Interest: By the CPC-EM article submission agreement, all authors are required to disclose all affiliations, funding sources and financial or management relationships that could be perceived as potential sources of bias. The authors disclosed none.

Copyright: © 2024 Walker et al. This is an open access article distributed in accordance with the terms of the Creative Commons Attribution (CC BY 4.0) License. See: <http://creativecommons.org/licenses/by/4.0/>

REFERENCES

1. DeMartino RR, Sen I, Huang Y, et al. Population-based assessment of the incidence of aortic dissection, intramural hematoma, and penetrating ulcer, and its associated mortality from 1995 to 2015. *Circ Cardiovasc Qual Outcomes* 2018;11(8):e004689.
2. Corsini A, Pacini D, Lovato L, et al. Long-term follow up of patients with acute aortic syndromes: relevance of both aortic and non-aortic events. *Eur J Vasc Endovasc Surg* 2018;56(2):200–8.
3. Gaul C, Dietrich W, Erbguth FJ. Neurological symptoms in aortic dissection: a challenge for neurologists. *Cerebrovasc Dis* 2008;26(1):1–8.
4. Hiratzka LF, Bakris GL, Beckman JA, et al. 2010 ACCF/AHA/AATS/ACR/ASA/SCA/SCAI/SIR/STS/SVM Guidelines for the Diagnosis and Management of Patients with Thoracic Aortic Disease: Executive Summary. *J Am Coll Cardiol*. 2010;55(14):1509–44.
5. Marcellino C, Zalewski NL, Rabinstein AA. Treatment of vascular myelopathies. *Curr Treat Options Neurol*. 2021;23(10):35.
6. Biglioli P, Roberto M, Cannata A, et al. Upper and lower spinal cord blood supply: the continuity of the anterior spinal artery and the relevance of the lumbar arteries. *J Thorac Cardiovasc Surg* 2004;127(4):1188–92.
7. Suarez-Pierre A, Zhou X, Gonzalez JE, et al. Association of preoperative spinal drain placement with spinal cord ischemia among patients undergoing thoracic and thoracoabdominal endovascular aortic repair. *J Vasc Surg*. 2019;70(2):393–403.
8. Spratt JR, Walker KL, Wallen TJ, et al. Safety of cerebrospinal fluid drainage for spinal cord ischemia prevention in thoracic endovascular aortic repair. *JTCVS Tech* 2022;14:9–28.

The Rare Sore Throat: A Case of Thyroid Storm and Agranulocytosis

Matthew J. Kunz, DO*
Wayne A. Martini, MD†
Levi Filler, DO‡

*Creighton of Phoenix Arizona (COPA), Emergency Medicine, Phoenix, Arizona
†Mayo Clinic, Department of Emergency Medicine, Phoenix, Arizona
‡University of Arizona College of Medicine - Phoenix, Department of Emergency Medicine, Phoenix, Arizona

Section Editor: R. Gentry Wilkerson, MD

Submission history: Submitted October 25, 2023; Revision received July 18, 2023; Accepted July 20, 2023

Electronically published December 6, 2023

Full text available through open access at http://escholarship.org/uc/uciem_cpem

DOI: [10.5811/cpcem.59284](https://doi.org/10.5811/cpcem.59284)

Introduction: Thyroid storm is a rare but potentially life-threatening metabolic disorder that presents unique management challenges in the emergency department. Thionamides are commonly used as monotherapy for first-line treatment of hyperthyroidism.

Case Report: In this case, a 26-year-old male presented to the emergency department with sore throat, fever, and diarrhea. He was found to have thyrotoxicosis as well as methimazole-induced bone marrow suppression resulting in agranulocytosis.

Conclusion: Thyroid storm is a rare condition that carries a high risk of mortality and can further compromise a patient's immune system due to complications of common treatment modalities. It can potentially be misdiagnosed as sepsis due to tachycardia, febrile state, and tachypnea. This case report includes a discussion of diagnostic studies, as well as medical and surgical treatment modalities that led to the patient's recovery. [Clin Pract Cases Emerg Med. 2024;8(1)34–37.]

Keywords: *case report; thyrotoxicosis; methimazole; bone marrow suppression; agranulocytosis.*

INTRODUCTION

Thyroid storm (TS) is a dangerous, life-threatening metabolic disorder that can present unique challenges in management for an emergency physician. While the incidence of TS among hospitalized patients is estimated to be low (1–2%), it carries a 12-fold increase in mortality compared to thyrotoxicosis that ranges from 8–22%.^{1–3} The use of thionamides, such as methimazole, for hyperthyroidism is common in the United States. A recent study found 60% of clinicians prefer thionamide monotherapy as the first-line treatment for hyperthyroidism.⁴ Although a mainstay of hyperthyroid management, thionamides can also be associated with agranulocytosis, a rare but dangerous side effect.⁵ Agranulocytosis can be life-threatening and is associated with a fatality rate as high as 7%.⁶

We present a case of TS in a young, otherwise healthy patient who presented to an emergency department (ED) in a

large, tertiary-care hospital and was found to have concurrent agranulocytosis as a side effect of his underlying thionamide treatment. There are few reported cases describing management of TS in the setting of agranulocytosis. Special considerations should be made surrounding proper management of both coexisting conditions.

CASE REPORT

A 26-year-old male with a past medical history of hyperthyroidism and thyromegaly presented to the ED with complaints of sore throat, fever, and diarrhea. He stated that nine days prior he began to have a progressively worsening sore throat, which prevented him from taking his prescribed methimazole (10 milligrams [mg] twice daily). Following the onset of his sore throat, he reported watery stools that occurred several times per day. He also complained of lesions to his chest, back, and oral mucosa that would appear

periodically. The patient described three similar episodes over the prior year, which prompted visits to other hospitals, with the most recent episode 2–3 months earlier. He was told on his most recent visit that he would require a tonsillectomy and was discharged with outpatient follow-up.

Initial physical examination revealed an uncomfortable appearing male, visibly diaphoretic and lethargic, but oriented to person, place, and time. Vital signs were notable for a heart rate of 167 beats per minute (bpm), blood pressure of 146/70 millimeters of mercury, respiratory rate of 20 breaths per minute, oxygen saturation of 99% on room air, and a temperature of 38.6°C. He was found to have posterior oropharyngeal erythema and tonsillar edema without exudates. No goiter or thyroid masses were palpable. He was tachypneic with clear breath sounds and tachycardic with a regular rhythm and no appreciable murmurs. Skin examination was notable for multiple acneiform lesions at various stages of healing to the anterior and posterior neck and trunk.

We considered a broad differential, but our preliminary investigation favored TS as the primary diagnosis. Thyroid storm with concomitant infection was also a consideration. Diagnostic tests ordered included a complete blood count (CBC), complete metabolic panel (CMP), electrocardiogram, blood cultures, urinalysis, strep A polymerase chain reaction (PCR), severe acute respiratory syndrome coronavirus 2 (SARs-CoV-2) PCR, lactate, thyroid stimulating hormone (TSH), free triiodothyronine (T3) and free thyroxine (T4), prothrombin time (PT), and international normalized ratio (INR). We calculated the Burch-Wartofsky point scale for thyrotoxicosis with a score of 60 (15 for temperature, 10 for agitation, 10 for diarrhea, 25 for heart rate), further supporting our leading diagnosis of TS.⁷

Initial therapies ordered included propranolol 1 mg intravenously (IV), sodium chloride 0.9% one liter (L) IV, acetaminophen 650 mg orally (PO), and methimazole 20 mg PO. Shortly after initial orders were placed, the laboratory called regarding a critical CBC result, noting a white blood cell count of 0.5×10^9 cells per L (reference range $4.5\text{--}11.0 \times 10^9/L$). This raised concern for drug-induced agranulocytosis in the setting of TS. Upon receiving this information, we canceled the order for methimazole, and the patient was placed in a negative pressure isolation room. Broad spectrum antibiotics, including piperacillin-tazobactam and vancomycin, were administered given agranulocytosis and neutropenic fever. Additional studies were notable for a lactate of 5 millimoles (mmol) per L ($0.5\text{--}2.2$ mmol/L); TSH less than 0.015 international units per milliliter (IU/mL) ($0.465\text{--}4.680$ IU/mL); T4 greater than 6.99 nanograms per deciliter (ng/dL) ($0.78\text{--}2.19$ ng/dL); T3 greater than 22.80 ng/dL ($2.77\text{--}5.27$ ng/dL); PT 28.2 seconds ($25.1\text{--}36.5$ seconds); and INR 2.5 ($0.9\text{--}1.1$). Pertinent CMP findings included a sodium level of 130 milliequivalents

CPC-EM Capsule

What do we already know about this clinical entity?

Thyroid storm and agranulocytosis have high mortality. Agranulocytosis is a known side effect of hypothyroid medications, but the incidence is low.

What makes this presentation of disease reportable?

The clinical presentation of combined drug-induced agranulocytosis and thyroid storm is extremely rare.

What is the major learning point?

Agranulocytosis is a rare side effect of commonly prescribed hypothyroid medications and should be considered in settings of thyroid storm.

How might this improve emergency medicine practice?

Sharing rare clinical presentations provides a collective learning environment for emergency clinicians.

(mEq) per L ($135\text{--}145$ mEq/L) and potassium level of 3.3 mEq/L ($3.5\text{--}5.1$ mEq/L).

The medical intensive care unit (MICU) was consulted for admission due to our diagnosis of TS and concomitant agranulocytosis with possible sepsis secondary to underlying bacterial illness. Clinical improvement was noted with the initial order of IV fluids and IV propranolol, including improvement of his tachycardia (110 bpm vs 167 bpm on arrival). Upon admission, the MICU ordered additional IV fluids, propranolol 40 mg PO, potassium chloride 10 mEq IV, magnesium 1g IV, and hydrocortisone sodium succinate 100 mg IV. While in the MICU the patient continued to receive beta-blockers (propranolol 60 mg PO four times daily), steroids (hydrocortisone 60 mg IV four times daily), and bile acid sequestrants (cholestyramine 4 g packet once daily). He continued to receive empiric antibiotics (piperacillin/tazobactam 4.5 g every eight hours, vancomycin 1.5 g every eight hours). He received a bone marrow biopsy, which was suggestive of methimazole-induced bone marrow suppression.

Both the endocrinology and otorhinolaryngology services evaluated the patient and determined that a thyroidectomy was required. He was subsequently transferred to another

facility to have this procedure performed. Fourteen days following his initial ED presentation, he underwent a total thyroidectomy. He continued to improve clinically following the procedure and was discharged the next day with instructions regarding outpatient endocrinology follow-up.

DISCUSSION

The recognition and treatment of thyroid emergencies is well within the scope of practice for the emergency physician. Isolated TS can be treated with a stepwise approach that has been well documented in the literature. Standard first-line pharmacotherapy in TS aims to block production and release of thyroid hormones with propylthiouracil or methimazole, inhibit release of preformed thyroid hormones with iodine, decrease peripheral conversion of T4 to T3 with propylthiouracil and steroids, and treat adrenergic symptoms with beta-blockade, prior to definitive treatment in the form of surgery or radioactive iodine ablation.⁸

Our patient represents a rare and complex case of TS with concurrent methimazole-induced agranulocytosis and neutropenic fever, who met sepsis parameters with symptoms that raised concern for underlying infectious process. This case highlights multiple challenges surrounding conventional TS treatment when standard, first-line pharmacotherapy also contributes to an alternate, life-threatening condition. To our knowledge, no specific literature or guidelines exist regarding the management of this presentation.

Given the inherently high mortality rate of both neutropenic sepsis and TS, it was imperative to implement therapeutic measures to optimally treat both conditions simultaneously, while also minimizing iatrogenic risk to the patient. It is well known that sepsis can mimic features of TS, and given that our patient presented with concurrent drug-induced agranulocytosis along with infectious symptomatology and concerning physical examination features, we could not exclude an underlying bacterial infectious process.⁹ Drug-induced agranulocytosis occurs in less than seven cases per million individuals per year.¹⁰ Most research regarding agranulocytosis is associated with bone marrow suppression in cancer treatment, and neutropenic fever has been identified as an important criterion in determining life-threatening infections in this specific patient population.

Neutropenic fever is defined as absolute neutrophil count less than 500 cells per microliter and fever as a single oral temperature of greater than 38.3°C or greater than 38.0°C sustained over a one-hour period.¹¹ Furthermore, high-risk patients with neutropenic fever are those with any of the following: hemodynamic instability; oral or gastrointestinal mucositis; gastrointestinal symptoms including abdominal pain, nausea, vomiting, or diarrhea; neurologic or mental-status changes; intravascular catheter infection; new

pulmonary infiltrate; or hypoxemia. Neutropenic sepsis has been shown to approach mortality of greater than 40% if left untreated at 48 hours.¹² Given our patient's underlying neutropenia, fever, and increased risk for infection, we made the decision to treat for neutropenic fever and sepsis immediately with IV fluid resuscitation and broad-spectrum IV antibiotics.

The patient's underlying agranulocytosis and neutropenia conflicted with the standard treatment options intended to control thyroid hormone production. Controlling the production of new thyroid hormone is imperative in the setting of TS by using thionamides; however, the first step in treating drug-induced agranulocytosis is to also stop the offending agent. Additionally, without a thionamide on board, it is contraindicated to give potassium iodide or Lugol's iodine in the ED, as it can increase thyroid hormone release.

Following the conventional stepwise approach for TS treatment, high-dose IV steroids were also considered; however, the use of high-dose steroids is associated with increased mortality in septic patients without neutropenia.^{8,13} In patients with neutropenic sepsis, hydrocortisone therapy has been associated with increased adverse events and has not been shown to improve mortality.¹⁴

Standard treatment of TS also requires the use of IV beta-blockers, which decrease sympathetic activity during TS and prevent peripheral conversion of T3 to T4. Use of beta-blockers in our patient required special scrutiny given his neutropenic fever and concern for concomitant sepsis from a bacterial source. Although it is controversial, recent literature suggests that beta-blocker therapy may be safe in septic patients.¹⁵ We decided the therapeutic benefits of beta-blockers in TS outweighed the risks of beta-blockade in the setting of potential sepsis, given that our patient was otherwise healthy and remained hemodynamically stable during his course of care.

Ultimately while under the care of the ED team, the patient was treated with IV beta-blockers, acetaminophen, IV fluids, and broad-spectrum antibiotics. His clinical status improved significantly following these measures, and he eventually required a total thyroidectomy as curative therapy.

CONCLUSION

Agranulocytosis, sepsis, and thyroid storm are life-threatening presentations that can be associated with hyperthyroidism. Together they present a unique diagnostic and therapeutic challenge for the emergency physician treating the thyroid-toxic patient, especially when sepsis is an additional consideration. Deviations from standard TS treatment guidelines should be considered in this patient population to avoid any potential complications and harm to them.

Address for Correspondence: Wayne A. Martini, Mayo Clinic, Department of Emergency Medicine, 5777 E. Mayo Blvd., Phoenix, Arizona, 85054. Email: Martini.Wayne@Mayo.edu

Conflicts of Interest: By the CPC-EM article submission agreement, all authors are required to disclose all affiliations, funding sources and financial or management relationships that could be perceived as potential sources of bias. The authors disclosed none.

Copyright: © 2024 Kunz et al. This is an open access article distributed in accordance with the terms of the Creative Commons Attribution (CC BY 4.0) License. See: <http://creativecommons.org/licenses/by/4.0/>

REFERENCES

1. Klubo-Gwiedzinska J, Wartofsky L. Thyroid emergencies. *Med Clin North Am.* 2012;96(2):385–403.
2. Angell TE, Lechner MG, Nguyen CT, et al. Clinical features and hospital outcomes in thyroid storm: a retrospective cohort study. *J Clin Endocrinol Metab.* 2015;100(2):451–9.
3. Swee du S, Chng CL, Lim A. Clinical characteristics and outcome of thyroid storm: a case series and review of neuropsychiatric derangements in thyrotoxicosis. *Endocr Pract.* 2015;21(2):182–9.
4. Brito JP, Payne S, Singh Ospina N, et al. Patterns of use, efficacy, and safety of treatment options for patients with Graves' disease: a nationwide population-based study *Thyroid.* 2020;30(3):357–64.
5. van Staa TP, Boulton F, Cooper C, et al. Neutropenia and agranulocytosis in England and Wales: incidence and risk factors. *Am J Hematol.* 2003;72(4):248–54.
6. Ibáñez L, Vidal X, Ballarín E, et al. Population-based drug-induced agranulocytosis. *Arch Intern Med.* 2005;165(8):869–74.
7. Burch HB, Wartofsky L. Life-threatening thyrotoxicosis. Thyroid storm. *Endocrinol Metab Clin North Am.* 1993;22(2):263–77.
8. Tintinalli JE. Endocrine disorders. In: *Tintinalli's Emergency Medicine: A Comprehensive Study Guide*, 9th ed. (p. 1454). New York, NY: McGraw-Hill Education; 2019.
9. Rayner SG, Hosseini F, Adedipe AA. Sepsis mimicking thyroid storm in a patient with methimazole-induced agranulocytosis. *BMJ Case Reports.* 2013;2013(jul16 1):bcr2013200145-b.
10. Strom BL, Carson JL, Schinnar R, et al. Descriptive epidemiology of agranulocytosis. *Arch Intern Med.* 1992;152(7):1475–80.
11. Freifeld AG, Bow EJ, Sepkowitz KA, et al. Clinical practice guideline for the use of antimicrobial agents in neutropenic patients with cancer: 2010 update by the Infectious Diseases Society of America. *Clin Infect Dis.* 2011;52(4):e56–93.
12. Bodey GP, Jadeja L, Elting L. Pseudomonas bacteremia. Retrospective analysis of 410 episodes. *Arch Intern Med.* 1985;145(9):1621–9.
13. Penack O, Becker C, Buchheidt D, et al. Management of sepsis in neutropenic patients: 2014 updated guidelines from the Infectious Diseases Working Party of the German Society of Hematology and Medical Oncology (AGIHO). *Ann Hematol.* 2014;93(7):1083–95.
14. Kang J, Han M, Hong SB, et al. Effect of adjunctive corticosteroid on 28-day mortality in neutropenic patients with septic shock. *Ann Hematol.* 2019;98(10):2311–8.
15. Hasegawa D, Sato R, Prasitlumkum N, et al. Effect of ultrashort-acting β -blockers on mortality in patients with sepsis with persistent tachycardia despite initial resuscitation: a systematic review and meta-analysis of randomized controlled trials. *Chest.* 2021;159(6):2289–300.

Vitamin C and D Deficiency in Urban America: A Case Report

Alyssa A. Lombardi, MD, PhD
Maura Sammon, MD
Kraftin E. Schreyer, MD, MBA, FAAEM

Temple University Hospital, Department of Emergency Medicine,
Philadelphia, Pennsylvania

Section Editor: R. Gentry Wilkerson, MD

Submission history: Submitted March 27, 2023; Revision received August 31, 2023; Accepted September 21, 2023

Electronically published December 20, 2023

Full text available through open access at http://escholarship.org/uc/uciem_cpccem

DOI: 10.5811/cpcem.1253

Introduction: Scurvy is caused by vitamin C deficiency and manifests with a variety of symptoms including generalized fatigue, apathy, anemia, myalgias, easy bruising, and poor wound healing. It is generally thought of as a disease of the past, especially in developed countries. However, vitamin C deficiency still occurs, especially in patients with lack of access to fruits and vegetables. Other micronutrient deficiencies, including vitamin D deficiency, are also prevalent and can cause a multitude of signs and symptoms including osteomalacia, muscle weakness, and increased risk of many chronic illnesses.

Case Report: Here we present a case of vitamin C and D deficiency in a previously healthy 26-year-old man during the coronavirus disease 2019 pandemic in urban America.

Conclusion: Severe nutritional deficiencies still exist today. Emergency clinicians should be aware of the signs and symptoms to promptly diagnose and initiate treatment. [Clin Pract Cases Emerg Med. 2024;8(1)38–41.]

Keywords: *scurvy; ascorbic acid; vitamin D; malnutrition; case report.*

INTRODUCTION

Vitamin C (ascorbic acid) is a vital piece of many biosynthetic pathways. However, humans are unable to synthesize ascorbic acid and must obtain it from their diet.¹ Clinically, it is well documented that vitamin C is crucial to prevent scurvy, which presents with fatigue, malaise, anemia, petechia, perifollicular hemorrhages, poor wound healing, and depression.^{1,2} Scurvy is often thought of as an ancient disease that afflicted sailors deprived of fruits and vegetables.³ We describe a case of a 26-year-old man who presented with scurvy during the coronavirus disease 2019 (COVID-19) pandemic. This case shows the importance of keeping nutritional deficiencies on the differential, especially with risk factors such as isolation, food insecurity, old age, restrictive diets, malabsorption syndromes, or substance use disorder.

CASE REPORT

A 26-year-old male with a past medical history of depression presented to our emergency department (ED)

twice, first in February 2021 and again in March 2021. On his initial visit, his chief concern was leg pain. The patient reported that his symptoms began as bilateral foot and low back pain about three months prior to arrival. While the back pain resolved, his foot pain progressed up his bilateral lower extremities, which had become stiff. Over the prior several weeks, he had begun to have difficulty extending his knees. He additionally noted easy bruising and small red dots all over his extremities. He denied fever, vomiting, diarrhea, abnormal bleeding, weight loss, and prior spinal surgeries. There was no known family history of rheumatologic, immunologic, metabolic, or connective tissue disorders. The patient did not drink alcohol, smoke, or use illicit substances. He did note that he had been eating pizza bagels since April 2020. He drank only water. He did not take any vitamin supplementation. At the time he was not employed and lived with a roommate. He had not been evaluated previously for these concerns.

The patient was afebrile, with a temperature of 98.1° Fahrenheit (F). He had a heart rate of 91 beats per minute

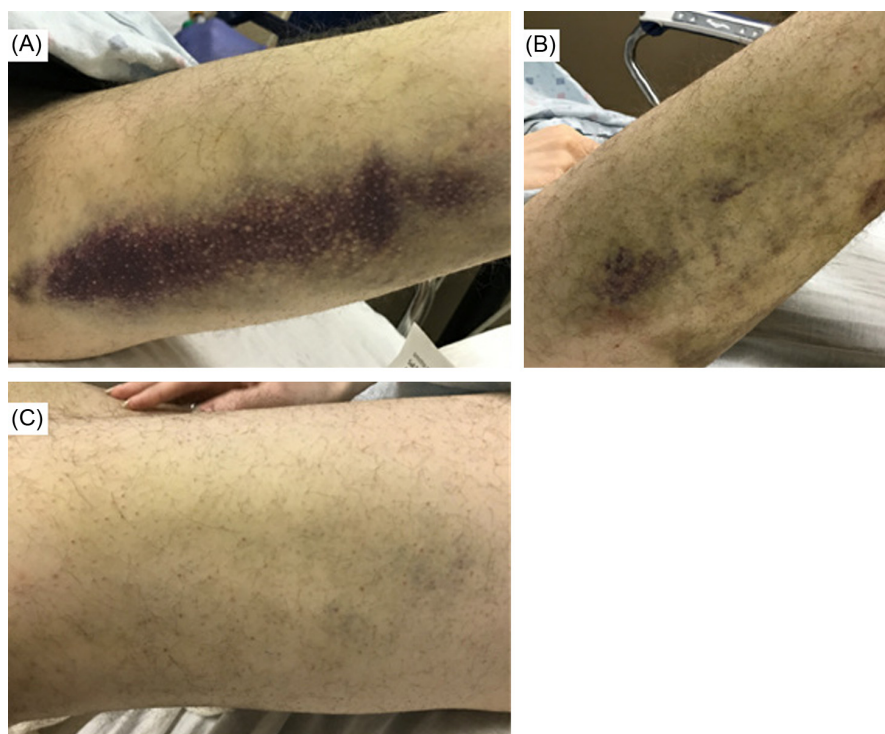


Image (A) Spontaneous ecchymoses on patient's left thigh. (B) and (C) Perfollicular hemorrhages and petechiae of the patient's right (B) and left (C) lower extremities.

(bpm), blood pressure 128/89 millimeters of mercury (mm Hg), and a respiratory rate of 16 breaths per minute. His oxygen saturation was 99% on room air. He weighed 61.2 kg. On physical examination, he was pale and thin. He had contractures in the bilateral lower extremities with healing ecchymoses in the flexor surfaces of bilateral thighs and knees. Perfollicular hemorrhages were noted diffusely in the bilateral upper and lower extremities (Image). Petechiae were noted on the bilateral lower extremities. He had full strength in the bilateral upper and lower extremities, and intact sensation in all extremities. He had a normal thyroid exam. There was no gingival bleeding. He had a negative Steinberg sign, also known as the thumb sign. This test is considered positive if the distal phalanx of the adducted thumb extends beyond the ulnar border of the palm when clenching one's fist (suggestive of Marfan disease).

His initial laboratory evaluation demonstrated a hemoglobin of 11.0 grams per deciliter (g/dL) with a mean corpuscular volume of 88.7 femtoliters (fL), a white blood cell count of 7.7×10^3 /milliliters (K/mL), and a platelet count of 321 K/mm³. The creatinine was 0.69 milligrams (mg)/dL, potassium 3.9 millimoles per liter, magnesium 2.3 mg/dL, calcium 8.4 mg/dL, and phosphorus 2.9 mg/dL. The albumin was 3.4 g/dL, and indirect bilirubin was elevated at 1.3 mg/dL (Table). He was discharged with hematology follow-up given the anemia and bruising.

He presented to the hematology clinic in March 2021 and was immediately referred back to the ED. At that time, he

was unable to ambulate and instead was moving around by pulling himself with his arms. On the second visit, he had a temperature of 97.3°F, heart rate of 94 bpm, blood pressure 94/57 mm Hg, and respiratory rate 20 breaths per minute. His oxygen saturation was 99% on room air. He weighed 59.9 kg. His physical examination was notable for progressive contractures in his bilateral lower extremities. He had pain and tenderness at tendon and ligament insertions, suggesting enthesitis and preventing knee extension. Additionally, he had contracture of the right elbow. Ecchymoses were also visible on the right upper extremity. He was noted to be apathetic and indifferent to his current physical condition. His repeat laboratory evaluation is noted in the table.

Diagnostic considerations included nutritional disorders, specifically, scurvy and Vitamin D deficiency, Ehlers-Danlos syndrome, scleroderma, coagulopathy secondary to factor XIII deficiency, alpha 2-antiplasmin, or plasminogen activator inhibitor-1 deficiency. Scurvy was highest on our differential based on his constellation of signs and symptoms. He was admitted for further evaluation and care.

During his hospital stay, he was treated presumptively for scurvy with ascorbic acid. The vitamin C level later resulted at 0.1 mg/dL (reference range: 0.4–1.7 mg/dL). He was also treated for vitamin D deficiency after his vitamin D level resulted at 9.7 nanograms per milliliter (ng/mL) (30–50 ng/mL). He was evaluated by nutrition, physical therapy, physical medicine and rehabilitation, dermatology, and endocrinology.

Table. Summary of scurvy patient's lab results during his two emergency department visits.

Lab	Unit	Reference range	1 st ED Visit February 2021	2 nd ED Visit March 2021
Hemoglobin	g/dL	14–17.5	11.0	8.5
Mean corpuscular volume	fL	80.00–96.0	88.7	87.9
White blood cells	K/mL	4.0–11.0	7.7	3.6
Platelets	K/mL	150–450	321	306
Creatinine	mg/dL	0.80–1.40	0.69	0.66
Potassium	mmol/L	3.5–5.2	3.9	3.8
Magnesium	mg/dL	1.7–3.0	2.3	2.1
Calcium	mg/dL	8.6–10.0	8.4	7.8
Phosphorus	mg/dL	2.8–4.5	2.9	3.7
Albumin	g/dL	3.5–5.0	3.4	3.4
Total bilirubin	mg/dL	0.0–1.0	1.3	1.3

g/dL, gram per deciliter; *fL*, femtoliters; *K/mm³*, thousand cells per cubic millimeter; *mg/dL*, milligram per deciliter; *mmol/L*, millimole per liter; *ED*, emergency department.

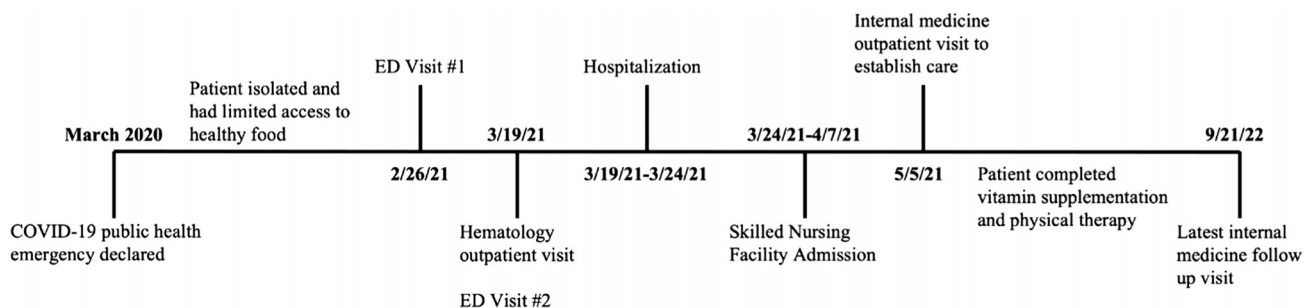


Figure Care timeline of a patient diagnosed with scurvy. *COVID-19*, coronavirus disease 2019; *ED*, emergency department.

He was ultimately discharged to a skilled nursing facility on ascorbic acid and ergocalciferol.

He completed treatment with ascorbic acid and high-dose ergocalciferol after 12 weeks. His symptoms, contractures, and skin findings resolved, and he was able to resume activities of daily living, including ambulation. He gained 5.4 kg. He continues to follow up with internal medicine and psychiatry. The figure above outlines the timeline of this case.

DISCUSSION

Scurvy is caused by vitamin C deficiency and manifests with multisystem organ involvement.^{1,3} The relationship between scurvy and citrus fruits was first described by James Lind in 1753, and subsequent research showed that the reason citrus fruits prevent scurvy is because they contain ascorbic acid.^{1,2} Humans are not able to derive ascorbic acid from glucose metabolism (unlike other animals); so, they need regular dietary intake of vitamin C.¹ In addition to citrus fruits, vitamin C is found in potatoes, tomatoes, berries, and green vegetables. It is important to note that cooking these items reduces their vitamin C content.⁴

This is probably why our patient developed scurvy despite eating tomatoes.

Ascorbic acid is involved in several important biosynthetic pathways including collagen assembly, amino acid metabolism, synthesis of norepinephrine, and iron absorption.¹ Accordingly, the clinical presentation of scurvy manifests with multiorgan system involvement reflective of the multitude of functions vitamin C plays in the body. After about 60–90 days without sufficient vitamin C, scurvy develops.⁵ Constitutional symptoms often present first with significant fatigue, progressive weakness, myalgias, and lassitude. Physical exam often displays specific cutaneous signs including follicular hyperkeratosis associated with coiled corkscrew hairs, perifollicular hemorrhages, petechiae, purpura, and ecchymoses. Other manifestations include gingival bleeding, joint pain, hemarthrosis, and anemia.^{1,5} Scurvy is curable with vitamin C repletion.^{2,5}

In addition to scurvy, our patient also had severe vitamin D deficiency. Humans need regular dietary intake of vitamin D and/or sunlight exposure. Foods naturally containing vitamin D include fish, eggs, mushrooms, and liver. In the

United States, vitamin D is often added to milk. Vitamin D deficiency is most well known for causing rickets in children and osteomalacia in adults. Vitamin D deficiency has also been associated with certain infections, autoimmune diseases, dementia, and depression.⁶⁻⁸

In industrialized countries, severe nutritional deficiencies are uncommon; however, many people have inadequate intake of micronutrients. Data from the National Health and Nutrition Examination Survey from 2005–2016 revealed that the prevalence of inadequate vitamin C intake was 46% and the prevalence of inadequate vitamin D intake was 95%.⁷

In this case, the COVID-19 pandemic led to unemployment and social isolation. As a result, the patient was only eating pizza bagels (which he made with bagels, tomato sauce, cheese, and pepperoni) and drinking water, which led to severe deficiencies of vitamins C and D. This case illustrates the importance of keeping nutritional deficiencies on the differential, especially when there are risk factors such as isolation and food insecurity.

CONCLUSION

Severe micronutrient deficiencies have significant clinical consequences. More specifically, vitamin C is involved in several important biosynthetic pathways, and deficiency results in a constellation of signs and symptoms that includes perifollicular hemorrhage, corkscrew hairs, purpura, gingivitis, arthralgias, poor wound healing, and fatigue. Having a high clinical suspicion for nutritional deficiencies is key to diagnosis and treatment.

The authors attest that their institution requires neither Institutional Review Board approval, nor patient consent for publication of this case report. Documentation on file.

Address for Correspondence: Alyssa A. Lombardi, MD, PhD, Temple University Hospital, Department of Emergency Medicine, 3401 North Broad Street, Jones Hall 10th Floor, Philadelphia, PA 19140. Email: alyssa.lombardi@tuhs.temple.edu

Conflicts of Interest: By the CPC-EM article submission agreement, all authors are required to disclose all affiliations, funding sources and financial or management relationships that could be perceived as potential sources of bias. The authors disclosed none.

Copyright: © 2024 Lombardi et al. This is an open access article distributed in accordance with the terms of the Creative Commons Attribution (CC BY 4.0) License. See: <http://creativecommons.org/licenses/by/4.0/>

REFERENCES

1. Levine M. New concepts in the biology and biochemistry of ascorbic acid. *N Engl J Med.* 1986;314(14):892–902.
2. Magiorkinis E, Beloukas A, Diamantis A. Scurvy: past, present and future. *Eur J Intern Med.* 2011;22(2):147–152.
3. Chaudhry SI, Newell EL, Lewis RR, et al. Scurvy: a forgotten disease. *Clin Exp Dermatol.* 2005;30(6):735–736.
4. Levine M, Rumsey SC, Daruwala R, et al. Criteria and recommendations for vitamin C intake. *JAMA.* 1999;281(15):1415–1423.
5. Hirschmann JV and Raugi GJ. Adult scurvy. *JAAD.* 1999;41(6):895–910.
6. Chang SW and Lee HC. Vitamin D and health: the missing vitamin in humans. *Pediatr Neonatol.* 2019;60(3):237–244.
7. Reider CA, Chung RY, Devarshi PP, et al. Inadequacy of immune health nutrients: intakes in US adults, the 2005-2016 NHANES. *Nutrients.* 2020;12(6):1735.
8. Holick MF. The vitamin D deficiency pandemic: approaches for diagnosis, treatment and prevention. *Rev Endocr Metab Disord.* 2017;18(2):153–165.

A Case Report of Unilateral Syphilitic Uveitis: A Diagnostic Challenge and the Role of Point-of-care Ultrasound

Susana Gutierrez-Luke, DO*
 Thijs Wolf, DO*
 Kyle Green, MD†
 Philip Graber, MD*

*University of Rochester Medical Center, Department of Emergency Medicine, Rochester, New York

†University of Rochester Medical Center, Department of Ophthalmology, Rochester, New York

Section Editors: Shadi Lahham, MD

Submission history: Submitted June 9, 2023; Revision received October 5, 2023; Accepted October 9, 2023

Electronically published January 9, 2024

Full text available through open access at http://escholarship.org/uc/uciem_cpem

DOI: [10.5811/cpem.1435](https://doi.org/10.5811/cpem.1435)

Introduction: Syphilis presents with diverse clinical manifestations, posing challenges for diagnosis, especially in the fast-paced emergency department (ED) setting.

Case Report: We report a rare case of unilateral syphilitic uveitis in an individual who had been sexually abstinent for 13 years. Using ocular point-of-care ultrasound in the ED, we successfully diagnosed this uncommon ocular manifestation.

Conclusion: Our case highlights the diagnostic challenges of ocular syphilis and emphasizes the crucial nature of timely identification. Collaborative efforts with specialties such as ophthalmology are essential in overcoming these challenges. [Clin Pract Cases Emerg Med. 2024;8(1)42–45.]

Keywords: *case report; syphilis; syphilitic uveitis; ocular ultrasound.*

INTRODUCTION

The incidence of syphilis has increased over the past two decades to 12.7 cases per 100,000, up from a low of 2.1 cases per 100,000 in 2001, representing a six-fold increase.¹ Syphilis, caused by the spirochete *Treponema pallidum*, is known as “the great mimicker” due to its various clinical presentations. Although rare, ocular syphilis can lead to devastating consequences. Timely administration of effective treatment is crucial in preventing irreversible visual impairment. Prompt evaluation of acute ocular pain and vision loss is particularly essential for monocular patients. Ocular point-of-care ultrasound (POCUS) is a rapid and dynamic imaging modality that emergency physicians can use to aid in diagnosis. We present the case of a 47-year-old man who, despite sexual abstinence for 13 years, was diagnosed with ocular syphilis with the assistance of POCUS.

CASE REPORT

A 47-year-old male was brought to the emergency department from his primary care physician’s office after

complaining of blurred vision and pain in his left eye for the prior four weeks. The patient initially dismissed these symptoms as a headache or optic neuritis, which he had previously experienced due to his medical history of multiple sclerosis. However, his vision gradually deteriorated over time, with the appearance of floaters and a significant increase in pain two weeks prior to presentation. On physical examination, the patient’s left eye had a visual acuity of 20/60 and a superior temporal field cut. Unfortunately, his right eye had previously suffered vision loss due to optic neuritis and could only perceive light. The intraocular pressure in the left eye was 14 millimeters of mercury (mm Hg), while the right eye’s pressure was 11 mm Hg. The patient’s neurologic examination was otherwise unremarkable.

The ophthalmologic exam revealed left conjunctival injection and ciliary flush. Dilated ophthalmic examination showed peripheral retinal whitening in the superonasal area of the left eye, as well as high-grade inflammation in the anterior chamber (3+ cell) and vitreous cavity (2+ cell) (Image 1). Laboratory testing revealed a rapid plasma reagin titer of 1:256, with the patient testing negative for HIV.

He was treated with intravenous penicillin 4 million units every 4 hours for 14 days. Ultrasonography of the eye revealed echogenic particles within the vitreous, with a possible undulating membrane that moved freely and swirled on dynamic exam (Image 2). The patient's retina was attached, and the diameter of the optic nerve was within normal limits.

USING OCULAR POINT-OF-CARE ULTRASOUND

To perform ocular POCUS the patient is placed supine; a tegaderm film is placed over the eye to eliminate air bubbles and then copious aqueous gel is spread over the closed eyelid. A linear transducer is used in both sagittal and axial planes of the eye with dynamic scanning. To get accurate views the clinician should hold the transducer like a pencil and brace their fifth digit over the patient's face gently to be mindful of how much pressure is being applied to the eye. Reducing the gain will show the walls of the globe and optic nerve sheath perfectly. Increasing the gain enables the contents of the vitreous body to be studied.

DISCUSSION

Syphilis has earned its reputation as the “great mimicker” due to its ability to cause symptoms that may imitate various diseases.² Ocular syphilis presents a challenge because of its diverse range of clinical features—it can be unilateral or bilateral, acute or chronic, and affect all or only certain anatomical locations.³ Point-of-care ultrasound can help distinguish between conditions that may be difficult to differentiate otherwise, owing to its portability, expedient bedside interpretation, and non-invasive nature. Syphilis is classified into four stages: primary, secondary, latent, and

tertiary syphilis.⁴ While ocular symptoms can occur at any stage of the disease, research indicates that they are most frequently seen in secondary syphilis.⁵

Population Health Research Capsule

What do we already know about this clinical entity?

Syphilis can present with ocular manifestations including uveitis, which is difficult to diagnose especially in the ED.

What makes this presentation of disease reportable?

Unilateral vitritis is a unique presentation of syphilis that can be seen on ocular point-of-care ultrasound (POCUS), which can be used as an adjunct when making this diagnosis.

What is the major learning point?

Ocular syphilis is difficult to diagnose. Ocular POCUS can aid with clinical suspicion. A multidisciplinary approach in collaboration with ophthalmologists is important.

How might this improve emergency medicine practice?

Emergency physicians can use POCUS to aid with diagnosis and clinical findings for ocular syphilis.

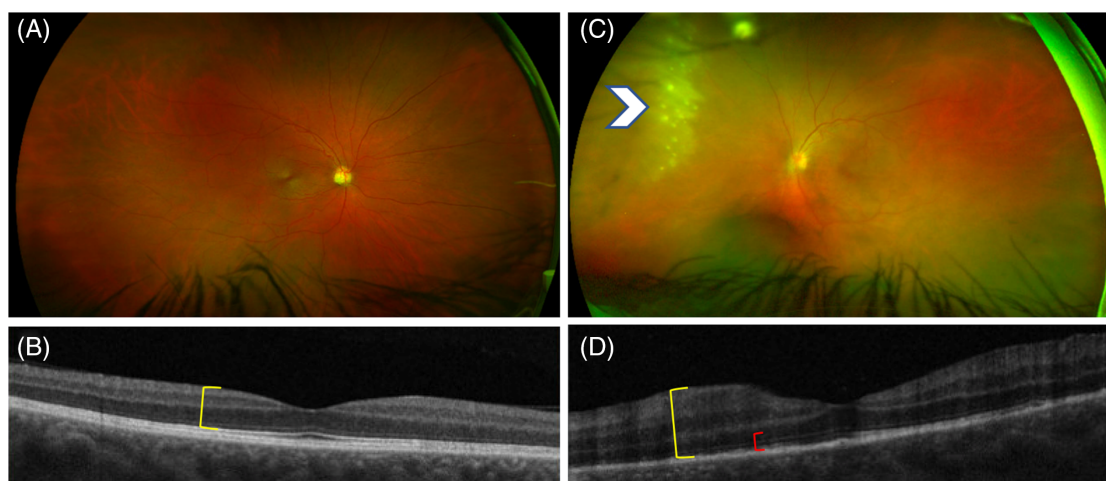


Image 1. Ophthalmic imaging of syphilitic retinitis. (A) Normal appearing fundus of the right eye captured with wide-field photography. (B) Accompanying optical coherence tomography of the macula in the right eye with slight thinning (yellow bracket) but otherwise normal-appearing retinal architecture. (C) Fundus photo of the left eye with area of superonasal retinal whitening and scattered focal white opacities (arrowhead) representing syphilitic retinitis (neurosyphilis). (D) Relative macular thickening of the left eye (yellow bracket) with an irregular photoreceptor layer (red bracket, compare to right eye).

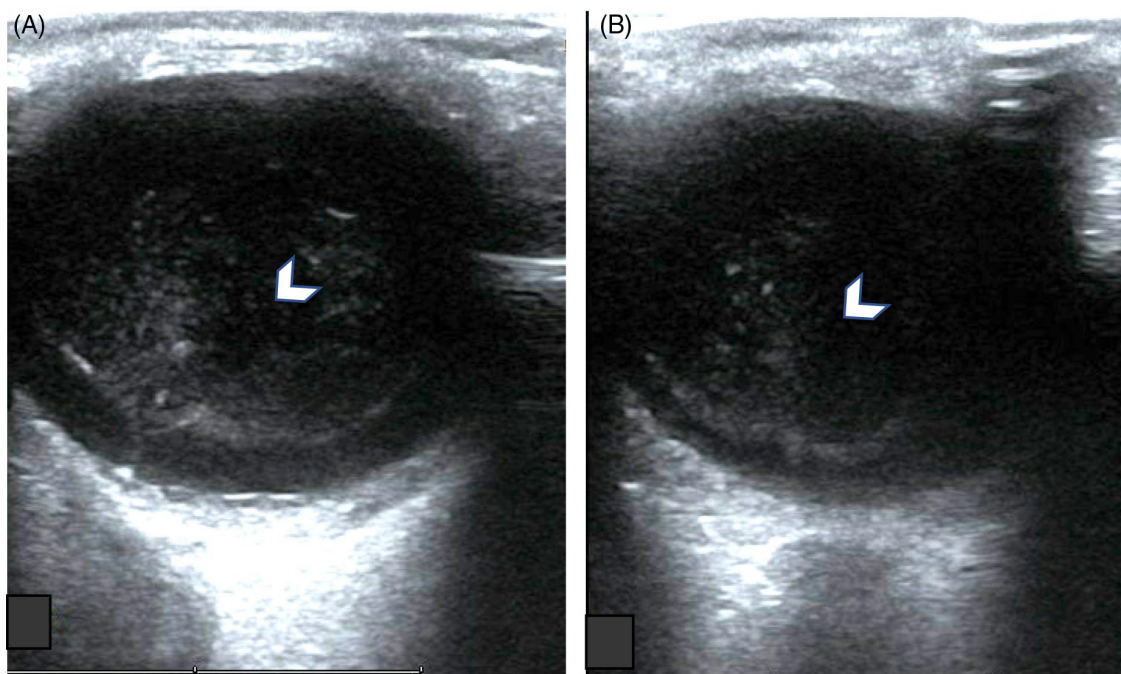


Image 2. Ocular point-of-care ultrasound using the linear probe. (A) Transverse view of the orbit. (B) Sagittal view of the orbit. Subtle echogenic material is seen floating in the vitreous (arrowheads).

Ocular manifestations account for 2–10% of infectious uveitis cases worldwide⁶ and can also be linked to neurosyphilis, with patients often presenting with eye pain, vision loss, and neurological changes.⁷ Retinitis, as a form of retinal involvement, qualifies as neurosyphilis since the retina is an extension of the central nervous system. If left untreated, the disease can progress to blindness, making it crucial to remain vigilant in certain high-risk populations. Men who have sex with men have been reported to have the highest transmission rates.¹ Diagnosing syphilitic eye infection can be challenging, as its presentation can overlap with many other conditions. A diagnosis typically requires an ophthalmic examination, combined with serological tests specifically for syphilis. Therefore, a thorough history, physical examination, and a high degree of clinical suspicion are critical for clinicians.

Strong indications for serological testing include a history of sexually transmitted diseases, high-risk sexual behavior, or inflammatory findings on ophthalmologic examination.⁸ The patient presented here had evidence of unilateral vitritis on POCUS, decreased visual acuity, vision loss, and ocular pain; he was immediately referred to a tertiary center to see an ophthalmologist. After the diagnosis, he was promptly treated with antibiotics, leading to resolution of his symptoms. Although nonspecific, sonographic imaging can aid in the differential diagnosis and follow-up of inflammatory and non-inflammatory pathologies of the posterior segment. Many posterior uveitis syndromes are due to underlying infections such as toxoplasmosis, syphilis,

toxocariasis, tuberculosis, cytomegalovirus retinitis, and ocular histoplasmosis syndrome.⁹ In addition, sonographic imaging can help detect complications of ocular syphilis, such as retinal detachments, optic neuritis, vitreous hemorrhage, or vitreous detachment. A multidisciplinary approach, particularly in collaboration with ophthalmologists, is crucial.

CONCLUSION

Ocular syphilis presents a diagnostic challenge due to its diverse clinical manifestations, often leading to misdiagnosis. Early diagnosis and treatment are crucial to prevent vision loss and other neurologic complications. A comprehensive evaluation that includes a thorough medical history, physical examination, ophthalmic examination, laboratory testing, and sonographic imaging can aid in the accurate diagnosis of ocular syphilis. Collaboration among primary care physicians, emergency physicians, and ophthalmologists is essential for the successful management of this condition.

The authors attest that their institution requires neither Institutional Review Board approval, nor patient consent for publication of this case report. Documentation on file.

Address for Correspondence: Dr. Susana Gutierrez-Luke, DO, University of Rochester Medical Center, Department of Emergency Medicine, 601 Elmwood Ave., Box 655, Rochester, NY 14642.
Email: Susana_gutierrez@urmc.rochester.edu

Conflicts of Interest: By the CPC-EM article submission agreement, all authors are required to disclose all affiliations, funding sources and financial or management relationships that could be perceived as potential sources of bias. The authors disclosed none.

Copyright: © 2024 Gutierrez-Luke et al. This is an open access article distributed in accordance with the terms of the Creative Commons Attribution (CC BY 4.0) License. See: <http://creativecommons.org/licenses/by/4.0/>

REFERENCES

- Centers for Disease Control and Prevention. Sexually Transmitted Disease Surveillance. Available at: <https://www.cdc.gov/std/statistics/2020/2020-SR-4-10-2023.pdf>. Accessed June 29, 2023.
- Deschenes J, Seamone C, Baines M. The ocular manifestations of sexually transmitted diseases. *Can J Ophthalmol*. 1990;25(4):177–85.
- Bollemeijer JG, Wieringa WG, Missotten TO, et al. Clinical manifestations and outcome of syphilitic uveitis. *Invest Ophthalmol Vis Sci*. 2016;57(2):404–11.
- Janier M, Hegyi V, Dupin N, et al. 2014 European guideline on the management of syphilis. *J Eur Acad Dermatol Venereol*. Dec 2014;28(12):1581–93.
- Eslami M, Nouredin G, Pakzad-Vaezi K, et al. Resurgence of ocular syphilis in British Columbia between 2013–2016: a retrospective chart review. *Can J Ophthalmol*. 2020;55(2):179–84.
- Bertrand PJ, Jamilloux Y, Ecochard R, et al. Uveitis: autoimmunity . . . and beyond. *Autoimmun Rev*. 2019;18(9):102351.
- Kiss S, Damico FM, Young LH. Ocular manifestations and treatment of syphilis. *Semin Ophthalmol*. 2005;20(3):161–7.
- Koundanya VV and Tripathy K. Syphilis ocular manifestations. *StatPearls*. 2022. Available at: <https://www.ncbi.nlm.nih.gov/pubmed/32644383>. Accessed June 29, 2023.
- Morais FB, Arantes TEFE, Muccioli C, et al. Ultrasonographic characteristics of active ocular toxoplasmosis. *Arq Bras Oftalmol*. 2019;82(4):317–21.

Cerebral Air Embolism After Endoscopy: A Case Report

James Whall, MD*
 Eli Besser, DO*
 Jaymes Lonzanida, MD*
 Ryan Roten, DO*

*Desert Regional Medical Center, Department of Emergency Medicine,
 Palm Springs, California

Section Editor: Christopher Sampson, MD

Submission history: Submitted May 15, 2023; Revision received October 27, 2023; Accepted November 2, 2023

Electronically published January 9, 2024

Full text available through open access at http://escholarship.org/uc/uciem_cpem

DOI: 10.5811/cpcem.1371

Introduction: Cerebral air embolisms are a rare but potentially devastating event where air enters the vascular system. Although commonly associated with intravascular catheters, they can arise from a variety of mechanisms including endoscopic procedures.

Case Report: We report the case of a 90-year-old woman who presented with focal neurologic deficits due to an air embolism after undergoing an esophagogastroduodenoscopy.

Conclusion: Cerebral air embolisms should be considered in patients who present to the emergency department with acute neurologic changes, especially after an endoscopic procedure. [Clin Pract Cases Emerg Med. 2024;8(1)46–48.]

Keywords: *case report; cerebral air embolism; endoscopy.*

INTRODUCTION

Air embolisms are characterized as unwanted air in the vascular system with potentially devastating morbidity and mortality.¹ More commonly associated with intravascular catheters, these events have been rarely reported in a variety of endoscopic procedures.² Although there are potentially devastating consequences of cerebral air embolisms (CAE), rapid diagnosis and treatment improves chances of recovery.³ Therefore, this rare complication should be considered in patients presenting for focal neurological deficits after endoscopic procedure.

CASE REPORT

A 90-year-old woman presented to the emergency department (ED) from an outpatient surgical center after undergoing an esophagogastroduodenoscopy (EGD) with right gaze deficit, left upper extremity flaccid paralysis, and aphasia. The patient received fentanyl and midazolam for sedation during the EGD, which were reversed with naloxone and flumazenil prior to arrival to the ED.

The patient's presenting vital signs were a temperature of 36.8° Celsius, heart rate of 75 beats per minute, respiratory rate of 16 breaths per minute, blood pressure of

130/75 millimeters of mercury, and pulse oximetry at 100% on room air. The physical exam was significant for forced gaze to the right, left lower facial weakness, left upper and lower extremity flaccid paralysis. The patient was able to intermittently follow commands but could not speak. She was rapidly taken for imaging. A computed tomography (CT) head without contrast found several sub-centimeter air embolisms in the right frontal parietal region (*Image 1*).

There was no evidence of intracranial hemorrhage or mass effect. A CT angiography of the head and neck did not reveal large vessel occlusions. A CT head with contrast found scattered right frontal, parietal, and temporal perfusion abnormalities compatible with ischemia (*Image 2*). Upon her return from imaging, the patient had seizure activity with rhythmic movement of the right upper extremity. The patient was treated with multiple doses of benzodiazepines and levetiracetam. She ultimately required intubation and was placed on a continuous infusion of midazolam.

Given the CT findings of CAE, the patient was placed in the left lateral Trendelenburg position, the fraction of inspired oxygen (FiO₂) was maximized to 100%, and dexamethasone was given upon recommendation from the neurologist. A transthoracic echocardiogram found a

normal ejection fraction, no patent foramen ovale, and no other significant findings. An electroencephalogram found no evidence of non-convulsive status epilepticus. The patient was transferred to a higher level of care for hyperbaric oxygen (HBO) therapy. Per the patient's family, the patient did not have improvement at the tertiary hospital and was placed on comfort care.

DISCUSSION

Cerebral air embolisms have been reported in a variety of endoscopic procedures; however, they remain uncommon. A recent review of inpatient procedures found a rate of 0.57/100,000 endoscopic procedures and specifically 0.44/100,000 for EGD.⁵ A review of recent literature found a case of CAE presenting as a tonic-clonic seizure in a 52-year-old man during an EGD and a 71-year-old man presenting with hemiparesis and dysarthria two hours after undergoing EGD.^{6,7} In total there appear to be only 13 reported cases of CAE after EGD, reinforcing its rarity.⁸

There are a variety of proposed mechanisms by which gas can enter vasculature during endoscopy including through the portal vein, exposed gastrointestinal vessels, or through adjacent veins of inflamed mucosa.² Theories on how air reaches the arterial system, and specifically the central nervous system, include paradoxical embolization through heart shunts such as a patent foramen ovale, retrograde flow through the superior vena cava, and through pulmonary veins if not filtered by the pulmonary system.⁸ The air then causes ischemia and injury by directly occluding vessels or by initiating an inflammatory cascade leading to thrombus formation.⁹

Although exceedingly rare, air embolism should be suspected in any patient with acute neurologic changes after an endoscopic procedure. A CT head may show evidence of cerebral gas embolism, as in this case. Gas may also be

Population Health Research Capsule

What do we already know about this clinical entity?

Cerebral air embolisms are a rare but potentially devastating condition caused by air entering the cerebral vasculature; they often present with stroke-like symptoms.

What makes this presentation of disease reportable?

Cerebral air embolism after esophagogastroduodenoscopy is extremely rare with only 13 previously reported cases.

What is the major learning point?

Air embolism should be suspected in any patient with acute neurologic changes after an endoscopic procedure. Treatment is hyperbaric oxygen therapy and repositioning.

How might this improve emergency medicine practice?

Awareness of this rare but serious disease process will lead to more rapid identification and treatment.

reabsorbed quickly and not be evident on imaging. Treatments include the following: 100% FiO₂ to reduce bubble volume and increase diffusion gradient; placement in the left lateral Trendelenburg position; and HBO.³ Hyperbaric oxygen therapy is the most critical intervention;

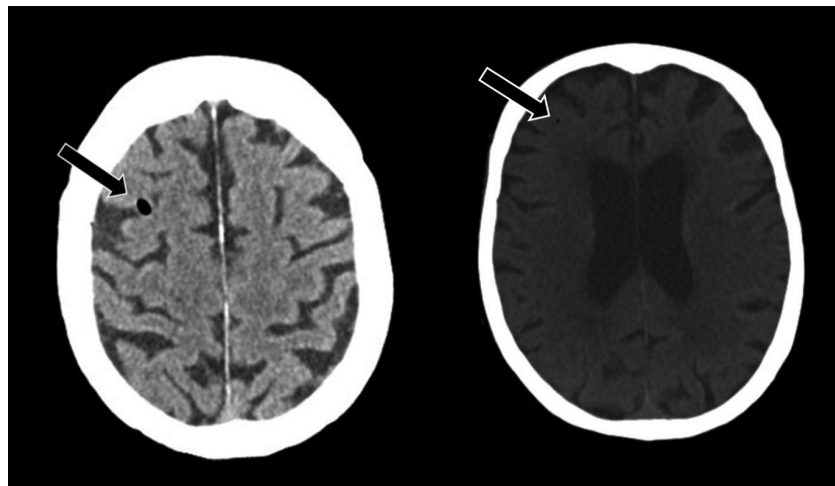


Image 1. Computed tomography head without contrast demonstrating air embolisms (arrow).

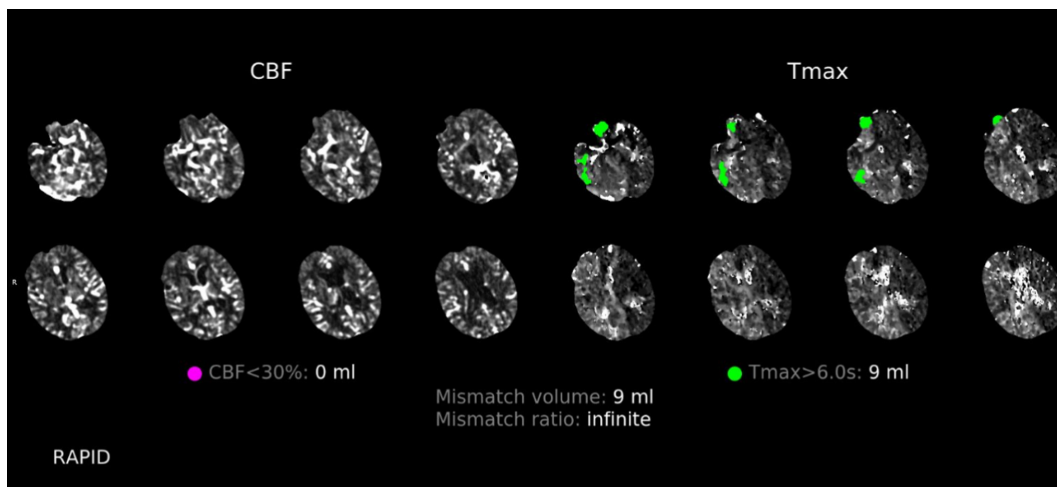


Image 2. Computed tomography head with contrast demonstrating right frontal, parietal, and temporal regions with perfusion deficits (green). These deficits are defined by a time-to-maximum delay of over six seconds for contrast to move to the tissue. Without intervention, these regions are a reliable estimate of the final infarction area. There are no regions with cerebral blood flow deficits (purple), which would indicate completed ischemia.⁴

CBF, cerebral blood flow; Tmax, time to maximum.

if started within five hours, HBO can double the chances of full recovery.¹⁰

CONCLUSION

Air embolisms are a rare but potentially devastating event. Air embolisms should be considered in patients who present to the ED with acute neurologic changes, especially after an endoscopic procedure. Rapid identification and treatment can lead to improved outcomes for the patient, highlighting the importance of increased awareness of this condition.

The authors attest that their institution requires neither Institutional Review Board approval, nor patient consent for publication of this case report. Documentation on file.

Address for Correspondence: James Whall, MD, Desert Regional Medical Center, Department of Emergency Medicine, 1150 N. Indian Canyon Dr., Palm Springs, CA 92262. Email: James.Whall@tenethealth.com

Conflicts of Interest: By the CPC-EM article submission agreement, all authors are required to disclose all affiliations, funding sources and financial or management relationships that could be perceived as potential sources of bias. James Whall, Eli Besser, Jaymes Lonzanida, and Ryan Roten are members of California ACEP.

Copyright: © 2024 Whall et al. This is an open access article distributed in accordance with the terms of the Creative Commons Attribution (CC BY 4.0) License. See: <http://creativecommons.org/licenses/by/4.0/>

REFERENCES

1. Lanke G and Adler DG. Gas embolism during endoscopic retrograde cholangiopancreatography: diagnosis and management. *Ann Gastroenterol.* 2019;32(2):156–67.
2. Donepudi S, Chavalitdhamrong D, Pu L, et al. Air embolism complicating gastrointestinal endoscopy: a systematic review. *World J Gastrointest Endosc.* 2013;5(8):359–65.
3. Cooper J. Treatment of endoscopy associated cerebral gas embolism. *Am J Gastroenterol.* 2018;113(12):1742–4.
4. Butcher K, Parsons M, Allport L, et al. Rapid assessment of perfusion–diffusion mismatch. *Stroke.* 2008;39(1):75–81.
5. Olaiya B and Adler DG. Air embolism secondary to endoscopy in hospitalized patients: results from the National Inpatient Sample (1998–2013). *Ann Gastroenterol.* 2019;32(5):476–81.
6. Popa D, Grover I, Hayden S, et al. Iatrogenic arterial gas embolism from esophagogastroduodenoscopy. *J Emerg Med.* 2019;57(5):683–8.
7. Pandurangadu AV, Paul JAP, Barawi M, et al. A case report of cerebral air embolism after esophagogastroduodenoscopy: diagnosis and management in the emergency department. *J Emerg Med.* 2012;43(6):976–9.
8. Farouji I, Chan KH, Abed H, et al. Cerebral air embolism after gastrointestinal procedure: a case report and literature review. *J Med Cases.* 2021;12(3):119–25.
9. Chuang DY, Sundararajan S, Sundararajan VA, et al. Accidental air embolism. *Stroke.* 2019;50(7):e183–6.
10. Murphy BP, Harford FJ, Cramer FS. Cerebral air embolism resulting from invasive medical procedures. Treatment with hyperbaric oxygen. *Ann Surg.* 1985;201(2):242–5.

Diagnosis and Management of *Amanita Phalloides* Toxicity in the Emergency Department Observation Unit: A Case Report

Matthew Tobias, MD*
Mary McGoldrick, MD†
Mary Rometti, MD*
Jessica Laub, PharmD*
Grant Wei, MD*
Denise Fernandez, MD*

*Rutgers Robert Wood Johnson Medical School, Department of Emergency Medicine, New Brunswick, New Jersey

†Columbia University Irving Medical Center, Department of Emergency Medicine, New York, New York

Section Editor: Lev Libet, MD

Submission history: Submitted April 3, 2023; Revision received October 2, 2023; Accepted October 9, 2023

Electronically published January 9, 2024

Full text available through open access at http://escholarship.org/uc/uciem_cpccem

DOI: 10.5811/cpcem.1268

Introduction: Mushroom toxicity is an important etiology of acute liver injury in a patient with gastrointestinal symptoms.

Case Report: We present the case of a male patient presenting to the emergency department (ED) with gastrointestinal distress who was placed under ED observation for elevated liver function tests. During his hospital course, it was revealed he had consumed wild mushrooms believed to be *Amanita phalloides*.

Conclusion: While mushroom ingestion and subsequent toxicity are rare, a high index of suspicion in foraging hobbyists is essential to arriving at the correct diagnosis and directing the patient to the appropriate management. [Clin Pract Cases Emerg Med. 2024;8(1)49–52.]

Keywords: toxicology; mushroom; amanita; case report.

INTRODUCTION

Of the estimated 100 mushroom species that are toxic to humans, *Amanita phalloides* and others containing amatoxin are responsible for 95% of mushroom poisoning fatalities worldwide.^{1,2} In fact, one *A phalloides* mushroom often contains α -amanitin exceeding the lethal dose of about 0.1 milligrams per kilogram (mg/kg) of body weight.^{3,4} Disturbingly, mushroom species can be easily mistaken for one another, with *A phalloides* (death cap) often misidentified as the harmless paddy straw mushroom (*Volvariella volvacea*).⁵ We report a case of mushroom poisoning with delayed identification, ultimately diagnosed in our emergency department (ED) observation unit after multiple interviews with the patient. We discuss the pathophysiology and current management of mushroom toxicity and highlight the importance of considering this diagnosis in patients presenting with severe acute liver injury.

CASE REPORT

A 59-year-old male with a history of hypertension and prediabetes presented to the ED in the morning with diffuse, crampy abdominal pain associated with vomiting and profuse diarrhea. His symptoms began five hours prior to arrival. He reported that the previous night he had eaten a dinner of fish and vegetable curry which tasted “off.” Initial vital signs showed a blood pressure of 153/94 millimeters of mercury, pulse of 83 beats per minute, respiratory rate of 18 respirations per minute, a temperature of 98.2° Fahrenheit, and an oxygen saturation of 98% on room air. Physical examination was unremarkable. He lacked any abdominal tenderness, appeared to be euvolemic, and was in no acute distress.

Treatment began with a one-liter bolus of intravenous (IV) normal saline, 8 milligrams (mg) of IV ondansetron, and 15 mg of IV ketorolac. Initial blood analysis is noted in the [table](#). Outpatient blood analysis from the month prior showed normal liver function testing (LFT) and creatinine (Cr) of 0.8.

Right upper quadrant ultrasound was ordered and showed hepatic steatosis, as well as cholelithiasis with biliary sludge, but no evidence of cholecystitis. Six-hour repeat basic metabolic panel (BMP) after fluid hydration did not demonstrate any significant change. The patient was tolerating fluids but complained of persistent abdominal pain and watery diarrhea. He was placed in the ED observation unit pending a computed tomography of the abdomen and pelvis (CTAP) with contrast and continued IV hydration.

Overnight, the patient’s symptoms continued. The CTAP showed nonspecific fatty stranding of the left adrenal gland, nonspecific fatty liver disease, and partial visualization of cystic lung disease. The morning laboratory analysis at 24 hours began to show significant and worsening abnormalities in BMP and LFT (table). The patient remained hemodynamically stable, with an unchanged exam. Arrangements were made for admission, and general surgery was consulted for acute liver injury.

On repeating his diet history to the consulting team, the patient revealed he used to forage for mushrooms in his home country. In fact, two days before symptom onset, he had eaten several mushrooms from his yard. He felt well afterward; so he consumed additional mushrooms in a fish curry that he later thought was the cause of his symptoms. Upon reevaluation, he reported 8/10 abdominal pain, 15–20 episodes of watery stools, profuse vomiting, anxiety, diaphoresis, and insomnia. Vital signs remained within normal limits, but his repeat abdominal exam showed mild, diffuse tenderness. He had anicteric sclera but lacked jaundice. Medical toxicology service was consulted for management of liver injury secondary to mushroom ingestion, and the patient was able to provide a photograph of the species he had consumed. While the mushroom itself was unavailable for testing, the photograph was reviewed with a mycologist and suspected to be *A phalloides* (Image).

Population Health Research Capsule

What do we know about this clinical entity?
Mushroom poisoning can result in liver failure and death. Early clinical presentation includes nonspecific gastrointestinal (GI) symptoms that can be easily missed.

What makes this presentation of disease reportable?
We identified this case of mushroom poisoning on reassessment of the patient in the setting of an emergency department observation unit (EDOU).

What is the major learning point?
Although rare, mushroom toxicity is an important consideration for patients presenting with GI distress and liver injury.

How might this improve emergency medicine practice?
Placing persistently symptomatic patients in an ED OU can provide the ideal location to reveal and rapidly act on critical diagnoses.

Treatment for mushroom toxicity was initiated with N-acetylcysteine (NAC) 21-hour IV protocol (150 mg/kg loading dose over 60 minutes followed by 50 mg/kg over four hours), high-dose IV penicillin at one million units per kg per day (U/kg/day) every four hours, activated charcoal (1g/kg by mouth), and IV hydration. His acetaminophen level,

Table Significant laboratory findings throughout patient’s hospital course.

	Reference range	Units	Initial presentation	6 hours	24 hours	Peak
Potassium	3.7–5.2	mEq/L	5.7	4.5	6.5	
Bicarbonate	23–29	mEq/L	19	18.4	16.7	
Glucose	70–100	mg/dL	216			
Creatinine	0.6–1.3	mg/dL	1.3	1.3	2.2	
Blood urea nitrogen	6–24	mg/dL	27	30		
Alanine transaminase	4–36	U/L	78		1,450	7,000
Aspartate aminotransferase	8–33	U/L	63		996	1734
Alkaline phosphatase	20–130	U/L	110		79	110
Total bilirubin	0.1–1.2	mg/dL	0.6		1.5	3.9
Prothrombin time	11–13.5	seconds				50.7
International normalized ratio	0.8–1.1					4.6

mEq/L, milliequivalents per liter; *mg/dL*, milligrams per deciliter; *U/L*, units per liter.



Image. Suspected *Amanita phalloides* mushroom picked by the patient.

ordered when his worsening transaminitis was identified, was negative. The U.S. Food and Drug Administration's emergency criteria for silibinin, an amatoxin antidote, were met, and it was initiated on day two as a 5 mg/kg loading dose over one hour followed by a continuous infusion of 20 mg/kg/day. The patient remained without encephalopathic changes. Over the course of several days, his laboratory abnormalities peaked, and their values can be seen in the table. After evaluation by the hepatobiliary service, he was transferred to a regional liver transplant center. Following transfer, treatment with NAC was continued. As LFTs continued to decline, the patient was discharged on hospital day seven without the need for transplant.

DISCUSSION

Poisoning from amatoxin-containing mushrooms, such as *A phalloides*, is rare worldwide with the highest incidence in western Europe where 50–100 cases are reported annually.³ However, this number may be increasing as many people found themselves discovering new hobbies amid the coronavirus disease 2019 pandemic. A recent retrospective review discusses an outbreak of mushroom poisoning in Israel in 2020, while several news reports during the pandemic described an increase in calls to poison control centers after mushroom foraging.^{6–9} This increase in foraging among amateur hobbyists may result in higher rates of mushroom poisoning presenting unknowingly to EDs.

Of the 15–20 cyclopeptides contained in *A phalloides*, two toxins are responsible for the majority of symptoms, which explains the different phases of the classic clinical course. The phallotoxin phalloidin is responsible for the initial gastrointestinal dysfunction seen 6–12 hours following ingestion and comprising phase I of toxicity. Based on his initial symptoms, this patient likely presented to the ED

during or just after this initial phase of poisoning. Phase III toxicity is hepatic, renal, and neurologic sequelae (such as encephalopathy) caused by the amatoxin α -amanitin, a heat stable ribonucleic acid polymerase inhibitor that is absorbed by hepatocytes and disrupts protein synthesis. This can be seen within 2–6 days following ingestion. In the interim period of phase II, there is short-lived clinical improvement concurrent with the onset of hepatic injury.³ Given his increasing transaminitis the morning following presentation, this patient likely was entering the third phase when he was transitioned to the ED observation unit.

Diagnosing mushroom toxicity in the ED relies on thorough history-taking and can be easily missed as earlier symptoms mimic gastroenteritis. Unfortunately, by the time Phase III of mushroom toxicity occurs, a patient may exhibit complications such as hepatorenal syndrome, hepatic encephalopathy, and fulminant liver failure. In the ED, many other potentially fatal diagnoses in the patient with undifferentiated abdominal pain may be revealed with the assistance of abdominal imaging. However, in the case of mushroom toxicity, there is no structural abnormality to be revealed by imaging. Unlike for most cases of gastroenteritis, laboratory testing can be useful for these patients. Increasingly elevated transaminases two to three days following mushroom ingestion is the classic course for amatoxin.⁴ However, while laboratory testing may alert a clinician that something is amiss, a detailed history is vital to uncovering this diagnosis.

Management of the mushroom-poisoned patient is multifactorial. Although there is no single amatoxin antidote, supportive care with fluid and electrolyte repletion is the cornerstone of treatment. Activated charcoal may be of use in blocking toxin reabsorption for a longer time course due to enterohepatic recycling, which continues for up to five days post ingestion.⁴ Animal studies have shown that 1g/kg (1 million U/kg) penicillin G may be beneficial in competing with amatoxin for transport into the hepatocytes. Similarly, NAC is also recommended for its protective effects on the liver, favorable side-effect profile, and impact on mortality. The exact mechanism of action remains unclear for either drug as an amatoxin antidote.³ Silibinin, branded as Legalon SIL, is an IV compound isolated from milk thistle extract that competitively inhibits the transporter responsible for the enterohepatic circulation of α -amanitin and may lower the incidence of mortality.^{2,3} In cases where these treatments fail, the only remaining therapy is liver transplantation for fulminant hepatic failure.

CONCLUSION

Mushroom poisoning is an uncommon toxicologic emergency. Symptoms are non-specific and delayed in presentation, while imaging is of little use and laboratory testing may only raise red flags once hepatic damage is already well underway. Emergency clinicians must rely on

detailed history-taking to make this crucial diagnosis and institute treatments in a timely manner. Finally, this case highlights the utility of an ED observation unit in identifying diagnoses that may not have been evident due to their nonspecific initial presentation.

The Institutional Review Board approval has been documented and filed for publication of this case report.

Address for Correspondence: Denise Fernandez, MD, Rutgers Robert Wood Johnson Medical School, Department of Emergency Medicine, 1 Robert Wood Place, MEB 288, New Brunswick, NJ 08901. Email: df555@rwjms.rutgers.edu

Conflicts of Interest: By the *CPC-EM* article submission agreement, all authors are required to disclose all affiliations, funding sources and financial or management relationships that could be perceived as potential sources of bias. The authors disclosed none.

Copyright: © 2024 Tobias et al. This is an open access article distributed in accordance with the terms of the Creative Commons Attribution (CC BY 4.0) License. See: <http://creativecommons.org/licenses/by/4.0/>

REFERENCES

1. Tran HH and Juergens AL. Mushroom toxicity. *StatPearls [Internet]*. 2023. Available at: <https://www.ncbi.nlm.nih.gov/books/NBK537111/>. Accessed January 10, 2023.
2. Mengs U, Pohl RT, Mitchell T. Legalon SIL: the antidote of choice in patients with acute hepatotoxicity from amatoxin poisoning. *Curr Pharm Biotechnol*. 2012;13(10):1964–70.
3. Goldfrank LR. Mushrooms. In: Goldfrank L and Flomenbaum N (Eds.), *Goldfrank's Toxicologic Emergencies (11e)*. 2019, New York, NY: McGraw Hill, New Brunswick, New Jersey, USA.
4. Garcia J, Costa VM, Carvalho A, et al. Amanita phalloides poisoning: mechanisms of toxicity and treatment. *Food Chem Toxicol*. 2015;86:41–55.
5. Horowitz BZ and Moss MJ. Amatoxin mushroom toxicity. *StatPearls [Internet]*. 2023. Available at: <https://www.ncbi.nlm.nih.gov/books/NBK431052/>. Accessed January 10, 2023.
6. Lurie Y, Lewinsohn D, Kurnik D. An outbreak of mushroom poisoning in Israel during the 2020 fall and winter season: an unexpected outcome of COVID-19 restrictions? *Clin Toxicol (Phila)*. 2022;60(3):386–8.
7. McNaughton J. Wild mushroom foraging booms during coronavirus pandemic, as poison hotline calls spike. 2020. *ABC News*. Available at: https://www.abc.net.au/news/rural/2020-05-12/mushroom-forage-coronavirus-death-cap-poison-hotline/12232412?utm_campaign=abc_news_web&utm_content=link&utm_medium=content_shared&utm_source=abc_news_web. Accessed August 7, 2022.
8. Gibson S. New England Poison Control Center staying busy due to abundance of mushrooms. 2021. *New Hampshire Public Radio*. Available at: <https://www.nhpr.org/nh-news/2021-08-09/new-england-poison-control-center-staying-busy-due-to-abundance-of-mushrooms>. Accessed August 7, 2022.
9. The Canadian Press. Ontario Poison Centre sees rise in calls related to mushroom foraging. 2020. *National Post*. Available at: <https://nationalpost.com/pmnn/news-pmnn/canada-news-pmnn/ontario-poison-centre-sees-rise-in-calls-related-to-mushroom-foraging>. Accessed August 7, 2022.

Lithium Toxicity: A Case Report of Toxicity Resulting in a Third-degree Heart Block

Samantha L. Gaetani, MD*
 Alexandra M. Amaducci, DO†
 Derek Fikse, DO†
 Andrew L. Koons, DO†

*Lehigh Valley Health Network/University of South Florida Morsani College of Medicine, Department of Emergency and Hospital Medicine, Allentown, Pennsylvania

†Lehigh Valley Health Network/University of South Florida Morsani College of Medicine, Department of Emergency and Hospital Medicine, Division of Medical Toxicology, Allentown, Pennsylvania

Section Editor: Shadi Lahham, MD

Submission history: Submitted June 16, 2023; Revision received August 28, 2023; Accepted November 1, 2023

Electronically published January 23, 2024

Full text available through open access at http://escholarship.org/uc/uciem_cpccem

DOI: 10.5811/cpcem.1442

Introduction: Lithium is a medication used to treat bipolar disorder. It has a narrow therapeutic index, which frequently causes toxicity in patients.

Case Report: We present an unusual case of a 66-year-old female with a history of bipolar disorder on chronic lithium, who developed a third-degree heart block, encephalopathy, and acute renal failure because of lithium toxicity.

Conclusion: This case highlights a rare but life-threatening case of complete heart block in the setting of lithium toxicity. The patient was treated with hemodialysis and pacemaker placement. [Clin Pract Cases Emerg Med. 2024;8(1)53–56.]

Keywords: *case report; lithium toxicity; heart block; therapeutic index; hemodialysis; pacemaker replacement.*

INTRODUCTION

Lithium has been approved by the United States Food and Drug Administration for treatment of bipolar 1 disorder since 1970.^{1,2} While its mechanism of action is incompletely understood, it is thought to act as a mood stabilizer by affecting neuronal plasticity.¹ Lithium mimics sodium and uses the sodium channels in the body, specifically in the kidneys, to be transferred across cell membranes.³ It is also excreted similarly to sodium through the proximal tubules of the kidney.³ Lithium is rapidly absorbed in the gastrointestinal tract, reaching peak concentrations in 1–2 hours, and its half-life is 14–30 hours.⁴ The normal dose is 300–2,400 milligrams (mg) daily.⁴

While lithium can be beneficial as a mood stabilizer, its narrow therapeutic index frequently causes toxicity in patients.⁵ The therapeutic range for lithium is 0.6–1.2 milliequivalents per liter (mEq/L), and toxicity occurs when concentrations rise to 1.5 mEq/L or greater.⁴ The acute toxic

dose of lithium is 1 mEq per kilogram (kg) or 40 mg/kg, which is about 20–30 tablets; acute on chronic and chronic toxicity can occur as well.⁴ Chronic toxicity results from drug interactions or changes to lithium excretion.⁵ For instance, dehydration, sodium depletion, or excessive sodium resorption can lead to chronic lithium toxicity.⁵ Third-degree heart block as a result of lithium toxicity has only twice before been described in the literature.^{6,7}

CASE REPORT

A 66-year-old female with a past medical history of hypothyroidism, type 2 diabetes, hypertension, and bipolar disorder presented to the emergency department (ED) for fatigue, depression, and tremors. Most of the history was provided by the patient's son, who estimated that the symptoms had been occurring for 3–7 days. The patient also reported decreased appetite and decreased fluid intake. She

reported taking her medications as prescribed. Her home medications included lithium 300 mg twice daily, levothyroxine 88 micrograms daily, bisoprolol-hydrochlorothiazide 10–6.25 mg daily, and atorvastatin 80 mg daily. The patient denied any abdominal pain, nausea, vomiting, dizziness, dysuria, fever, headache, syncope, or shortness of breath.

On initial presentation, the patient had a heart rate of 34 beats per minute, blood pressure 157/59 millimeters of mercury, oxygen saturation of 100% on room air, respiratory rate of 14 breaths per minute, and a temperature of 97.5° Fahrenheit. On her initial physical exam pertinent findings included somnolence, although she answered questions appropriately, mild tremors of the upper and lower extremities, and marked bradycardia.

An electrocardiogram was completed (Image 1) and demonstrated a third-degree heart block. A lithium concentration of greater than 3 mEq/L (reference range: 0.60–1.2 mEq/L, with 3 mEq/L the maximum detectable in our laboratory) was detected. A send-out test determined her initial lithium concentration to be 3.8 mEq/L (0.5–1.2 mEq/L). Other pertinent abnormal labs included sodium 130 mEq/L (135–145 mEq/L), creatinine 1.89 mg per deciliter (dL) (0.40–1.10 mg/dL), and glomerular filtration rate 27 (reference range: >60). Given the bradycardia with prolonged QRS complexes and QTc intervals with lithium toxicity, our bedside medical toxicology consultation service recommended normal saline, two ampules of sodium bicarbonate, and two grams of magnesium sulfate. However, the patient developed worsening encephalopathy, and

hemodialysis (HD) was recommended. She was taken to the catheterization lab to have a temporary transvenous pacemaker placed.

Population Health Research Capsule

What do we already know about this clinical entity?

Lithium can be beneficial as a mood stabilizer in patients with bipolar disorder, but its narrow therapeutic index frequently causes toxicity.

What makes this presentation of disease reportable?

Third-degree heart block as a result of lithium toxicity has only twice before been reported in the literature.

What is the major learning point?

Cardiotoxic effects of lithium toxicity are rare but can be life-threatening.

How might this improve emergency medicine practice?

Clinicians should be aware that lithium's mechanism of action is incompletely understood and can present with a multitude of toxicities.

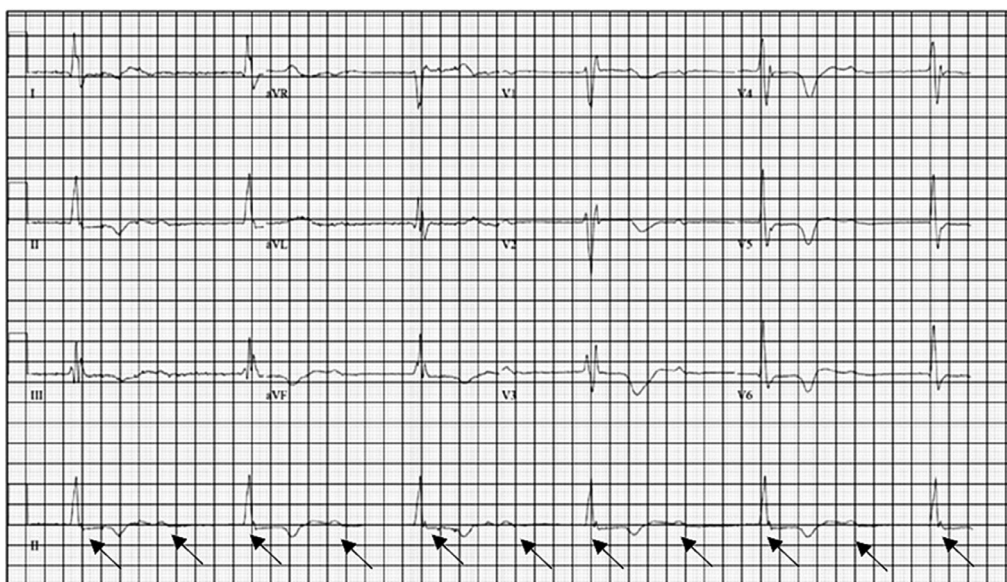


Image 1. This electrocardiogram shows third-degree heart block at a rate of 33 beats per minute. There is QRS complex widening at 174 milliseconds (ms) with Right Bundle Branch Block and a prolonged QTc interval at 560 ms. (Normal QRS is 70–100 ms and normal QTc less than 450 ms for males and less than 470 ms for females). The p-waves (indicated by black arrows) do not line up with the QRS complexes, thus demonstrating a third-degree heart block.

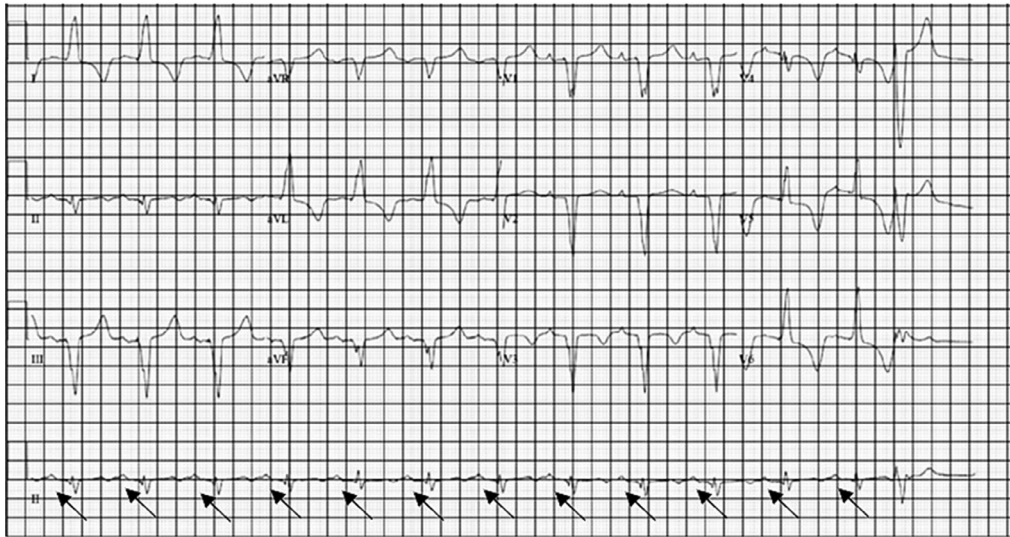


Image 2. Electrocardiogram after a permanent pacemaker was placed. Atrial-sensed ventricular-paced rhythm with occasional premature ventricular complexes at a rate of 82 beats per minute. There is a p-wave (black arrows) before every QRS complex with regular intervals, indicating the patient is no longer in third-degree heart block.

Throughout her intensive care unit (ICU) stay, the patient underwent emergent dialysis, which resulted in improvement of her mental status and laboratory abnormalities. The third-degree heart block, however, had not resolved. A permanent Medtronic DC pacemaker was subsequently placed (Image 2).

DISCUSSION

Lithium is a xenobiotic that can cause severe toxicity when it exceeds therapeutic range.⁵ The lithium concentration in our patient was 3.8 mEq/L. While she had been on lithium for many years, over the prior several days she had decreased oral intake. This likely led to dehydration and renal dysfunction. In addition, this patient was on hydrochlorothiazide, potentially contributing to reduced renal elimination and dehydration with subsequent lithium accumulation. Symptoms of toxicity occur on a spectrum. Mild toxicity may manifest as nausea, vomiting, tremors, drowsiness, hyperreflexia, hypertonia, fasciculations, slurred speech, ataxia, and apathy, while severely poisoned patients may have coma, seizures, hyperthermia, delirium, and death.⁴

Lithium can also cause nephrogenic diabetes insipidus, hyperparathyroidism, hypothyroidism, and rarely hyperthyroidism.⁴ Our patient was initially somnolent and had tremors consistent with mild symptoms; however, she became encephalopathic and hemodynamically unstable leading to the decision to start HD. Hemodialysis is the mainstay of treatment for severe lithium toxicity in patients with seizures, a severely abnormal mental status, hemodynamic instability, or in a patient

who is unable to excrete lithium through the kidneys.^{4,8}

This case is unusual due to the associated third-degree heart block. Lithium toxicity infrequently causes cardiotoxicity.⁹ There have been reports of cardiac arrhythmias, t-wave changes, and even an unmasking of Brugada syndrome.⁹ T-wave flattening/inversions and depressed ST segments can commonly be seen with lithium toxicity; however, bradycardia, sinus node arrest, third-degree heart block, and unmasking of Brugada morphology have rarely been reported.^{4,9} These cardiotoxic effects are believed to be caused by lithium interacting with sodium channels in the cardiac tissue resulting in dysfunction in the cardiac membrane physiology.⁹ Similar to the neurologic manifestation of lithium poisoning termed SILENT (Syndrome of Irreversible Lithium-Effectuated NeuroToxicity), it does not immediately or potentially ever resolve with removal of lithium.¹⁰ It may be reasonable to hypothesize that the same cardiotoxic effects are caused and persist despite removal of lithium, although the mechanism is not known.

CONCLUSION

While lithium is a medication that has been used for more than 50 years, its mechanism of action is still incompletely understood, and it can present with a multitude of toxicities. This case highlights a rare but life-threatening case of complete heart block in the setting of lithium toxicity.

Patient consent has been obtained and filed for the publication of this case report.

Address for Correspondence: Andrew L. Koons, DO, Lehigh Valley Health Network/ USF Morsani College of Medicine, Department of Emergency and Hospital Medicine, Division of Medical Toxicology, 2545 Schoenersville Road, EM Research, 4th Floor, South Wing, Bethlehem, PA 18017. Email: Andrew.Koons@lvhn.org

Conflicts of Interest: By the CPC-EM article submission agreement, all authors are required to disclose all affiliations, funding sources and financial or management relationships that could be perceived as potential sources of bias. The authors disclosed none.

Copyright: © 2024 Gaetani et al. This is an open access article distributed in accordance with the terms of the Creative Commons Attribution (CC BY 4.0) License. See: <http://creativecommons.org/licenses/by/4.0/>

REFERENCES

1. Won E and Kim YK. An oldie but goodie: lithium in the treatment of bipolar disorder through neuroprotective and neurotrophic mechanisms. *Int J Mol Sci.* 2017;18(12):2679.
2. West-Ward Pharmaceuticals. Lithium Carbonate. Highlights of Prescribing Information. 2018. Available at: https://www.accessdata.fda.gov/drugsatfda_docs/label/2018/017812s033,018421s032,018558s027lbl.pdf. Accessed June 10, 2023.
3. Wen J, Sawmiller D, Wheeldon B, et al. A Review for lithium: pharmacokinetics, drug design, and toxicity. *CNS Neurol Disord Drug Targets.* 2019;18(10):769–78.
4. Anderson IB, Benowitz NL, Blanc PD, et al. *Poisoning & Drug Overdose* (293-5). Olson K ed. 7th ed. San Francisco, CA: McGraw Hill Education; 2018.
5. Baird-Gunning J, Lea-Henry T, Hoegberg LCG, et al. Lithium poisoning. *J Intensive Care Med.* 2017;32(4):249–63.
6. Serinken M, Karcioglu O, Korkmaz A. Rarely seen cardiotoxicity of lithium overdose: complete heart block. *Int J Cardiol.* 2009;132(2):276–8.
7. Maddala RNM, Ashwal AJ, Rao MS, et al. Chronic lithium intoxication: varying electrocardiogram manifestations. *Indian J Pharmacol.* 2017;49(1):127–9.
8. Decker BS, Goldfarb DS, Dargan PI, et al. Extracorporeal treatment for lithium poisoning: systematic review and recommendations from the EXTRIP Workgroup. *Clin J Am Soc Nephrol.* 2015;10(5):875–88.
9. Mehta N and Vannozzi R. Lithium-induced electrocardiographic changes: a complete review. *Clin Cardiol.* 2017;40(12):1363–7.
10. Fernandes Santos C and Gomes R. Syndrome of irreversible lithium-effectuated neurotoxicity (SILENT): a review. *Eur Psychiatry.* 2022;65(Suppl 1):S717.

Median Arcuate Ligament Syndrome in 17-year-old Male with Abdominal Pain: Case Report

Jessica Doctor, MD
Jonathan Henderson, MD

San Antonio Uniformed Services Health Education Consortium, Fort Sam Houston, TX

Section Editor: Melanie S. Heniff, MD, JD

Submission history: Submitted July 7, 2023; Revision received October 16, 2023; Accepted November 1, 2023

Electronically published January 23, 2024

Full text available through open access at http://escholarship.org/uc/uciem_cpce

DOI: 10.5811/cpcem.1510

Introduction: Median arcuate ligament syndrome (MALS) is an uncommon cause of chronic abdominal pain resulting from the compression of the celiac artery. It shares symptoms with chronic functional abdominal pain, a more common cause of pediatric chronic abdominal pain. Typically found in middle-aged females, MALS is a diagnosis of exclusion.

Case Report: A 17-year-old male who presented to the emergency department with periumbilical pain for two months was subsequently diagnosed with MALS through computed tomography angiography. Further vascular and gastroenterology evaluations confirmed the diagnosis, ruling out other common causes of chronic abdominal pain. The patient received non-operative treatment in the form of endoscopic ultrasound celiac plexus block, with the possibility of surgical management if necessary.

Conclusion: Median arcuate ligament syndrome is an uncommon cause of chronic abdominal pain that is difficult to differentiate from other causes, especially in pediatric patients. It should be considered in the patient whose previous workup was not conclusive and symptom management had failed. Management is multidisciplinary with non-operative management preferred initially. If there is no improvement, surgical management should be considered. [Clin Pract Cases Emerg Med. 2024;8(1)57–59.]

Keywords: *median arcuate ligament syndrome; angiogram; case report.*

INTRODUCTION

Median arcuate ligament syndrome (MALS), also known as celiac artery compression syndrome or Dunbar syndrome, is characterized by the compression of the celiac artery by the median arcuate ligament—a fibrous arch connecting the diaphragmatic crura. This rare condition presents with symptoms of foregut ischemia, including postprandial or exercise-induced abdominal pain, nausea, vomiting, and weight loss.¹ These symptoms often overlap with those of chronic functional abdominal pain (CFAP), commonly attributed to conditions such as irritable bowel syndrome (IBS).² The etiology and pathophysiology of MALS remain poorly understood but are believed to involve both ischemic and neuropathic components. While perfusion to the intestines is usually unaffected due to collateral circulation, the proximity of the celiac ganglion to the compressed celiac artery and the observed symptomatic improvement

following interventions targeting the celiac ganglion suggest a neuropathic contribution. Median arcuate ligament syndrome typically presents more commonly in females (4:1 ratio) and is more common between the ages of 30–50 years in those with a thin habitus. It can occur in pediatric patients.¹

CASE REPORT

A 17-year-old, otherwise healthy White male was brought in by his mother to the emergency department (ED) for abdominal pain that had been constant for two months. He was previously seen at an urgent care and unsuccessfully treated for a urinary tract infection despite having normal urinalysis. He had followed up with his pediatrician and was referred to the ED for further computed tomography (CT) imaging and laboratory studies. He described his pain as sharp, located in the umbilical region, and worse with

physical activity. Pain was not worse with eating. He'd had intermittent nausea and vomiting since he was a child. The patient was notably thin and had a lifetime of short stature and being underweight, but his growth curve was otherwise tracking. He typically had one to two bowel movements daily without any pain relief.

Due to concerns for a vascular etiology of his abdominal pain, a CT angiogram of the abdomen and pelvis was obtained in the ED, which demonstrated narrowing of the origin of the celiac artery at the location of median arcuate ligament and post stenotic dilation (*Image*). The celiac artery was otherwise patent. The rest of his CT showed normal findings. His other workup in the ED, including a complete blood count with differential, comprehensive metabolic panel, and lipase, was unremarkable. The patient subsequently followed up with the vascular surgery outpatient clinic, where vascular ultrasound demonstrated significant velocity elevations in the celiac artery at rest, further increasing with end expiration—an indicative finding of MALS. He was referred to gastroenterology for further evaluation of other, more common causes of abdominal pain.

During subsequent months, the patient underwent a comprehensive gastroenterological workup, which included negative celiac antibodies, normal erythrocyte sedimentation rate, normal C-reactive protein, and esophagogastroduodenoscopy. The endoscopy revealed normal findings in the esophagus, stomach, and duodenum, with biopsies indicating minimal evidence of acid reflux but did not otherwise explain his periumbilical pain. The patient trialed esomeprazole for acid reflux with minimal improvement observed. The gastroenterology team

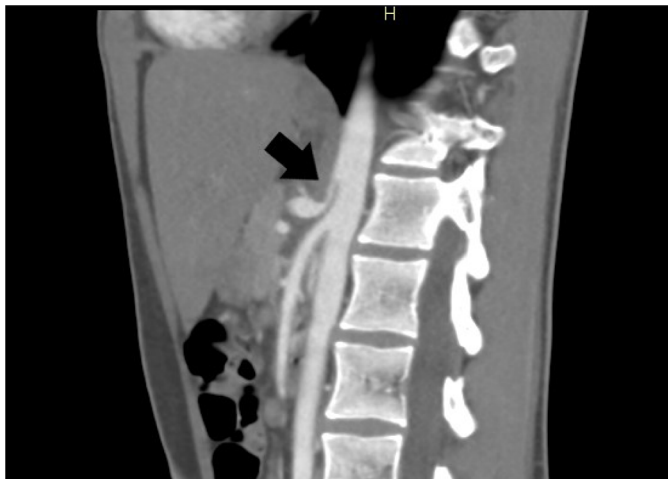

Image. Computed tomography angiography abdomen and pelvis demonstrating narrowing of the celiac artery in a J-shaped configuration with post stenotic dilation seen in median arcuate ligament syndrome (arrow).

Population Health Research Capsule

What do we already know about this clinical entity?

Median arcuate ligament syndrome (MALS) is a rare cause of chronic abdominal pain due to celiac artery compression, typically diagnosed in females 30–50 years old.

What makes this presentation of disease reportable?

A male pediatric patient was diagnosed with MALS via computed tomography angiogram rather than the usual mesenteric duplex ultrasound.

What is the major learning point?

Vascular pathology should be considered as a cause of chronic abdominal pain in pediatric patients whose clinical picture does not fit other common diagnoses.

How might this improve emergency medicine practice?

This case report may broaden an emergency physician's differential diagnosis and change workup by ordering the appropriate study.

suggested trying sertraline or amitriptyline for neuropathic gastrointestinal pain, but the family declined this option. Instead, they opted for conservative management of MALS, focusing on non-operative treatment through endoscopic ultrasound celiac plexus block. Post-treatment follow-up will determine whether surgical management is necessary in the absence of significant symptom improvement.

DISCUSSION

Median arcuate ligament syndrome is an infrequent cause of abdominal pain, which frequently presents as a primary complaint in ED visits. It is less commonly diagnosed in pediatric males and often mimics CFAP symptoms, leading to misdiagnoses such as IBS, functional dyspepsia, or abdominal migraine.² This case highlights the importance of considering vascular etiologies such as MALS in pediatric patients whose clinical presentation does not align with other common causes of chronic abdominal pain. The patient's repeated visits and investigations underscore the challenges in diagnosing this condition, which is typically confirmed using mesenteric duplex ultrasound as a non-invasive first-line option, or CT angiography.¹

The management of MALS varies due to the multifaceted nature of its etiology. Treatment strategies aim to alleviate the vascular or neuropathic sources of pain. In this case, the patient and his family decided to pursue non-surgical management through celiac plexus block. Other non-operative approaches include a multidisciplinary approach involving general surgery, vascular surgery, and psychiatry. The involvement of psychiatry is crucial not only for managing the stress associated with potential surgery but also for addressing concurrent psychiatric conditions, such as depression and eating disorders, commonly observed in these patients. Surgical management typically entails the release of the median arcuate ligament through laparoscopic, robotic, or open procedures, all of which have been proven to be safe and effective.^{3,4} However, it should be noted that prolonged compression of the celiac artery may induce structural changes in the vascular layers, including intimal hyperplasia, media elastin proliferation, and adventitial disorganization. These changes may explain why surgical release of the median arcuate ligament does not consistently alleviate symptoms.⁵

CONCLUSION

Median arcuate ligament syndrome is a rare cause of chronic abdominal pain that poses a diagnostic challenge, particularly in pediatric patients. Vascular etiologies such as MALS should be considered when previous workup and management have failed to provide a definitive diagnosis. A multidisciplinary approach to management is essential, with non-operative treatment recommended initially. Surgical management, involving the release of the median arcuate ligament, should be considered if conservative measures fail to yield significant symptom improvement.

The authors attest that their institution requires neither Institutional Review Board approval, nor patient consent for publication of this case report. Documentation on file.

Address for Correspondence: Jessica Doctor, MD, San Antonio Uniformed Services Health Education Consortium, Department, 3551 Roger Brooke Drive, Fort Sam Houston, TX 78234.
Email: jess.i.doctor@gmail.com

Conflicts of Interest: By the CPC-EM article submission agreement, all authors are required to disclose all affiliations, funding sources and financial or management relationships that could be perceived as potential sources of bias. The authors disclosed none.

Copyright: © 2024 Doctor et al. This is an open access article distributed in accordance with the terms of the Creative Commons Attribution (CC BY 4.0) License. See: <http://creativecommons.org/licenses/by/4.0/>

REFERENCES

1. Goodall R, Langridge B, Onida S, et al. Median arcuate ligament syndrome. *J Vasc Surg.* 2020;71(6):2170–6.
2. Mak GZ, Speaker C, Anderson K, et al. Median arcuate ligament syndrome in the pediatric population. *J Pediatr Surg.* 2013;48(11):2261–70.
3. Skelly CL and Mak GZ. Median arcuate ligament syndrome: current state of management. *Semin Pediatr Surg.* 2021;30(6):151129.
4. Duffy AJ, Panait L, Eisenberg D, et al. Management of median arcuate ligament syndrome: a new paradigm. *Ann Vasc Surg.* 2009;23(6):778–84.
5. Bech F, Loesberg A, Rosenblum J, et al. Median arcuate ligament compression syndrome in monozygotic twins. *J Vasc Surg.* 1994;19(5):934–8.

Septic Arthritis of the Sternoclavicular Joint

George V. Koshy, DO, MPH
Richard Davis, DO, CAQSM, RMSK
Christopher Wilson, MD

Department of Emergency Medicine, Geisinger Medical Center,
Danville, Pennsylvania

Section Editor: Anna McFarlin, MD

Submission history: Submitted July 28, 2023; Revision received November 17, 2023; Accepted November 20, 2023

Electronically published January 25, 2024

Full text available through open access at http://escholarship.org/uc/uciem_cpem

DOI: 10.5811/cpem.1563

Introduction: Sternoclavicular joint (SCJ) septic arthritis is a rare but rapidly fatal joint infection. Without proper medical or surgical management, it can progress to osteomyelitis, chest wall abscess, mediastinitis, or myositis.

Case Report: A 57-year-old male with a past history of intravenous drug use presented to the emergency department (ED) with chest tenderness of one week duration. Vital signs were unremarkable, and exam was notable for tender, raised right SCJ without any fluctuance. On point-of-care ultrasound we noted fluid collection and capsular distention along the SCJ, which aided in rapidly diagnosing septic arthritis. The patient was immediately started on antibiotics and taken to the operating room for excision and debridement.

Conclusion: While computed tomography is routinely used in the emergency department for diagnosing septic arthritis, ultrasound offers a rapid and safe alternative for diagnosis. [Clin Pract Cases Emerg Med. 2024;8(1)60–63.]

Keywords: *septic arthritis; sternoclavicular joint; ultrasound.*

INTRODUCTION

Sternoclavicular joint (SCJ) septic arthritis is a rare but potentially fatal condition, representing less than 1% of all bone and joint infections.¹ It often presents insidiously with vague and poorly localized signs. The majority of the laboratory markers and imaging modalities are nonspecific with definitive diagnosis being arthrocentesis with cell count and culture. It is classically seen in males with a mean age of 45 years and associated with intravenous (IV) drug use, diabetes, and infections in other locations. However, more than 25% of patients have no risk factors.^{2,3} Without proper medical or surgical management, it can progress to osteomyelitis, chest wall abscess, mediastinitis or myositis.^{4,5} Thus, a high index of suspicion with prompt recognition and management in the emergency department (ED) is vital to avoid poor outcomes. Here we present a case of SCJ septic arthritis with associated osteomyelitis and acute myositis, with rapid assessment and diagnosis using ultrasound.

CASE REPORT

A 57-year-old male with a past medical history of IV methamphetamine abuse, hepatitis C, and hypertension

presented to the ED for tenderness along the right anterior chest. His symptoms started about a week prior to presentation with an audible pop and subsequent pain that he felt in his right sternoclavicular area. Symptoms had been progressively worsening in severity, without radiation, and no aggravating or alleviating factors. He tried taking acetaminophen and ibuprofen without much relief. He denied any associated symptoms including shortness of breath, fevers, or nausea and vomiting. He also denied history of direct injection to this joint or any other type of direct trauma. Social history was notable for homelessness, poor medication compliance, marijuana use, and a history of IV substance use 10 years prior, but he denied recent drug or alcohol use.

Upon presentation, vital signs were notable for temperature of 97.2° Fahrenheit, blood pressure 128/76 millimeters (mm) of mercury, heart rate 87 beats per minute, respiratory rate 16 breaths per minute, and room air oxygen saturation of 98%. Physical examination was notable for tender, raised right SCJ without any fluctuance, as seen in [Image 1](#). Labs were notable for white blood cell count of

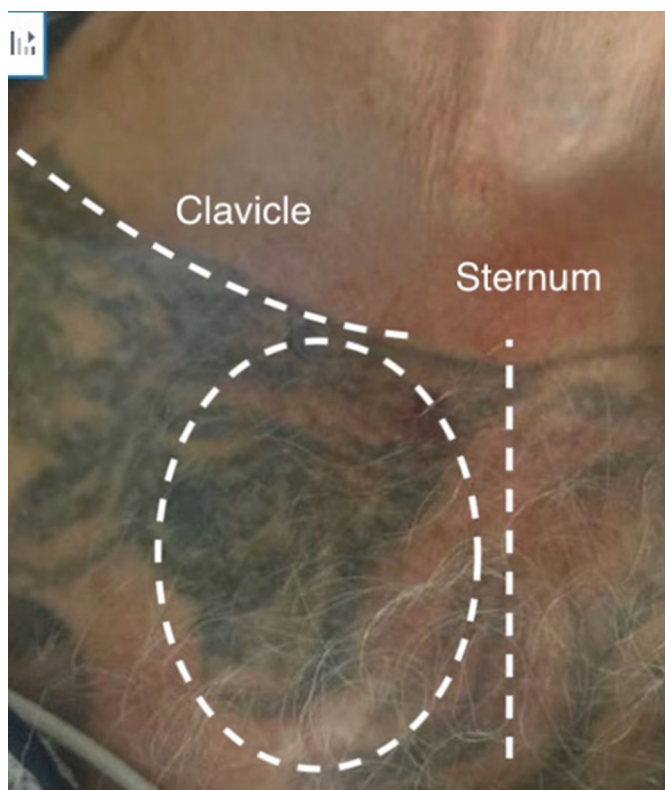


Image 1. Sternoclavicular joint on initial presentation. No fluctuance noted.

12.3×10^9 /liter (L) (reference range 4.5 to 11.0×10^9 /L); platelets of 639×10^9 /L (150 to 400×10^9 /L); erythrocyte sedimentation rate of 120 mm/hour (hr) (0 to 15 mm/hr), and C-reactive protein of 34 milligrams (mg)/L (8–10 mg/L). A rapid point-of-care ultrasound revealed a fluid collection and capsular distention along the SCJ (**Image 2**) concerning for septic arthritis. Orthopedics was consulted.

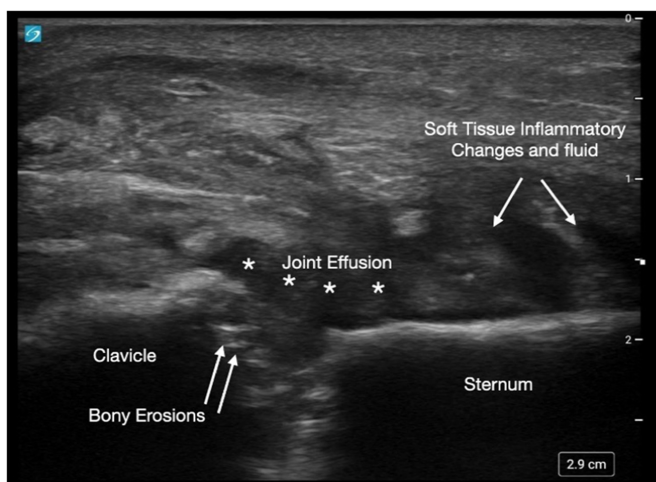


Image 2. Point-of-care ultrasound of the sternoclavicular joint revealing intra-articular effusion and capsular distention.

Population Health Research Capsule

What do we already know about this clinical entity?

Sternoclavicular joint (SCJ) septic arthritis is a rare but serious condition, constituting less than 1% of bone and joint infections.

What makes this presentation of disease reportable?

In our case, ultrasound revealed intra-articular effusion and capsular distention, which suggested presence of septic arthritis and possible osteomyelitis.

What is the major learning point?

Given that >90% of cases do not have joint swelling and symptoms are vague, the clinician should have a high index of suspicion for SCJ septic arthritis.

How might this improve emergency medicine practice?

Point-of-care ultrasound may be used in the initial diagnostic consideration when advanced imaging or orthopedic consult is not available.

While waiting for orthopedics evaluation, computed tomography (CT) was performed for confirmation, which revealed SCJ effusion, bony erosions in the clavicle and adjacent sternal manubrium, and associated extensive soft tissue inflammation, concerning for septic arthritis and osteomyelitis (**Image 3**). Orthopedics was unable to aspirate

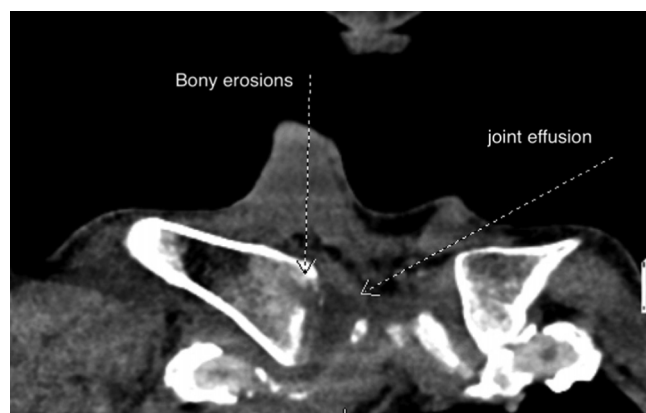


Image 3. Computed tomography revealing joint effusion, bony erosions in the clavicle and adjacent sternal manubrium.

the joint and, thus, interventional radiology was consulted for joint aspiration and biopsy. Due to absence of septic signs, the patient was not immediately started on antibiotics. Post biopsy, the patient was started on piperacillin/tazobactam and admitted for further management. Joint aspirate cultures were positive for Gram positive cocci in chains, and antibiotics was changed to ceftriaxone as per infectious disease recommendation. The patient was subsequently taken to the operating room for right medial clavicle excision and SCJ debridement and irrigation. He remained afebrile in the post-operative period. Tissue cultures were positive for *Streptococcus pneumoniae*. He was discharged within a week with outpatient follow-up with infectious disease and orthopedics.

DISCUSSION

Infections in the SCJ carries a high risk of systemic complications. Joint effusions in this joint progress slowly, with large effusions associated with infiltration into the systemic circulation. The most common symptoms on presentation include fever, chest pain, and neck pain.⁶ A review by Ross et al⁷ found that up to 96% of cases do not have swelling of the joint. Given the relatively vague presentation, and lack of systemic complaints, it is important that the emergency clinician carry a high index of suspicion especially for patients with known risk factors.

Traditionally, CT is the most commonly used tool followed by magnetic resonance imaging (MRI) in making the diagnosis. However, there is little data in the literature about using ultrasound to detect SCJ septic arthritis. In a case report by Kawashiri et al, ultrasound of a SCJ septic arthritis revealed inflammation and appearance of bony erosions, which aided in rapid assessment and diagnosis. In a case report by Monteiro et al,⁹ use of ultrasound aided in the early assessment of power Doppler-positive synovitis of the SCJ. Findings of joint effusion and irregularities of bony margins, which appear as anechoic or complex non-septate collections are suspicious of infections. In our case, ultrasound revealed intra-articular effusion and capsular distention, which suggested presence of septic arthritis and possible osteomyelitis (Image 2).

While we used confirmatory CT, we had consulted orthopedics for suspected septic arthritis based only on ultrasound findings. This is especially significant for EDs where CT or MRI are not readily available and diagnostic evaluation can be initiated based on ultrasound alone. Some emergency physicians practice in facilities where advanced diagnostic imaging and orthopedic consultation may not be immediately available and necessitate transfer of the patient for further diagnostic and definitive care. While confirmatory studies such as CT and MRI have been traditionally used in diagnosing SCJ septic arthritis, we hope that this paper adds to the evidence that point-of-care ultrasound may be used in the initial diagnostic consideration.

Management of SCJ septic arthritis includes surgical debridement along with IV antibiotics. Most common etiologic agents include *Staphylococcus aureus* (58%), methicillin resistant *staphylococcus aureus* (5%), *Pseudomonas aeruginosa* (10%), and *Brucella melitensis* (7%).^{6,8} Once blood cultures are drawn and patient meets sepsis criteria including fever or tachycardia, initial management with broad spectrum antibiotics such as cefazolin or piperacillin/tazobactam is recommended.^{5,10}

CONCLUSION

Septic arthritis of the sternoclavicular joint is an uncommon entity among joint infections, without a specific defined diagnostic or therapeutic pathway. Ultrasound offers a rapid and safe alternative for diagnosis. Prompt recognition and management with antibiotics and early involvement of multidisciplinary team can lead to improved patient care and outcomes.

Patient consent has been obtained and filed for the publication of this case report.

Address for Correspondence: George V. Koshy, DO, MPH, Geisinger Medical Center, Emergency Department, 100 N. Academy Ave., Danville, PA, 17822. Email: gvivek27@gmail.com

Conflicts of Interest: By the CPC-EM article submission agreement, all authors are required to disclose all affiliations, funding sources and financial or management relationships that could be perceived as potential sources of bias. The authors disclosed none.

Copyright: © 2024 Koshy et al. This is an open access article distributed in accordance with the terms of the Creative Commons Attribution (CC BY 4.0) License. See: <http://creativecommons.org/licenses/by/4.0/>

REFERENCES

1. Bar-Natan M, Salai M, Sidi Y, et al. Sternoclavicular infectious arthritis in previously healthy adults. *Semin Arthritis Rheum*. 2002;32(3):189–95.
2. Kwon HY, Cha B, Im JH, et al. Medical management of septic arthritis of sternoclavicular joint: a case report. *Medicine*. 2020;99(44):e22938.
3. Alhariri S, Kalas MA, Hassan M, et al. Medical management of septic arthritis of the sternoclavicular joint with extended-spectrum beta-lactamase-producing escherichia coli: a case report. *Cureus*. 2022;14(4):e23969.
4. Tanaka Y, Kato H, Shirai K, et al. Sternoclavicular joint septic arthritis with chest wall abscess in a healthy adult: a case report. *J Med Case Rep*. 2016;10:69.
5. von Glinski A, Yilmaz E, Rausch V, et al. Surgical management of sternoclavicular joint septic arthritis. *J Clin Orthop Trauma*. 2019;10(2):406–13.

6. Tapscott DC and Benham MD. Sternoclavicular Joint Infection Continuing Education Activity. 2023. Available at: <https://www.ncbi.nlm.nih.gov/books/NBK551721/?report=printable>. Accessed April 17, 2023.
7. Ross JJ and Shamsuddin H. Sternoclavicular septic arthritis: review of 180 cases. *Medicine*. 2004;83(3):139–48.
8. Kawashiri SY, Edo Y, Kawakami A. Early detection of inflammation and joint destruction revealed by ultrasound in a patient with sternoclavicular septic arthritis. *Intern Med*. 2019;58(6):865–9.
9. Monteiro N, Moleiro F, Lérias G, et al. Sternoclavicular septic arthritis due to methicillin-resistant *Staphylococcus aureus* in a patient with a suprapubic catheter. *BMJ Case Rep*. 2015;2015:bcr2014208748.
10. Murga A, Copeland H, Hargrove R, et al. Treatment for sternoclavicular joint infections: a multi-institutional study. *J Thorac Dis*. 2017;9(6):1503–8.

Spontaneously Conceived Ruptured Heterotopic Pregnancy Presenting with Chest Pain and Dyspnea: A Case Report

Farrah Nasrollahi, MD*
Kevin Cao, BS†
Janae Hohbein, DO*
Wesley Eilbert, MD*

*University of Illinois, College of Medicine, Department of Emergency Medicine,
Chicago, Illinois

†University of Illinois, College of Medicine, Chicago, Illinois

Section Editor: Lev Libet, MD

Submission history: Submitted September 14, 2023; Revision received October 6, 2023; Accepted November 1, 2023

Electronically published January 23, 2024

Full text available through open access at http://escholarship.org/uc/uciem_cpccm

DOI: [10.5811/cpcem.1671](https://doi.org/10.5811/cpcem.1671)

Introduction: Heterotopic pregnancy, defined as simultaneous intrauterine and ectopic pregnancy, is a rare and potentially life-threatening condition. The incidence of heterotopic pregnancy has significantly increased in the modern era, primarily due to use of assisted reproductive technology. Heterotopic pregnancy in the absence of risk factors is uncommon. The symptoms of heterotopic pregnancy are similar to those of ectopic pregnancy, primarily abdominal pain and vaginal bleeding.

Case Report: We report a case of heterotopic pregnancy occurring in the absence of risk factors and presenting with primary symptoms of chest pain and shortness of breath.

Conclusion: While uncommon, heterotopic pregnancy may occur in patients without risk factors and may present with atypical symptoms such as chest pain and shortness of breath. [Clin Pract Cases Emerg Med. 2024;8(1)64–67.]

Keywords: *heterotopic pregnancy; ectopic pregnancy; case report.*

INTRODUCTION

First described in 1761 as an autopsy finding, heterotopic pregnancy (HP) is a simultaneous intrauterine and ectopic pregnancy. It is a rare and potentially life-threatening condition. The reported incidence of HP in the era before assisted reproductive technology was 1 in 30,000; its incidence has significantly increased in the modern era.¹ The majority of HPs occur in women with risk factors, with only 29% of HPs occurring in women with no risk factors.² Conception with the use of assisted reproductive technology is the main risk factor for HP.^{2,3} Abdominal pain, vaginal bleeding, and symptoms of hemoperitoneum are the main presenting symptoms.^{2–5} We report the case of a spontaneously conceived, ruptured HP in a patient who presented with symptoms of pleuritic chest pain and shortness of breath.

CASE REPORT

A 28-year-old woman at eight weeks gestation based on last menstrual period presented to the emergency department (ED) with three weeks of shortness of breath, pleuritic anterior chest pain, and near syncope with exertion. Associated symptoms included mild lower abdominal cramping and some bright red vaginal spotting. The pregnancy had been conceived naturally, without assisted reproductive technology or hormonal therapy. She had no history of pelvic inflammatory disease and no prior gynecologic surgeries. She had been evaluated at an outside ED one week prior for similar symptoms. Notable workup at the outside ED included a transvaginal ultrasound revealing a live intrauterine pregnancy (IUP) dated at eight weeks gestation with otherwise normal uterus and adnexa. Additional laboratory studies at that time included a serum

hemoglobin (Hgb) level of 13.8 grams per deciliter (g/dL) (reference range: 12.0–15.5 g/dL) and a serum beta-human chorionic gonadotropin (bHCG) level of 84,320 milli-international units per milliliter (mIU/mL), an appropriate level for seven weeks gestation.

On presentation to our ED, the patient was afebrile with a pulse of 100 beats per minute and a blood pressure of 106/93 millimeters of mercury. Her oxygen saturation on room air was 99%. On physical examination, her abdomen was soft and without notable tenderness or guarding on palpation. Vaginal speculum exam revealed dark red blood in the vaginal vault, with some blood oozing from a closed cervical os. Bimanual examination was notable for moderate tenderness to palpation of the right adnexa. Laboratory studies included a Hgb level of 11.7 g/dL and bHCG level of 101,505 mIU/ml, an appropriate level for eight weeks gestation.

Transvaginal ultrasound showed a live IUP with an estimated gestational age of eight weeks. The left ovary was not visualized, and the right ovary was noted to be normal in size and morphology with a thick-walled cystic structure thought to represent a corpus luteum cyst (Image 1). A moderate amount of hypoechoic material was noted in the cul-de-sac consistent with intraperitoneal blood. Computed tomography (CT) pulmonary angiography was obtained due to concern for pulmonary embolism. While no pulmonary embolism was seen on the CT, free fluid was seen incidentally in the peritoneum. After discussion with radiology and obstetrics as well as risks and benefits discussed with the patient, a CT of the abdomen and pelvis was obtained to rule out a nonpelvic source of hemoperitoneum. The CT redemonstrated moderate hemoperitoneum of suspected pelvic origin and a 1.69-centimeter area of nonspecific low

Population Health Research Capsule

What do we already know about this clinical entity?

Heterotopic pregnancy (HP) in the absence of risk factors is rare. It typically presents with abdominal pain, vaginal bleeding, and symptoms of hemoperitoneum.

What makes this presentation of disease reportable?

A patient with no risk factors for HP presented to the emergency department (ED) with symptoms of pleuritic chest pain and shortness of breath.

What is the major learning point?

Heterotopic pregnancy may rarely occur in the absence of risk factors and present with the atypical symptoms of pleuritic chest pain and shortness of breath.

How might this improve emergency medicine practice?

This case of HP occurring in the absence of risk factors and with atypical symptoms may assist clinicians in the diagnosis of similar cases.

attenuation in the right adnexa (Image 2). The patient was admitted for serial abdominal examinations and Hgb levels.

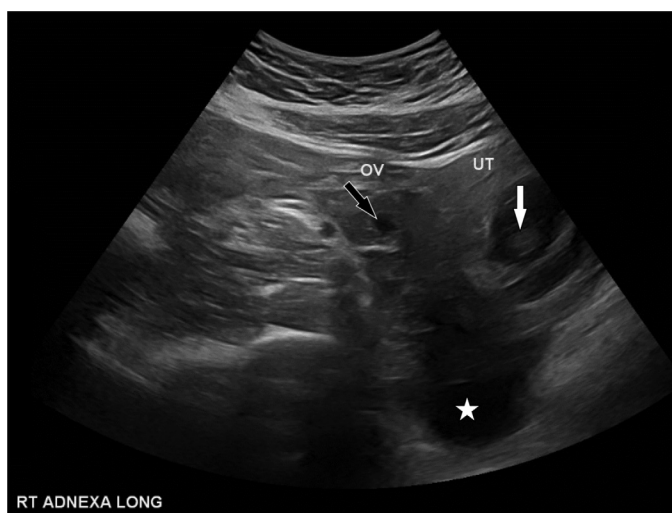


Image 1. Transvaginal ultrasound showing intrauterine pregnancy (white arrow), right ovary with adjacent cystic structure (black arrow), and fluid in the cul-de-sac (white star). OV, ovary; UT, uterus.

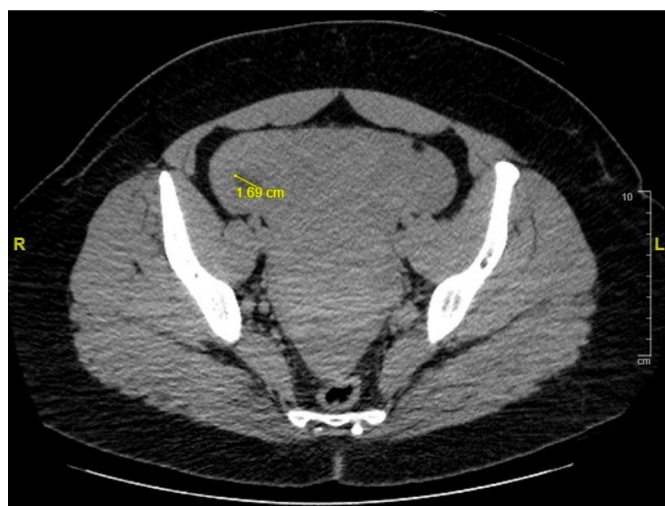

Image 2. Computed tomography of the pelvis showing a 1.69-centimeter area of low attenuation in the right adnexa. cm, centimeter.

On hospital day three, the patient's Hgb level dropped to 8.3 g/dL, and she was taken for exploratory laparotomy. A ruptured right fallopian tube with ectopic pregnancy was found. The patient underwent a right salpingectomy, and after an unremarkable postoperative course was discharged home. The patient ultimately delivered a healthy infant at term.

DISCUSSION

While rare, the incidence of HP has increased significantly in the last 50 years with the increased use of assisted reproductive technology.⁶ The risk of HP among women who have undergone in vitro fertilization is estimated to be as high as one in 100.⁷ While assisted reproductive technology is the main risk factor for HP, the presence of any traditional risk factors for ectopic pregnancy also increases the likelihood of HP (Table). Previous authors have recommended that further investigation of HP is not necessary in cases where an IUP is identified on point of care ultrasound in the ED and there are no risk factors for HP.⁸ This case, along with others reporting HP in the absence of risk factors, suggests this practice is not foolproof, particularly if free intraperitoneal fluid is noted on the ultrasound.⁹

As with this case, the majority (71%) of HPs are diagnosed between 5-8 weeks gestation, with 29% diagnosed after the ninth week.³ With abdominal pain and vaginal bleeding as the primary symptoms of HP, it is likely that many HPs are initially misdiagnosed as threatened abortion, as in this case. In fact, 33% of HPs have a previously documented IUP at the time of diagnosis.² Further adding to the diagnostic challenge of HP is the fact that 5% of pregnancies will have an associated adnexal mass, with corpus luteum cysts being one of the main causes.¹⁰ Similar to this case, it is likely that many heterotopic pregnancies are initially misdiagnosed as an IUP with an associated hemorrhagic corpus luteum cyst. Serial bHCG measurements are not a useful aid in the diagnosis of HP due to the concomitant IUP.^{2,6} While in the past the diagnosis of HP was made at the time of surgery for most cases, approximately 66% of cases are now being diagnosed by ultrasound.² Transvaginal ultrasound is the imaging modality of choice for HP, and magnetic resonance imaging may be used to provide additional information without the use of ionizing radiation.

Table. Risk factors for heterotopic pregnancy.

- Assisted reproductive technology including in vitro fertilization and fertility medication
- History of pelvic inflammatory disease
- Prior pelvic or abdominal surgeries
- Endometriosis
- Previous use of an intrauterine contraceptive device
- Previous ectopic pregnancy

To our knowledge, only one case of heterotopic pregnancy and two cases of ectopic pregnancy presenting with chest pain have been previously described.¹¹⁻¹³ As with our case, in each of these three previously reported cases pulmonary embolism was an initial concern. It is likely the chest pain described in all these cases was due to diaphragmatic irritation from intraperitoneal blood causing referred pain.

The lack of significant tachycardia in this patient despite the presence of significant hemoperitoneum has been previously described.^{14,15} It is theorized that this phenomenon may be due to pregnant patients typically being young and healthy and, therefore, less likely to develop an early tachycardic response to blood loss.¹⁴ Another theory is that blood in the peritoneum may trigger a parasympathetic reflex mediated by the vagus or pelvic nerves.¹⁵

The ultimate goal of the management of HP is to terminate the extrauterine pregnancy while minimizing the threat to the IUP. Treatment options include expectant management, sonographic-guided embryo aspiration with or without embryo toxic drugs, and surgical intervention.⁶ The chosen treatment approach for HP is dependent on several factors, including the location of the extrauterine pregnancy and the hemodynamic stability of the patient.⁶ As with this case, patients with significant intraperitoneal hemorrhage should be managed surgically.⁴ Recent case series have reported 74-88% of HPs will result in a live birth.^{2,4,5}

CONCLUSION

While uncommon, HP may occur in patients without associated risk factors. Heterotopic pregnancy typically presents with abdominal pain and vaginal bleeding and is often initially misdiagnosed as threatened abortion. As this case illustrates, HP may present with chief complaints of dyspnea and chest pain, resulting from intraperitoneal hemorrhage and diaphragmatic irritation.

The authors attest that their institution requires neither Institutional Review Board approval, nor patient consent for publication of this case report. Documentation on file.

Address for Correspondence: Wesley Eilbert, MD, University of Illinois, College of Medicine, Department of Emergency Medicine, 1819 West Polk St., Room 469, Chicago, IL 60612.
Email: weilbert@uic.edu

Conflicts of Interest: By the CPC-EM article submission agreement, all authors are required to disclose all affiliations, funding sources and financial or management relationships that could be perceived as potential sources of bias. The authors disclosed none.

Copyright: © 2024 Nasrollahi et al. This is an open access article distributed in accordance with the terms of the Creative Commons Attribution (CC BY 4.0) License. See: <http://creativecommons.org/licenses/by/4.0/>

REFERENCES

1. Devoe RW and Pratt JH. Simultaneous intrauterine and extrauterine pregnancy. *Am J Obstet Gynecol.* 1948;56(6):1119–26.
2. Talbot K, Simpson R, Price N, et al. Heterotopic pregnancy. *J Obstet Gynaecol.* 2011;31(1):7–12.
3. Tal J, Haddad S, Gordan N, et al. Heterotopic pregnancy after ovulation induction and assisted reproductive technologies: a literature review from 1971 to 1993. *Fertil Steril.* 1996;66(1):1–12.
4. Yu Y, Xu W, Wie Z, et al. Management and outcome of 25 heterotopic pregnancies in Zhejiang, China. *Eur J Obstet Gynecol Reprod Biol.* 2014;180:157–61.
5. Jeon JH, Hwang YI, Shin IH, et al. The risk factors and pregnancy outcomes of 48 cases of heterotopic pregnancy from a single center. *J Korean Med Sci.* 2016;31(7):1094–99.
6. Elsayed S, Farah N, Anglim M. Heterotopic pregnancy: case series and review of diagnosis and management. *Case Rep Obstet Gynecol.* 2023;2023:2124191.
7. American College of Obstetricians and Gynecologists' Committee on Practice Bulletins – Gynecology. ACOG Practice Bulletin No. 193: Tubal Ectopic Pregnancy. *Obstet Gynecol.* 2018;131(3):e91–103.
8. Durham B, Lane B, Burbridge L, et al. Pelvic ultrasound performed by emergency physicians for detection of ectopic pregnancy in complicated first-trimester pregnancies. *Ann Emerg Med.* 1997;29(3):338–47.
9. O'Donnell R, Siacunco E, Quesada D, et al. Early diagnosis of heterotopic pregnancy in a primigravid without risk factors in the emergency department. *Clin Pract Cases Emerg Med.* 2019;3(2):162–3.
10. Mukhopadhyay A, Shinde A, Naik R. Ovarian cysts and cancer in pregnancy. *Best Pract Res Clin Obstet Gynaecol.* 2016;33:57–82.
11. Bildik F, Demircan A, Keles A, et al. Heterotopic pregnancy presenting with acute left chest pain. *Am J Emerg Med.* 2008;26(7):835.e1–2.
12. Dichter E, Espinosa J, Baird J, et al. An unusual emergency department case: ruptured ectopic pregnancy presenting as chest pain. *World J Emerg Med.* 2017;8(1):71–3.
13. Woolnough B and Ballermann C. An atypical presentation of ectopic pregnancy with unicornate uterus and undescended fallopian tube. *J Obstet Gynaecol Can.* 2019;41(2):214–6.
14. Hick JL, Rodgerson JD, Heegaard WG, et al. Vital signs fail to correlate with hemoperitoneum from ruptured ectopic pregnancy. *Am J Emerg Med.* 2001;19(6):488–91.
15. Snyder HS. Lack of tachycardic response to hypotension with ruptured ectopic pregnancy. *Am J Emerg Med.* 1990;8(1):23–6.

Ultrasound-Guided, Mid-Forearm Median Nerve Block for Relief of Carpal Tunnel Syndrome Pain in the Emergency Department: A Case Report

Daniel L. Puebla, MD, MS*
 Ilya Luchitsky, MD*
 Roman Montes De Oca, BS*
 Michael Shalaby, MD*†
 Robert A. Farrow II, DO, MS*†

*Mount Sinai Medical Center, Department of Emergency Medicine, Miami, Florida
 †Florida International University, Herbert Wertheim College of Medicine, Department of Emergency Medicine, Miami, Florida

Section Editor: Steven Walsh, MD, MSc

Submission history: Submitted March 31, 2023; Revision received October 5, 2023; Accepted October 6, 2023

Electronically published January 23, 2024

Full text available through open access at http://escholarship.org/uc/uciem_cpem

DOI: [10.5811/cpcem.1265](https://doi.org/10.5811/cpcem.1265)

Introduction: Carpal tunnel syndrome (CTS) is a common complaint in the emergency department (ED) and accounts for approximately 90% of all peripheral neuropathies.⁶ Pain control from injection with corticosteroids into the carpal tunnel space is associated with multiple possible complications including atrophy, iatrogenic median nerve injury, and skin changes. Ultrasound (US)-guided mid-forearm median nerve block is an ED procedure that can be used to avoid direct injection into the carpal tunnel space. Here we present a case report proposing the use of US-guided mid-forearm block as a safe and effective adjunct to the management of acute pain caused by CTS.

Case Report: A previously healthy 44-year-old, right-hand dominant female presented to the ED with left wrist pain. Her clinical exam and US findings were consistent with CTS. Given her allergy to non-steroidal anti-inflammatory drugs, she was offered a median nerve block, which was performed in the ED. The patient reported continued pain relief 24 hours after discharge from the ED.

Conclusion: There is limited data on the use of US-guided mid-forearm median nerve block as an acute pain management tool for CTS in the ED. The US-guided median nerve block done in the mid-forearm location can provide pain control for those with CTS while reducing the risk of complications associated with direct carpal tunnel injection. [Clin Pract Cases Emerg Med. 2024;8(1)68–71.]

Keywords: *case report; carpal tunnel syndrome; median nerve block; ultrasound guidance; regional anesthesia.*

INTRODUCTION

Carpal tunnel syndrome (CTS) is a constellation of signs and symptoms that results from compression of the median nerve. It is the most common of all peripheral neuropathies (90% of cases) and is estimated to have a prevalence of 1–5%.^{1,2} Carpal tunnel syndrome is a clinical diagnosis, and the most common symptoms include numbness and tingling in the median nerve distribution, nocturnal numbness, weakness of the thenar musculature, positive Phalen test (sensitivity 42–85%, specificity

54–98%), and positive Tinel sign (sensitivity 38–100%, specificity 55–100%).^{1,3}

An entrapment neuropathy caused by a combination of compression and traction, CTS causes changes in the microvascular structure of the nerve. This subsequently leads to increased permeability of the endoneurial vessels leading to edema of the median nerve.⁴ Ultrasound (US) may assist in the diagnosis of CTS by measuring the cross-sectional area of the median nerve. A median nerve cross-sectional area greater than 0.098 centimeters squared (cm²) with subjective

findings on examination is 98% sensitive for the diagnosis of CTS.⁵

Direct injection of anesthetic and/or steroid into the carpal tunnel space can cause injury or weaken the median nerve.⁶⁻⁸ Studies show that injection nerve palsies have a reported incidence of 2% with median nerve palsies accounting for 3.6% of these complications.⁹ In this case report we propose the use of a mid-forearm, US-guided median nerve block as a safe and effective adjunct to the management of acute pain caused by CTS.

CASE REPORT

A previously healthy, 44-year-old, right-hand dominant female presented to the ED with a chief complaint of two days of atraumatic left wrist pain exacerbated by wrist overuse secondary to her job as a waitress. Physical examination was notable for tenderness to palpation of the volar aspect of the left wrist and positive Tinel sign. Radiographs of the wrist were within normal limits. The median nerve was identified on US, and it demonstrated a cross-sectional area of 0.11cm², suggesting the diagnosis of CTS (Image 1).

Pain management options were discussed with the patient. Since the patient was allergic to non-steroidal anti-inflammatory drugs (NSAID) and had minimal pain relief from acetaminophen, she was offered a median nerve block to which she consented. A pre-procedure US identified the median nerve between the deep and superficial flexor muscles, and a suitable location was selected to perform the nerve block. The mid-forearm median nerve block was performed using aseptic preparation and an in-plane, US-guided needle technique. A 27-gauge needle was used for the block with a 10-milliliter (mL) syringe filled with 10 mL of bupivacaine 0.5% without epinephrine. The fascial plane

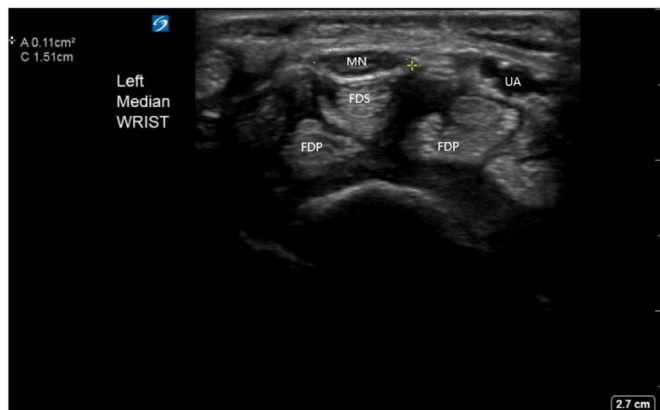


Image 1. Carpal tunnel anatomy on ultrasound and median nerve (MN) sheath diameter. Surrounding the MN is the measurement tool indicating a MN sheath diameter of 0.11cm², consistent with the diagnosis of carpal tunnel syndrome.

MN, median nerve; FDS, flexor digitorum superficialis; FDP, flexor digitorum profundus; UA, ulnar artery.

Population Health Research Capsule

What do we already know about this clinical entity?

Carpal tunnel syndrome (CTS) presents with pain and paresthesias along the median nerve distribution. Treatment typically involves splinting and anti-inflammatories.

What makes this presentation of disease reportable?

We discuss a novel adjunct to pain control: ultrasound-guided mid-forearm median nerve block.

What is the major learning point?

This can be a useful adjunct for multimodal pain management in patients with CTS, avoiding complications associated with injecting into the carpal space.

How might this improve emergency medicine practice?

Mid-forearm median nerve block can improve pain management while reducing the incidence of CTS complications.

between the deep and superficial flexor groups was hydrodissected with bupivacaine until the median nerve was surrounded by anesthetic (Images 2 and 3).

The patient had significant pain relief within minutes. She was discharged in a Velcro volar splint and sling, with instructions to use acetaminophen as needed. At telephone follow-up 24 hours post procedure she reported significant improvement of her pain symptoms.

DISCUSSION

Carpal tunnel syndrome management in the ED generally consists of NSAIDs in conjunction with splinting and follow up with a hand specialist. A study analyzing conservative management of CTS comprised of NSAIDs and night-time splinting demonstrated that approximately 25% of patients fail treatment with this approach.¹⁰ Another potential treatment is steroid injection; this requires injection directly into the carpal tunnel and ultimately offers short-term pain relief but no statistically significant long-term pain relief.¹¹

The median nerve block is frequently performed in the ED as a means to effectively anesthetize the palmar aspect of the first three digits, the radial half of the fourth digit, and the distal dorsal portion of the second and third digits.¹² The block is performed by extending the patient's arm in the volar

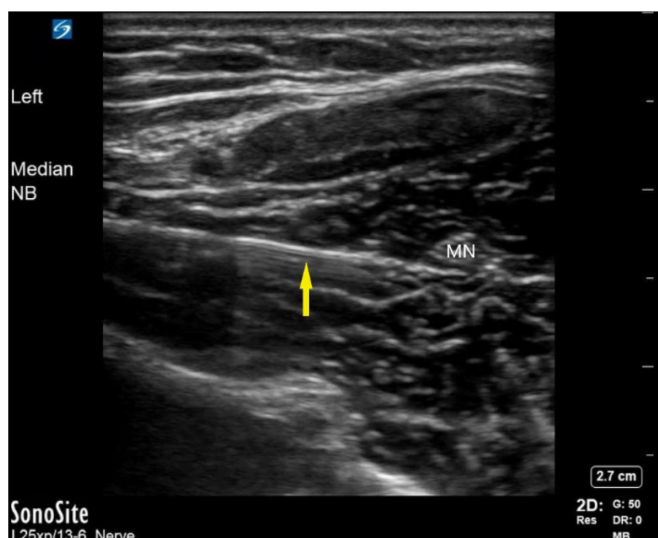

Image 2. Median nerve block. This still frame of the median nerve block (NB) using a dynamic in-plane approach. The yellow arrow indicates the needle with underlying reverberation artifact. The needle is approaching from the left side of the screen along the fascia plane prior to injection of the anesthetic. MN, median nerve; NB, nerve block.

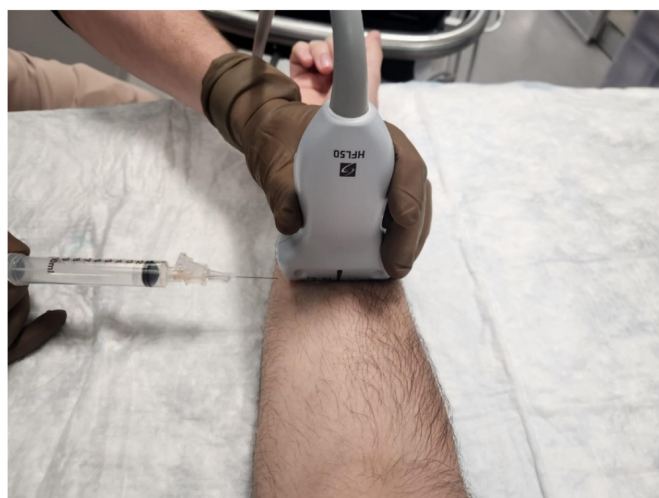

Image 3. Representation of correct needle placement under ultrasound guidance using a linear high-frequency probe and needle. The in-plane lateral approach allows for complete needle visualization as the needle approaches the median nerve (MN). This image is used only for demonstration purposes of correct needle placement. The MN block should be performed under sterile conditions with a probe cover and a sterile field.

position, placing the probe in transverse position along the carpal tunnel space, and moving proximally until the median nerve is localized between the flexor digitorum superficialis and flexor digitorum profundus. The mid-forearm approach avoids direct injection into the carpal tunnel space, which can potentially cause median nerve injury.² Using a sterile

US probe cover during the procedure and appropriate sterile technique, approximately 5–10 mL of anesthetic can be safely injected for intended effect. Potential complications of this procedure include pain and discomfort during the injection, infection, and potential compromise of the brachial artery, which runs parallel to the median nerve.¹² We recommend using the pre-procedure US to survey the selected needle path for any possible neurovascular structures.

There is limited data on the use of US-guided, mid-forearm median nerve block as an acute pain management tool for CTS in the ED. A study analyzing pain relief with forearm nerve block vs intravenous regional anesthesia (Bier block) in patients undergoing carpal tunnel release did show a statistically significant pain improvement at discharge with forearm block,¹³ demonstrating potential treatment viability. Steroids may be associated with complications such as increased numbness and tingling in hands in 5% of cases, transient sympathetic reaction in 2% of cases, skin depigmentation in 1.3–4% of cases, and atrophy in 1.5–40% of cases.¹⁴ Suggested benefits of using mid-forearm block include acute pain relief, avoidance of complications secondary to carpal tunnel space injection, and lack of complications associated with steroids.

CONCLUSION

The case presented demonstrates the use of US-guided median nerve block as a potential adjunct treatment for pain management in carpal tunnel syndrome, which can be performed in the ED setting. The use of a median nerve block in a 44-year-old female with CTS provided significant pain relief, which was sustained at 24 hours follow-up. Future studies could evaluate the acute benefit of this treatment approach as an adjunct to NSAIDs, rest, and nightly splinting.

The authors attest that their institution requires neither Institutional Review Board approval, nor patient consent for publication of this case report. Documentation on file.

Address for Correspondence: Daniel L Puebla, MD, MS, Mount Sinai Medical Center, Department of Emergency Medicine, 4300 Alton Road, Miami Beach, FL 33140. Email: Daniel.puebla@msmc.com

Conflicts of Interest: By the CPC-EM article submission agreement, all authors are required to disclose all affiliations, funding sources and financial or management relationships that could be perceived as potential sources of bias. The authors disclosed none.

Copyright: © 2024 Puebla et al. This is an open access article distributed in accordance with the terms of the Creative Commons Attribution (CC BY 4.0) License. See: <http://creativecommons.org/licenses/by/4.0/>

REFERENCES

1. Padua L, Coraci D, Erra C, et al. Carpal tunnel syndrome: clinical features, diagnosis, and management. *Lancet Neurol*. 2016;15(12):1273–84.
2. Pourmemari M-H, Heliövaara M, Viikari-Juntura E, et al. Carpal tunnel release: lifetime prevalence, annual incidence, and risk factors. *Muscle Nerve*. 2018;58(4):497–502.
3. Keith MW, Masear V, Chung K, et al. Diagnosis of carpal tunnel syndrome. *J Am Acad Orthop Surg*. 2009;17(6):389–96.
4. Aboonq MS. Pathophysiology of carpal tunnel syndrome. *Neurosciences (Riyadh)*. 2015;20(1):4–9.
5. Ooi CC, Wong SK, Tan AB, et al. Diagnostic criteria of carpal tunnel syndrome using high-resolution ultrasonography: correlation with nerve conduction studies. *Skeletal Radiol*. 2014;43(10):1387–94.
6. Dun S, Kaufmann RA, Li Z-M. Lower median nerve block impairs precision grip. *J Electromyogr Kinesiol*. 2007;17(3):348–54.
7. Li Z-M and Nimbarte AD. Peripheral median nerve block impairs precision pinch movement. *Clin Neurophysiol*. 2006;117(9):1941–8.
8. Hsu Y-C, Yang F-C, Hsu H-H, et al. Median nerve injury in ultrasound-guided hydrodissection and corticosteroid injections for carpal tunnel syndrome. *Ultraschall Med*. 2020;43(02):186–93.
9. Andrea A, Gonzales JR, Iwanaga J, et al. Median nerve palsies due to injections: a review. *Cureus*. 2017;9(5):e1287.
10. Taylor-Gjevre RM, Gjevre JA, Strueby L, et al. Treatments for carpal tunnel syndrome: who does what, when . . . and why? *Can Fam Physician*. 2007Jul;53(7):1186–90.
11. Atroshi I. Steroid injection or wrist splint for first-time carpal tunnel syndrome? *Lancet*. 2018;392(10156):1383–4.
12. Strakowski JA. Ultrasound-guided peripheral nerve procedures. *Phys Med Rehabil Clin N Am*. 2016;27(3):687–715.
13. Jalil H, Polfliet F, Nijs K, et al. Efficacy of ultrasound-guided forearm nerve block versus forearm intravenous regional anaesthesia in patients undergoing carpal tunnel release: a randomized controlled trial. *PLOS ONE*. 2021;16(2).
14. Brinks A, Koes BW, Volkers AC, et al. Adverse effects of extra-articular corticosteroid injections: a systematic review. *BMC Musculoskelet Disord*. 2010;11:206.

A Case of Perforating Folliculitis in a Peritoneal Dialysis Patient

Glenn Goodwin, DO, EMT-P*

Katherine L. O'Neil, DO*

Megan Dekok, MS[†]

Moshe Bengio, DO*

Philip O. Scumpia, MD, PhD[‡]

Abhishek Roka, MD*

Alexander J. Scumpia, DO, MHA, MSc*

*HCA Florida Aventura Hospital, Department of Emergency Medicine, Aventura, Florida

[†]Rocky Vista University College of Osteopathic Medicine, Parker, Colorado

[‡]University of California Los Angeles David Geffen School of Medicine, Division of Dermatology/Dermatopathology, Los Angeles, California

Section Editor: Manish Amin, DO

Submission history: Submitted June 29, 2023; Revision received October 5, 2023; Accepted October 6, 2023

Electronically published January 9, 2024

Full text available through open access at http://escholarship.org/uc/uciem_cpem

DOI: 10.5811/cpem.1470

Case Presentation: A 30-year-old male with a past medical history of hypertension and renal failure on peritoneal dialysis presented to the emergency department with a chief complaint of a rash on his anterior trunk for the prior three weeks. Dermatological examination revealed multiple, discrete folliculocentric, erythematous, and hyperpigmented papules, with scattered adjacent angulated erosions.

Discussion: Perforating folliculitis is a rare and often difficult to diagnose skin condition classically seen in patients with chronic renal disease or underlying immunodeficiency. [Clin Pract Cases Emerg Med. 2024;8(1)72–73.]

Keywords: case report; peritoneal dialysis; perforating folliculitis.

CASE PRESENTATION

A 30-year-old male with a past medical history of hypertension and renal failure on peritoneal dialysis presented to the emergency department (ED) through triage with a chief complaint of a pruritic rash on his anterior trunk for the prior three weeks. The patient had complaints of multiple dark, erythematous, raised, pruritic lesions on the lower chest and anterior abdomen. He denied any new exposures, new medications, or recent travel. Symptomatic management was not initiated prior to presenting to the ED. The patient also denied associated systemic symptoms. Routine laboratory results were within normal limits. Dermatological examination revealed multiple, discrete folliculocentric, erythematous, and hyperpigmented papules with scattered adjacent angulated erosions (Image). The rash spared mucosal surfaces with no signs of contiguous spread onto the limbs, palms, or soles.

DISCUSSION

Perforating disorders are characterized by transepidermal extrusion of altered keratin or other dermal connective tissue products and include four main conditions; however, the

secondary form of this collection of diseases is regarded as acquired perforating dermatosis (APD)^{1,2} The only way to differentiate among the four conditions is through histopathological assessment, but clinical diagnosis of APD is often sufficient in the setting of a phenotypical assessment of the lesions along with the patient having diabetes and/or chronic renal failure.² Other common associated comorbidities include diabetes, vitamin A deficiency, and HIV.^{2–4}

The diagnosis of perforating folliculitis can be challenging. Emergency physicians are trained to recognize well-known, life-threatening rashes; however, they must also be cognizant of more benign rashes. While not life-threatening, these rashes can be debilitating and cause severe patient discomfort, necessitating accurate diagnosis to administer proper care and management. Our patient was treated with topical 0.1% triamcinolone lotion and given outpatient dermatology follow-up upon discharge from the ED. Perforating folliculitis is often treated with systemic or topical corticosteroids, retinoids, and keratolytic agents such as urea or salicylic acid.⁵ The pruritic symptoms are often treated with emollients and oral antihistamines.⁵

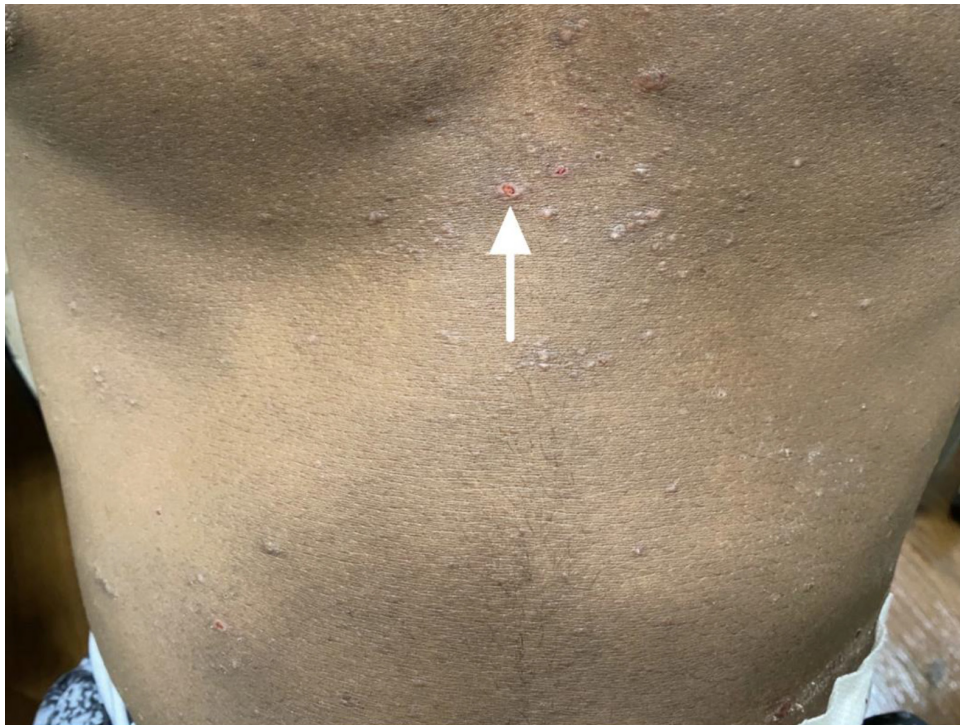

Image. 30-year-old male with multiple, discrete folliculocentric, erythematous, and hyperpigmented papules on the anterior chest consistent with perforating folliculitis (arrow).

Patient consent has been obtained and filed for the publication of this case report.

Address for Correspondence: Glenn Goodwin, DO, HCA Florida Aventura Hospital, Department of Emergency Medicine, 8911 NW 19 Street, Coral Springs, FL 33071 Email: XXX@xxx.com.

Conflicts of Interest: By the CPC-EM article submission agreement, all authors are required to disclose all affiliations, funding sources and financial or management relationships that could be perceived as potential sources of bias. The authors disclosed none.

Copyright: © 2024 Goodwin et al. This is an open access article distributed in accordance with the terms of the Creative Commons Attribution (CC BY 4.0) License. See: <http://creativecommons.org/licenses/by/4.0/>

REFERENCES

1. Fernandes KA, Lima LA, Guedes JC, et al. Acquired perforating dermatosis in a patient with chronic renal failure. *An Bras Dermatol.* 2016;91(5 suppl 1):10–3.
2. Rapini RP, Herbert AA, Drucker CR. Acquired perforating dermatosis. Evidence for combined transepidermal elimination of both collagen and elastic fibers. *Arch Dermatol.* 1989;125(8):1074–8.
3. Hudson RD and Apisarnthanarax P. Renal failure and perforating folliculitis. *JAMA.* 1982;247(14):1936.
4. Neill SM, Pembroke AC, du Vivier AW, et al. Phrynoderma and perforating folliculitis due to vitamin A deficiency in a diabetic. *J R Soc Med.* 1988;81(3):171–2.
5. Haseer Koya H, Ananthan D, Varghese D, Njeru M, Curtiss C, Khanna A. Acquired reactive perforating dermatosis: a rare skin manifestation in end stage renal disease. *Nephrology (Carlton).* 2014;19(8):515–6.

Population Health Research Capsule

What do we already know about this clinical entity?

Perforating folliculitis is classically seen in patients with chronic renal disease or underlying immunodeficiency.

What is the major impact of the image?

This case highlights the importance of broadening the differential for undifferentiated rashes that present to the emergency department.

How might this improve emergency medicine practice?

Awareness of the association between the patient's receiving peritoneal dialysis and the development of perforating folliculitis can expedite patient care.

Insidious Manifestations of Cutaneous T-cell Lymphoma

Alexis L. Cates, DO*
Heather P. Kahn, MD†

*Ochsner Medical Center, Department of Emergency Medicine, New Orleans, Louisiana
†Ochsner Medical Center, Department of Hospital Medicine, New Orleans, Louisiana

Section Editor: Steven Walsh, MD

Submission history: Submitted June 26, 2023; Revision received October 11, 2023; Accepted November 1, 2023

Electronically published December 20, 2023

Full text available through open access at http://escholarship.org/uc/uciem_cpem

DOI: 10.5811/cpcem.1393

Case Presentation: A 66-year-old gentleman presented with several months of a generalized pruritic skin eruption along his face, thorax, and extremities. Although he had been seen previously, no diagnosis was made until he presented to the emergency department (ED) with worsening lesions. The patient was ultimately diagnosed with cutaneous T-cell lymphoma.

Discussion: Accurately diagnosing a rash in the ED is not always possible as more invasive studies may be needed. Emergency physicians can expedite these studies where there is a high suspicion for a diagnosis that may need urgent evaluation and management by specialists through hospital admission and appropriate consultations. The clinical images here are an example of a rare disease manifesting as a debilitating rash, requiring inpatient evaluation and management. [Clin Pract Cases Emerg Med. 2024;8(1)74–76.]

Keywords: rash; neoplasm; dermatology.

CASE PRESENTATION

A 66-year-old Black male with documented history of peptic ulcer disease presented to the emergency department (ED) with a generalized skin eruption for four months. Initially he was prescribed an oral steroid and antihistamine for a pruritic eruption along his arms and face. This emergency visit was prompted when the rash reappeared on his torso and insidiously progressed to his face, arms, and thighs. He denied mucosal or genital lesions, exposures, contacts with similar symptoms, prescribed or over-the-counter medications, or international or domestic travel. He did not exhibit systemic symptoms of infection.

The patient was well-appearing with a blood pressure 175/101 millimeters of mercury, pulse 77 beats per minute, and oral temperature 98.1° Fahrenheit. His skin revealed indurated and ulcerated plaque-like lesions with patchy erythema along the face and torso (Images 1 and 2). Plaque-like lesions were present on the thighs, and flat, scaly lesions were present on the hands and feet. There was no mucosal involvement. The periorbital lesions were vesicular and edematous but did not affect his vision (Image 3).

A computed tomography (CT) with iodinated contrast of the orbits showed preseptal and facial cellulitis. He was given clindamycin intravenously and oral hydroxyzine for itching. Pertinent labs included white blood cell count 5.8×10^9 per liter (L) (reference range: $3.9\text{--}12.7 \times 10^9/\text{L}$), hemoglobin 10.3 grams per deciliter (g/dL) (14.0–18.0 g/dL), platelets $200 \times 10^9/\text{L}$ ($150\text{--}450 \times 10^9/\text{L}$), international normalized ratio 1.0 (0.8–1.2), C-reactive protein 47.3 milligrams (mg)/dL (0.0–8.2 mg/L), erythrocyte sedimentation rate 128 millimeters per hour (mm/hr) (0–23 mm/hr) and normal electrolytes, renal function, and transaminases. A polymerase chain reaction test for herpes simplex virus was positive. Superficial aerobic cultures of the right chest and right back skin lesions resulted with methicillin-sensitive *Staphylococcus aureus*.

The patient was admitted to hospital medicine. Antibiotic coverage was broadened with vancomycin and ceftriaxone. Ophthalmology recommended topical erythromycin for the periorbital lesions. Dermatology raised concern for cutaneous T-cell lymphoma. A skin biopsy was obtained from the right back and sent to pathology for further diagnosis. Oncology recommended CT of the chest, abdomen, and pelvis. This revealed multiple areas of

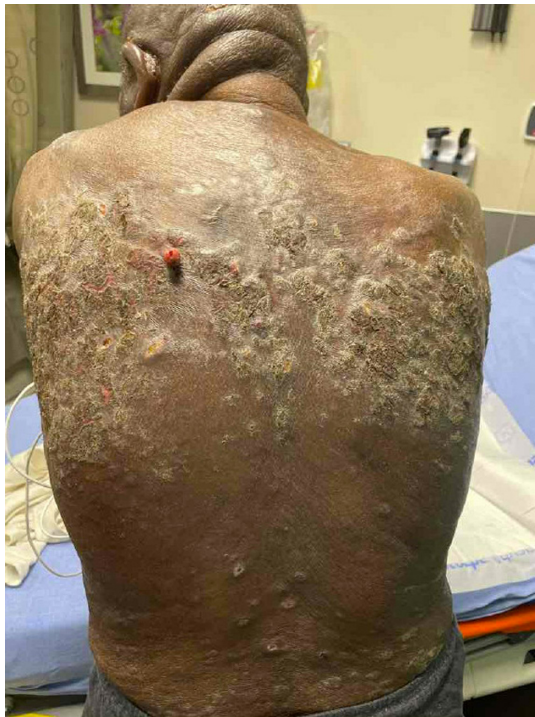

Image 1. Scaly plaques with one large papular lesion near the left scapula in a patient with cutaneous T-cell lymphoma.

lymphadenopathy and mild splenomegaly suspicious for lymphoproliferative disorder. The patient declined an excisional lymph node biopsy. He was discharged from the

hospital with a 10-day antibiotic course and outpatient oncology follow-up.

An outpatient positron emission tomography showed increased diffuse lymphadenopathy and soft tissue thickening, compatible with the suspected diagnosis of cutaneous lymphoma. Skin and right inguinal excisional lymph node biopsies confirmed T-cell lymphoma.

Population Health Research Capsule

What do we already know about this clinical entity?

Cutaneous T-cell lymphoma is insidious and may resemble other pathology such as eczema or cellulitis.

What is the major impact of the images?

Diffuse symptomology and inclusion of the face and periorbital region warrant hospital admission for further urgent investigations.

How might this improve emergency medicine practice?

Physicians should keep cutaneous manifestations of systemic illness like cutaneous T-cell lymphoma on their differential for rashes.

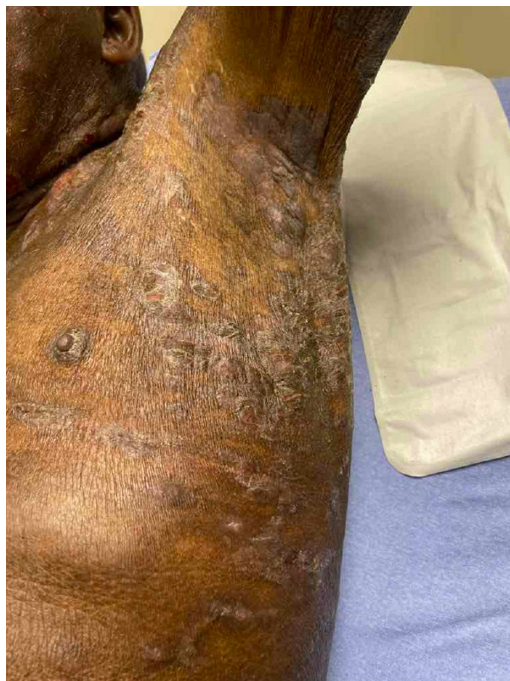

Image 2. Scaly plaques secondary to cutaneous T-cell lymphoma along the patient's left axilla and truncal region.

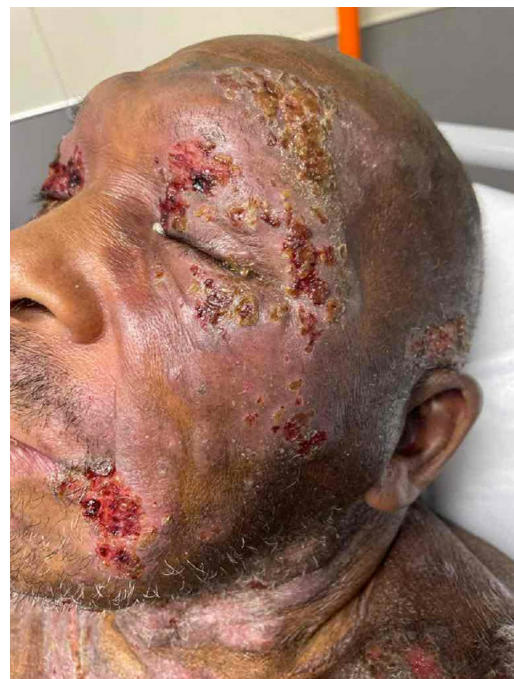

Image 3. Crusted periorbital lesions, some of which were weeping and appeared to be superinfected, in a patient with cutaneous T-cell lymphoma.

DISCUSSION

Cutaneous T-cell lymphoma is a rare diagnosis with an incidence of approximately 8.55 per million according to a United States population data analysis from 2000–2018.¹ Early in its course, it resembles eczema or psoriasis.² It can take several years for the disease to progress to be diagnosed by biopsy.² Most cases occur in patients 50–60 years old.² Prognosis depends on lymph node and visceral involvement. Those with limited skin disease have a good prognosis.² Treatment with topical or systemic immunotherapies depends on organ involvement.² Morbidity and mortality may arise from infections of the ulcerated lesions. It is important for physicians to keep cutaneous manifestations of systemic illness like cutaneous T-cell lymphoma on their differential for rashes, particularly those that are chronic, disseminated, or debilitating.

Patient consent has been obtained and filed for the publication of the images and manuscript.

Address for Correspondence: Alexis L. Cates, DO, Ochsner Medical Center, Department of Emergency Medicine, 1514 Jefferson Highway, New Orleans, LA, 70121.
Email: Alexis.Cates@ochsner.org

Conflicts of Interest: By the CPC-EM article submission agreement, all authors are required to disclose all affiliations, funding sources and financial or management relationships that could be perceived as potential sources of bias. The authors disclosed none.

Copyright: © 2024 Cates et al. This is an open access article distributed in accordance with the terms of the Creative Commons Attribution (CC BY 4.0) License. See: <http://creativecommons.org/licenses/by/4.0/>

REFERENCES

1. Cai ZR, Chen ML, Weinstock MA, et al. Incidence trends of primary cutaneous T-cell lymphoma in the US from 2000 to 2018: A SEER population data analysis. *JAMA Oncol.* 2022;8(11):1690–2.
2. Elmer KB and George RM. Cutaneous T-cell lymphoma presenting as benign dermatoses. *Am Fam Physician.* 1999;59(10):2809–13.

Man Presenting After Hydrochloric Acid Ingestion

Emma R. Furlano, MD*[†]

Gregory P. Wu, MD*[‡]

Brendan Vosburgh, MD*

Cameron R. Waldman, MD*

Jessica Noonan, MD*

Alexander Bracey, MD*

*Albany Medical Center, Department of Emergency Medicine, Albany, New York

[†]Albany Medical Center, Department of Medicine, Division of Pulmonary Critical Care Medicine, Albany, New York

[‡]Albany Medical Center, Department of Emergency Medicine, Division of Toxicology and Addiction Medicine, Albany, New York

Section Editor: R. Gentry Wilkerson, MD

Submission history: Submitted June 10, 2023; Revision received September 14, 2023; Accepted September 21, 2023

Electronically published December 6, 2023

Full text available through open access at http://escholarship.org/uc/uciem_cpem

DOI: [10.5811/cpcem.1436](https://doi.org/10.5811/cpcem.1436)

Case Presentation: We describe a case of a man who developed severe caustic injury of his upper gastrointestinal tract after ingestion of a commercially available 9.5% hydrochloric acidic cleaning solution. He rapidly deteriorated and required endotracheal intubation. He underwent several imaging modalities demonstrating his injuries and ultimately succumbed to his injuries.

Discussion: Acidic caustic ingestions may range in severity and uncommonly result in death. Diagnosis is most often achieved by esophagogastroduodenoscopy, although computed tomography may increasingly play a role in defining the extent of injury. Esophagogastroduodenoscopy findings are often assigned a Zargar grade, which guides management. Medical management of acidic caustic ingestion may include bowel rest, steroids, antibiotics, and proton pump inhibitors depending on the extent of injury, although surgery may be required if esophageal perforation occurs. [Clin Pract Cases Emerg Med. 2024;8(1)77–79.]

Keywords: *caustic ingestion; toxicology; acidic ingestion; critical care; esophageal perforation.*

CASE PRESENTATION

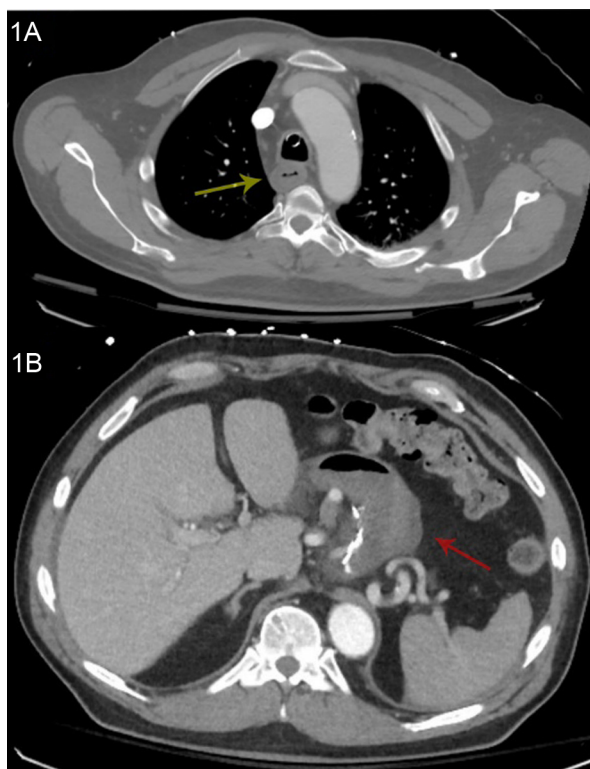
A 63-year-old man presented to the emergency department (ED) via ambulance with recurrent hematemesis after an intentional ingestion of a commercially available 9.5% hydrochloric acid, toilet bowl cleaning solution. While initially stable, he rapidly deteriorated following arrival and was unable to tolerate his secretions and ultimately required endotracheal intubation for airway protection. He underwent computed tomography (CT) of his chest, abdomen, and pelvis ([Image 1](#)), which identified diffuse thickening of the proximal gastrointestinal (GI) tract without evidence of perforation. A pantoprazole infusion was initiated while gastroenterology and toxicology were consulted. A bedside esophagogastroduodenoscopy (EGD) was performed in the ED, which revealed Zargar grade 3B esophagitis and active bleeding from the duodenum ([Image 2](#)).

The patient was admitted to the intensive care unit for ongoing medical management. Repeat CT imaging revealed

esophageal perforation with mediastinal and intra-abdominal free fluid ([Image 3](#)). Given the extent of the esophageal injury, the patient was not a candidate for esophagectomy and ultimately died despite aggressive medical management.

DISCUSSION

Hydrochloric acid ingestion resulting in death is rare. In 2019, the American Association of Poison Control Centers reported 184,677 exposures to cleaning products, which includes caustics. Of 16 deaths related to acidic ingestion, only two were from hydrochloric acid, and neither one was related to toilet cleaning products.¹ Acidic ingestions cause a coagulative necrosis in the GI tract. Severe oropharyngeal pain, odynophagia, and hypersalivation are commonly observed clinical features following ingestion, although, importantly, the degree of injury does not correlate with symptom severity.² While EGD remains the gold standard, the role of CT for diagnosis, prognostication, and surgical



CPC-EM Capsule

What do we already know about this clinical entity?
Acidic ingestions can cause injury from coagulative necrosis, especially of the GI tract. Severe ingestions can cause viscous perforation and multisystem organ failure.

What is the major impact of the image(s)?
EGD is the gold standard for injury diagnosis and management planning, but the role of CT is expanding for acidic ingestions. EGD is contraindicated in viscous perforation.

How might this improve emergency medicine practice?
When available, bedside EGD can be used for rapidly determining patient management plans. CT is a useful adjunct for surgical planning and in viscous perforation.

Image 1. Computed tomography (CT) of the chest and abdomen shortly after admission. 1A: CT chest with contrast shortly after intubation; the yellow arrow indicates region of esophageal thickening in the proximal esophagus. 1B: CT abdomen pelvis with contrast shortly after intubation; the red arrow shows thickening of the stomach.

planning is expanding. In addition to diagnosis, EGD can be used to assign a Zargar grade of esophageal injury.

The Zargar grading system is widely used for caustic ingestion grading and guides further management.³⁻⁵ Zargar grade 2A or less may be treated conservatively with bowel rest and supportive care. High-dose systemic corticosteroids are indicated for the prevention of strictures in Grade 2B lesions, while more severe injury may require surgical intervention. However, EGD has limited ability to detect the

depth of necrotic injury, which may influence surgical planning.⁵ Esophagogastroduodenoscopy is ideally performed within the first 48 hours from time of injury to minimize the risk of iatrogenic esophageal perforation and is contraindicated in instances of known viscous perforation.^{4,6} Multiple grading systems to compare CT findings to EGD findings have been proposed; in one, CT grade I lesions correspond to Zargar grade 1-2A, while CT grade III corresponds to Zargar grade 3B.⁵⁻⁷

Blind insertion of naso- or orogastric tubes is contraindicated, as this may result in further esophageal injury or perforation, but they can be placed under direct endoscopic guidance.⁴ Antibiotics for identified sources of infection and proton pump infusions are reasonable with consequential injuries.⁸

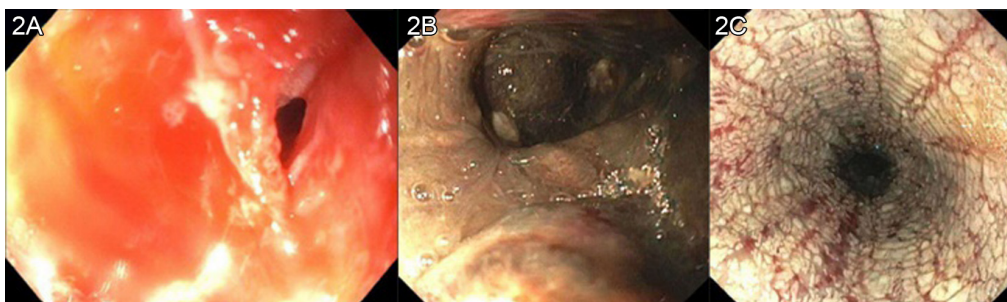


Image 2. Endoscopy in the first 24 hours after intubation. 2A: view of the proximal esophagus showing diffuse thickening and edema, with narrowed lumen from caustic esophagitis. 2B: view of the lower third of esophagus showing grade 3B esophagitis. 2C: view of the duodenum, with hematin and caustic injury.

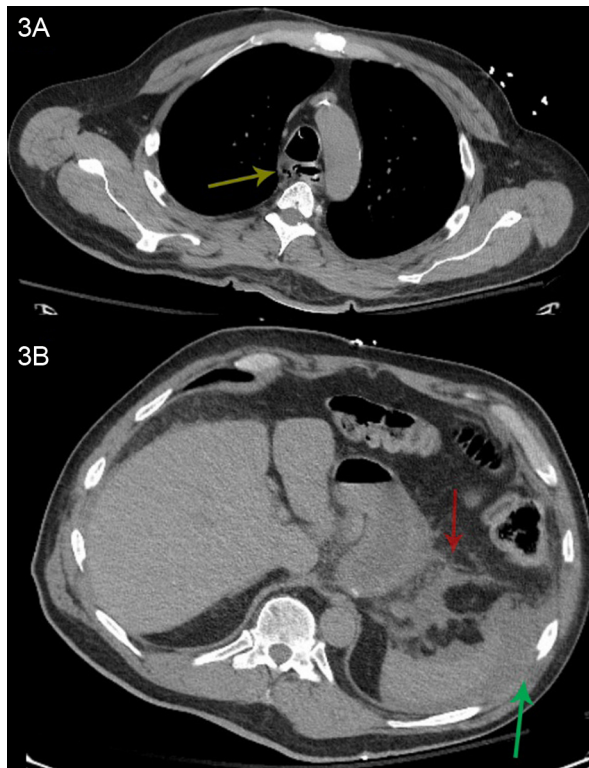


Image 3. Computed tomography (CT) of the chest and abdomen one day later. 3A: CT chest without contrast, same region cut as 1A. The yellow arrow indicates mediastinal air around the esophagus. 3B: CT abdomen pelvis without contrast, same region as 1B. The red arrow indicates free fluid around the stomach; the green arrow indicates free fluid around the spleen.

The authors attest that their institution requires neither Institutional Review Board approval, nor patient consent for publication of this case report. Documentation on file.

Address for Correspondence: Alexander Bracey, MD, Albany Medical Center, Department of Emergency Medicine, 43 New Scotland Avenue MC-139, Albany, NY 12208. Email: Bracey@amc.edu

Conflicts of Interest: By the CPC-EM article submission agreement, all authors are required to disclose all affiliations, funding sources and financial or management relationships that could be perceived as potential sources of bias. The authors disclosed none.

Copyright: © 2024 Vosburgh et al. This is an open access article distributed in accordance with the terms of the Creative Commons Attribution (CC BY 4.0) License. See: <http://creativecommons.org/licenses/by/4.0/>

REFERENCES

- Gummin DD, Mowry JB, Beuhler MC, et al. 2019 Annual Report of the American Association of Poison Control Centers' National Poison Data System (NPDS): 37th Annual Report. *Clin Toxicol (Phila)*. 2020 Dec;58(12):1360–1541.
- Park KS. Evaluation and management of caustic injuries from ingestion of acid or alkaline substances. *Clin Endosc*. 2014 Jul;47(4):301–7.
- Zargar SA, Kochhar R, Mehta S, et al. The role of fiberoptic endoscopy in the management of corrosive ingestion and modified endoscopic classification of burns. *Gastrointest Endosc*. 1991 Mar–Apr;37(2):165–9.
- Hoffman RS, Burns MM, Gosselin S. Ingestion of caustic substances. *N Engl J Med*. 2020 Apr 30;382(18):1739–48.
- Bonavina L, Chirica M, Skrobic O, et al. Foregut caustic injuries: results of the World Society of Emergency Surgery Consensus Conference. *World J Emerg Surg*. 2015 Sep 26;10:44.
- Chen RJ, O'Malley RN, Salzman M. Updates on the evaluation and management of caustic exposures. *Emerg Med Clin North Am*. 2022 May;40(2):343–64.
- Kalayarasan R, Ananthakrishnan N, Kate V. Corrosive ingestion. *Indian J Crit Care Med*. 2019 Dec;23(Suppl 4):S282–6.
- Wightman RS and Fulton JA. Caustics. In: Nelson LS, Howland M, Lewin NA, Smith SW, Goldfrank LR, Hoffman RS (Eds.), *Goldfrank's Toxicologic Emergencies, 11e*. New York, NY: McGraw Hill, 2019.

Caution Regarding Self-reported Tramadol Dependence

James Dunford, MD*[†]
Aaron Schneur, MD[‡]

*University of California San Diego, School of Medicine, San Diego, California

[†]McAlister Institute for Treatment and Education, El Cajon, California

[‡]University of California San Diego Health System, Department of Emergency Medicine,
Division of Medical Toxicology, San Diego, California

Section Editor: Rick Alan McPheeters, DO

Submission history: Submitted October 13, 2023; Revision received October 17, 2023; Accepted November 21, 2023

Electronically published January 25, 2024

Full text available through open access at http://escholarship.org/uc/uciem_cpchem

DOI: [10.5811/cpchem.2589](https://doi.org/10.5811/cpchem.2589)

We are writing in regard to the following article in the current issue of CAL/ACEP's *Lifeline* Volume 4, 2022–23, which was first published in *Clinical Practice and Cases in Emergency Medicine* in 2022.¹ In the report, the authors describe an opioid-dependent patient who was initially prescribed tramadol by her primary care physician but who ultimately began traveling to Mexico to purchase escalating doses of tramadol. The authors appropriately highlight the potential nuances of managing tramadol withdrawal versus that from pure opioid agonists. It is certainly possible that the patient was exclusively ingesting tramadol and that buprenorphine was successful in managing the withdrawal from it.

However, we feel obligated to point out a major limitation: that at least as described in the report, there was not testing of the tramadol product she obtained from Mexico nor of the patient to confirm the presence of tramadol and exclude the presence of other opioids such as fentanyl. There is increasing recognition that counterfeit tablets sold ostensibly as controlled substances in Northern Mexican pharmacies may in fact contain illicit drugs such as fentanyl and heroin.² Before this case report continues to be cited as evidence of the successful management of tramadol dependence with buprenorphine, we feel this limitation should be recognized.

Thank you.

Address for Correspondence: James Dunford, MD, 1986 Linwood Street, San Diego, CA 92110. Email: jdunford@ucsd.edu

Conflicts of Interest: By the CPC-EM article submission agreement, all authors are required to disclose all affiliations, funding sources and financial or management relationships that could be perceived as potential sources of bias. The authors disclosed none.

Copyright: © 2024 Dunford et al. This is an open access article distributed in accordance with the terms of the Creative Commons Attribution (CC BY 4.0) License. See: <http://creativecommons.org/licenses/by/4.0/>

REFERENCES

1. Mukau L, Wormley K, Tomaszewski C, et al. Buprenorphine for high-dose tramadol dependence: a case report of successful outpatient treatment. *Clin Pract Cases Emerg Med.* 2022;6(1):71–4.
2. Friedman J, Godvin M, Molina C, et al. Fentanyl, heroin, and methamphetamine-based counterfeit pills sold at tourist-oriented pharmacies in Mexico: an ethnographic and drug checking study. *Drug Alcohol Depend.* 2023;249:110819.

Buprenorphine for High-dose Tramadol Dependence: A Case Report of Successful Outpatient Treatment

Leslie Mukau, MD*†
Kadia Wormley, MD‡
Christian Tomaszewski, MD, MS, MBA*†
Bushra Ahmad, MD, MPA§
Rais Vohra, MD||
Andrew A. Herring, MD*¶

*University of California San Diego, Department of Emergency Medicine, San Diego, California
†El Centro Regional Medical Center, Department of Emergency Medicine, El Centro, California
‡Highland Hospital-Alameda Health System, Department of Emergency Medicine, Oakland, California
§Imperial County Behavioral Health Services, Division of Substance Use Disorder Treatment Program, El Centro, California
||University of California San Francisco-Fresno, Department of Emergency Medicine, Fresno, California
¶University of California San Francisco, Department of Emergency Medicine, San Francisco, California

Section Editors: Rick Alan McPheeters, DO and R. Gentry Wilkerson, MD

Submission history: Submitted November 6, 2023; Revision received November 17, 2023; Accepted November 21, 2023

Electronically published January 25, 2024

Full text available through open access at http://escholarship.org/uc/uciem_cpem

DOI: 10.5811/cpcem.4914

We appreciate the interest expressed by the commentators with regard to our tramadol dependence case report.¹ However, we respectfully disagree that not testing the tramadol product the patient obtained from Mexico nor testing the patient herself to confirm the presence of tramadol and exclude the presence of other opioids such as fentanyl is a major limitation of our case report.

We are well aware of the role increasingly being played by toxic adulterants and other pharmacologically active components, and specifically fentanyl, in illicitly manufactured pharmaceuticals in the United States and global street markets.^{2,3} These toxic adulterants either alone or in combination with other pharmacologically active components have been implicated as possible causes of adverse health outcomes, including death.⁴ Since 2021, illicit fentanyl has been involved in the vast majority of overdose deaths in the United States.⁵ Our patient was taking extremely high doses of tramadol and would most likely have overdosed and died had it been laced with fentanyl.

To expedite quick initiation of buprenorphine in the emergency department (ED) for patients with opioid use disorder (OUD), the California bridge model, increasingly adopted by many EDs in California and nationwide, does not encourage unnecessary treatment barriers such as diagnostic urine drug testing.⁶ At the Behavioral Health Outpatient Clinic, where the patient was originally seen, she had been referred for laboratory testing multiple times but did not go due to the coronavirus disease 2019 pandemic and behavioral changes due to her high-dose tramadol substance use disorder.

The majority of patients currently seen for OUD in most EDs are there due to fentanyl abuse, either deliberate or unintentional, and they do not usually have the symptoms that our patient was exhibiting. Seizures are usually a characteristic of high-dose tramadol use.⁷ Fentanyl, a synthetic μ -selective opioid agonist, which is typically 50–100 times more potent than morphine, does not cause seizures even at high doses. In fact, fentanyl in combination with certain neuroleptic medications as part of therapeutic neuroleptanalgesia can be used to treat seizures.^{8,9} As of this writing, our patient remains in treatment and not taking illicit tramadol and is currently free of seizures.

We, therefore, strongly believe our patient's drug issues were most likely due to the use of high-dose tramadol.

Address for Correspondence: Leslie Mukau, MD, University of California San Diego, Department of Emergency Medicine, 200 W. Arbor Dr. #8676, San Diego, CA 92103.
Email: lmukau@health.ucsd.edu

Conflicts of Interest: By the CPC-EM article submission agreement, all authors are required to disclose all affiliations, funding sources and financial or management relationships that could be perceived as potential sources of bias. The authors disclosed none.

Copyright: © 2024 Mukau et al. This is an open access article distributed in accordance with the terms of the Creative Commons Attribution (CC BY 4.0) License. See: <http://creativecommons.org/licenses/by/4.0/>

REFERENCES

1. Mukau L, Wormley K, Tomaszewski C, et al. Buprenorphine for high-dose tramadol dependence: a case report of successful outpatient treatment. *Clin Pract Cases Emerg Med.* 2022;6(1):71–4.
2. Singh VM, Browne T, Montgomery J. The emerging role of toxic adulterants in street drugs in the US illicit opioid crisis. *Public Health Rep.* 2020;135(1):6–10.
3. Montero F, Bourgois P, Friedman J, 2022. Potency-enhancing synthetics in the drug overdose epidemic: xylazine (“Tranq”), fentanyl, methamphetamine, and the displacement of heroin in Philadelphia and Tijuana. *J Illicit Econ Dev.* 2022;4(2):204–22.
4. United Nations Office on Drugs and Crime. 2017 Global Synthetic Drugs Assessment. Vienna, Austria: United Nations Office on Drugs and Crime. 2017. Available at: https://www.unodc.org/documents/scientific/Global_Drugs_Assessment_2017.pdf. Accessed October 25, 2023.
5. National Center for Health Statistics. NCHS Fact Sheet. 2021. Available at: https://www.cdc.gov/nchs/data/factsheets/factsheet_Measuring_our_Nations_Health.pdf. Accessed October 25, 2023.
6. CA Bridge. Rapid implementation of opioid use disorder treatment in the hospital nationwide. 2022. Available at: <https://bridgetotreatment.org/resource/rapid-implementation-of-opioid-use-disorder-treatment-in-the-hospital-nationwide/>. Accessed October 25, 2023.
7. Hassamal S, Miotto K, Dale W, et al. Tramadol: understanding the risk of serotonin syndrome and seizures. *Am J Med.* 2018;131(11):1382.e1–6.
8. Hagedorn H, Kenny M, Gordon AJ, et al. Advancing pharmacological treatments for opioid use disorder (ADaPT-ODU): protocol for testing a novel strategy to improve implementation of medication-assisted treatment for veterans with opioid use disorders in low-performing facilities. *Addict Sci Clin Pract.* 2018;13(1):25.
9. Ramos-Matos CF, Bistas KG, Lopez-Ojeda W. Fentanyl. 2023. Available at: <https://www.ncbi.nlm.nih.gov/books/NBK459275/>. Accessed October 25, 2023.

JOIN
CAL/AAEM!



CALAAEM

CALIFORNIA CHAPTER MEMBER OF THE
AMERICAN SOCIETY OF EMERGENCY MEDICINE

*Championing
individual physician rights
and workplace fairness*

BENEFITS

- Western Journal of Emergency Medicine Subscription
- CAL/AAEM News Service email updates
- Discounted AAEM pre-conference fees
- And more!

CAL/AAEM NEWS SERVICE

- Healthcare industry news
- Public policy
- Government issues
- Legal cases and court decisions

In collaboration with our official journal

WestJEM Integrating Emergency Care
with Population Health



FACEBOOK.COM/CALAAEM



FOLLOW US @CALAAEM

[HTTP://WWW.CALAAEM.ORG](http://www.calaaem.org)



CALIFORNIA ACEP

AMERICAN COLLEGE OF EMERGENCY PHYSICIANS

MEDI-CAL RATE INCREASE

**CALIFORNIA ACEP SECURED
\$200M ANNUALLY TO
INCREASE MEDI-CAL
REIMBURSEMENT FOR
EMERGENCY PHYSICIANS!**

**EMERGENCY MEDICINE IS THE ONLY
SPECIALTY WITH ITS OWN BUDGET
ALLOCATION.**

@CALIFORNIAACEP

www.californiaacep.org