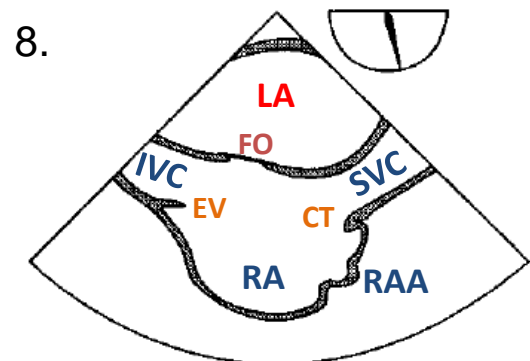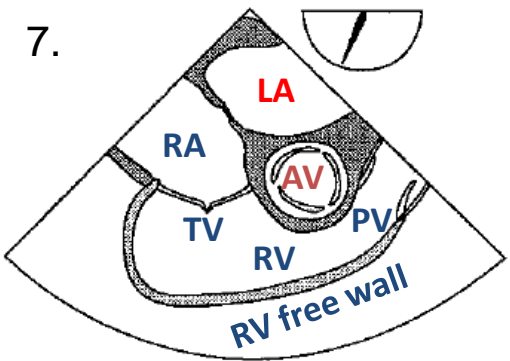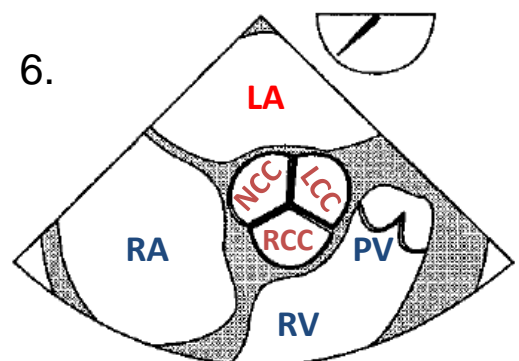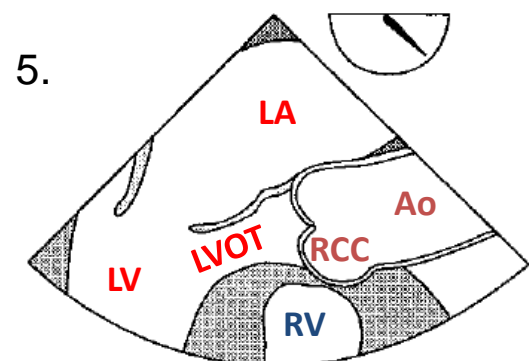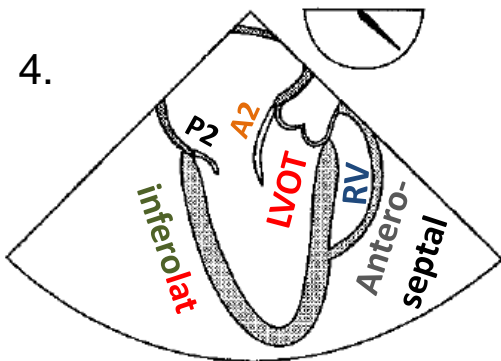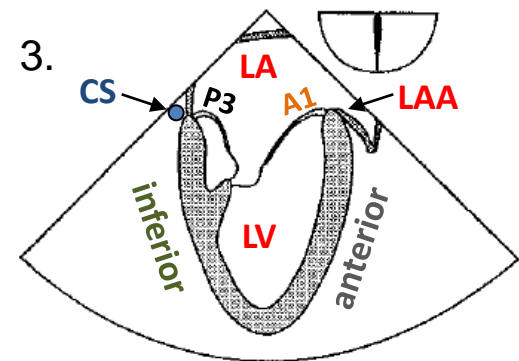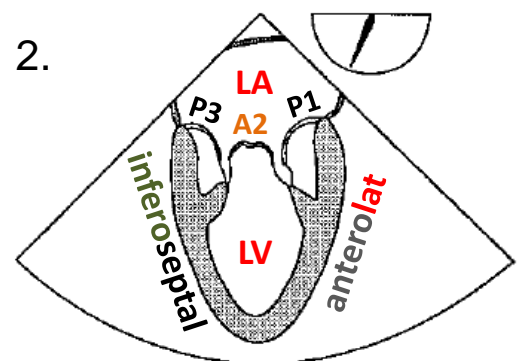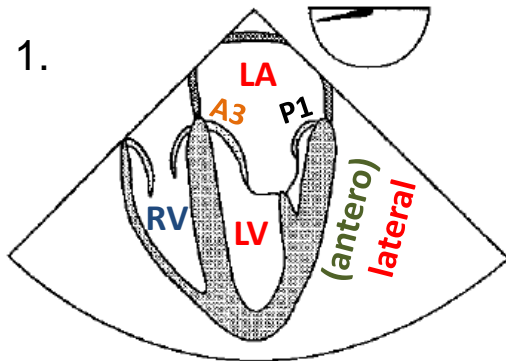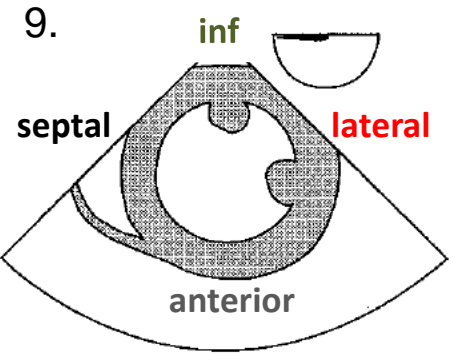
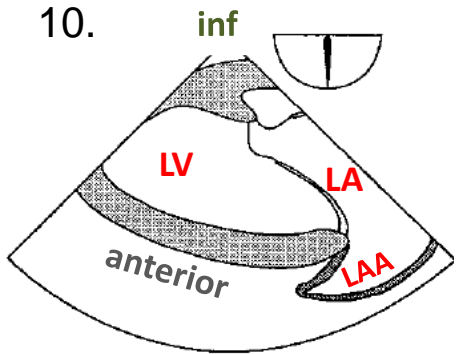


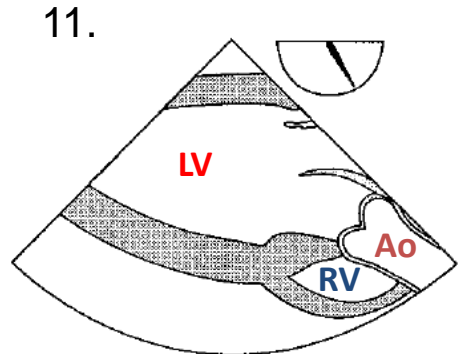
- RAA- Right atrial appendage
- CS- Coronary sinus
- EV- Eustacian valve
- CT- Crista terminalis
- LVOT- Left ventricular outflow tract
- LAA- Left atrial appendage
- Ao- Aorta
- FO- Foramen ovale
- RCC, LCC, NCC- Right, Left & Non-coronary cusps of AV
- A1-3- Mitral valve anterior leaflets
- P1-3- Mitral valve posterior leaflets



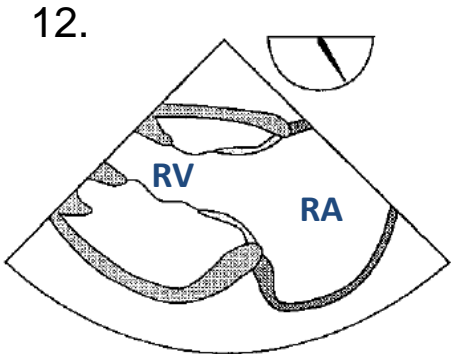
TG mid SAX



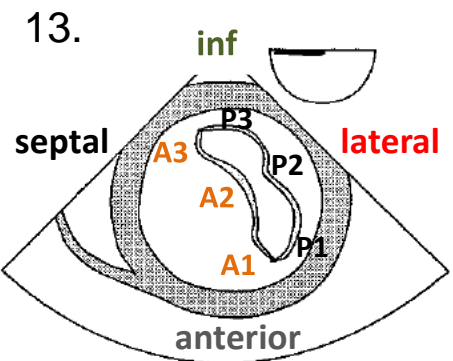
TG two chamber



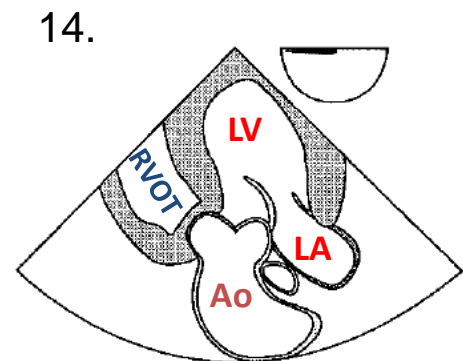
TG LAX



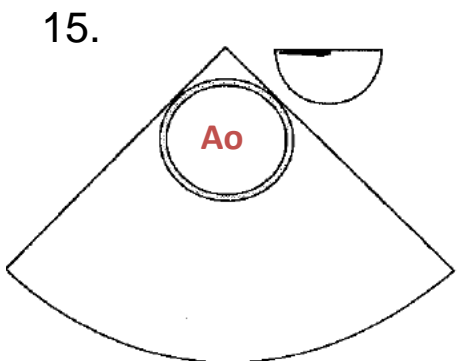
TG RV inflow



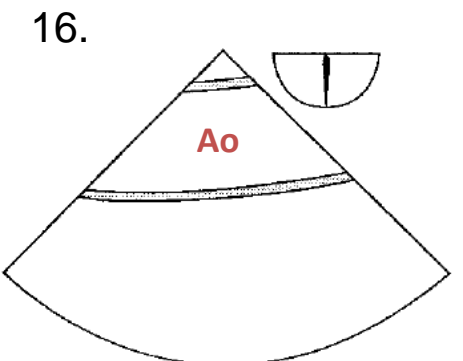
TG basal SAX



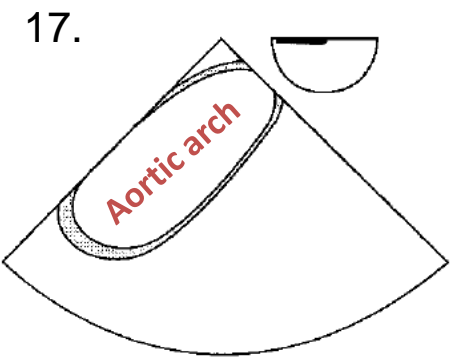
deep TG LAX



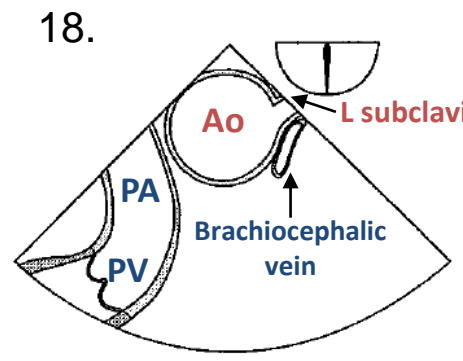
desc aortic SAX



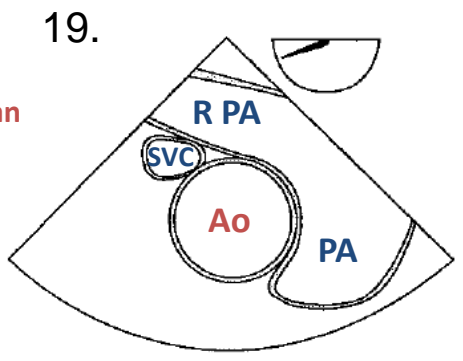
desc aortic LAX



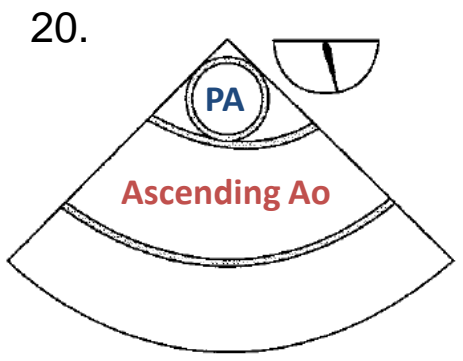
UE aortic arch LAX



UE aortic arch SAX



ME asc aortic SAX



ME asc aortic LAX