

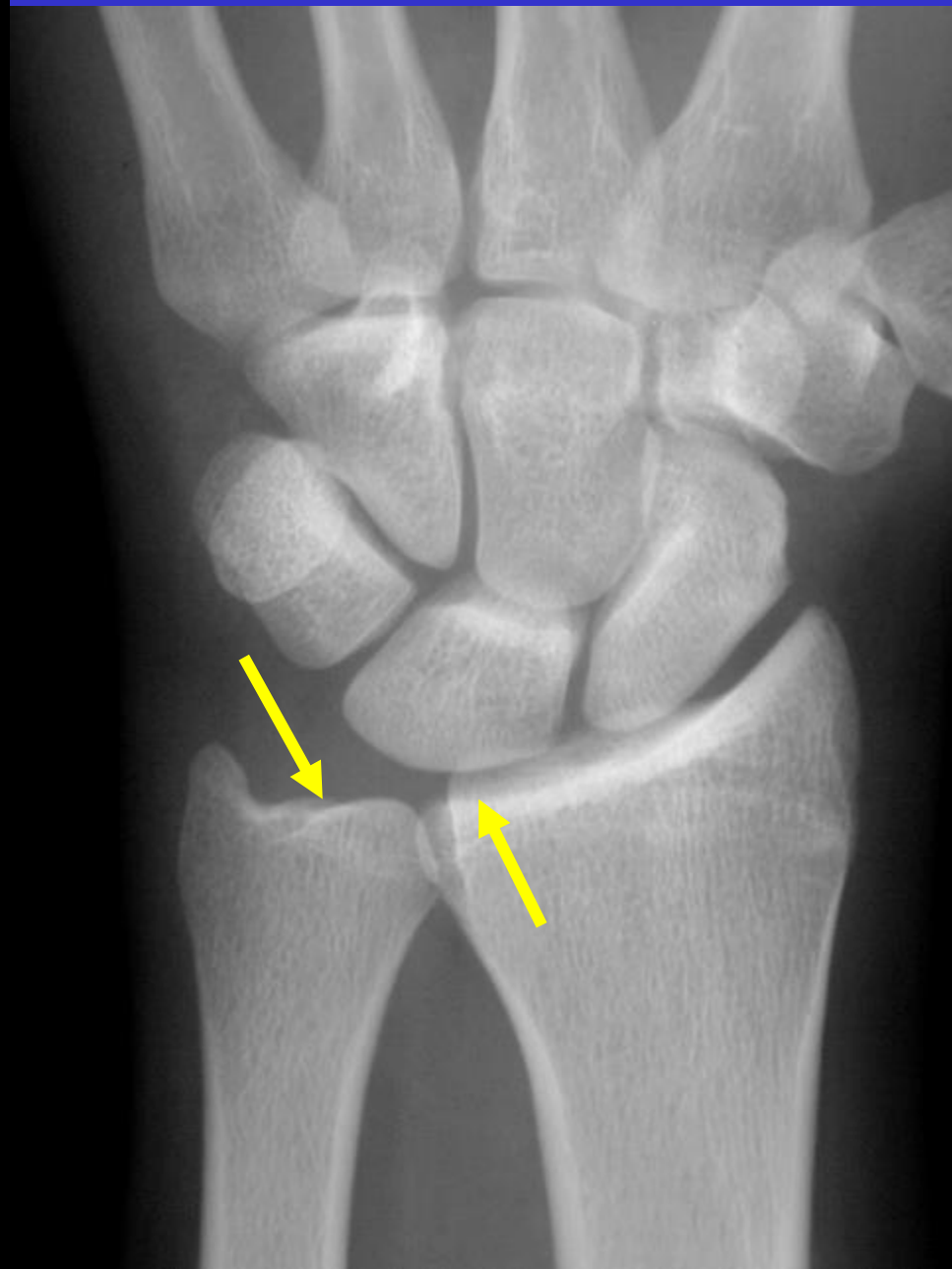
Distal Radio-ulnar Joint

Dr Stuart Myers

Orthopaedic Hand Surgeon,
Prince of Wales Hospital, Sydney
Sydney Orthopaedic Specialists

www.myhand.com.au



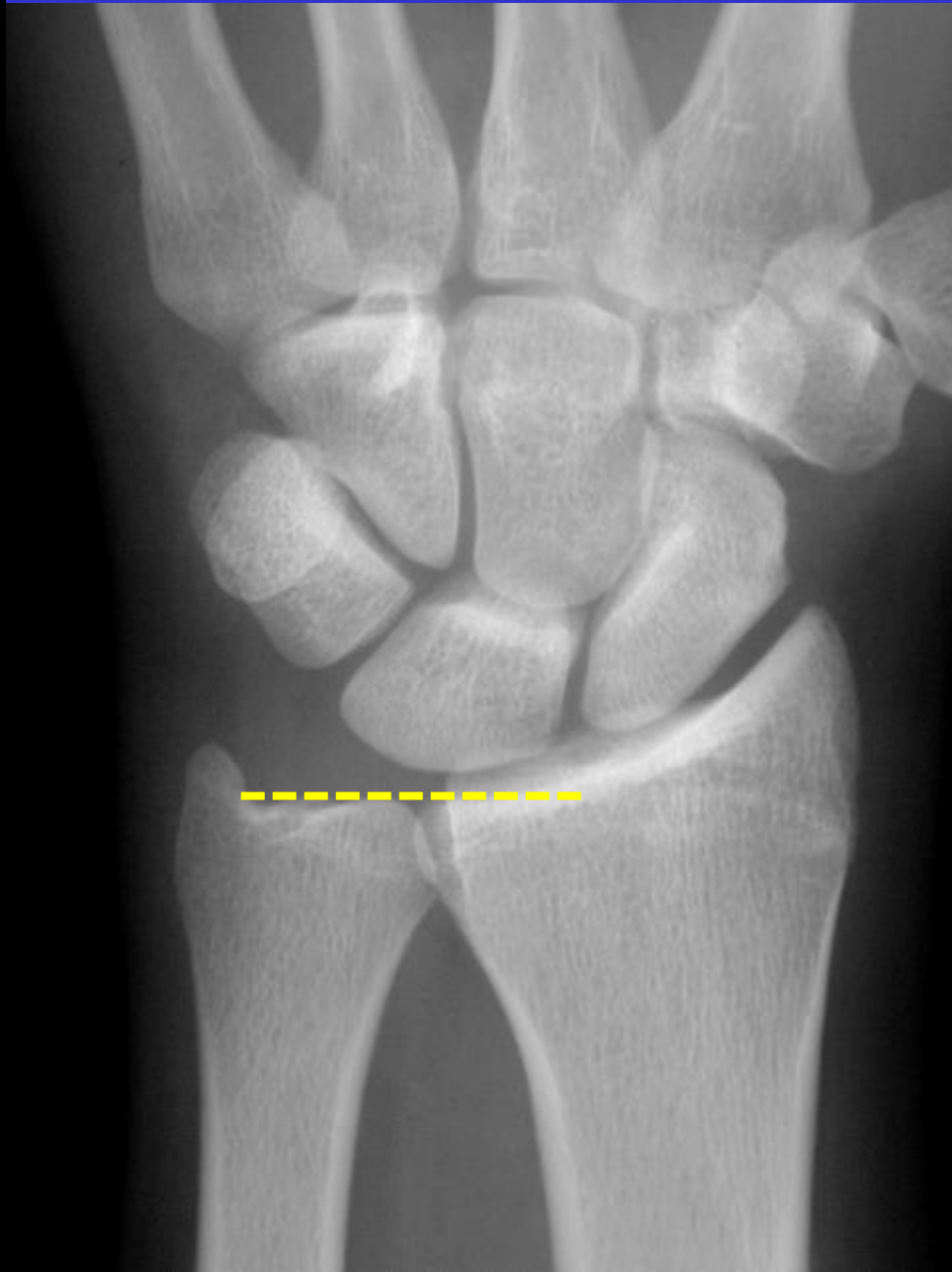


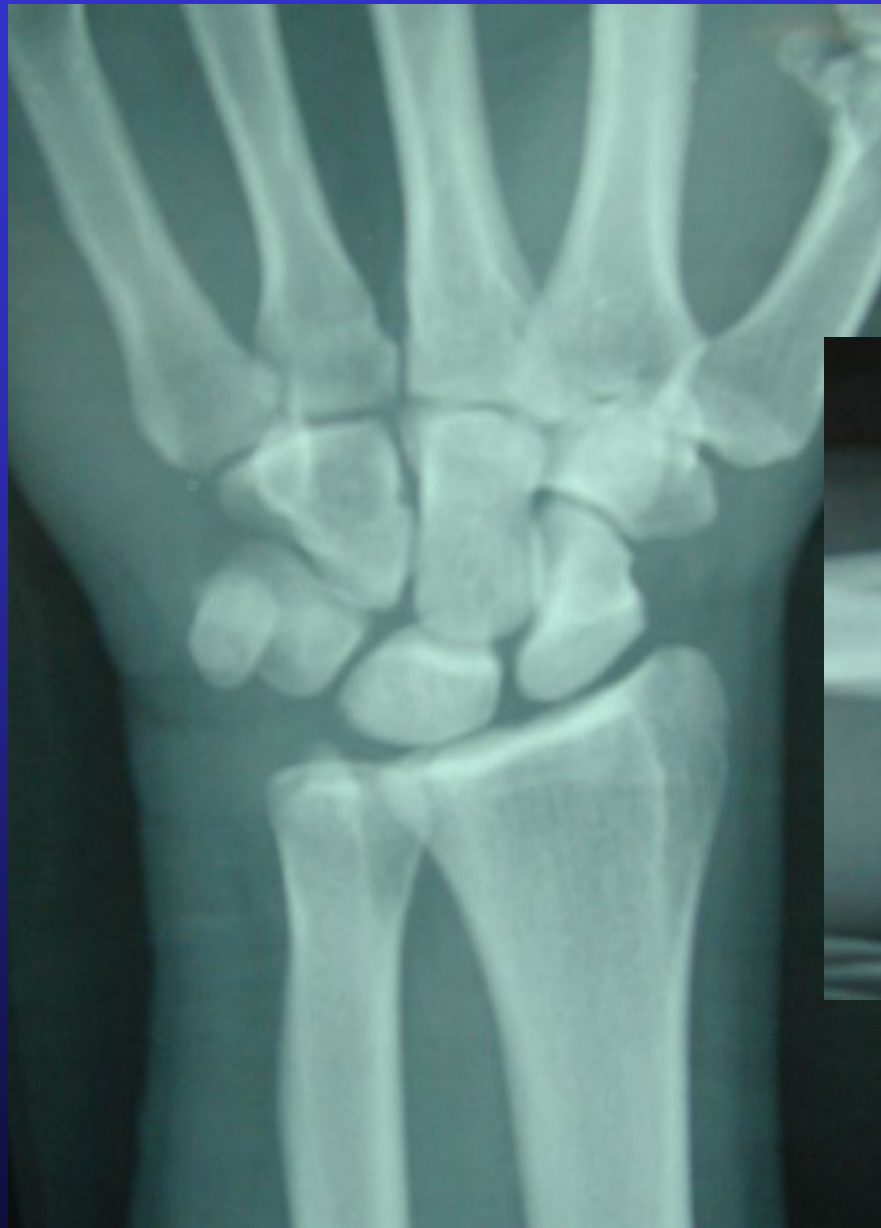- Ulnar Variance

Ulna Variance

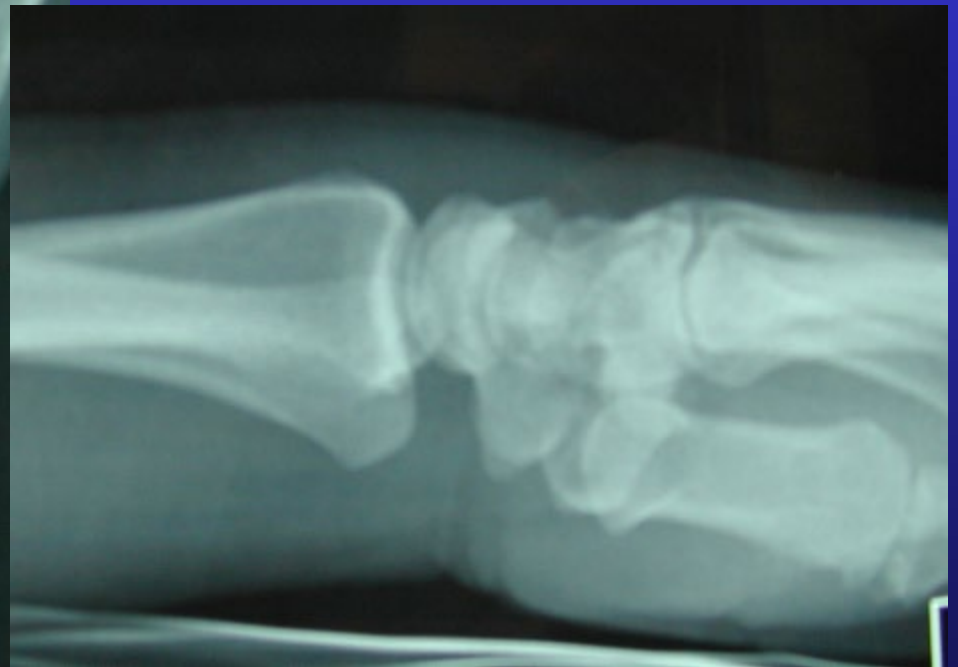“Neutral”

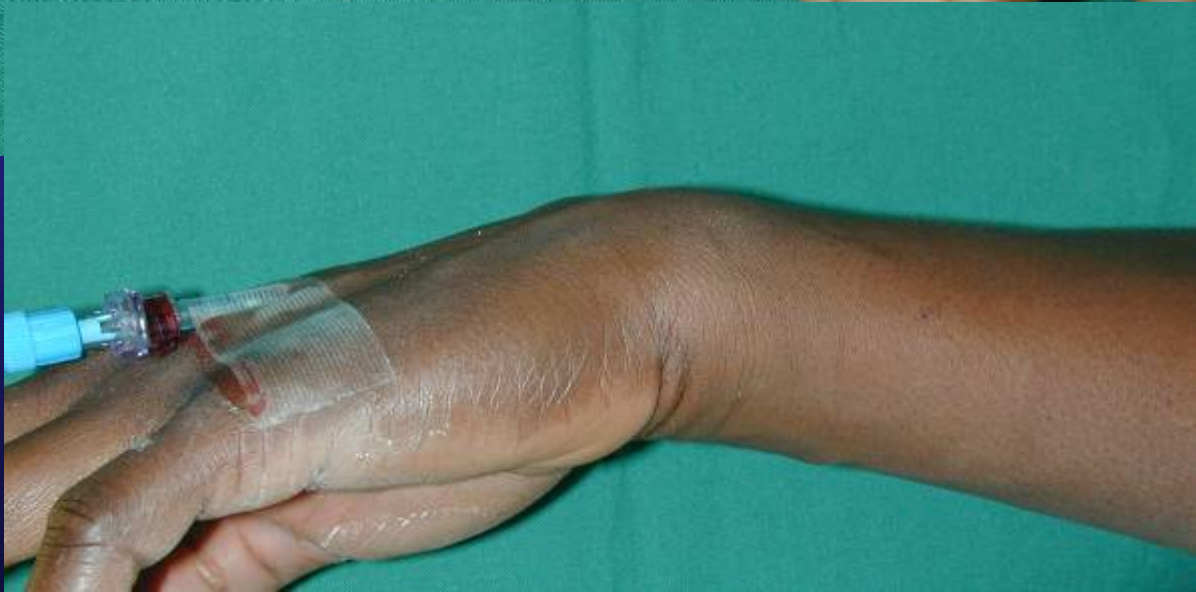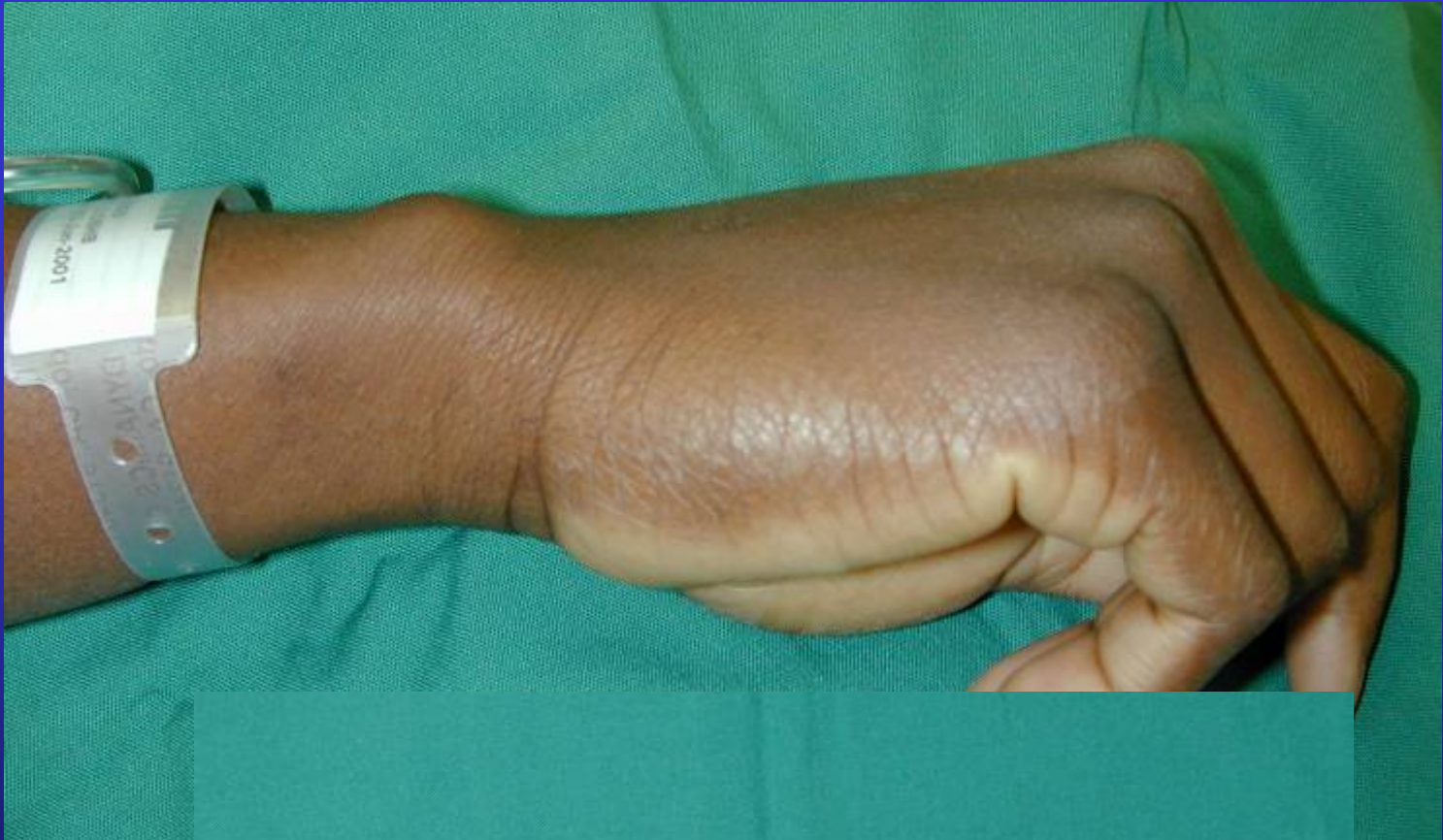60% population



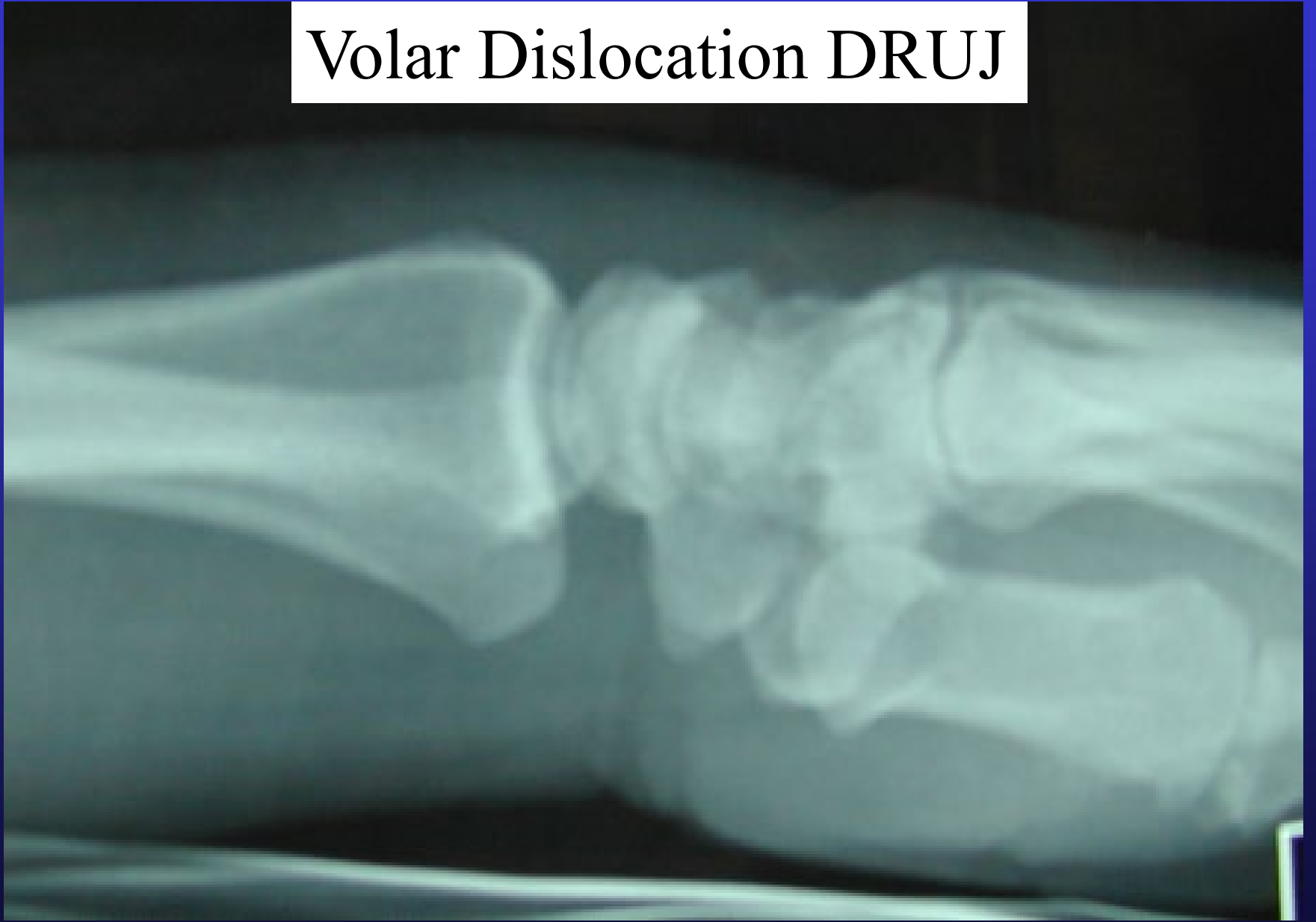

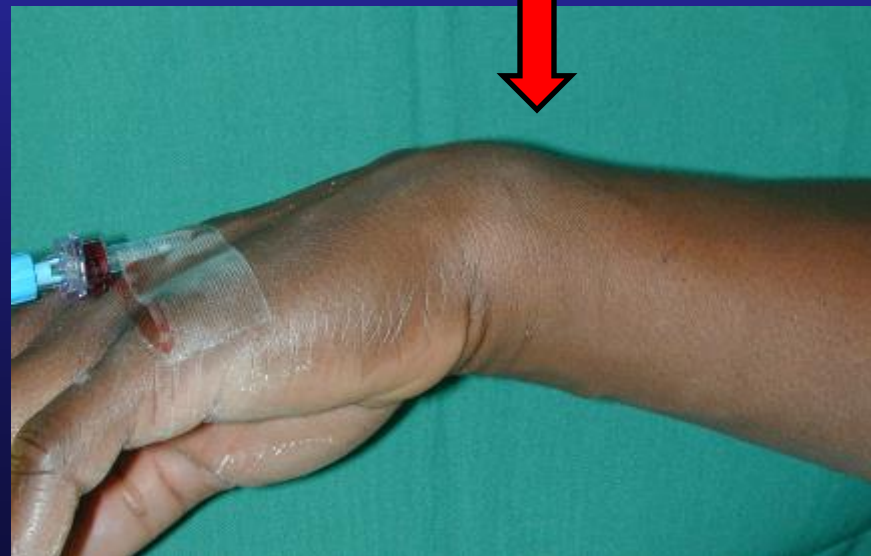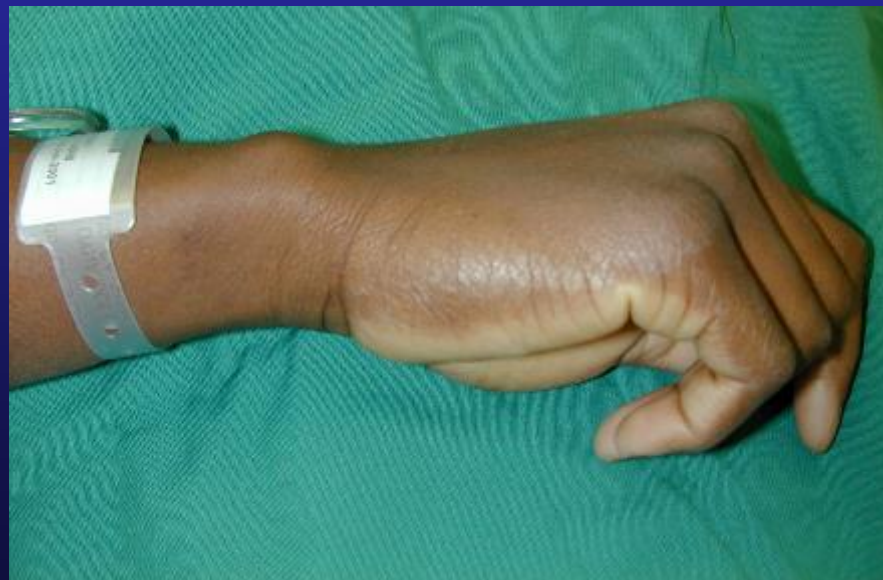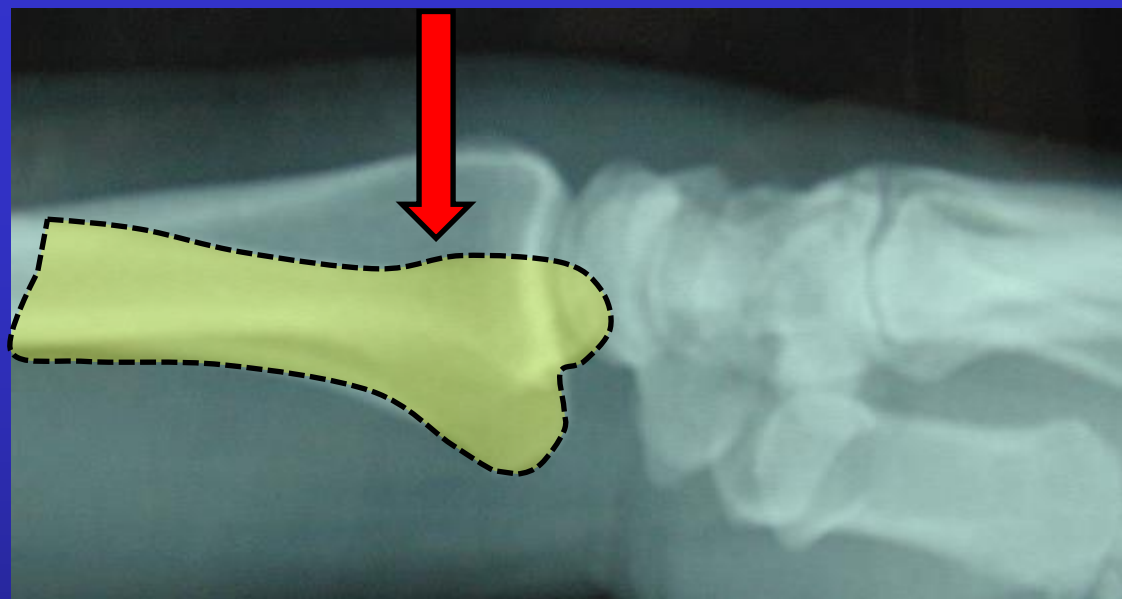
???



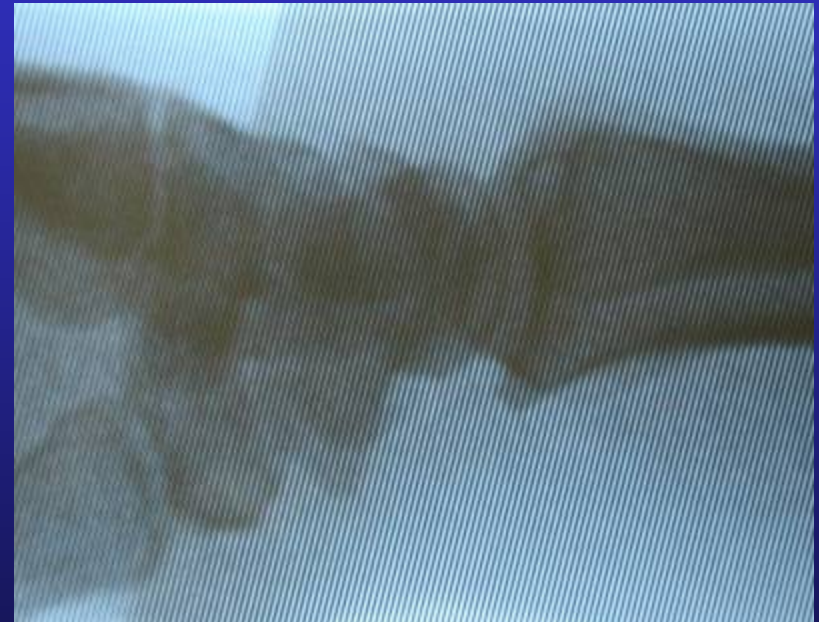
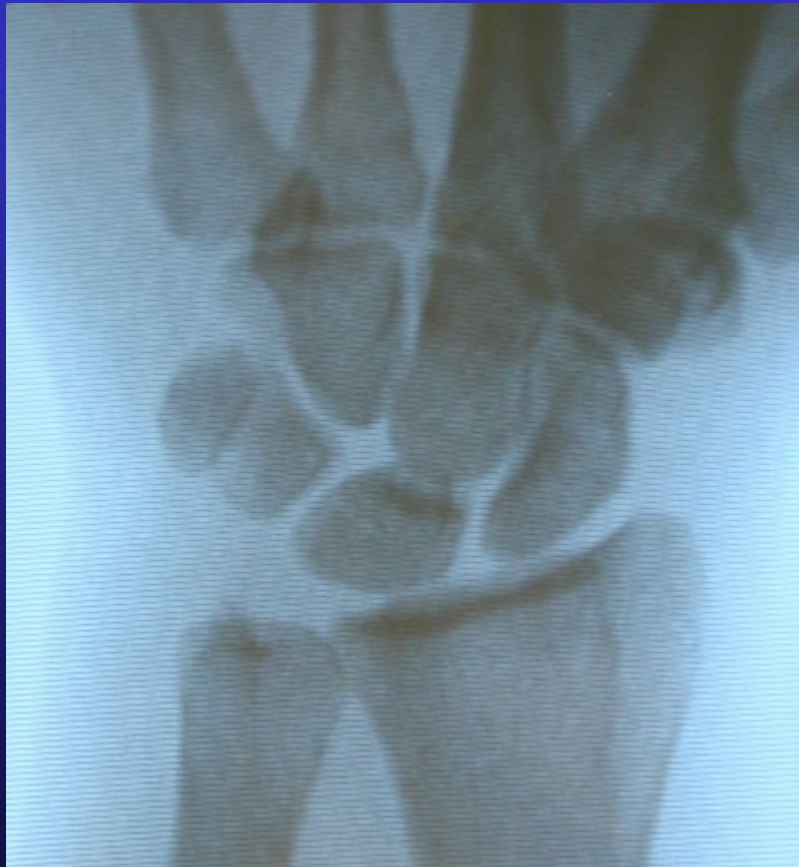
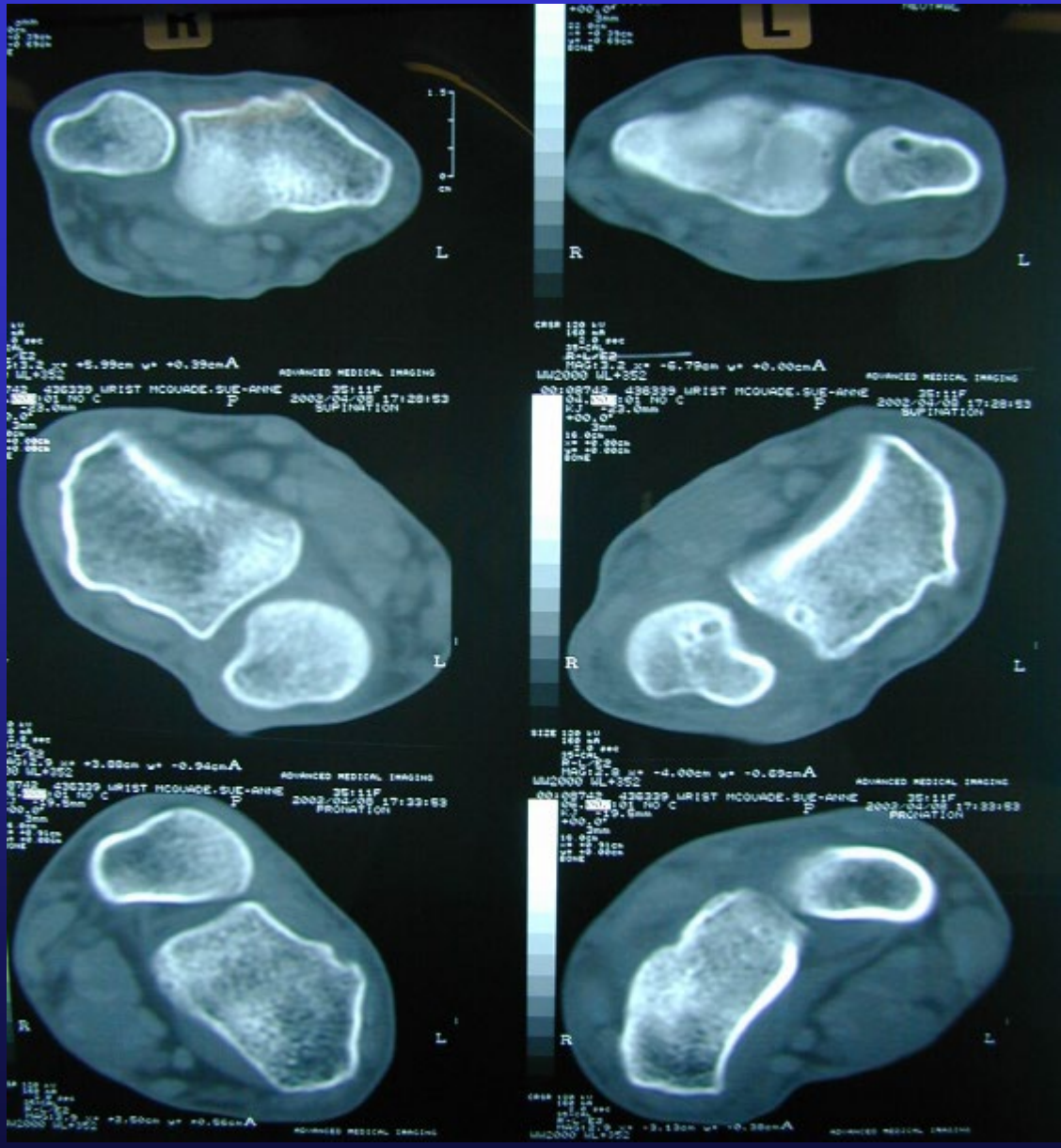
Volar Dislocation DRUJ





DRUJ Post reduction

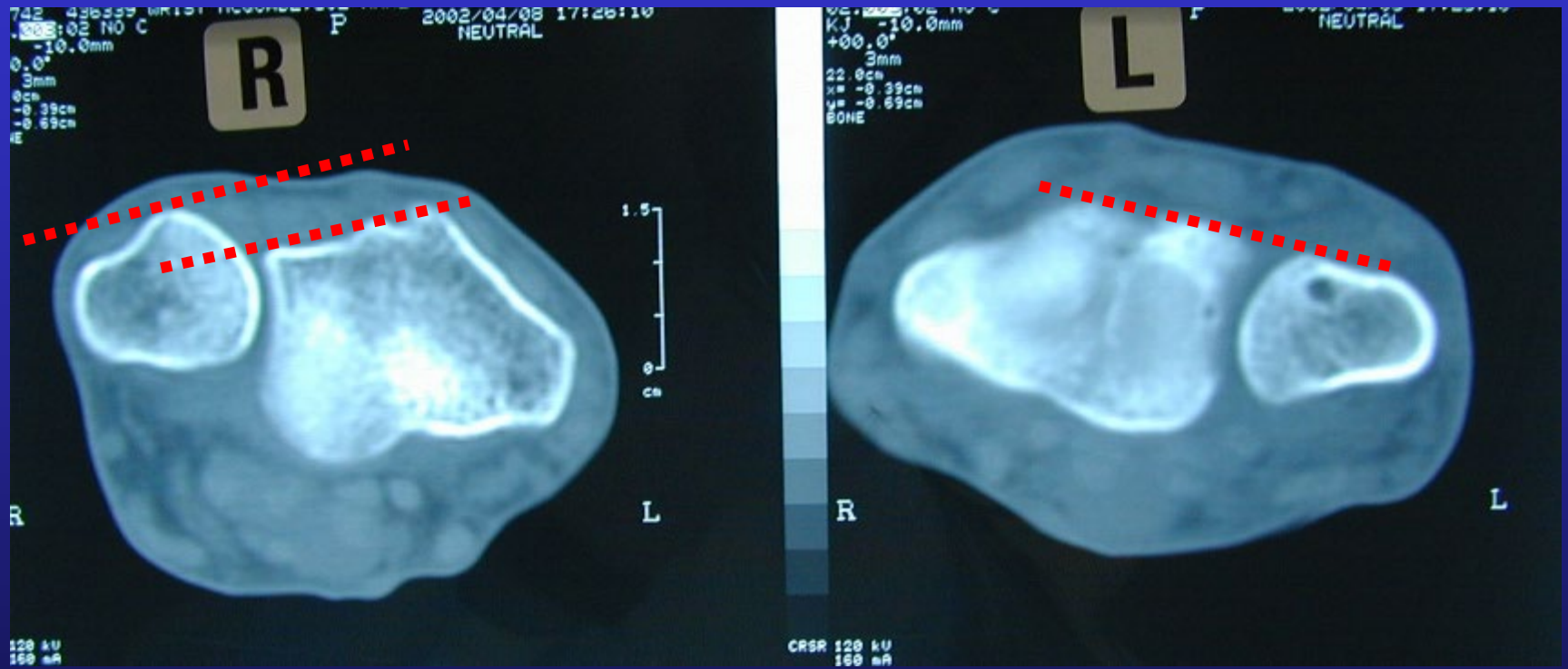




Neutral

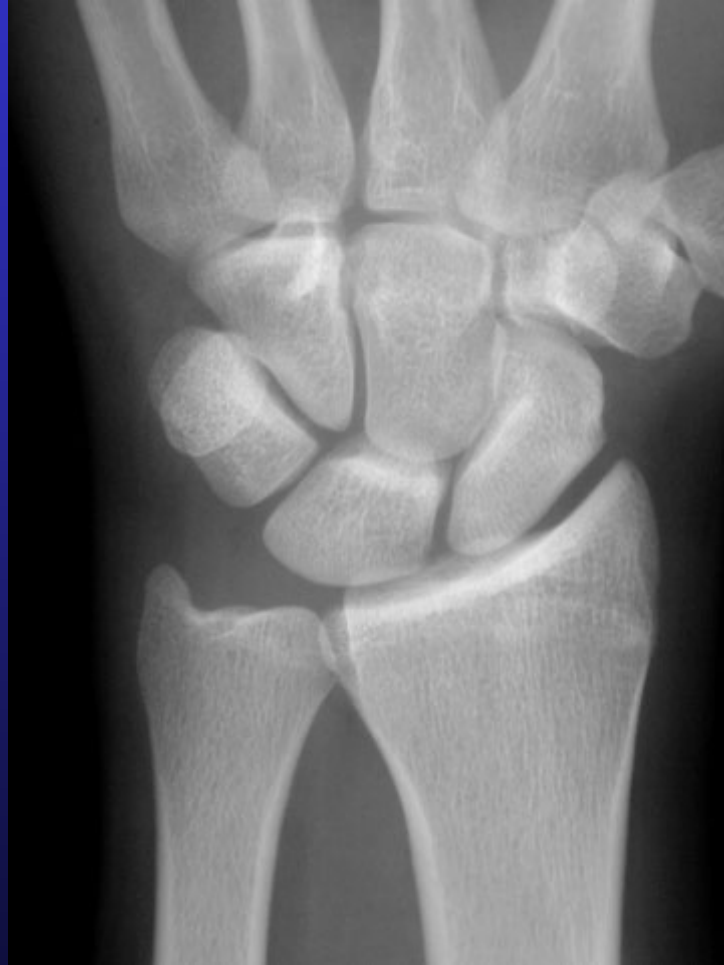Supination

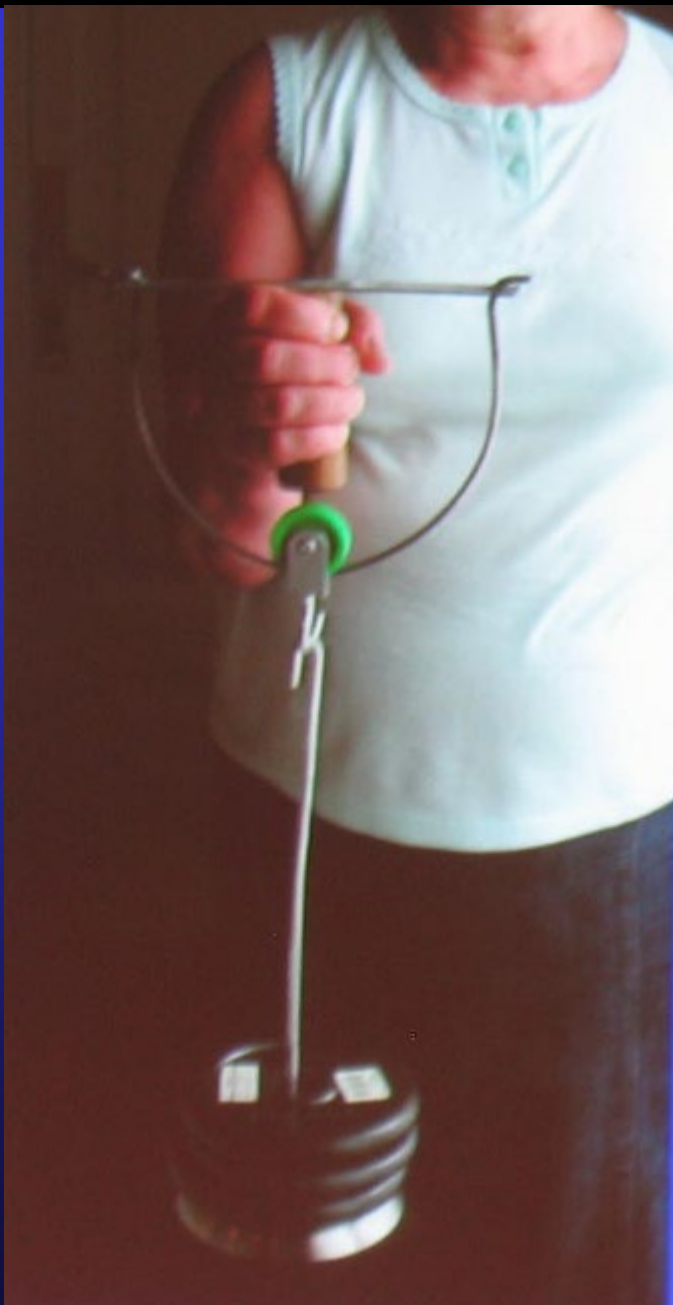Pronation



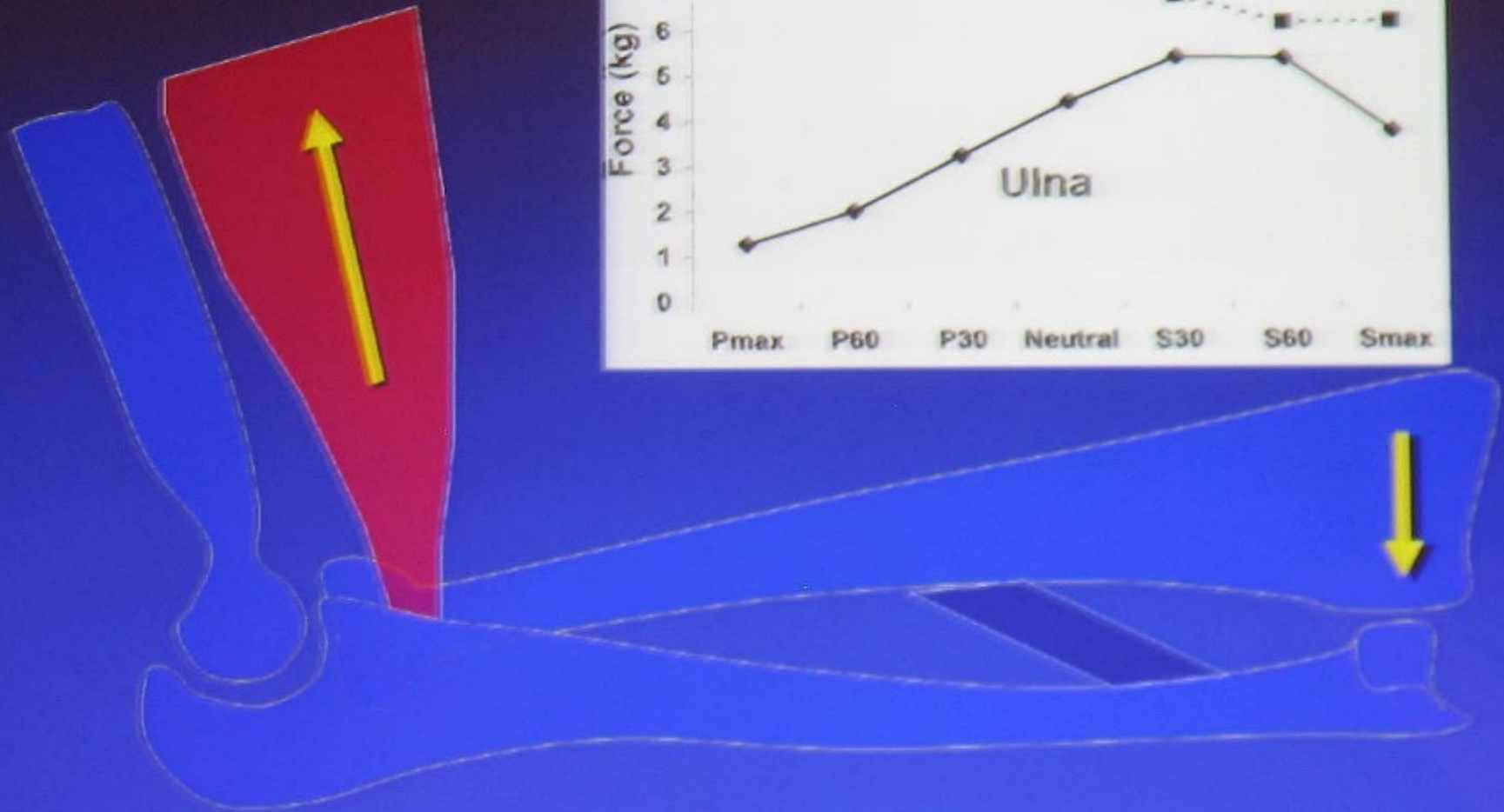
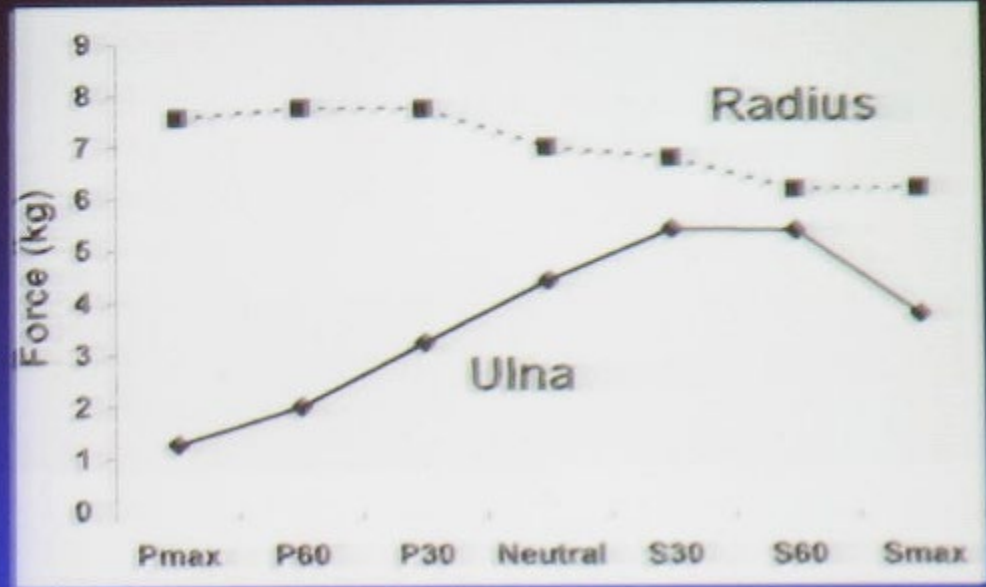
DRUJ Weight Bearing JT

- When Carrying a weight in front of you

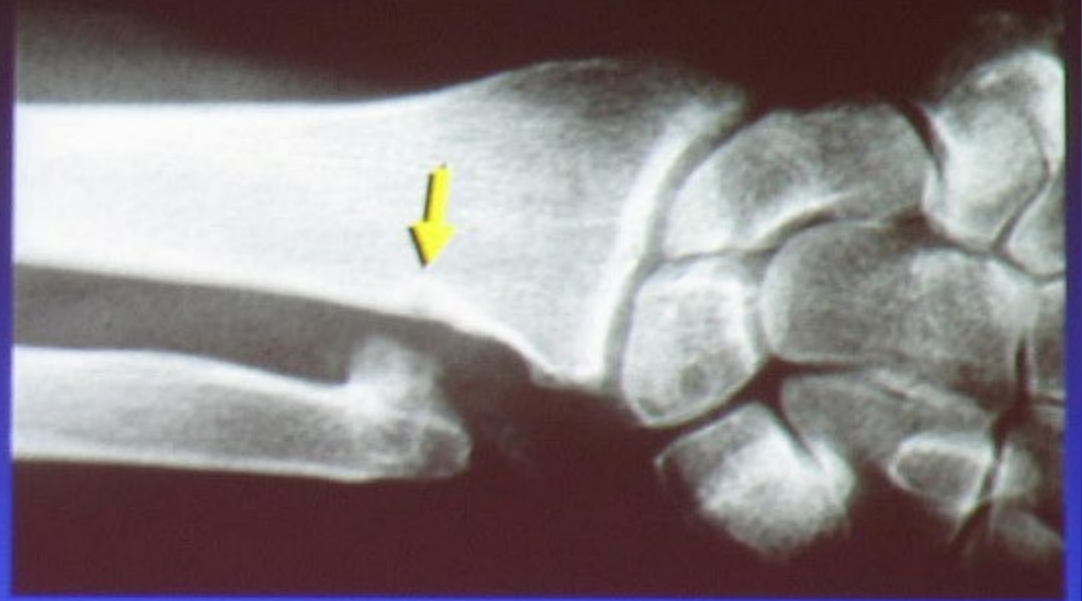


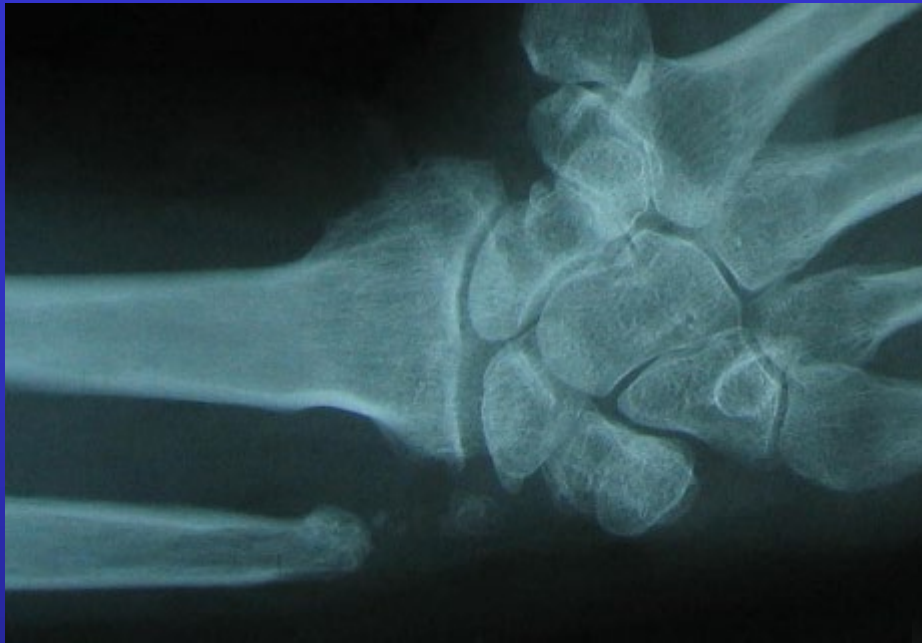
Shaaban et al. J Hand Surg 29A:85,2004



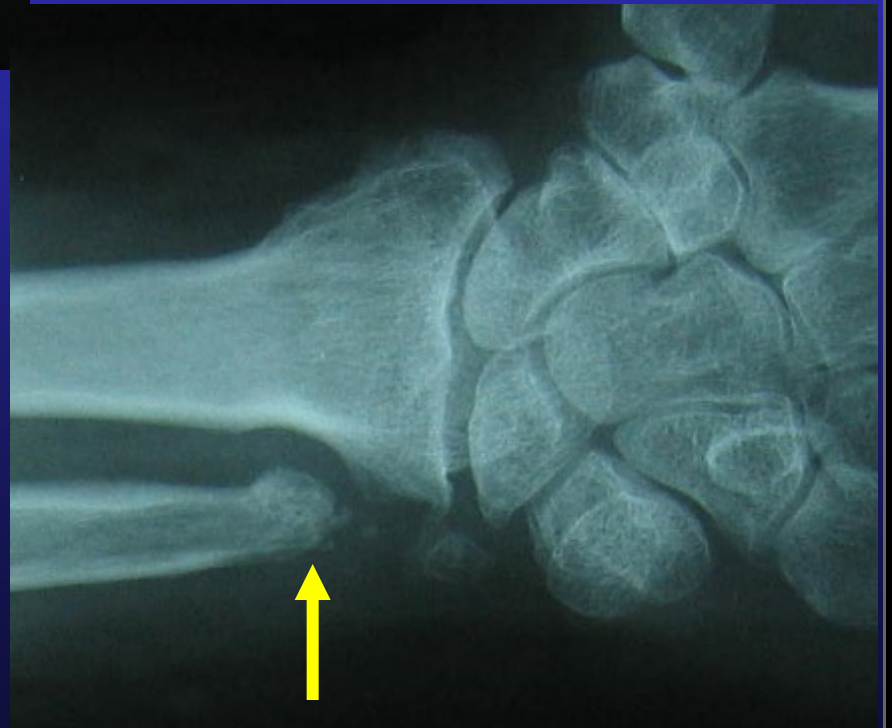Brachialis



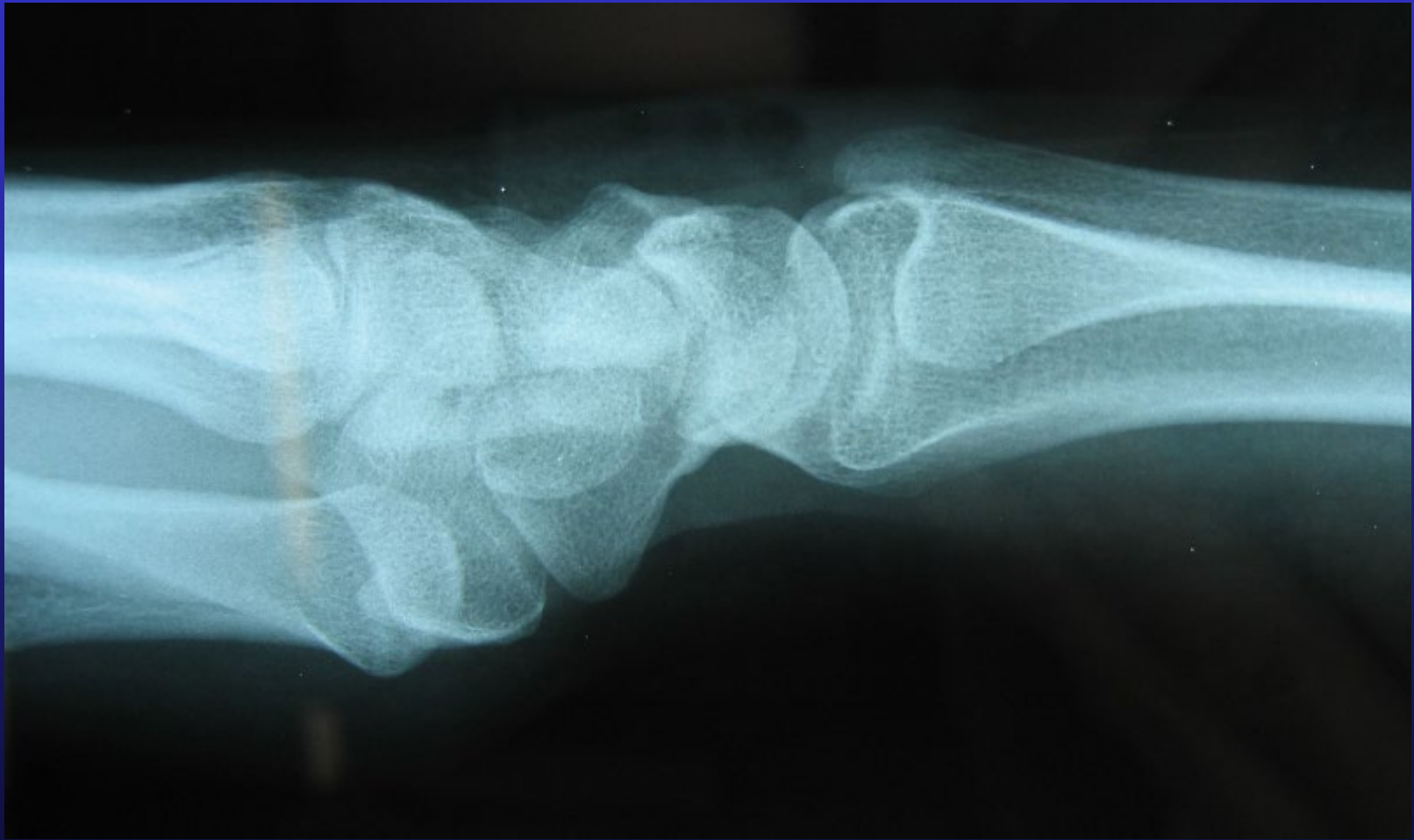

- Non Weight Bearing

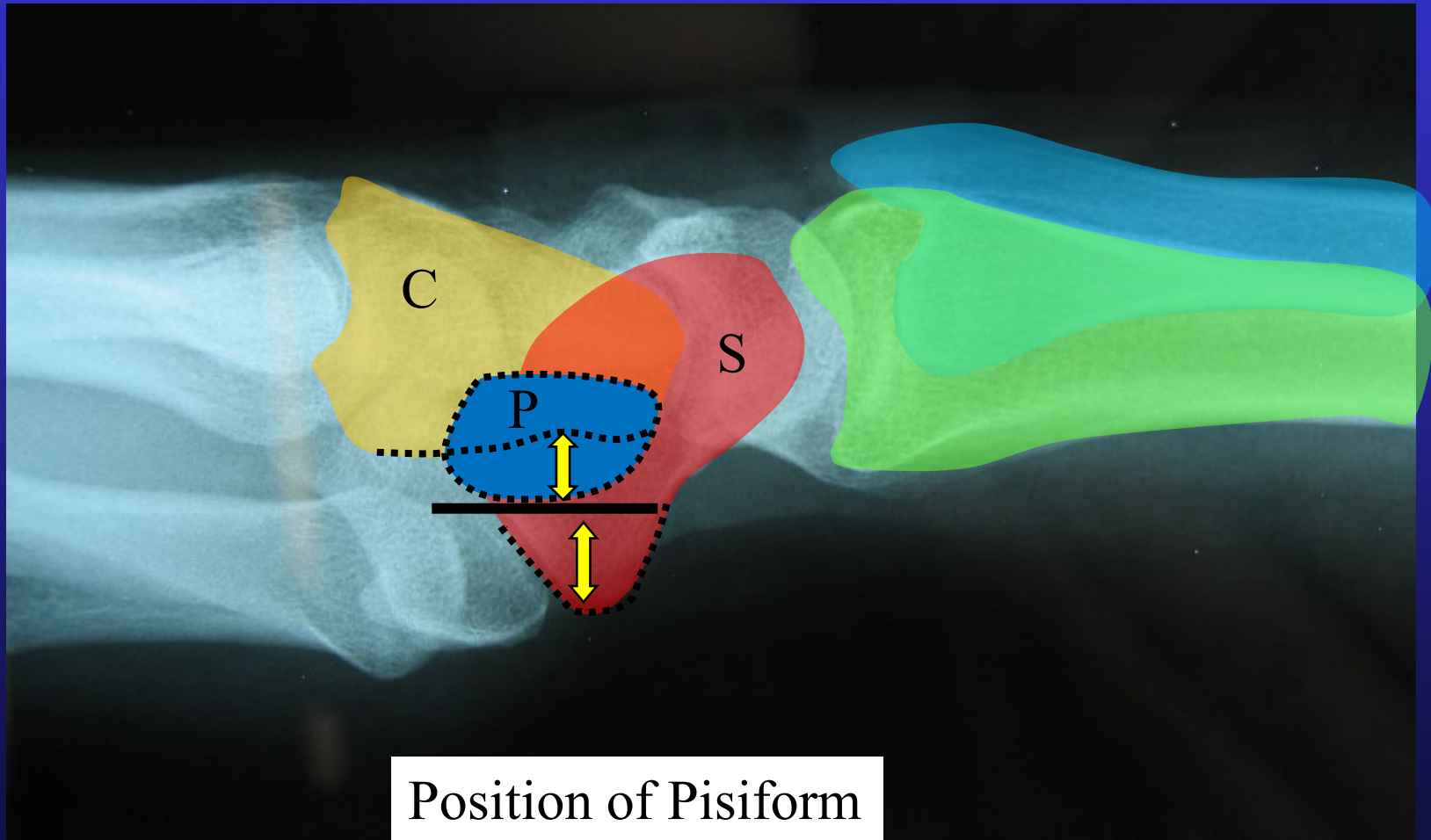
- Weight Bearing



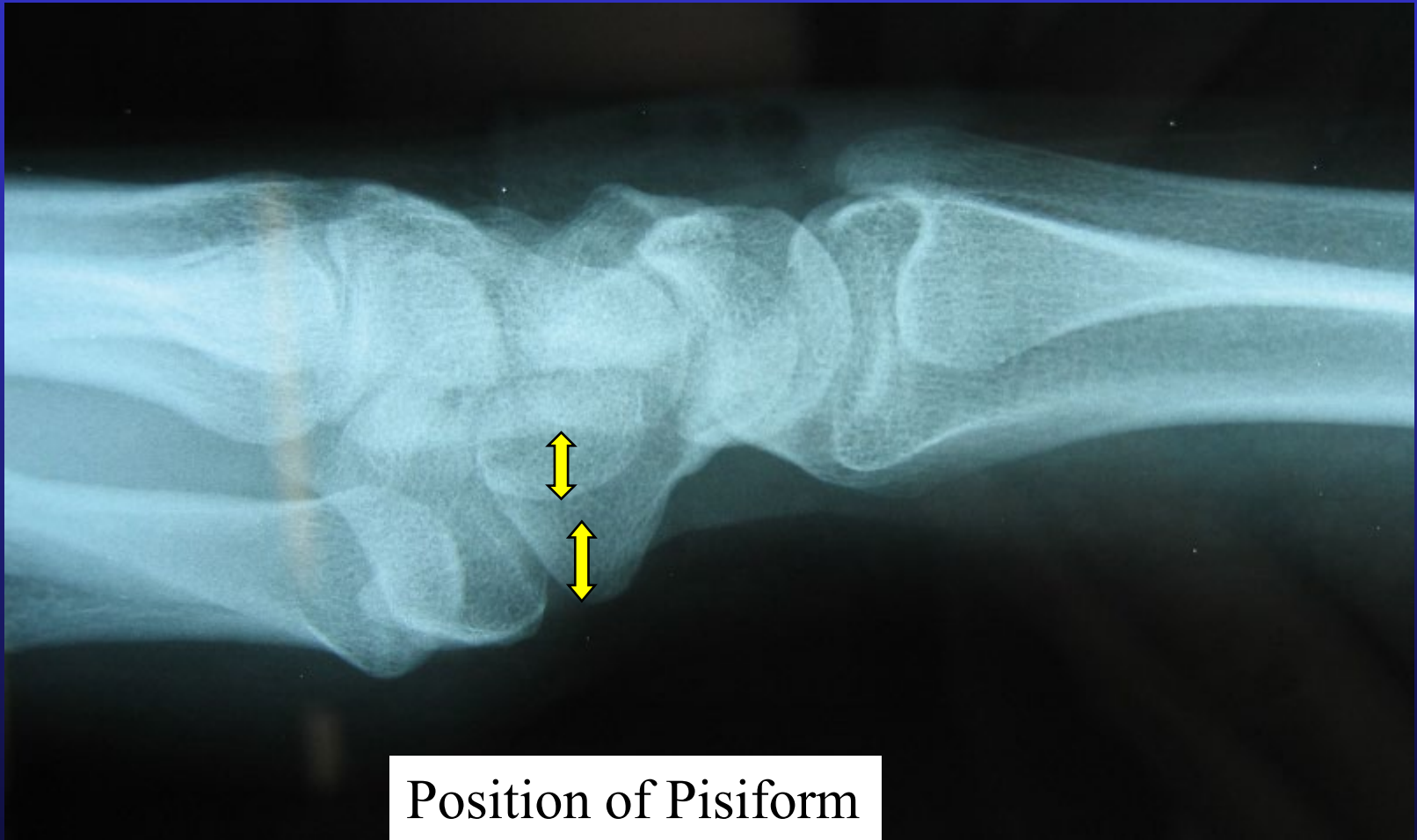Lateral Views




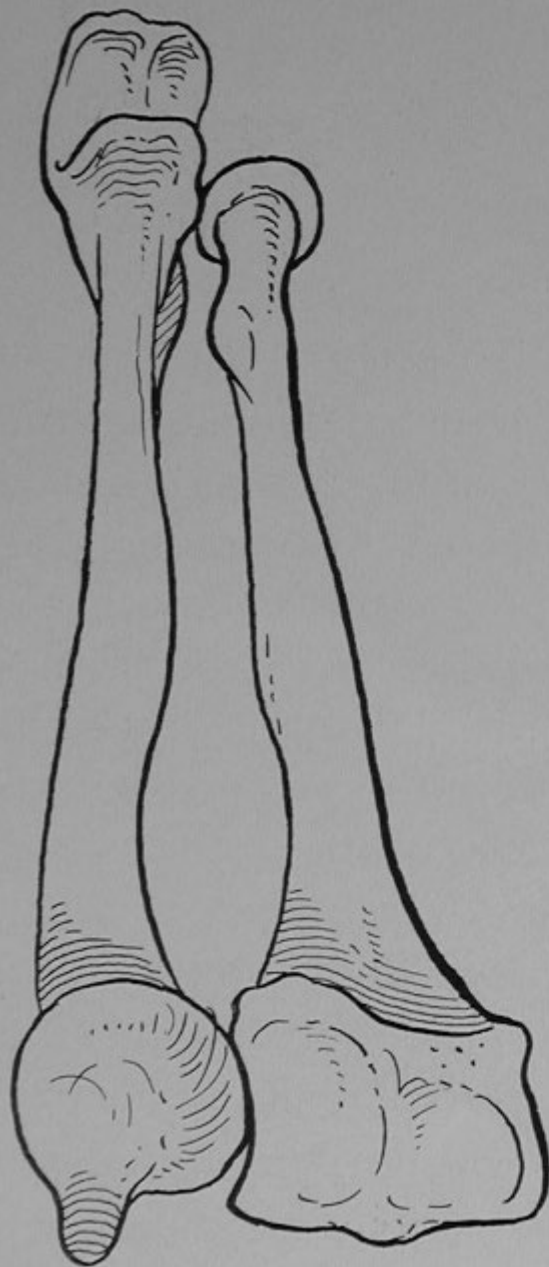
“True Lateral”


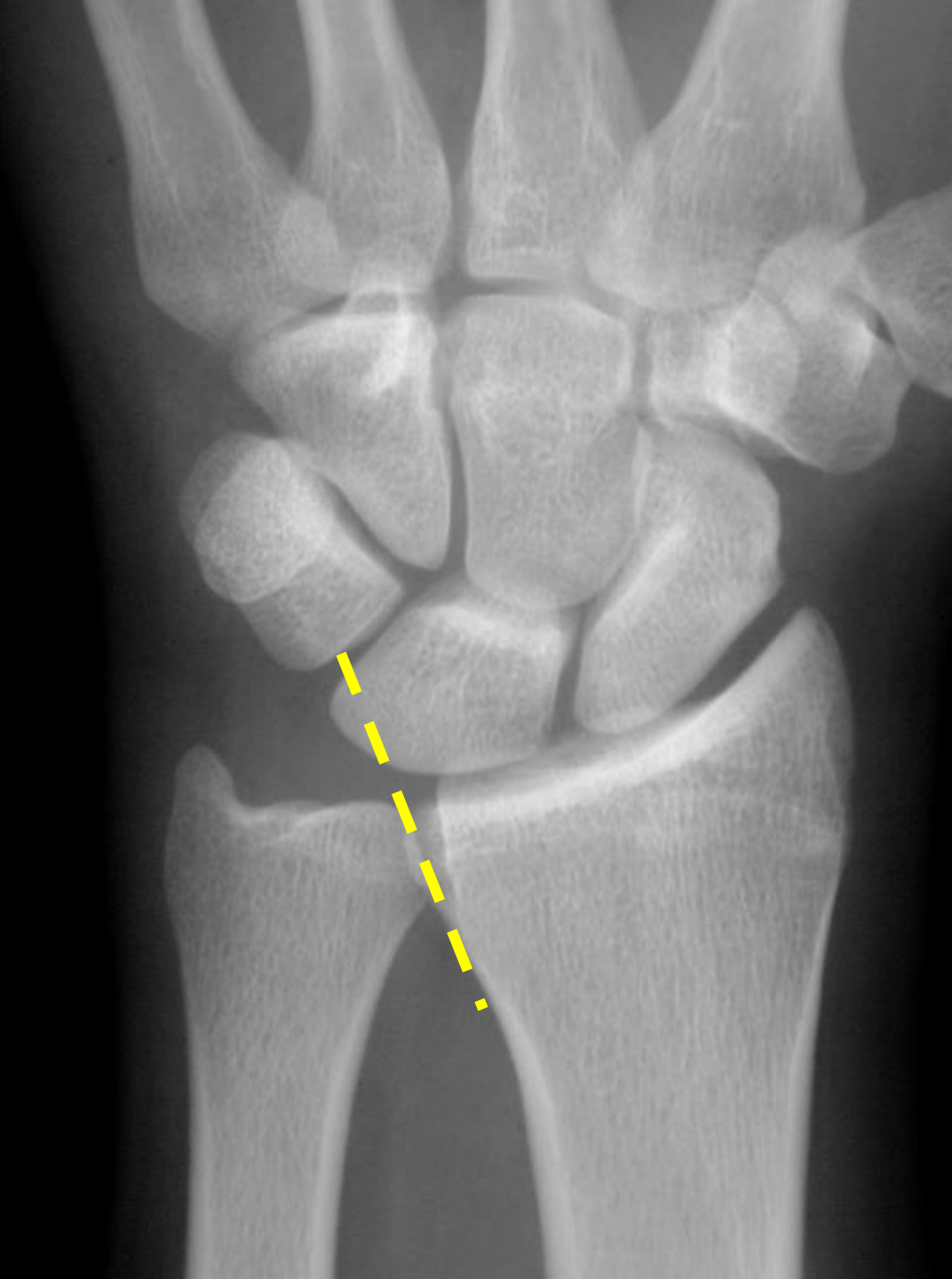


“True Lateral”

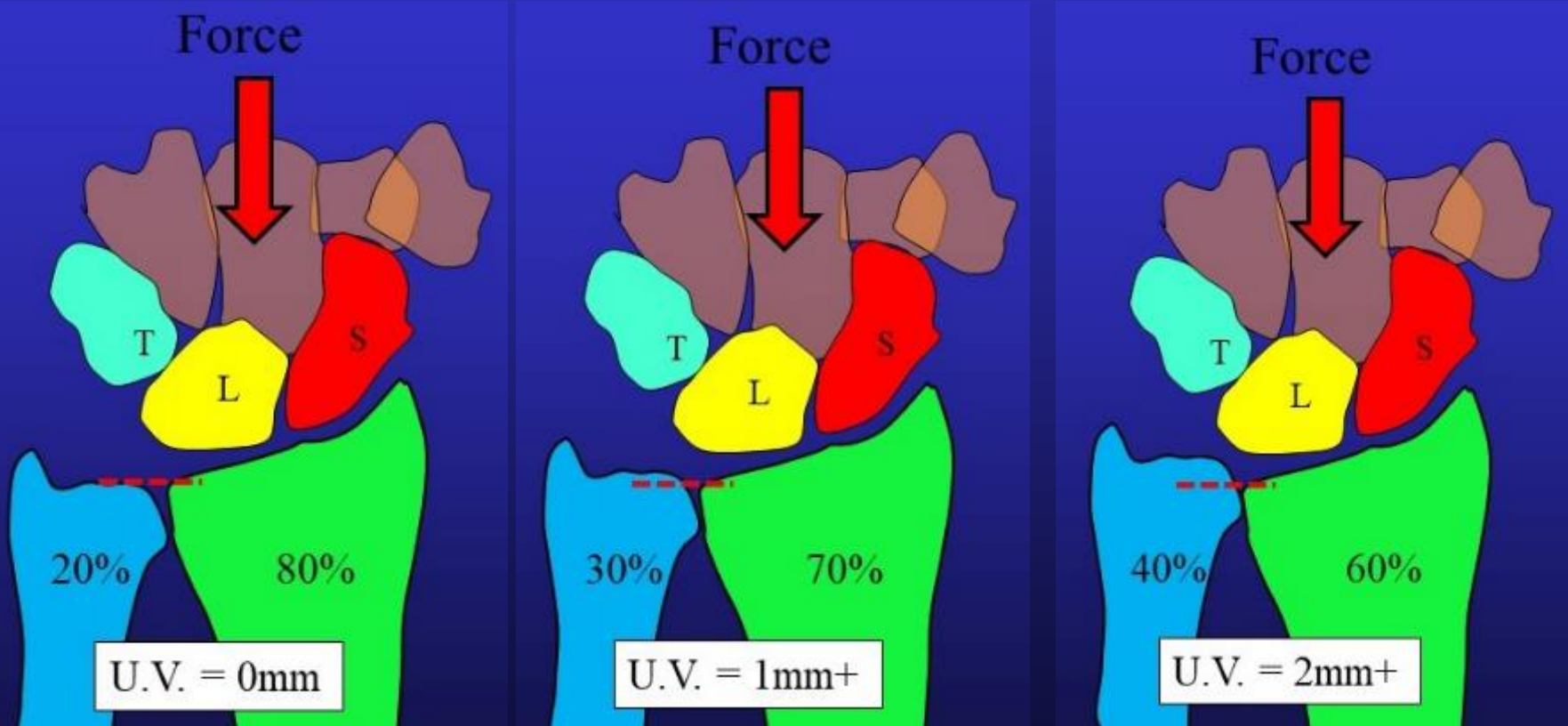


Position of Pisiform





Force across wrist



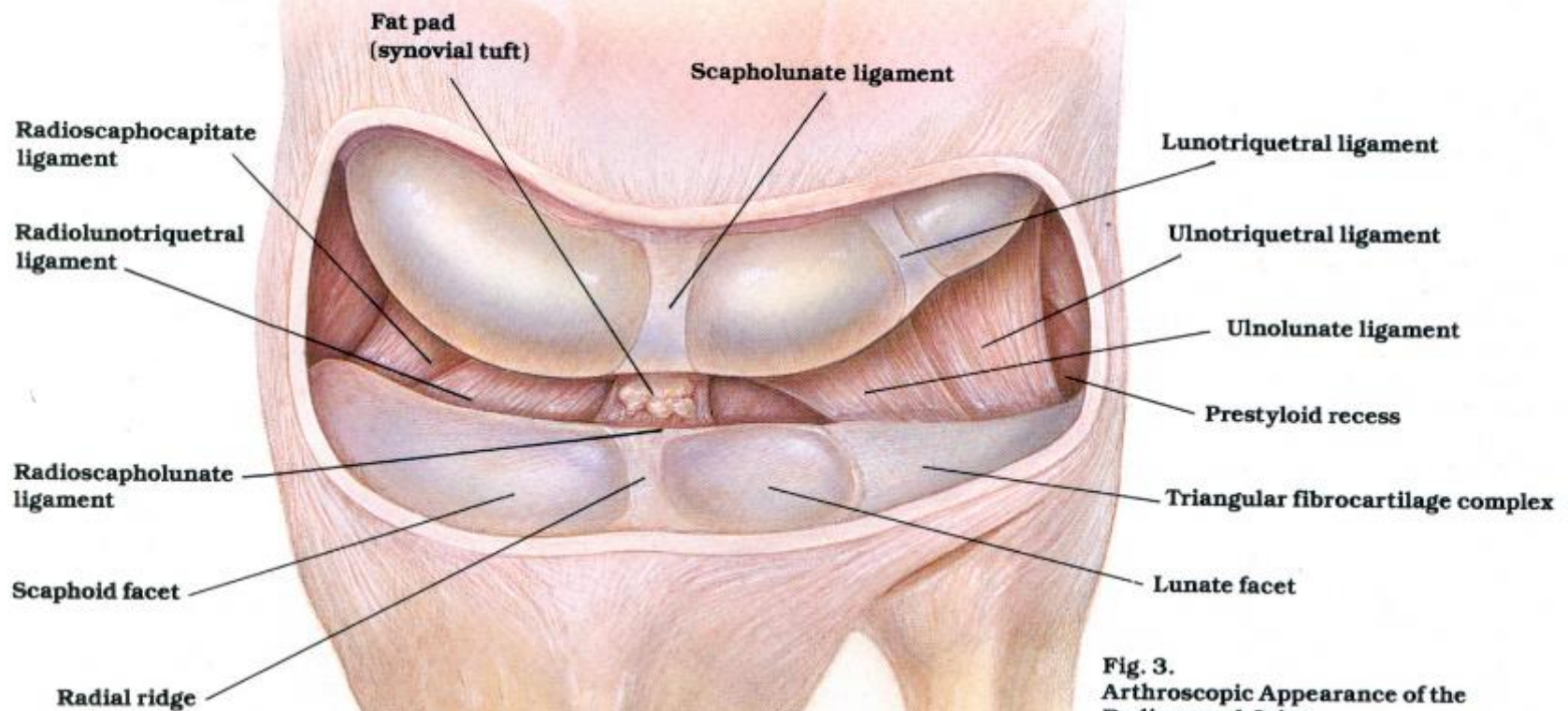
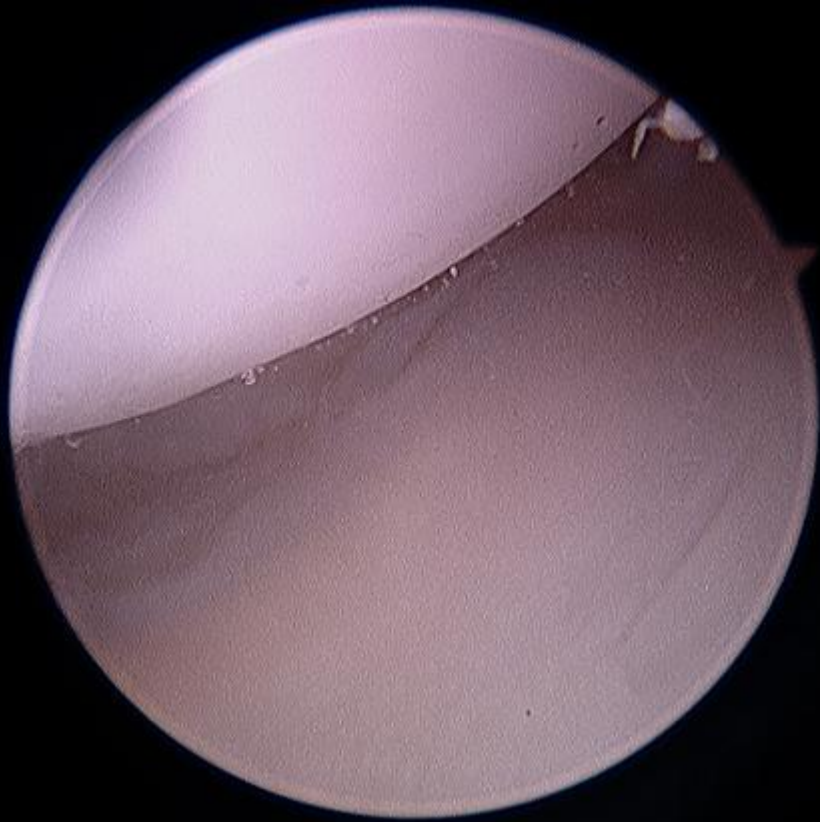
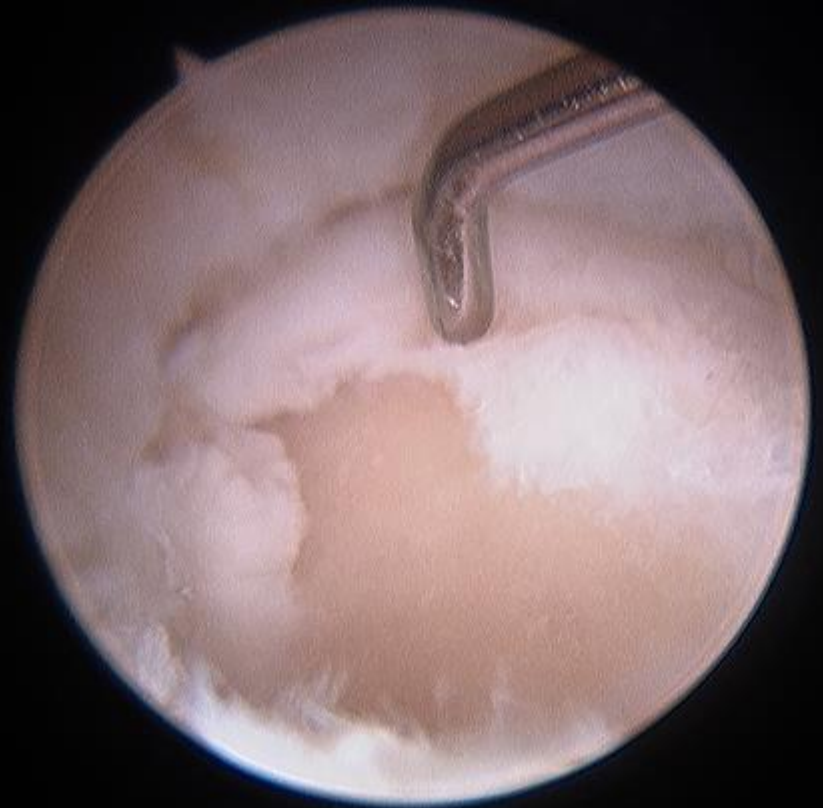

Fig. 3.
Arthroscopic Appearance of the Radiocarpal Joint
 The fat pad, sometimes referred to as the synovial tuft, over the radioscapholunate ligament (ligament of Testut), is usually the first structure seen through the 3-4 portal, and is a convenient landmark for orientation during arthroscopy. The scapholunate ligament is above, and the radial ridge, between the scaphoid and lunate facets of the radius, is below.

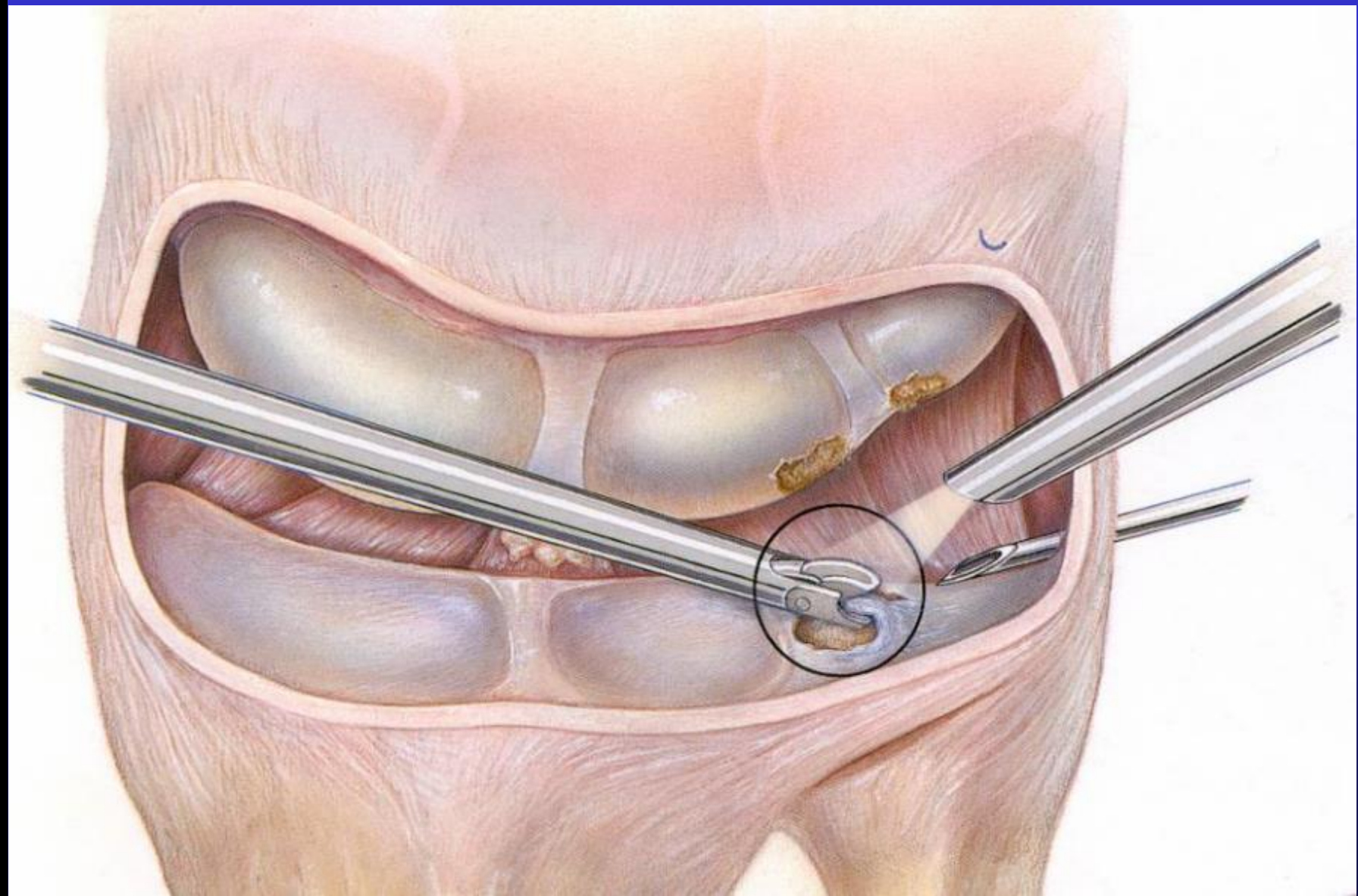
Wrist Arthroscopy



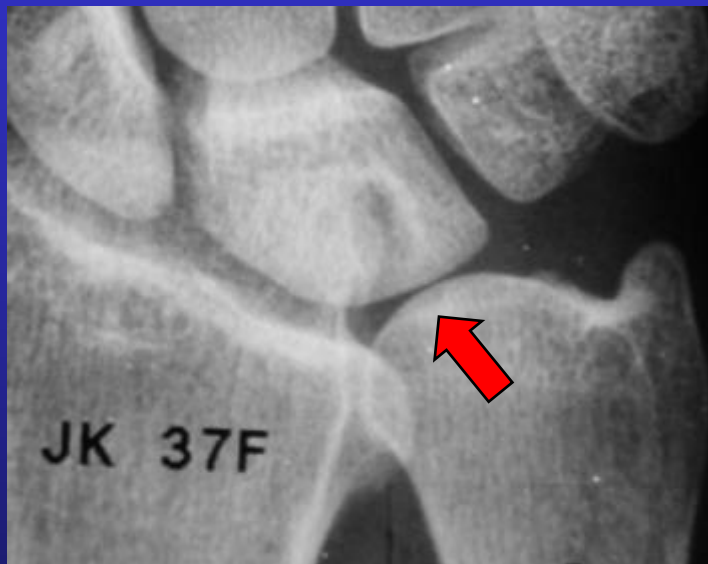
Normal joint surfaces



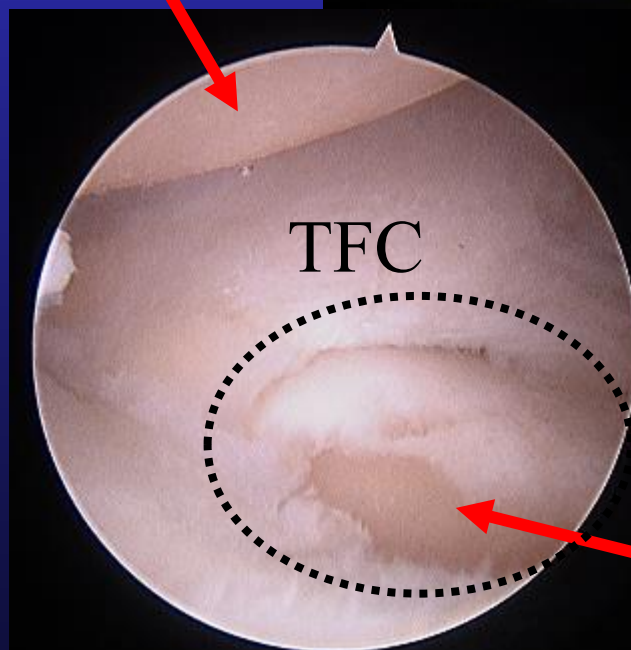
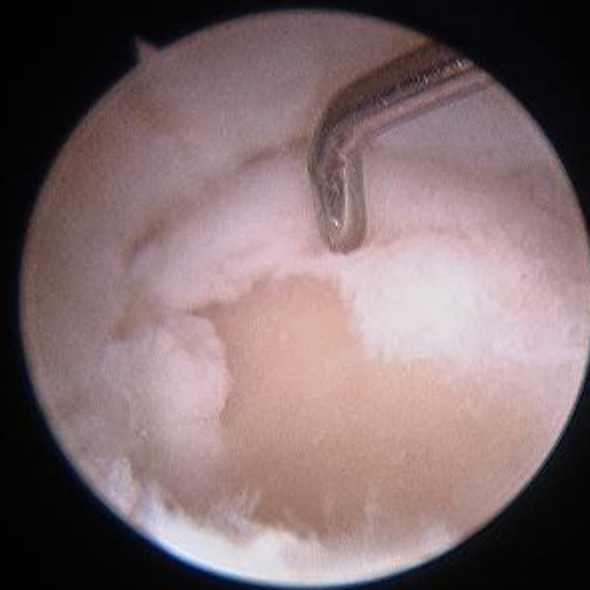Full thickness cartilage defect



Distal Ulnar Impaction



Lunate



Ulna head