

Scaphoid Fractures

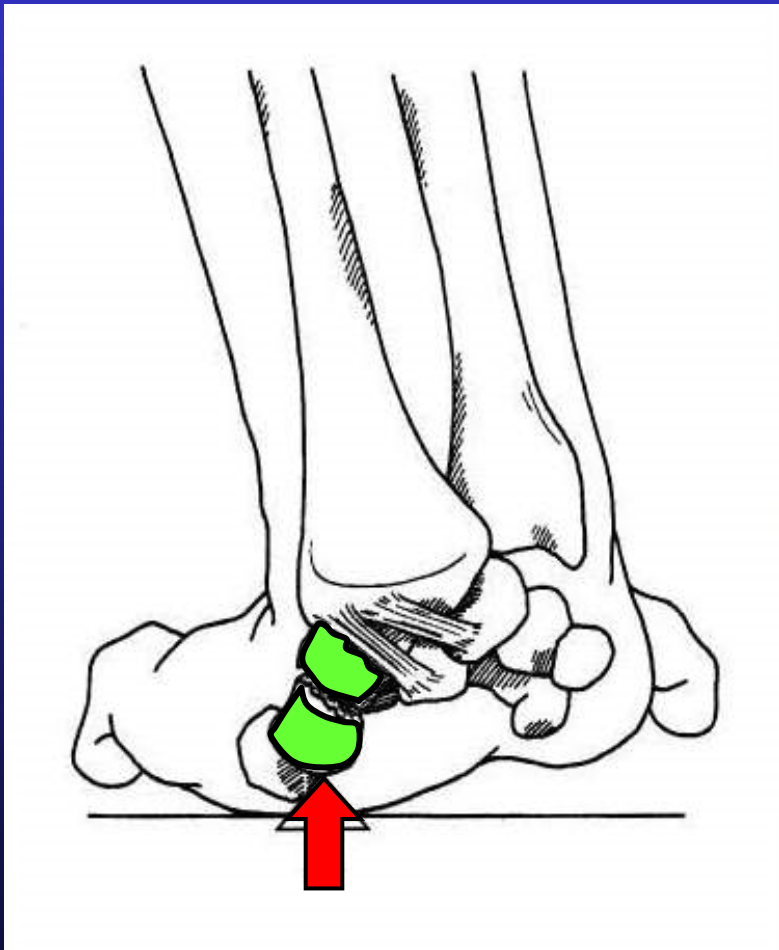
Dr Stuart Myers

Orthopaedic Hand Surgeon,
Sydney Orthopaedic Specialists

www.myhand.com.au

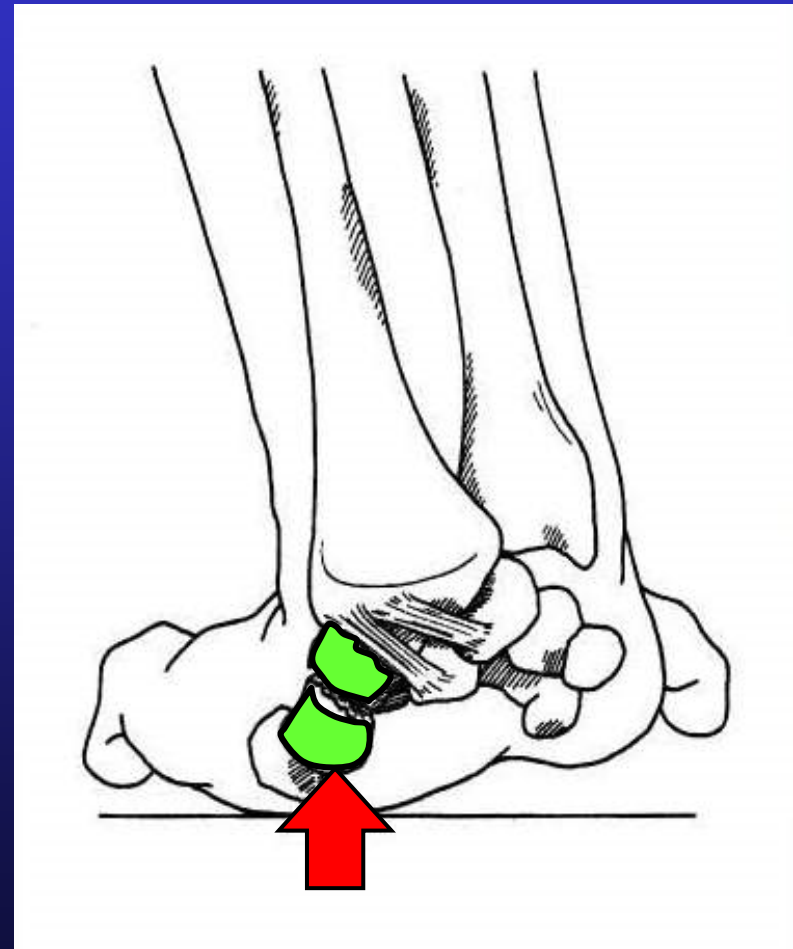
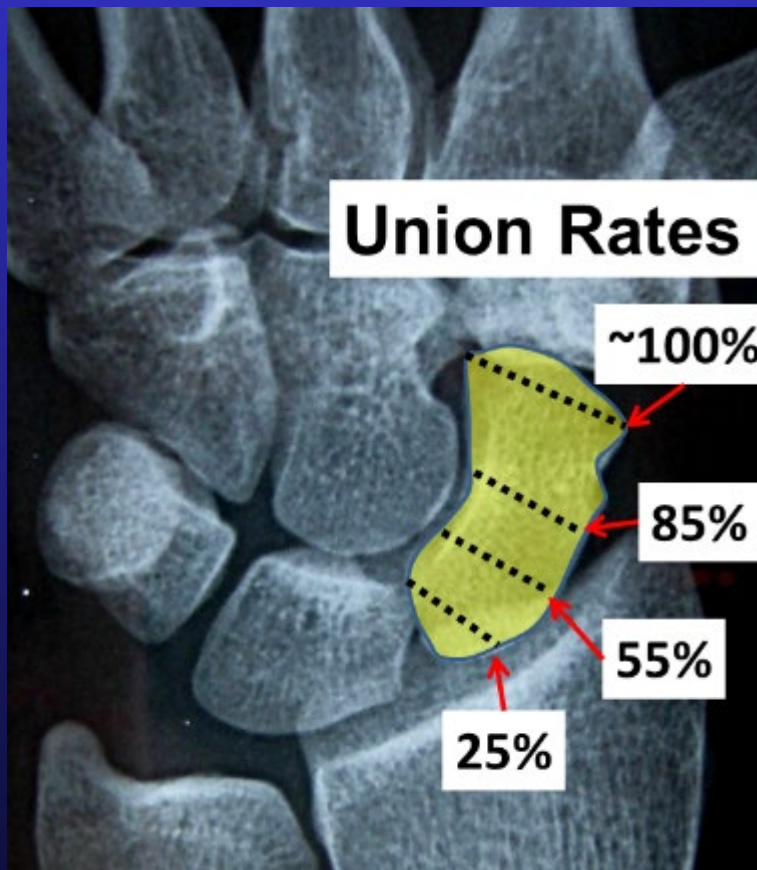


Scaphoid #s \$\$\$\$

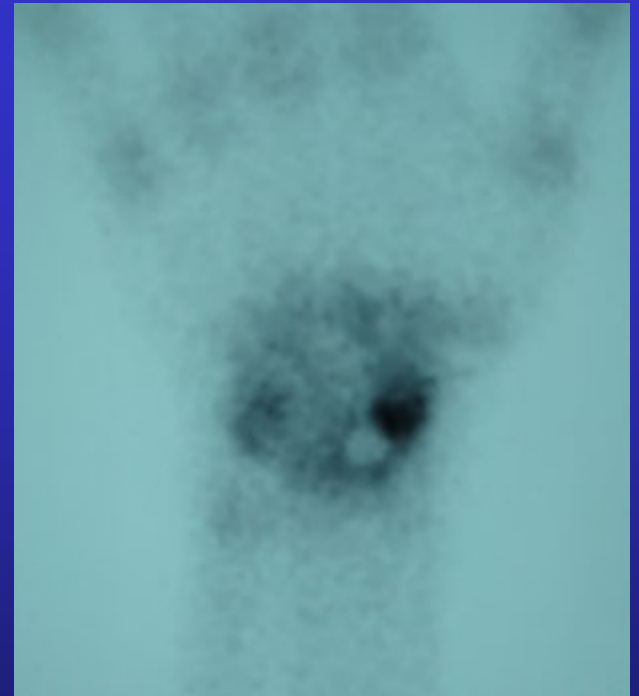
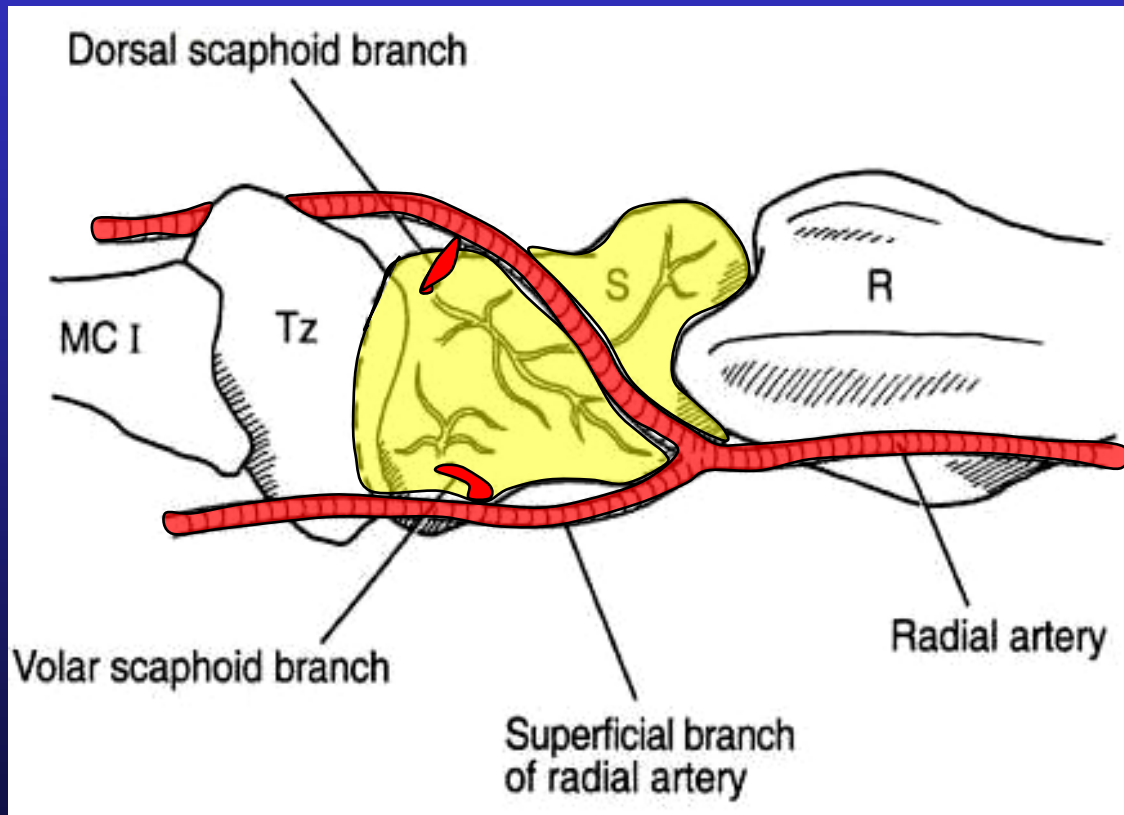


- Diagnosis still missed
 - “Wrist Sprain”
- Delayed Union
- Non - Union
- Avascular necrosis
- Diagnosing Union


“The Problem Bone”



Blood Supply

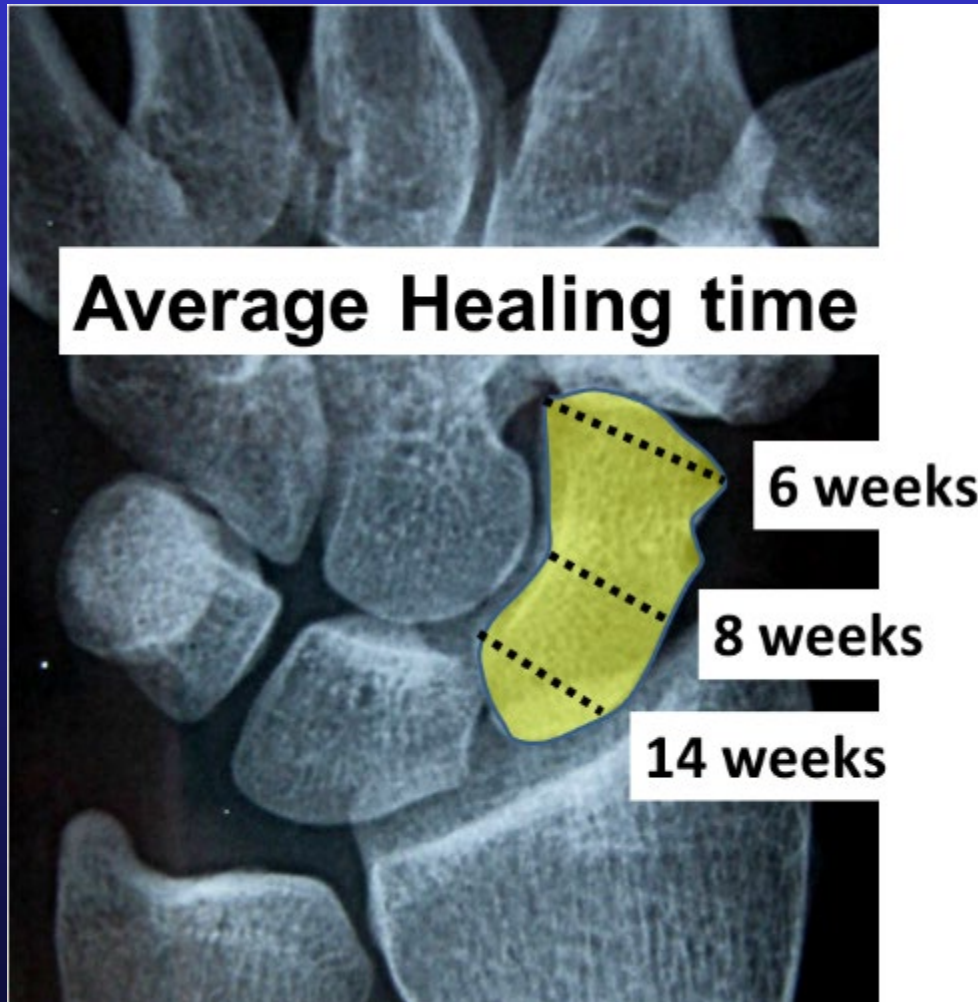

Blood Supply

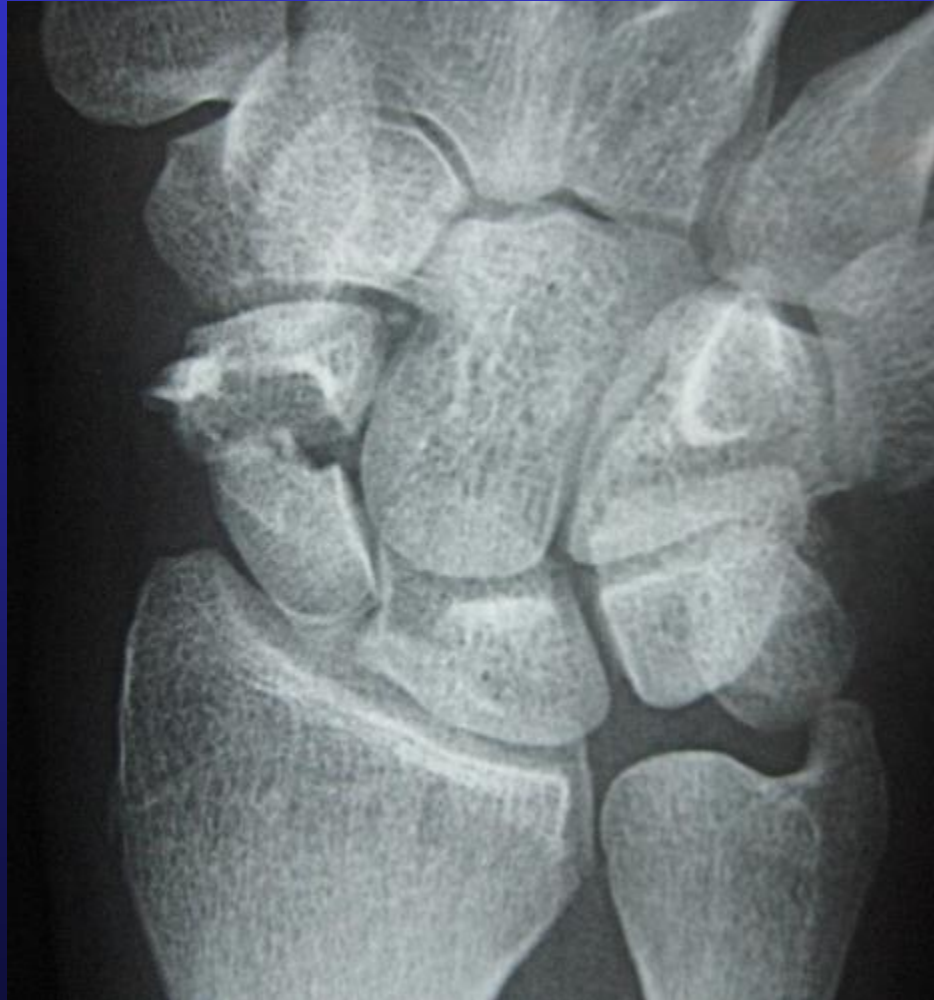

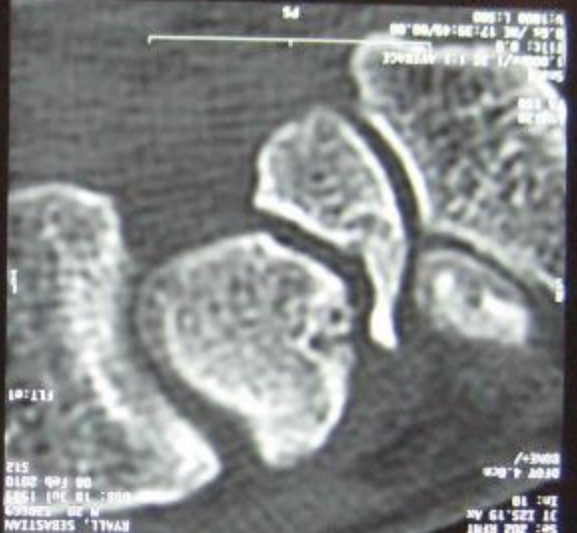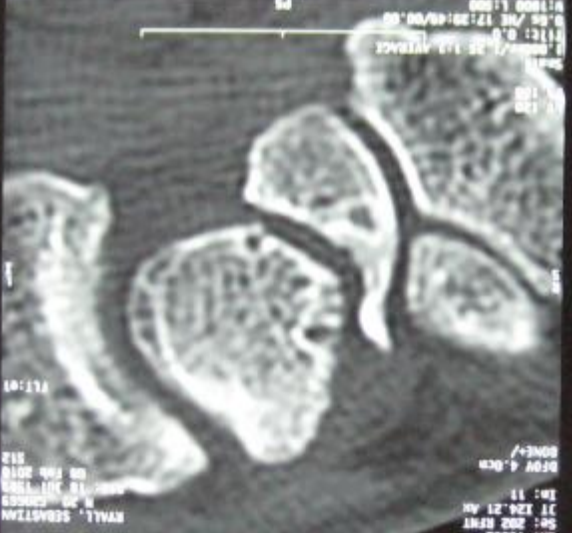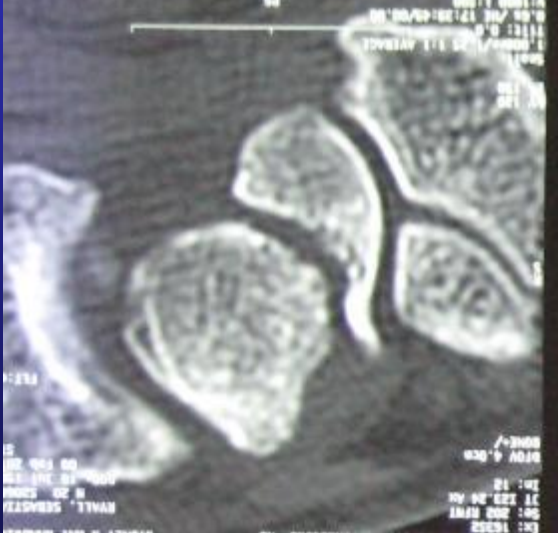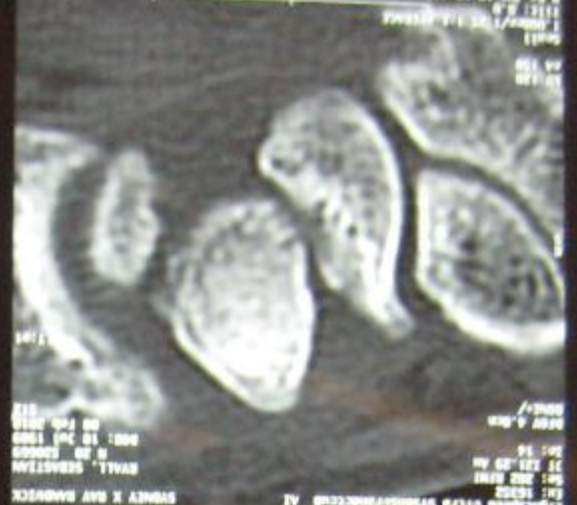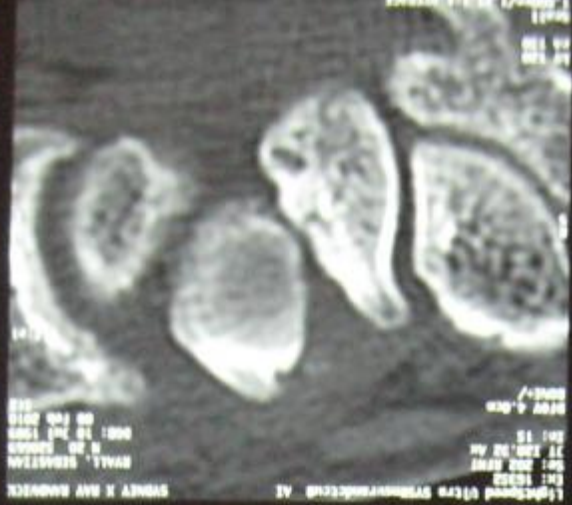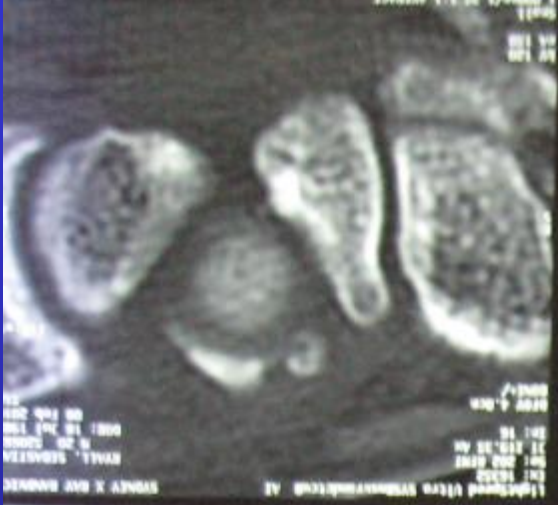Bone dies

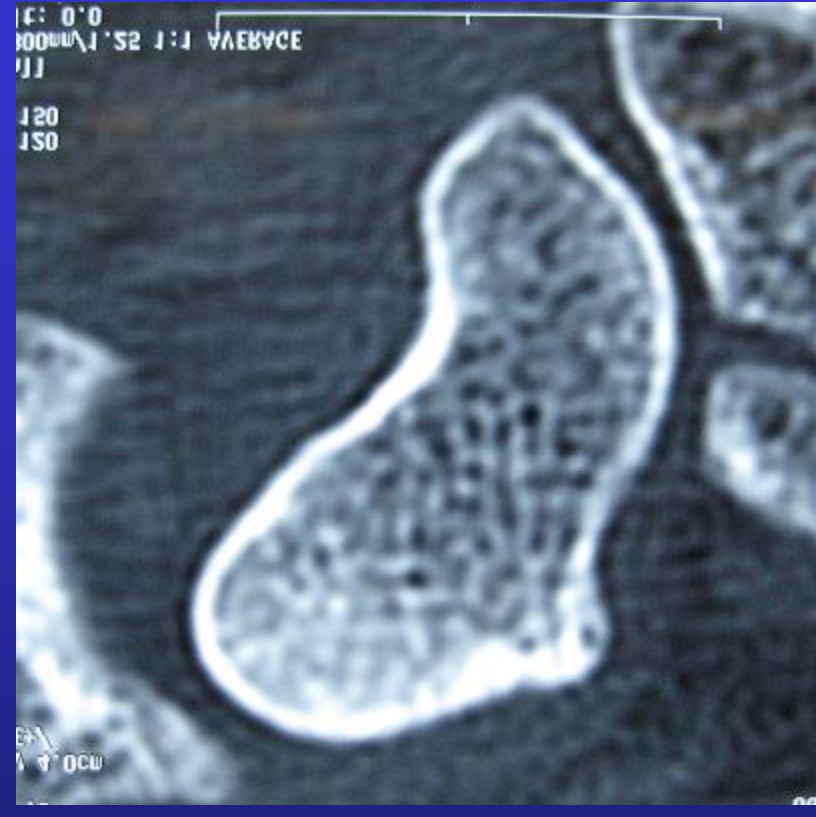
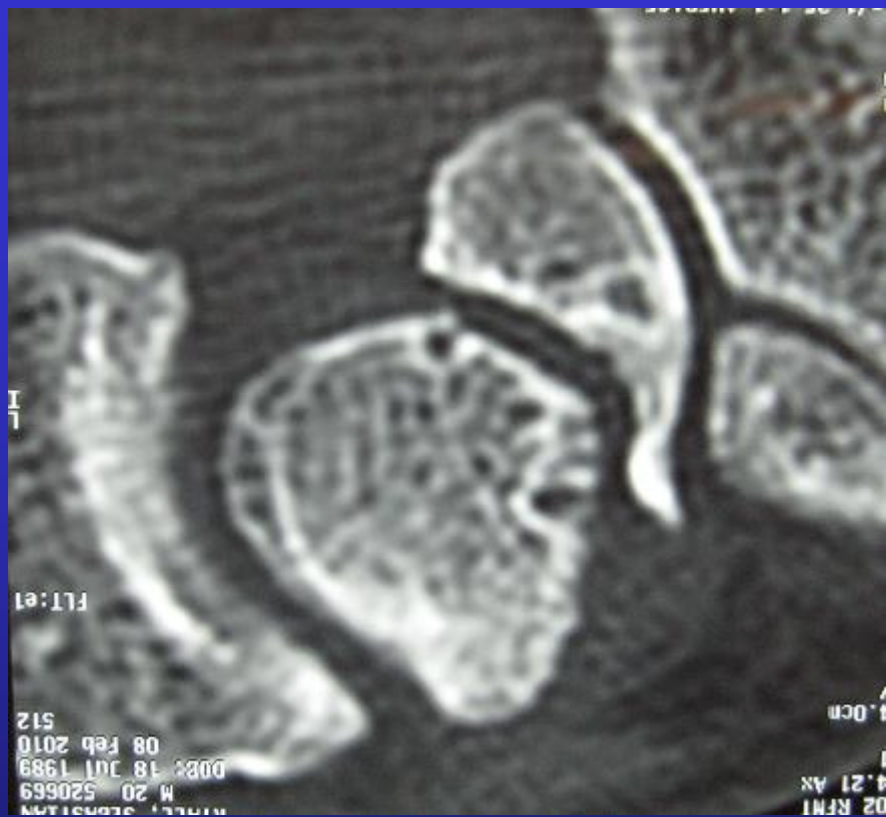Delayed Healing



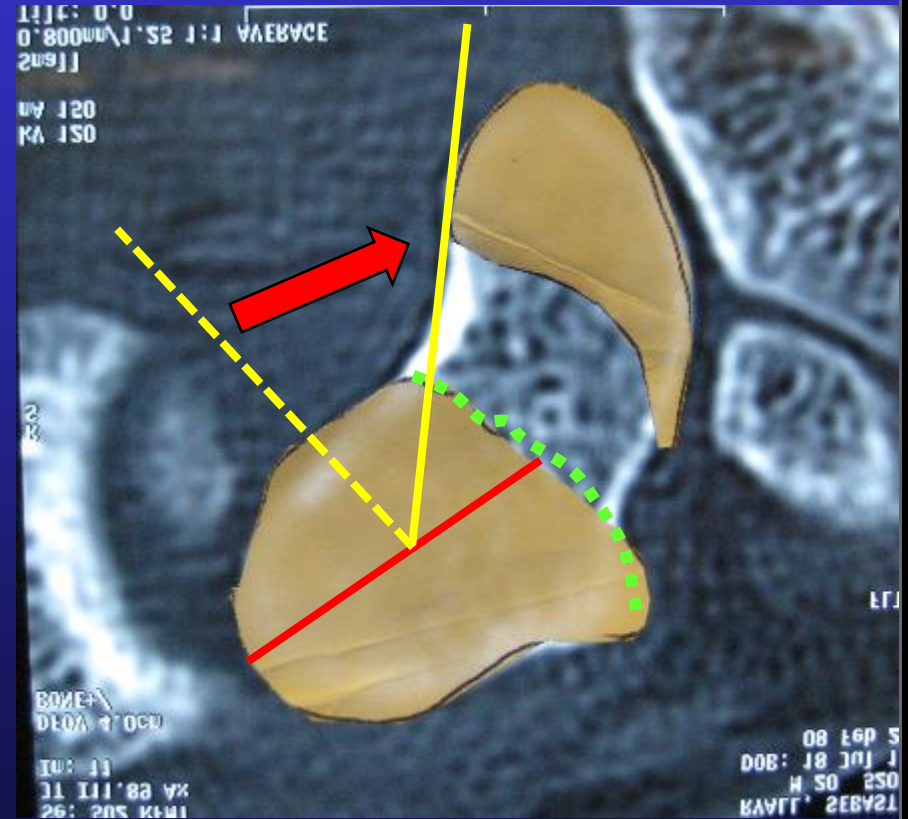
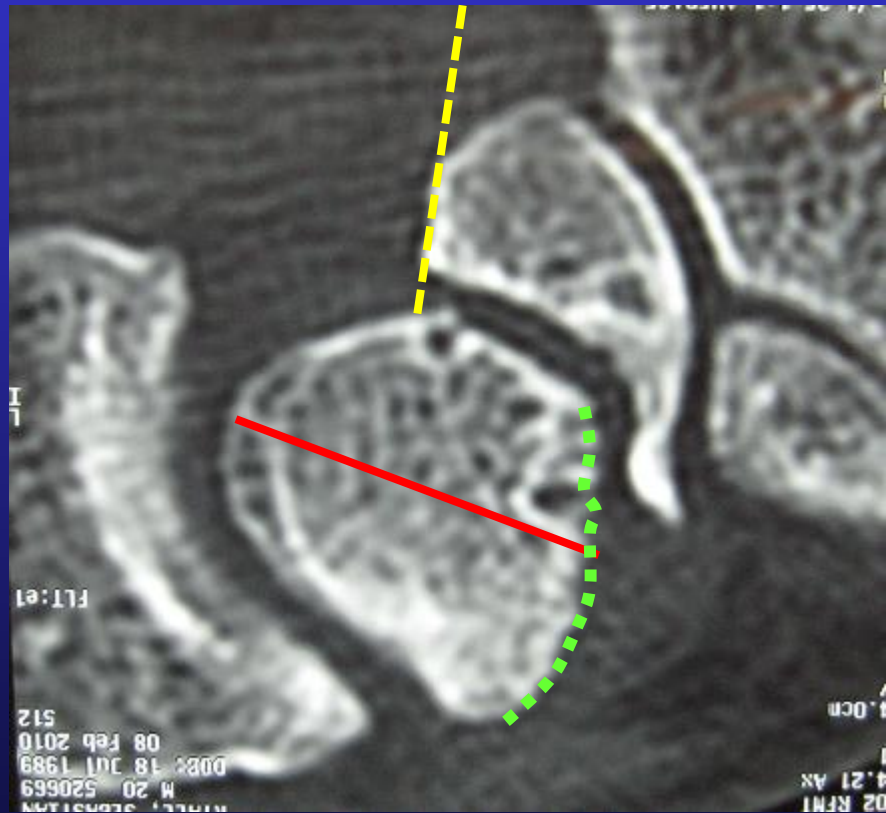
Non union

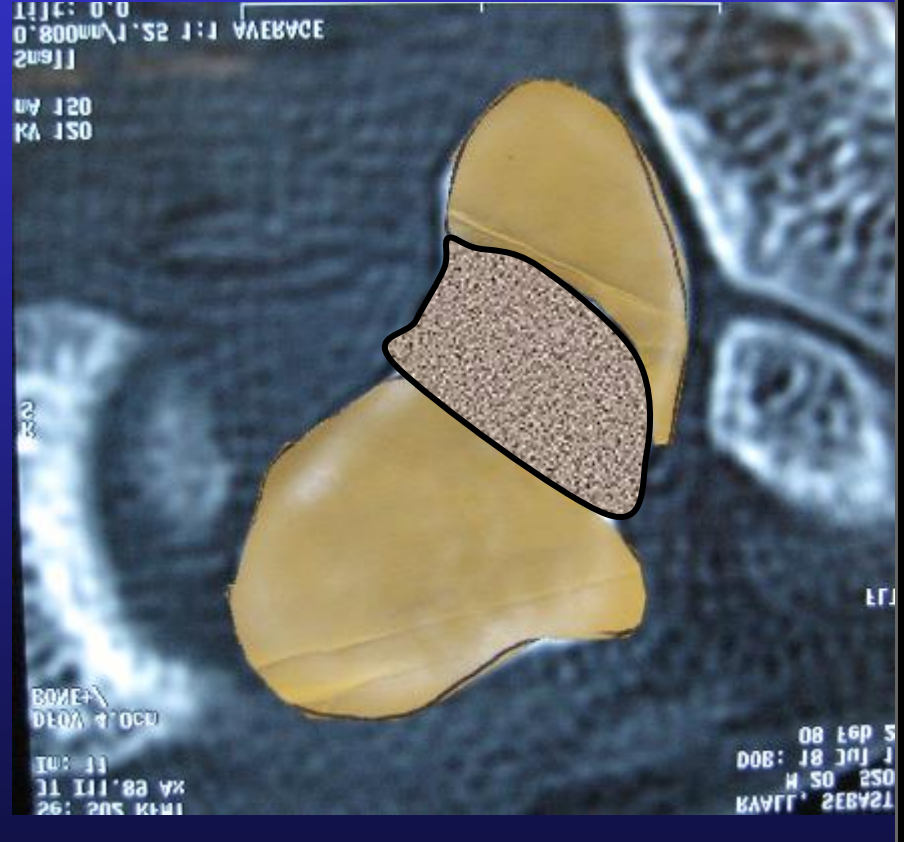
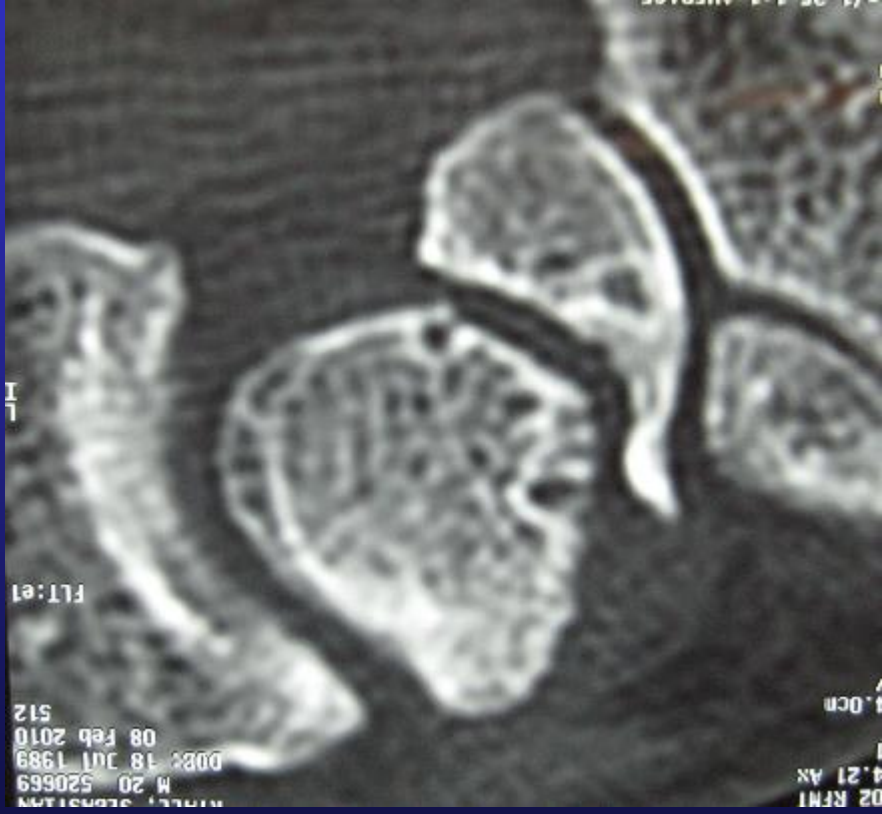




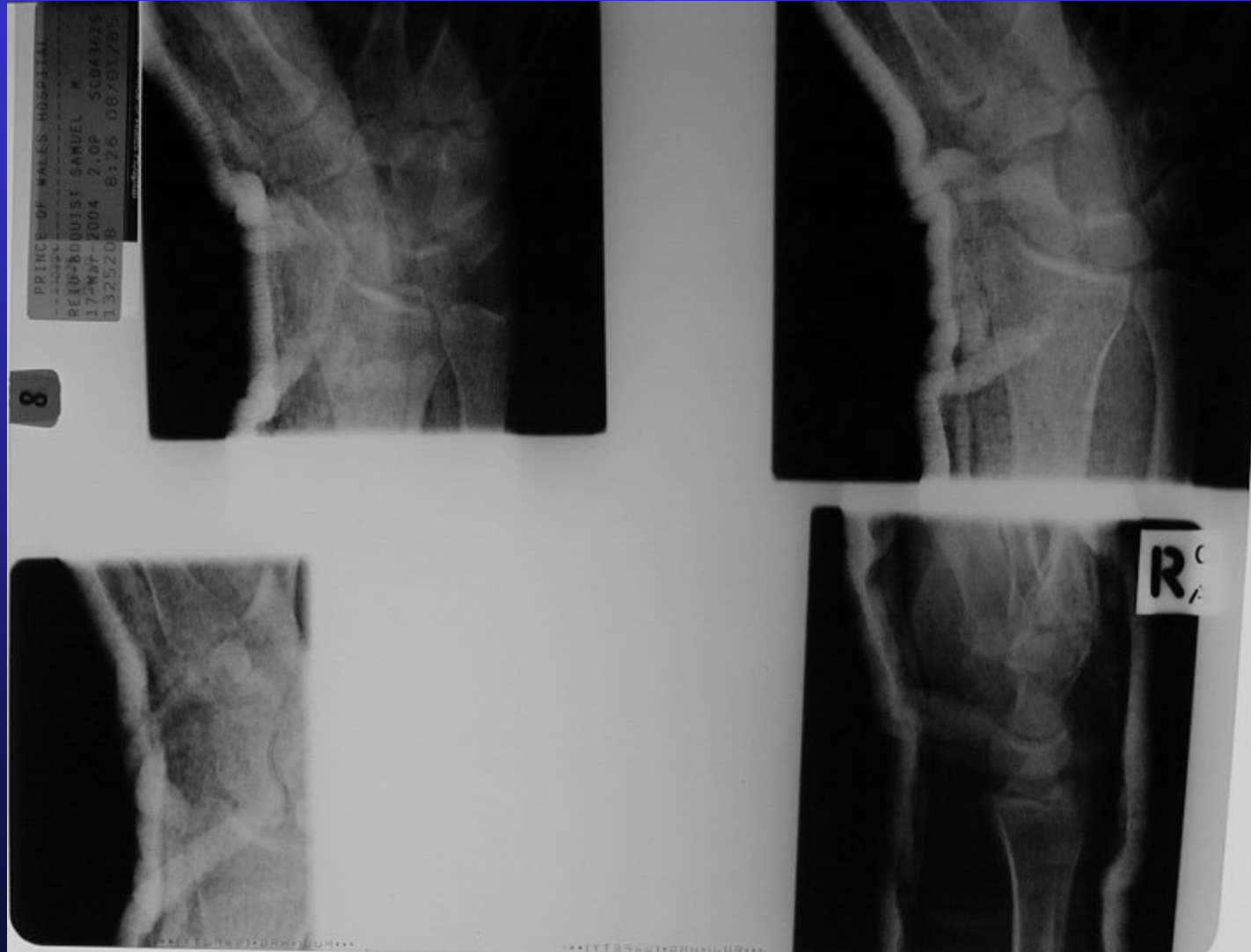


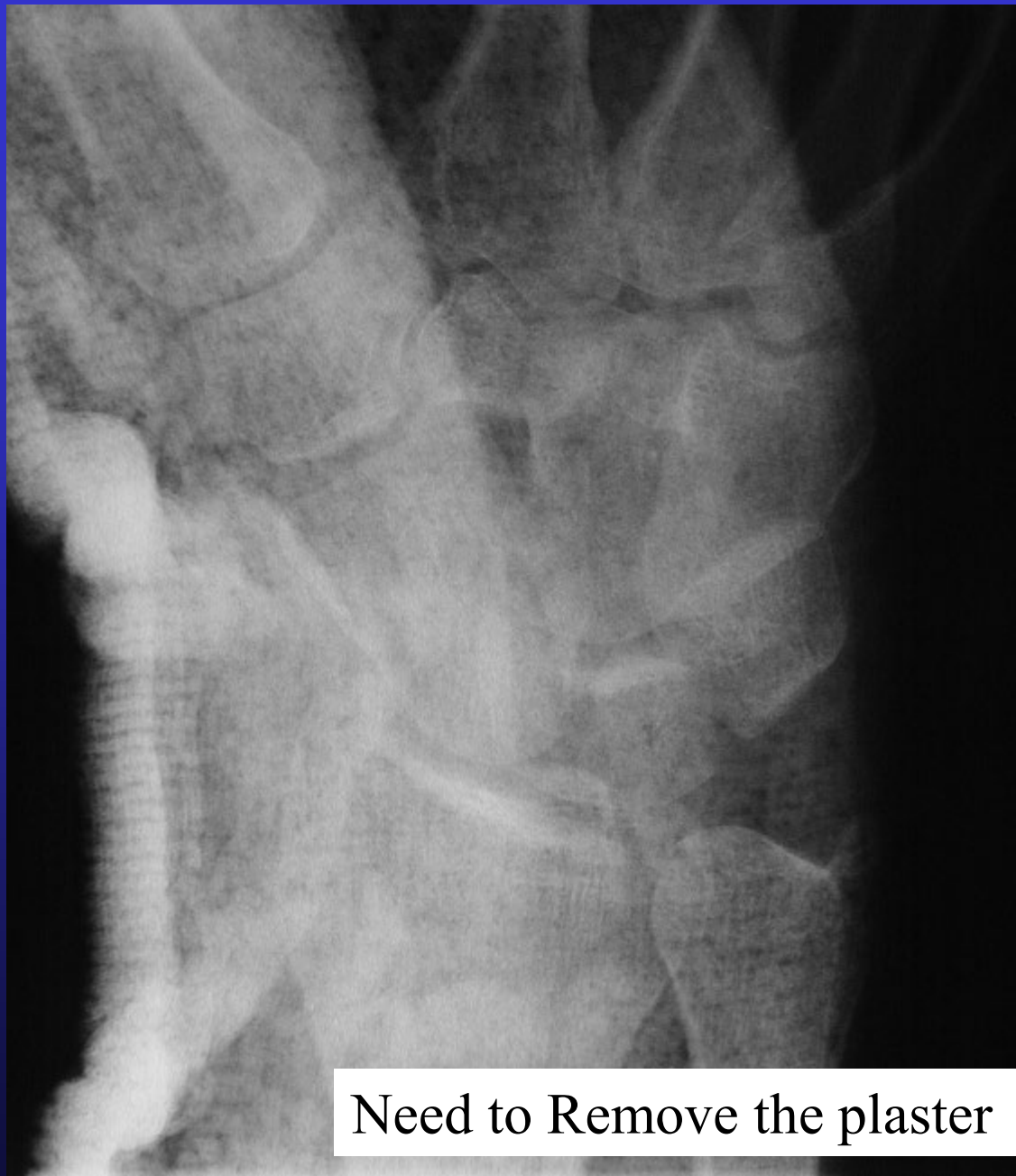
Planningg Bone Graft





Scaphoid #s





Need to Remove the plaster

Healed or
NOT!!!!

The Form!!!!

PLEASE BRING PREVIOUS FILMS OR CD FOR COMPARISON

Teenage Boofhead Boy

ADDRESS: _____

INDICATION OF FRESHNESS? YES NO UNSURE ADDRESS CORRECTION

X-RAY CT SONOGRAPHY DMS
 ULTRASOUND MRI 4-ULTRASOUND LG/LEP
 SCHEMATIC END INTERVENTIONAL

Right Scaphoid

**?? Scaphoid #
Fall pushbike**

SUBMITTED: _____

COPIES TO: _____

YOUR DOCTOR HAS RECOMMENDED THAT YOU USE I-MED RADIOLOGY.
YOU MAY CHOOSE ANOTHER PROVIDER BUT PLEASE DISCUSS THIS WITH YOUR DOC FOR FIRST.

Results E-MAIL PRINTING FAX CD EMAIL FOR MEDICAL REFERENCE REQUEST FOR NEW MATERIAL 500G

- 1 Day ? # (Cast Off)
- 10 Days ? # (Cast Off)
- 6 weeks ? Healed (cast Off - then reapply with tape until union confirmed)
- 3 months ? Healed

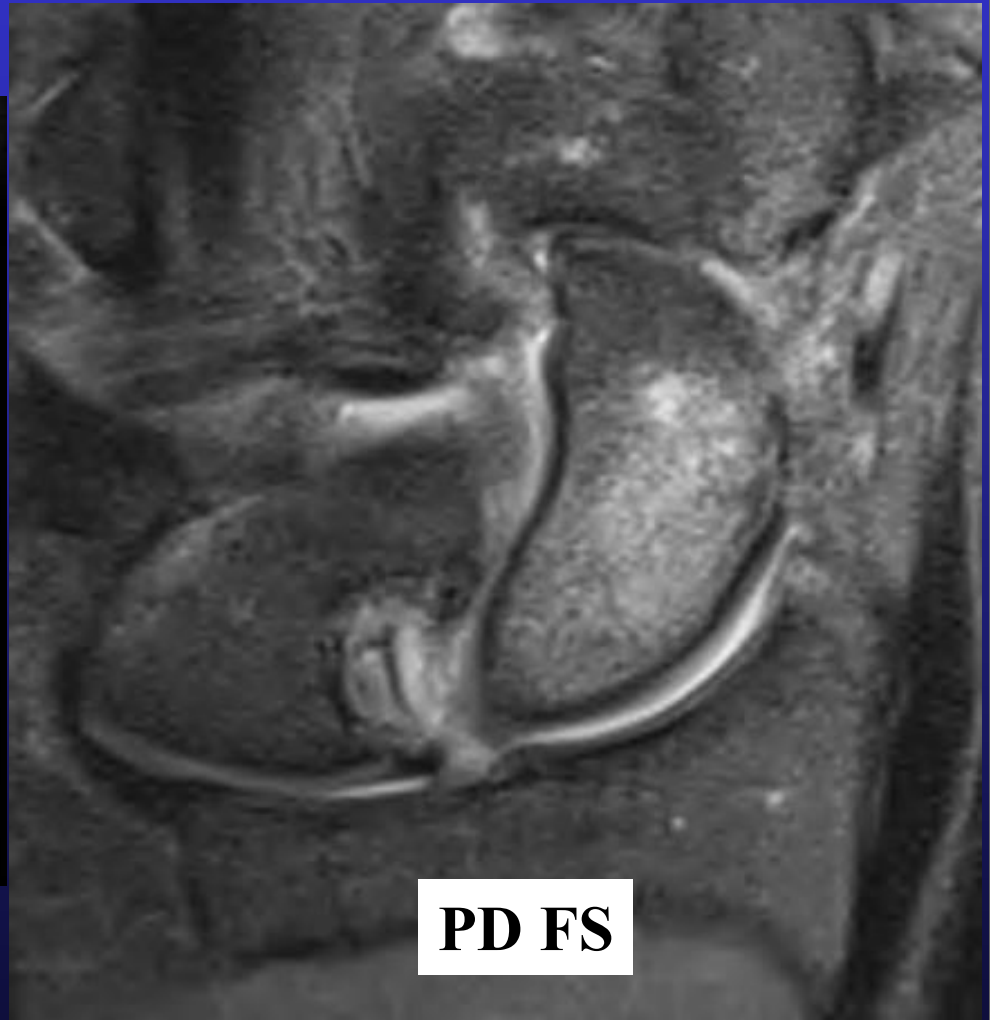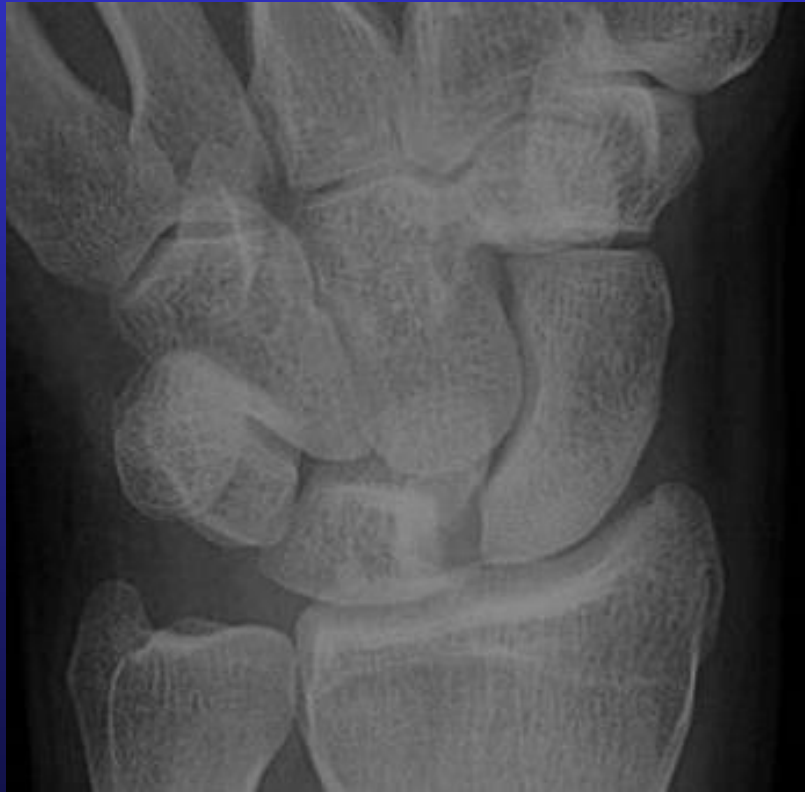Scaphoid Fractures

- If negative x-ray Day 1 and
- Clinical suspicion of fracture
- OR Form Says ? Scaphoid #
-  MRI & Splint
- Not f/up xray at 10/7

Scaphoid Fractures

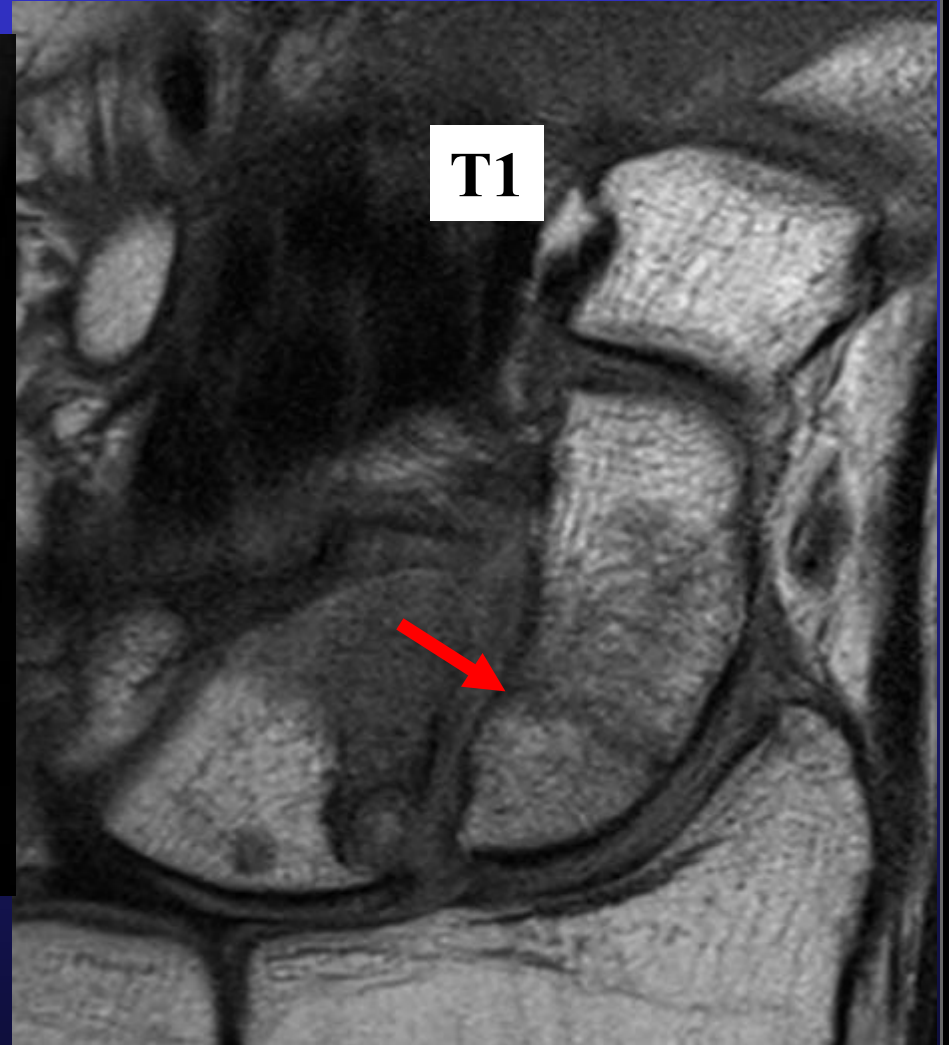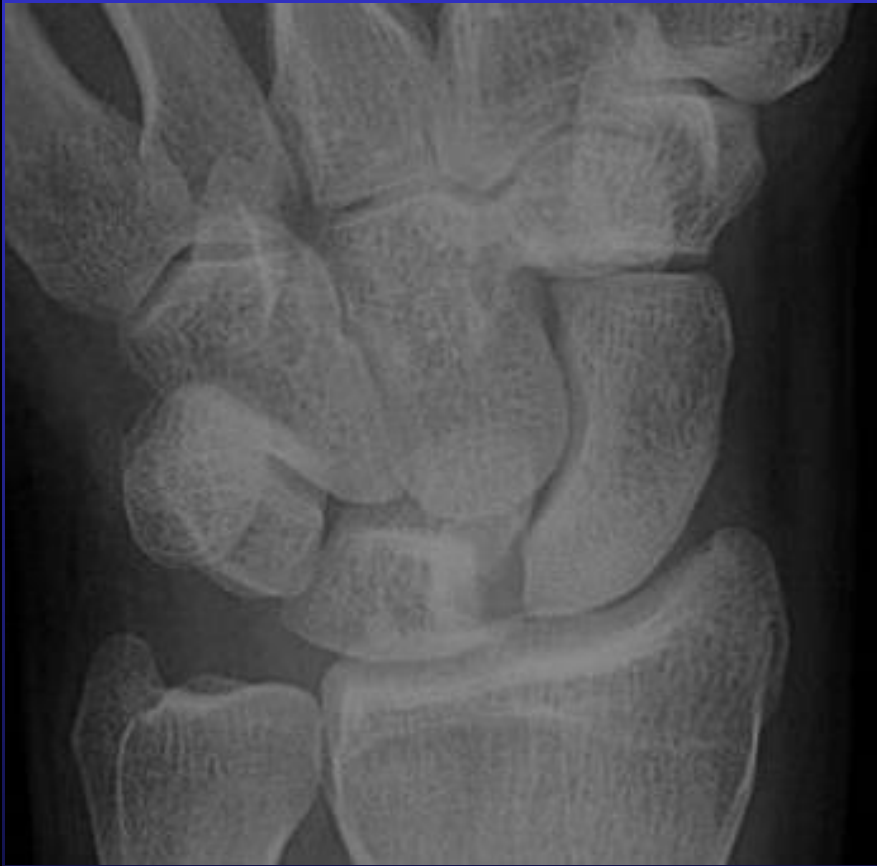- MRI Scan
 - T1 best for Fx line
 - T2 or PD easiest to see bone oedema
- EVERYONE (GP, Radiographer, Radiologist) should reinforce need for **Immediate splintage** until diagnosis confirmed
- **A Normal XR & Normal CT DOES NOT EXCLUDE A SCAPHOID # at Day 1**

Scaphoid Fractures



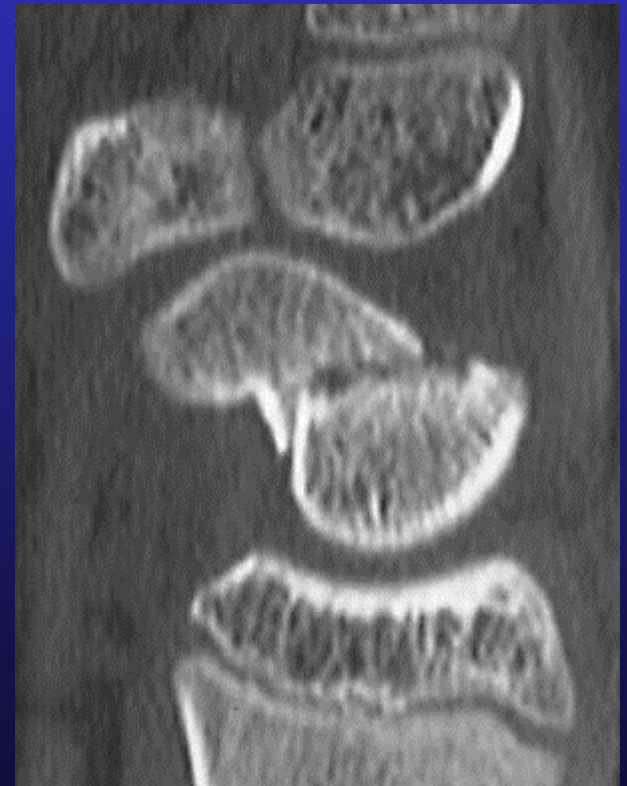PD FS

Scaphoid Fractures

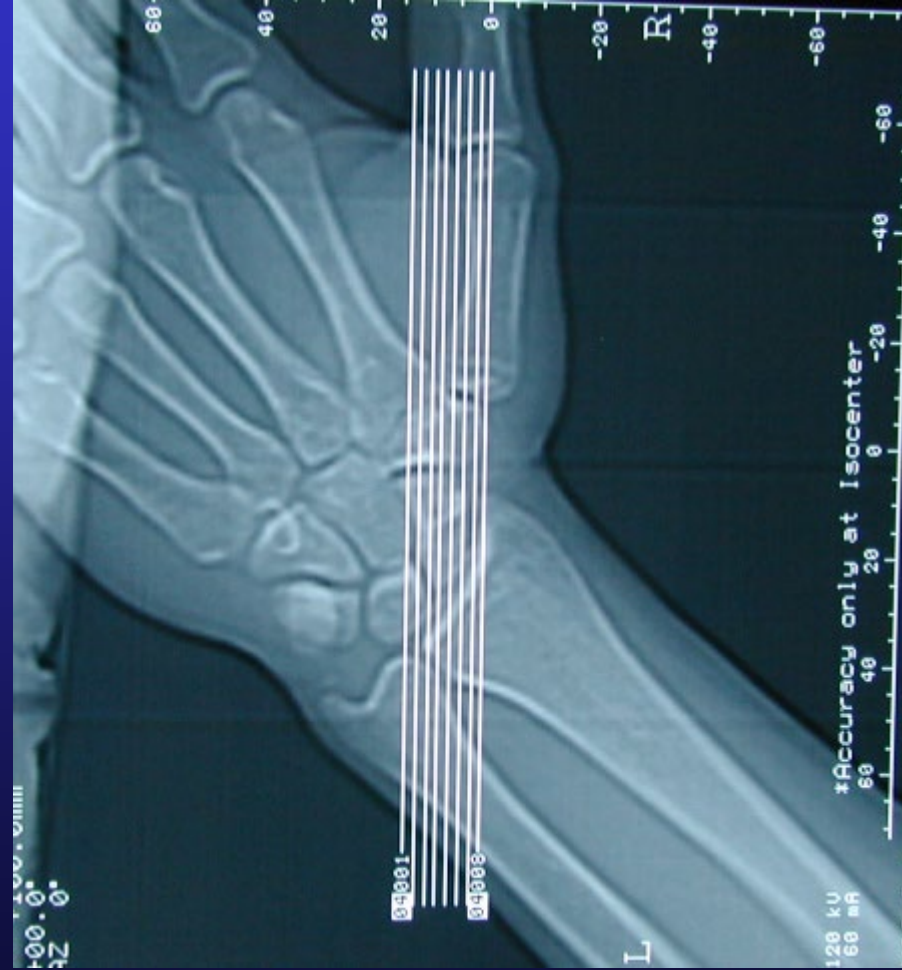

Scaphoid CT

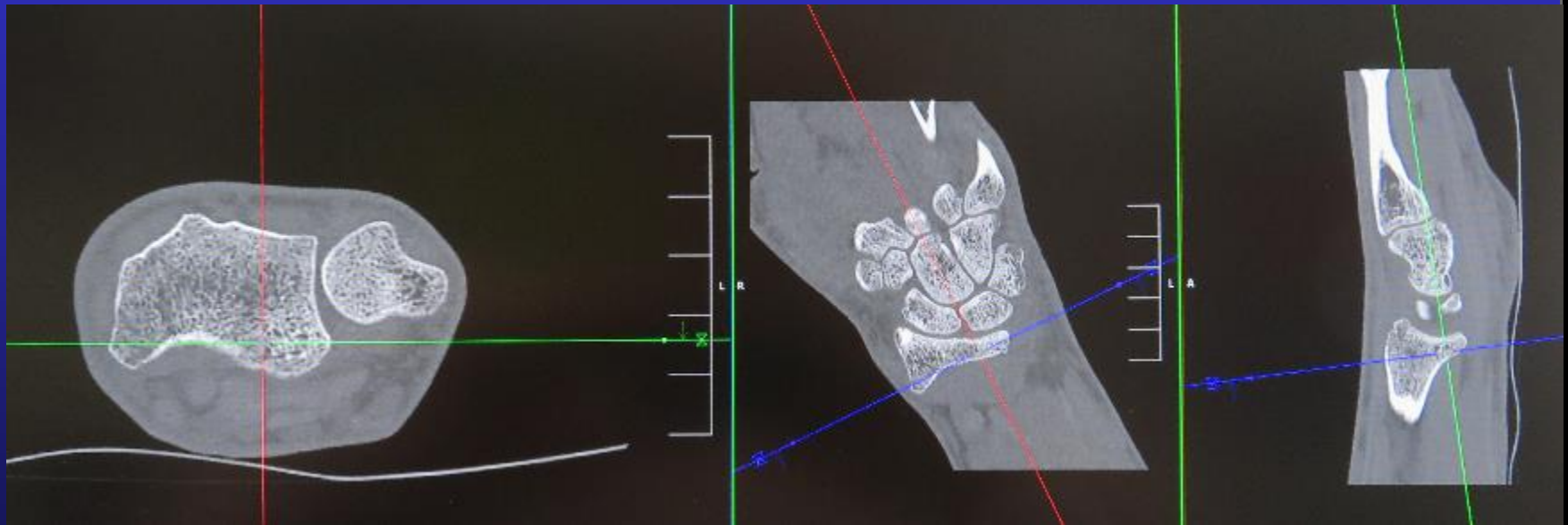
- **DOES NOT EXCLUDE AN ACUTE FRACTURE**
- Good for:
 1. Assessing known fractures
 - displacement
 - deformity
 2. Assessing fracture Union



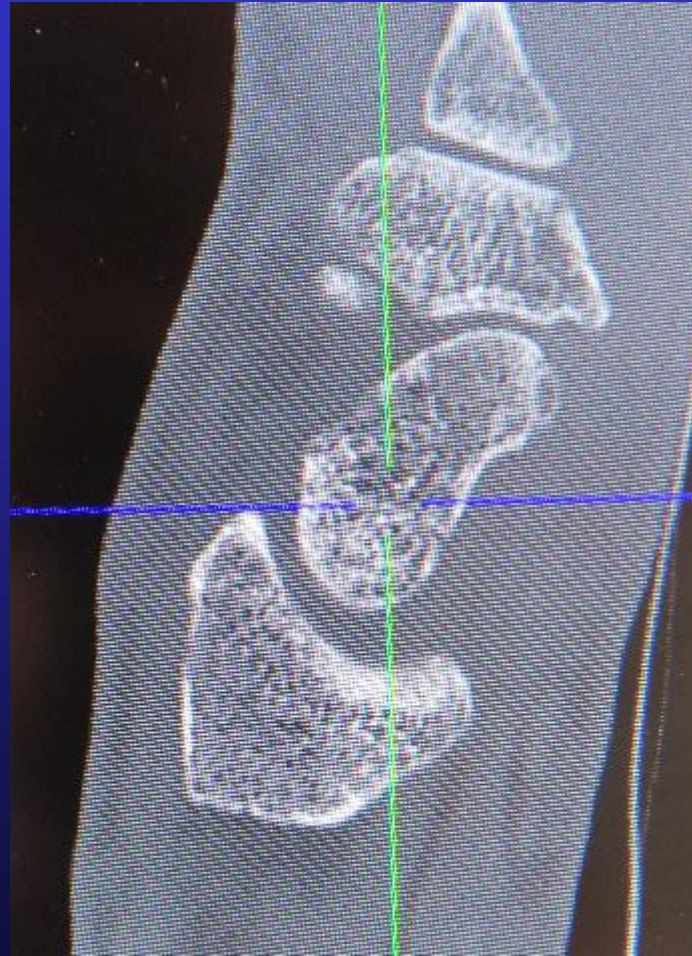
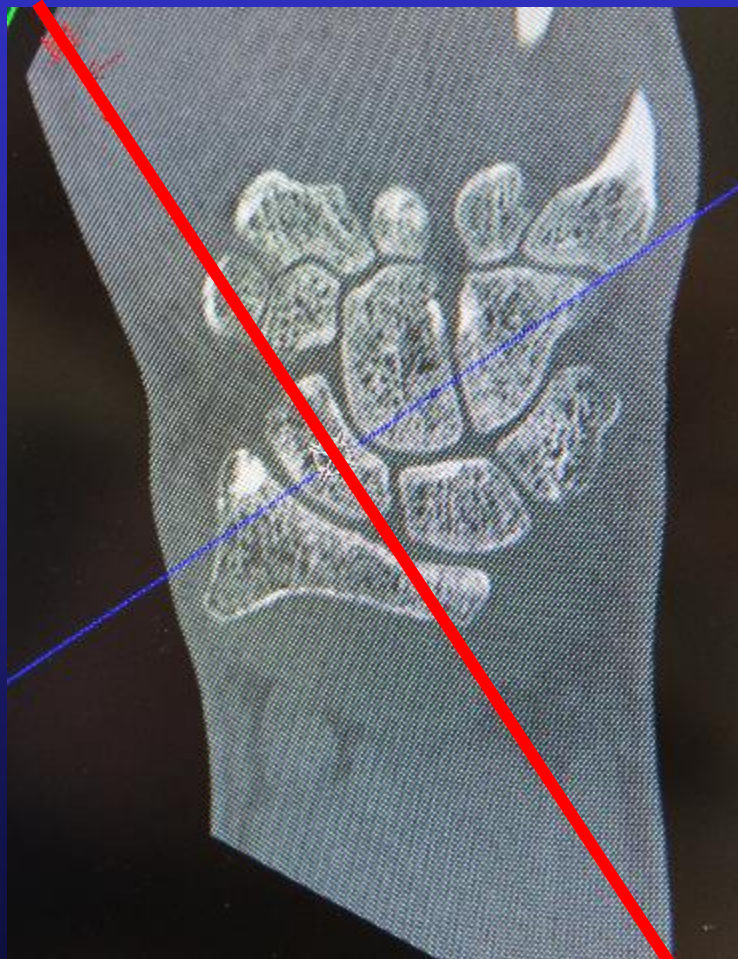Sanders Views



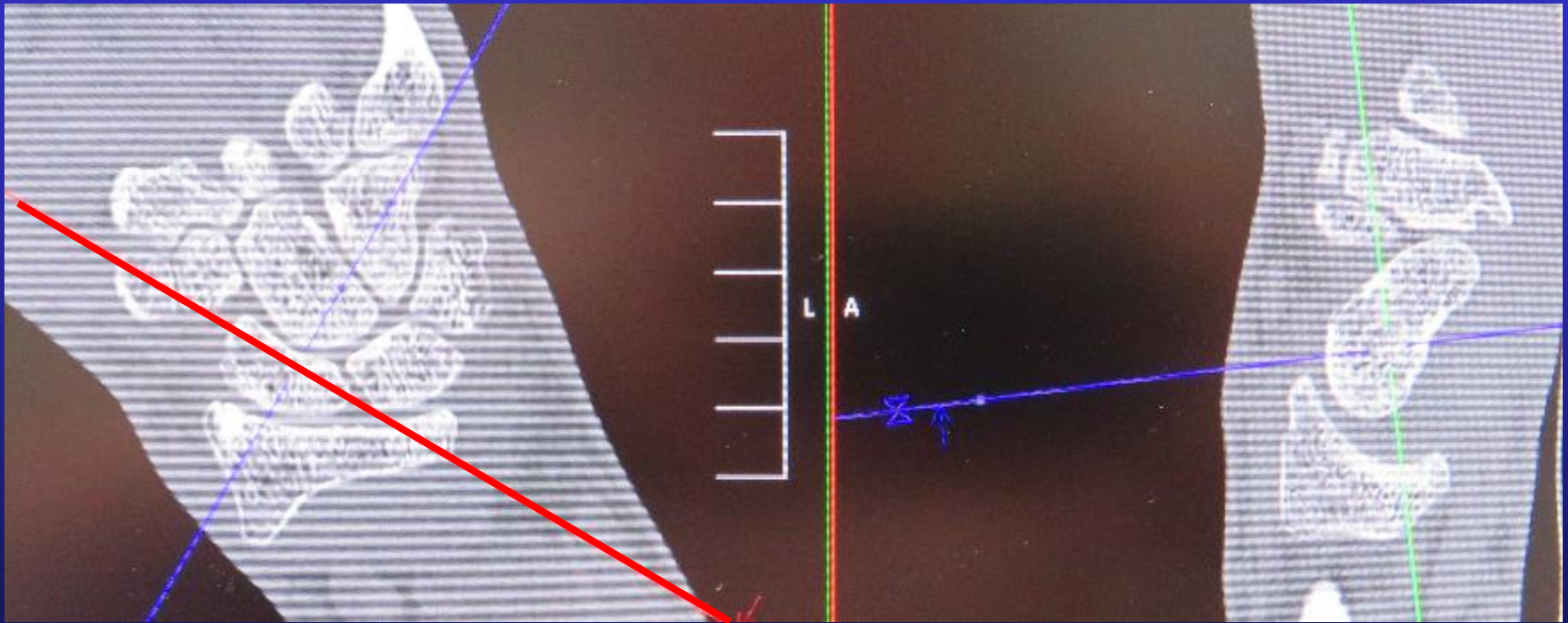
Scaphoid CT



Scaphoid CT

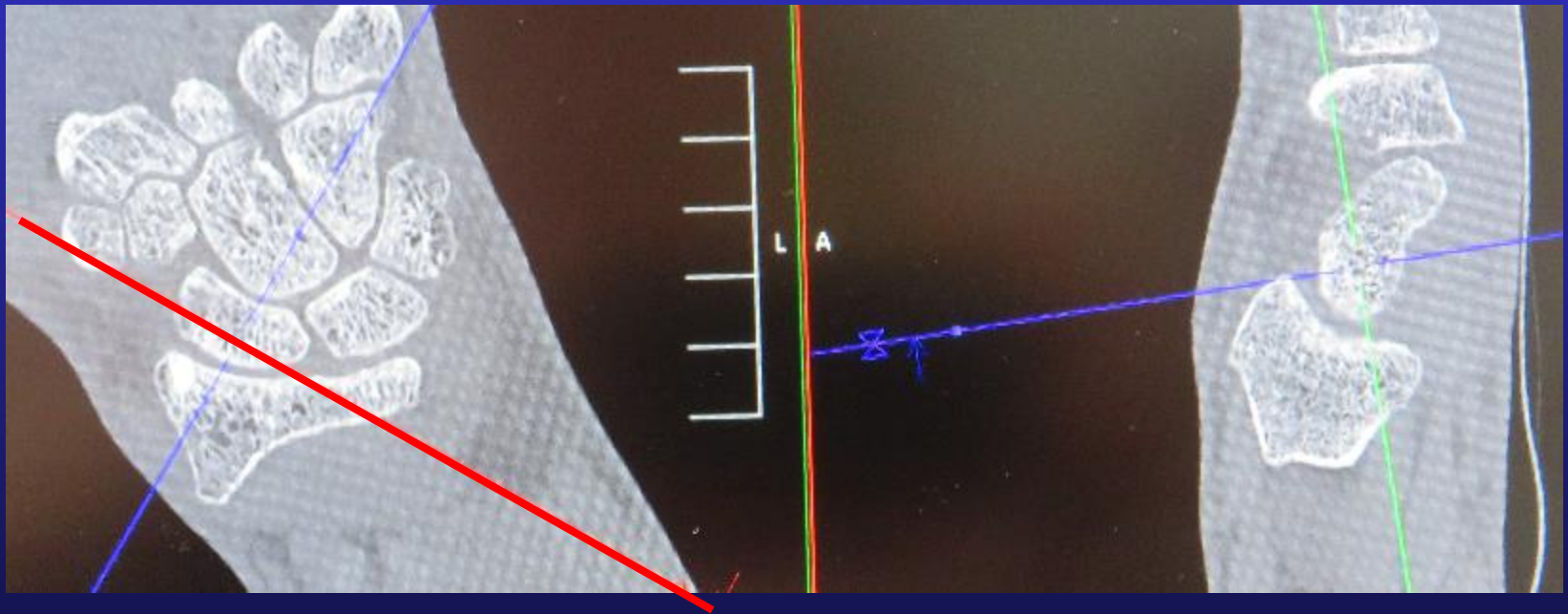

Scaphoid CT



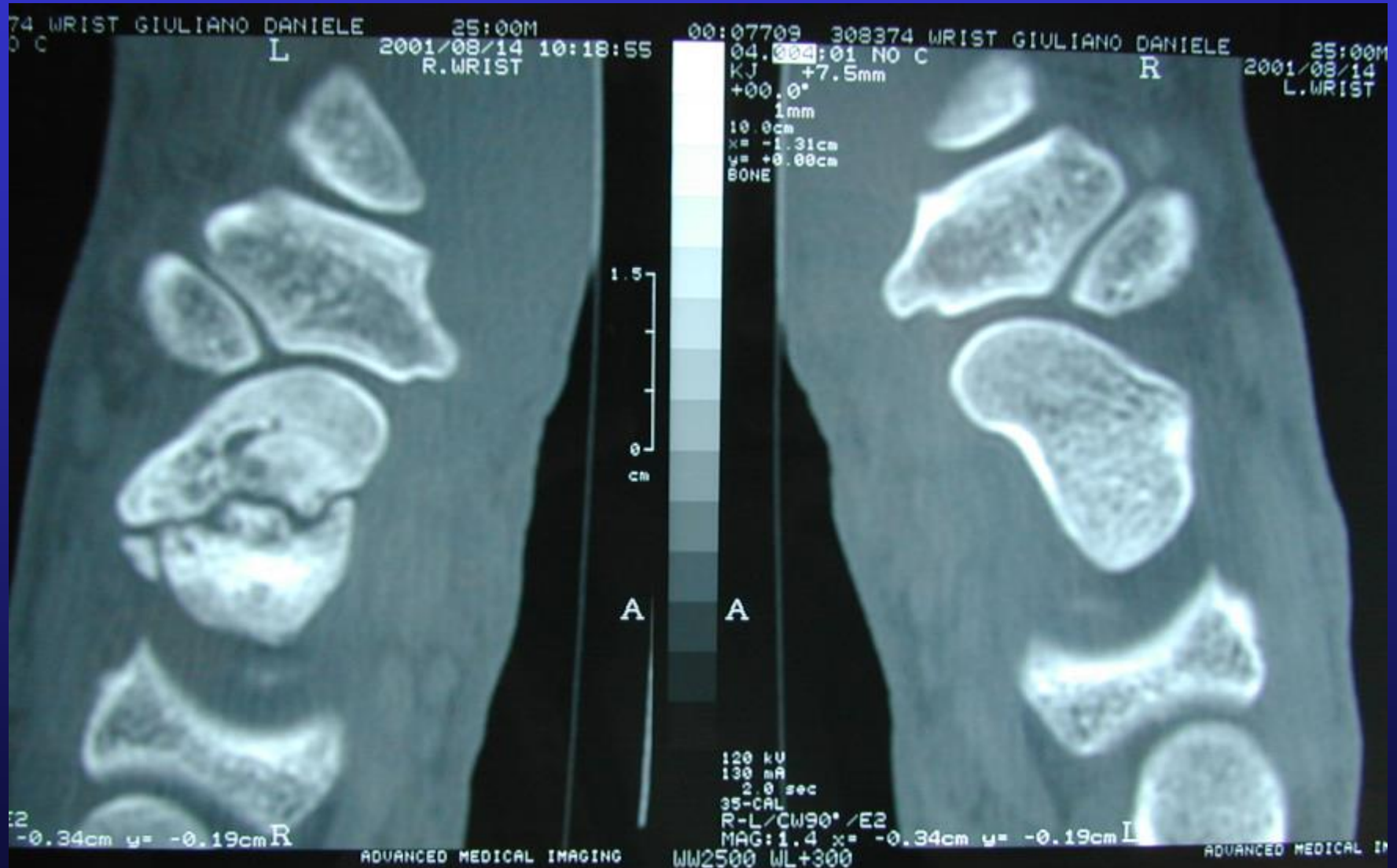
Scaphoid CT

Count the number of images showing fracture union

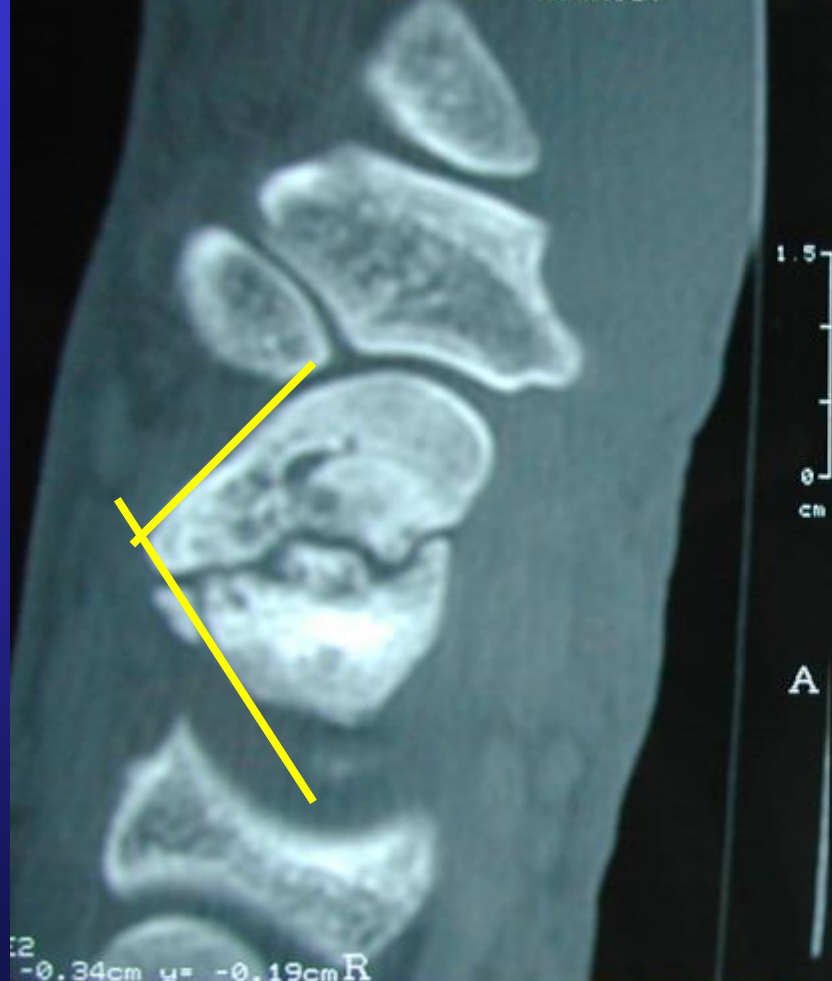


$>50\%$ = United

Planning Bone Graft



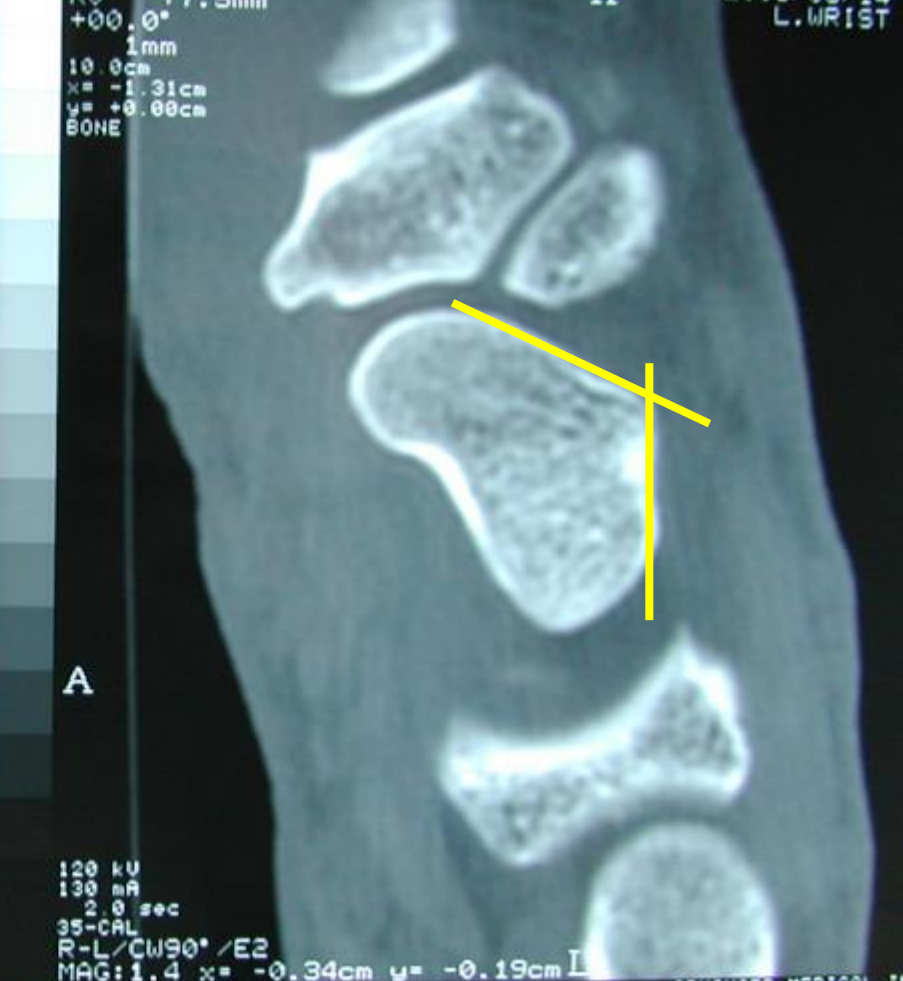74 WRIST GIULIANO DANIELE 25:00M
0 C L 2001/08/14 10:18:55
R.WRIST



12
-0.34cm y= -0.19cm R

ADVANCED MEDICAL IMAGING

00:07709 308374 WRIST GIULIANO DANIELE 25:00M
04.004:01 NO C R 2001/08/14
KJ +7.5mm L.WRIST



120 kV
130 mA
2.0 sec
35-CAL
R-L/CW90°/E2
MAG:1.4 x= -0.34cm y= -0.19cm L

WW2500 WL+300

ADVANCED MEDICAL I

A nighttime photograph of a city skyline, likely Sydney, Australia, featuring several prominent skyscrapers illuminated with warm yellow and white lights. The buildings are reflected in the water in the foreground. A bright yellow rectangular box is overlaid on the lower-left portion of the image, containing the website address. The text 'The End' is written in a large, white, serif font with a black outline in the bottom right corner.

www.myhand.com.au

The End