

# Finger Xrays

**Dr Stuart Myers**

Orthopaedic Hand Surgeon,  
Prince of Wales Hospital, Sydney  
Sydney Orthopaedic Specialists

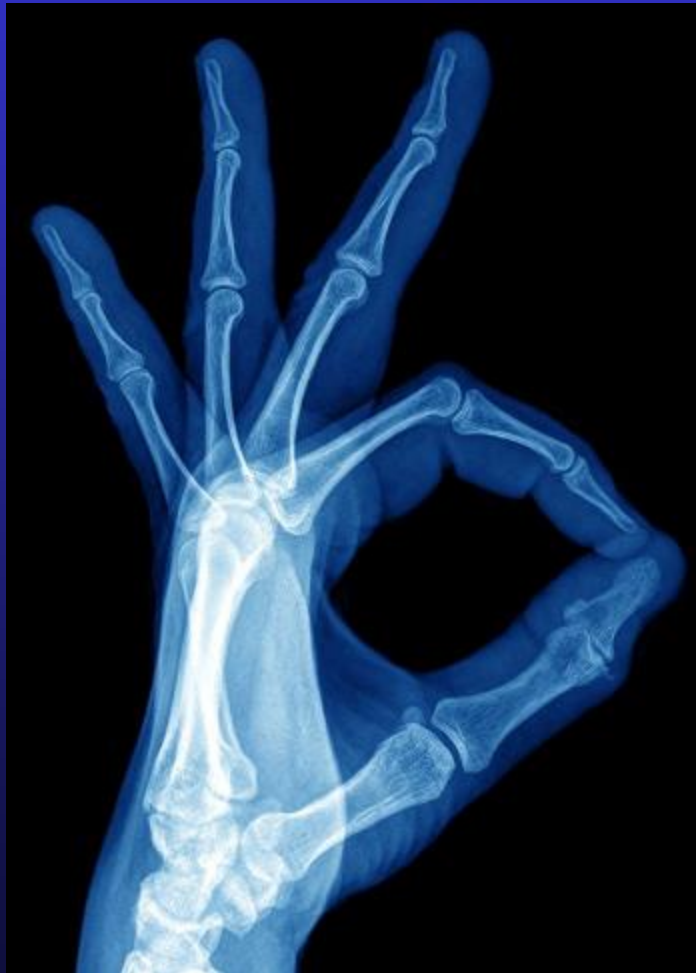[www.myhand.com.au](http://www.myhand.com.au)



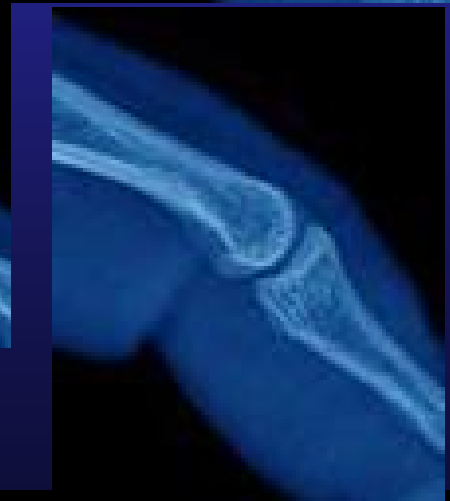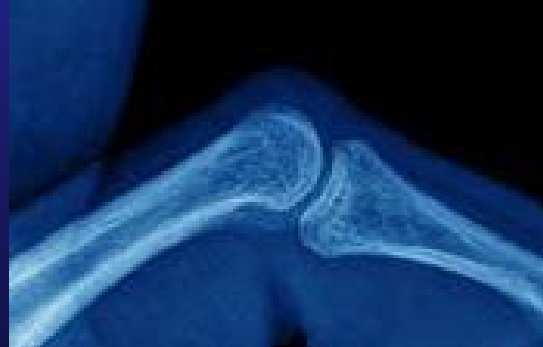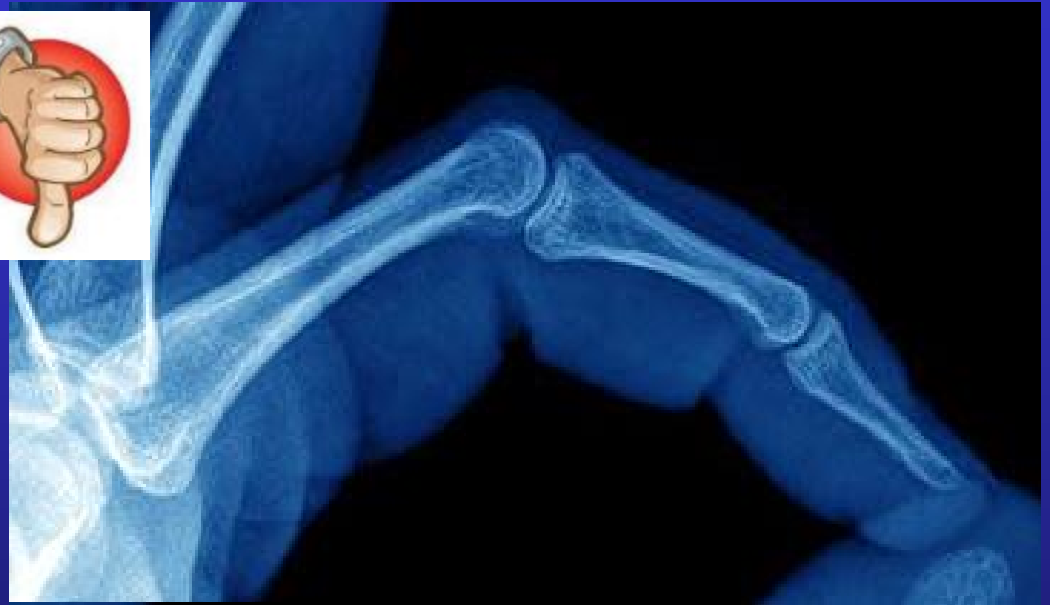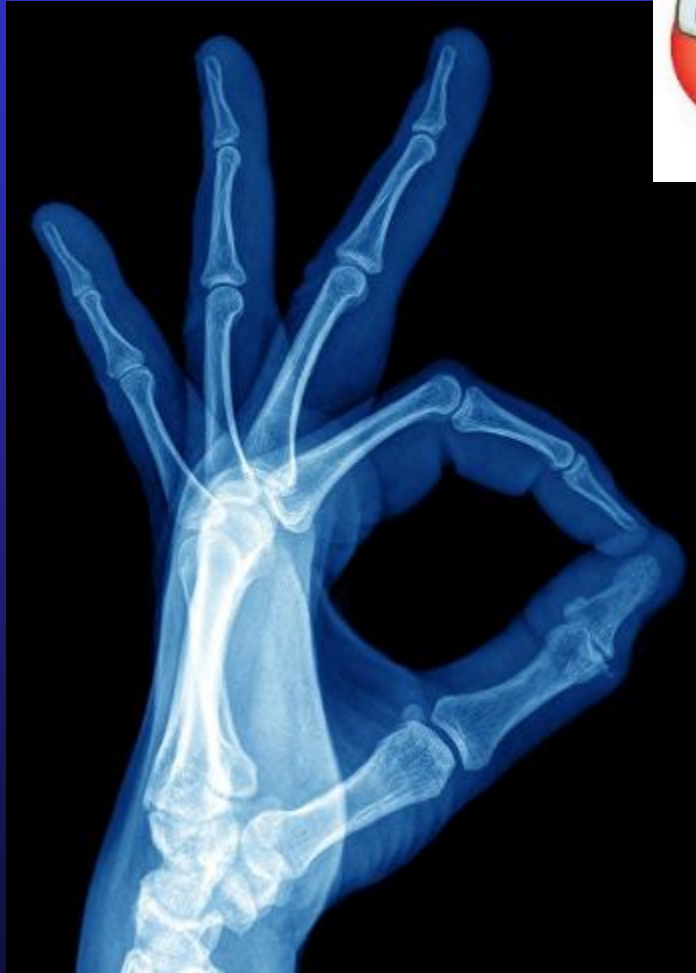# Reason for Xray?????

- Alignment
  - Bones
  - Joints
- Fractures
  - Diagnosis
  - Union
- Position of internal fixation

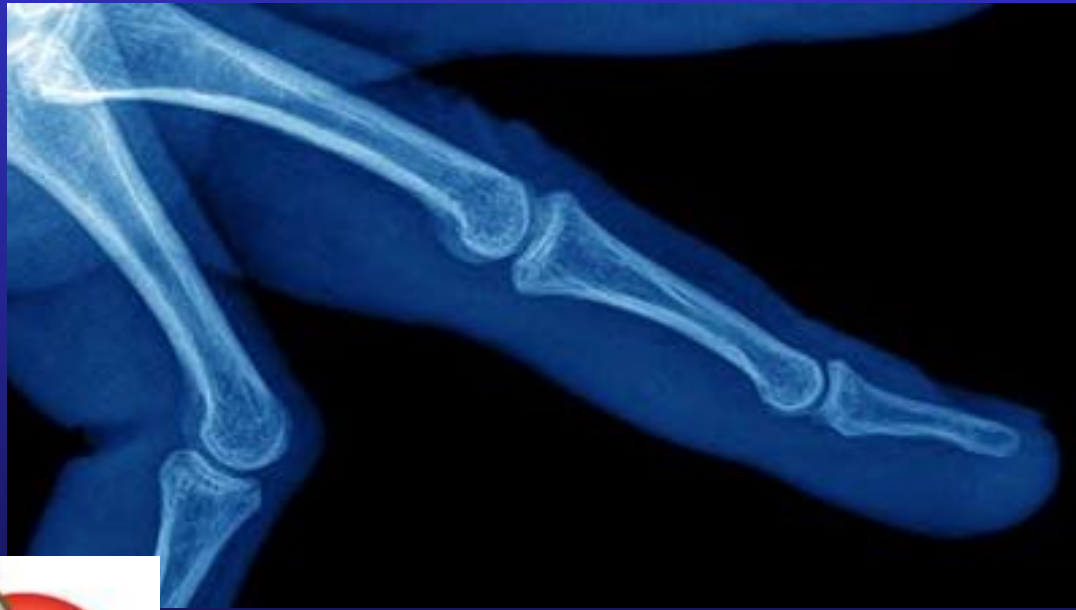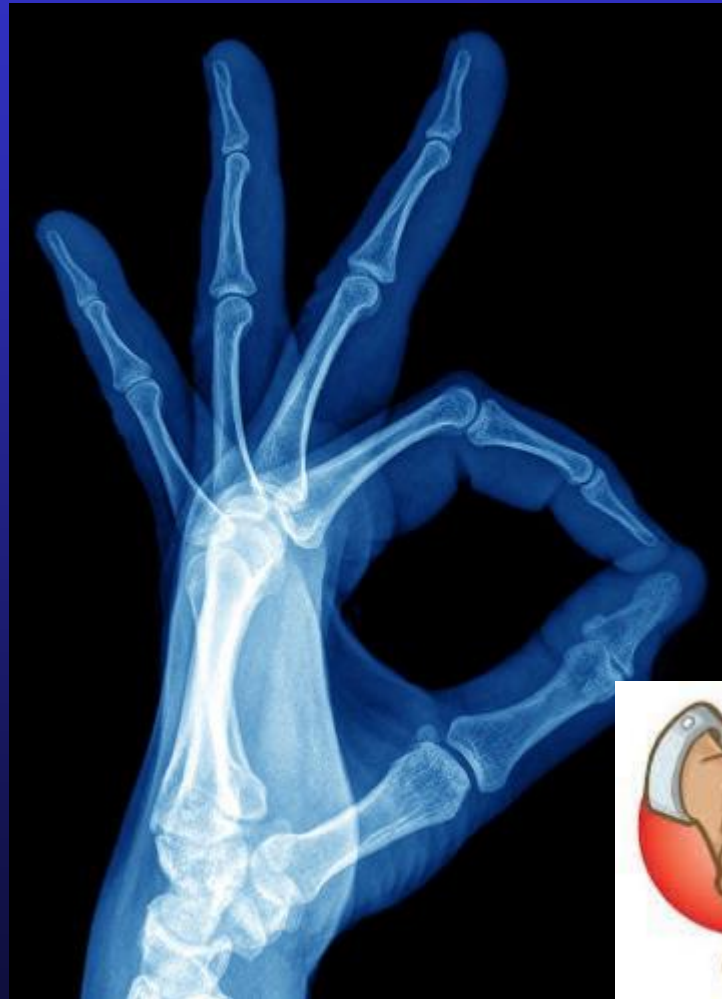# Good Xray!!



# Good Xray Index finger??

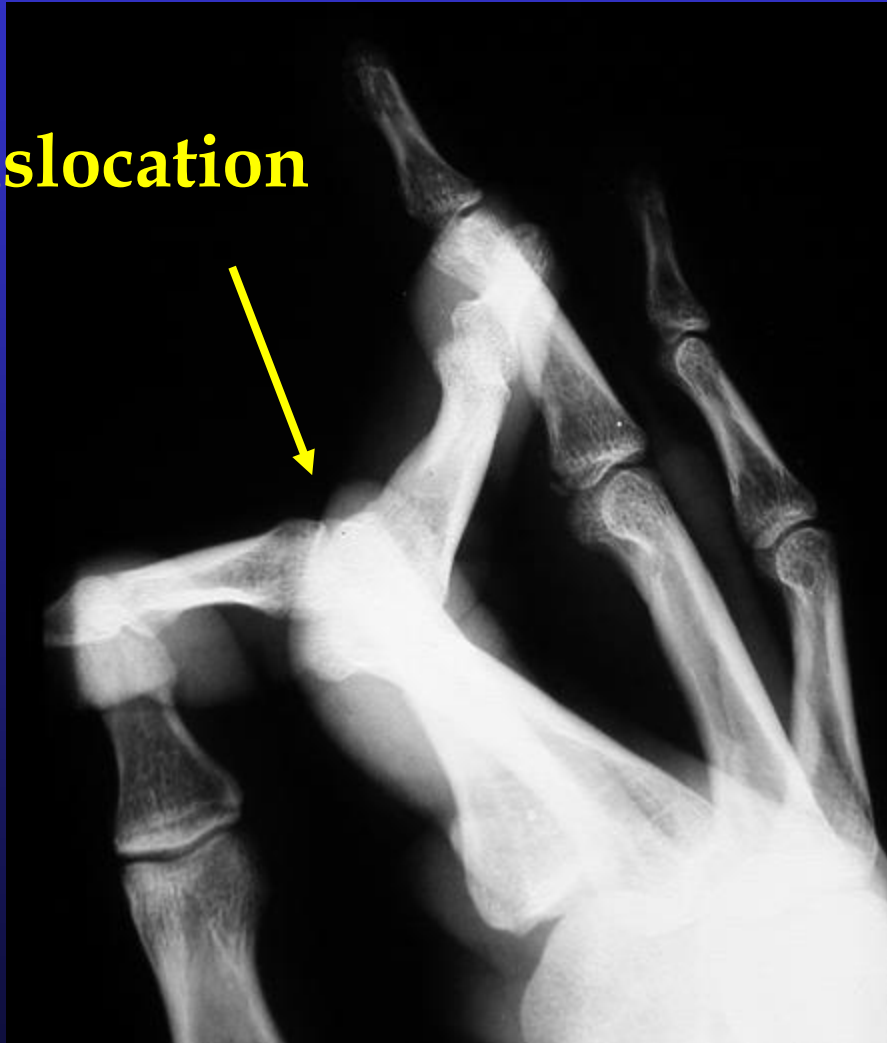


# Good Xray Middle finger??

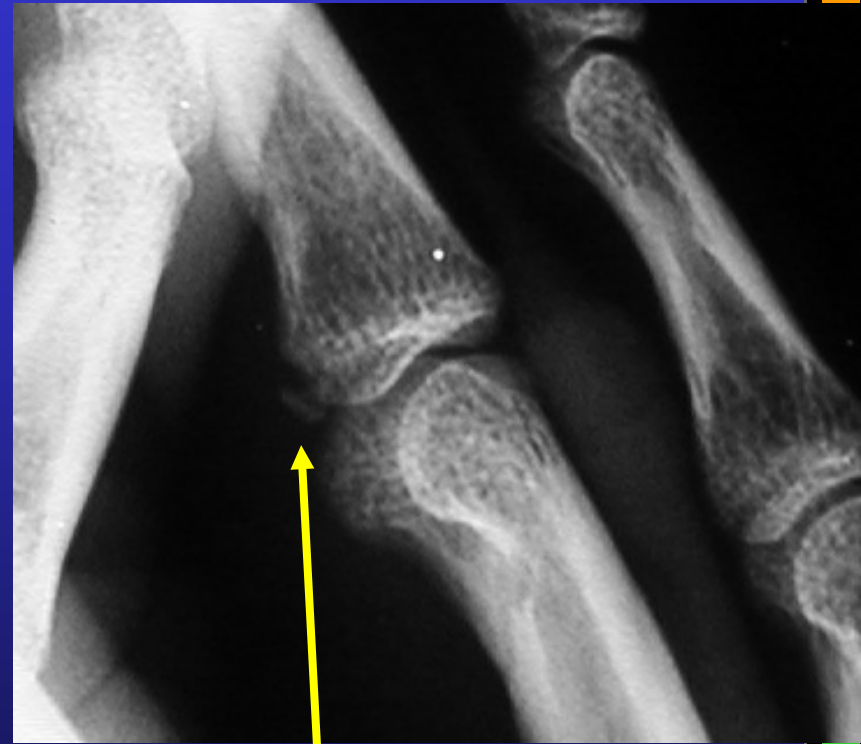
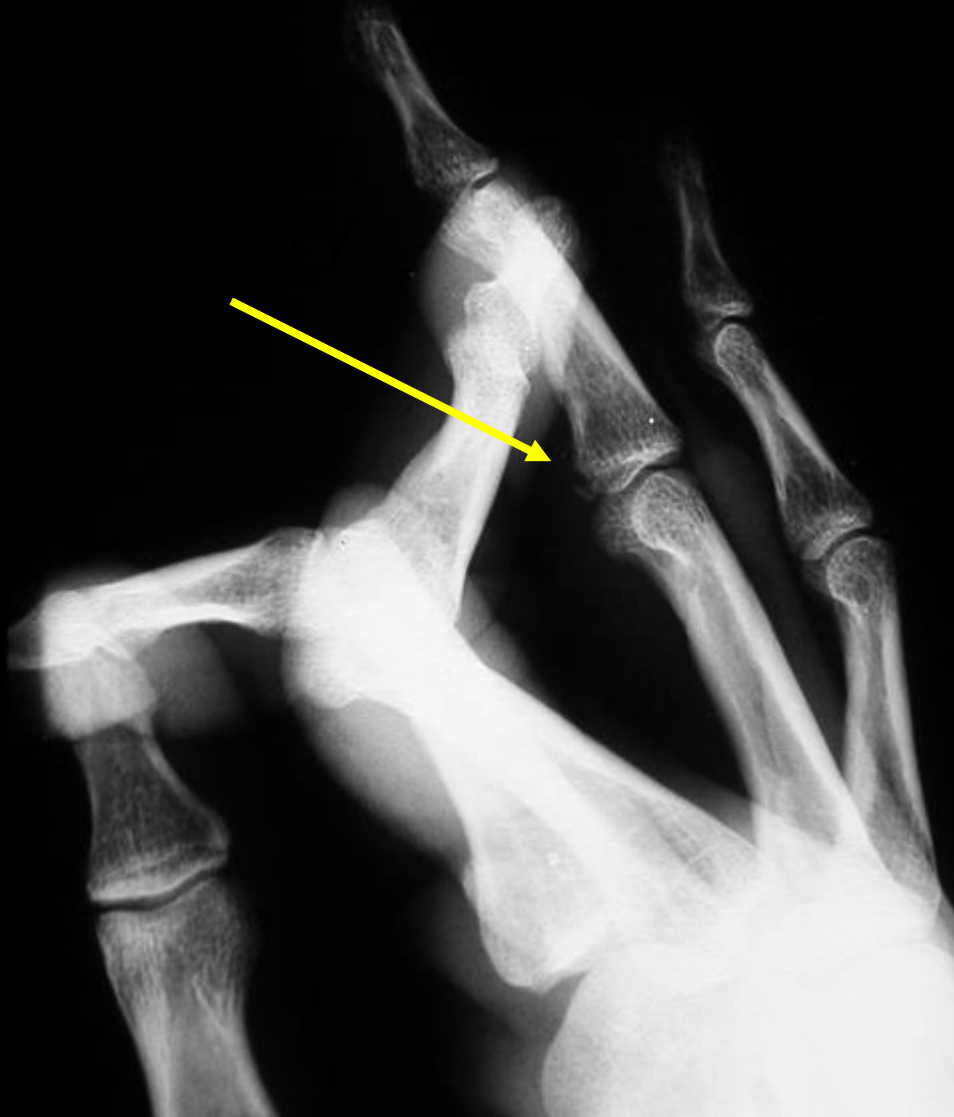

# Finger X-Rays

**Dislocation**



# Finger X-Rays



**Volar Plate  
Avulsion**

# The Request form is the Problem

<input checked="" type="checkbox"/> X-RAY	<input type="checkbox"/> CT	<input type="checkbox"/> MAMMOGRAPHY +/- ULTRASOUND	<input type="checkbox"/> OPG
<input type="checkbox"/> ULTRASOUND	<input type="checkbox"/> MRI	<input type="checkbox"/> INTERVENTIONAL	<input type="checkbox"/> LAT/CEPH
<input type="checkbox"/> DOPPLER	<input type="checkbox"/> BMD		

Exam

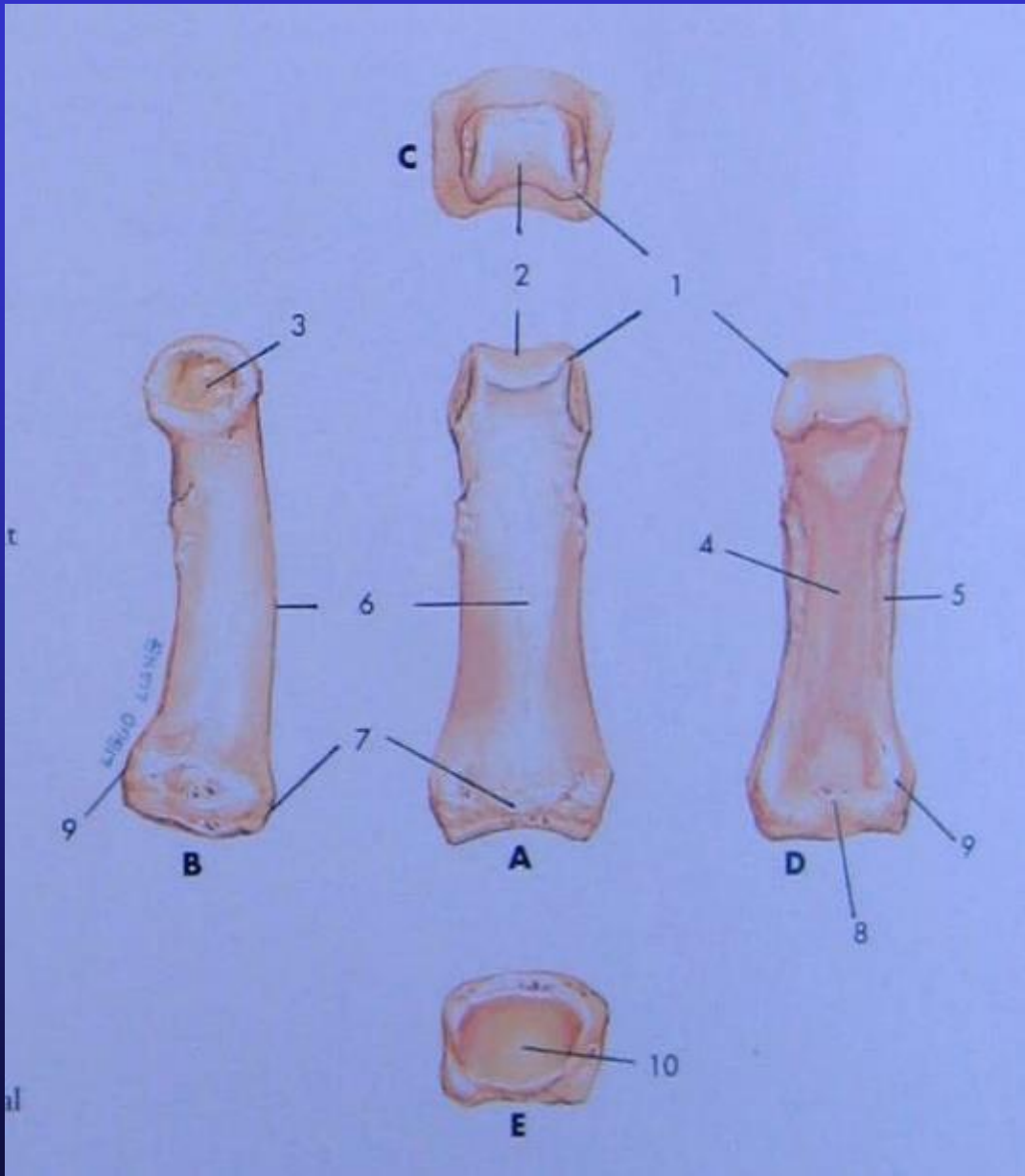
Clinical Notes

Right little eye PRJ

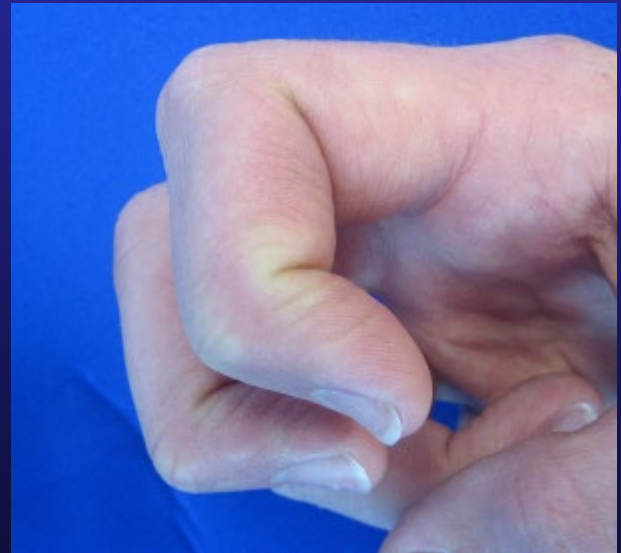
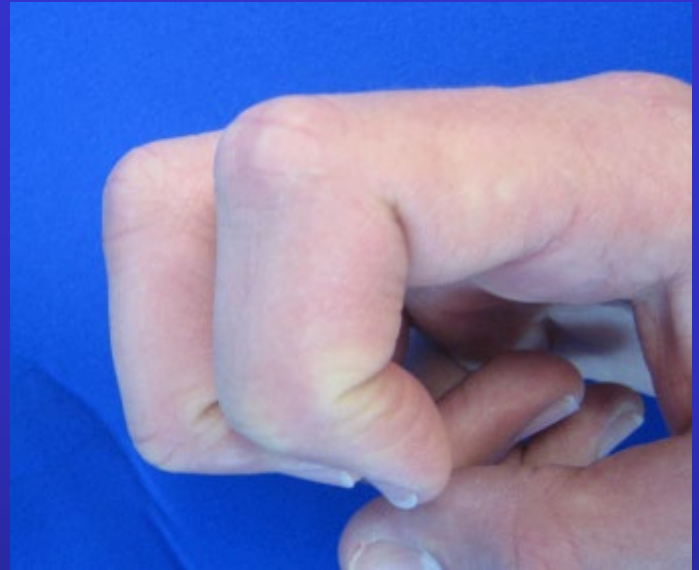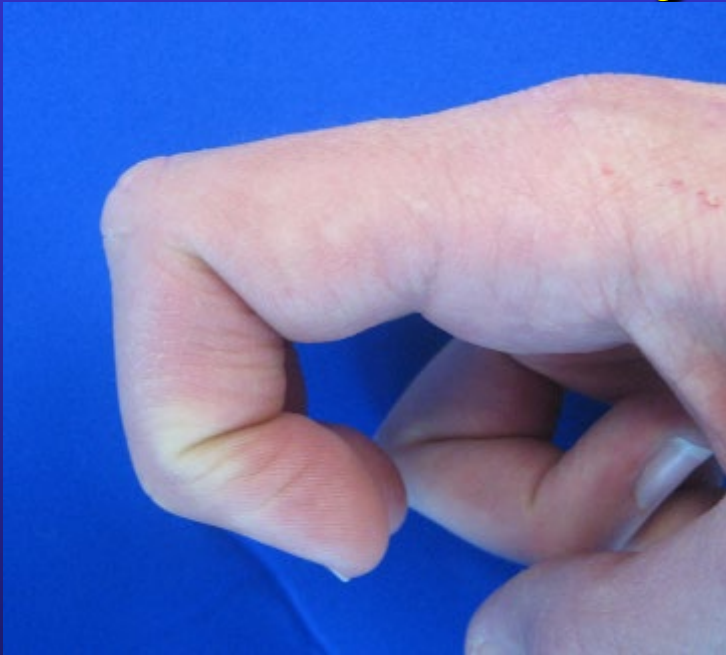IN spirit

(Volar plate arthroplasty 10/7)

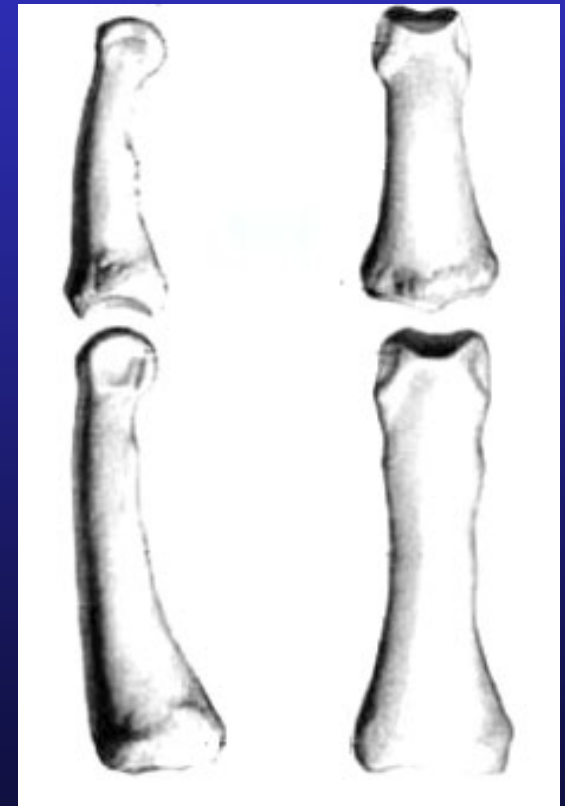
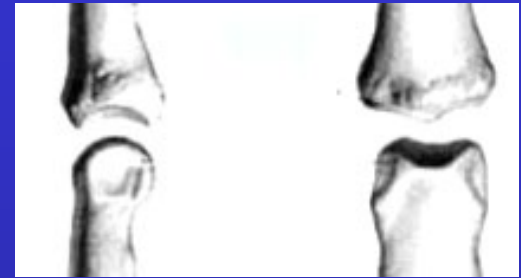
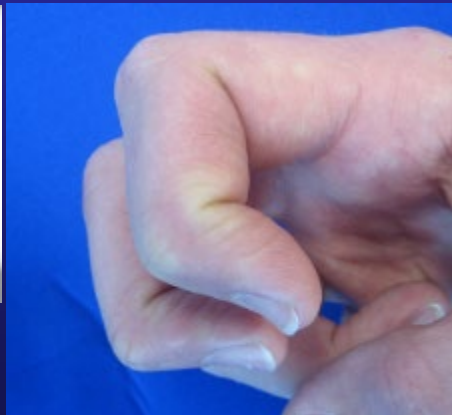
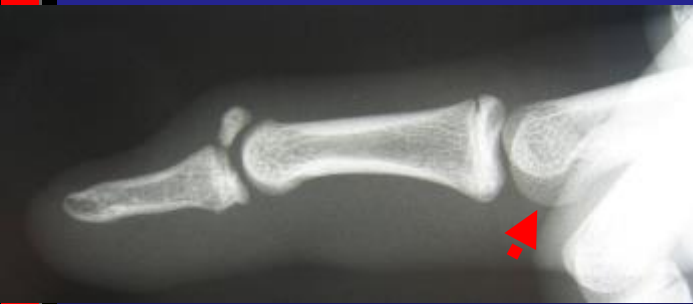
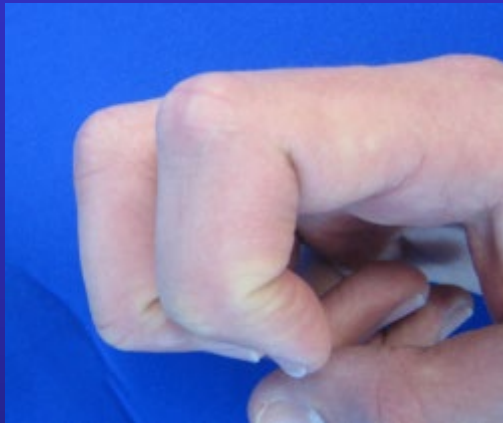
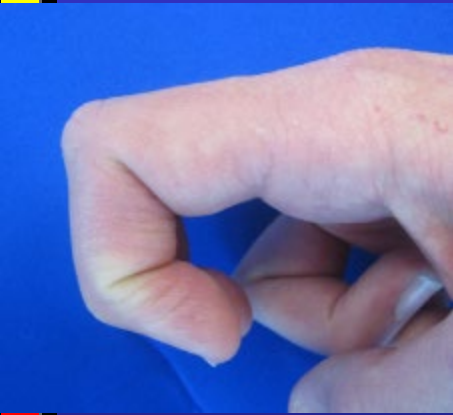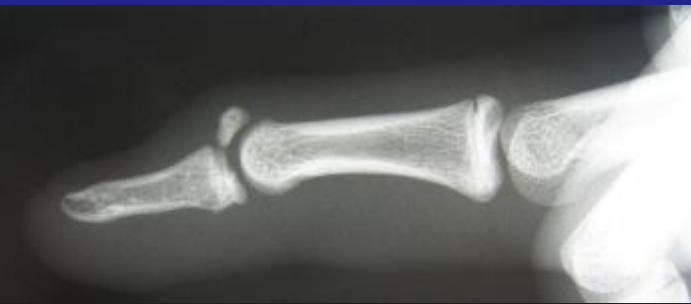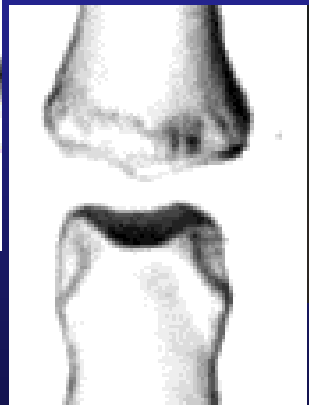
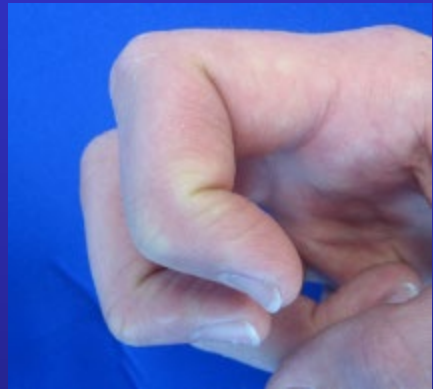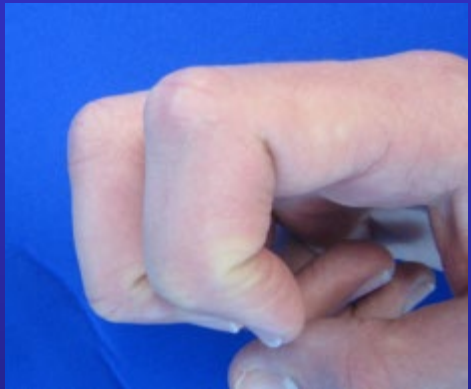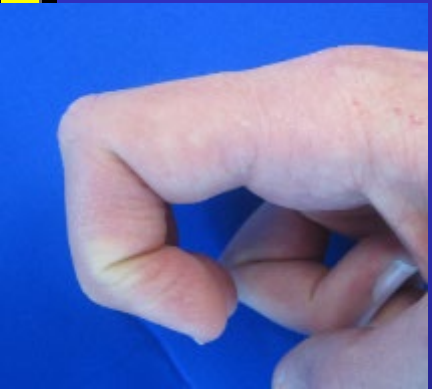# X-Rays



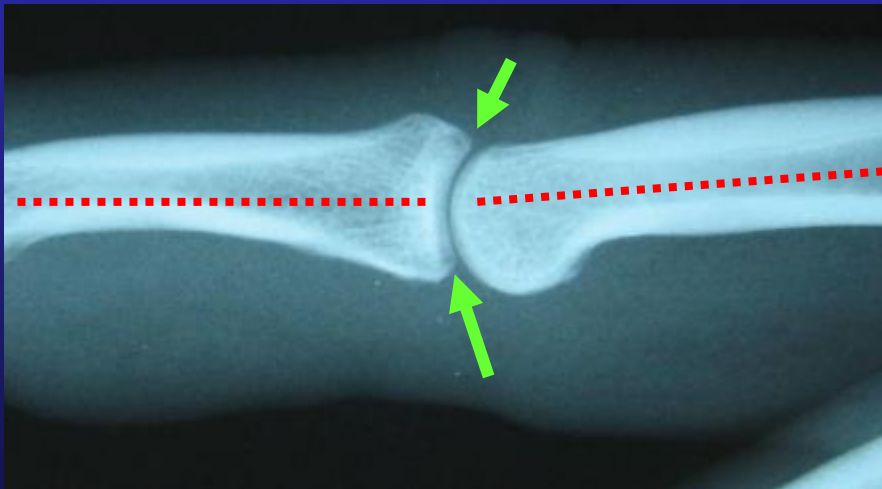
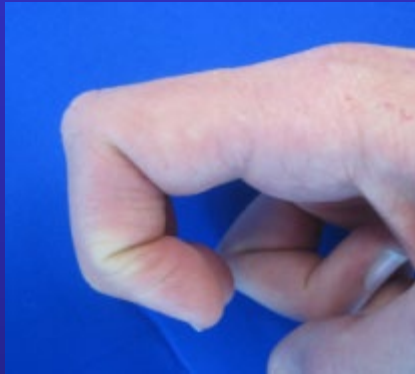# X-Rays



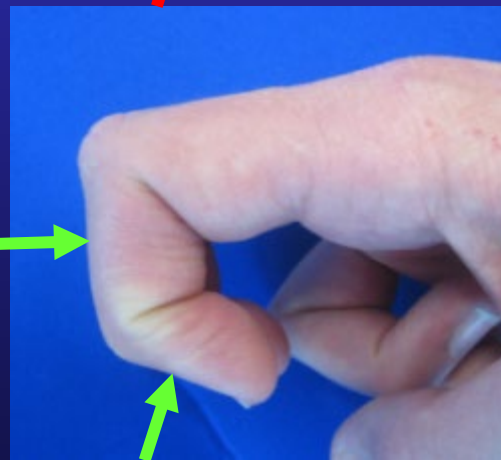
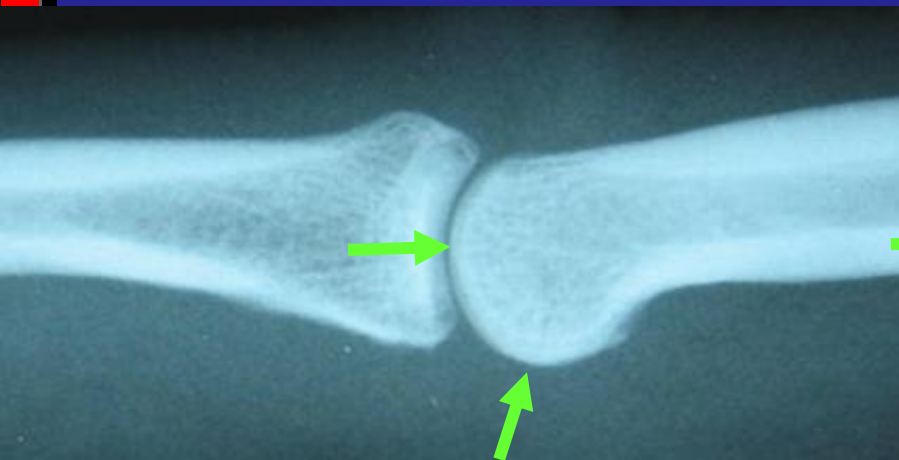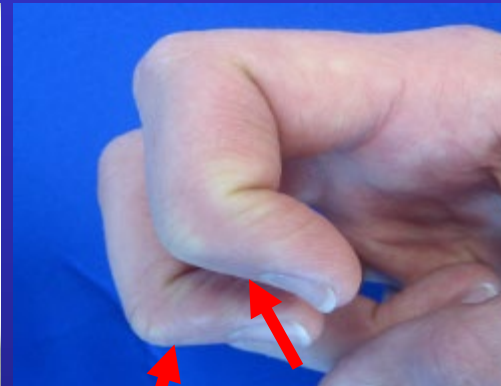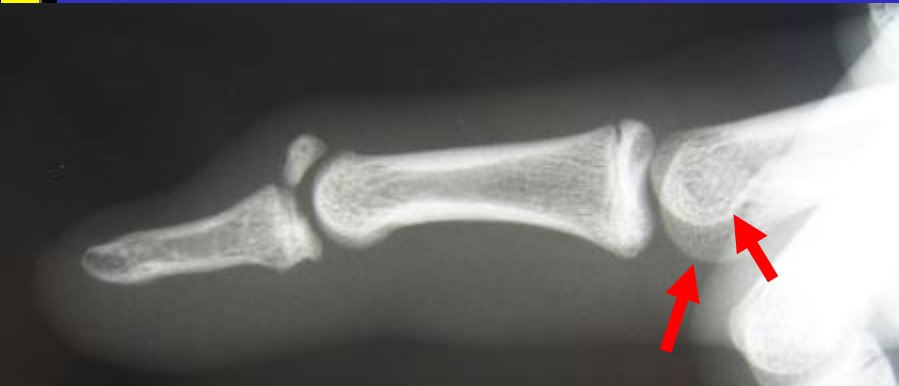# X-Rays



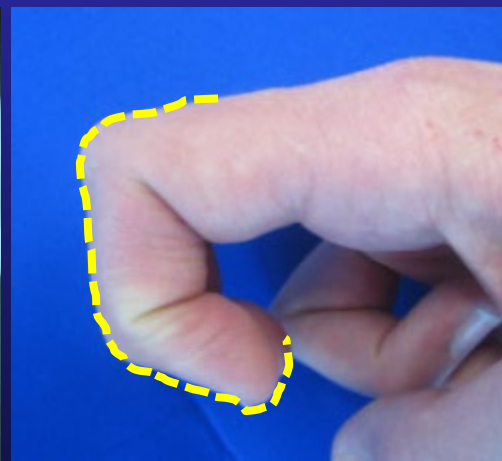
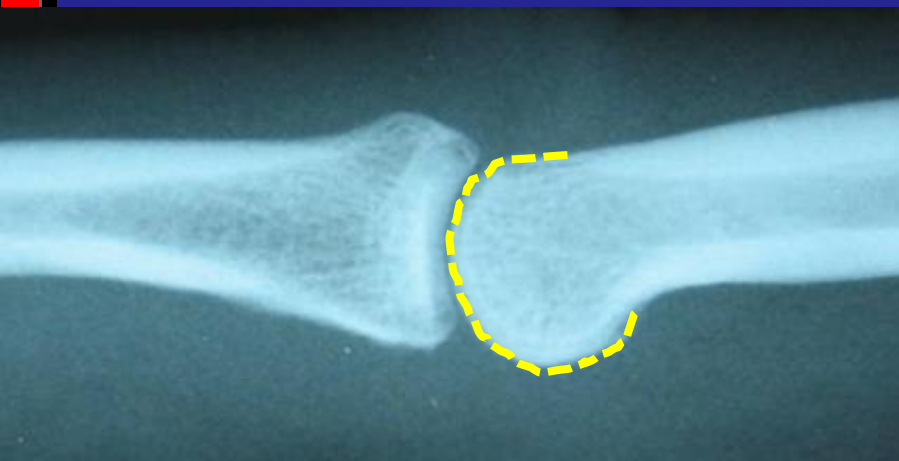
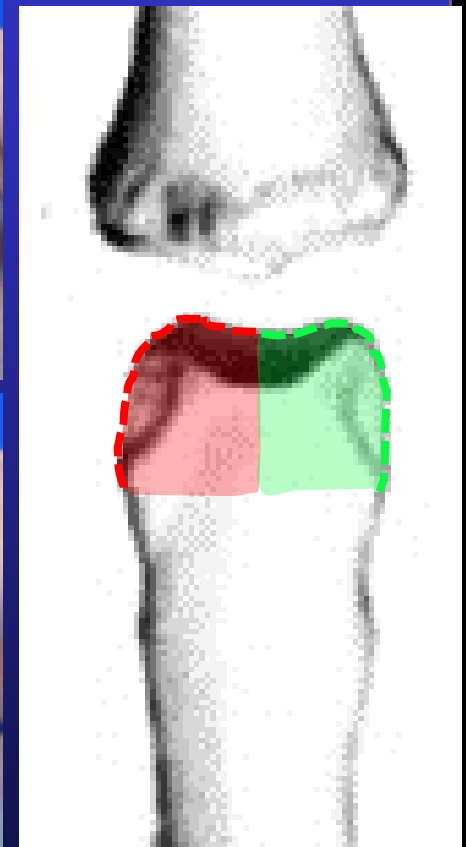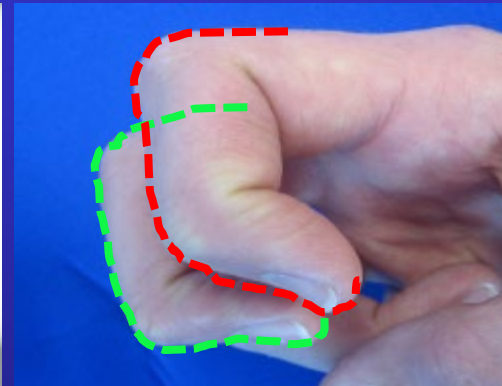
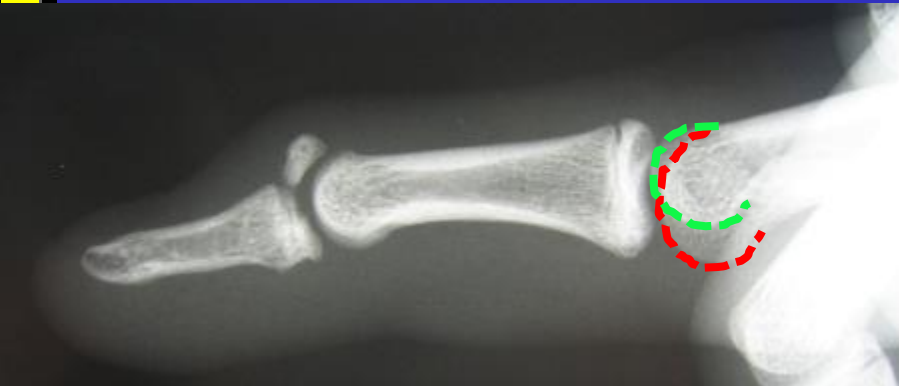# True Lateral



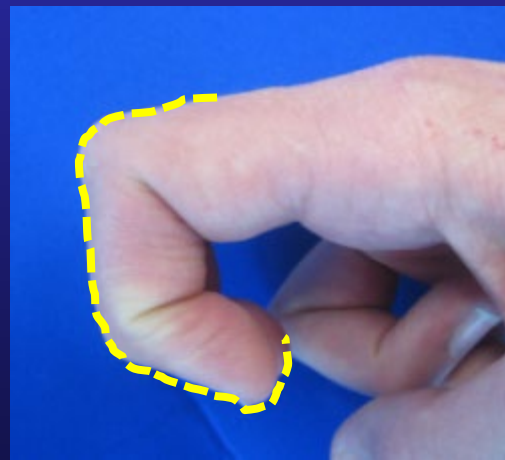
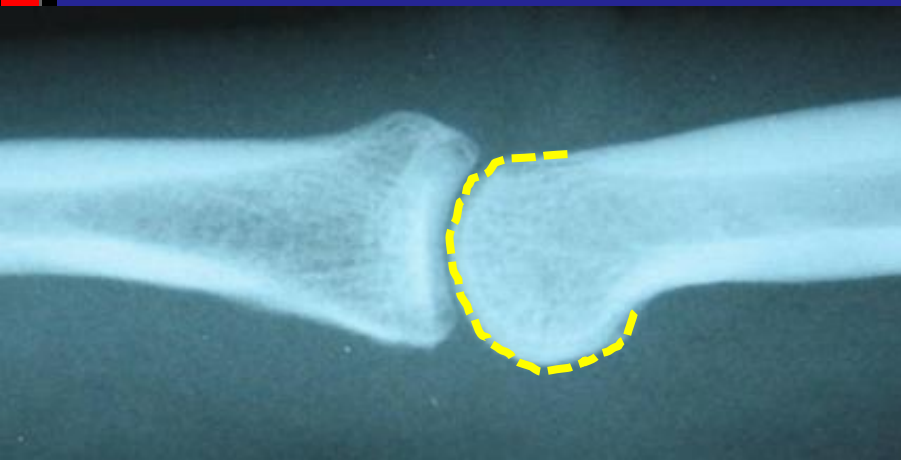
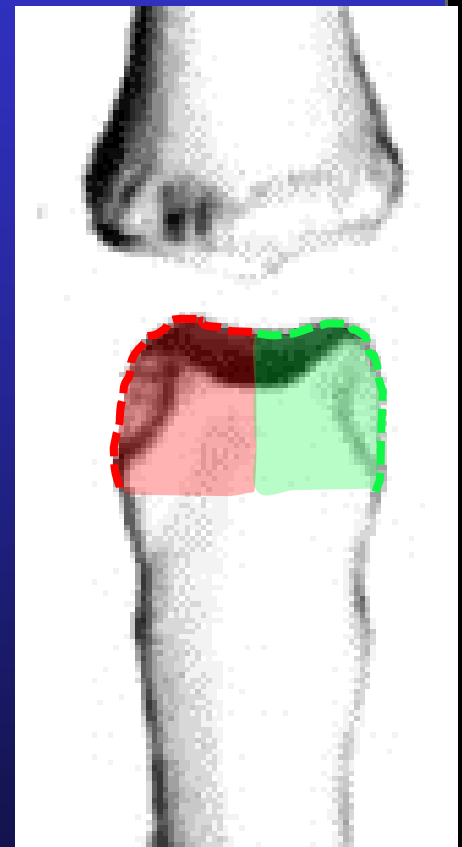
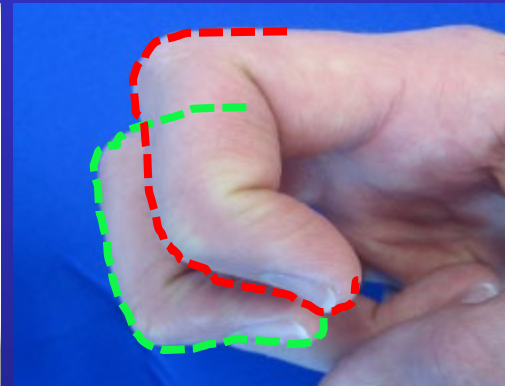
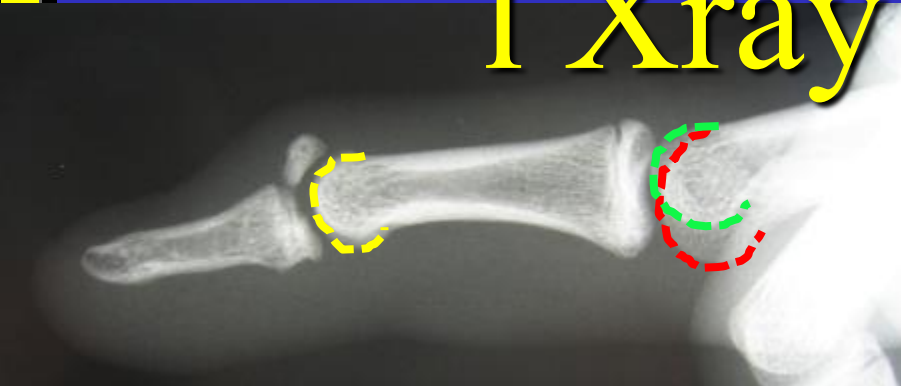
# Lateral Xray



# Lateral Xray



# Lateral 1 Xray



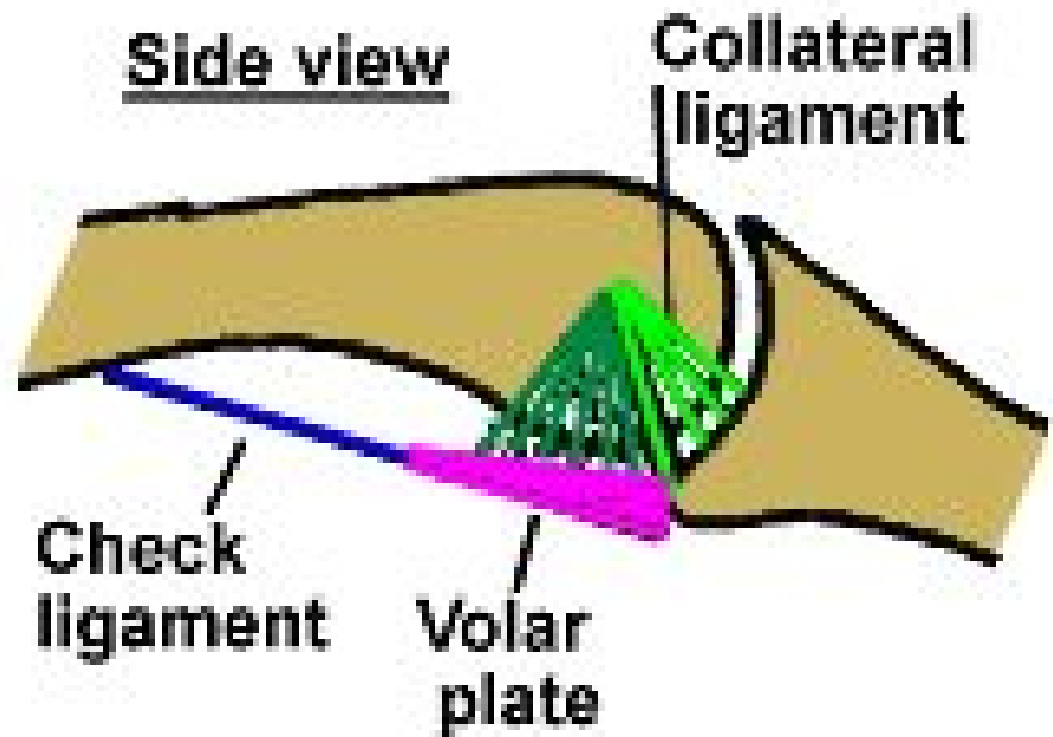


# PIP Joint

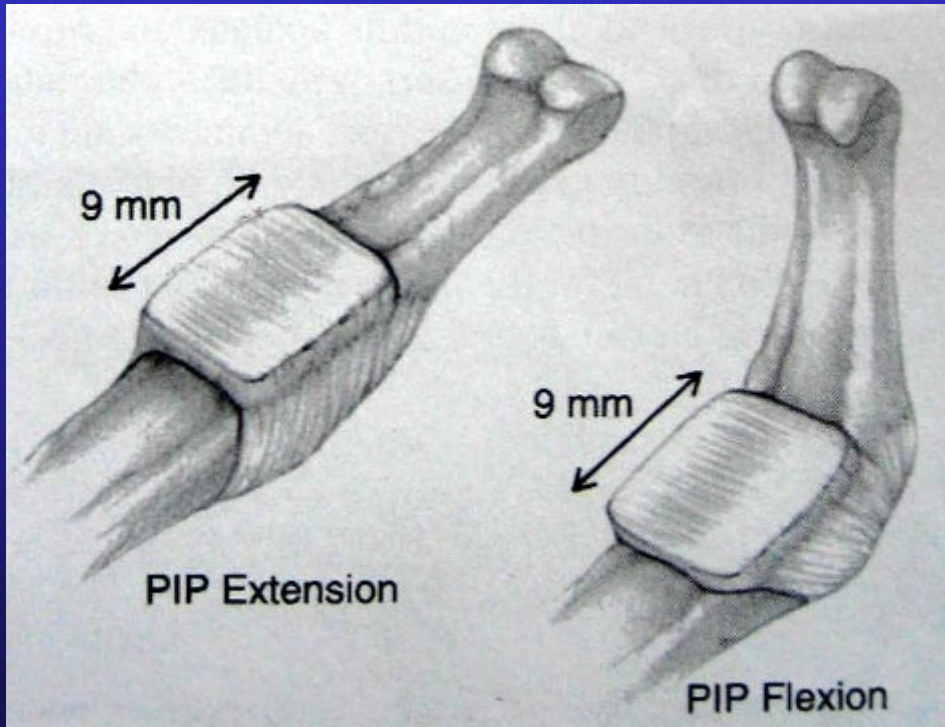
Back View



Side view

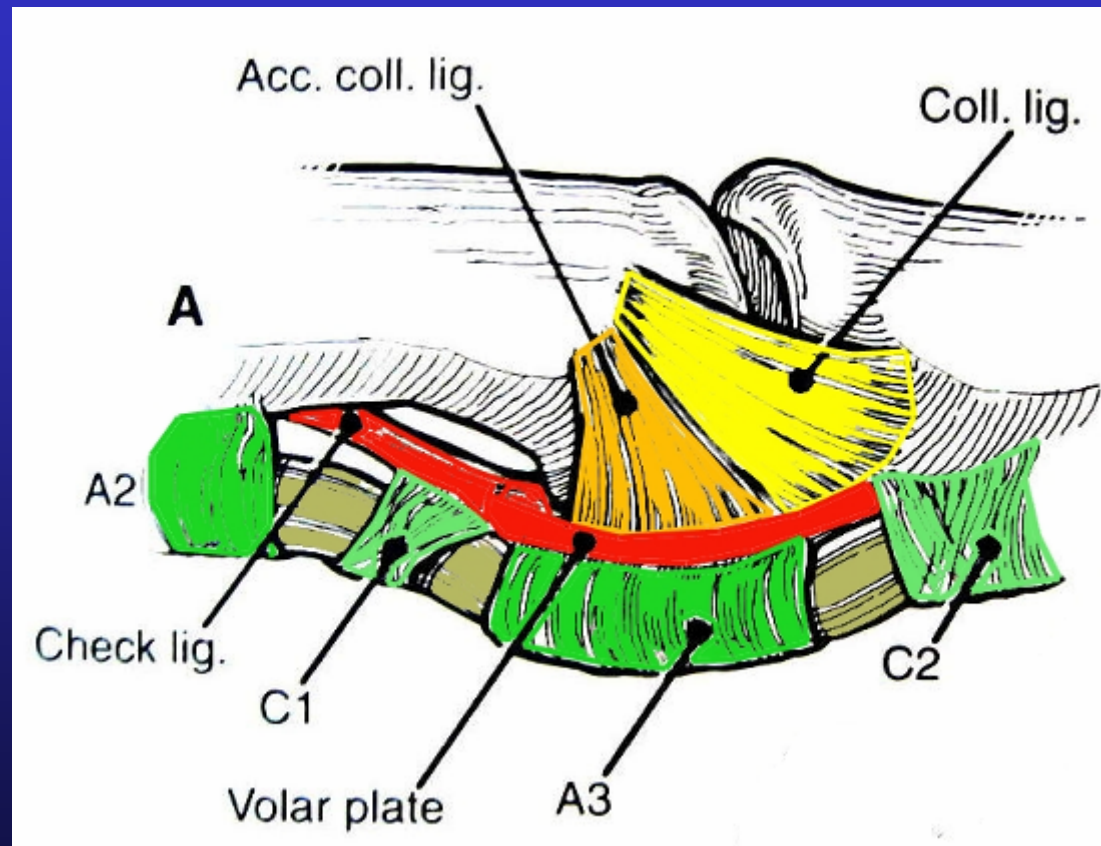


# PIP Volar plate




- Transverse fibres
- Excursion ++
- In-elastic

# PIP joint

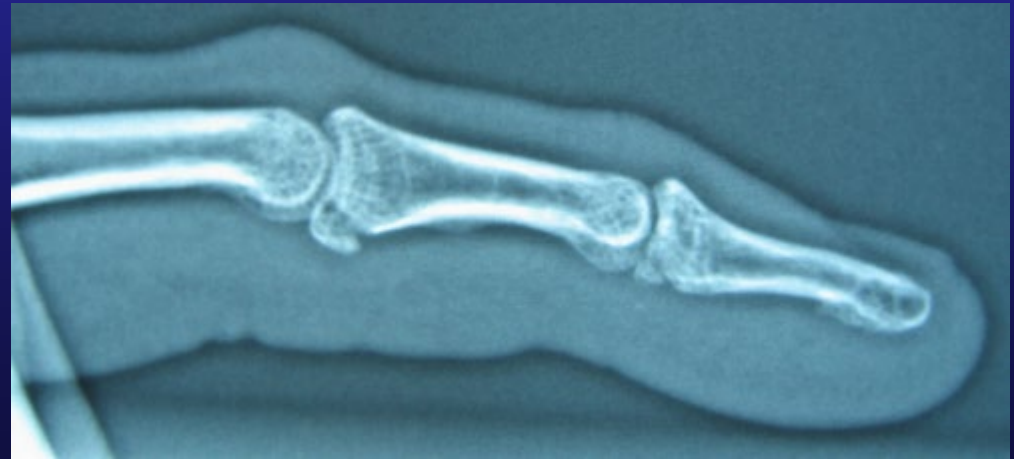

# PIP Jt Injuries

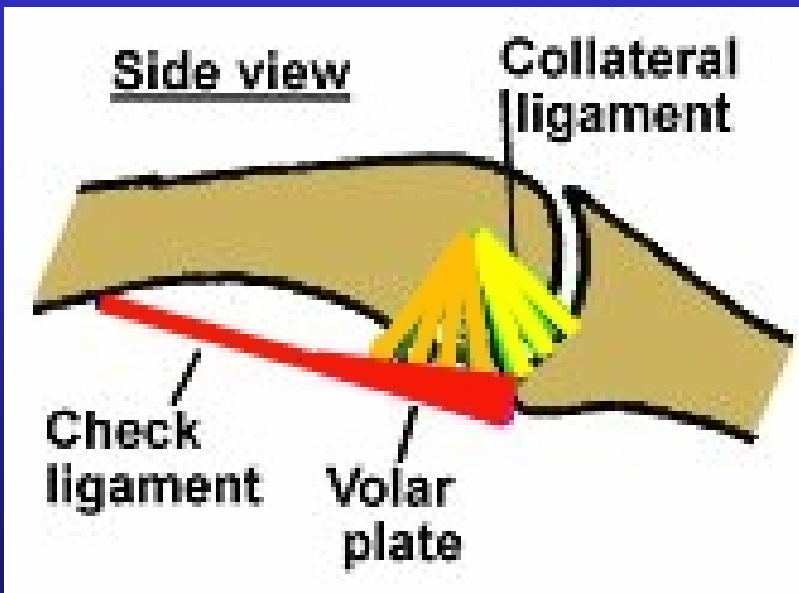
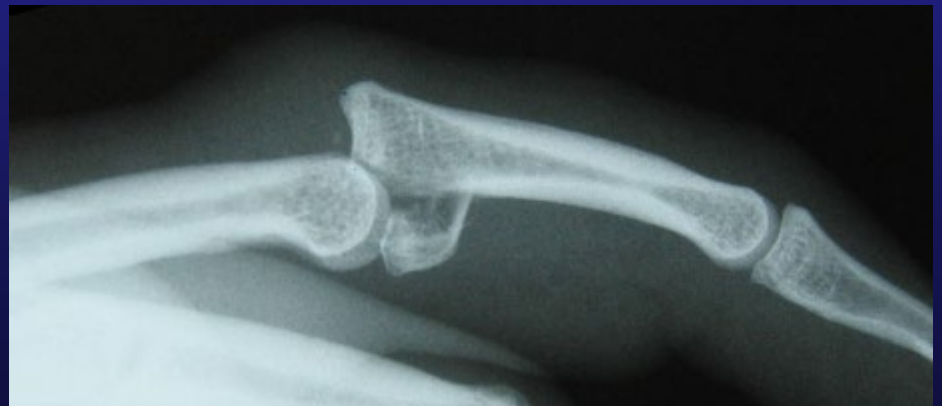
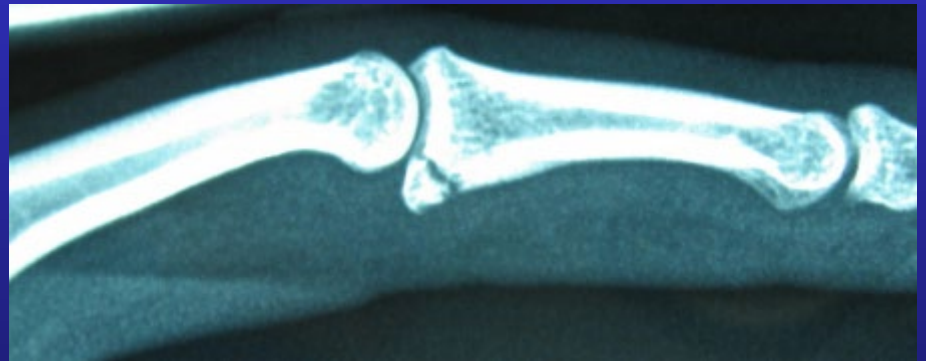
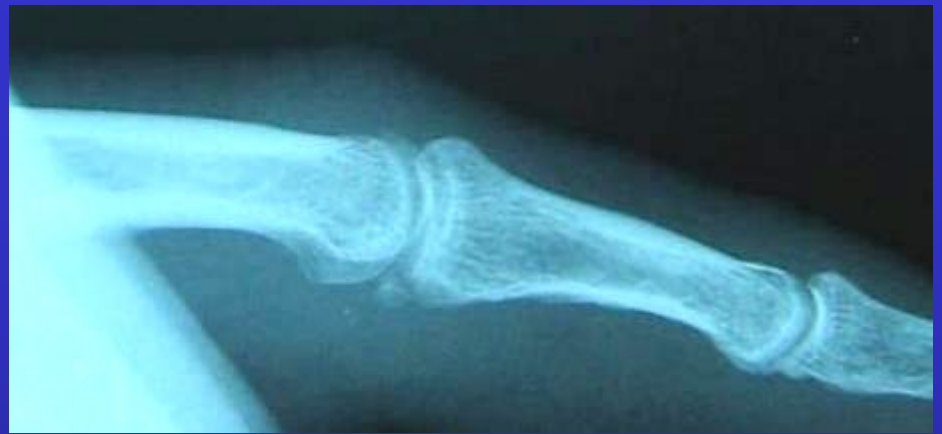Volar Plate Avulsion

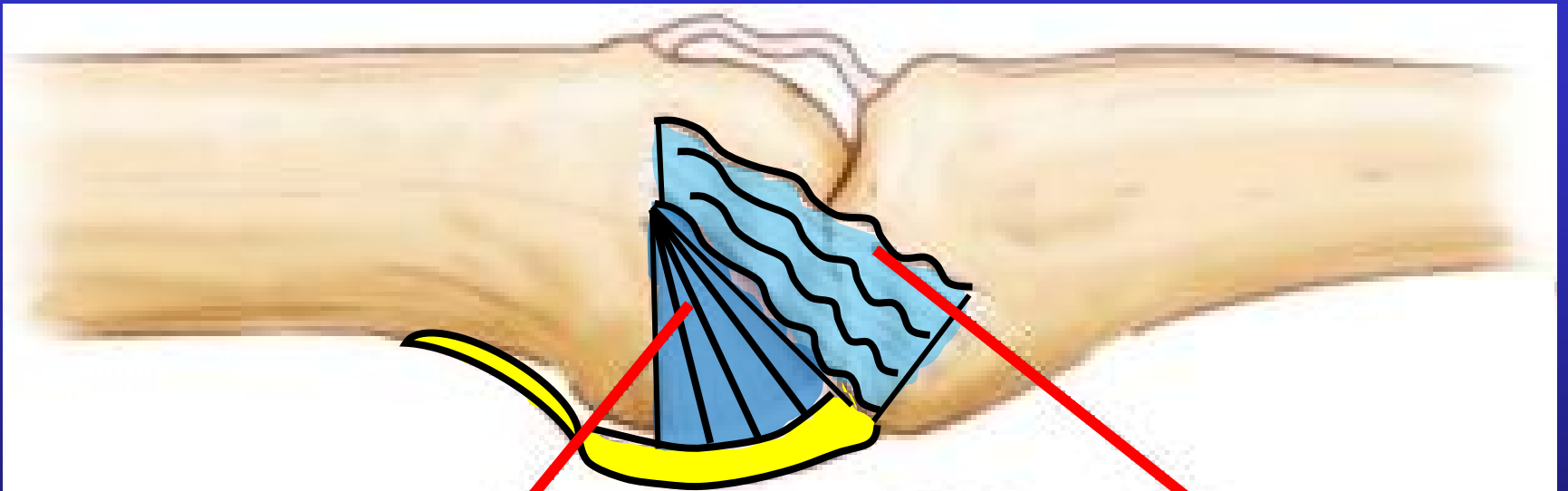
Hyper extension  
Injuries



40%



## Extension

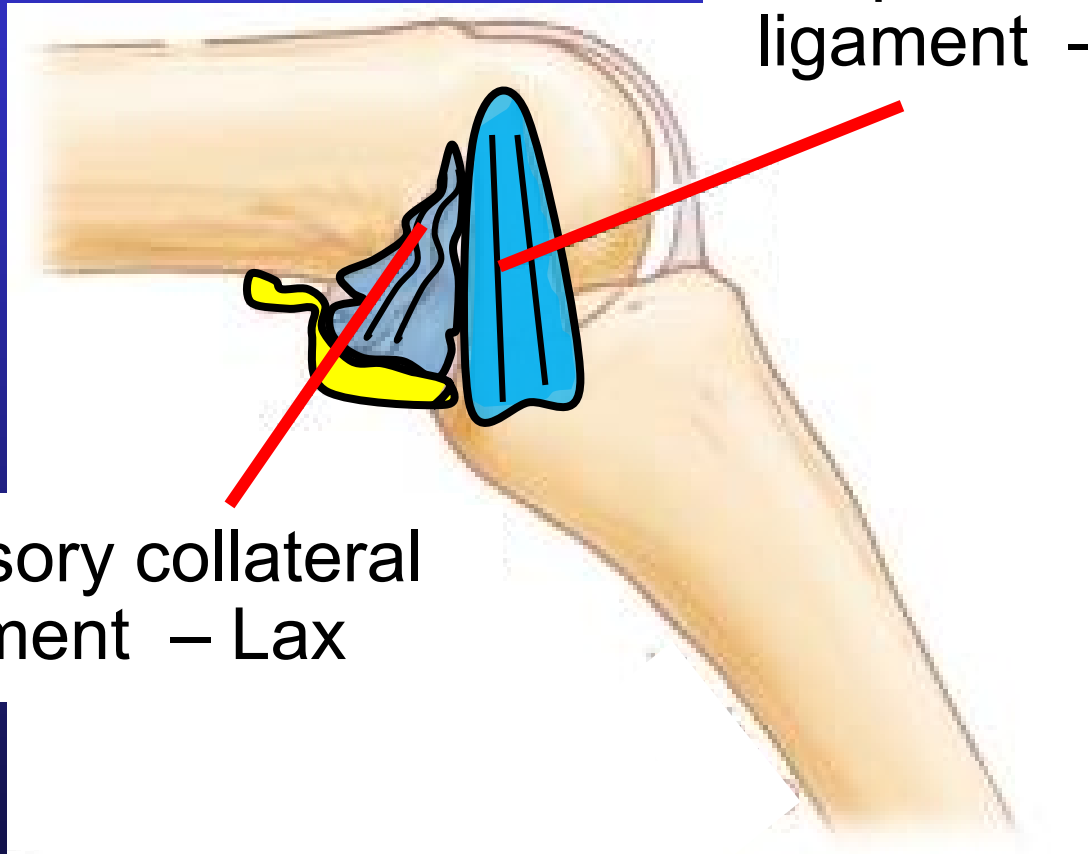


Accessory collateral  
ligament – Tight

Proper collateral  
ligament – Lax

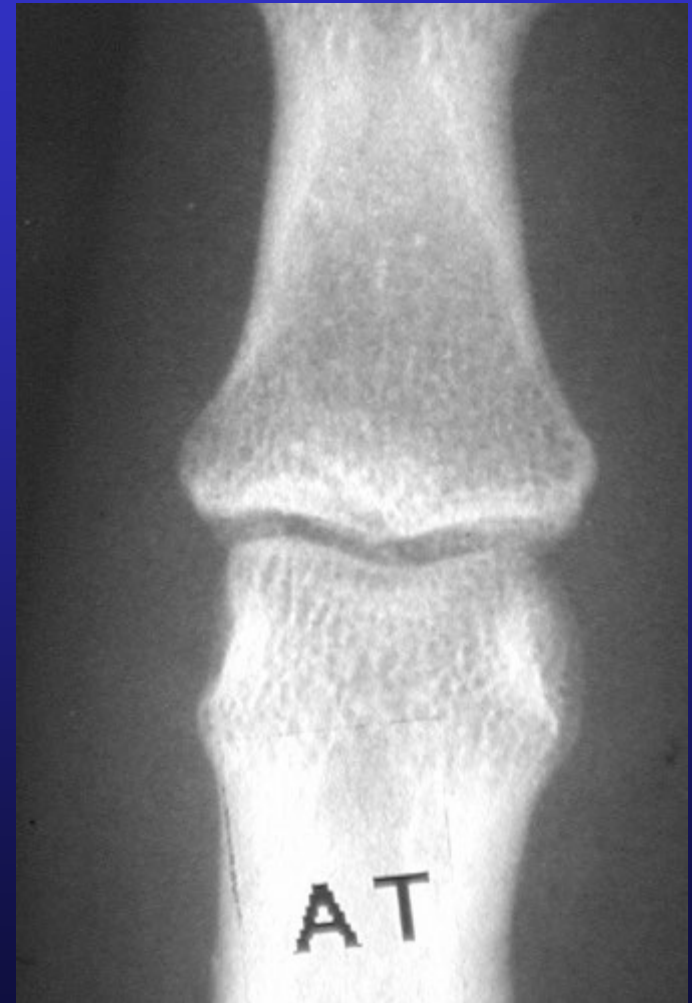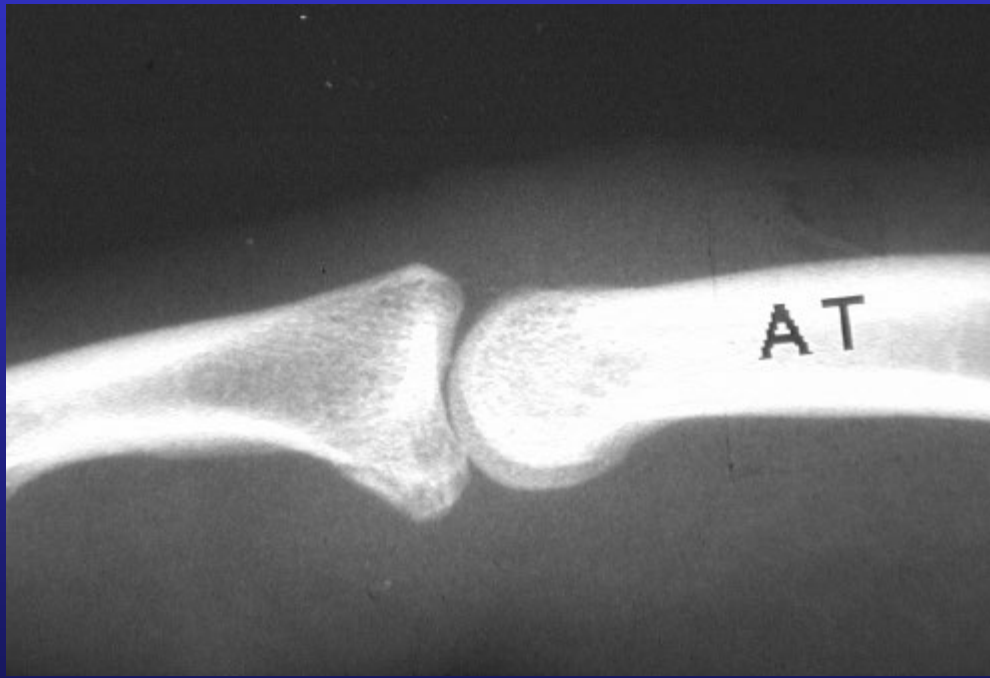
Flexion

Proper collateral ligament – Tight



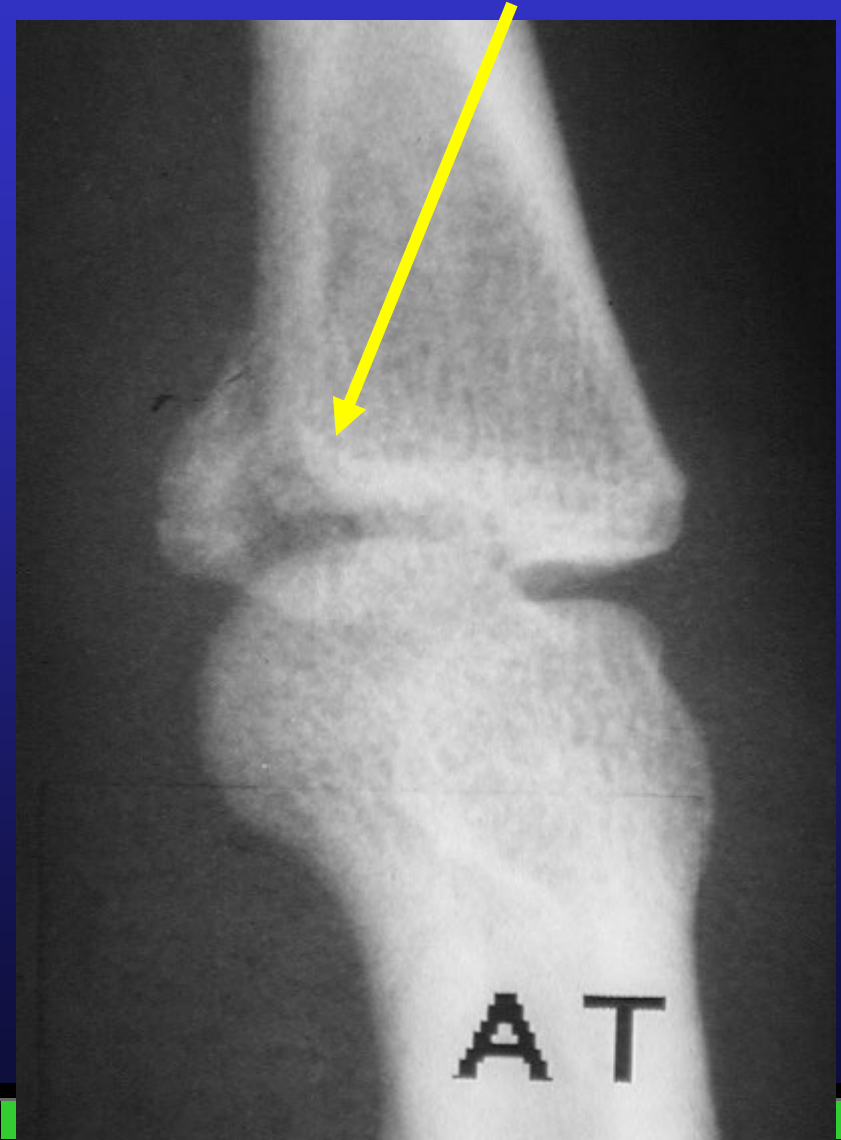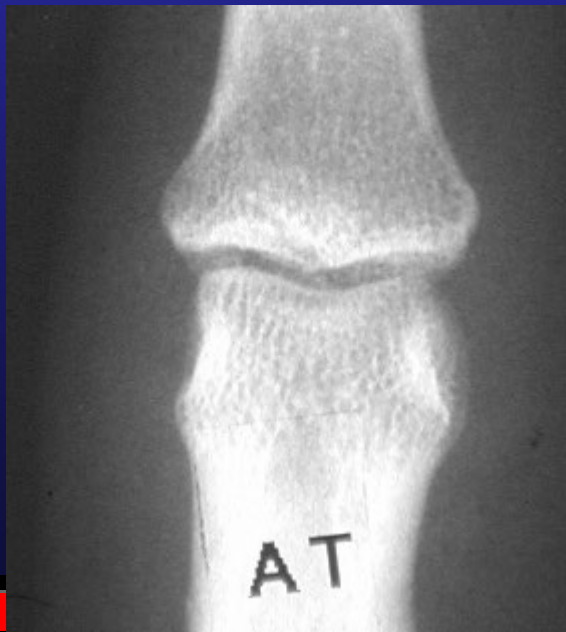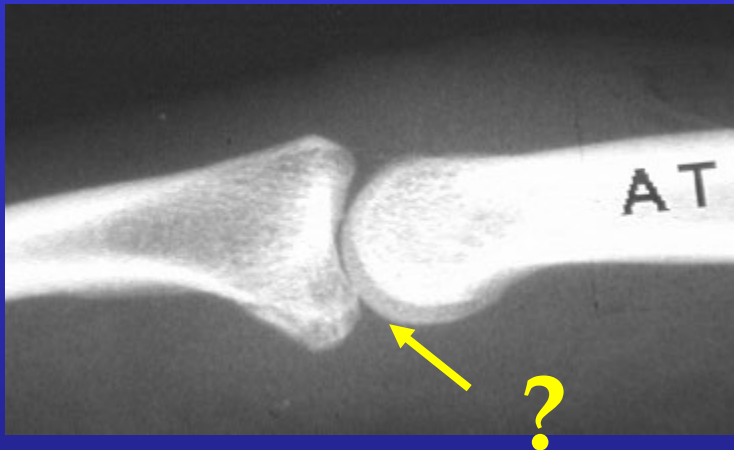
Accessory collateral ligament – Lax

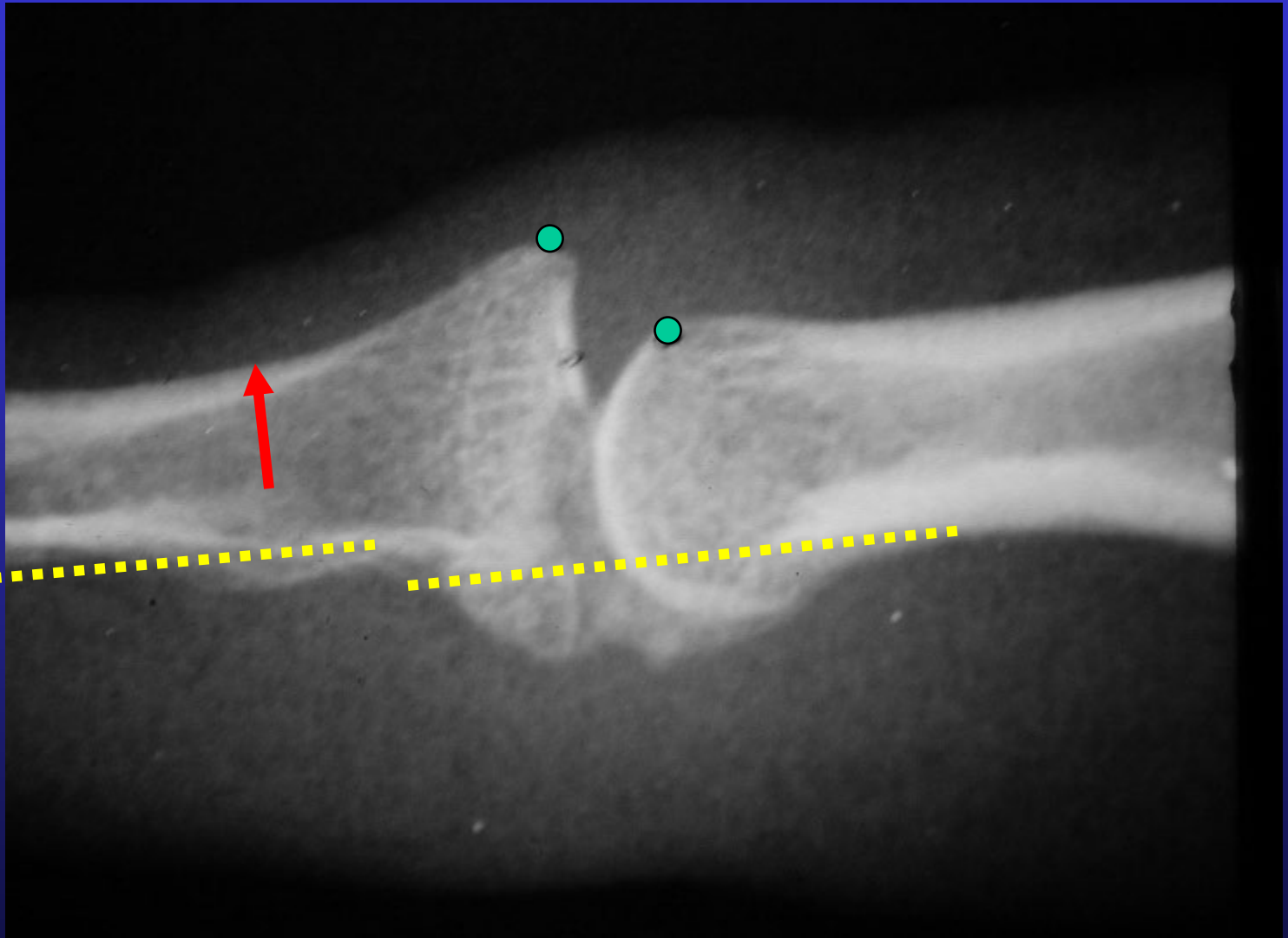
# P.I.P. Joint Xray

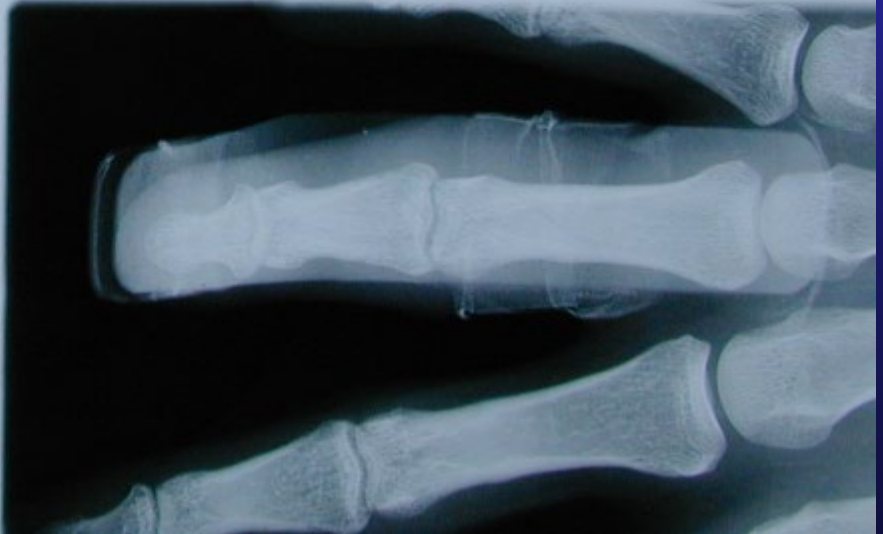
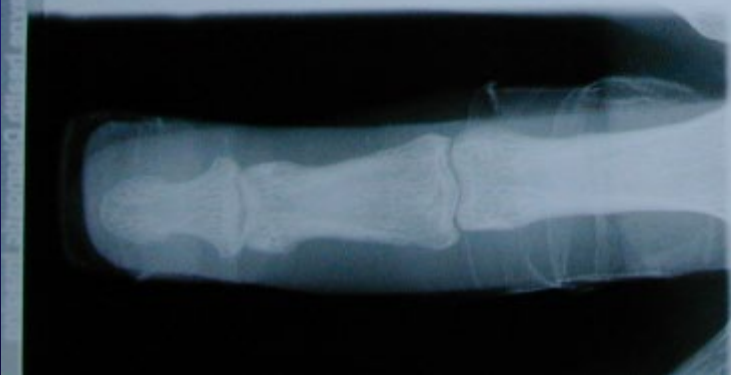
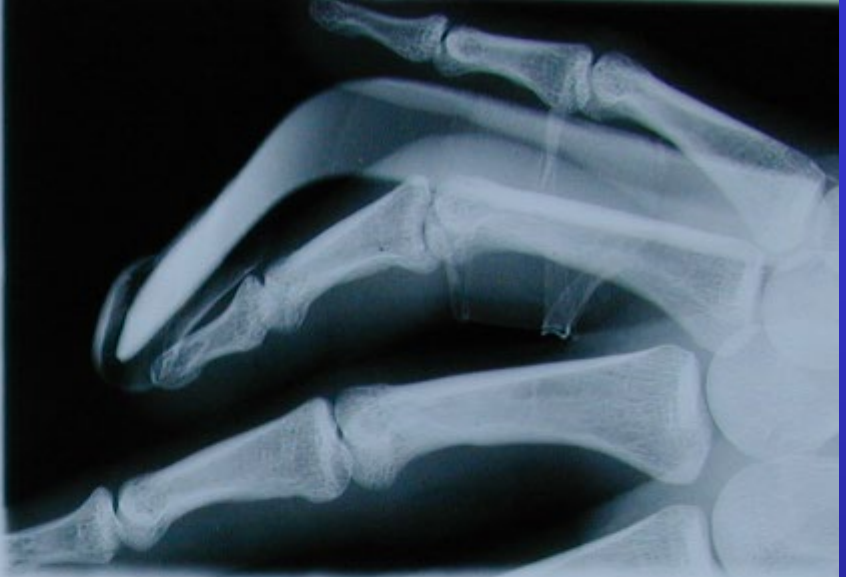
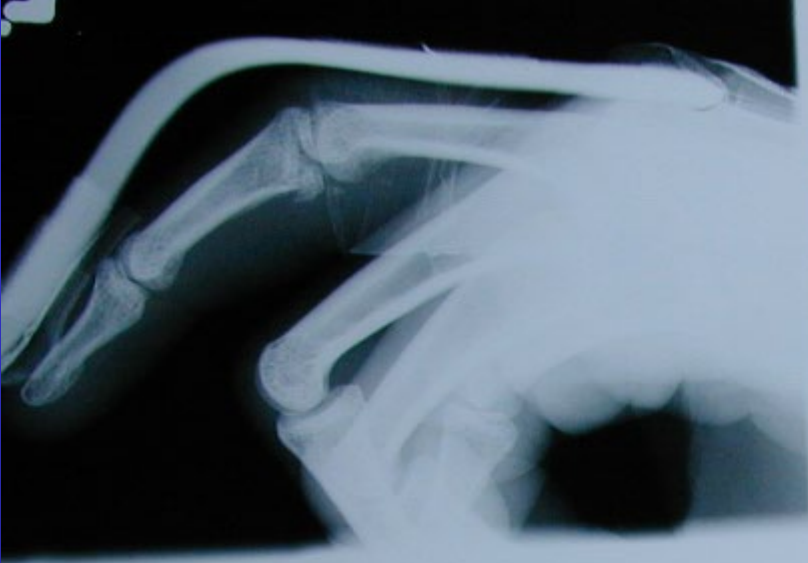

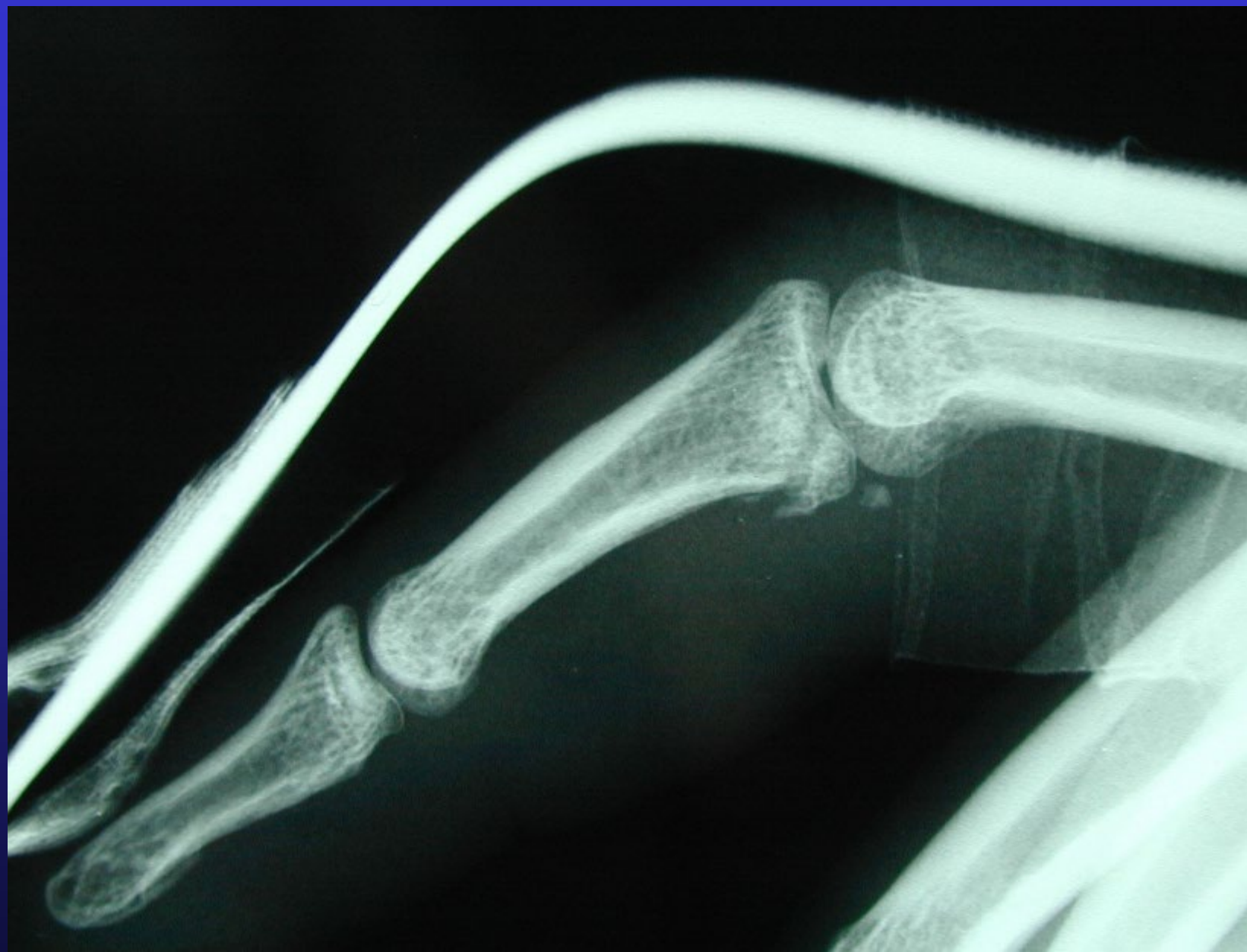
# 3 Views - Oblique

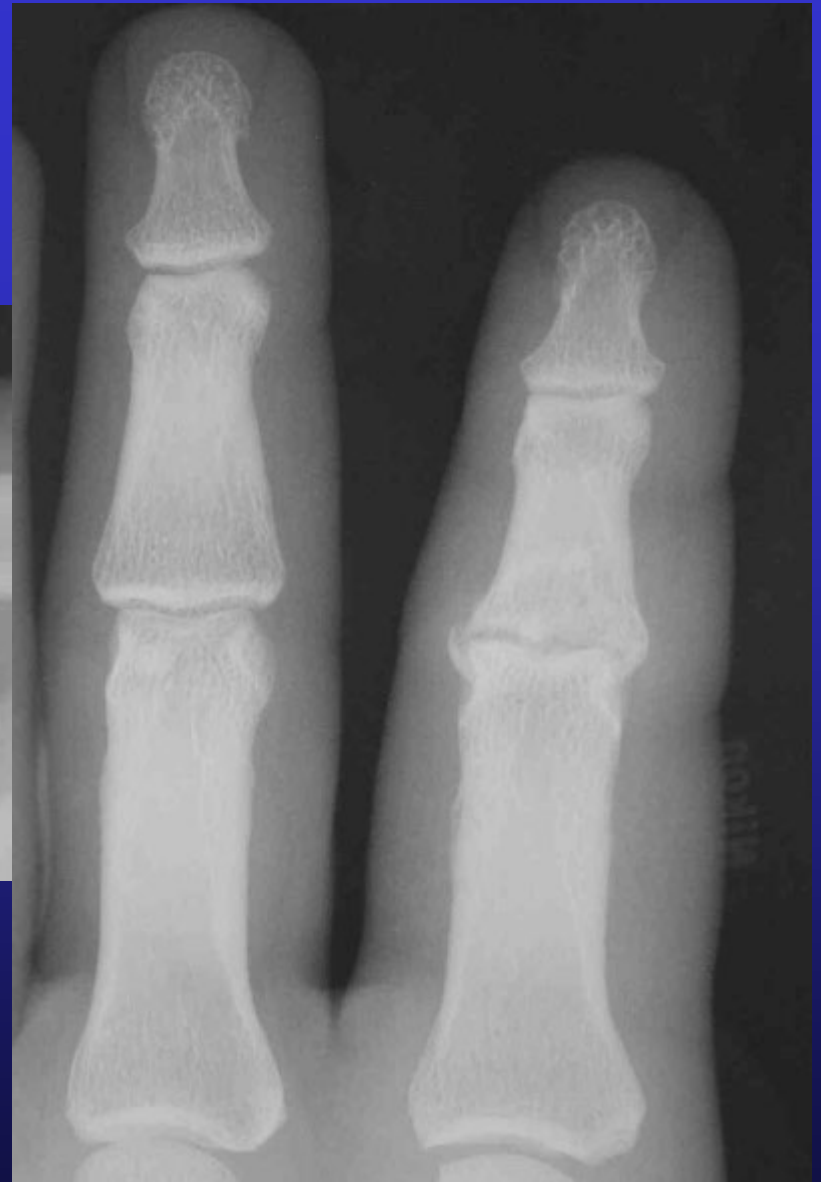
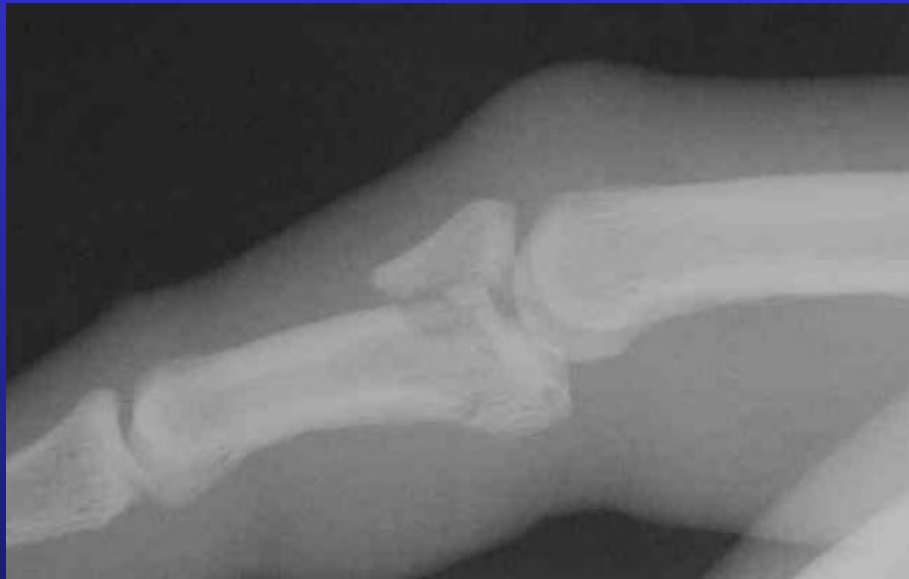


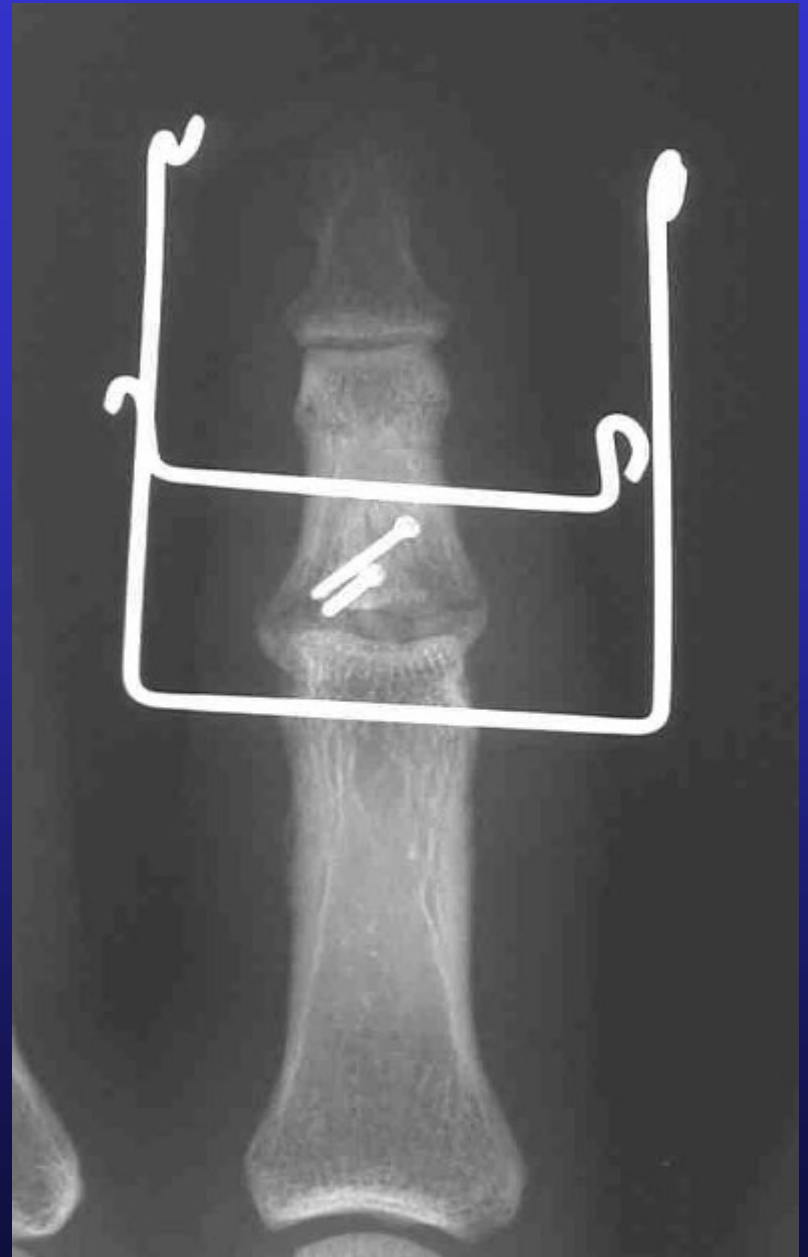
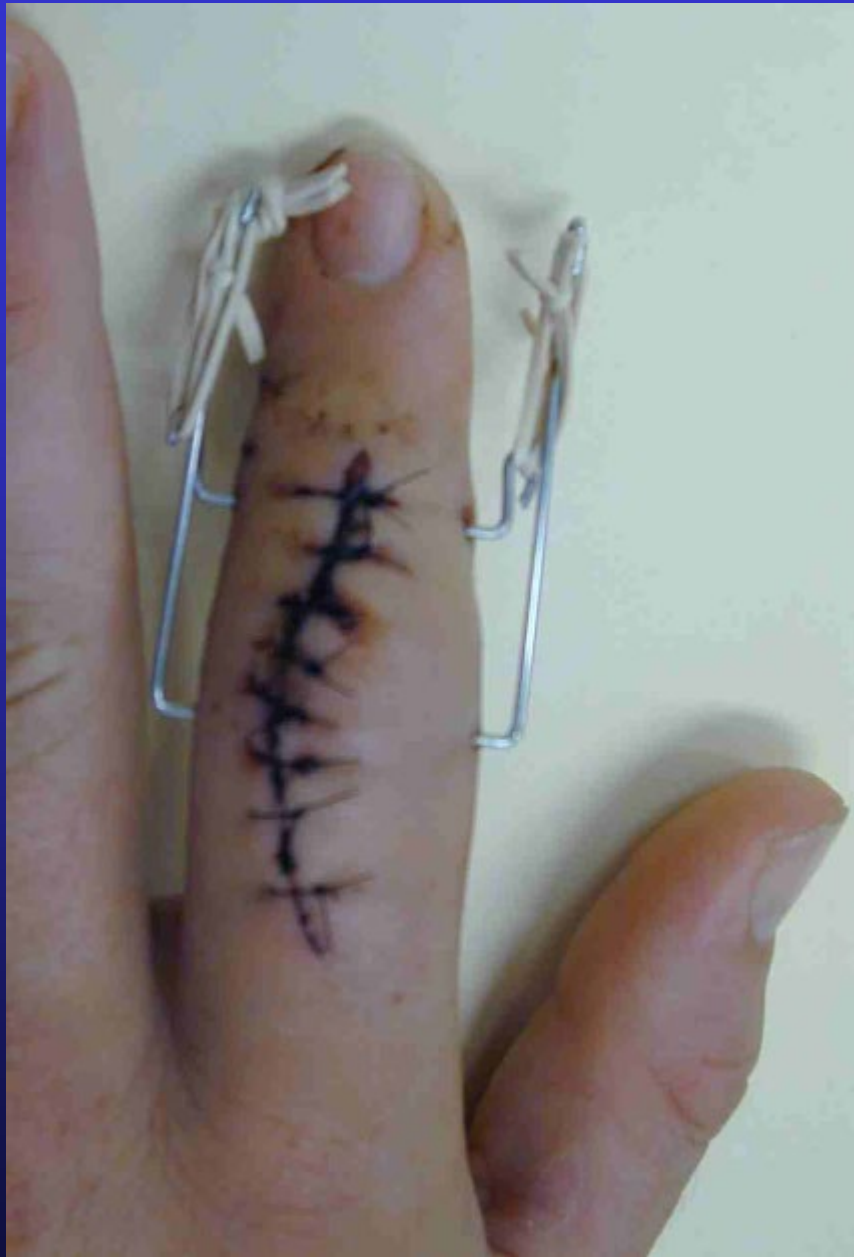

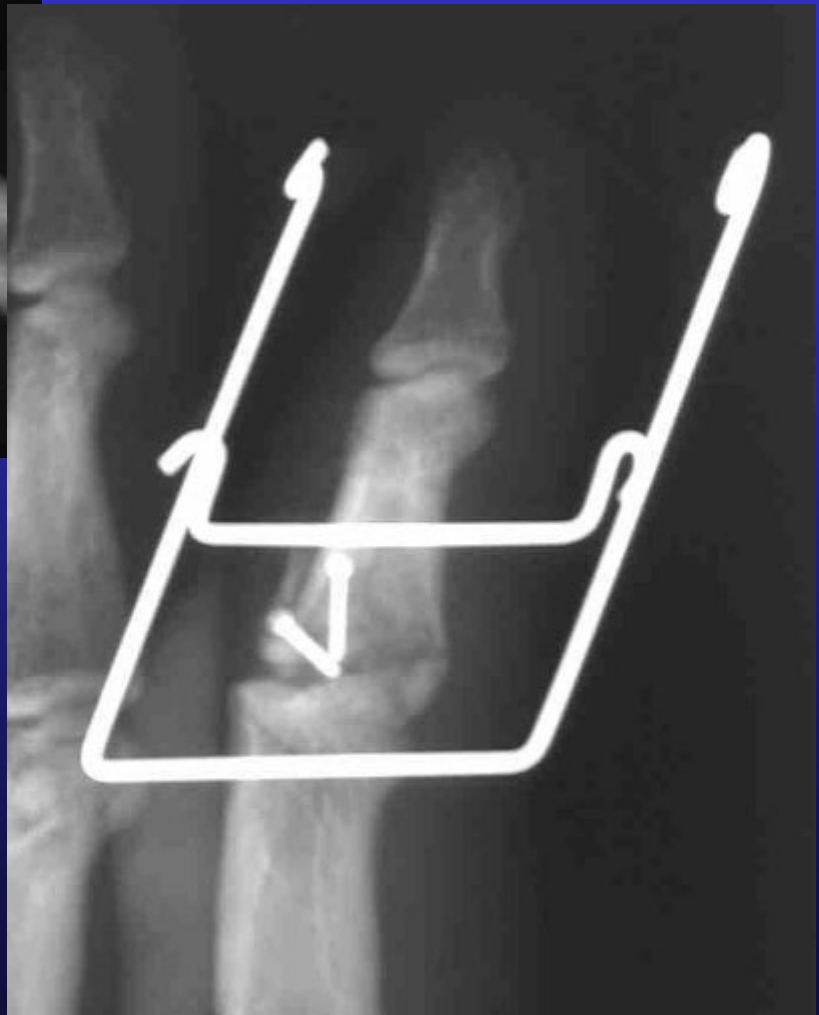Distal Radius Proximal Ulna

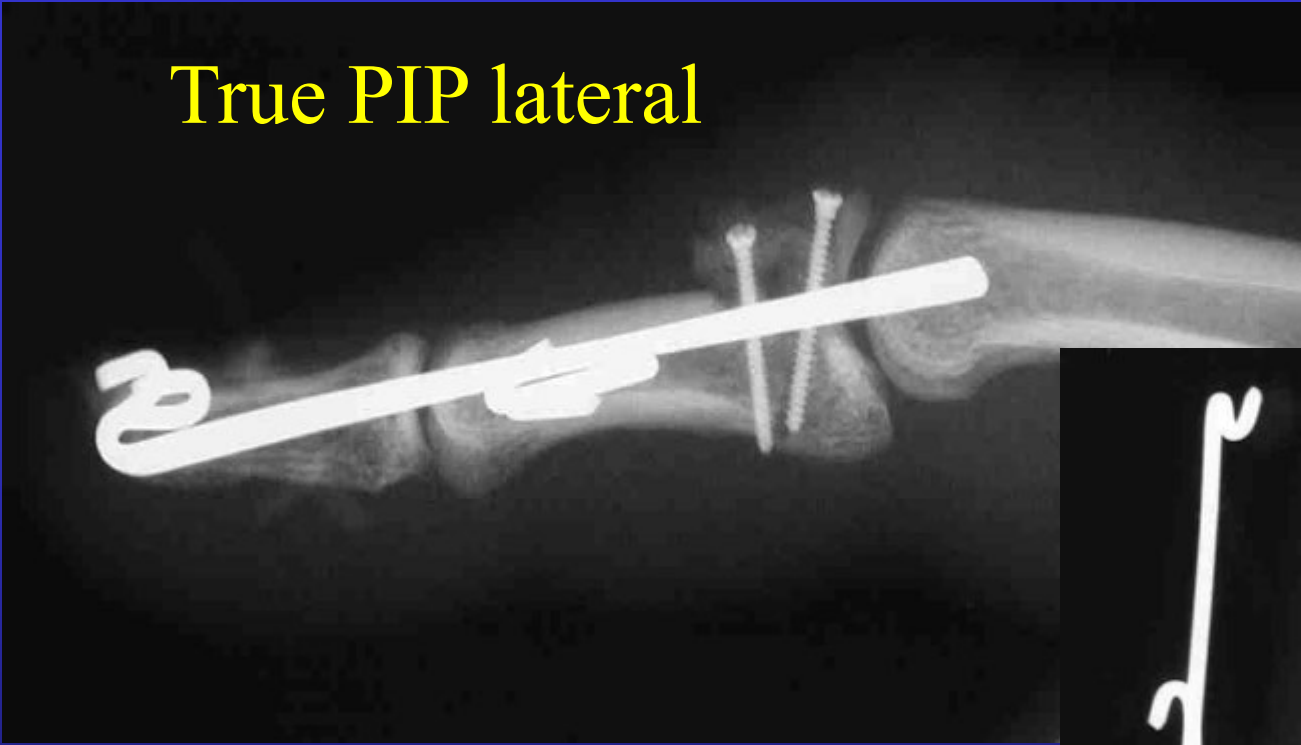




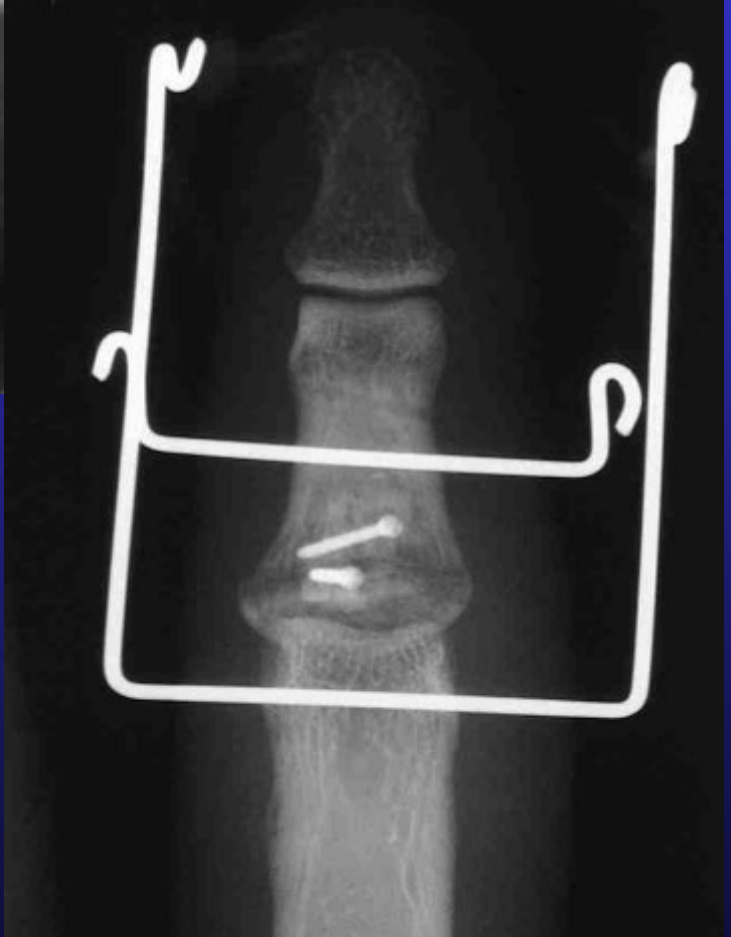



# True PIP lateral

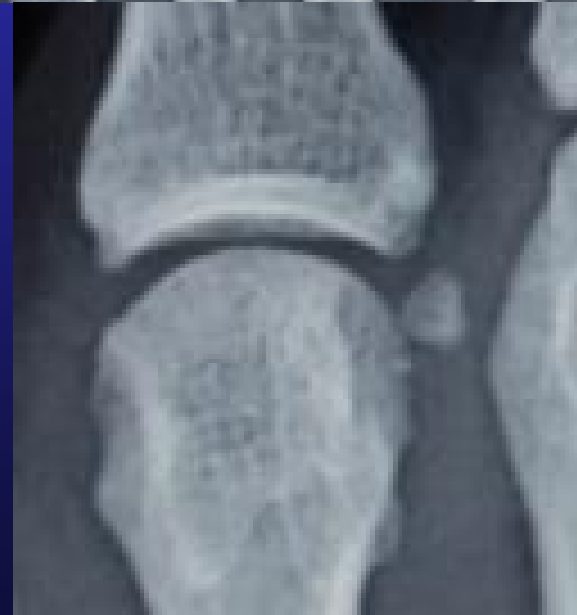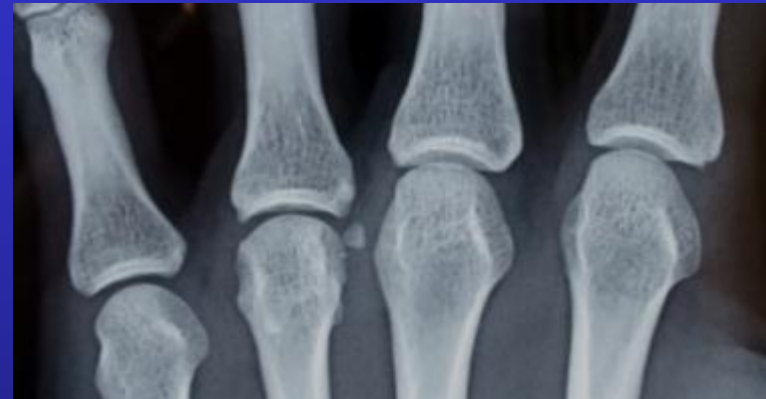

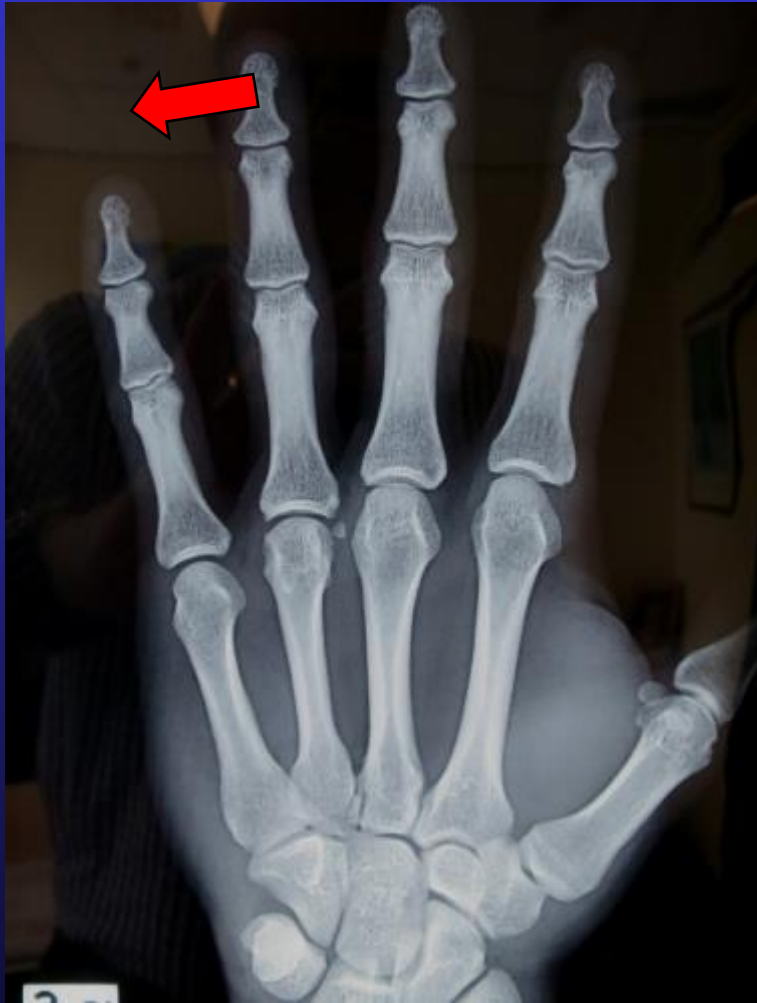
PA of What?????  
Need AP view of Middle  
Phalanx

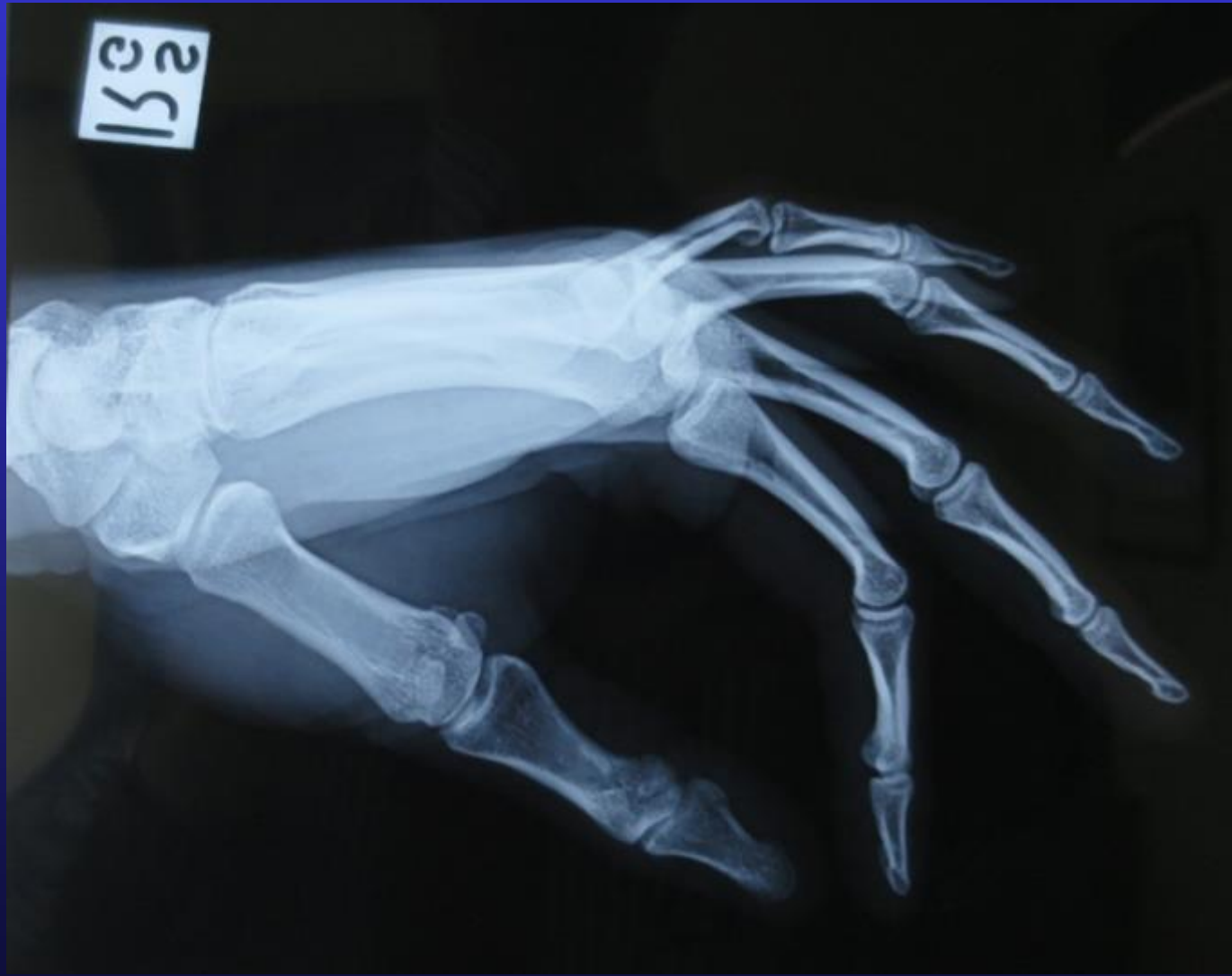


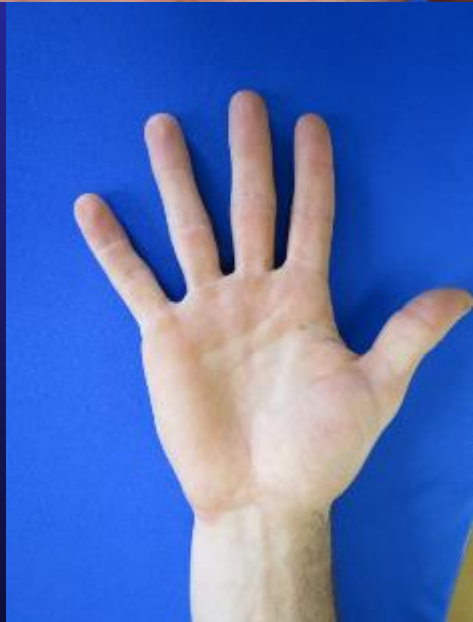
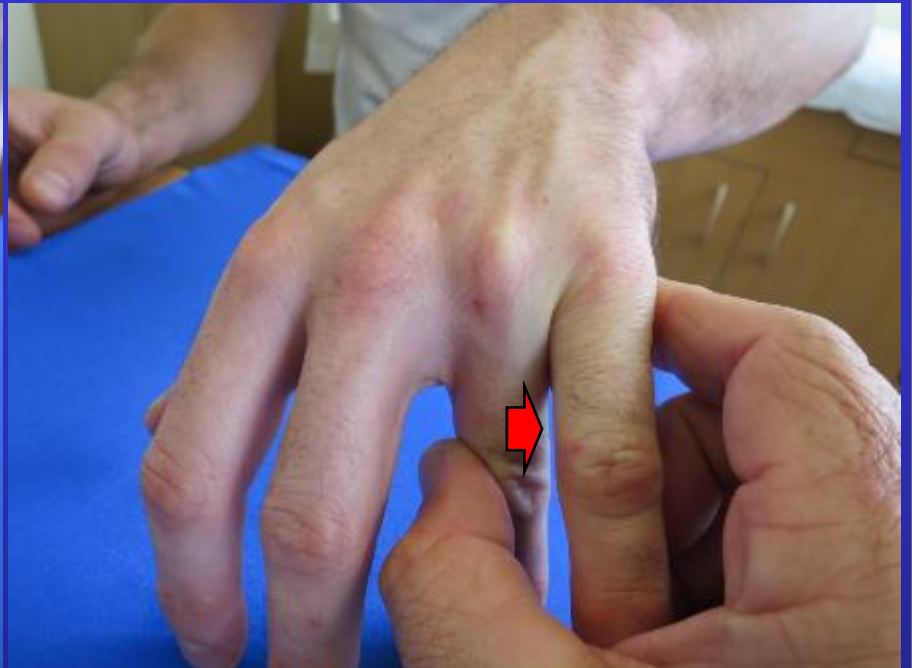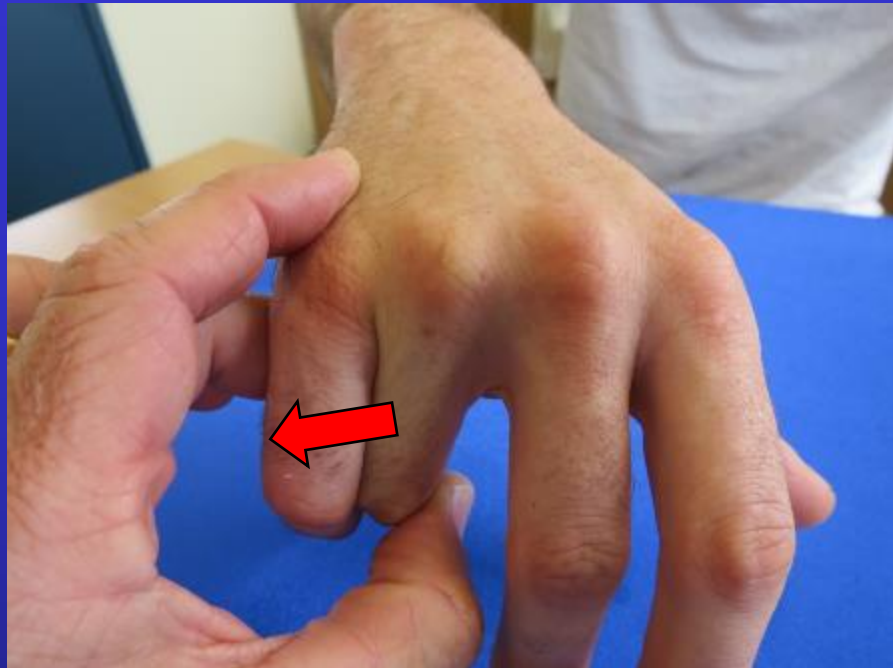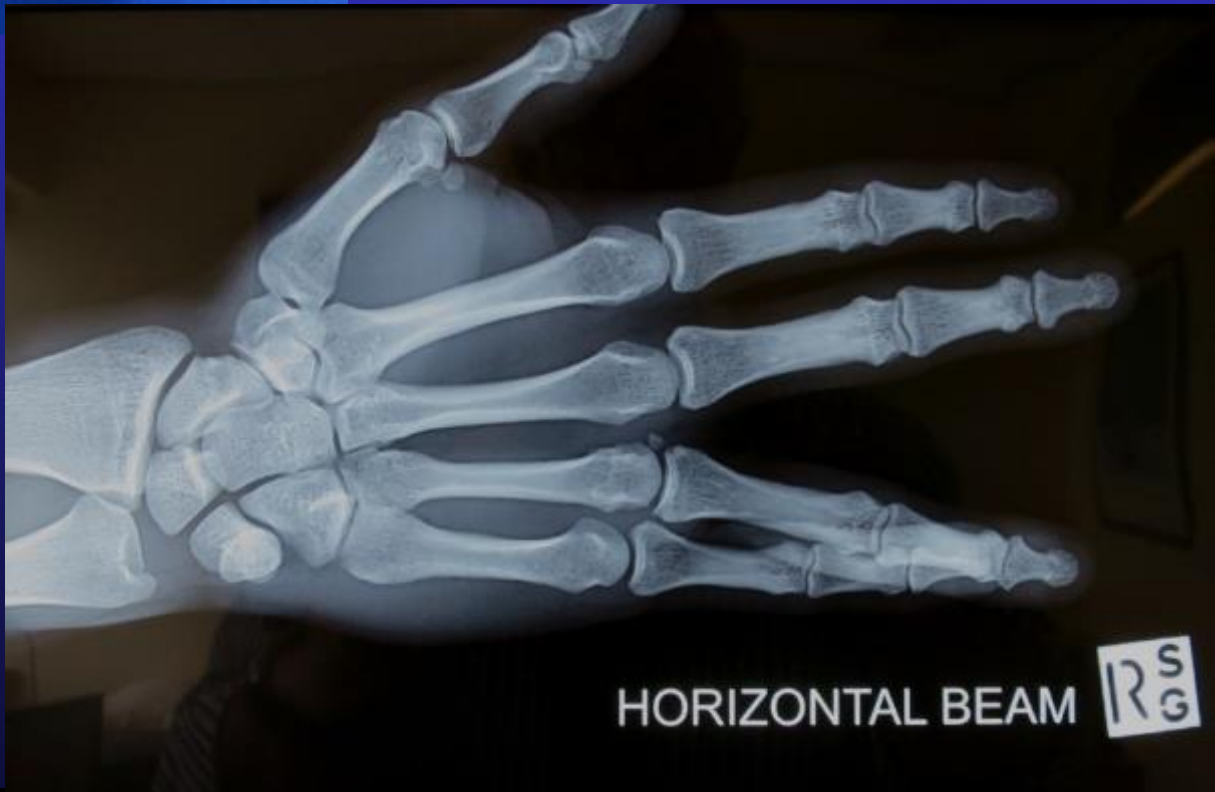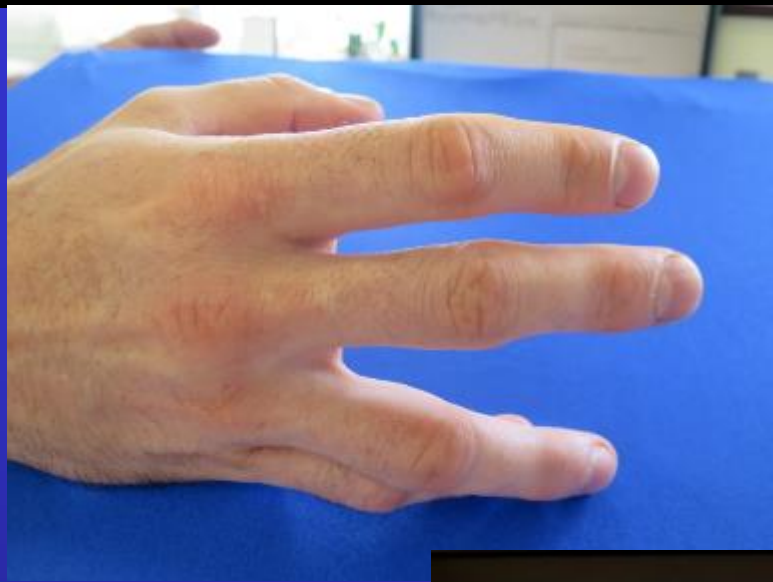# 30 M Martial Arts 6/12 ago



# 30 M Martial Arts 6/12 ago



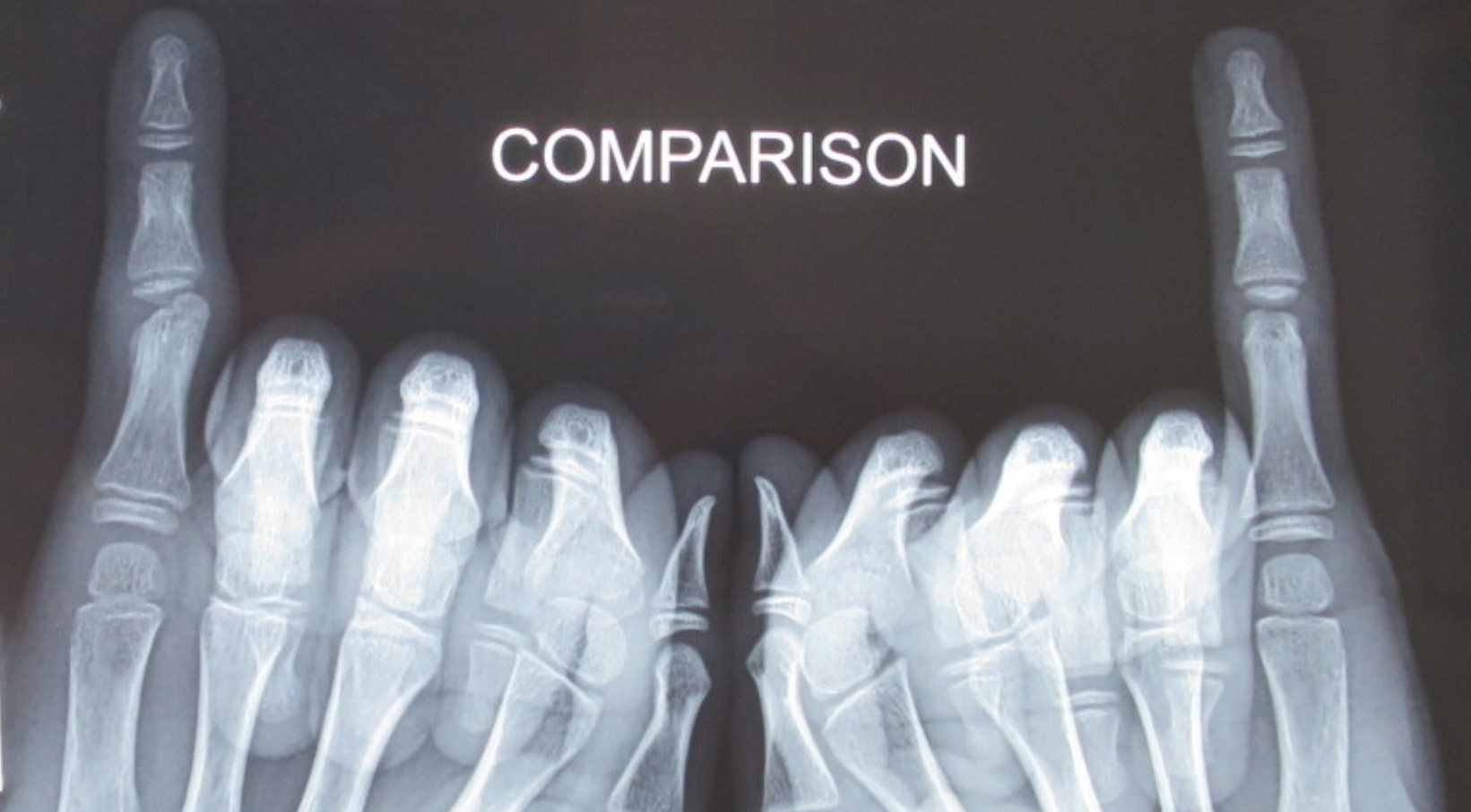



COMPARISON

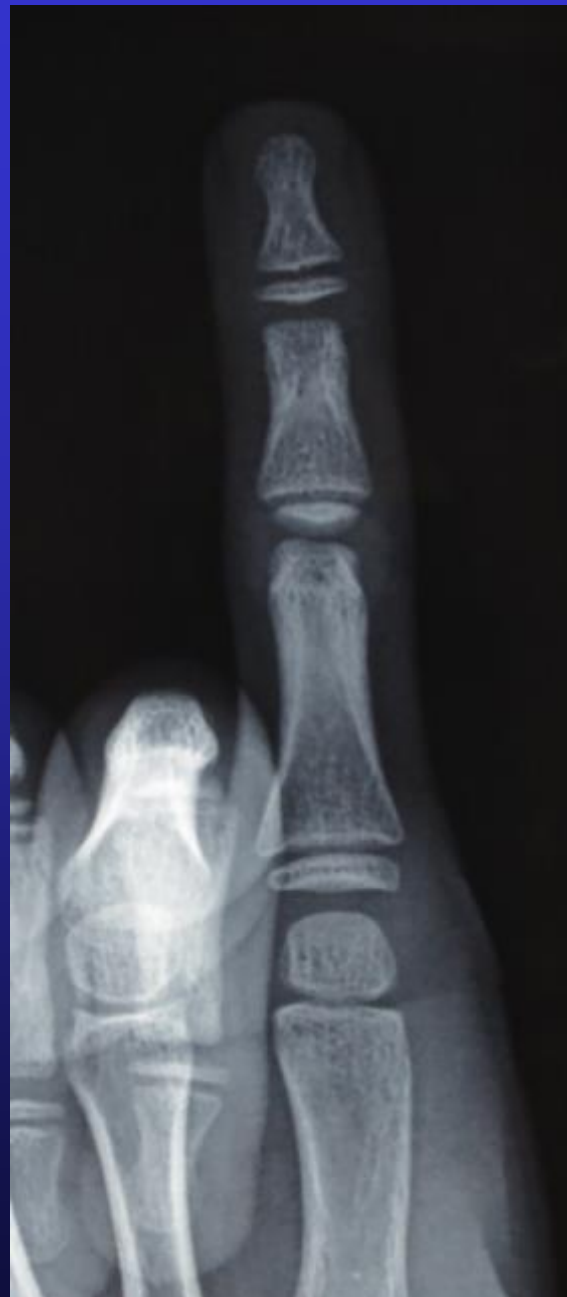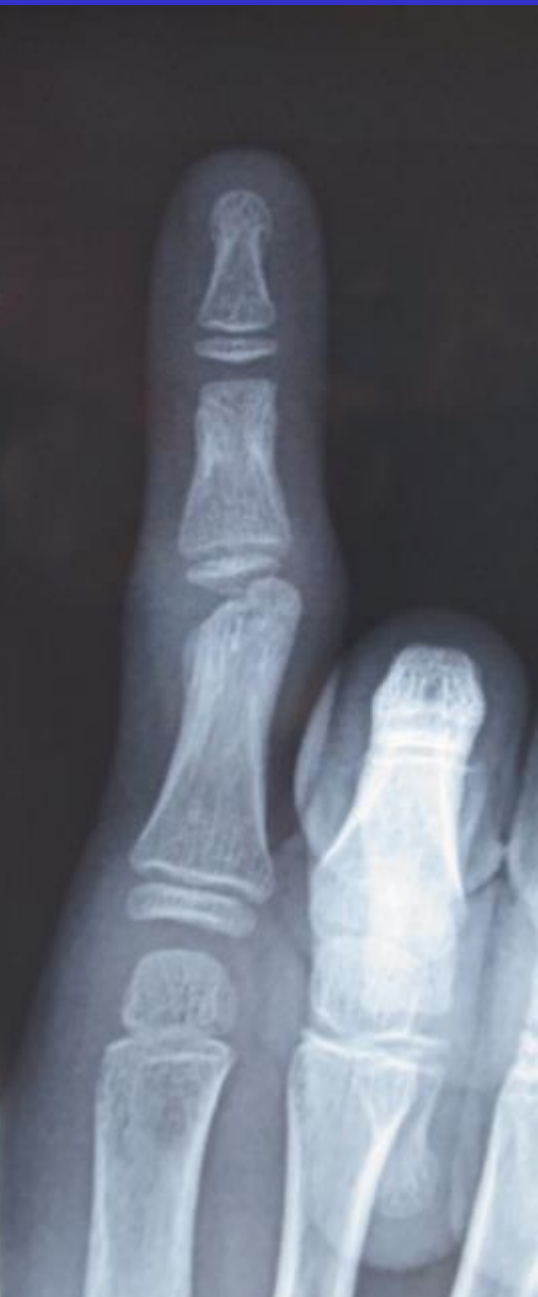L

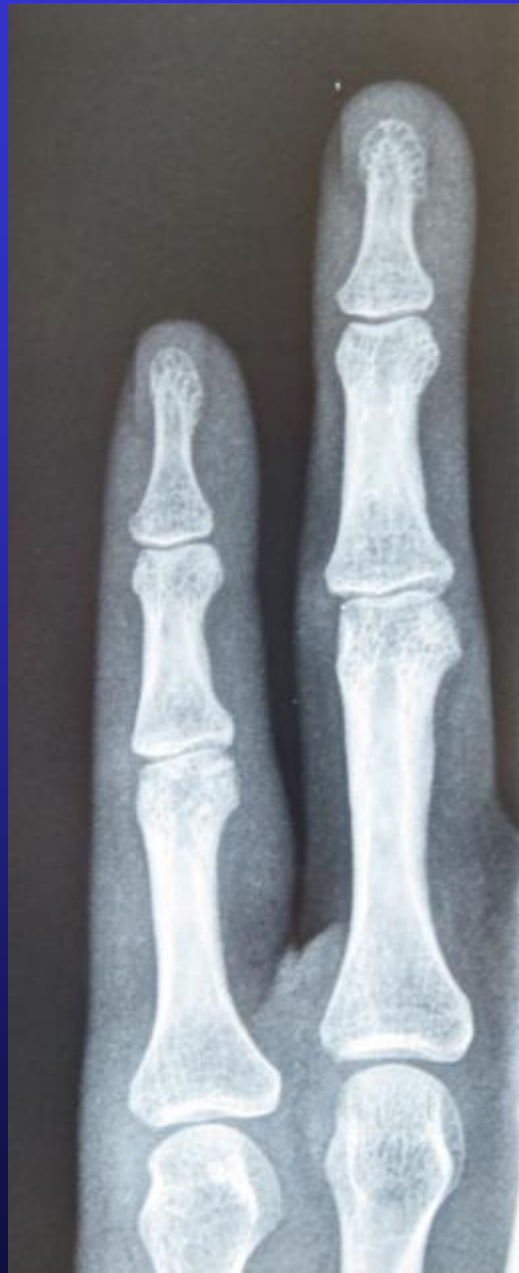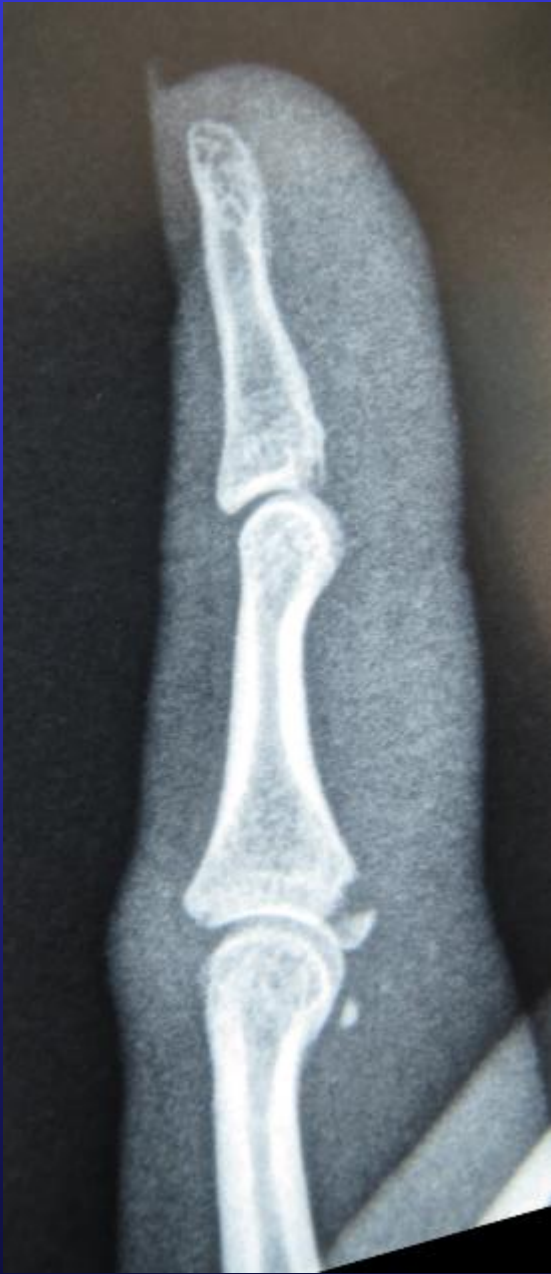J  
-13

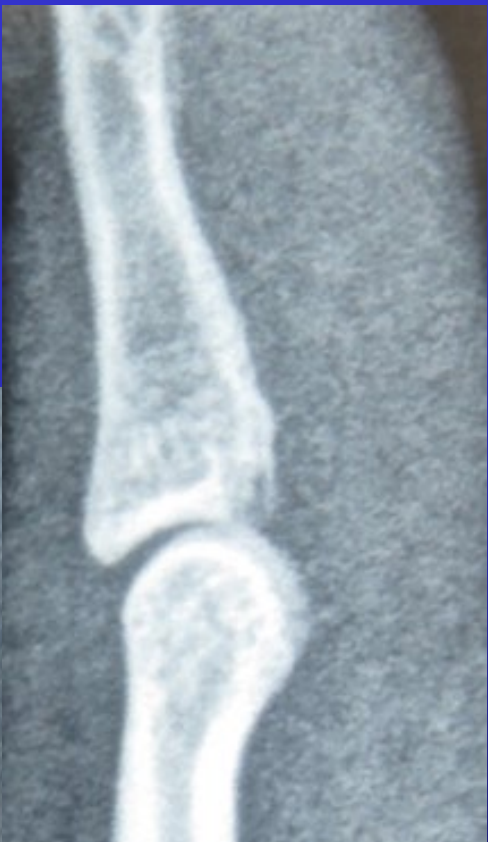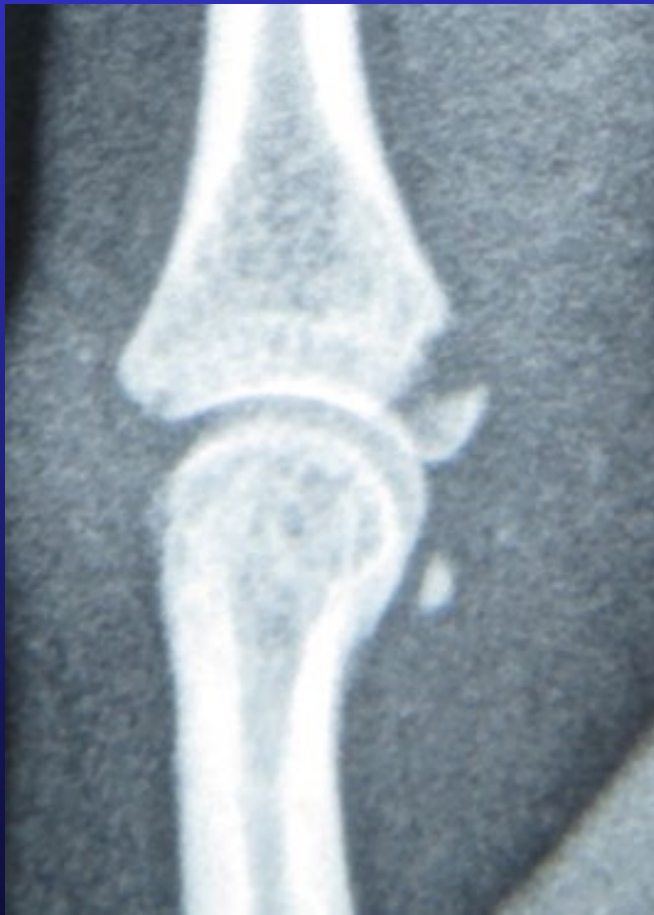

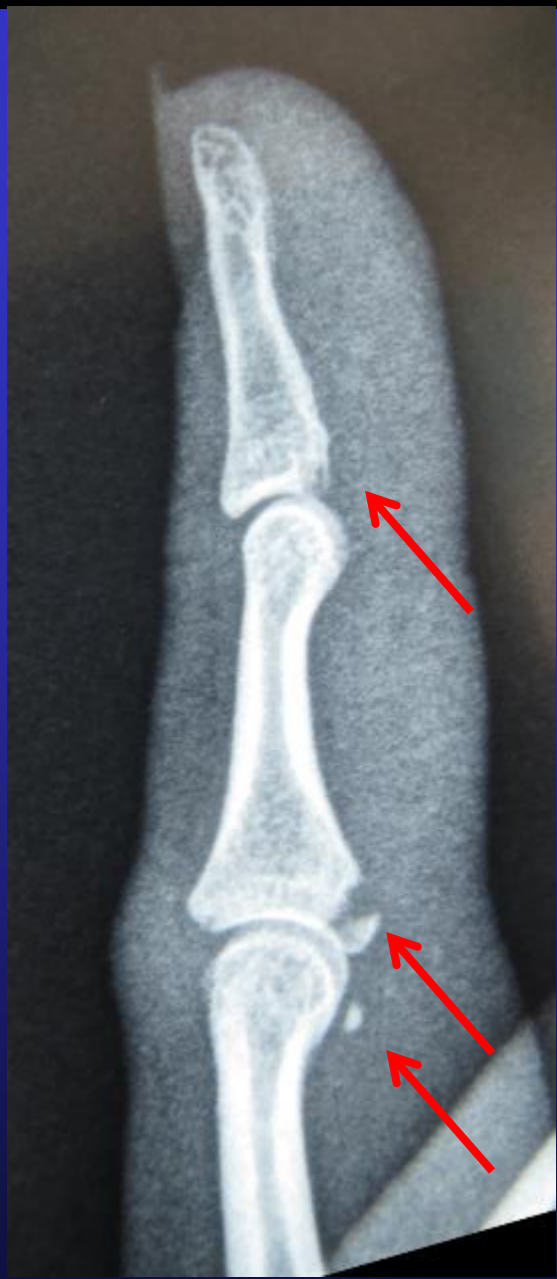
L

J  
-13











The End