

# A2 Pulley Reconstruction

## Dr Stuart Myers

Orthopaedic Hand Surgeon,  
Sydney Orthopaedic Specialists

[www.myhand.com.au](http://www.myhand.com.au)

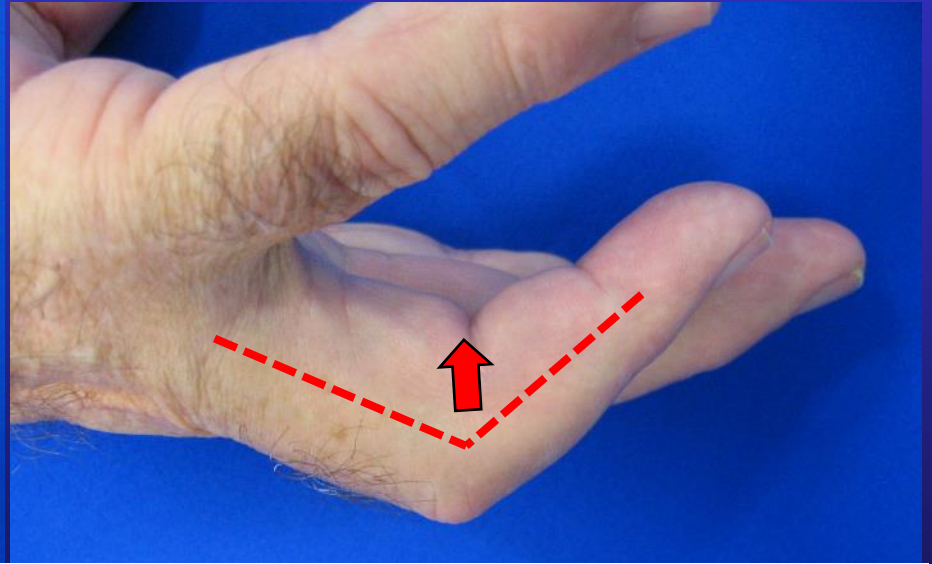
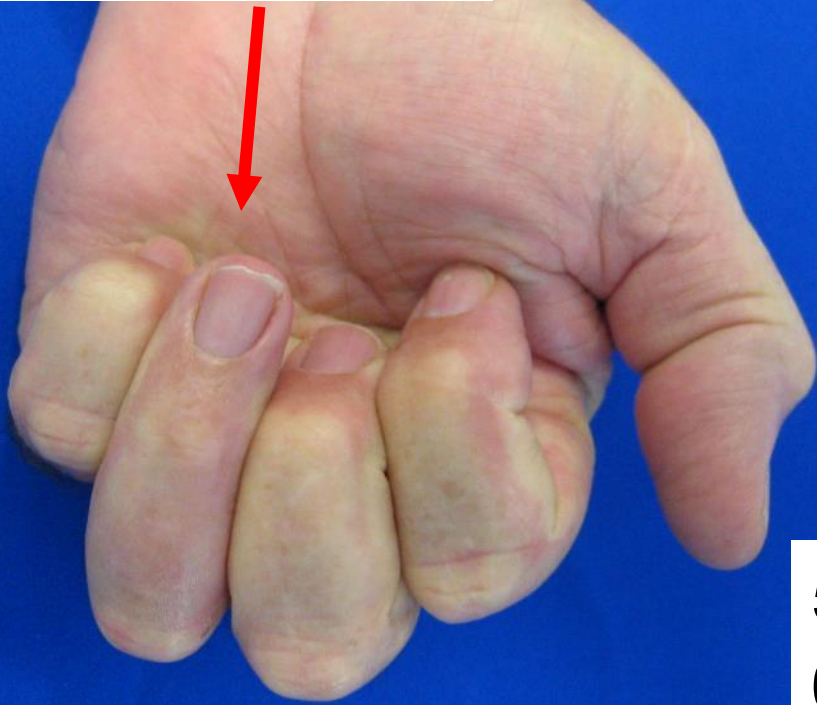


KAREENA  
PRIVATE HOSPITAL



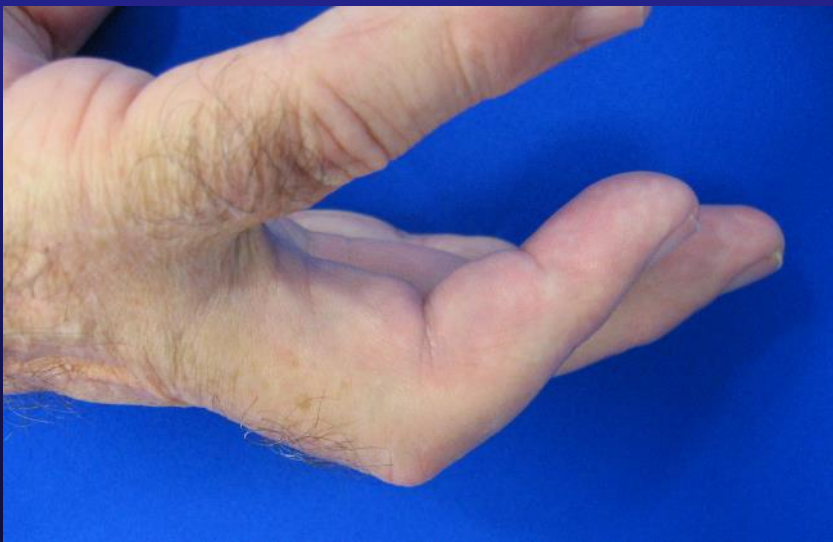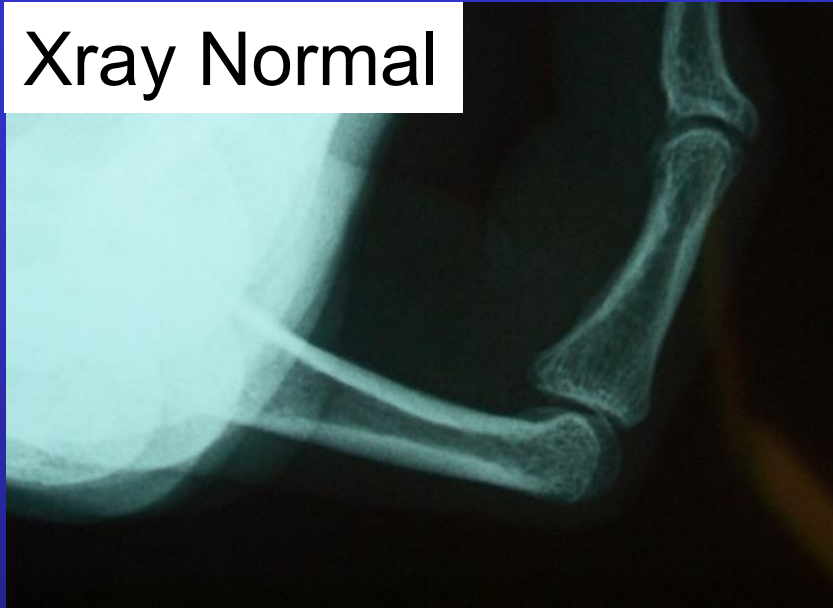
SOS  
SYDNEY  
ORTHOPAEDIC  
SPECIALISTS

Limited flexion

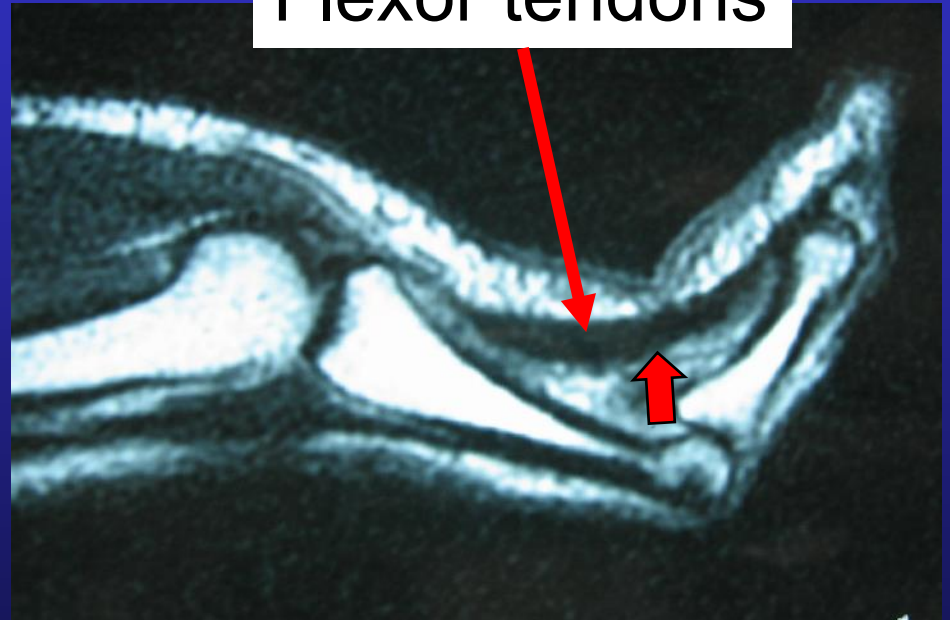


5 months post injury  
60\* FIXED flexion deformity

Xray Normal

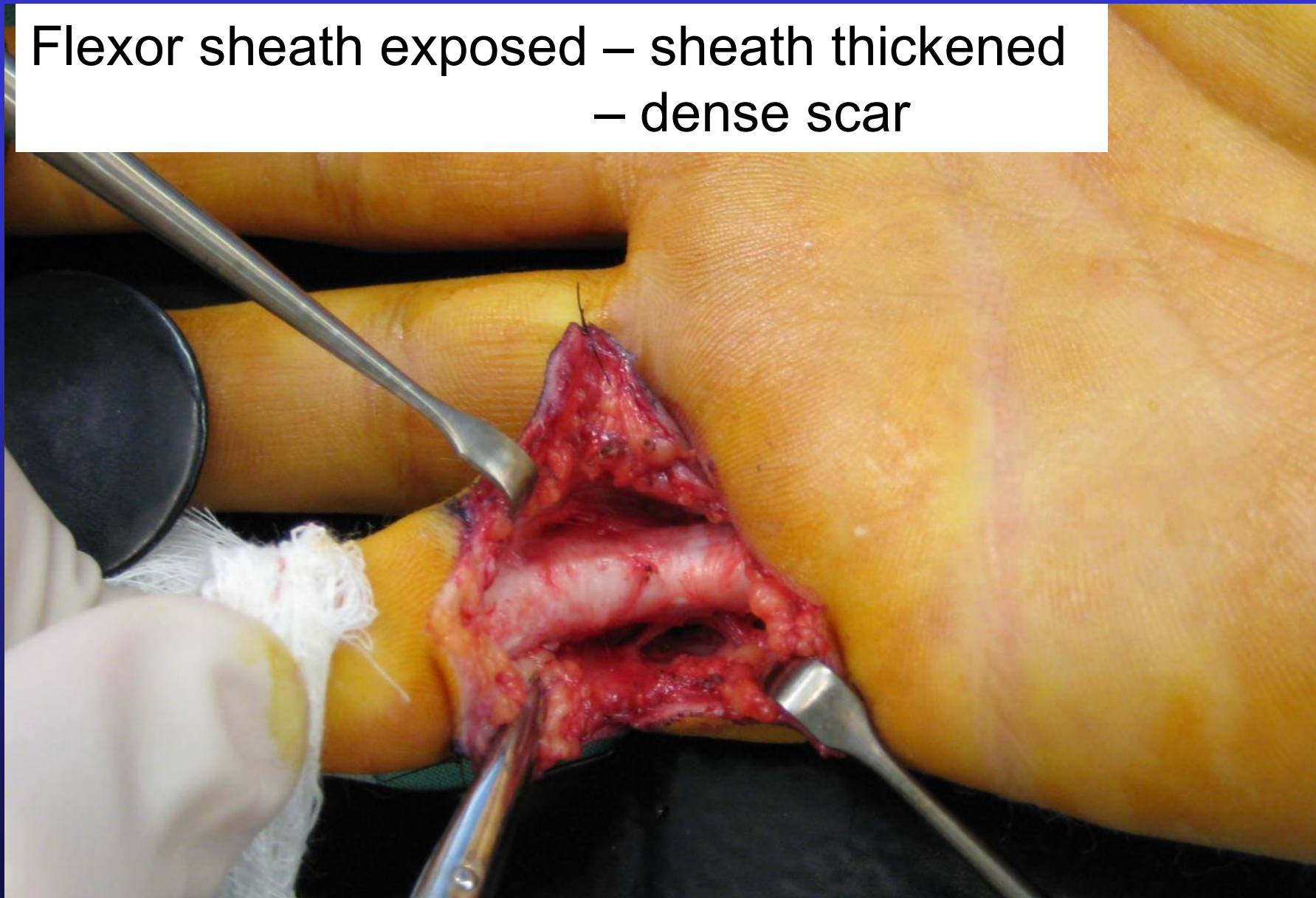


Flexor tendons

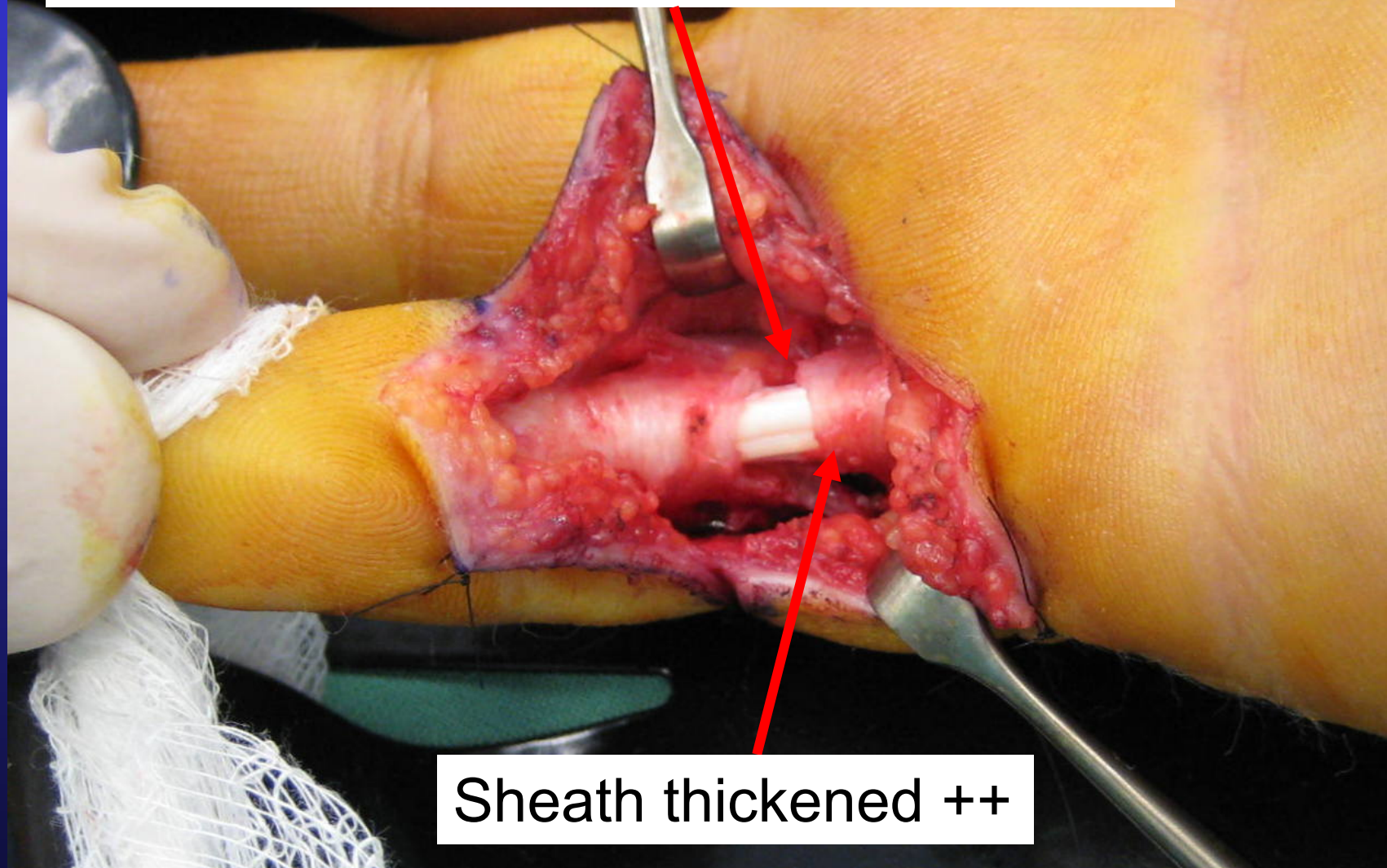


“Bowstringing”

Flexor sheath exposed – sheath thickened  
– dense scar

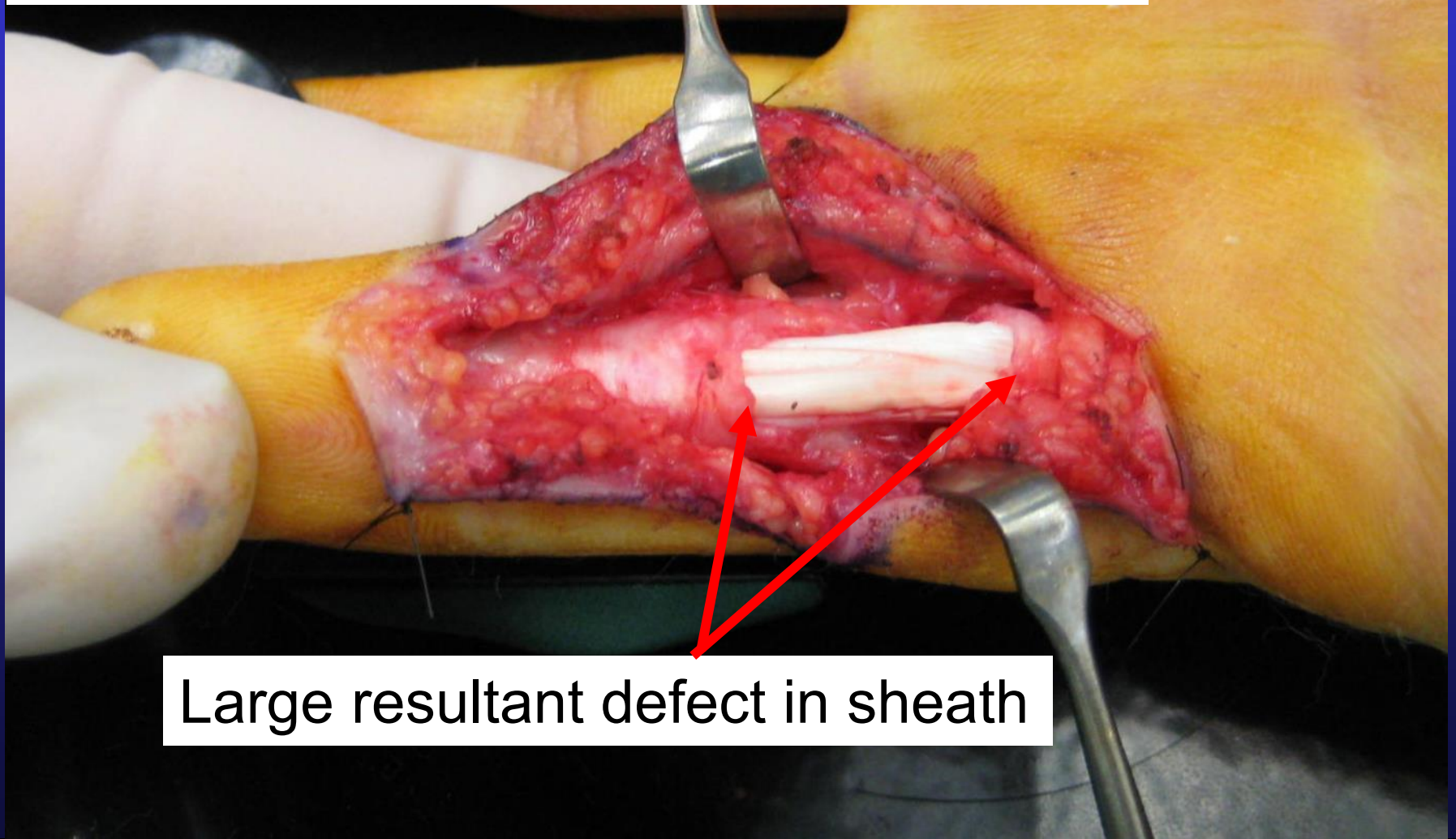


Sheath incised just proximal to PIP joint  
– Joint still stiff



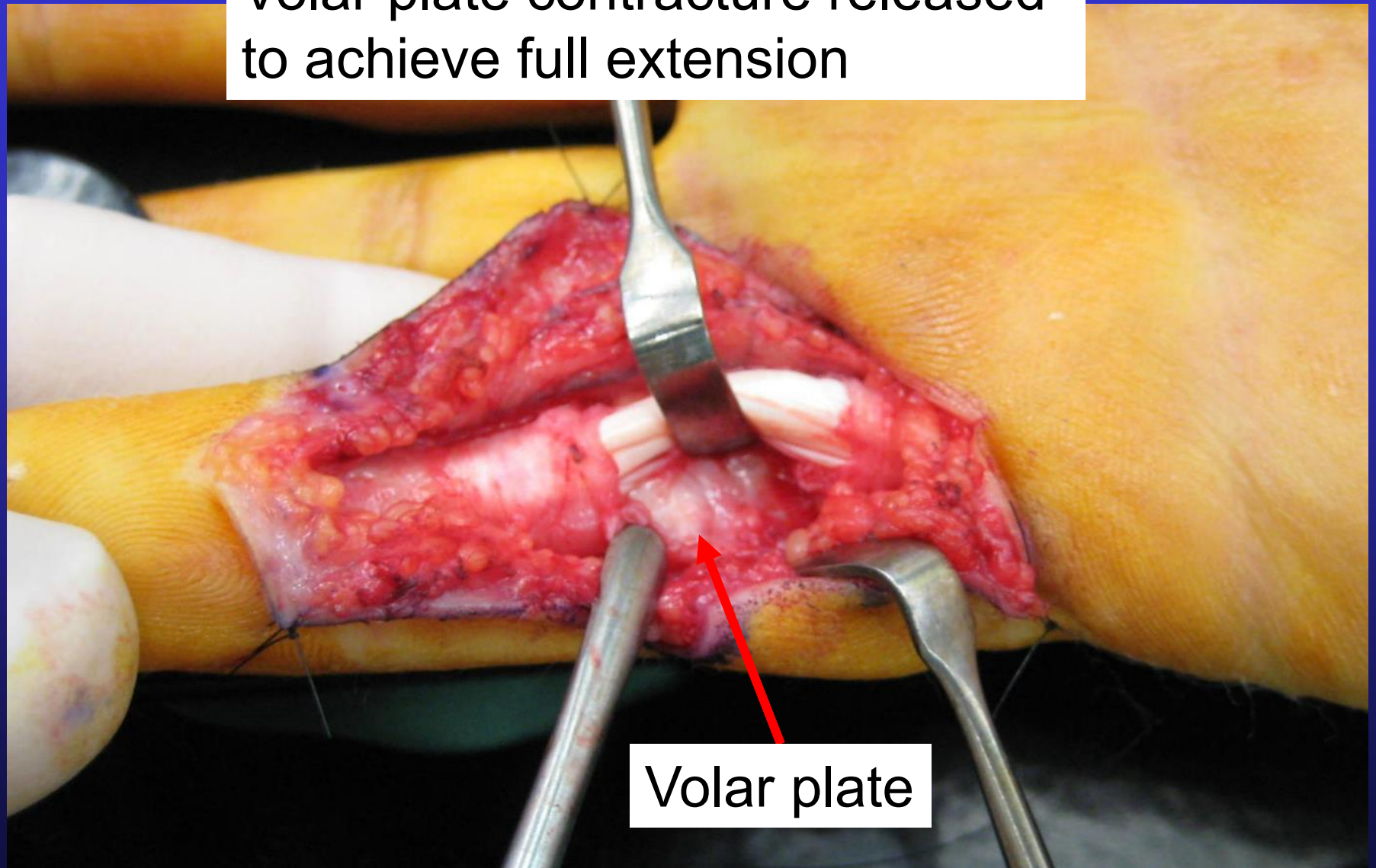
Sheath thickened ++

Joint manipulated into near full extension



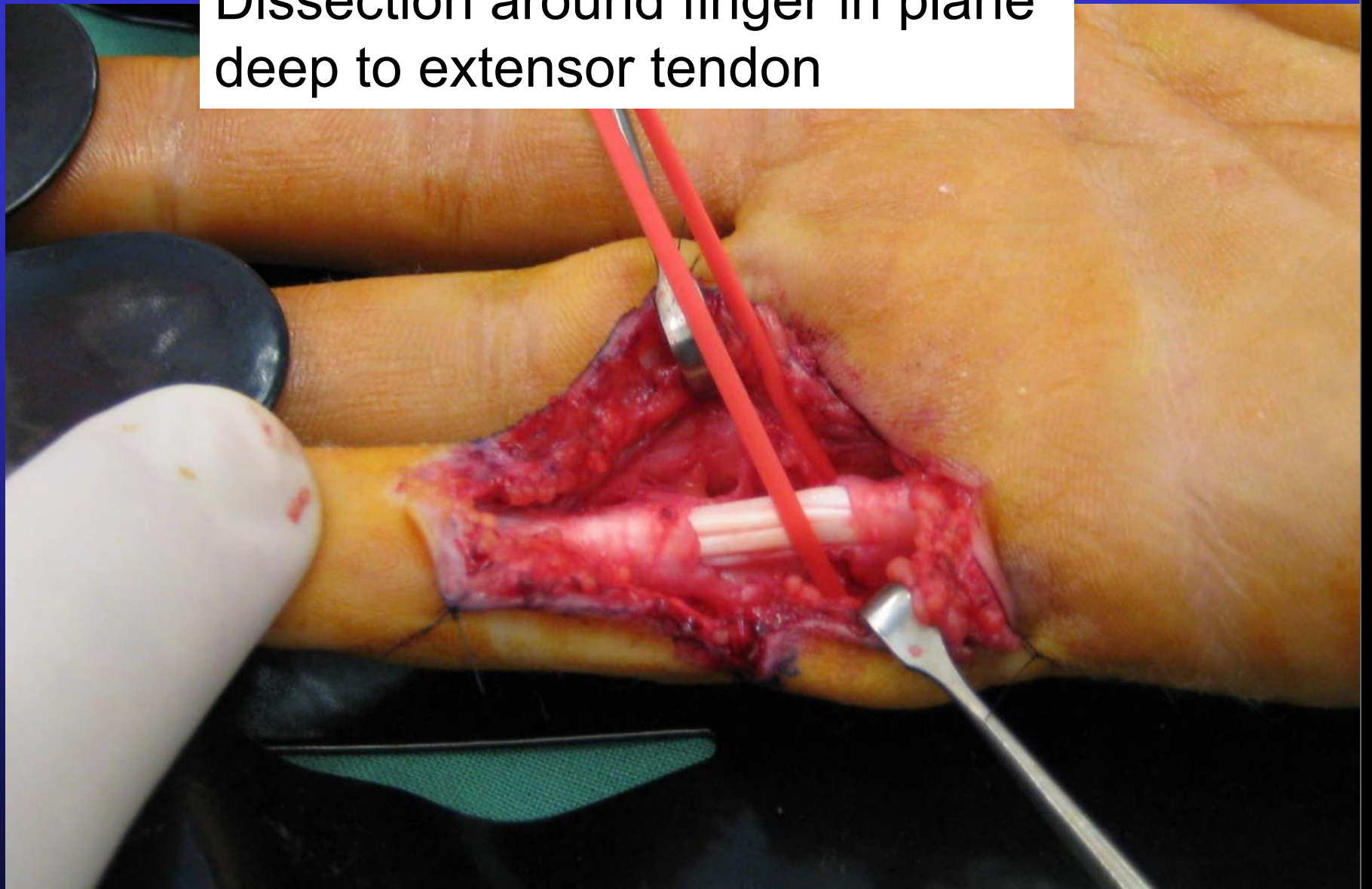
Large resultant defect in sheath

Volar plate contracture released  
to achieve full extension

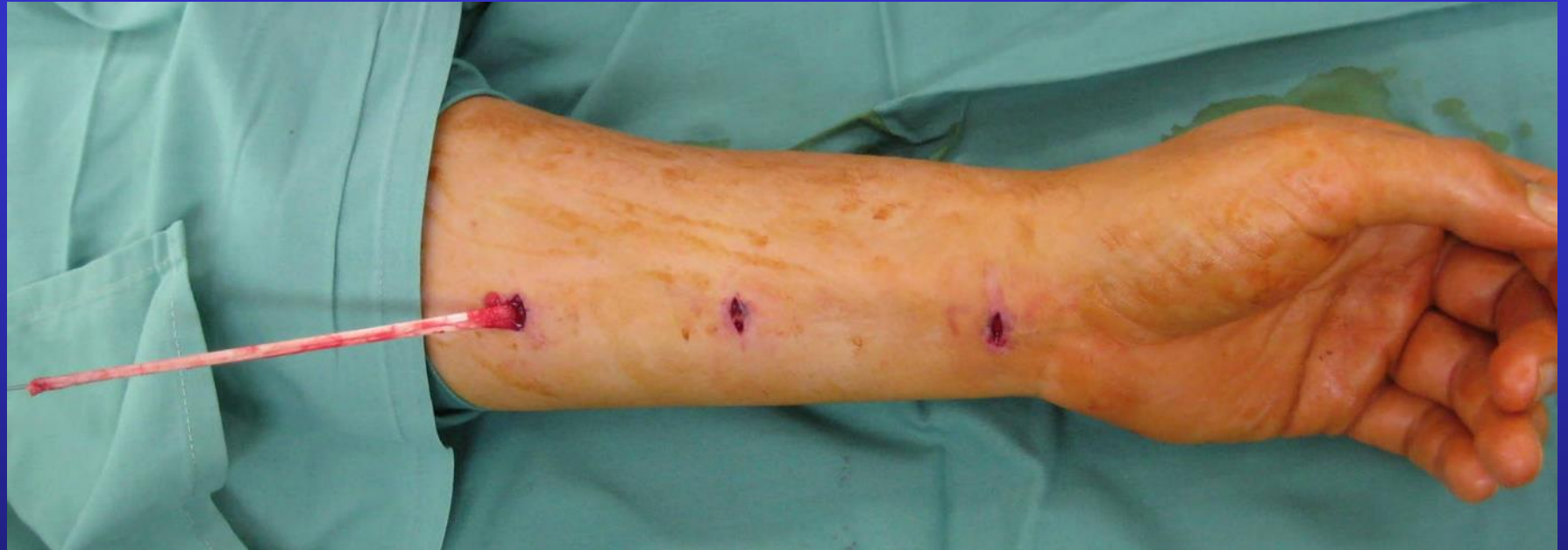

Volar plate

Dissection around finger in plane deep to extensor tendon

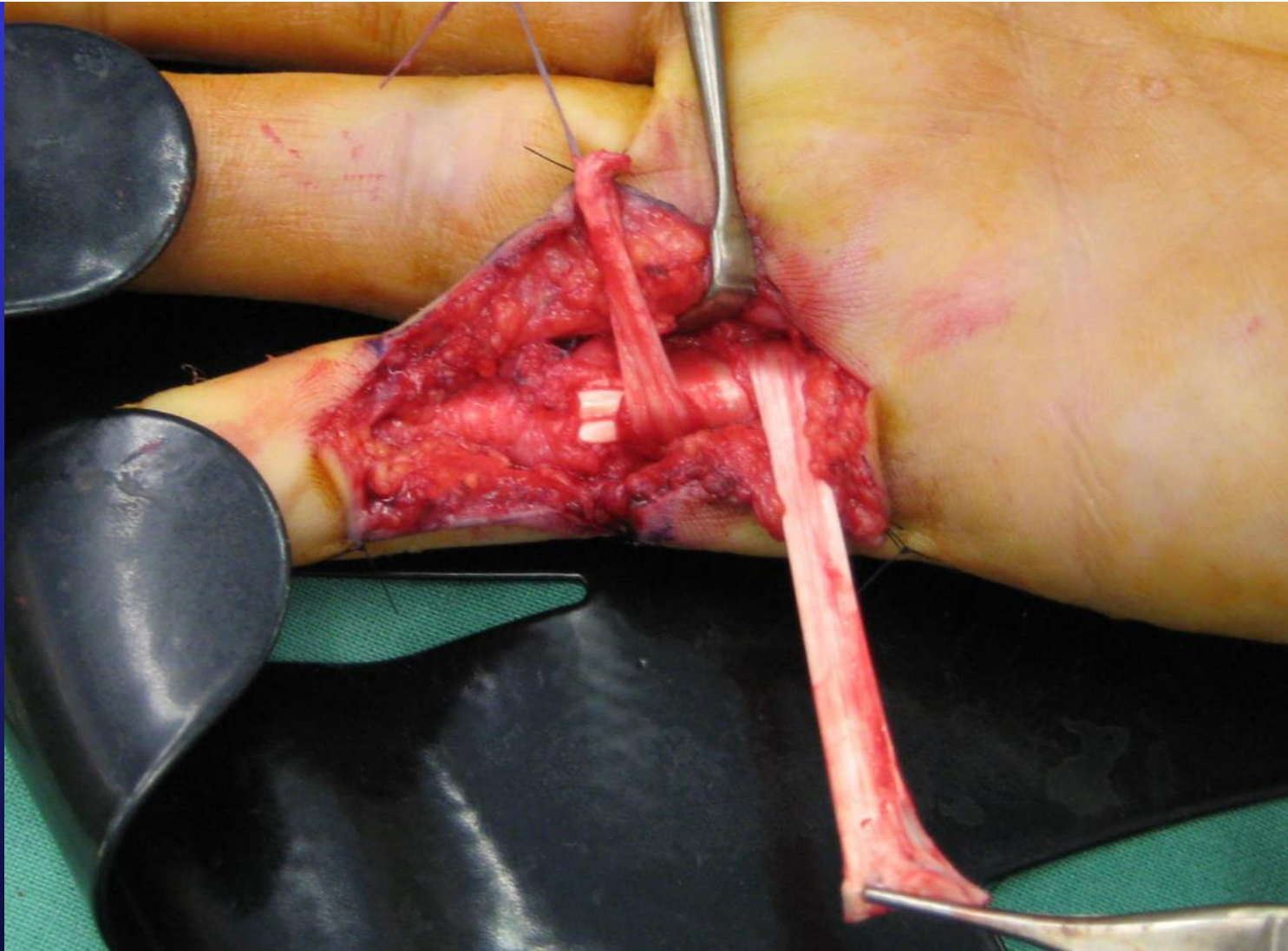




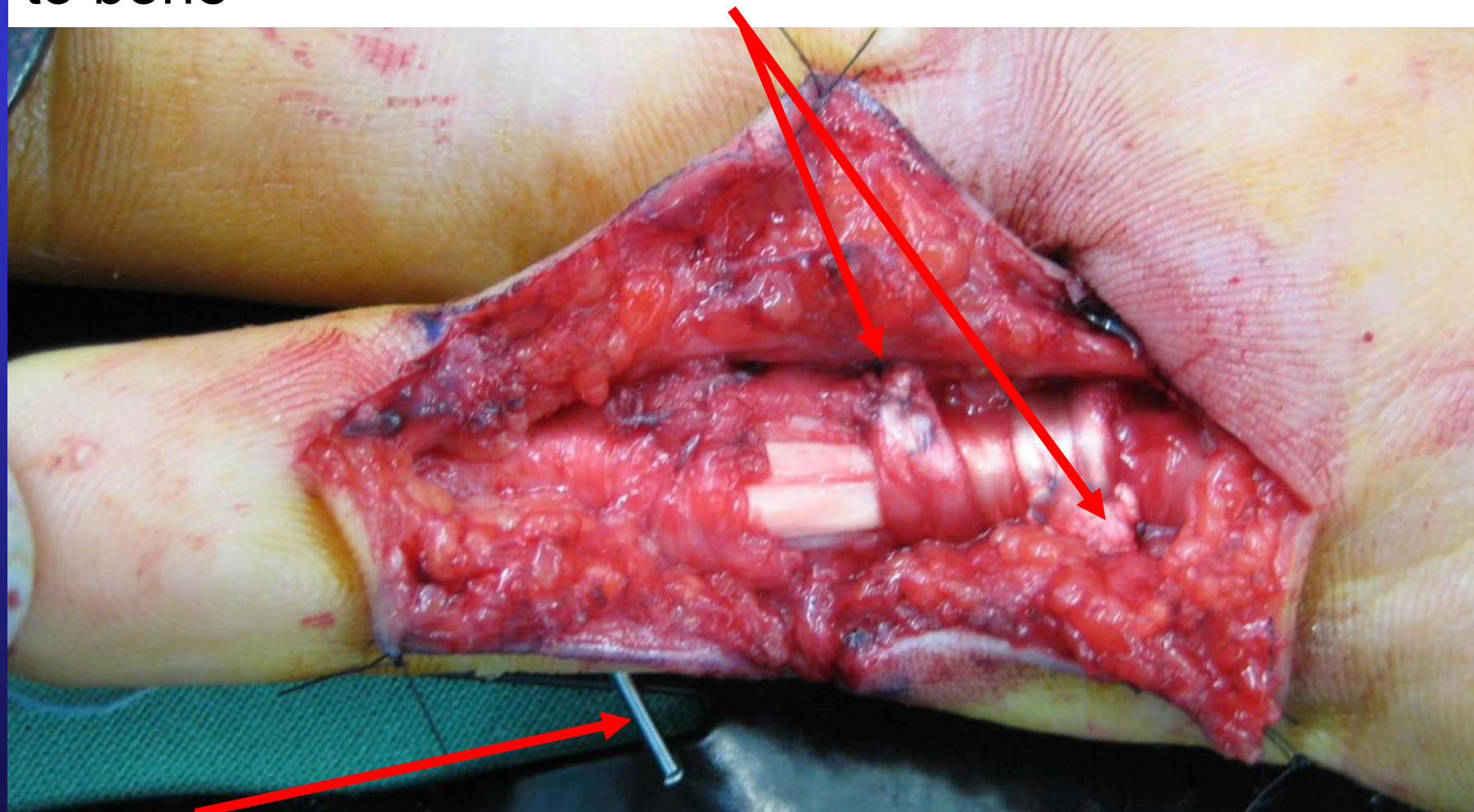


Palmaris longus tendon graft harvested through small incisions

Graft wrapped around finger over flexor tendons  
Deep to extensor tendon

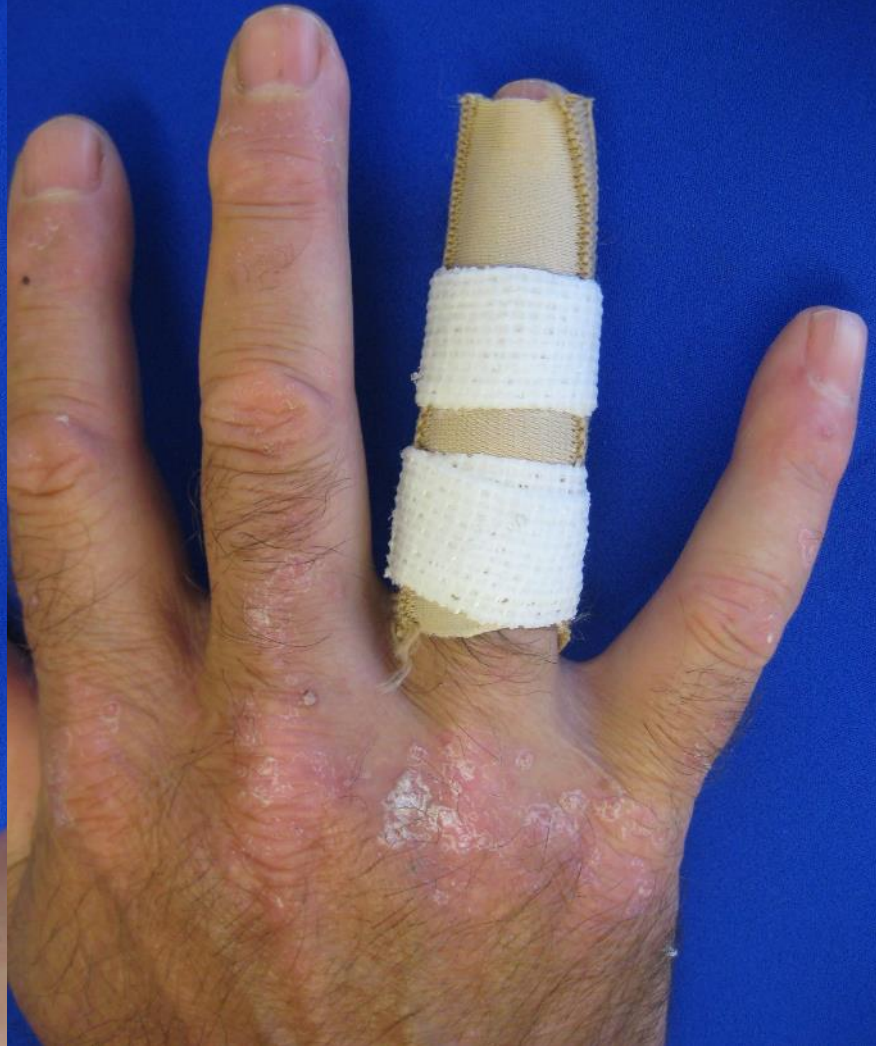
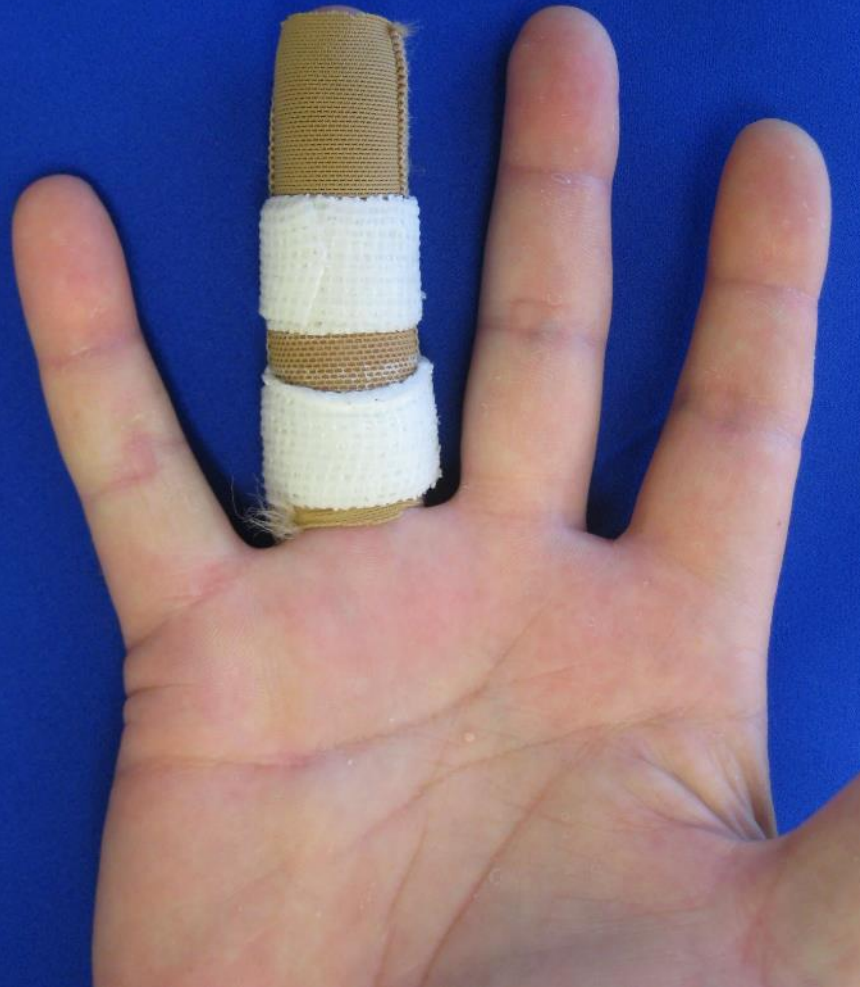
Graft sutured to edge of existing sheath attachment to bone

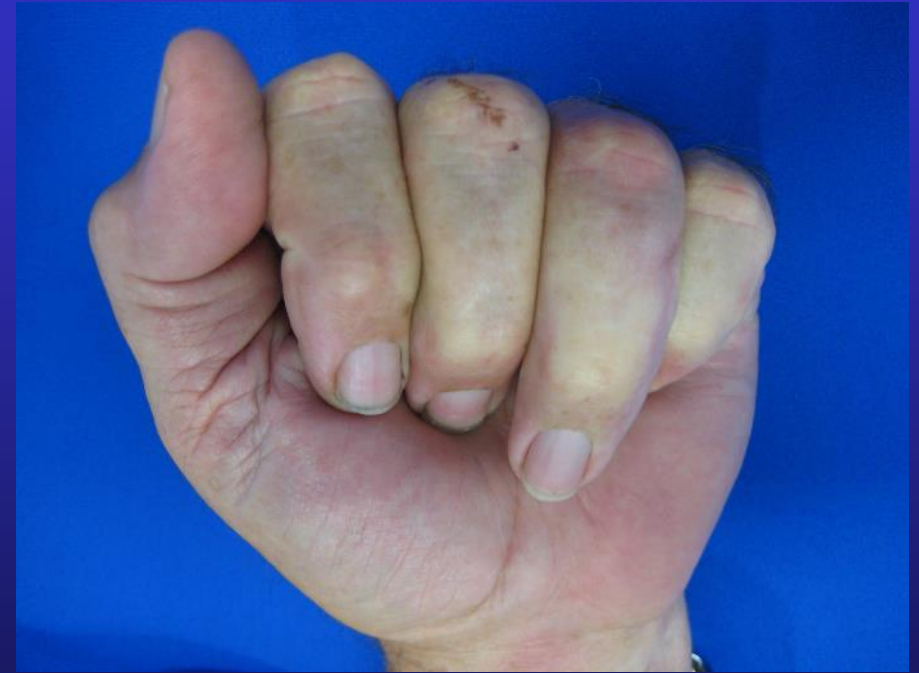
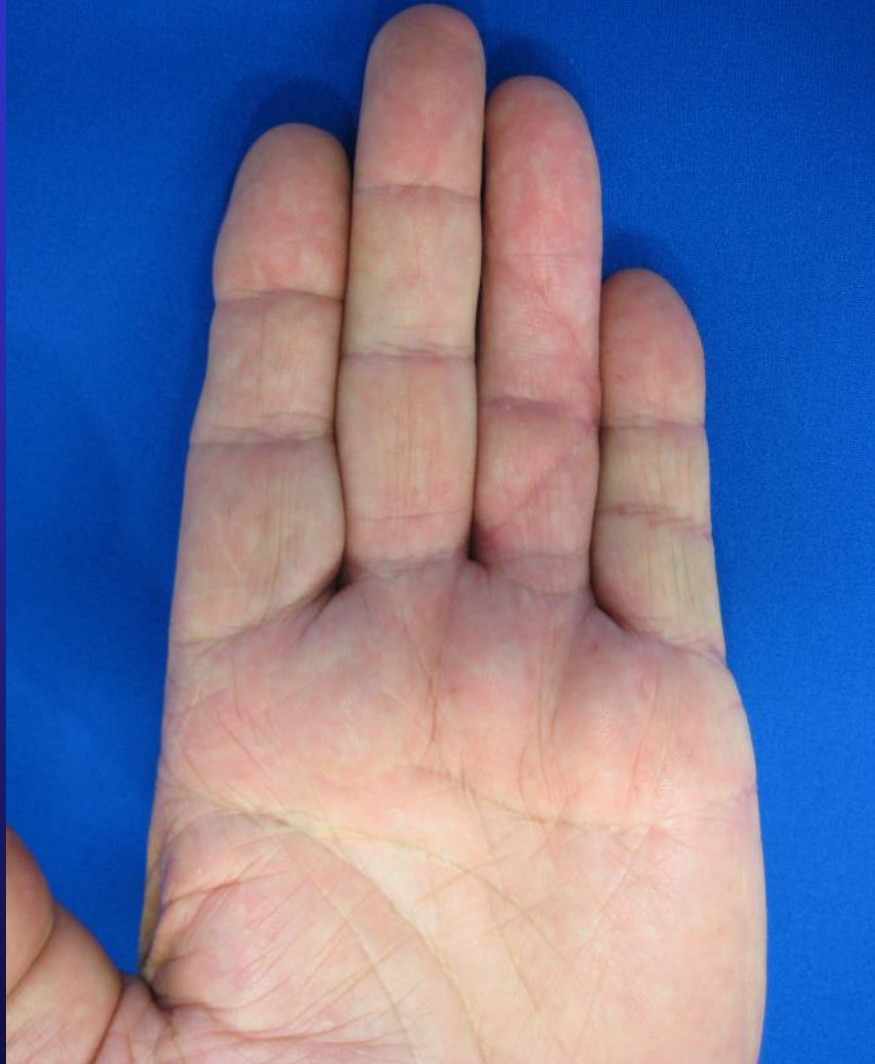
Wire inserted across PIP joint to hold full extension

Ring splints protect flexor sheath but allow range of motion after wound healed and wire removed at 3/52



Near full extension but still not full flexion



A nighttime photograph of a city skyline with numerous illuminated skyscrapers. The lights are reflected in the water in the foreground. A yellow rectangular box is overlaid on the image, containing the website address.

[www.myhand.com.au](http://www.myhand.com.au)

**The End**